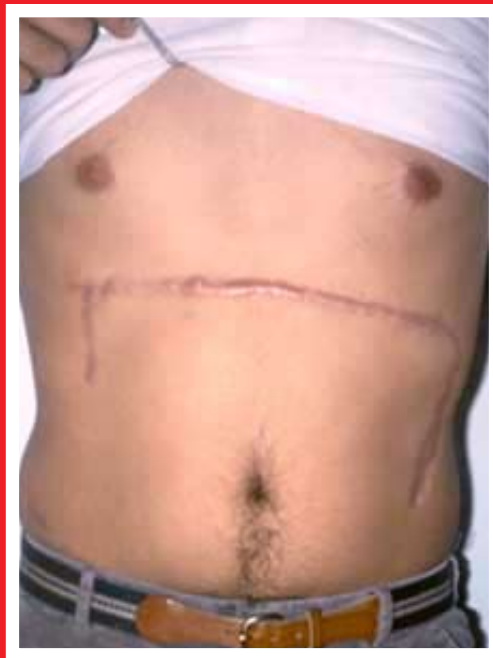

Abdominal Pedicle Flaps To The Hand And Forearm



**John C. Kelleher
M.D., F.A.C.S.**

Chapter Four:

INDICATIONS FOR PEDICLE FLAP COVERAGE

Local flaps are preferable to distant flaps but are limited for use by area requirements, rotation limitations, and blood supply which may be compromised by the original trauma.

In general, distant pedicle flaps are indicated for coverage of exposed bones, joints, tendons and nerves if these vital parts are to be retained and recover their maximal function in the restoration of the essential ingredients of pinch and grasp. Flaps may also aid recovery of motor or sensory nerve function by replacing firm constricting scar tissue with soft, well-vascularized tissue.

If the wound circumstances are such that the pedicle coverage is better done as a deferred procedure, then the use of the 'parasitic' skin graft or other biological dressings to obtain wound closure is indicated. Secondary flap replacement may afford the same advantage as we get with a primary flap, but there is usually some residual deep fibrosis and stiffness that remains. The primary pedicle flap has the benefit of providing a supple, soft, flexible skin coverage with its own vascularity carried in from the subdermal plexus.

Example case: A 24-year-old white male was involved in a motor vehicle accident and suffered a severe degloving injury to the dorsal radial side of the right hand and wrist. (See photo 4.A)

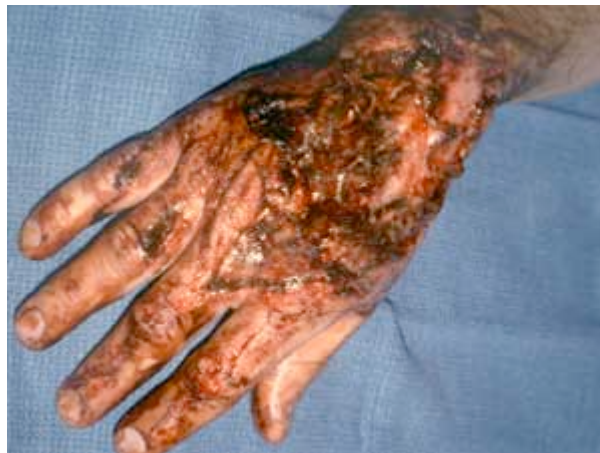

Photo 4.A

Operative note: After a full clinical and radiographic evaluation, the patient was taken to surgery and found to have a large soft tissue coverage loss from the wrist to the metacarpal phalangeal level and from the thumb-index web to the ring metacarpal area. All this tissue was contaminated with gravel and road material. There were no injuries to the volar side of the hand, and all digits were well perfused. Extensor tendons to the right index and long finger were avulsed. A portion of the extensor digitorum communis to the ring finger was destroyed.

The wound was debrided and irrigated with saline until considered surgically clean. The wound border defects were excised in "V" points to break up a straight line healing scar and to increase the linear length of capillary bridging from the flap to the recipient skin borders. (See photo 4.B)

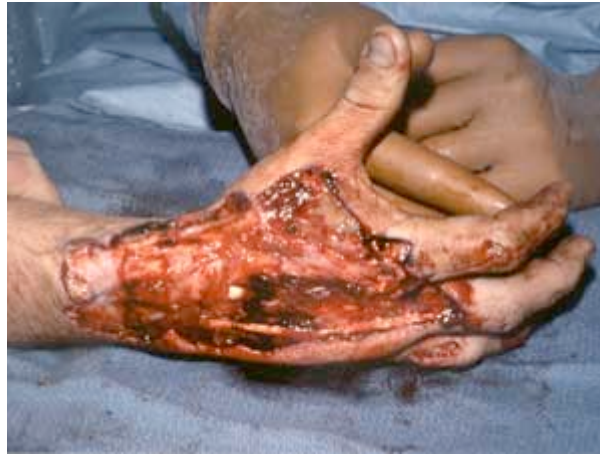

Photo 4.B

This area of skin loss and planned flap replacement measured 15 cm. along the radial side of the hand and forearm and 9 cm. transversely. A sheet of plastic was laid over the debrided dorsum of the hand which included the "V" point flaps. A marking pen was used to outline a pattern on the plastic for the pedicle. This pattern was then cut out from the sheet of plastic and stapled to the **recipient site**. The arm and stapled pattern were then brought into the abdominal donor area. The stem of the pattern was then stapled to the appropriate area of the abdominal wall. The staples holding the pattern to the recipient area on the hand or upper extremity were removed to allow the pattern to then lie flat on the abdominal donor area.
(See photo 4.C)



Photo 4.C

This then allows us to raise a donor flap of the exact size as the defect on the recipient hand. It is very important that the donor flap be of the **exact same size** as the defect to be covered on the dorsum of the hand. It is important because if the flap is not the exact same size and shape, there may be some oblique traction applied to the flap which may impede the arterial supply and venous return to the thinned abdominal pedicle flap. This flap is raised from the deep fascia of the abdominal wall and turned upward or downward as the need requires and for which the surgical plan calls. The donor area is then partially closed by advancing the borders of the donor area and tacking the deep corner of the dermis to the deep fascia with absorbable suture. The remaining open areas are closed with a split thickness skin graft and tie-over dressing. **It is important to leave all fat in place on the pedicle until the donor area is closed so as to avoid desiccation of the tissues of the pedicle.** At this

point, the pedicle is defatted down to the desired thickness to cover and replace the skin and subcutaneous tissue on the back of the hand.

Chapter Four: INDICATIONS FOR PEDICLE FLAP COVERAGE

The technique of defatting is critical to the success of these thinned flaps. The surgeon allows the flap to drain over the non-dominant hand with the fat side up. The fat is best trimmed with scissors until there is only a thin layer covering the essential subdermal plexus. The deeper fat is contained in large globules; whereas, the more superficial fat near the subdermal plexus is contained in very small globules. This allows the surgeon to be aware when the subdermal plexus is near. This defatting should only be performed on the flap to be retained at the recipient site. The pedicle and the stem of the flap are left thick. In this case, the slides show a dotted line across the stem of the flap (see photo 4.D.) which indicates that the "parasitic fat" is removed to that point.

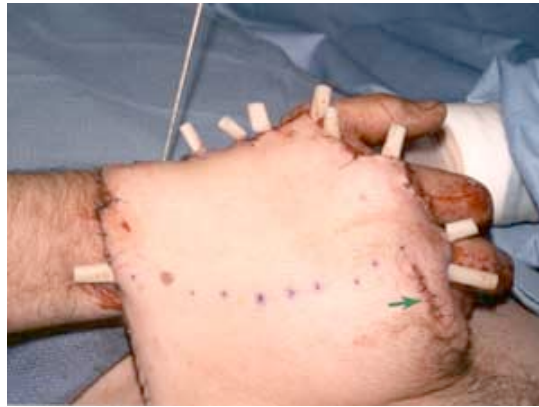

Photo 4.D

After adequate defatting of the flap and adequate hemostasis has been obtained, the flap is then inset with simple and half-buried mattress sutures only in the skin. Since the stem side of the flap is wide open, there is usually no need for any type of drain. However, in this case, Penrose drains were used in the suture line, which were removed 24 to 48 hours post-op. We can see some ecchymosis of the skin points at the distal edge of the flap (see photo 4.E) 2 days postop, however this will heal satisfactorily because of capillary bridging at the wound's edge.

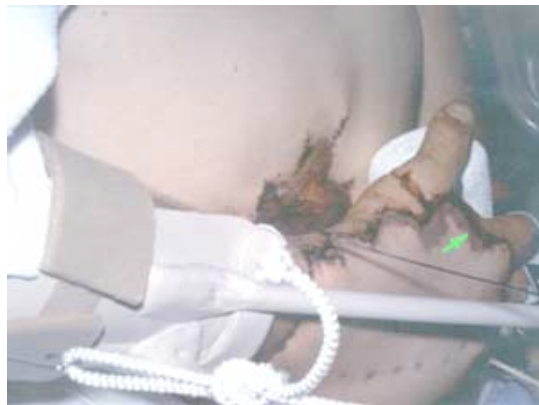

Photo 4.E

Operation II: After three weeks, the flap is healing well to its recipient site and is ready for division. Photo 4.F shows the appearance of the flap just prior to division of the pedicle. The pedicle is divided, and the wound is closed in a zigzag fashion, primarily. Multiple Penrose drains are used for 2-3 days along the hand recipient border when the flap stem is cut, thinned, and inset.

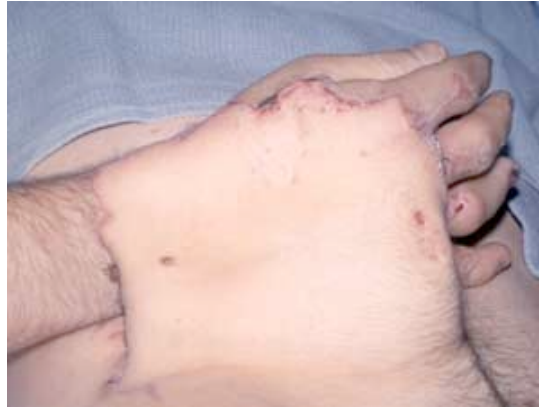


Photo 4.F

It is important to note that a number of well-respected plastic surgeons leave the stem open for 2-5 days before inserting the stem border because of a concern for possible infection and inadequate circulation. I have never found this necessary. In this case, at the time of the separation of the flap from the abdomen, the skin graft covering the donor site was excised, and the lower abdominal skin (pedicle) was advanced upward to leave only the peripheral scar. This technique of skin graft excision and coverage with the available abdominal skin can be obtained, in most cases, in either one or two stages of surgery leaving only an irregular scar on the abdominal donor site.

Operation III: Four months later, palmaris longus tendon grafts were used to reconstruct the extensor tendons of the index and long fingers. This is done by exposing the area through the borders of the flap. These flaps can be raised with impunity allowing tendon graft reconstructions and other procedures and then simply closing them in the original incisions.

Two years later, the function of the hand is good with full extension in all joints to a straight line and flexion in all joints to the distal palmar crease. A valid personal criticism would be that perhaps a little too much fat was left on the flap at the time of this procedure. Total reconstruction time was five months. (See photos 4.G & H)

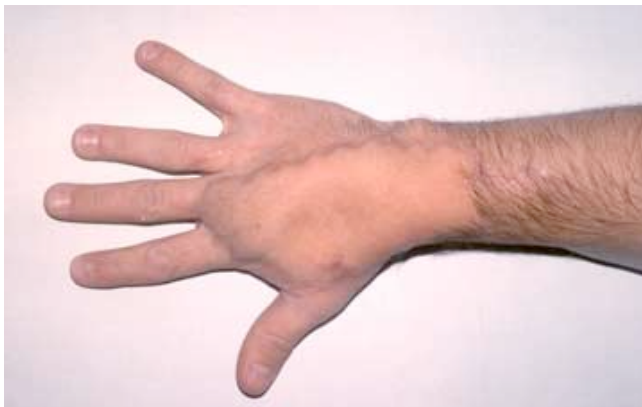

Photo 4.G

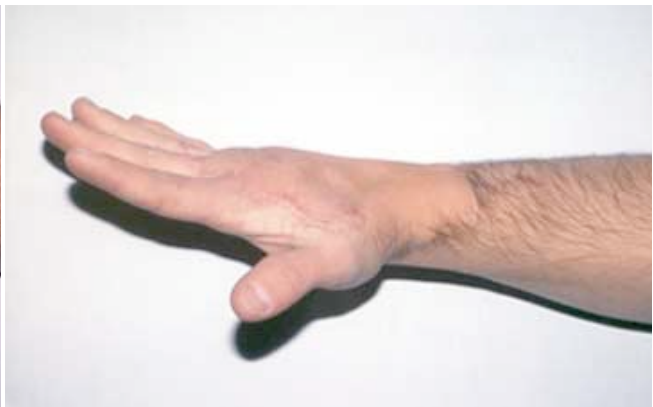

Photo 4.H