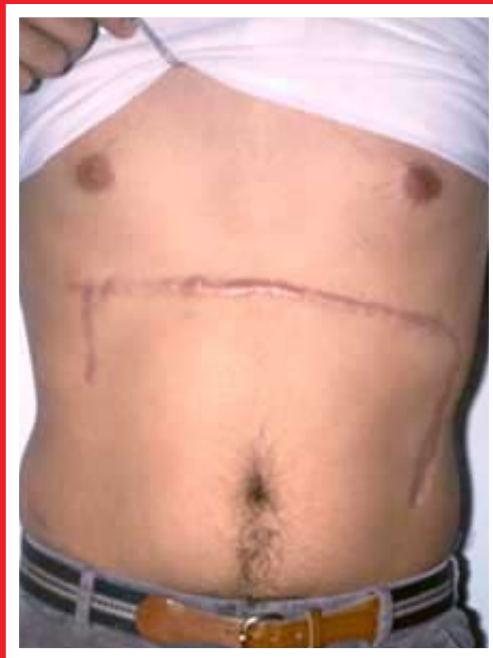

Abdominal Pedicle Flaps To The Hand And Forearm



**John C. Kelleher
M.D., F.A.C.S.**

Chapter Seven:

THE TECHNIQUE OF EFFECTIVELY DEFATTING AN ABDOMINAL FLAP

This is perhaps the most important chapter in this monograph. I am convinced that the ability to thin and defat the flap is the principle factor in the effective and successful transfer of these large flaps.

Once the plastic pattern is laid out on the abdominal wall, the skin is incised with a scalpel down to the plane of the abdominal aponeurosis, and the flap is then raised back to its planned stem. Bleeding is carefully controlled. The flap is not thinned until the donor area is completely closed and the flap is ready to inset onto the recipient site. This prevents desiccation of the final thinned flap and protects the subdermal plexus.

The donor area is closed by undermining in the plane of the abdominal aponeurosis and advancing the edges. The dermis is tacked down to the deep fascia after maximum advancement with multiple 2-0 gut sutures. If complete closure is not possible with this advancement, then a split thickness skin graft as a non-perforated sheet graft is sutured to the edges of the donor area and carried up onto the stem of the pedicle and held in place with a tieover dressing.

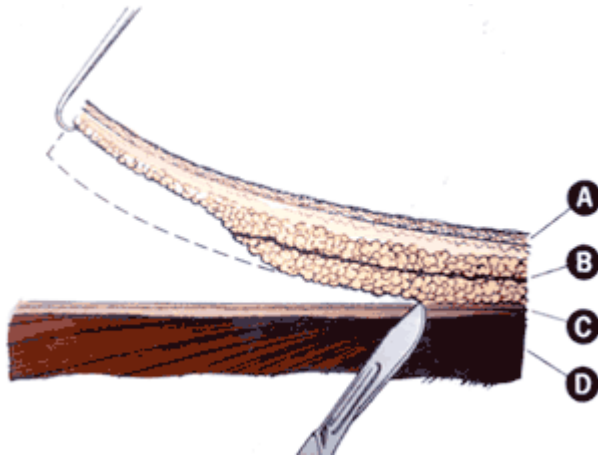


Figure 7.A

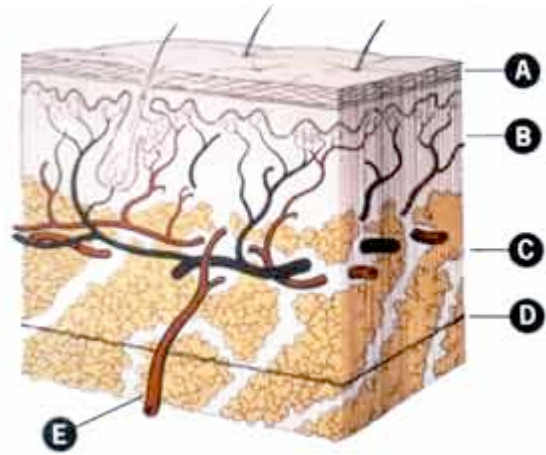


Figure 7.B

At this point, one begins the defatting of the flap to be laid on the hand. The very base or the stem of the flap is left full thickness (see figure 7.A) because there are major axial vessels deep in the fat that send perforators up to join the subdermal plexus (see figure 7.B). Only that portion of the skin flap that will be placed on the recipient site and remain as part of the reconstruction is thinned to the comparable thickness of the recipient skin area. All fat deep to Scarpa's fascia is removed, as is Scarpa's fascia itself. Occasionally Scarpa's fascia can be retained as an interpositional pedicle of tissue in special situations. This leaves the important layer of fat; that is, the fat between the Scarpa's fascia and the skin. The fat in this area can be carefully defatted just deep to the subdermal plexus. I have always used the palpable feel and the observation of the size of the fat lobules as indicators of the thickness of the flap being created. The fat is removed with sharp surgical scissors while holding the flap in the palm and fingers of the nondominant hand (see photo 7.C).

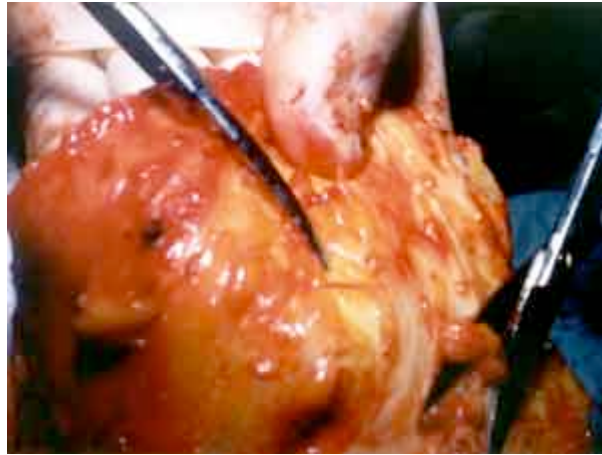


Photo 7.C

This removal of fat is done very carefully noting the size of the fat lobules. As one gets closer to the subdermal plexus, the lobules of fat become much smaller. In the deeper fat, the lobules are larger (see photo 7.D). Excess fat retained in the flap does, in fact, increase the circulatory demands of the flap because the flap is parasitic and brings in no additional circulation. As Dr. Sumner Koch said, "It leaves more *mouths to feed*" (see photo 7.E).

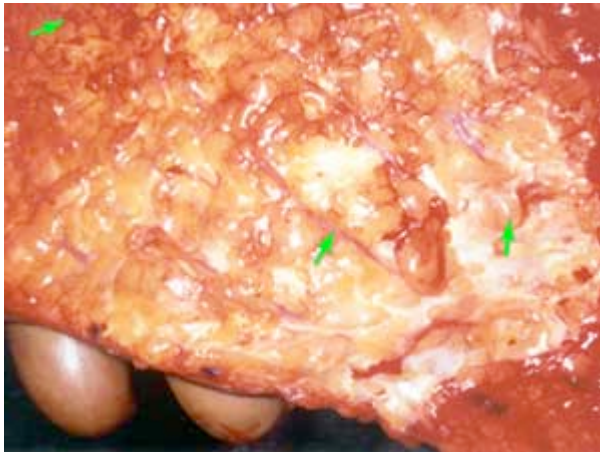

Figure 7.D

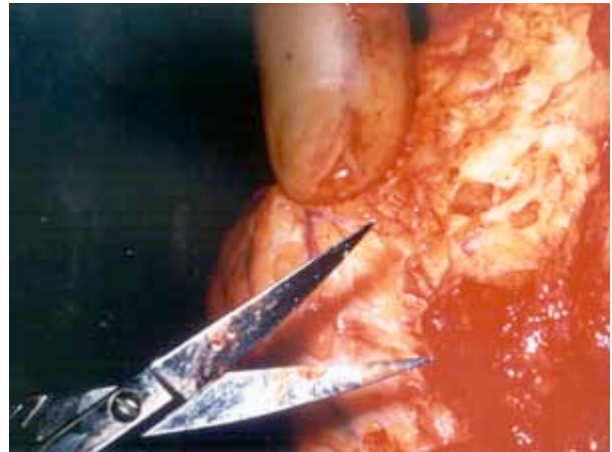

Figure 7.E

It should be emphasized that the flap should be as thin as necessary to match the recipient site and supply the reconstructive needs. If one is replacing scar and skin only and there are no plans for further deep reconstruction, minimal fat is allowed to remain. If there will be a later need for tendon grafts or a need to cover bare bone, a little thicker layer of fat can be left. However, the overall tendency of most surgeons is to leave much more fat than what is really needed for the reconstruction.

Chapter Seven: THE TECHNIQUE OF EFFECTIVELY DEFATTING AN ABDOMINAL FLAP

Example Case

A 21-year-old man sustained a near complete amputation of the left forearm when an acetylene welding torch caused a 50 gallon oil drum to explode. This resulted in open fractures of the radius and ulna and disruption of the vascularity of the forearm. A saphenous vein graft was used to repair the radial artery, and the radius and ulna were reduced and fixed with plates (see photo 7.F). I was called in consultation to manage the soft tissue injury. The wound was debrided, fascial compartments were released, and the area was covered with a sheet of split thickness skin graft, 4 x 8 inches. Postoperative course was uneventful.

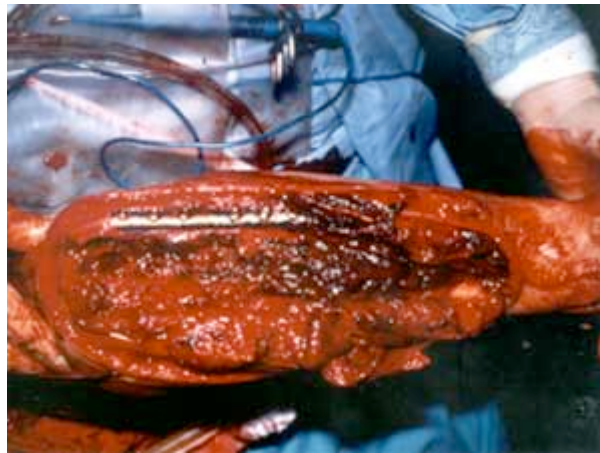


Photo 7.F

Eight months after the injury and this surgery, the patient was seen at our Hand Conference and was noted to lack extension of the fingers and wrist, which was felt to be due to a combination of adherence of the muscles in the skin grafted area as well as traumatic destruction of the muscles and scarring due to the extensive fractures (see photo 7.G). It was felt that he needed replacement of the split thickness graft and release of the scarring, as much as possible, and the coverage with an abdominal flap to provide good supple skin coverage in anticipation of subsequent reconstruction with tendon grafts and tendon transfers.

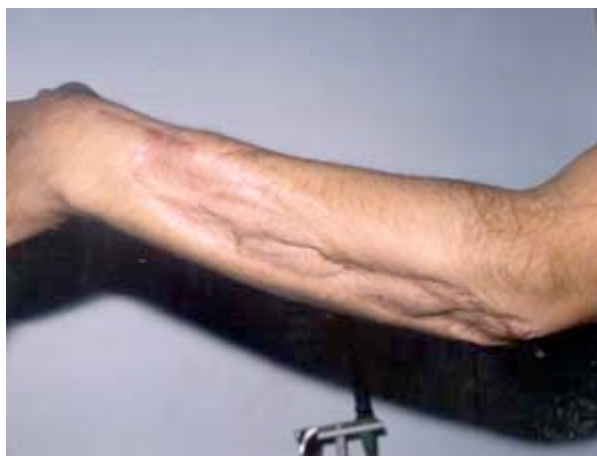

Photo 7.G

Chapter Seven: THE TECHNIQUE OF EFFECTIVELY DEFATTING AN ABDOMINAL FLAP

Abdominal Flap 10 Months After Injury

The surgery consisted of:

1. Excision of the split thickness skin graft and other scar tissue adherent to the muscles of the forearm.
2. Elevation, thinning, and application of an abdominal flap from the upper abdomen to the prepared recipient site. Note, in **photo H**, the Scarpa's fascia being raised and discarded. Note the large lobules of fat (green arrow) to be removed with further thinning of the flap. The donor site was closed with a split thickness skin graft carried up to the stem of the flap.
3. **Photo I** shows a well-healed abdominal flap in position. There is also balanced skeletal traction to immobilize the arm.

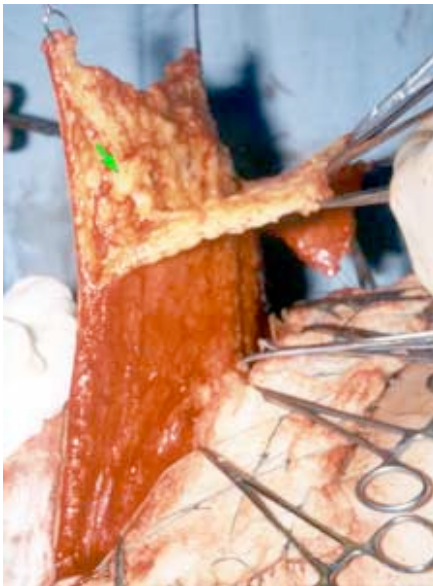


Photo 7.H

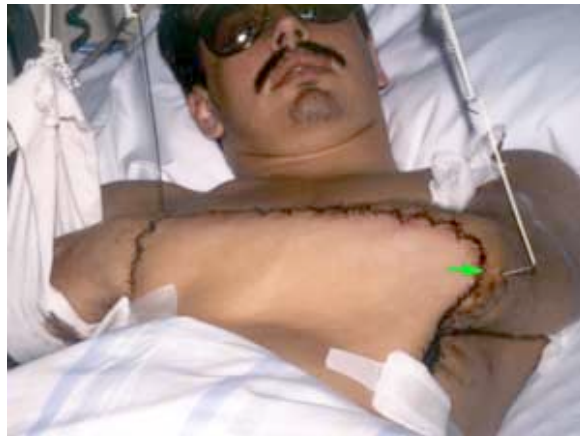

Photo 7.I

Division and Insertion of the Flap

Four weeks after application of the flap, Stage II of the reconstruction consisted of:

1. Sectioning of the stem of the flap and creating multiple "V's" in the recipient site and the flap (**see photo 7.J**). The flap was then sutured to the recipient site (**see photo 7.K**).

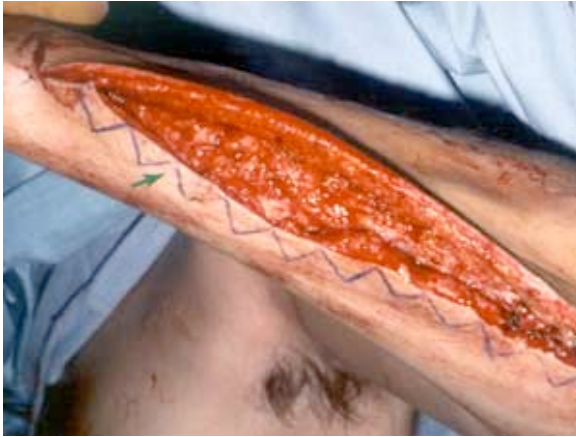

Photo 7.J

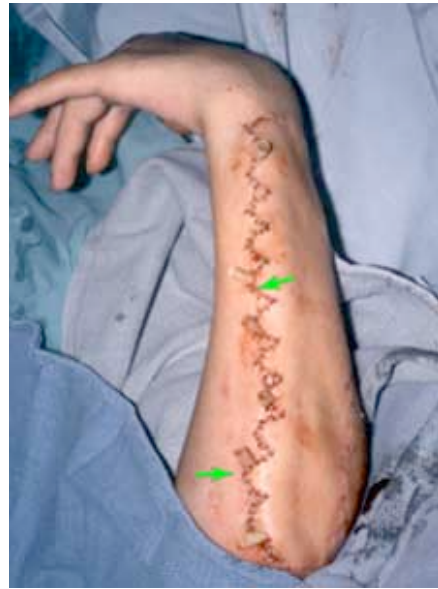

Photo 7.K

2. The flap donor site was undermined using the principles of an abdominoplasty (reversed in this case) and closed as a straight line scar across the upper abdomen (see photo 7.L). Nine months post insertion of the flap, the flap is seen, in photo 7.M, just prior to reconstruction with tendon transfers and tendon grafts. The flap provides an excellent supple site for the intended reconstruction.

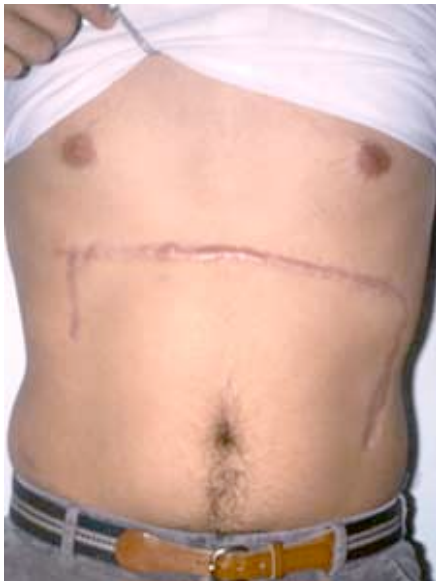

Photo 7.L

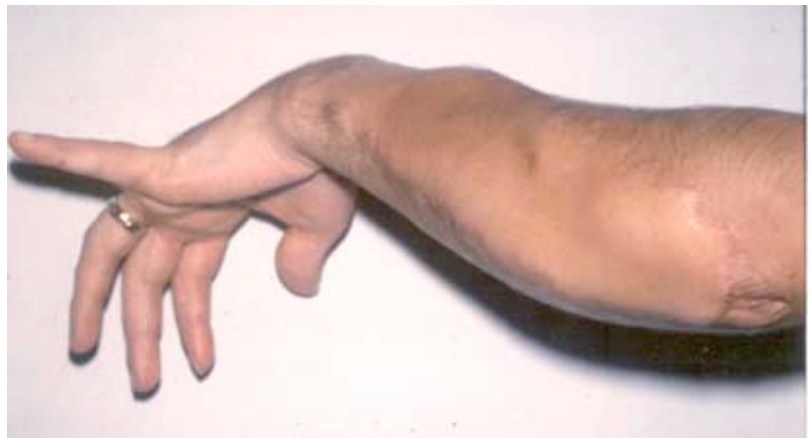

Photo 7.M