

McCraw and Arnold's Atlas of Muscle and Musculocutaneous Flaps



John B. McCraw
Phillip G. Arnold



Global-HELP
Publication

STERNOCLEIDOMASTOID

ANATOMICAL CONSIDERATIONS

Surface Markings

The surface markings are demonstrated by the course of the contracted sternocleidomastoid muscle, which can easily be palpated in the neck.

Origin and Insertion

The sternocleidomastoid muscle arises from two tendinous bands which straddle the head of the clavicle and the upper sternum. The muscle inserts over a broad area of the anterior and inferior surfaces of the mastoid process. The function of the sternocleidomastoid muscle is to tilt the head into the "his master's voice" (RCA® Radio) position.

Adjacent Muscles

Only the platysma muscle is superficial to the sternocleidomastoid muscle. The omohyoid and the other deep muscles of the neck lie subjacent to the sternocleidomastoid muscle. At its mastoid insertion the sternocleidomastoid muscle is appreciably fused with the trapezius muscle. No muscle runs parallel to the sternocleidomastoid muscle; hence, it splits the neck into anterior and posterior "halves."

Vascular Pattern

The sternocleidomastoid is a typical long thin muscle with a tripartite, segmental blood supply. The sternocleidomastoid muscle can be raised on either a superior or inferior vascular base, and it can carry a "paddle" of skin in either direction at the distal end of the muscle. The upper two-thirds of the muscle is independently supplied by the occipital artery. The lower two-thirds of the muscle is similarly supplied by the thyrocervical trunk. The superior thyroid vessels must be divided in the middle portion of the muscle whether the muscle is rotated superiorly or inferiorly.

Motor Nerve

Accessory nerve.

Sensory Nerve

Cervical plexus.

USES

Since the sternocleidomastoid flap can be raised on distinct inferior and superior pedicles, the muscle has different applications in its two separate arcs of rotation.

The inferiorly based flap, which is supplied by the thyrocervical trunk, provides a "paddle" of skin attached to the upper portion of the sternocleidomastoid muscle that will reach the larynx, the trachea, and the jugular notch. The superiorly based flap is generally used for intraoral problems which include small defects (i.e. five by five cm) in the anterior floor of the mouth, the sulcus, and the tonsillar fossa. It is almost never used for cheek skin replacement because of the associated donor site deformity.

REGIONAL FLAP COMPARISONS

The sternocleidomastoid flap is a reasonably reliable and readily accessible flap. It has generally fallen into disfavor because of the usefulness of the other local flaps. For instance, the galeal fascia flap and the temporalis muscle flap both offer much less donor deformity. Unlike the sternocleidomastoid flap, each of these flaps will reach the forehead and the orbit. The temporalis muscle flap provides more than comparable intraoral coverage. Further, small intraoral and cheek defects can be repaired just as effectively with the platysma myocutaneous flap but at a much smaller price. The pectoralis "paddle" is the most common distant flap chosen for major intraoral defects because it is larger and more reliable than the sternocleidomastoid flap. When a sternocleidomastoid flap is seriously considered for an intraoral defect, it is also logical to consider a "free" jejunal flap. In this special instance a radical departure from the "reconstructive ladder" method of thinking is reasonable.

DISADVANTAGES

The use of the sternocleidomastoid flap is virtually never recommended in the irradiated neck. It is discouraged not because it won't survive but rather because the vertical closure of the irradiated neck skin may place the carotid vessels in jeopardy. Should one have to use a secondary flap to resurface the neck, the sternocleidomastoid flap becomes superfluous because the other major flaps, e.g. the latissimus and the pectoralis musculocutaneous flaps, can simultaneously resurface the neck and repair an intraoral defect.

The reliability of the sternocleidomastoid flap is very good unless the skin "paddle" is extended past the point where there are good sternomastoid muscular connections to the skin. This specifically applies to the skin

“paddle” distal to the clavicle, which preferably should be delayed. Occasionally, the vascular pedicle is not well visualized in its superior location because of the surrounding perivascular fatty tissue.

The functional loss with the use of this muscle is only noticed with forcible activities. It does leave a major contour deformity which is comparable to the defect of a standard radical neck dissection. Elevation of the sternocleidomastoid muscle also disrupts the majority of the sensory nerves to the ear and to the ipsilateral neck skin.

Its use is contraindicated in the clinically “positive” neck. It also should not be used when the palpable lymph nodes impinge upon any surface of the sternocleidomastoid muscle. This is particularly true in the upper neck where adequate excision of the lymphatic tissue necessitates the resection of a portion of the upper sternocleidomastoid muscle or its supplying vessels. In the “conservative” neck dissection, which spares the jugular vein, theoretically the use of this flap should not hamper the lymphatic dissection in the lower two-thirds of the neck.

ADVANTAGES

The sternocleidomastoid myocutaneous flap is easily elevated and readily accessible for small intraoral or upper pharyngeal defects. The inferiorly based flap can offer straightforward solutions to some difficult postirradiation healing problems in the laryngeal and upper tracheal areas. Although the sternocleidomastoid flap has several

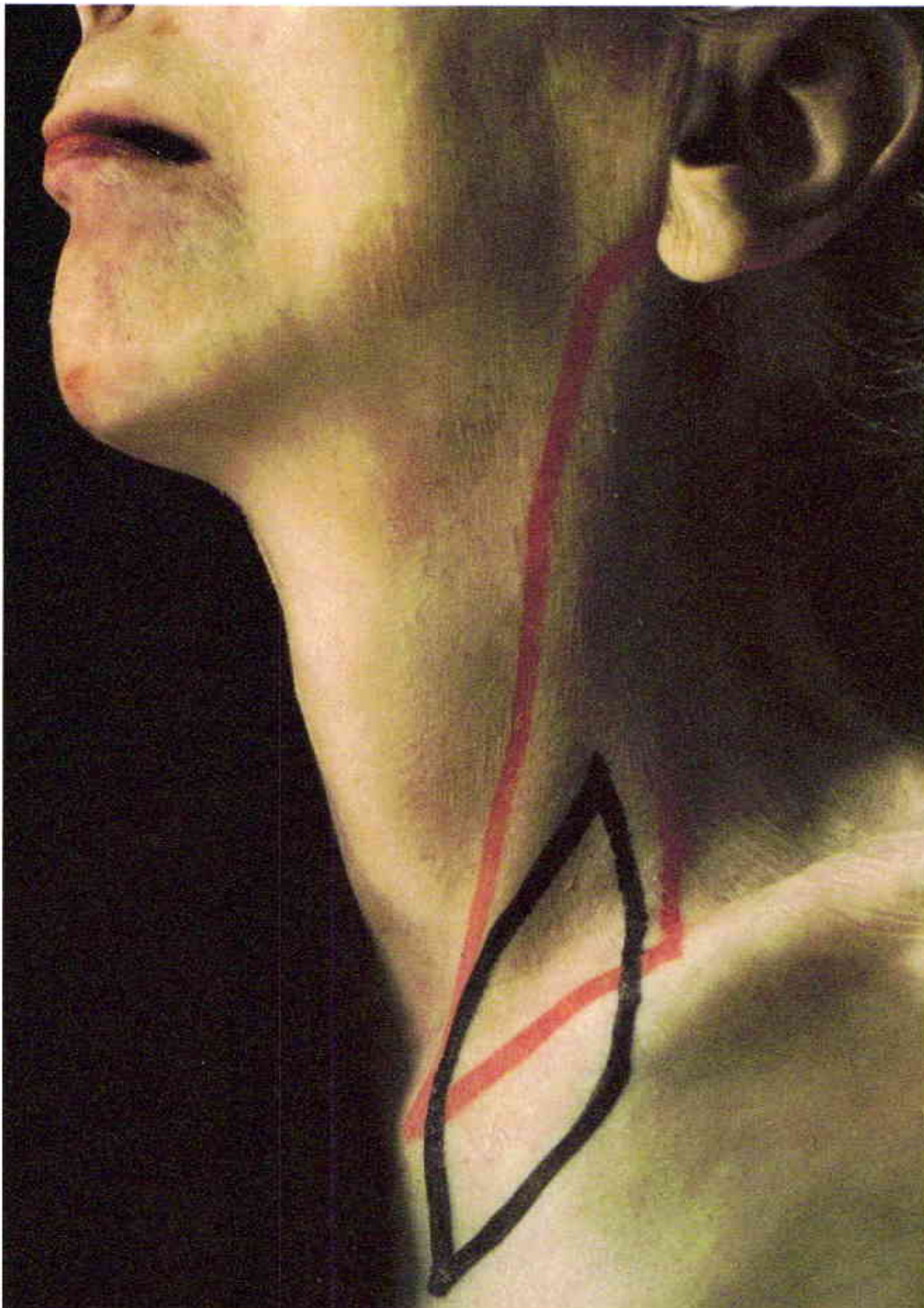
commendable features, the disadvantages related to the donor site often outweigh its recognized advantages.

COMPLICATIONS, PITFALLS, AND DONOR SITE

When the sternocleidomastoid myocutaneous flap is used for intraoral coverage, there is always concern about a watertight closure. This encourages the operator to constrict the muscle as it enters the oral cavity. Any muscular compression should be avoided because the ensuing muscular swelling can compromise the vascularity of the muscle and lead to flap necrosis.

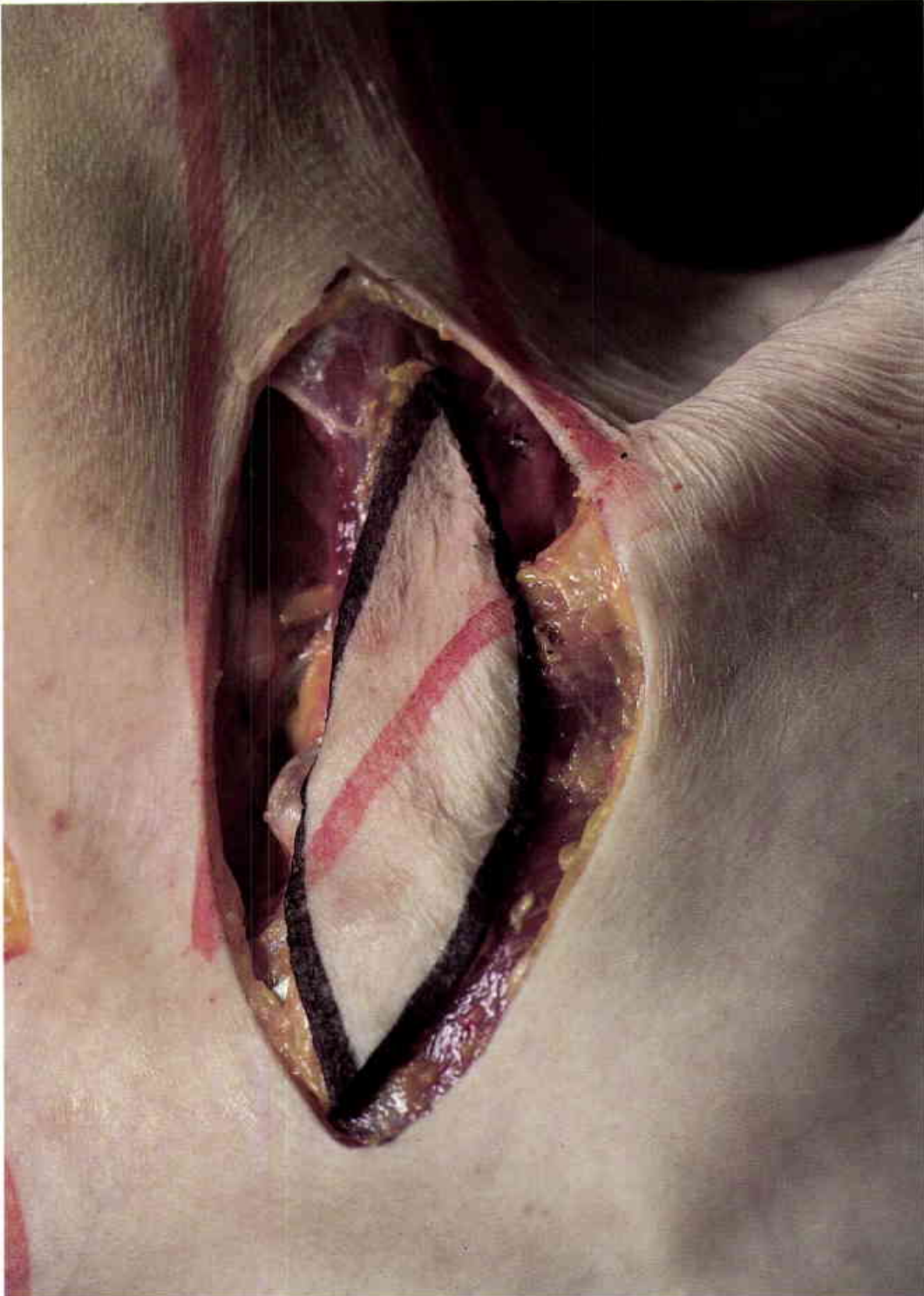
The primary pitfalls are related to identification and protection of the dominant vasculature during flap elevation. This is particularly true of the upper vessels which are surrounded by fat and difficult to identify. One may be confused as to what is the highest “safe” point of dissection because the two superior vessels enter the muscle from the occipital artery without any singular dominance between them. One should always fluoresce this flap to assess its viability. This is especially important when it is used in the critical intraoral and pharyngeal areas. Although total flap loss has not occurred, minimal losses have been sustained in the distal cutaneous “paddle” of the superiorly based flap.

This is not a particularly cold sensitive flap, nor is it one in which we have noted vascular “spasm.” Both the donor site contour deformity and the potentially fragile skin closure over the carotid vessels offer quite major disadvantages.



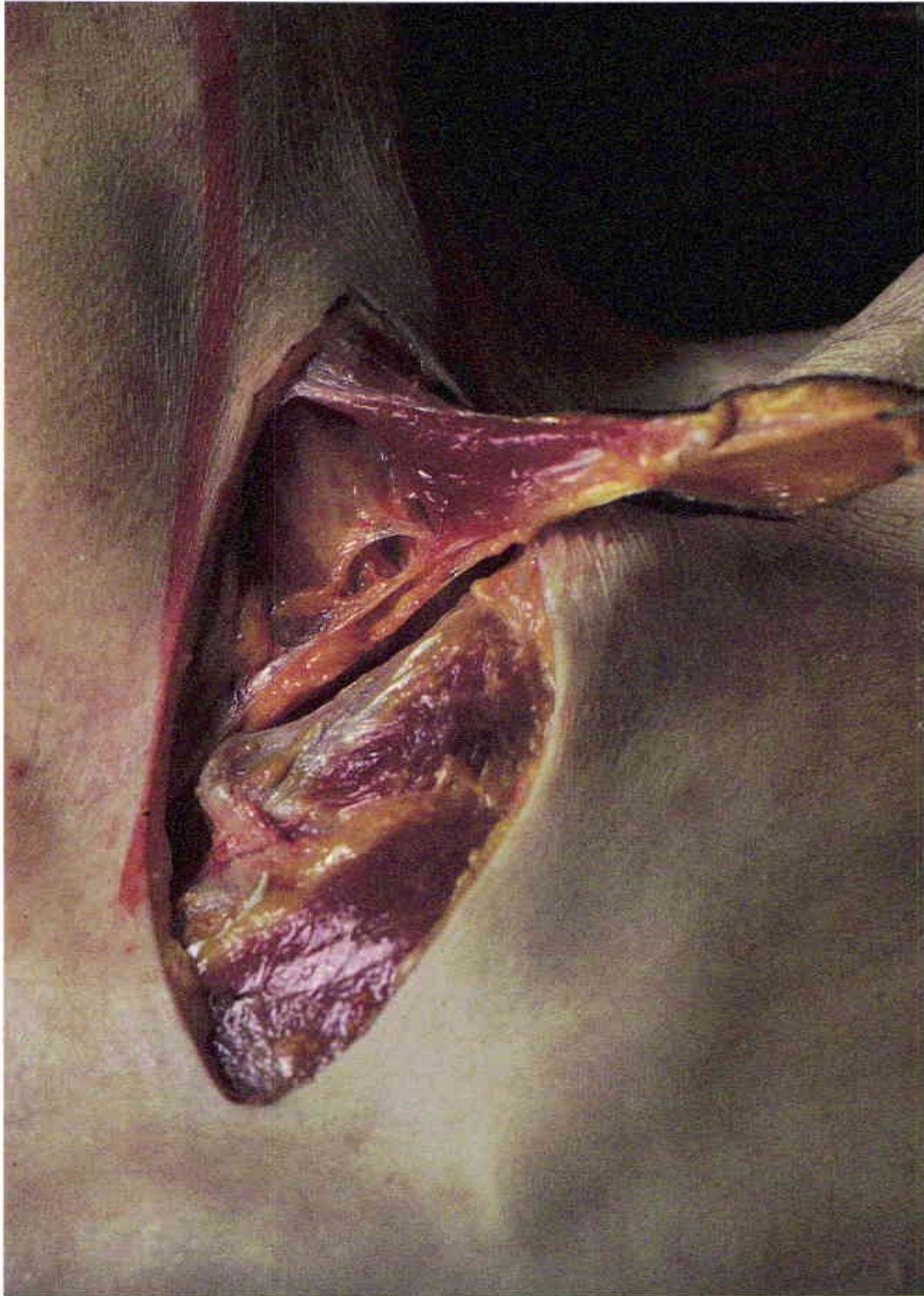
1

The red markings outline the sternocleidomastoid muscle. All of the skin overlying the muscle can be included with the compound flap. The cutaneous segment distal to the clavicle (outlined in black) should be "delayed" to ensure its viability.



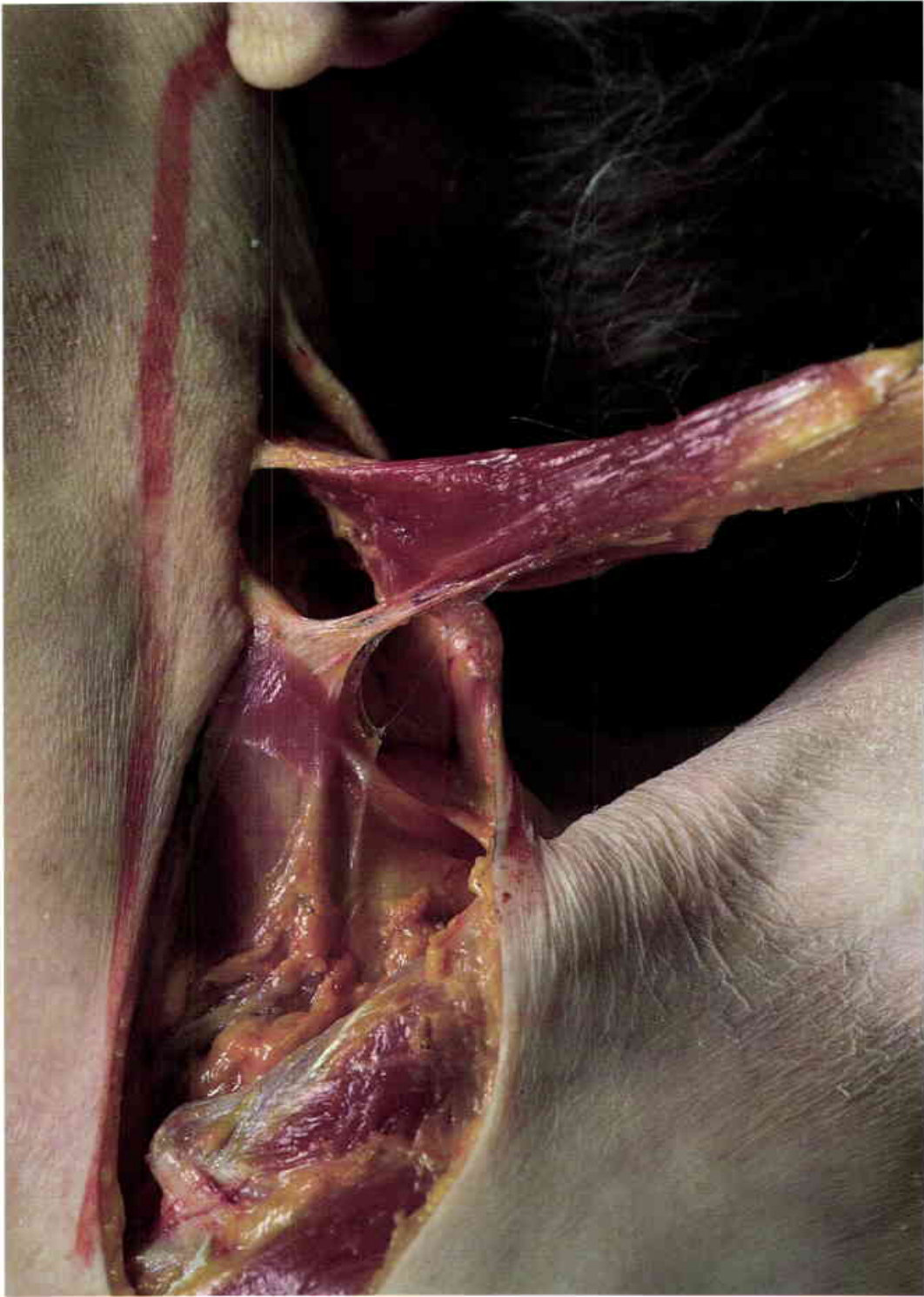
2

The distal skin ‘paddle’ is outlined. The sternocleidomastoid muscle is exposed by first dividing the platysma muscle which is always carried with the compound flap.



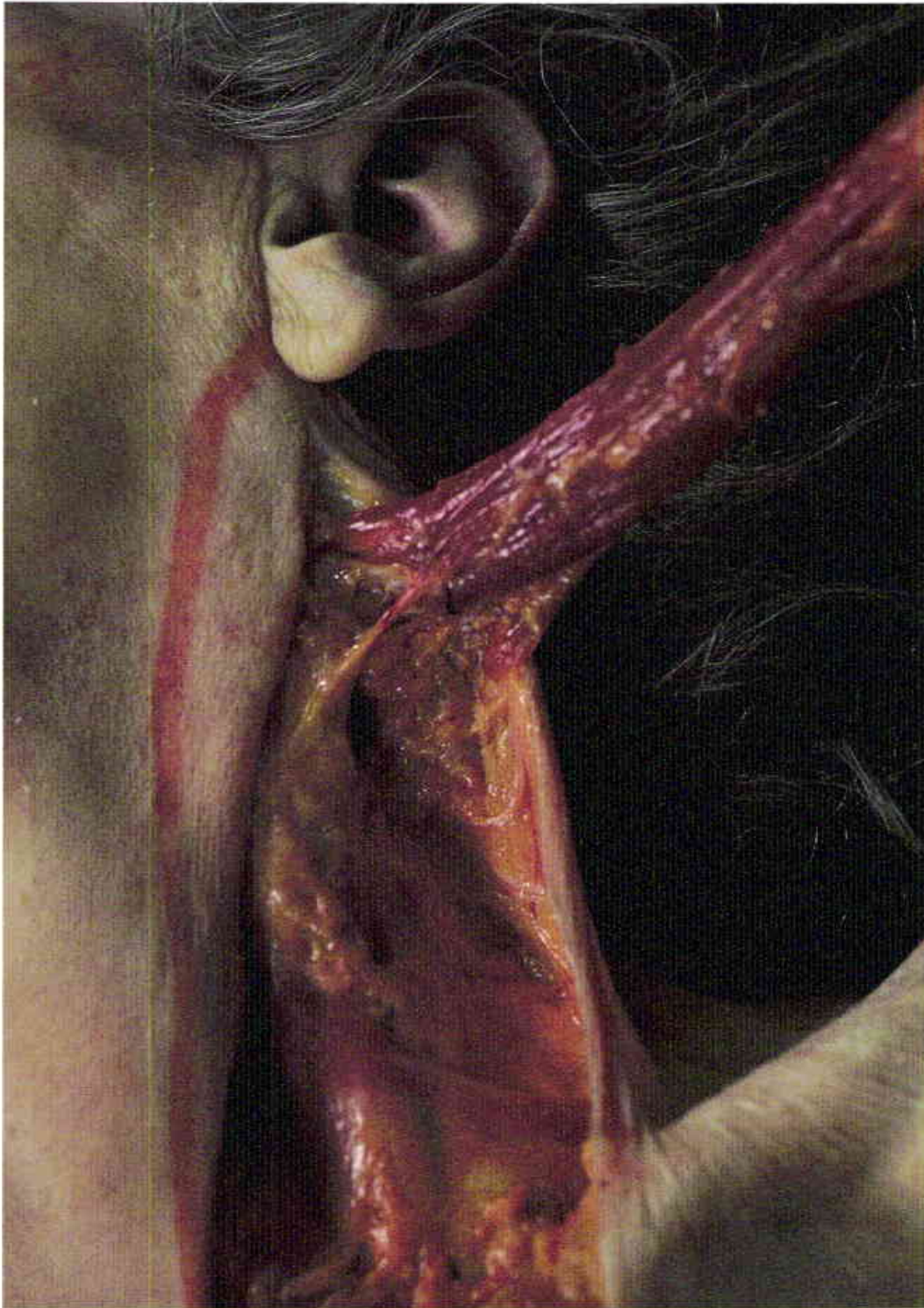
3

The inferior blood supply from the thyrocervical trunk is seen just above the clavicle in this fatty areolar layer.



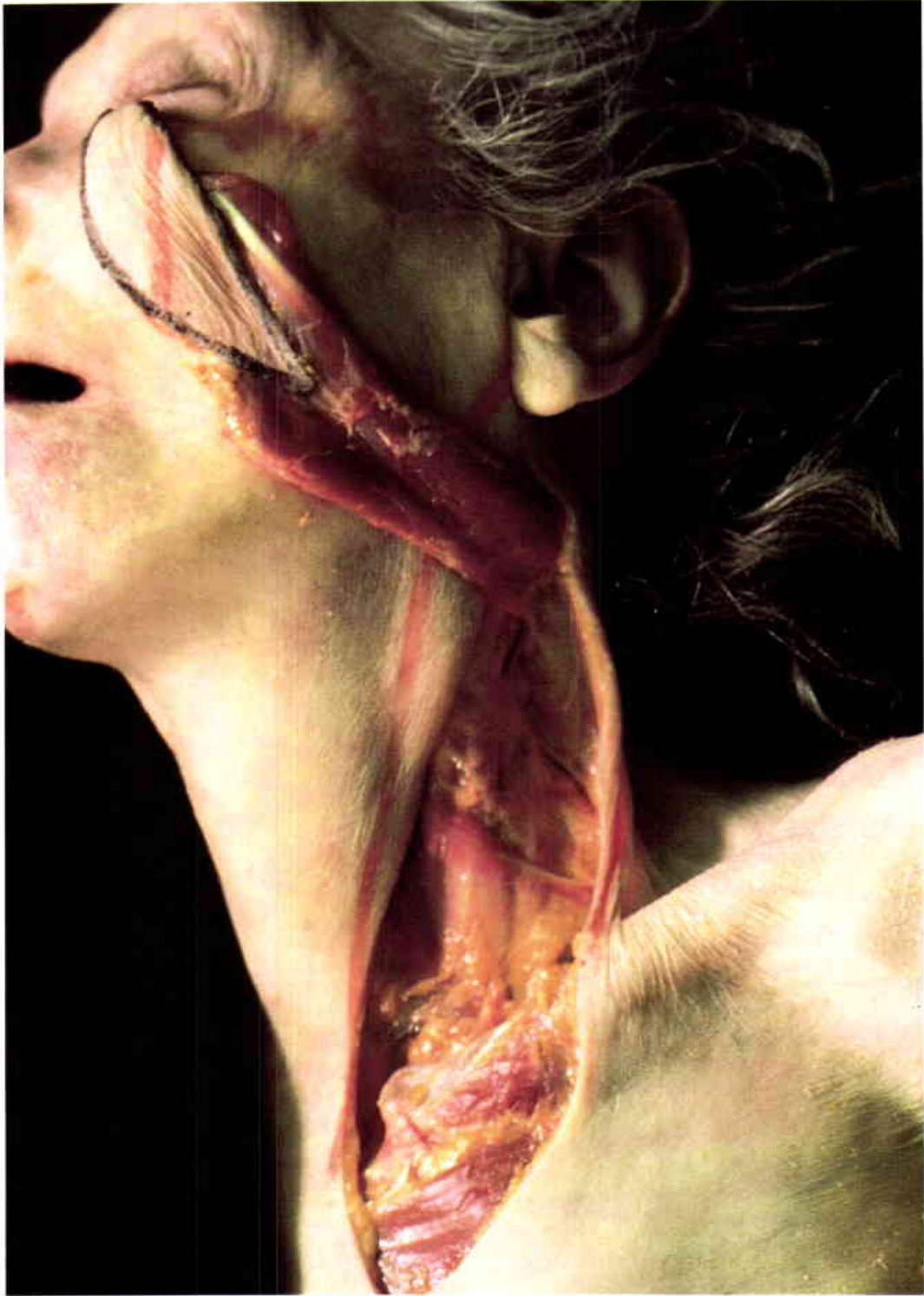4

The middle blood supply from the superior thyroid vessel is seen entering the mid-portion of the sternomastoid muscle above the omohyoid muscle.

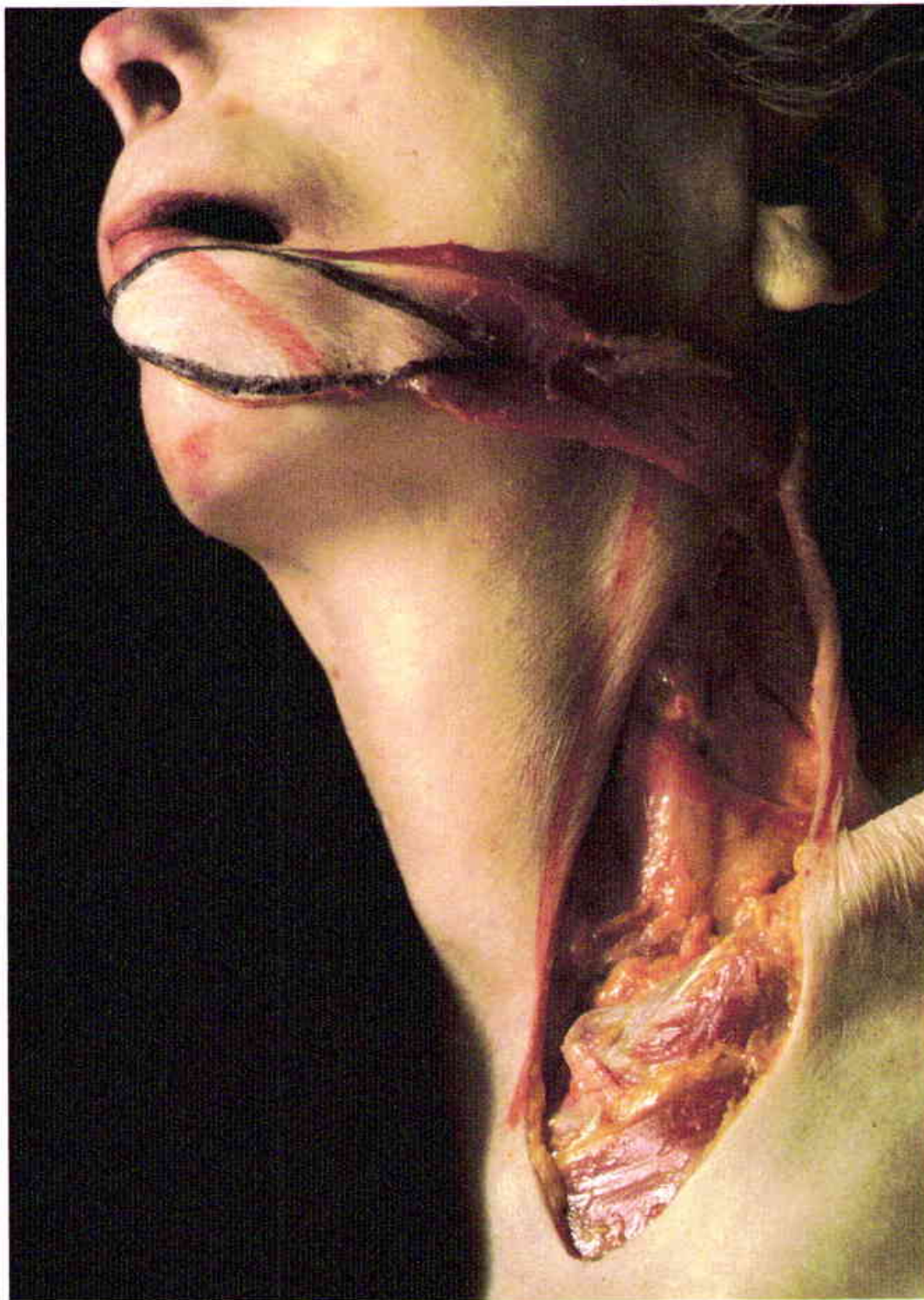


5

The superior blood supply from the occipital artery passes laterally from the external carotid artery. Isolation of these vessels can be difficult because of the surrounding perivascular fat.

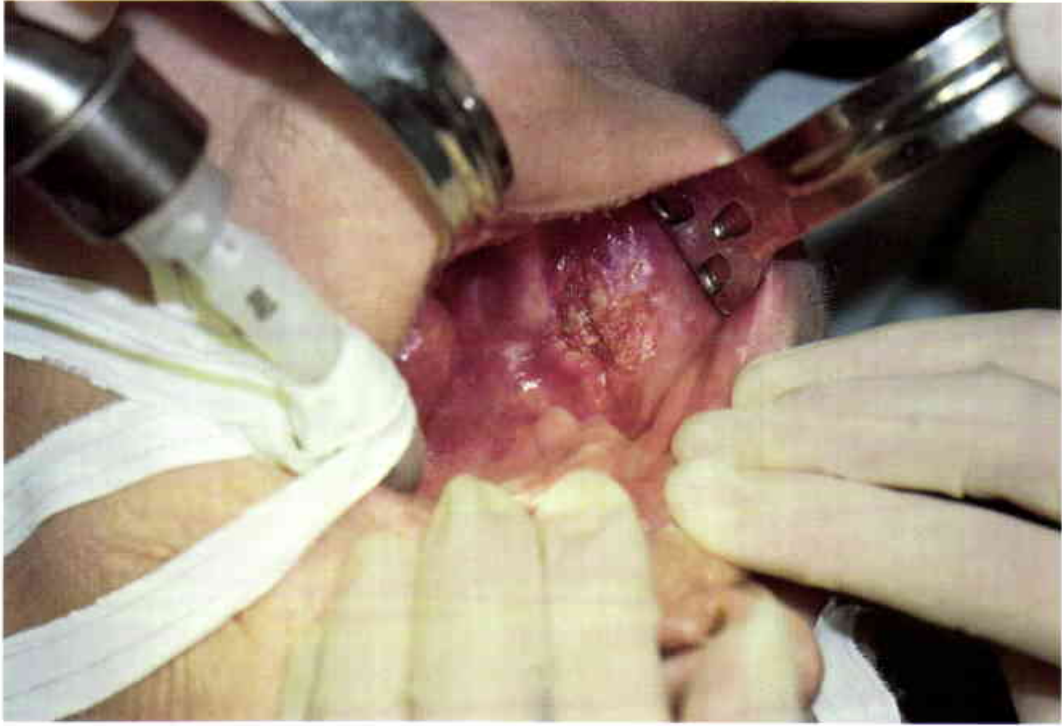
**6**

The arc of the superiorly based flap extends from the zygoma to the mastoid area.



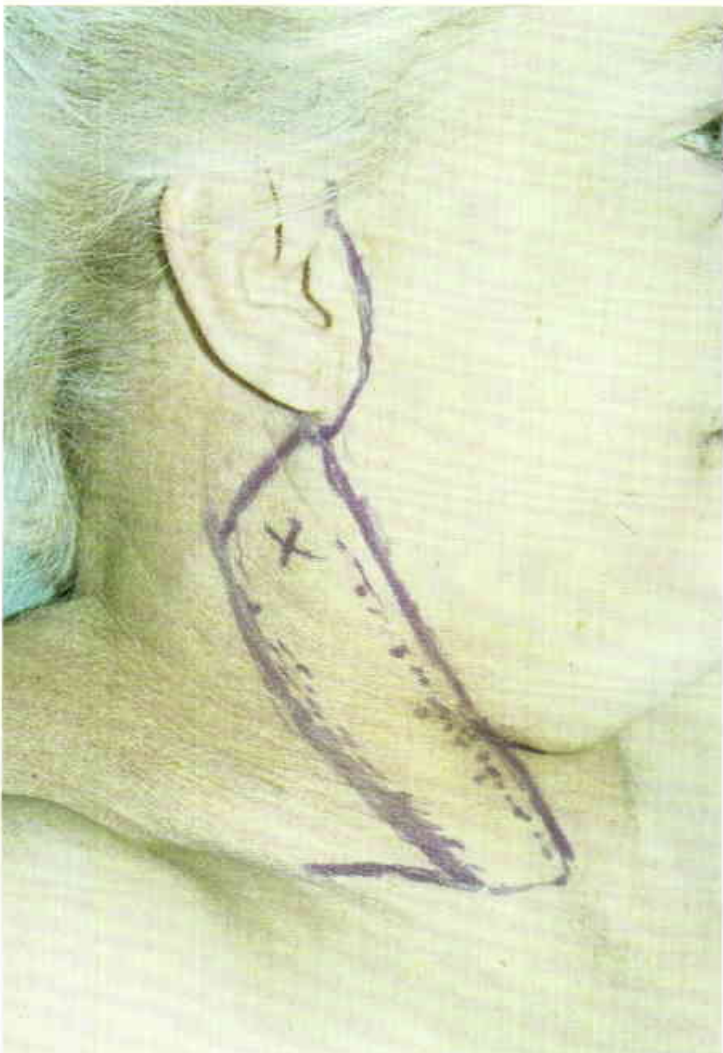7

The distal skin "paddle" reaches the chin and the floor of the mouth. Only the neck skin which is directly attached to the sternocleidomastoid muscle can be expected to survive without a "delay."



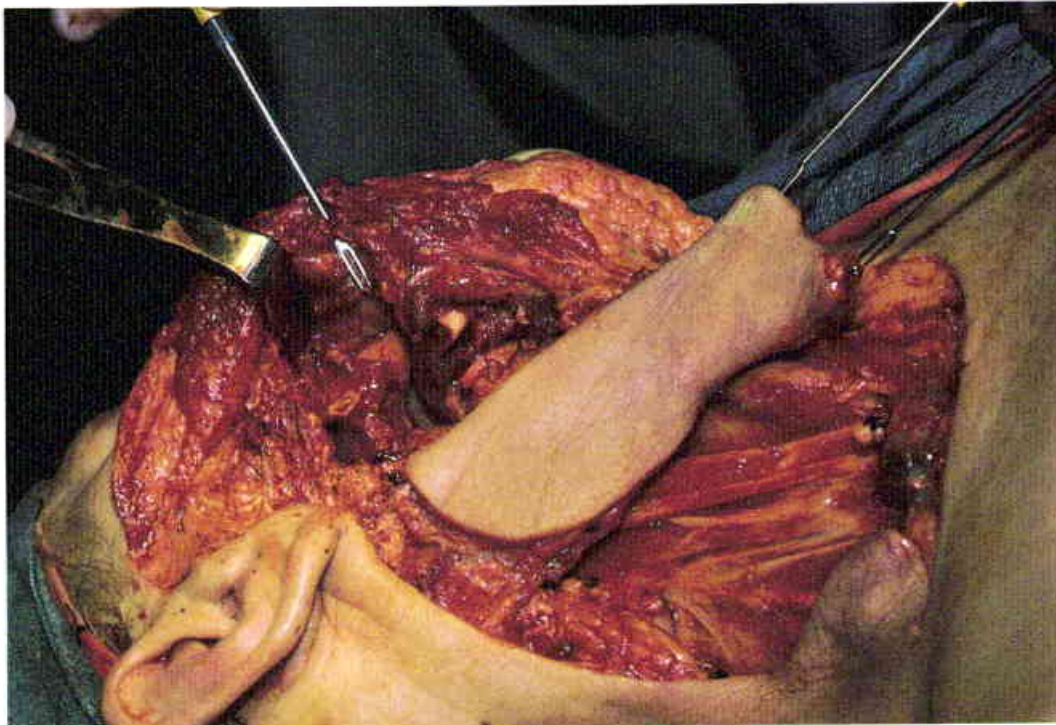
8

Fifty-six-year-old female with a well differentiated squamous cell carcinoma of the buccal mucosa in the area of Stensen's duct. The tumor involved both the mandible and the hard palate. (Case of J.B. McCraw)



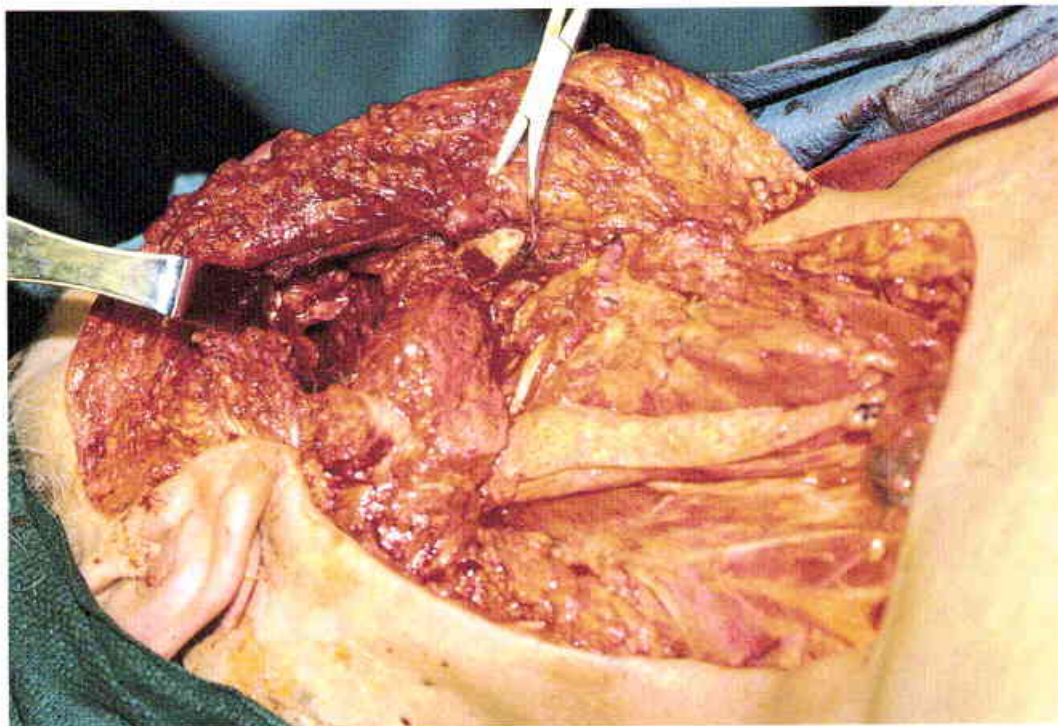
9

Outlined sternocleidomastoid flap. The tumor and the clinically "negative" neck were treated with preoperative irradiation.



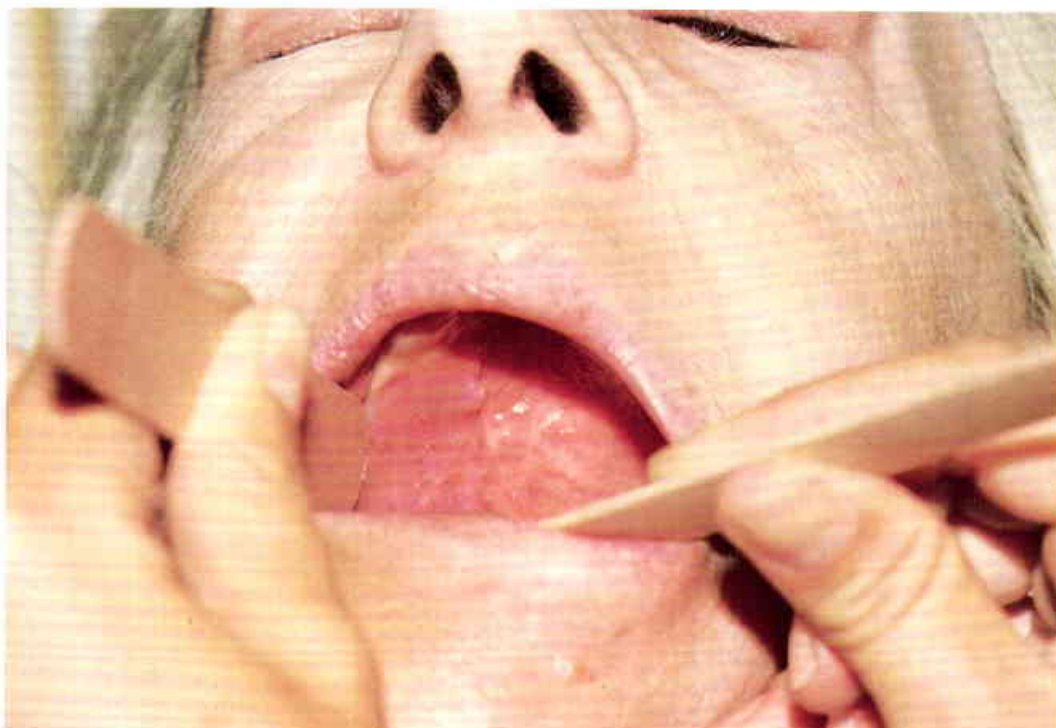10

Elevated sternocleidomastoid flap adjacent to the resected body of the mandible. The margin of the hard palate resection is retracted. A total parotidectomy was also done to protect the facial nerve in the deep dissection of the tumor.

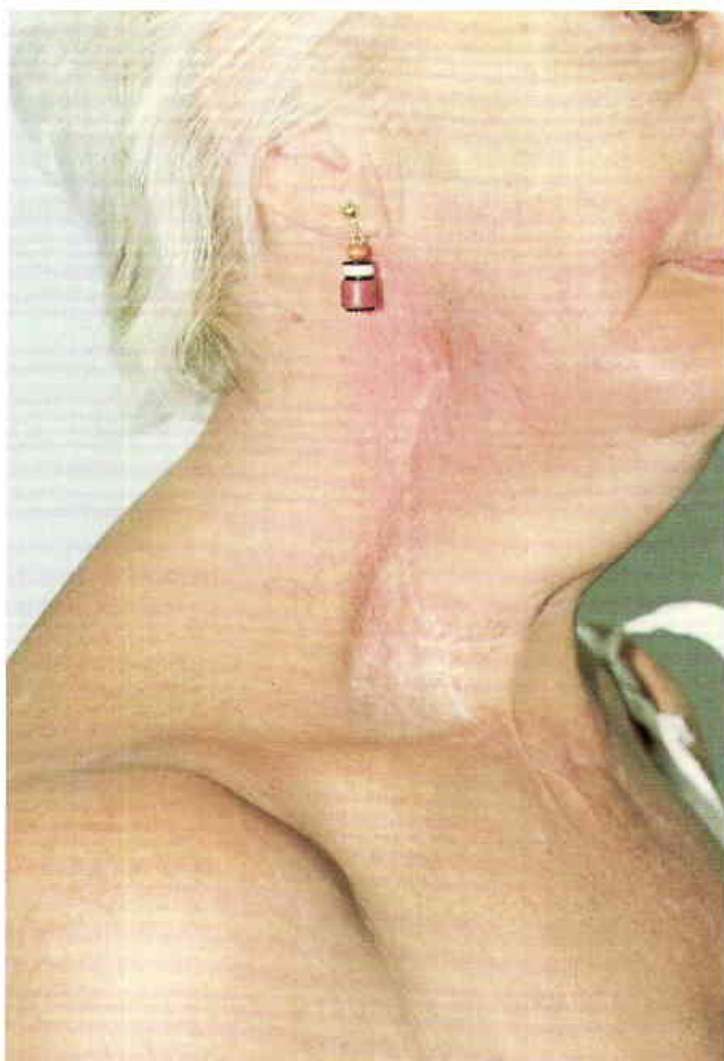

11

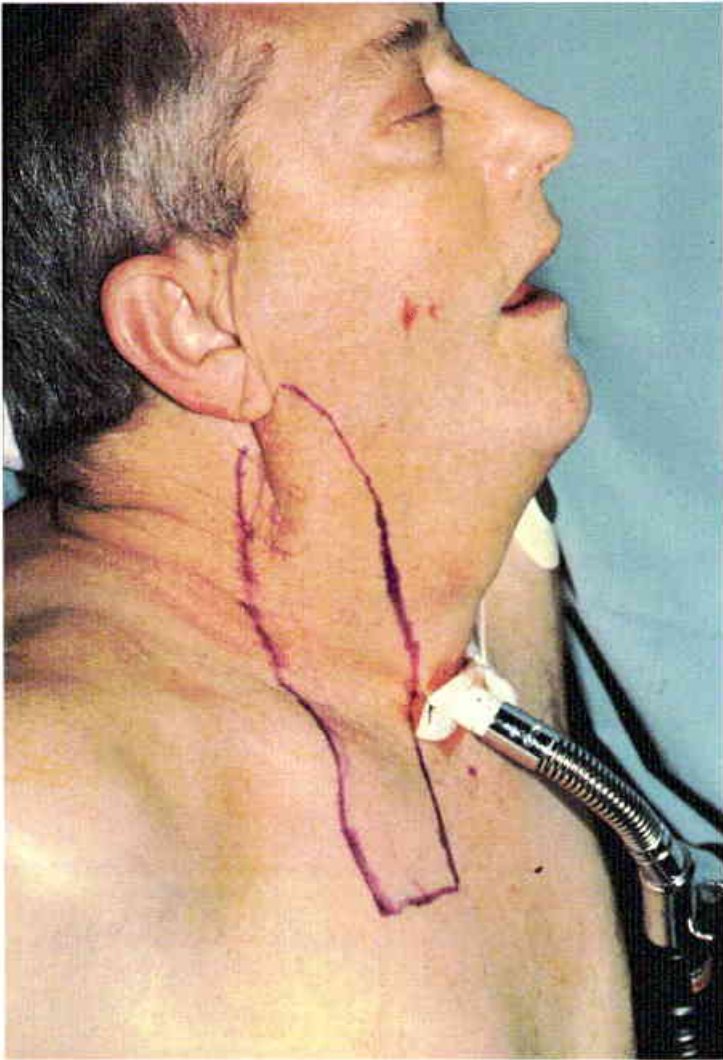Flap inset beneath the resected body of the mandible which is retracted. A dermis graft was used to cover the carotid artery.



12
The sternocleidomastoid flap resurfaced half of the hard palate and the buccal mucosa.

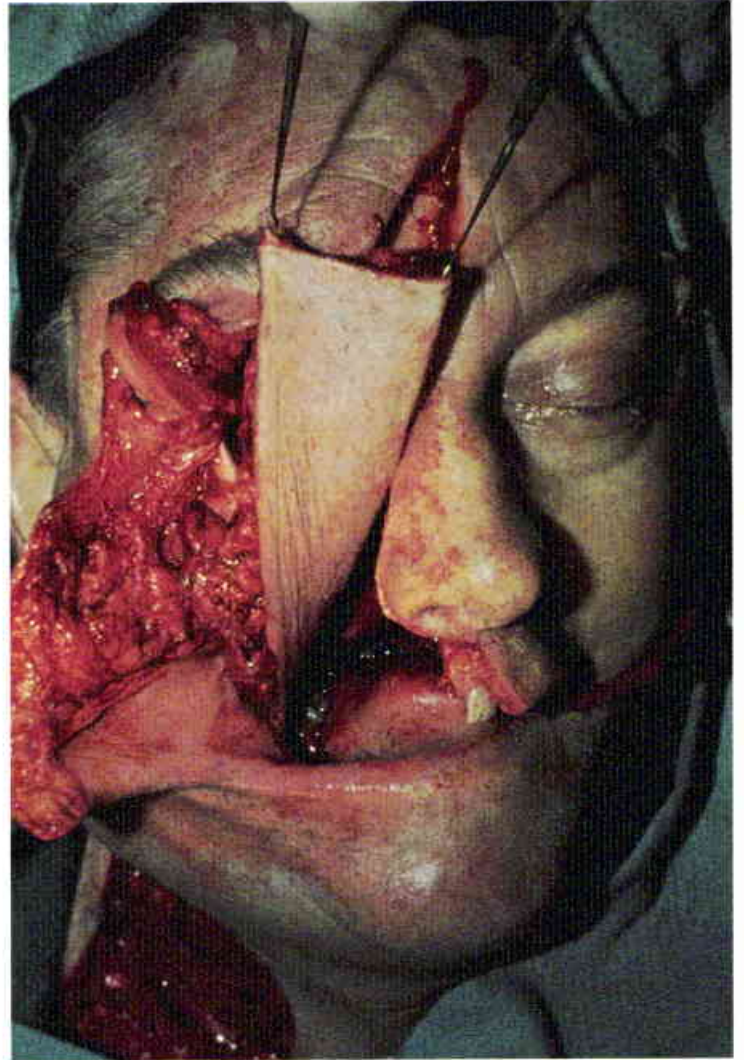


13
Appearance at two years. The donor site deformity is significant.



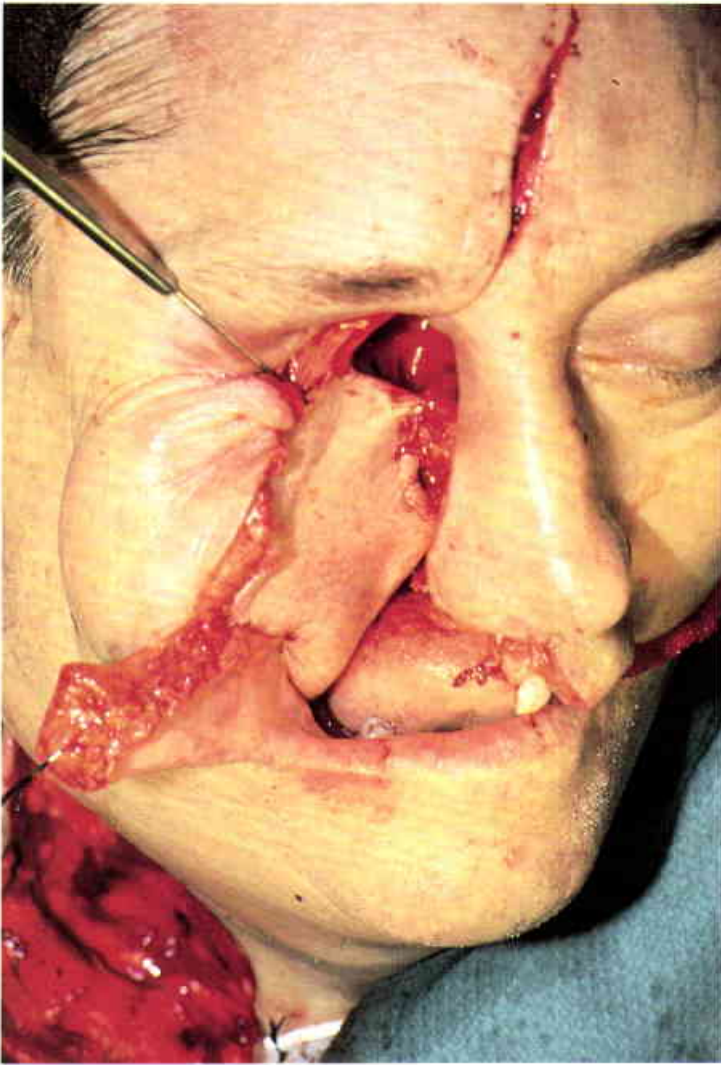
14

Outline of an "extended" sternocleidomastoid flap in a patient with an invasive adenocarcinoma of the maxillary antrum. (Case of J.B. McCraw and W.P. Magee)



15

Upward excursion of the sternocleidomastoid flap. The resection included the maxilla, the orbit, the sphenoid sinus, and half of the septum and hard palate.



16

Flap inset into the maxillary and palatal defects. A posterior pharyngeal flap was used to replace the resected soft palate.



17

Seven years following the procedure. The orbital exenteration deformity is camouflaged with a prosthesis.

STERNOCLEIDOMASTOID

- Alvarez, G.E., Escamilla, J.T., and Carranza, A. "The split sternocleidomastoid myocutaneous flap." *Br. J. Plast. Surg.* 36(2): 183, 1983.
- Ariyan, S. "One-stage reconstruction for defects of the mouth using a sternomastoid myocutaneous flap." *Plast. Reconstr. Surg.* 63: 618, 1979.
- Ariyan, S. "One-stage repair of a cervical esophagostome with two myocutaneous flaps from the neck and shoulder." *Plast. Reconstr. Surg.* 63(3): 426, 1979.
- Ariyan, S. "The sternocleidomastoid myocutaneous flap." *Laryngoscope* 90(4): 676, 1980.
- Ariyan, S. "Functional radical neck dissection." *Plast. Reconstr. Surg.* 65(6): 768, 1980.
- Bakamjian, V.Y. "A technique for primary reconstruction of the palate after radical maxillectomy for cancer." *Plast. Reconstr. Surg.* 31: 103, 1963.
- Barnes, D.R., Ossoff, R.H., Pecaro, B., and Sisson, G.A. "Immediate reconstruction of mandibular defects with a composite sternocleidomastoid musculocutaneous flap." *Arch. Otolaryngol.* 107(11): 711, 1981.
- Barnes, D.R., Ossoff, R.H., Pecaro, B., Sisson, G.A., Conley, J., and Gullane, P.J. "The sternocleidomastoid muscle flap." *Head Neck Surg.* 2(4): 308, 1980.
- Caliot, P., Cabanie, P., Bousquet, V., and Midy, D. "A contribution to the study of the innervation of the sternocleidomastoid muscle." *Anat. Clin.* 6(1): 21, 1984.
- Cole, H.P. "Ununited fractures of the mandible: their incidence, causation and treatment." *Br. J. Plast. Surg.* 6:57, 1918-19.
- Conley, J. "Use of composite flaps containing bone for major repairs of the head and neck." *Plast. Reconstr. Surg.* 49: 522, 1972.
- Conley, J. and Gullane, P.J. "The sternocleidomastoid muscle flap." *Head Neck Surg.* 2(4): 308, 1980.
- Dupuis, A., Princ, G., and Gitton, E. "Palatal reconstruction using a sternocleidomastoid flap with an upper pedicle." *Ann. Chir. Plast. Esth.* 30: 251, 1985.
- Eliachar, I. and Moscona, A.R. "Reconstruction of the laryngotracheal complex in children using the sternocleidomastoid myocutaneous flap." *Head Neck Surg.* 4(1): 16, 1981.
- Gouet, O. "Interet du lambeau osteo-myo-cutane de clavicule dans les grands delabrements de la face: un cas clinique." *Ann. Chir. Plast. Esth.* 29(1): 35, 1984.
- Gupta, A.K., Bhasin, D., and Shah, R. "Closure of post laryngectomy pharyngocutaneous fistula with sternocleidomastoid muscle flap." *Ann. Acad. Med. Singapore* 12(2 Suppl.): 407, 1983.
- Hill, H.L. and Brown, R.G. "The sternocleidomastoid flap to restore facial contour in mandibular reconstruction." *Br. J. Plast. Surg.* 31(2): 143, 1978.
- Jabaley, M.E., Heckler, F.R., Wallace, W.H., and Knott, L.H. "Sternocleidomastoid regional flaps: a new look at an old concept." *Br. J. Plast. Surg.* 32(2): 106, 1979.
- Kanavel, A.B. "Plastic procedure for the obliteration of cavities with non-collapsible walls." *Surg. Gynecol. Obstet.* 32: 453, 1921.
- Lagier, J.P., Lachard, A., Blanc, J.L., and Lachard, J. "Current trends in the treatment of mandibular osteoradionecrosis: use of a sternocleidomastoid osteomyocutaneous flap." *Reve. Stomatol. Chir. Maxillofac.* 86(1): 15, 1985.
- Larson, D.L. and Goepfert, H. "Limitations of the sternocleidomastoid musculocutaneous flap in head and neck cancer reconstruction." *Plast. Reconstr. Surg.* 70(3): 328, 1982.
- Littlewood, M. "Compound skin and sternomastoid flaps for repair in extensive carcinoma of the head and neck." *Br. J. Plast. Surg.* 20: 403, 1967.
- Littlewood, M. "Compound flaps." In *Skin Flaps*. Grabb, W.C. and Myers, M.B. (Eds.) Boston: Little, Brown & Co., 1975, 297-306.
- Marx, R.E. and McDonald, D.K. "The sternocleidomastoid muscle as a muscular or myocutaneous flap for oral and facial reconstruction." *J. Oral Maxillofac. Surg.* 43(3): 155, 1985.
- Matulic, Z., Barlovic, M., Mikolji, V., and Virag, M. "Tongue reconstruction by means of the sternocleidomastoid muscle and a forehead flap." *Br. J. Plast. Surg.* 31(2): 147, 1978.
- Mazzola, R.F., Oldini, C., and Sambataro, G. "Use of submandibular flaps to close pharyngostomes and other defects of lower anterior neck region." *Plast. Reconstr. Surg.* 64: 340, 1979.
- McCraw, J.B., Dibbell, D.G., and Carraway, J.H. "Clinical definition of independent myocutaneous vascular territories." *Plast. Reconstr. Surg.* 60: 341, 1977.
- McCraw, J.B., Magee, W.P., and Kalwaic, H. "Use of the trapezius and sternomastoid myocutaneous flaps in the head and neck reconstruction." *Plast. Reconstr. Surg.* 63: 49, 1979.
- McKinley, L.M. and Hamilton, L.R. "Torticollis caused by absence of the right sternocleidomastoid muscle." *South Med. J.* 69(8): 1099, 1976.
- Mikaelian, D.O. "Reconstruction of the tongue." *Laryngoscope* 94(1): 34, 1984.
- O'Brien, B. "A muscle-skin pedicle for total reconstruction of the lower lip." *Plast. Reconstr. Surg.* 45: 395, 1970.
- Owens, N. "A compound neck pedicle designed for repair of massive facial defects." *Plast. Reconstr. Surg.* 15: 369, 1955.
- Rabson, J.A., Hurwitz, D.J., and Futrell, J.W. "The cutaneous blood supply of the neck: relevance to incision planning and surgical reconstruction." *Br. J. Plast. Surg.* 38(2): 208, 1985.
- Sasaki, C.T. "The sternocleidomastoid myocutaneous flap." *Arch. Otolaryngol.* 106(2): 74, 1980.

STERNOCLEIDOMASTOID

- Siemssen, S.O., Kirby, B., and O'Connor, T.P.F. "Immediate reconstruction of a resected segment of the lower jaw, using a compound flap of clavicle and sternomastoid muscle." *Plast. Reconstr. Surg.* 61: 724, 1978.
- Snyder, C.C., et al. "Mandibulofacial restoration with live osteocutaneous flaps." *Plast. Reconstr. Surg.* 45: 14, 1970.
- Toomey, J.M. and Jacobs, J.R. "The extended sternocleidomastoid flap for one stage repair of defects of the oral cavity." *Laryngoscope* 90: 886, 1980.
- Tovi, F. and Gittot, A. "Sternocleidomastoid myoperiosteal flap for the repair of laryngeal and tracheal wall defects." *Head Neck Surg.* 5(5): 447, 1983.
- Viti, M., Fujiwara, M., Basmanjian, J.M. and Iida, M. "The integrated roles of longus colli and sternocleidomastoid muscles: an electromyographic study." *Anat. Rec.* 177(4): 471, 1973.
- Yamaguchi, K.T., Sanderson, R., and Turnbull, F. "Repair of the hemimandibulectomy defect with a sternocleidomastoid muscle rotation flap." *Trans Pac. Coast Otoophthalmol. Soc.* 58: 351, 1977.