

McCraw and Arnold's Atlas of Muscle and Musculocutaneous Flaps



John B. McCraw
Phillip G. Arnold



Global-HELP
Publication

PECTORALIS MUSCLE

ANATOMICAL CONSIDERATIONS

Surface Markings

The pectoralis muscle parallels the clavicle superiorly and the sternum, medially. The lateral border is palpable as the anterior axillary fold which extends from the lower margin of the deltoid muscle to slightly below the nipple. The inferior border of the muscle partially covers the fifth rib and the superior extent of the rectus abdominis and serratus anterior fascia attachments to the chest wall.

Origin and Insertion

The muscle originates over a broad front which encompasses the sternum, the clavicle, and the first five ribs. Inferiorly, the origin of the pectoralis major muscle extends approximately five centimeters beyond the limits of the pectoralis minor muscle. The pectoralis major muscle can be considered to have a secondary clavicular "head" which originates from the upper three ribs and the full length of the clavicle. The muscle inserts into the intertubercular groove of the humerus just lateral to the insertion of the latissimus dorsi muscle. If the other eighteen shoulder girdle muscles are still intact, the functional loss of the pectoralis muscle is seldom detectable.

Adjacent Muscles

The bulk of the pectoralis major muscle overlies the anterior aspects of the first five intercostal muscles and completely covers the pectoralis minor muscle. Inferiorly and laterally, the pectoralis muscle abuts upon the multipennate origin of the serratus anterior muscle and the upper margin of the rectus abdominis muscle.

Vascular Pattern

The pectoralis major muscle is a classic example of a broad, flat muscle with an abundant intramuscular arborization between the two separate vascular systems. The primary blood supply is from the thoracoacromial vessels, and the secondary vascular supply is from the numerous deep perforating branches of the internal mammary artery which lie adjacent to the sternum. These parasternal perforating vessels finally perforate the skin to form the vascular basis for the medial deltopectoral flap.

The *thoracoacromial artery* is a short branch from the second part of the axillary artery. This artery passes on the medial border of the pectoralis minor muscle and pierces the clavipectoral fascia to divide into four arterial branches: pectoral, acromial, clavicular, and deltoid. The *pectoral branch* is the largest of these vessels and

enters both the pectoralis major and minor muscles at the level of the mid-clavicle. It is this branch which supplies the standard pectoralis major "island" flap. The pectoral branch is easily seen on the undersurface of the pectoralis major muscle above the level of the third rib, but it is not well identified in the distal half of the muscle. The intramuscular course of this vessel parallels the fibers of the muscle, after splitting in the mid-portion of the muscle. This vessel is a significant contributor to the blood supply of the breast. It also has extensive anastomoses with the perforating branches of the internal mammary artery and the lateral thoracic artery. The *acromial branch* runs laterally over the coracoid process in its course to the deltoid muscle, where it anastomoses with the branches of the suprascapular artery. The *deltoid branch* arises near the acromial branch. Terminally, it parallels the cephalic vein in the interval between the pectoralis major and the deltoid muscles. The *clavicular branch* runs medially in the clavicular portion of the pectoralis major and provides branches to the sternoclavicular joint and the subclavius muscle.

In raising an "island" pectoralis major or pectoralis minor muscle flap, only the *pectoral branch* is normally preserved. The *acromial branch* can be quite large and may require ligation, but it should not be confused with the dominant blood supply. Because of the extensive intramuscular collateralization, one can also use only the acromial branch to supply a pectoralis muscle "island" flap when it is necessary to do so for a lateral defect.

Motor Nerve

The upper half of the pectoralis major muscle is innervated by the *lateral pectoral nerve*, and the lower or lateral half of the muscle is innervated by the *medial pectoral nerve*. This nerve is designated as *medial or lateral* because of its exit point from the brachial plexus rather than because of its relationship to the coracoid process or the pectoralis minor muscle.

Sensory Nerve

Intercostal nerves.

USES

The pectoralis major muscle offers a wide variety of surface applications in the area of the sternum, the anterior chest, and the shoulder. Because of the large number of median sternotomies performed for coronary artery bypass procedures, one of the most common uses is for chronic sternotomy infections. When a chest wall

or sternal reconstruction requires stabilization with either autogenous bone or an artificial mesh, the pectoralis major muscle provides an excellent source for both coverage and revascularization. For intrathoracic purposes the pectoralis major muscle will reach virtually any site within the upper chest and mediastinum. In unusual circumstances of irradiation or chronic infection, the pectoralis muscle can be transposed to the neck, shoulder, arm, and axilla. It is also a secondary source of functional muscle replacement for the biceps and triceps muscle of the arm.

REGIONAL FLAP COMPARISONS

Basically, the pectoralis major muscle is the mirror image of its counterpart on the back — the latissimus dorsi muscle. Both muscles are used essentially for the same types of problems in different locations. When the pectoralis major and latissimus muscles are not available, the serratus muscle is equally as useful, particularly for intrathoracic defects. The latissimus dorsi muscle is used more often than the pectoralis major muscle for the restoration of elbow flexion because of its relative strength and lesser donor site deformity.

DISADVANTAGES

The disadvantage of using the pectoralis major muscle is primarily cosmetic in nature, particularly in men. The prominent visibility of the ribs cannot be camouflaged, but an attempt should be made to preserve the contour of the anterior axillary fold. This is done by leaving the lateral margin of the pectoralis muscle as a static band between the chest wall and the humerus. Although the pectoralis major muscle would seem to be a functionally important muscle, it is not.

ADVANTAGES

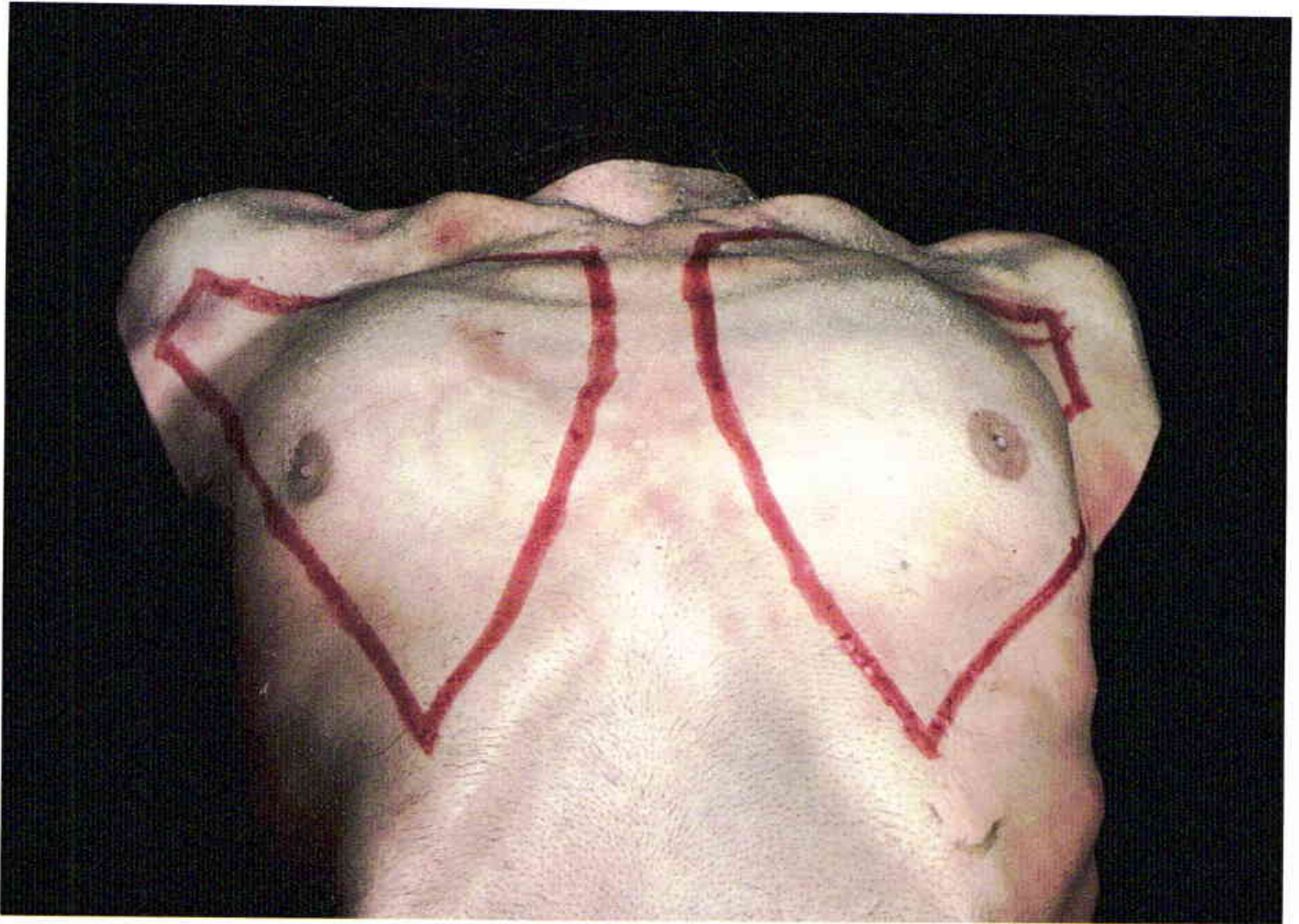
The advantages of the pectoralis major muscle flap are readily apparent. The vertical length of the muscle measures at least twenty centimeters so that the expected muscle coverage can be estimated by measuring twenty centimeters from its axis of rotation at the midclavicle. The expected arc of rotation easily encompasses the neck, the upper two-thirds of the sternal area, and the upper anterior chest as well as the shoulder and the axilla. The muscle can also be passed directly into the chest and the mediastinum. The pectoralis major muscle is particularly helpful in avascular situations caused by irradiation or infection. The two pectoralis muscles am-

ply provide complete muscle coverage of the infected sternotomy wound. This complete muscle coverage is absolutely necessary to eradicate the residual infection whether the sternum is partially or totally excised. The pectoralis major muscle will also provide good revascularization for rib grafts or artificial mesh grafts which are used to replace the sternum or the chest wall.

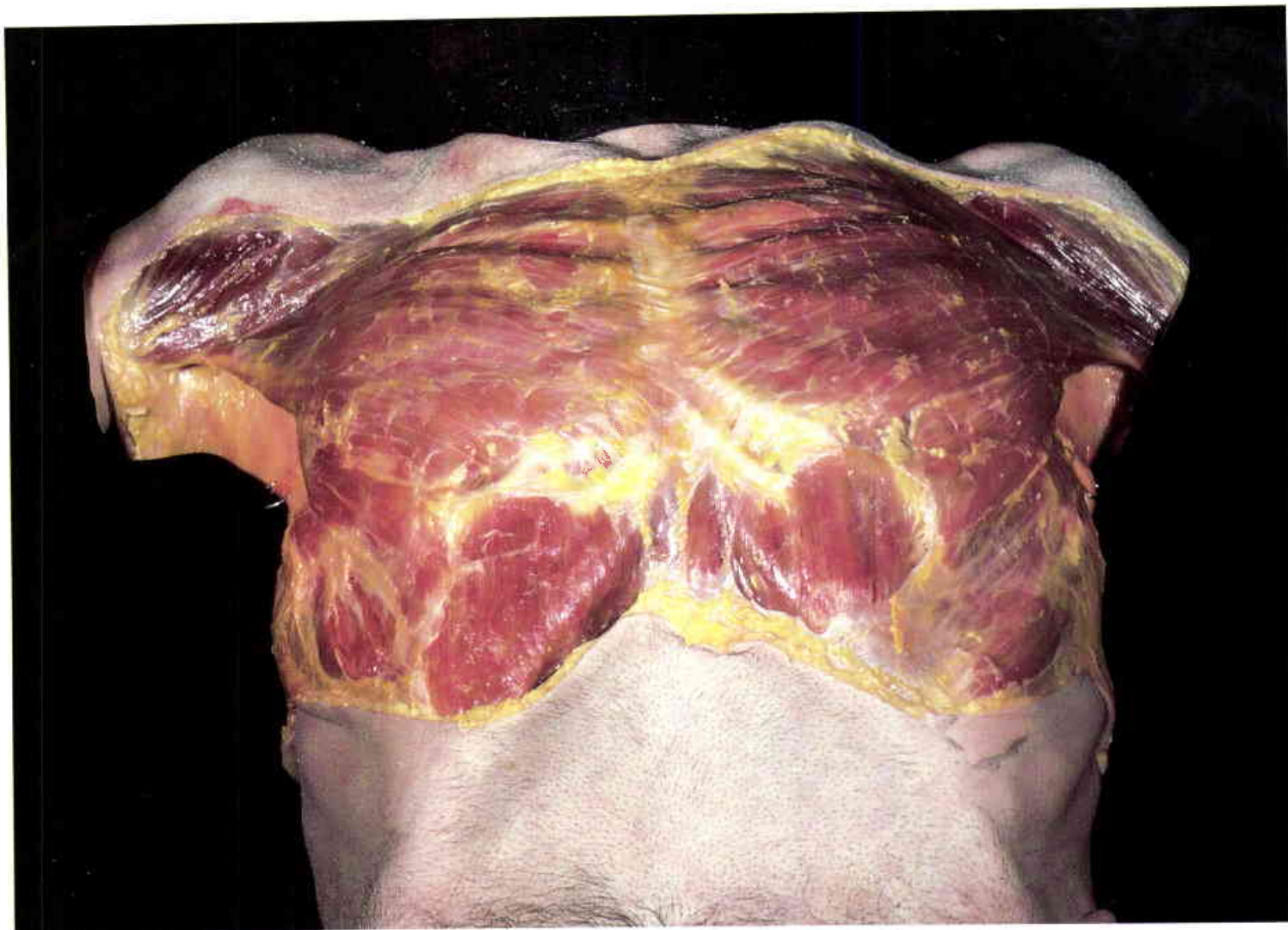
COMPLICATIONS, PITFALLS, AND DONOR SITE

Because numerous vessels are encountered during the flap elevation, the procedure should be done under direct vision to prevent an unrecognized hematoma. For the same reason the large area of dissection should always be adequately decompressed with suction drains. When the humeral insertion is divided, bleeding can be expected from the acromial branch of the thoracoacromial axis. Care must also be taken to protect the axillary and cephalic veins which pass along side the pectoralis major muscular insertion.

The pectoralis fascia should be meticulously preserved in the flap elevation because this provides a dense fascial layer which will hold sutures. If this is not done, one may be left with a frayed and ragged muscle and need to use large suture bites which can devascularize the muscle. The donor site does result in a significant contour deformity, but this obvious disadvantage is mitigated by the reconstructive benefits obtained from the use of this versatile muscle flap.

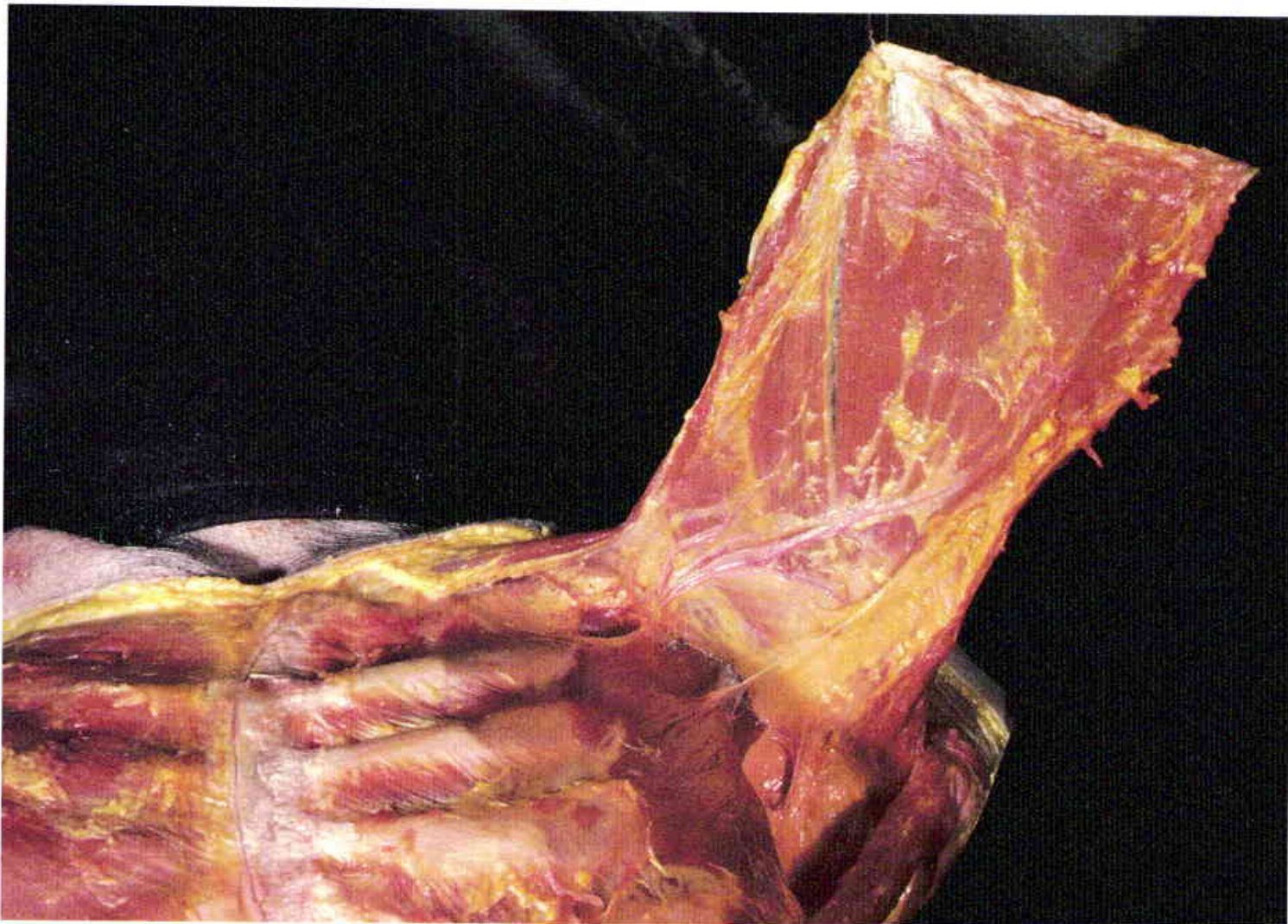

1
Surface markings of the pectoralis major
muscles.



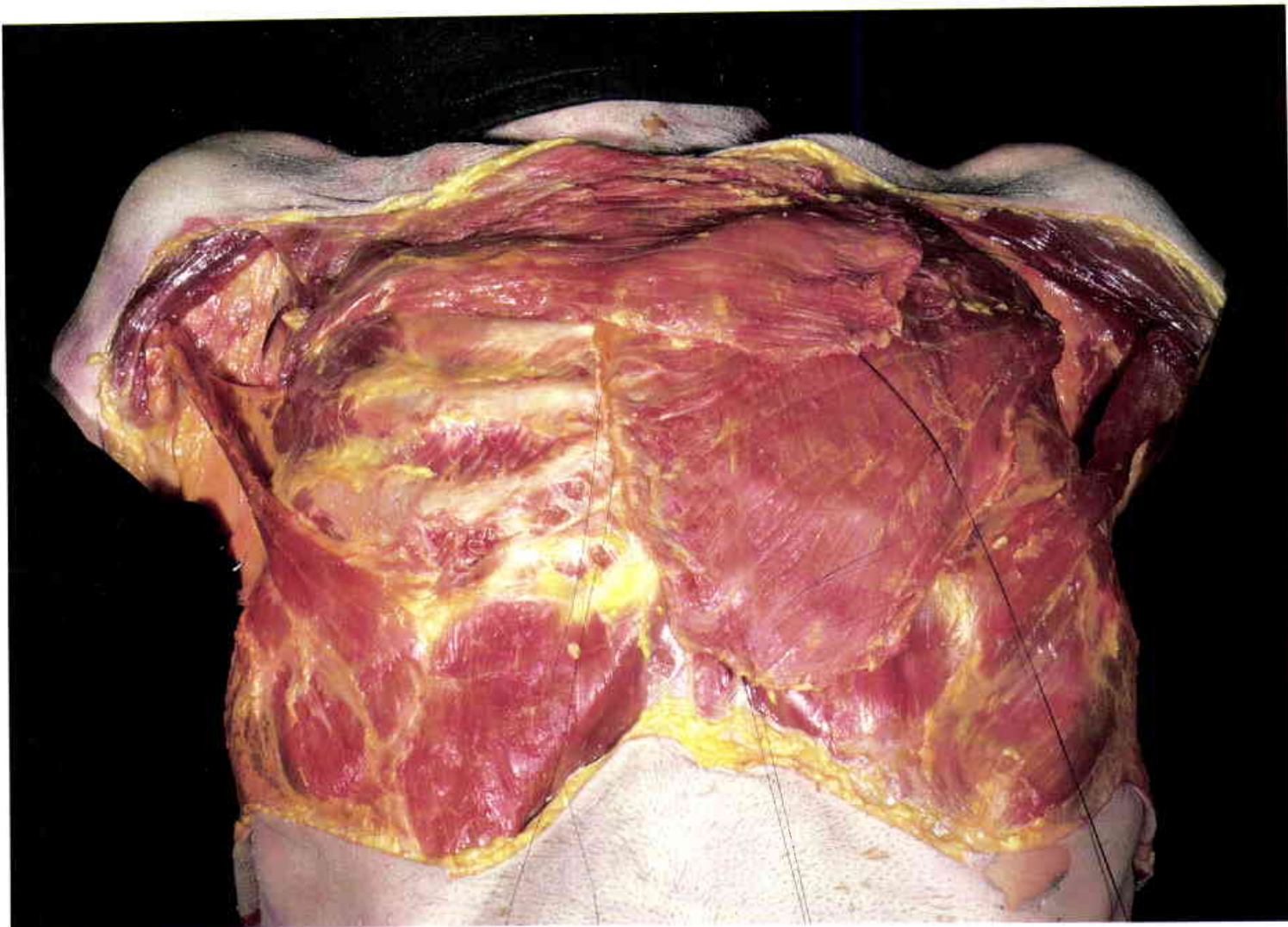2

Full view of the pectoralis major muscles. Note the relationships of the deltoid muscle superiorly and the rectus abdominis and serratus anterior muscles inferiorly.



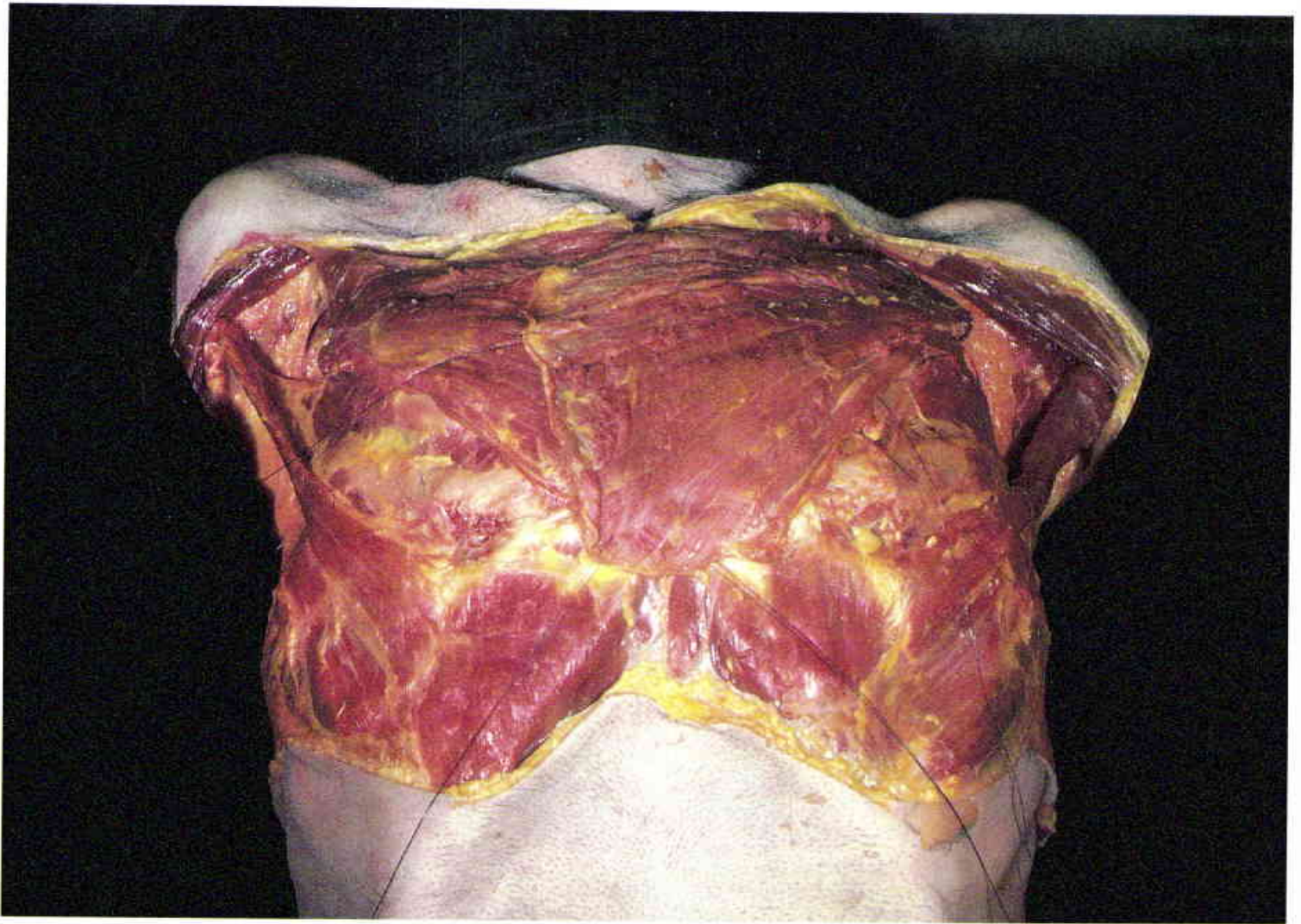
3

Completely elevated left pectoralis major muscle. The thoracoacromial vessels are seen on the undersurface of the muscle. The muscular insertion has been divided. A three centimeter "strip" of the pectoralis muscle has been left in place laterally in order to maintain some of the contour of the anterior axillary fold.



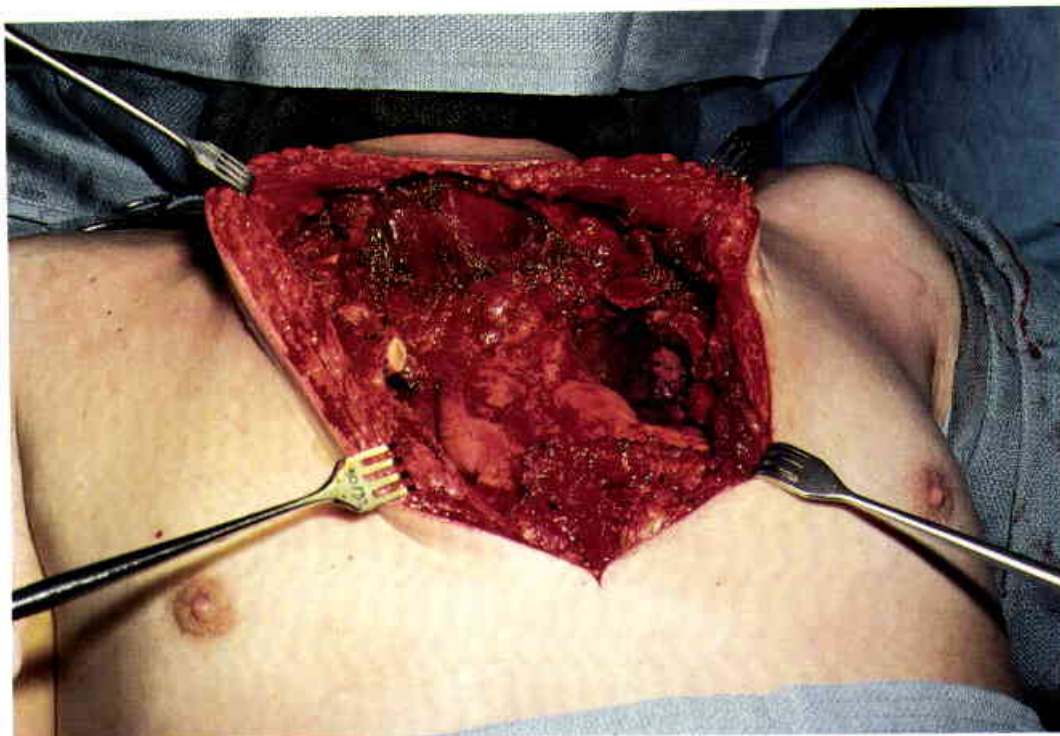
4

The left pectoralis muscle is advanced over the lower sternum after dividing the muscular insertion. The right muscle is rotated onto the upper chest wall after releasing its insertion. Note that a static band of the right pectoralis muscle has been left to simulate the anterior axillary fold.



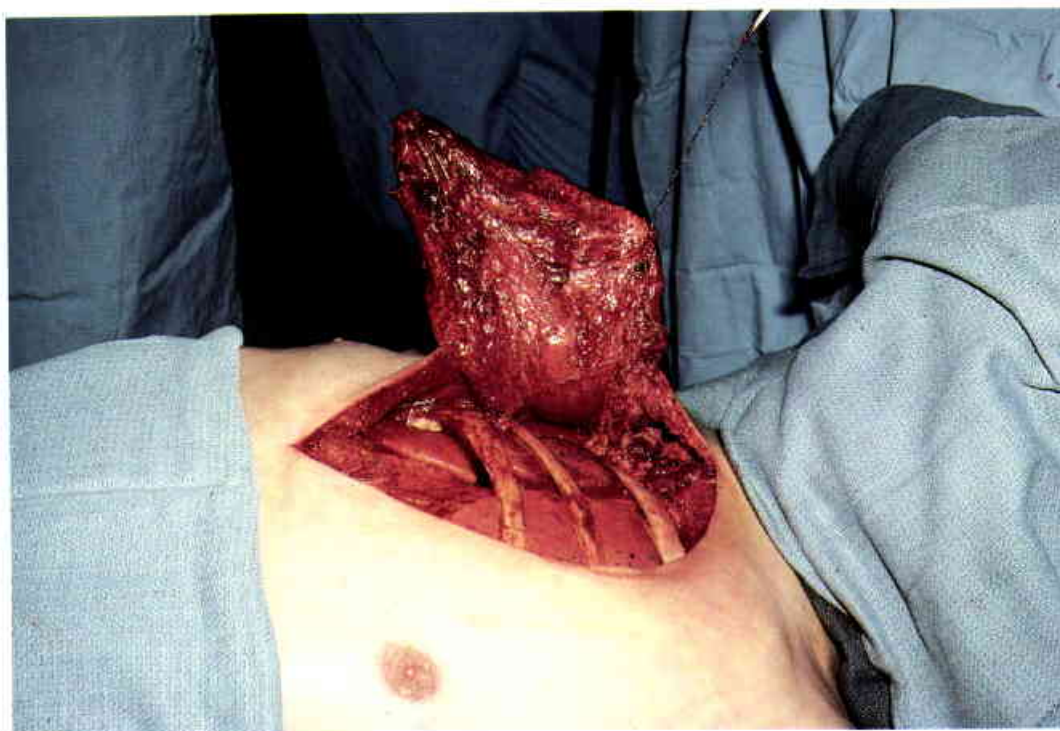5

Crossing pectoralis muscles with the right muscle passed behind the left muscle. Both muscular insertions have been divided.



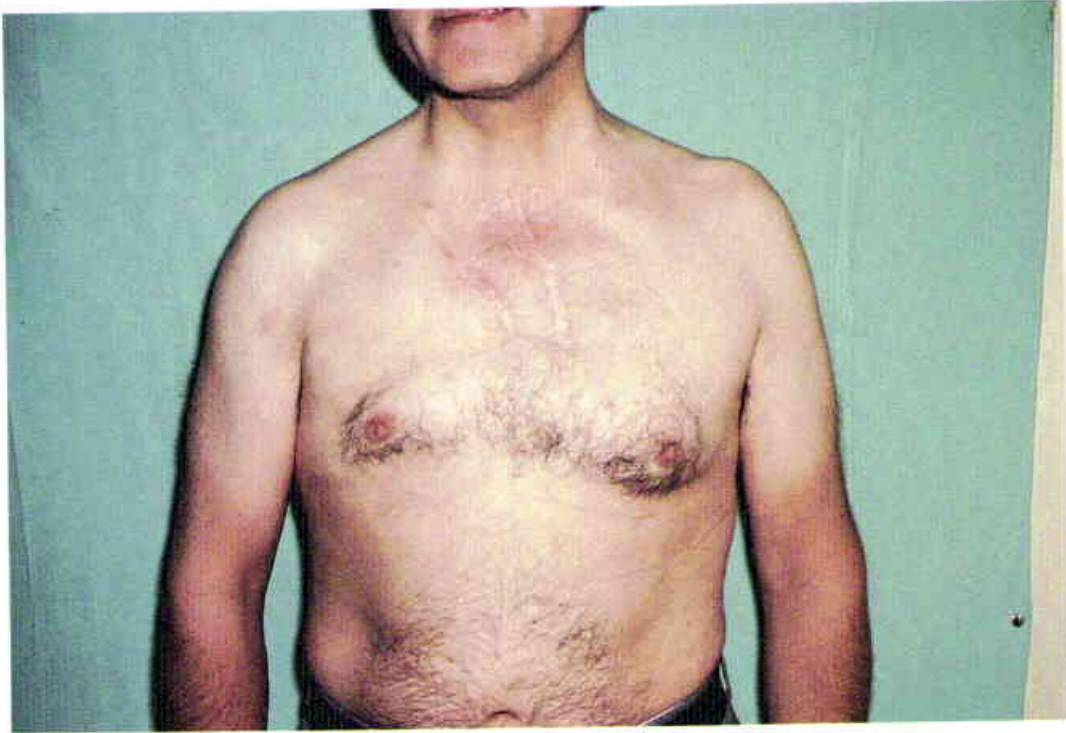6

Chondrosarcoma of the manubrium in a young patient. The resection included the upper two-thirds of the sternum and the adjacent ribs. (Case of P.G. Arnold)



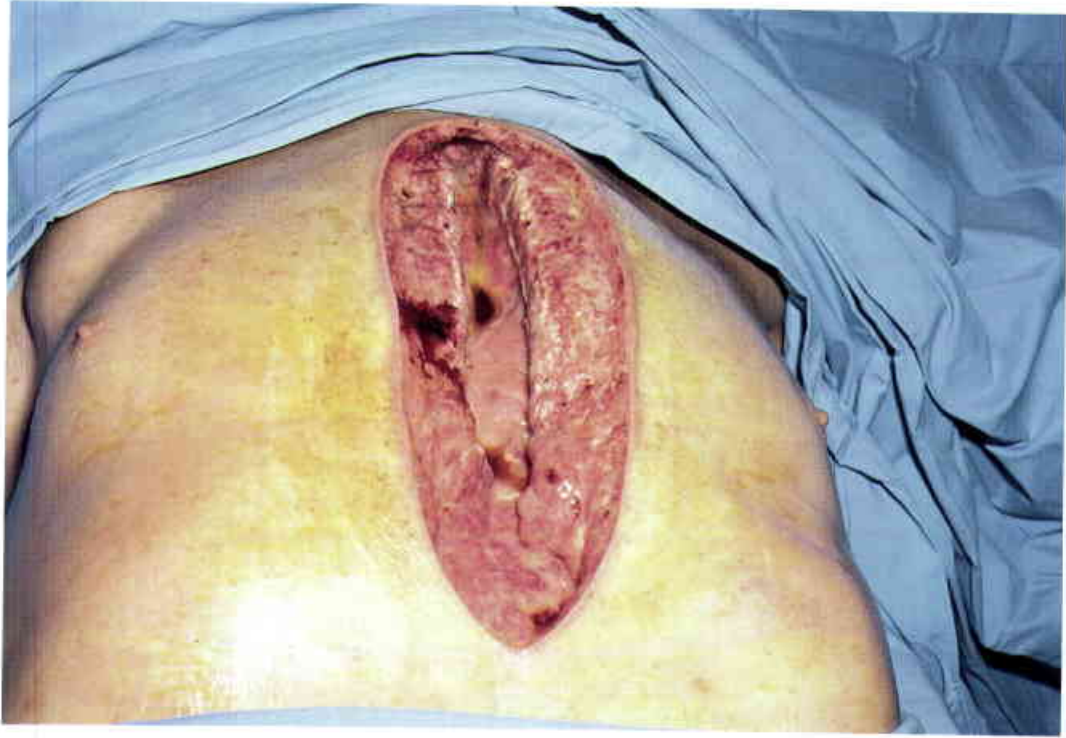
7

The large structural defect has been reconstituted with rib grafts. A right pectoralis major muscle flap is elevated to cover the rib grafts.



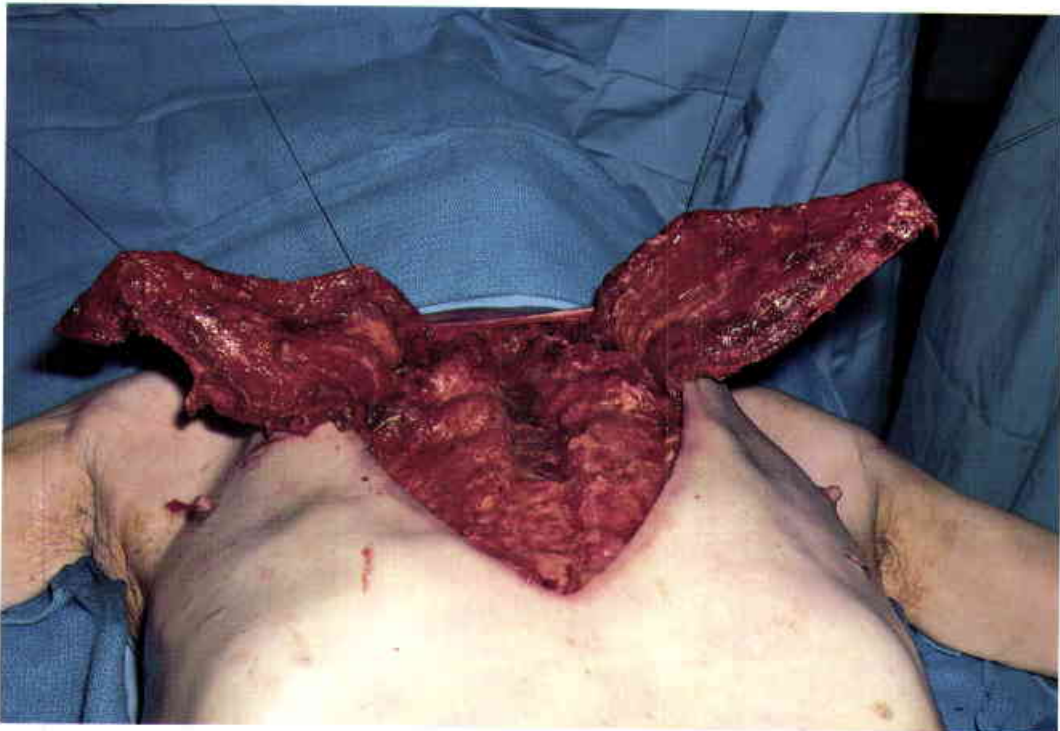
8

Anterior view at three years. Note the
“weakened” right anterior axillary fold.
The patient has survived for eight years.



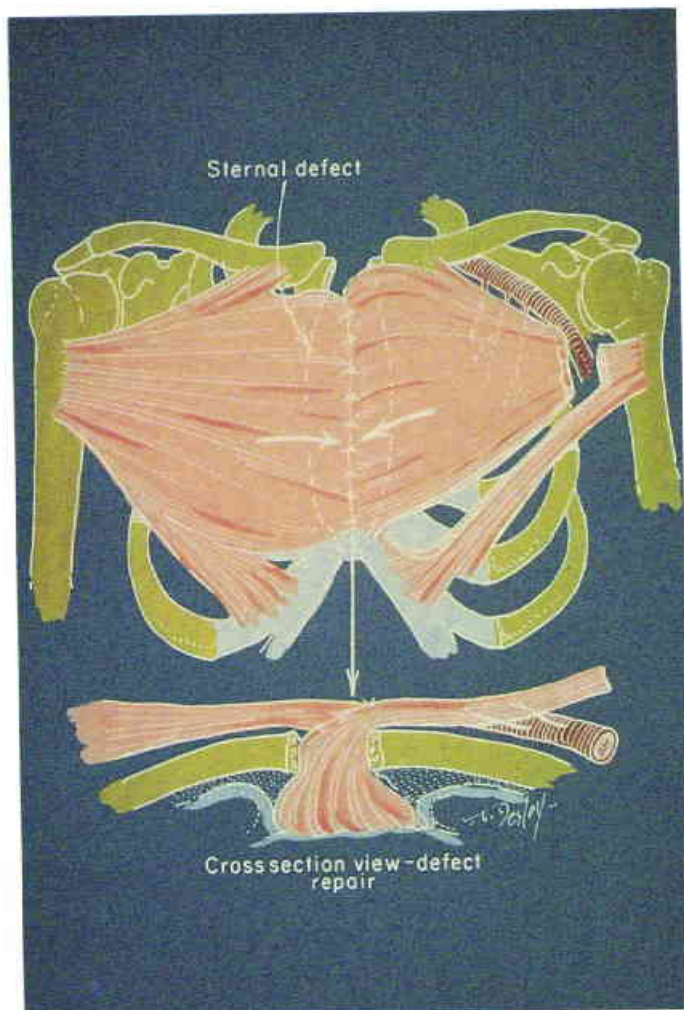
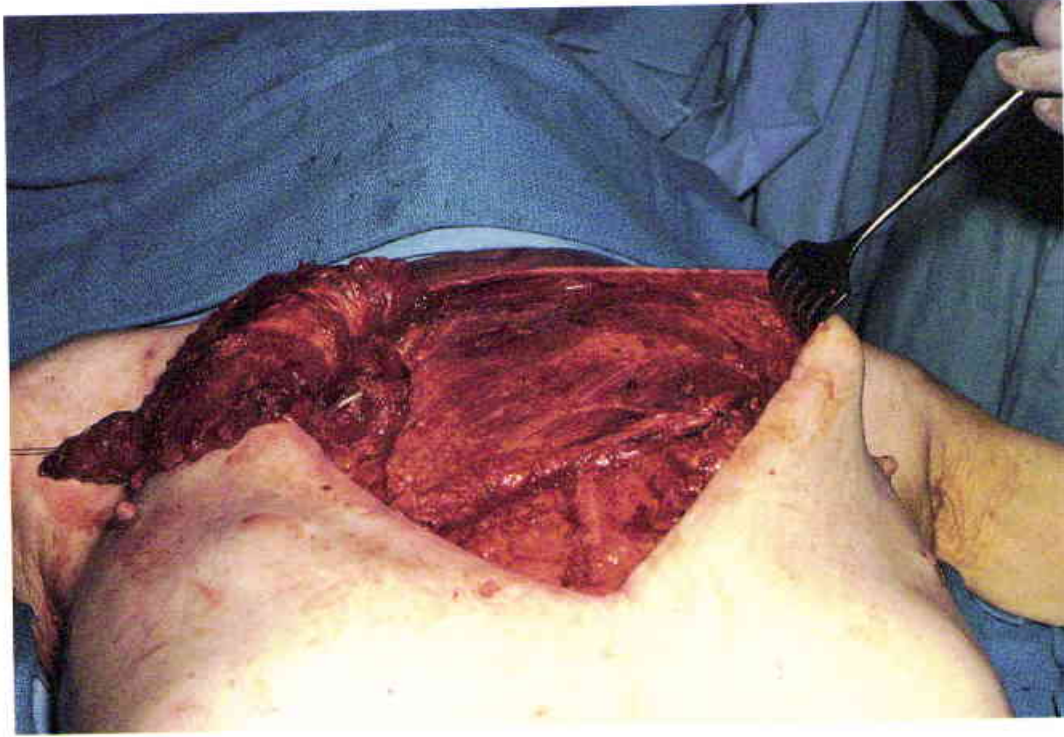
9

Seventy-five-year-old male with an infected median sternotomy following a coronary artery bypass. The open wound was treated with frequent dressing changes and showers until there was no further drainage. (Case of P.G. Arnold)

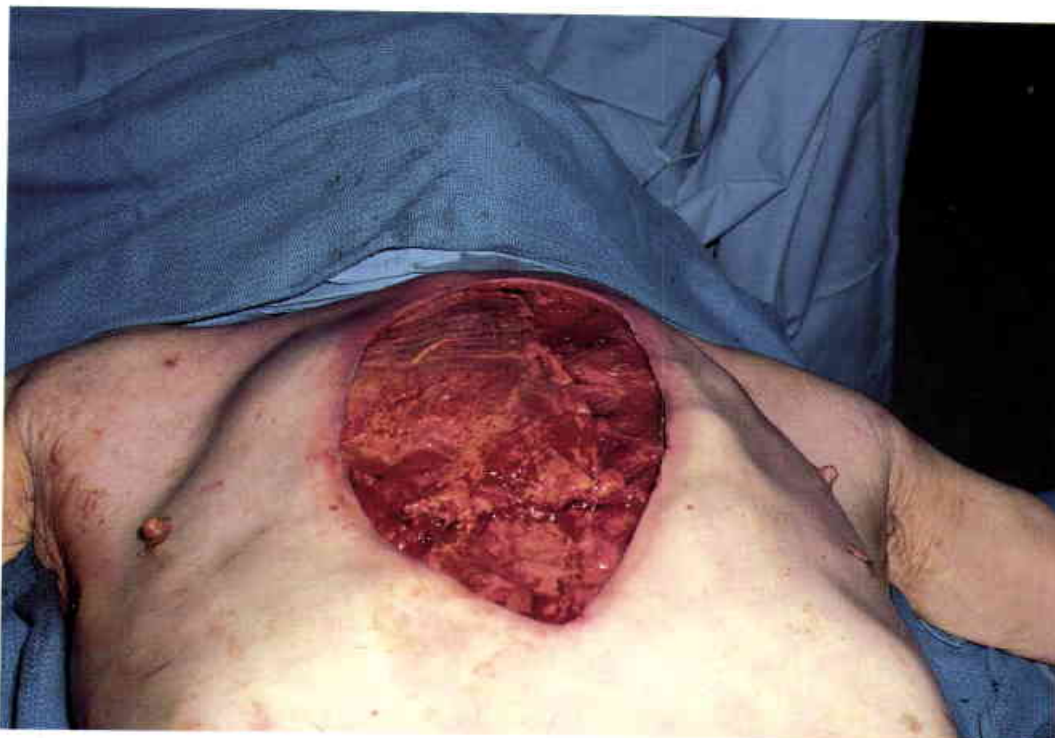

10

Elevation of the pectoralis major muscles at the time of the initial operative debridement.

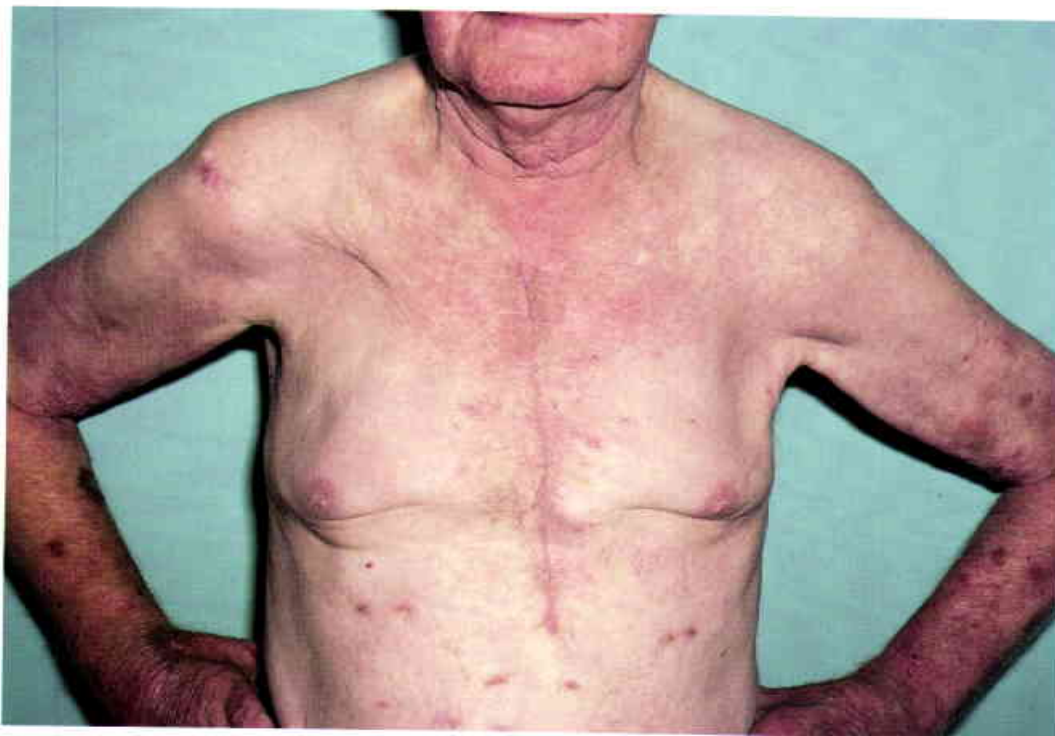**11, 12**

The humeral insertion of the left (non-dominant) pectoralis muscle was divided. This facilitated the movement of the left pectoralis muscle into a mediastinal position (see illustration) to fill in the sternal defect.



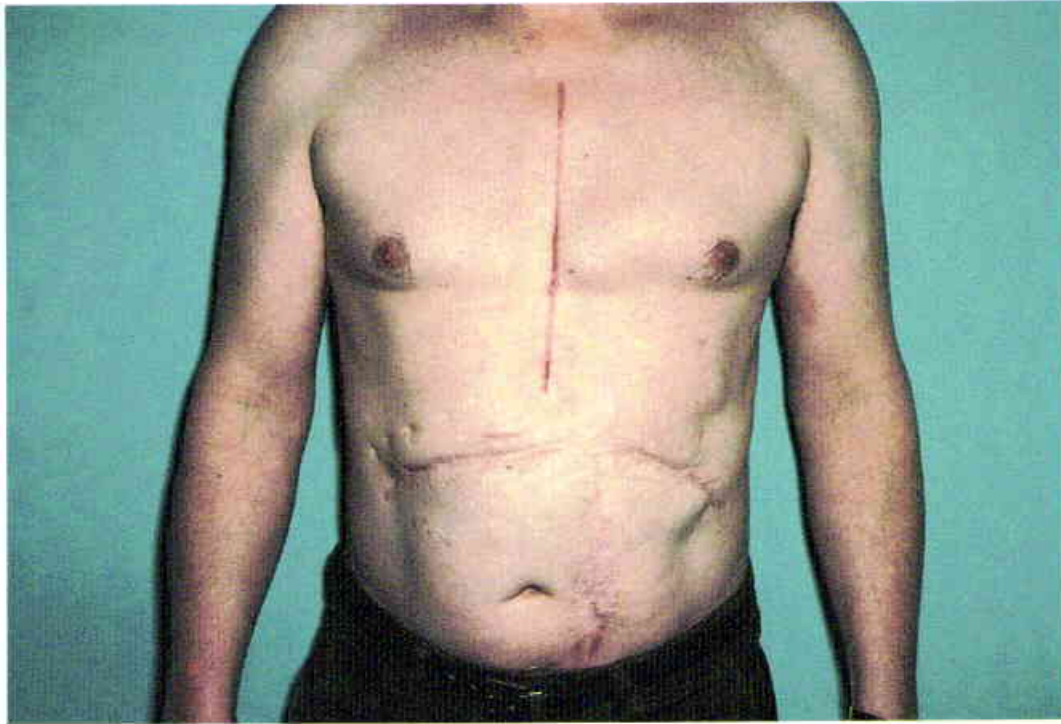
13

The right pectoralis muscle was brought completely over the sternal defect and approximated to the opposite muscle. Both muscular insertions were eventually divided in this case, but it is not always necessary to divide the insertion of the second muscle.



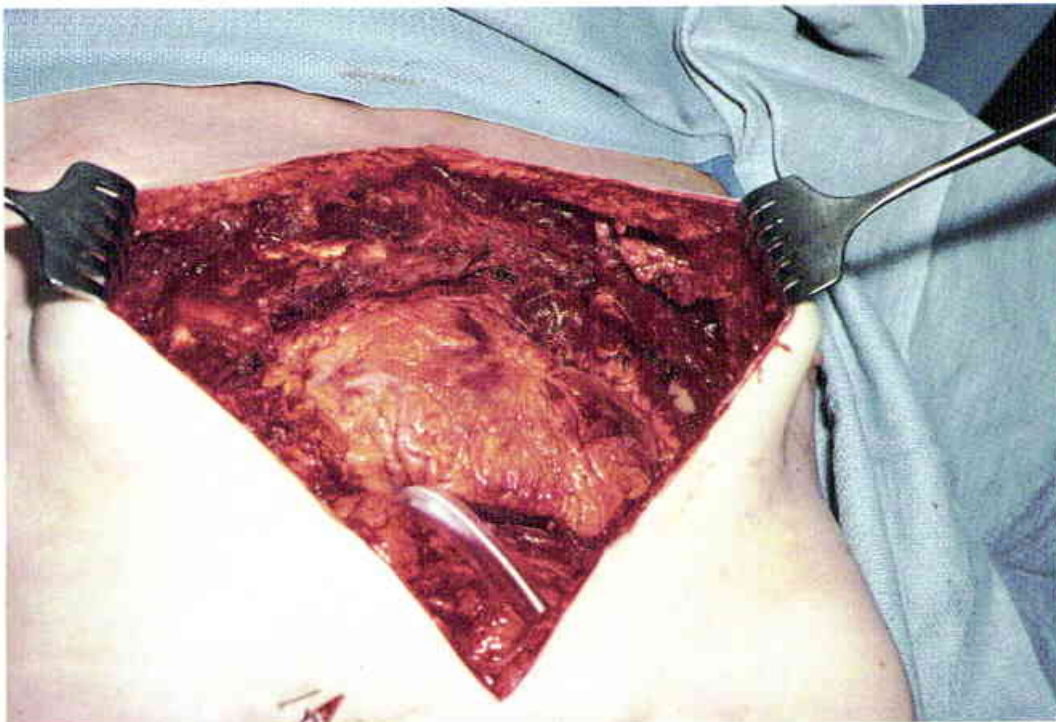
14

Appearance one year following closure. The skin was directly approximated without buried sutures. The contour deformity of the anterior axillary folds is a small price to pay for such a complex wound closure.



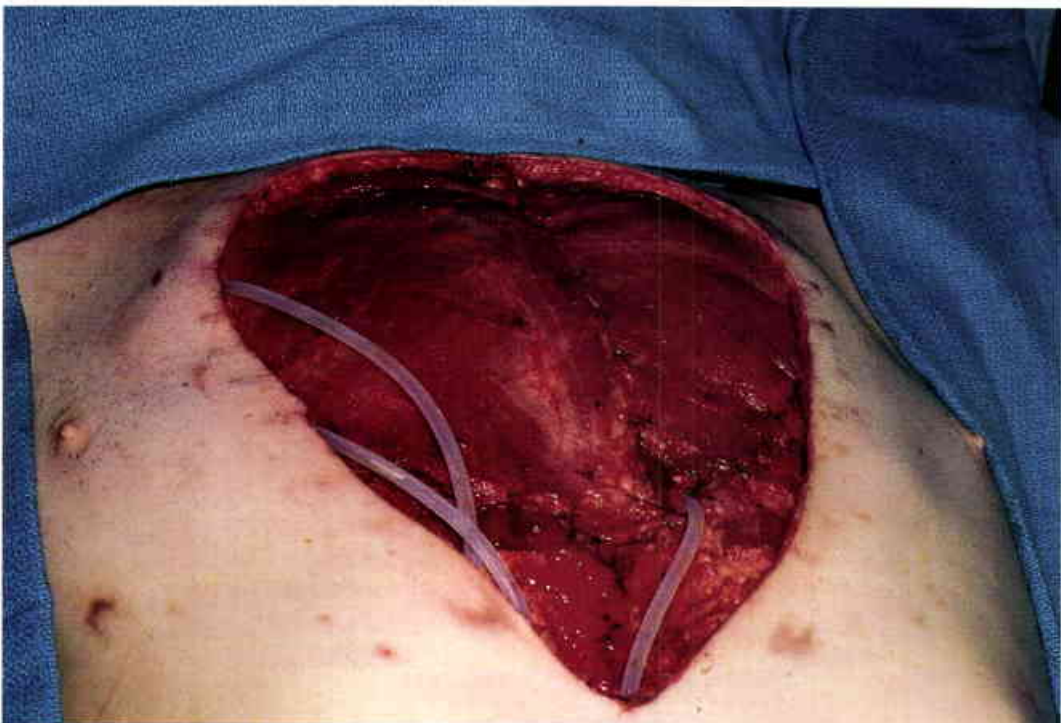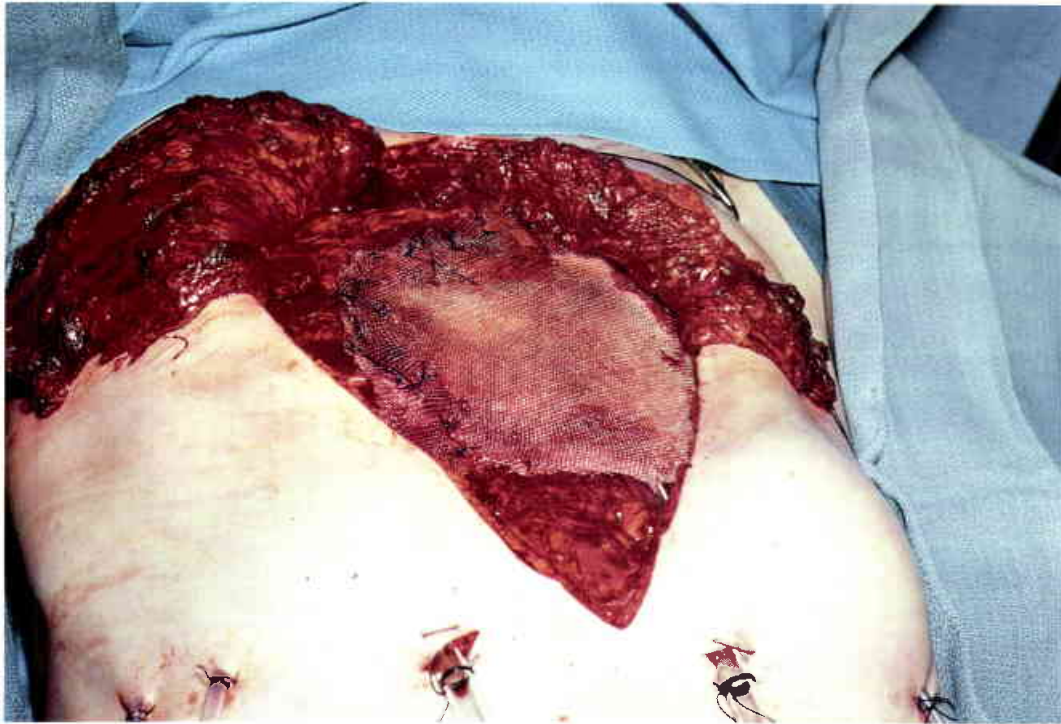
15

Forty-one-year-old man with a recurrent fibrosarcoma of the sternal area. The abdominal scarring is unrelated to the previous sarcoma resection. (Case of P.G. Arnold)



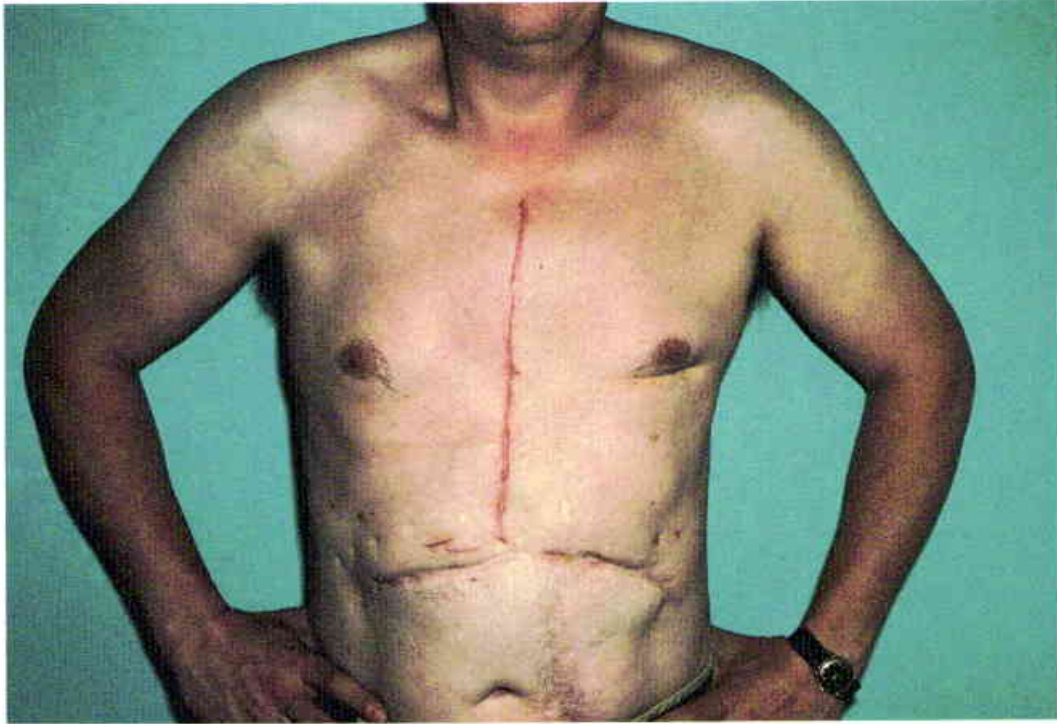
16

The tumor resection included the lower two-thirds of the sternum along with the adjacent costal cartilages and pericardium.



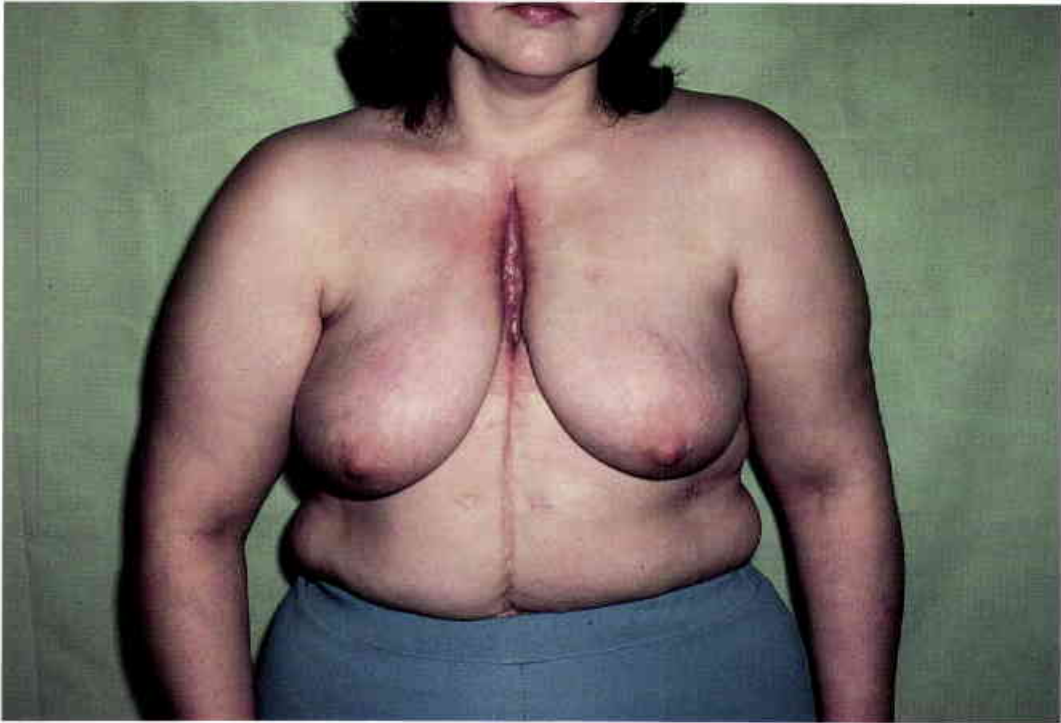
17, 18

Prolene[®] mesh has been used to stabilize the sternal defect. Both pectoralis major muscles are elevated to cover the artificial mesh.



19

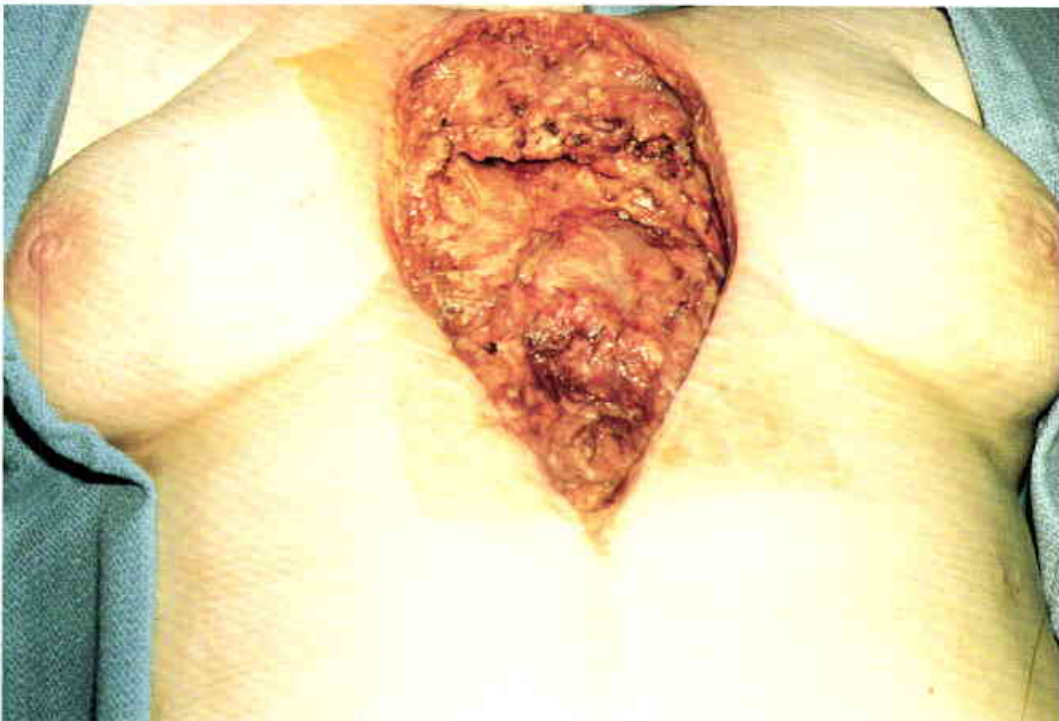Healed wound at six months. The loss of the pectoralis major muscles does not contribute to a significant contour deformity in this patient.



20

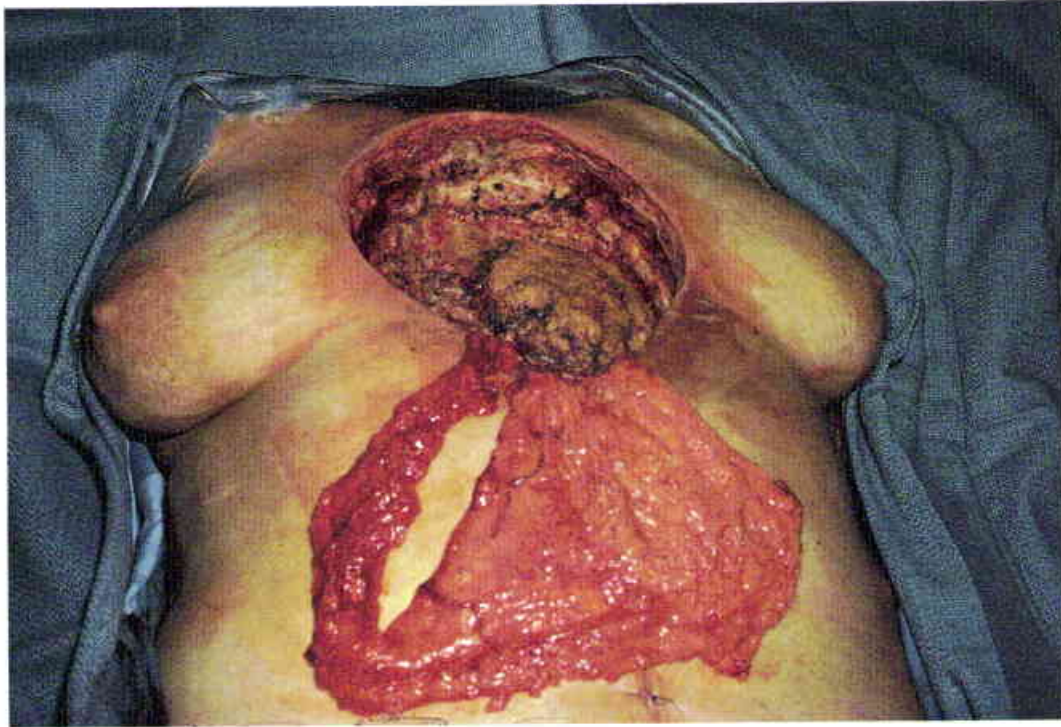
Thirty-five-year-old female following mediastinal irradiation for Hodgkin's disease fifteen years earlier. Two years prior to this photograph a pericardiectomy was

done and the wound never healed. She presents with a persistent osteomyelitis and suppurative mediastinitis with constant drainage. (Case of P.G. Arnold)



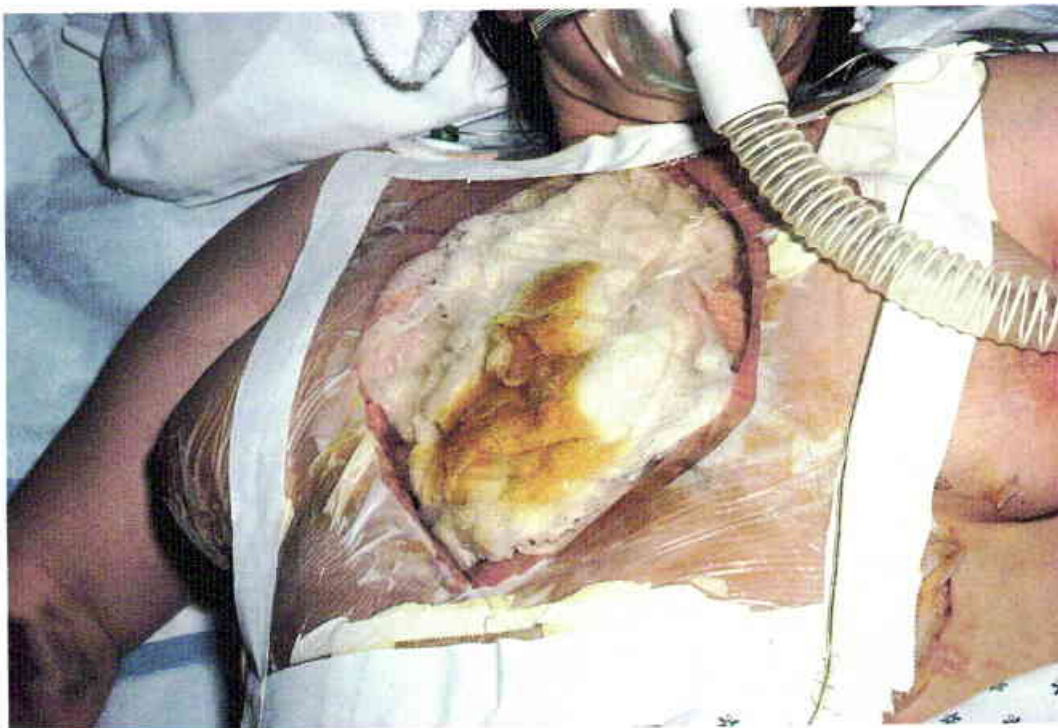
21

The sternum was completely resected at the initial debridement. The suppurative infection diffusely involved the mediastinal structures. The epicardium is exposed and dessicating in spite of constant moist dressings.



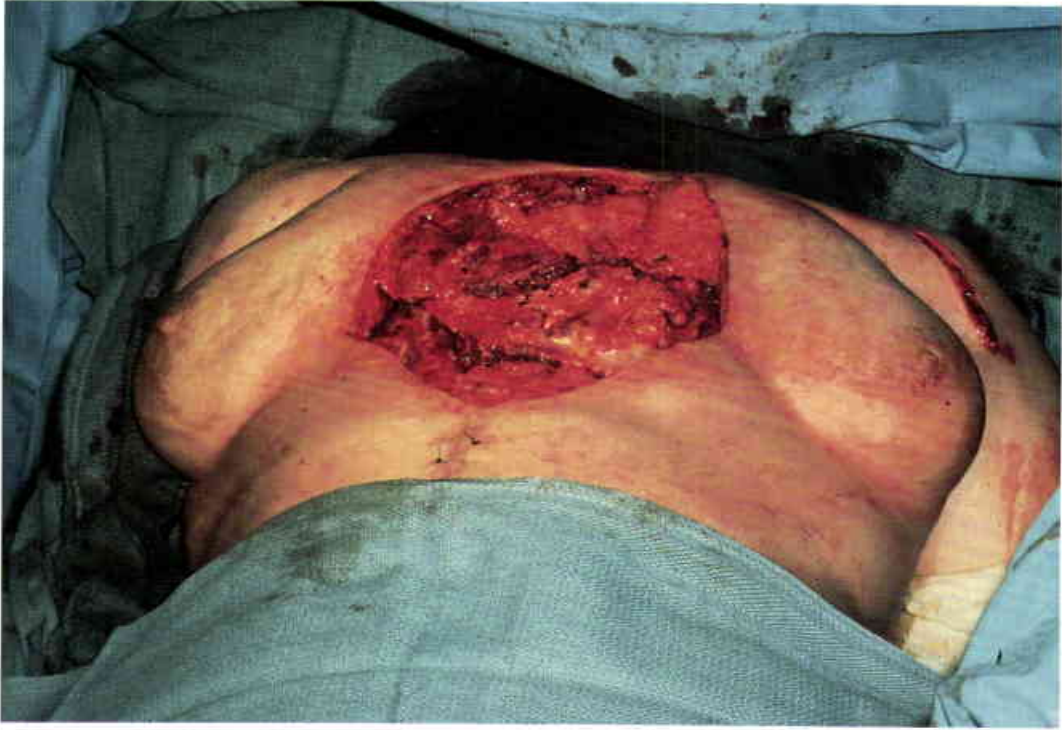22

The omentum was mobilized to cover the exposed heart.



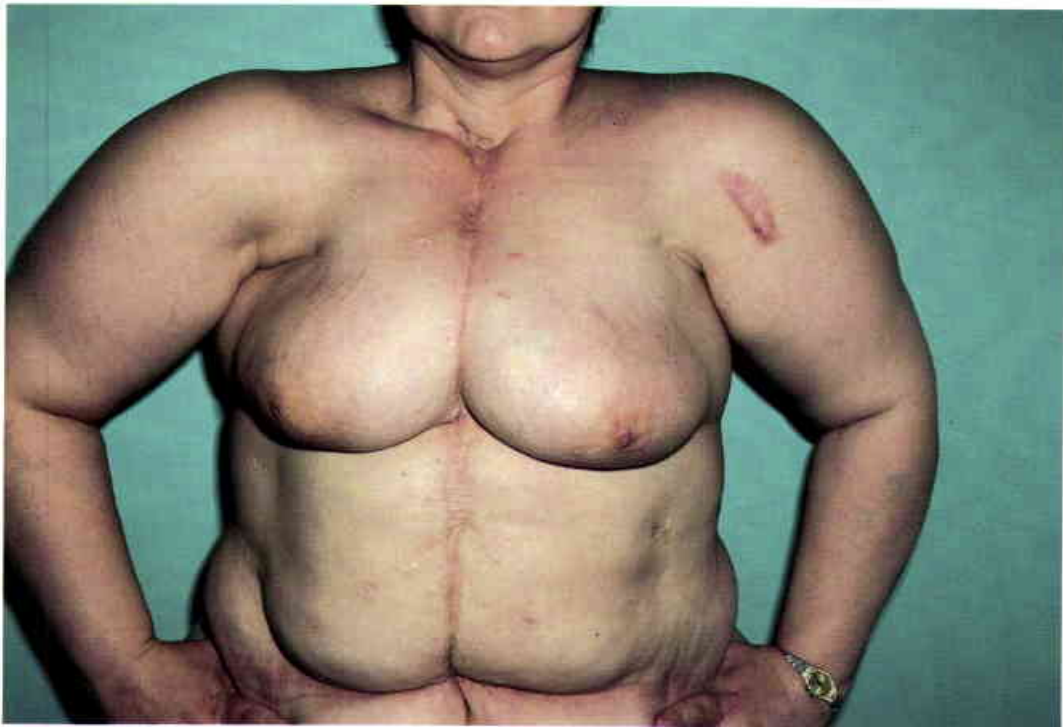
23

Moist gauze dressing changes were continued for a week following the omental transposition to control the mediastinal sepsis.



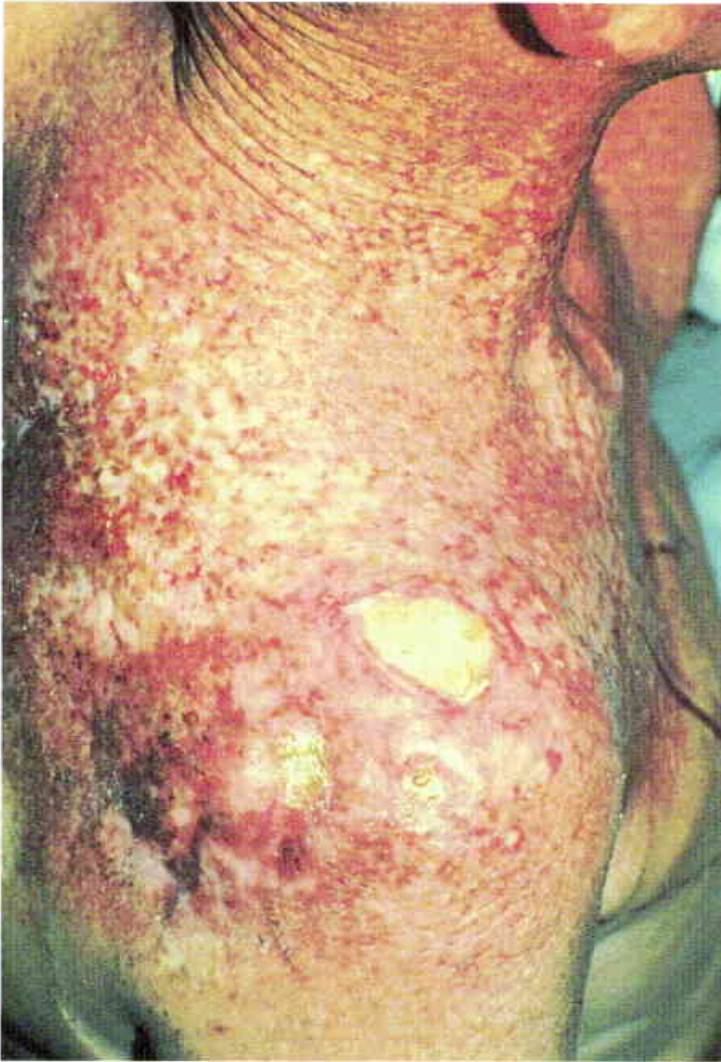24

Both pectoralis major muscles were transposed over the omentum to complete the sternal coverage.



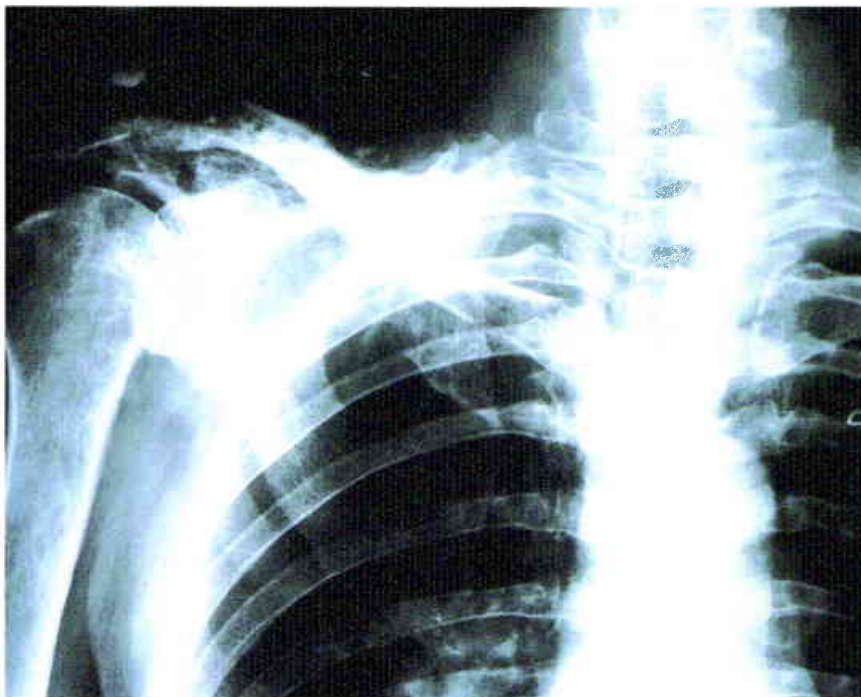25

A midline skin closure was achieved. The wound has remained healed for five years.



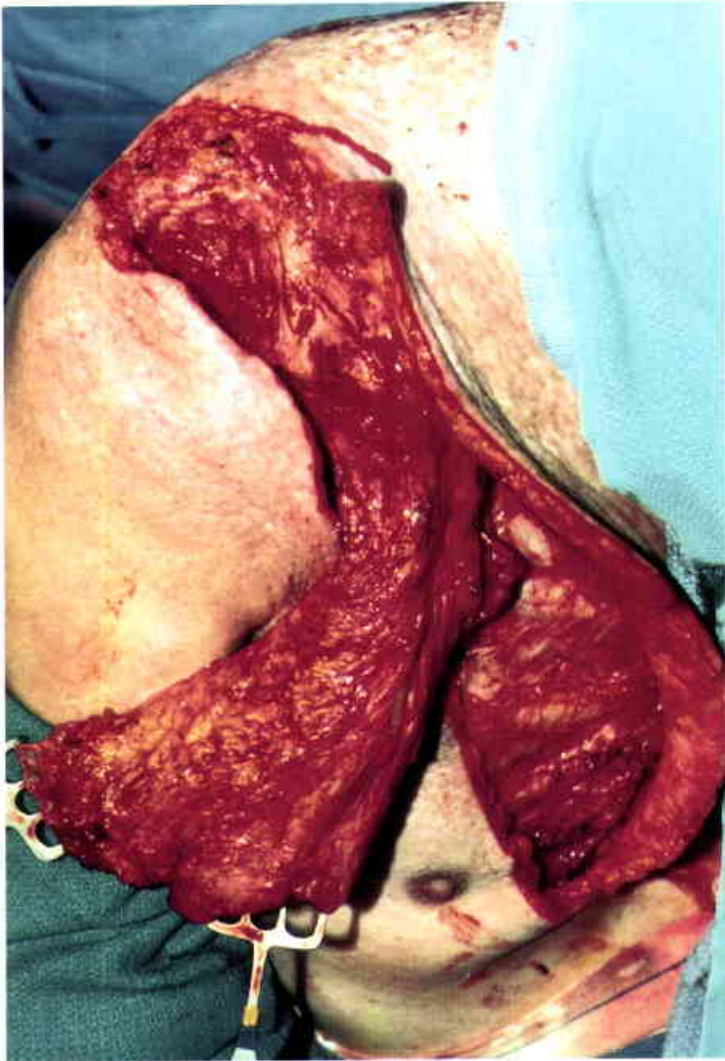
26

Fifty-seven-year-old male with suppurative osteoradionecrosis of the shoulder. The neck was irradiated thirty years earlier for Hodgkin's disease. (Case of J.B. McCraw and R. Neff)



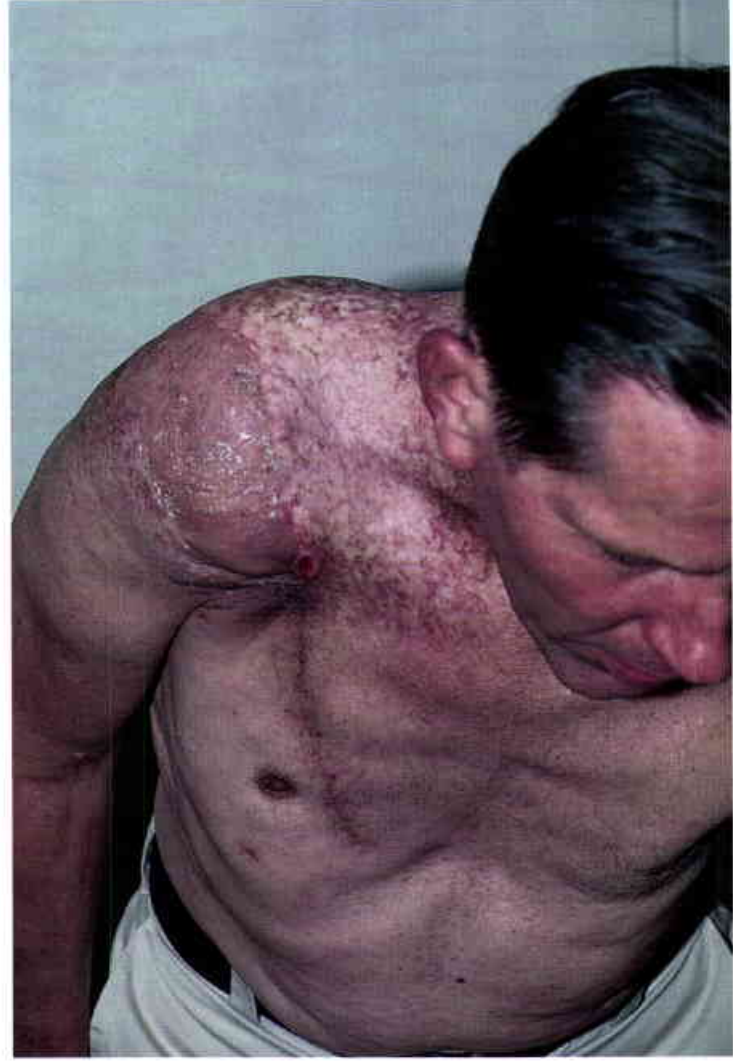27

The entire shoulder girdle is affected by the irradiation damage.



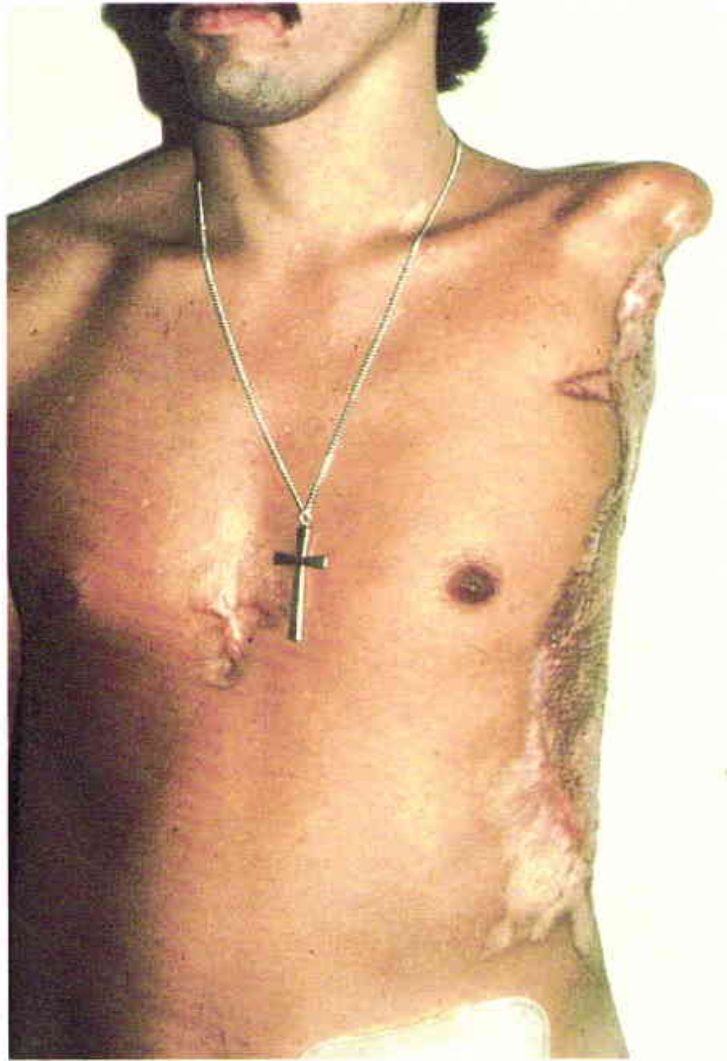28

Resection of the humeral head and the glenoid fossa. The intense irradiation fibrosis made elevation of the pectoralis muscle flap difficult.



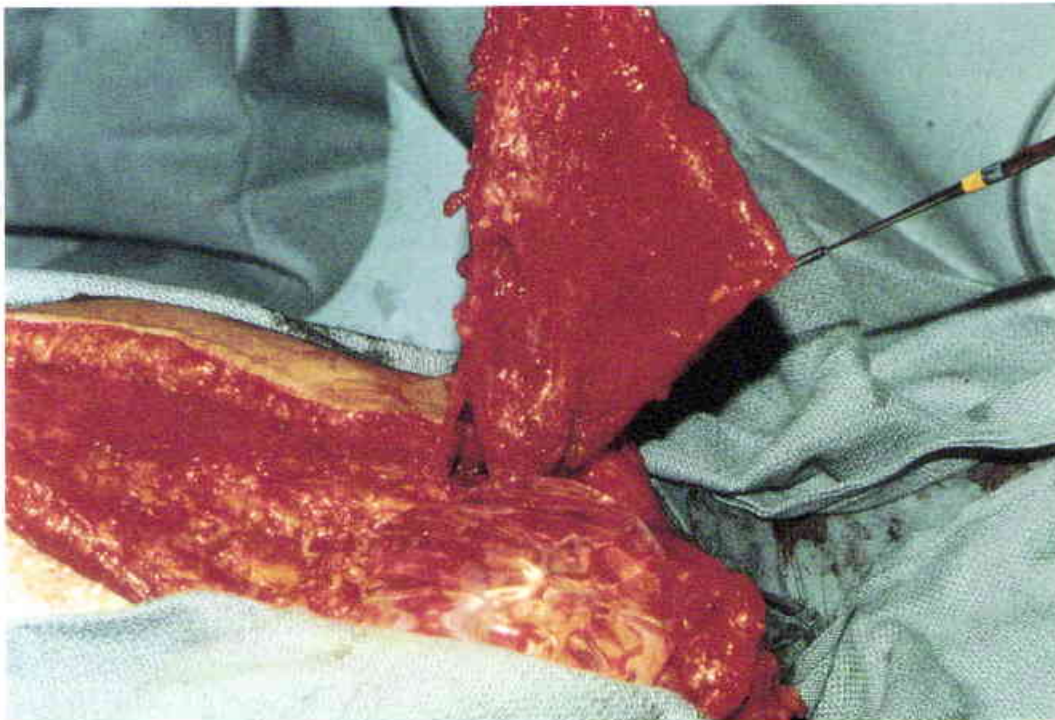
29

Healed skin graft on the pectoralis major muscle. The osteomyelitis was obliterated and shoulder motion was slightly improved. Note the donor site deformity in a thin male.



30

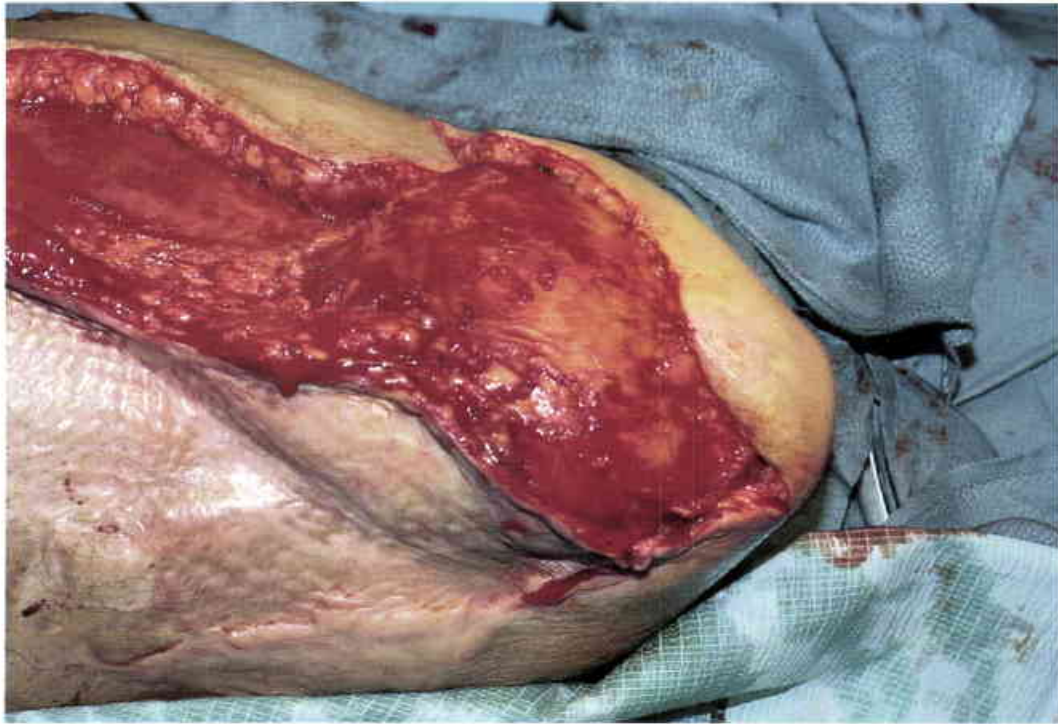
Twenty-four-year-old male who lost his left arm, scapula, and latissimus muscle in a high voltage injury. The skin-grafted clavicle was painful. (Case of J.B. McCraw)



31

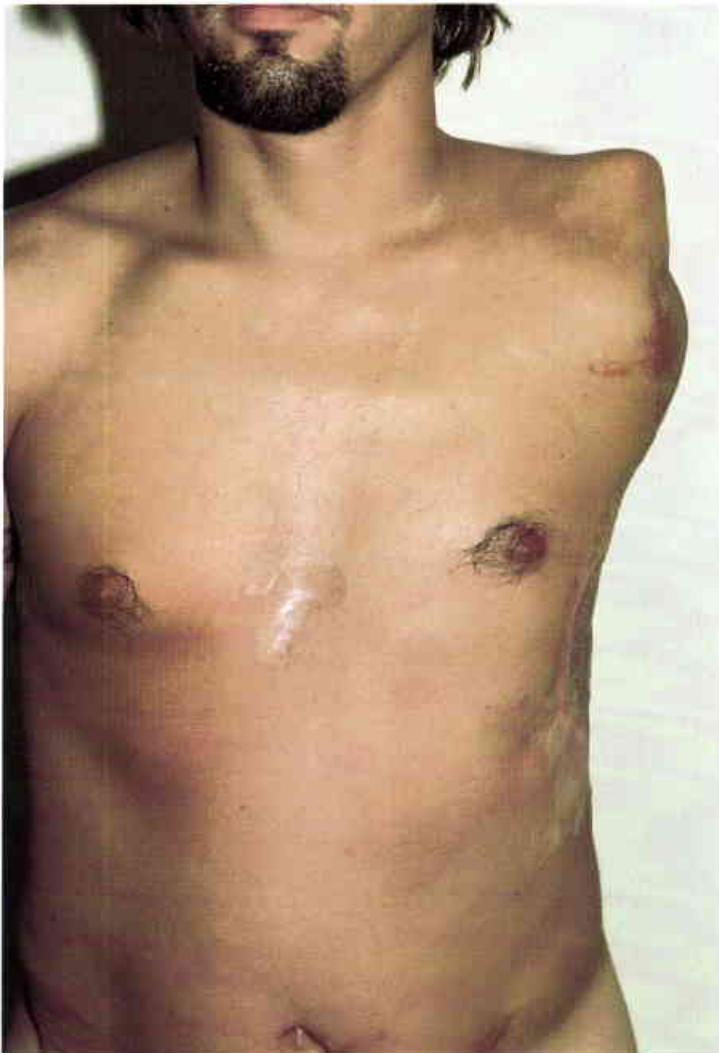A silicone gel breast prosthesis is used to correct the contour deformity. The elevated pectoralis major muscle will cover

the implant which is seen below the clavicle.



32

Lateral view of the shoulder demonstrating the pectoralis muscle covering the silicone implant. The pectoralis muscle was skin grafted.



33

Healed muscle flap and skin graft at six months. The improved soft tissue cover relieved the bone pain and improved his ability to wear normal clothes. As expected, the implant developed a capsule.

PECTORALIS MUSCLE

- Arnold, P.G. and Pairolero, P.C. "Chondrosarcoma of the manubrium: Resection and reconstruction with pectoralis major muscle." *Mayo Clin. Proc.* 53(1): 54, 1978.
- Arnold, P.G. and Pairolero, P.C. "Use of pectoralis major muscle flaps to repair defects of anterior chest wall." *Plast. Reconstr. Surg.* 63: 205, 1979.
- Arnold, P.G. and Pairolero, P.C. "Chest wall reconstruction: Experience with 100 consecutive patients." *Ann. Surg.* 199(6): 725, 1984.
- Atkins, R.M., Bell, M.J., and Sharrard, W.J. "Pectoralis major transfer for paralysis of elbow flexion in children." *J. Bone Joint Surg. (Br.)* 67(4): 640, 1985.
- Baek, S.M., Lawson, W., and Biller, H.F. "An analysis of 133 pectoralis major myocutaneous flaps." *Plast. Reconstr. Surg.* 69(3): 460, 1982.
- Brown, R.G., Fleming, W.H., and Jurkiewicz, M.J. "An island flap of pectoralis major muscle." *Br. J. Plast. Surg.* 30: 161, 1977.
- Burman, M. "The pectoralis major tendon as retinaculum of the long head of the biceps." *Bull. Hosp. Joint Dis.* 33(1): 80, 1972.
- Calteux, N., Hamoir, M., de Coninck, A. "Mediastinal tracheostomy with a pectoralis major musculocutaneous island flap." *Am. Chir. Plast. Esth.* 30: 283, 1985.
- Cantrell, R.W. "Myocutaneous flaps." *Otolaryngol Clin. North Am.* 16(2): 353, 1983.
- Castilla, E.E., Paz, J.E., and Orioli, I.M. "Pectoralis major muscle defect and Poland complex." *Am. J. Med. Genet.* 4(3): 263, 1979.
- Carroll, R.E. and Kleinman, W.B. "Pectoralis major transplantation to restore elbow flexion to the paralytic limb." *J. Hand Surg. (Am.)* 4(6): 501, 1979.
- Coleman, J.J., III. "Complex thoracic wounds: muscle and musculocutaneous anatomy in closure." *South Med. J.* 78(2): 125, 1985.
- Davis, R.K. and Price, J.C. "Bipedicled delay of the deltopectoral flap in raising the pectoral myocutaneous flap." *Laryngoscope* 94(4): 554, 1984.
- Desphieux, J.L., Ducasse, A., and Lelattre, J.F. "The pectoralis major musculocutaneous flap: an anatomical study." *Ann. Chir. Plast. Esth.* 29: 23, 1984.
- Dowden, R.V. and McCraw, J.B. "Muscle flap reconstruction of shoulder defects." *J. Hand Surg.* 5(4): 382, 1980.
- Evans, P.H. and Das Gupta, A.R. "The use of the pectoralis major myocutaneous flap for one-stage reconstruction of the base of the tongue." *J. Laryngol. Otol.* 95(8): 809, 1981.
- Frias, J.L. and Felman, A.H. "Absence of the pectoralis major, with ipsilateral aplasia of the radius, thumb, hemidiaphragm and lung: an extreme expression of Poland anomaly?" *Birth Defects* 10(5): 55, 1974.
- Gardiner, L.J., Ariyan, S., and Pillsbury, H.C., III. "Myocutaneous flaps for challenging problems in head and neck reconstruction." *Arch. Otolaryngol* 109(6): 396, 1983.
- Gudmundsson, B. "A case of rupture of the pectoralis major muscle." *Acta. Orthop. Scand.* 44(2): 213, 1973.
- Harii, K., Ono, I., and Ebihara, S. "Closure of total cheek defects with two combined myocutaneous free flaps." *Arch. Otolaryngol.* 108(5): 303, 1982.
- Harrison, D.H. "The pectoralis minor vascularized muscle graft for the treatment of unilateral facial palsy." *Plast. Reconstr. Surg.* 75(2): 206, 1985.
- Hedge, H.R. and Shokeir, M.H. "Posterior shoulder girdle abnormalities with absence of pectoralis major muscle." *Am. J. Med. Genet.* 13(3): 285, 1982.
- Hueston, J.T. and McConchie, I.H. "A compound pectoral flap." *Aust. N.Z. J. Surg.* 38(1): 61, 1968.
- Johnsonbaugh, R.E., Catalano, J.D., and Meyer, B.P. "Congenital, unilateral absence of the breast and pectoralis major muscle." *South Med. J.* 64(4): 465, 1971.
- Jonsson, B., Olofsson, B.M., and Steffner, L.C. "Function of the teres major latissimus dorsi and pectoralis major muscles: A preliminary study." *Acta. Morpho. Neerl. Scand.* 9(4): 275, 1972.
- Jurkiewicz, M.J., and Arnold, P.G. "The omentum: an account of its use in reconstruction of the chest wall." *Ann. Surg.* 185: 548, 1977.
- Jurkiewicz, M.J., Bostwick, J., III, and Hester, T.R. "Infected median sternotomy wound: successful treatment with muscle flap." *Am. Surg.* 191: 738, 1980.
- Larson, D.L. and McMurtrey, M.J. "Musculocutaneous flap reconstruction of chest-wall defects: an experience with 50 patients." *Plast. Reconstr. Surg.* 73(5): 734, 1984.
- Maier, H.C. and Luomanen, R.K.J. "Pectoral myoplasty for closure of residual empyema cavity and bronchial fistula." *Surgery* 25: 621, 1949.
- Manktelow, R.T. "Discussion of the pectoralis minor vascularized muscle graft for the treatment of unilateral fascial palsy." *Plast. Reconstr. Surg.* 75: 214, 1985.
- Manktelow, R.T., McKee, N.H., and Vettese, T. "An anatomical study of the pectoralis major muscle as related to functioning free muscle transplantation." *Plast. Reconstr. Surg.* 65(5): 610, 1980.
- McCraw, J.B., Dibbell, D.G., and Carraway, J.H. "Clinical definition of independent myocutaneous vascular territories." *Plast. Reconstr. Surg.* 60: 341, 1977.
- McEntire, J.E., Hess, W.E., and Coleman, S.S. "Rupture of the pectoralis major muscle: A report of eleven injuries and review of fifty-six." *J. Bone Joint Surg. (Am.)* 54(5): 1040, 1972.
- Morain, W.D., Colen, L.B., and Hutchings, J.C. "The segmental pectoralis major muscle flap: a function-preserving procedure." *Plast. Reconstr. Surg.* 75(6): 825, 1985.

PECTORALIS MUSCLE

- Morris, D.M., Reed, W., and Cunningham, M. "Primary head and neck reconstruction with a simultaneous ipsilateral pectoralis major myocutaneous flap and deltopectoral flap." *J. Surg. Oncol.* 25(1): 50, 1984.
- Nahai, F., Morales, L., Jr., Bone, D.K., and Bostwick, J., III. "Pectoralis major muscle turnover flaps for closure of the infected sternotomy wound with preservation of form and function." *Plast. Reconstr. Surg.* 70(4): 471, 1982.
- Pairolero, P.C. and Arnold, P.G. "Bronchopleural fistula: treatment by transportation of pectoralis major muscle." *J. Thorac. Cardiovasc. Surg.* 79(1): 142, 1980.
- Pearl, S.N. and Dibbell, D.G. "Reconstruction after median sternotomy infection." *Surg. Gynecol. Obstet.* 159(1): 47, 1984.
- Rees, R.S., Ivey, G.L., Shock, R.B., et al. "Pectoralis major myocutaneous flaps: long-term follow-up of hypopharyngeal reconstruction." *Plast. Reconstr. Surg.* 77: 586, 1986.
- Reid, C.D. and Taylor, G.I. "The vascular territory of the acromiothoracic axis." *Br. J. Plast. Surg.* 37(2): 194, 1984.
- Robertson, M.S. and Robinson, J.M. "Immediate pharyngoesophageal reconstruction. Use of a quilted skin-grafted pectoralis major muscle flap." *Arch. Otolaryngol.* 11(6): 386, 1984.
- Sisson, G.A., Strachley, C.J., Jr., and Johnson, N.E. "Mediastinal dissection for recurrent cancer after laryngectomy." *Laryngoscope* 72: 1064, 1962.
- Tobin, G.R. "Pectoralis major segmental anatomy and segmentally split pectoralis major flaps." *Plast. Reconstr. Surg.* 75: 814, 1985.
- Tsai, T.M., Kalisman, M., Burns, J., and Kleinert, H.E. "Restoration of elbow flexion by pectoralis major and pectoralis minor transfer." *J. Hand Surg. (Am.)* 8(2): 186, 1983.
- Urs, N.D. and Jani, D.M. "Surgical repair of rupture of the pectoralis major muscle: a case report." *J. Trauma* 16(9): 749, 1976.
- Weber-Laumann, A. "Recurrent dislocation of the shoulder treated by transposition of the tendon to pectoralis minor: a follow-up of fifteen patients." *Acta. Orthop. Scand.* 41(2): 161, 1970.
- Wilk, A., Balme, P., Keiling, R., et al. "The use of the pectoralis major flap in the cervicomaxillary surgery of irradiated patients." *Ann. Chir. Plast. Esth.* 30: 373, 1985.
- Withers, E.H., Franklin, J.D., Madden, J.J., and Lynch, J.B. "Immediate reconstruction of the pharynx and cervical esophagus with the pectoralis major myocutaneous flap following laryngopharyngectomy." *Plast. Reconstr. Surg.* 68(6): 898, 1981.