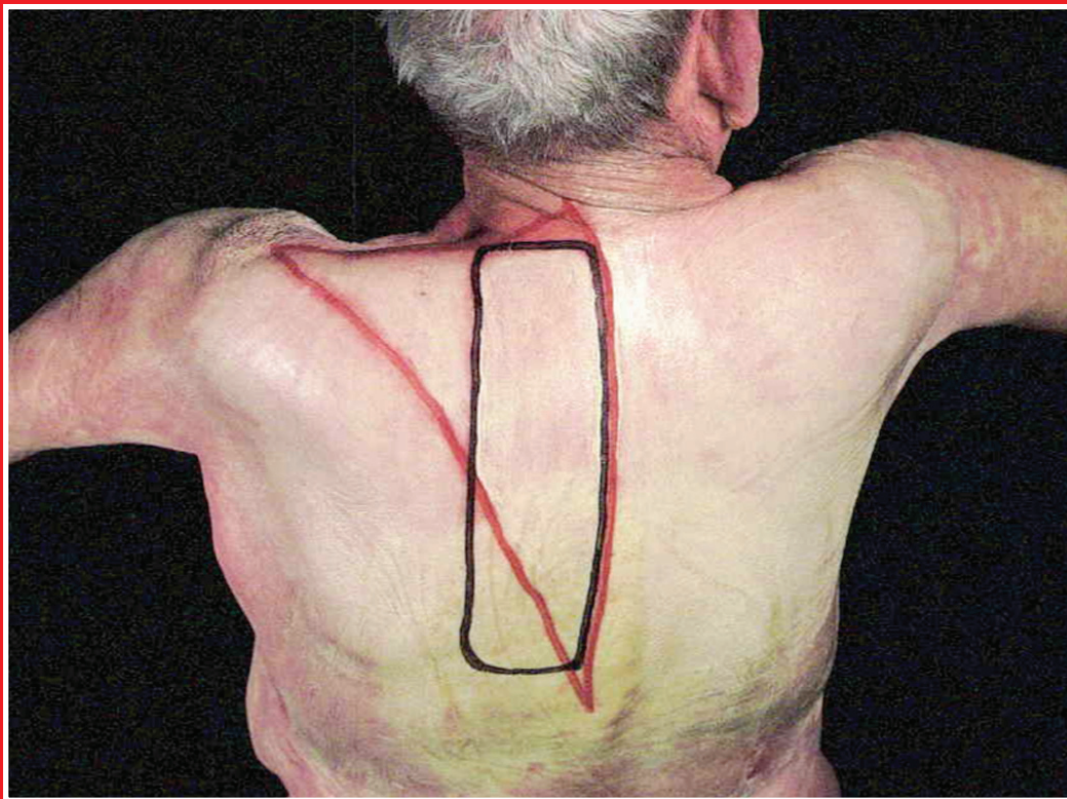

McCraw and Arnold's Atlas of Muscle and Musculocutaneous Flaps



John B. McCraw
Phillip G. Arnold



Global-HELP
Publication

GLUTEUS MAXIMUS

ANATOMICAL CONSIDERATIONS

Surface Markings

The belly of the gluteus maximus muscle forms the bulk of the buttock. The medial margin is densely attached to the sacrum, and the inferior margin loosely creates the gluteal fold. The superior edge is palpable at the posterior border of the iliac crest.

Origin and Insertion

The majority of the muscle originates from the lateral margin of the sacrum and from the posterior superior iliac crest. To a lesser extent, it arises from the coccyx and the sacrotuberous ligament. The width of this quadrilateral shaped muscle is maintained throughout its course as it passes anterior to the greater trochanter and into the iliotibial tract. The muscle inserts more extensively into the iliotibial tract than it does into the greater trochanter. Unlike the vertically oriented gluteus medius and tensor muscles, which act as abductors and internal rotators of the hip, the gluteus maximus muscle is the strongest external rotator and extensor of the hip. These two motions are effected through the bidirectional insertion of the gluteus maximus muscle. The upper half of the muscle “wraps” horizontally around the greater trochanter and contributes to stair climbing and jogging. The lower half of the muscle inserts vertically into the iliotibial tract. Although both of these insertions contribute to abduction of the thigh at the hip joint, the upper half of the gluteus maximus muscle is more important to this function.

Adjacent Muscles

In its superior half the gluteus maximus overlies the gluteus medius muscle. Below this it covers the piriformis, obturator, and quadratus femoris muscles. The sciatic nerve is the most important structure in this area as it passes beneath the piriformis muscle and over the obturator internus and obturator externus muscles. The inferior gluteal nerve arises from the sciatic nerve to supply the gluteus maximus muscle while the superior gluteal nerve supplies the gluteus medius and gluteus minimus muscles. In the upper half of the buttock there is a distinct plane between the gluteus maximus and gluteus medius muscles, but in the lower half of the buttock the plane between the gluteus maximus muscle and the deeper muscles is less distinct. For this reason, the gluteus maximus muscle is initially identified at either the posterior iliac crest or the lateral sacral margin. The vertically oriented muscle fibers of the gluteus medius muscle and the transversely oriented fibers of the gluteus

maximus muscle facilitate the identification of each muscle.

Vascular Pattern

The gluteus maximus muscle has a dual blood supply from the superior and inferior gluteal vessels which arise from the internal iliac vessels. The piriformis muscle serves as the landmark which separates these two sets of vessels. The superior vessels pass above the piriformis muscle, and the inferior vessels pass below it. The superior vessels can be predictably located at a point three centimeters lateral to the sacrum and five centimeters below the posterior superior iliac spine. The larger inferior gluteal vessels pass beneath the piriformis muscle just medial to the sciatic nerve at a point five centimeters from the sacral edge. There is usually a duplicate branch of the inferior gluteal vessels which passes to the lower half of the muscle. Even though the inferior gluteal vessels are dominant, the excellent intramuscular vascular connections allow the gluteus maximus muscle to be supplied by either set of vessels.

Motor Nerve

Inferior gluteal nerve (L-5, S-1, S-2).

Sensory Nerves

Superior, medial, and inferior clunial nerves.

USES

The gluteus maximus myocutaneous flap serves as the primary choice for coverage of the sacrum and as a secondary flap source for the ischium. In either case it can be used as a rotational flap, but it is more often moved in a V to Y fashion. For sacral coverage problems the flap is usually rotated on the superior gluteal vessels. However, the inferior gluteal vessels are more often used to supply the flap for ischial coverage. When bilateral V to Y flaps are employed for sacral defects, it is seldom necessary to divide either set of vessels or to release the muscular insertions.

The gluteus maximus muscle can also be split in the line of its fibers into caudal and cranial “island” myocutaneous flaps. An isolated “island” of skin can be placed on the lateral aspect of the gluteus maximus muscle and the donor site can be primarily closed. The cranial split “island” flap will reach the lumbar area and it has also been employed as a “free” flap donor site for breast reconstruction. The caudal split island flap can be used to transfer skin to the ischium and the central perineum because of the proximate rotation point

of the inferior gluteal vessels. The gluteus maximus is rarely used as an isolated muscle flap because the amount of coverage provided by the pure muscle flap is disappointing and because a skin grafted muscle flap seems to be less durable than a standard myocutaneous flap.

REGIONAL FLAP COMPARISONS

The gluteus maximus musculocutaneous flap is the predominant flap chosen for coverage of the sacral area. As a bilateral V-Y flap it can cover essentially any sacral defect and later be readvanced to solve a subsequent sacral problem. Both the "reversed" latissimus dorsi myocutaneous flap and the intercostal "island" flap will reach the lower lumbar and upper sacral areas. However, both offer significant disadvantages in their complicated dissections, and neither will cover a large central sacral defect. The intercostal flap requires a preliminary "delay" and a complex intrathoracic dissection, but it does provide sensibility to its site of inset. Although the "reversed" latissimus flap is reasonably reliable, the dissection of the deep perforating vasculature is tedious and the arc of rotation is variable. It certainly is not applicable to most sacral defects. A transverse back flap is seldom considered because it is much less reliable than the gluteus maximus myocutaneous flap and because it leaves a skin-grafted donor site. Because of its better survivability, the cranial split "island" gluteus maximus myocutaneous flap would always be preferentially considered over both the "reversed" latissimus and the transverse back flaps.

Although the gluteus maximus myocutaneous flap can be used for ischial coverage problems, it must be compared to the equally reliable and less complicated V to Y biceps femoris myocutaneous flap. The V-Y biceps femoris flap is electively chosen for an isolated ischial ulcer, leaving the unique gluteus maximus flap in "reserve" for a subsequent sacral ulcer. When the biceps femoris flap is unavailable for coverage of an isolated ischial ulcer, the gluteus maximus flap can also be "saved" by using either the vastus lateralis muscle flap or the tensor fascia lata flap. The caudal split gluteus maximus "island" myocutaneous flap is another alternative for isolated ischial and perineal defects. Fortunately, it does not preclude the use of a V-Y gluteus maximus myocutaneous flap for a subsequent sacral defect.

One recent addition to our sacral coverage armamentarium is the combined gluteus maximus myocutaneous and posterior thigh fasciocutaneous flap, which is supplied by the inferior gluteal vessels. The inferior gluteal vessels will reliably supply the majority of the skin of the posterior thigh, and this combined unit can

be rotated as an "island" flap to resurface the sacrum and the ischium at the same time.

DISADVANTAGES

The gluteus maximus muscle is an important muscle in the ambulatory person because it is the primary extender and abductor of the hip. Strong hip "stabilization" is necessary for climbing, rising from a "stooped" position, and standing on one leg. The total loss of this muscle leaves a significant functional deformity which is described as a "gluteus limp." This can be prevented by "splitting" the gluteus maximus muscle and leaving a portion of the muscle undisturbed. If the gluteus maximus myocutaneous flap is used as a rotation flap rather than as a V-Y flap, it may be necessary to skin graft the exposed gluteus medius muscle. This adds some morbidity to the procedure because skin grafts in this area usually increase the healing time. Bilateral V-Y gluteus advancement flaps are preferred for large sacral defects since the donor defects can be primarily closed. The gluteus maximus muscle is seldom used without its overlying skin, because of the disappointing amount of coverage provided by the muscle alone.

ADVANTAGES

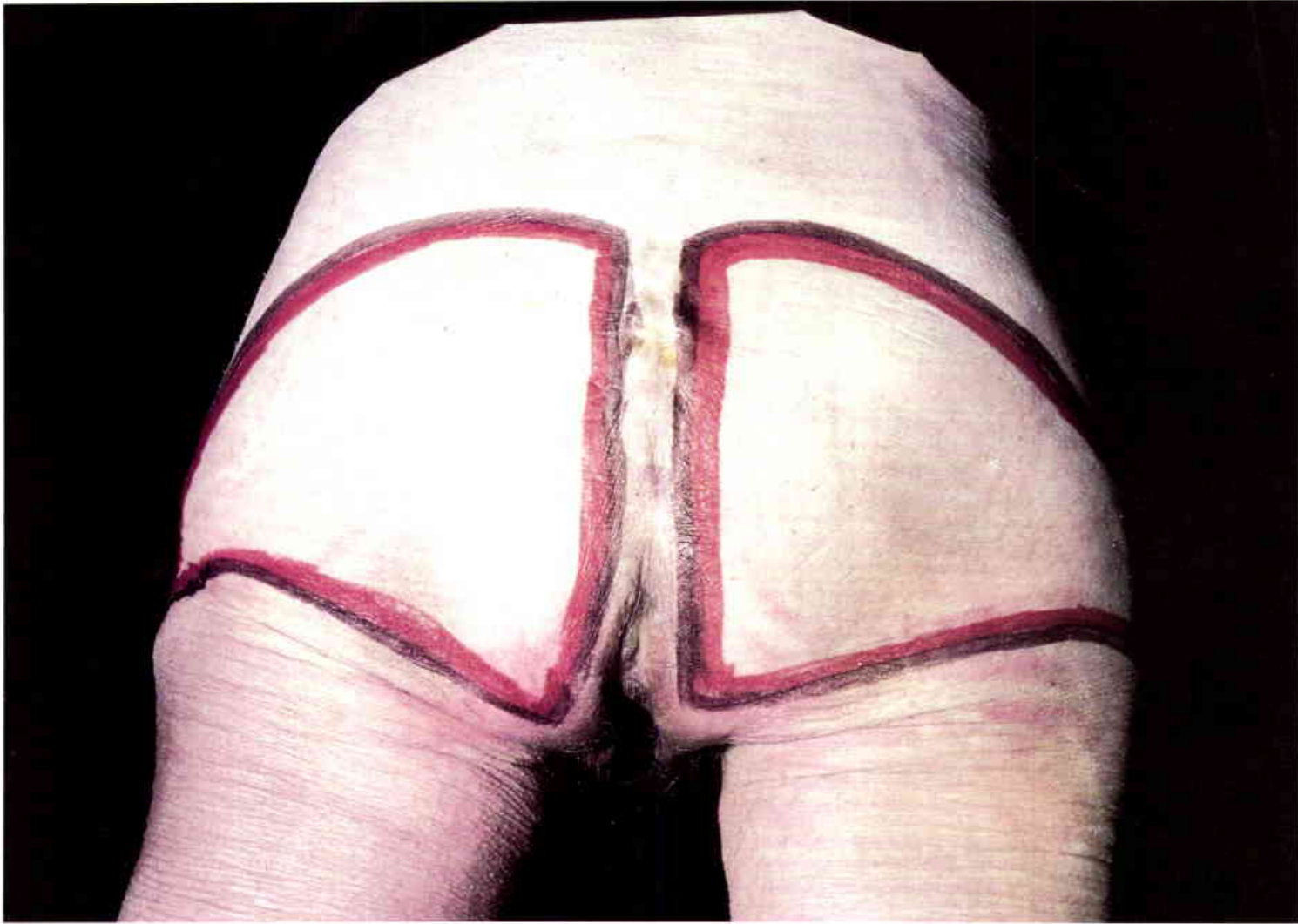
Because of its dual blood supply, the gluteus maximus is an extremely dependable musculocutaneous flap. It can be raised as an "island" flap on either artery or the muscle can be split into two halves as separate "island" flaps. "Splitting" the muscle is useful in the ambulatory individual as this usually circumvents any functional loss. Most large sacral ulcers can be closed with bilateral V-Y myocutaneous flaps without dividing the trochanteric and iliotibial tract insertions since the majority of flap movement is obtained by elevating the muscle away from the sacrum. One added advantage of the V-Y flap is that it can be "re-advanced" to cover a recurrent sacral ulcer.

COMPLICATIONS, PITFALLS, AND DONOR SITE

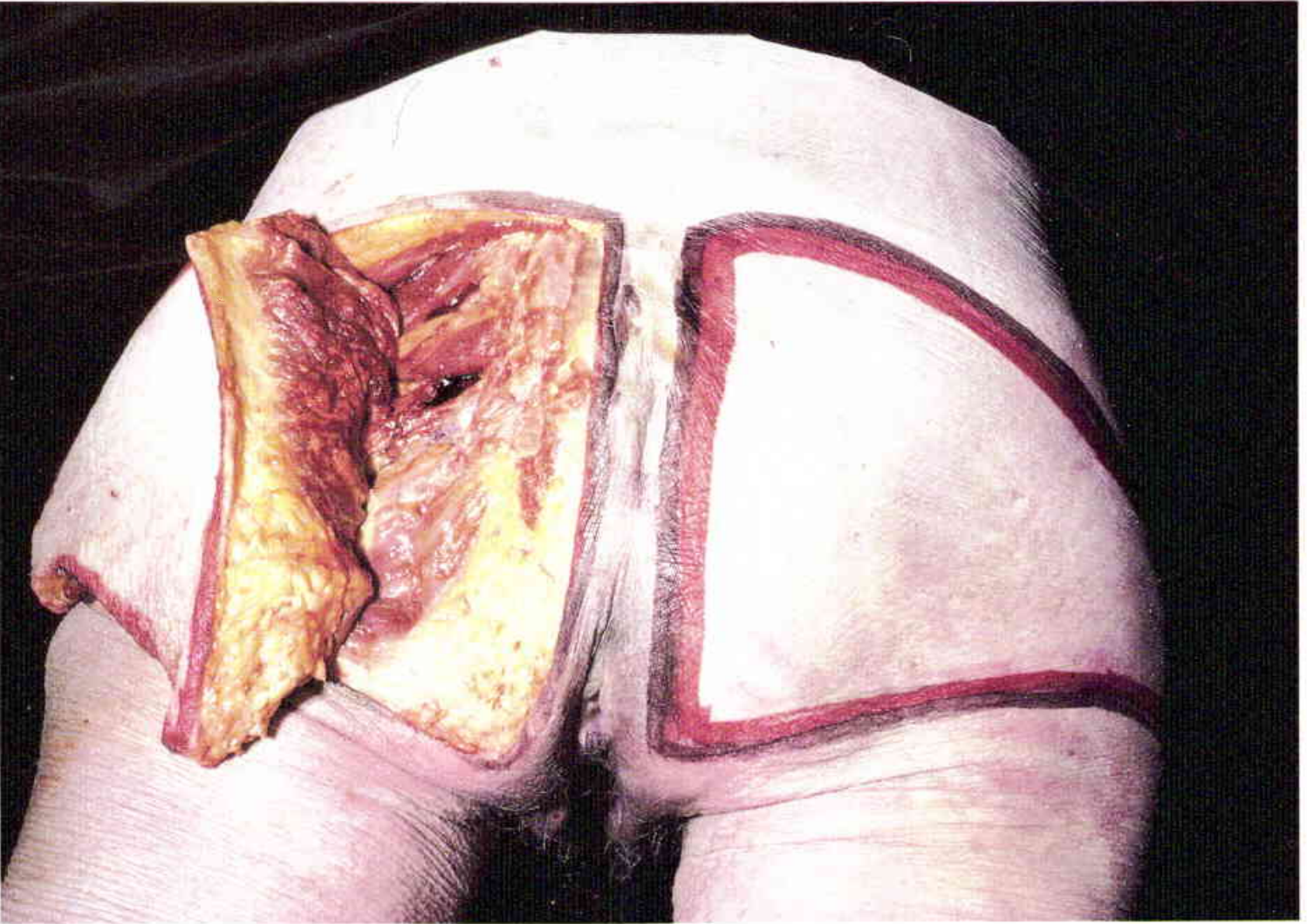
Definition of this muscle in the quadriplegic may be difficult because of muscle atrophy. The plane between the gluteus maximus and gluteus medius muscles is best identified either at the posterior iliac crest or at the sacral margin. Alternatively, the plane between these two muscles can be identified by tracing the sciatic nerve up to the piriformis muscle. Once the plane between the gluteus medius and maximus muscles is established, the gluteal vessels should be located. The larger inferior vessels are identified below the piriformis muscle, and

the smaller superior gluteal vessels are identified approximately three centimeters above the piriformis muscle. The advancement of the V-Y flap is facilitated by separating the gluteus maximus away from the gluteus medius muscle. The most significant medial release comes from the division of the fascial attachments of the gluteus maximus muscle to the sacrum. Further advancement is obtained by dividing the gluteus maximus muscular insertions. It should be unusual to injure the sciatic nerve since it is easily identified and well removed from the usual plane of dissection. This is a real consideration in spastic paraplegics because sciatic motor innervation may be important in "transferring" activities.

The donor site of the primarily closed V-Y flap rarely causes any problem if it is properly closed. The flap must be sufficiently mobilized to provide a tension-free closure, and large sutures must be used. Horizontal mattress #2 nylon retention sutures tied over 4 x 4 bolsters are effective in obliterating the deadspace and preventing wound disruptions. These large sutures are unsightly, but they obviate the need for buried sutures which may potentiate wound infections.

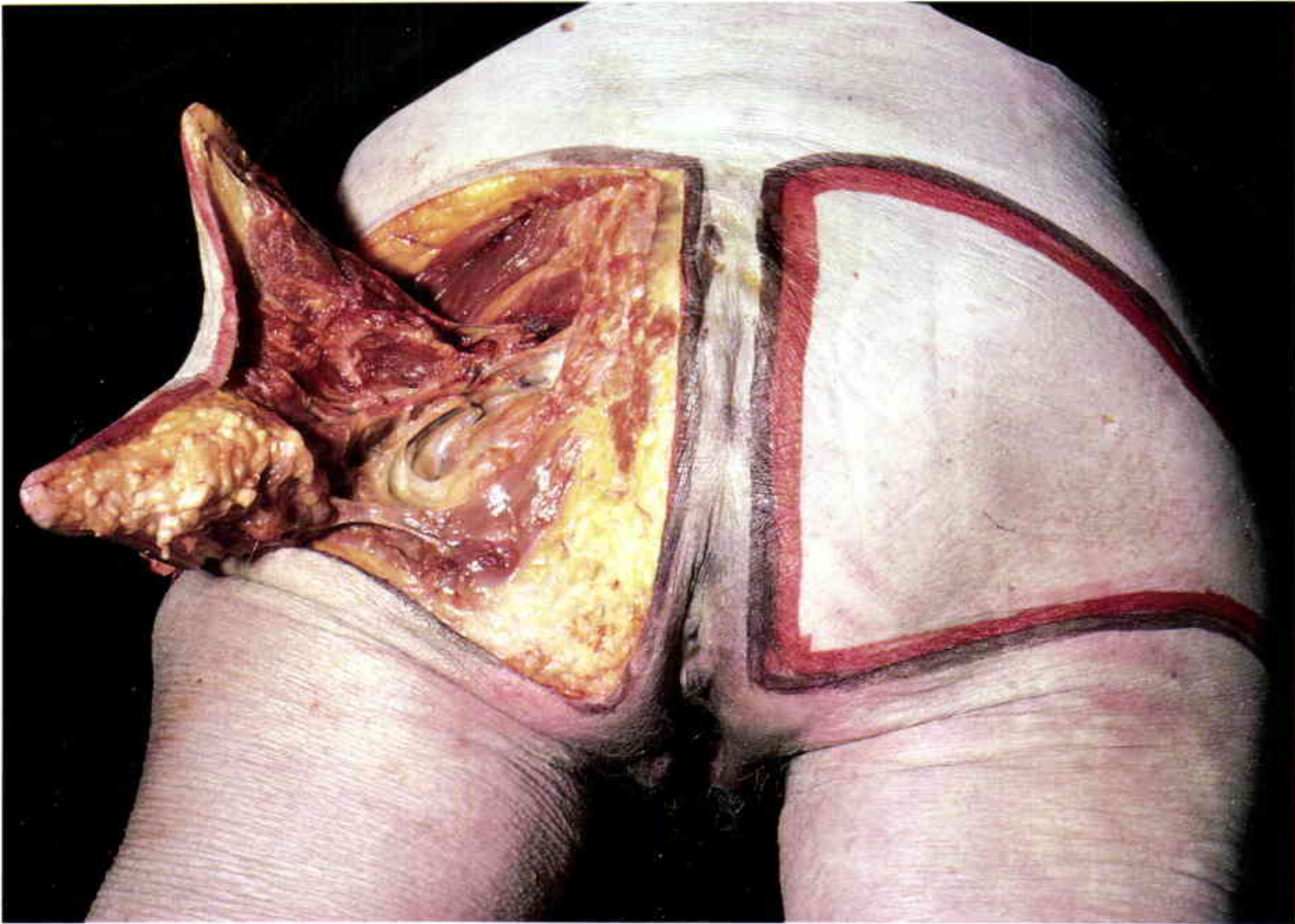


1
Outline of the margins of the gluteus
maximus muscles.



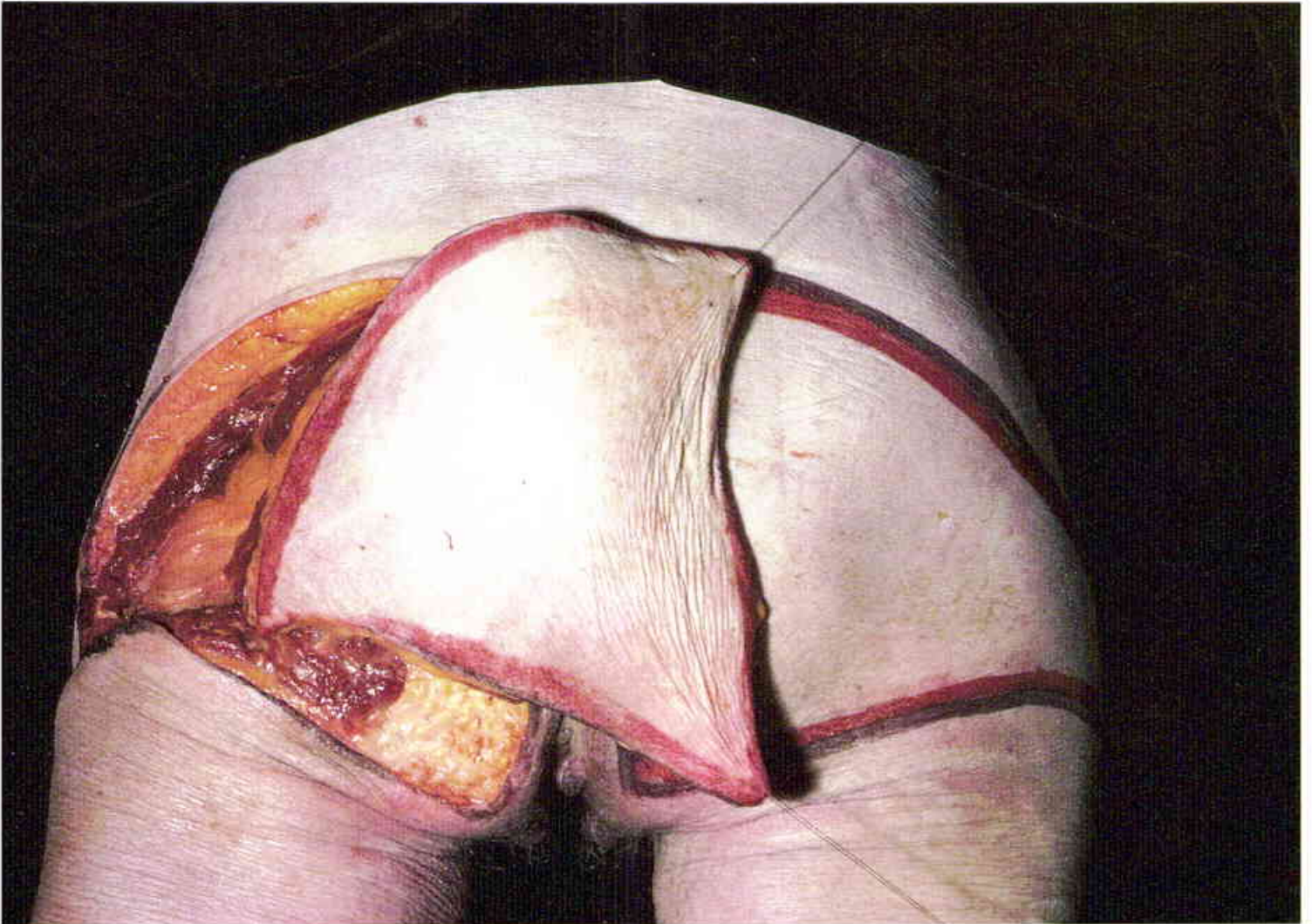
2

The skin incision is completed, and the gluteus maximus muscle is partially elevated away from the gluteus medius muscle. The gluteus maximus muscle has been detached from the sacrum and iliac crest attachments but not from the greater trochanter.



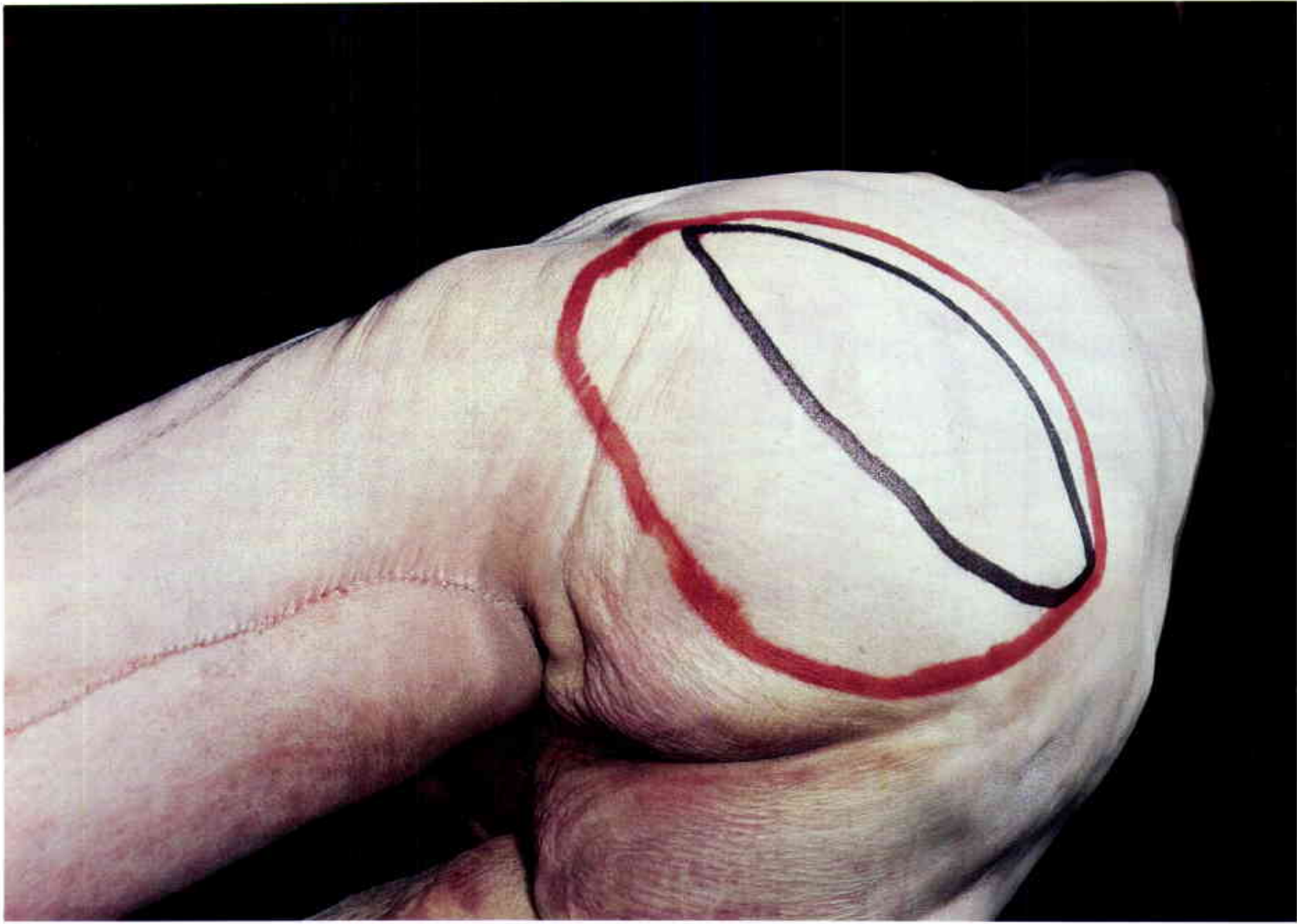3

Completion of the "island" flap elevation, demonstrating the superior and inferior gluteal vessels.



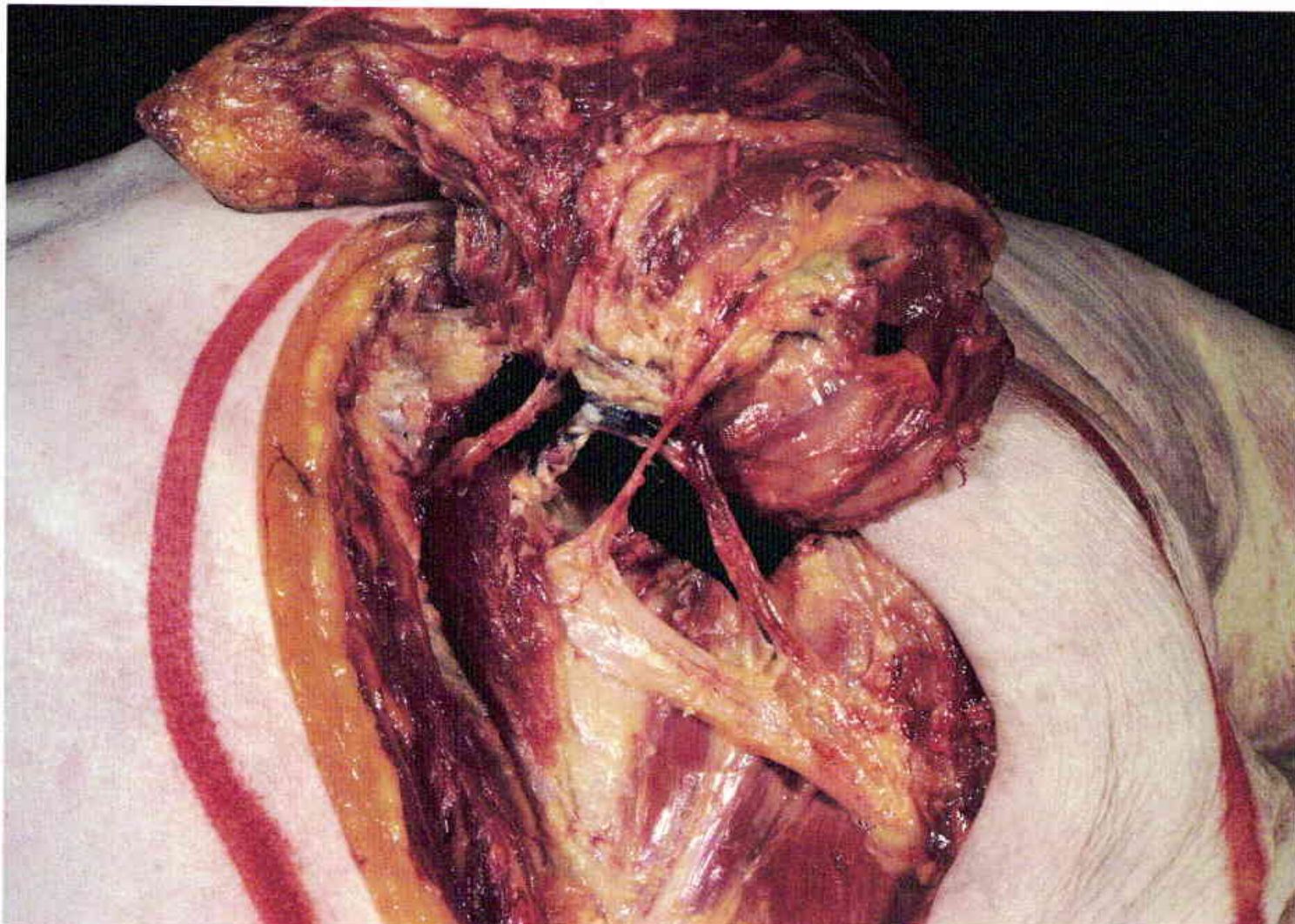
4

Central advancement of the "island" gluteus musculocutaneous flap after the division of the muscular insertion. It is usually not necessary to divide the muscular insertion when bilateral myocutaneous flaps are centrally advanced.



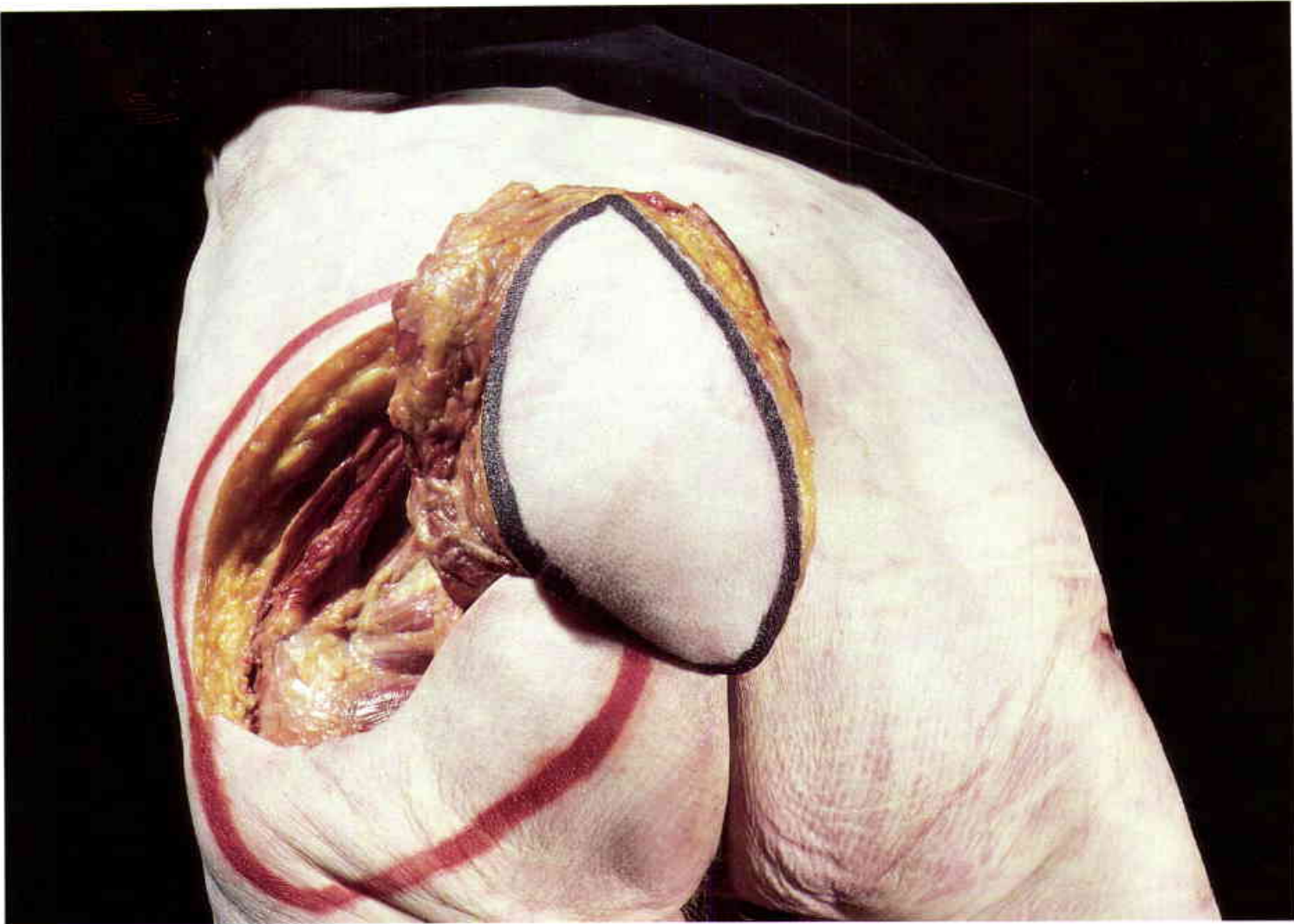
5

Outline of a gluteus maximus "island" flap. The muscle is outlined in red.



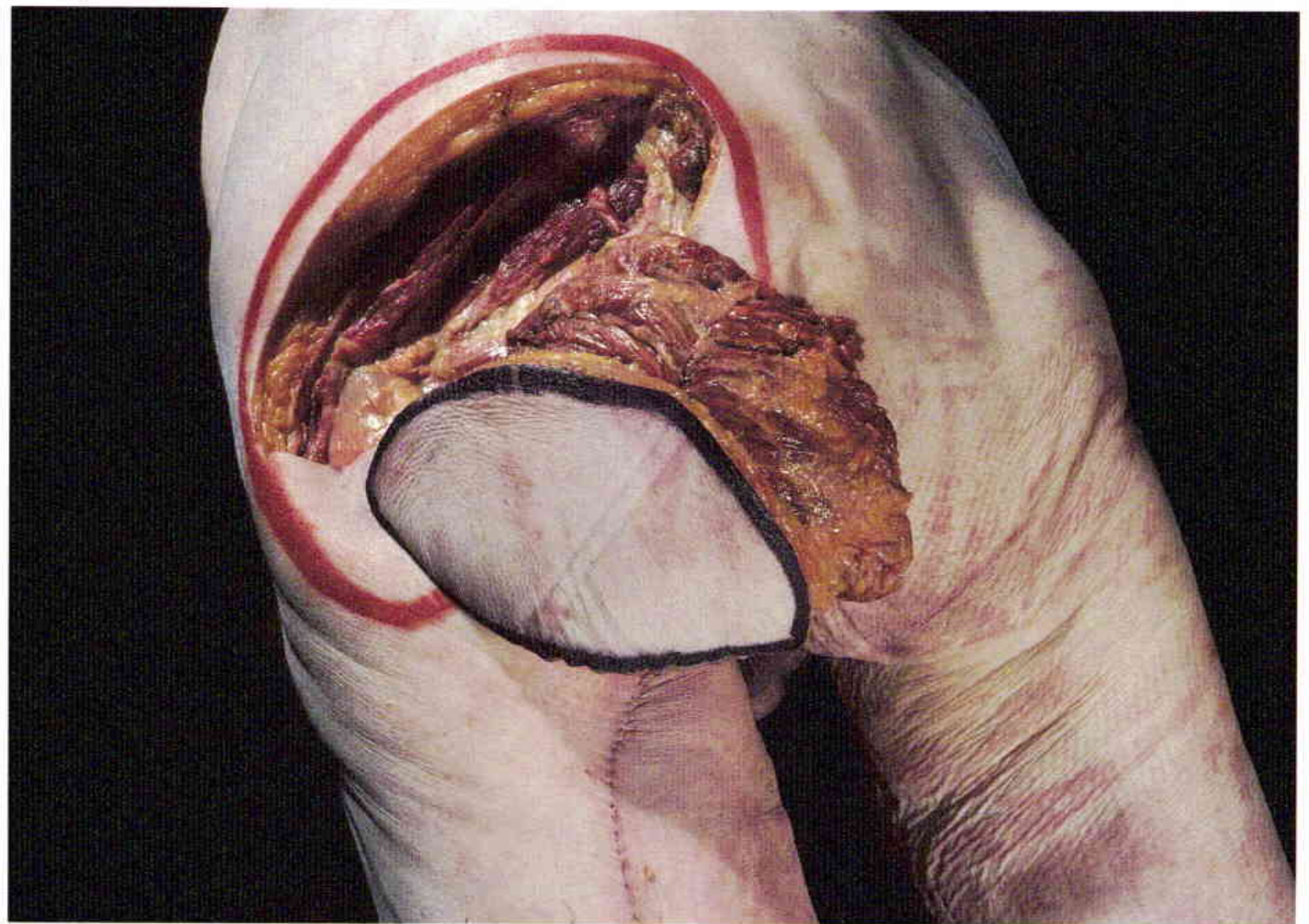
6

The sciatic nerve is seen passing beneath the piriformis muscle. The superior and inferior gluteal vessels are seen on either side of the piriformis muscle.



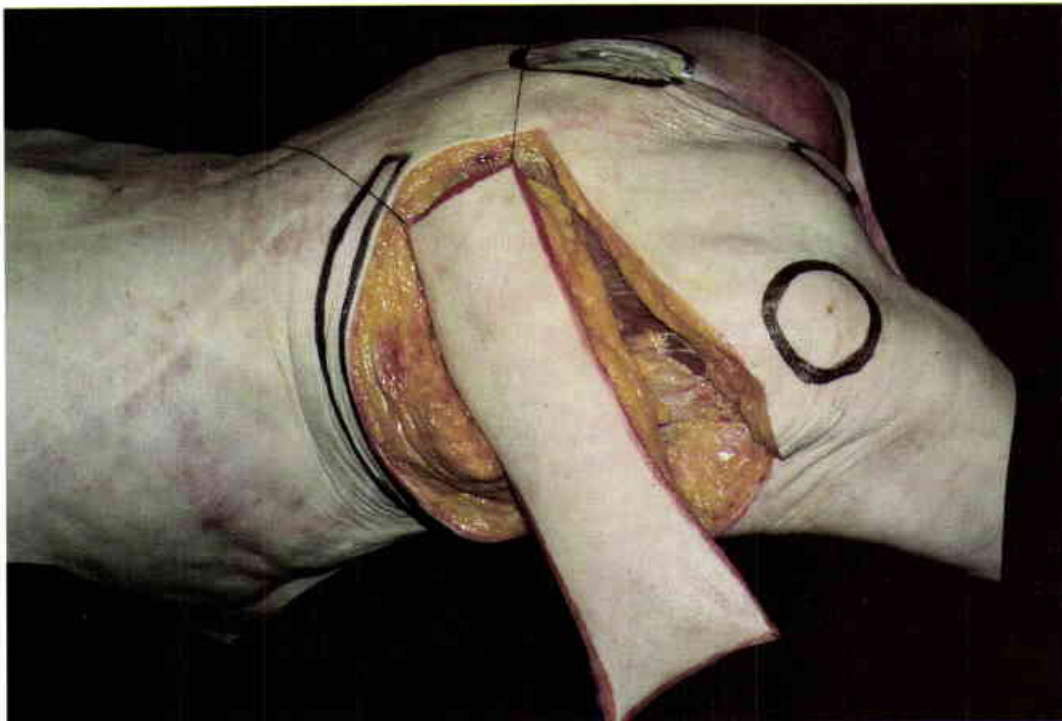
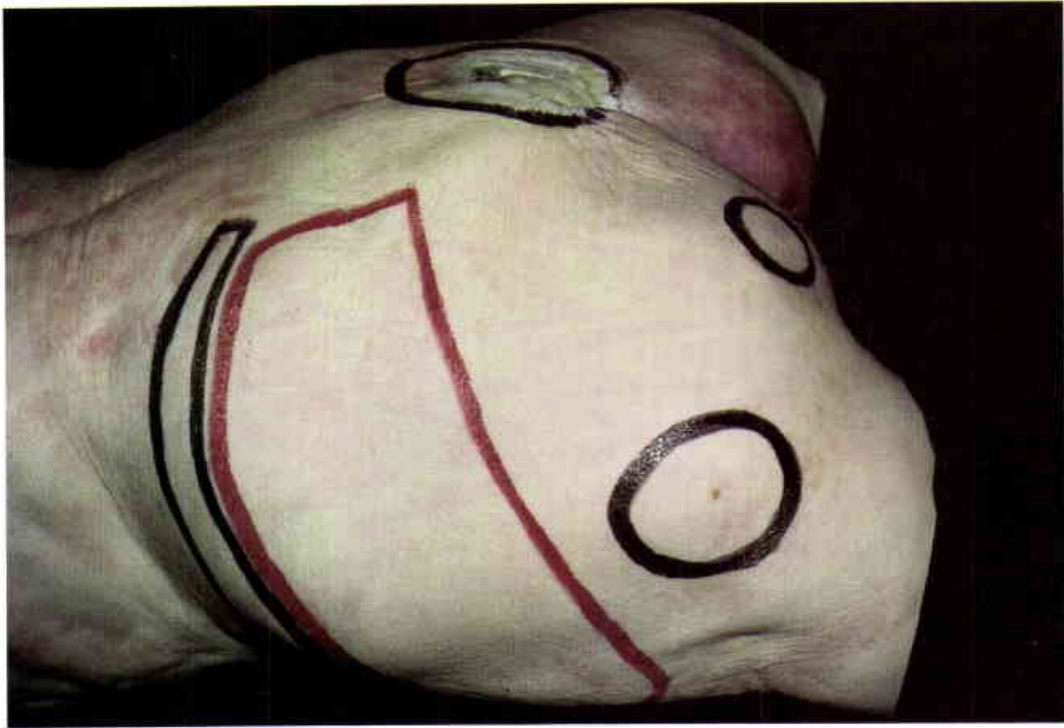7

A single "island" flap can be rotated onto the sacrum. This results in a significant donor site deformity unless the skin can be primarily closed. Bilateral V-Y advancements are generally preferred for major sacral defects.



8

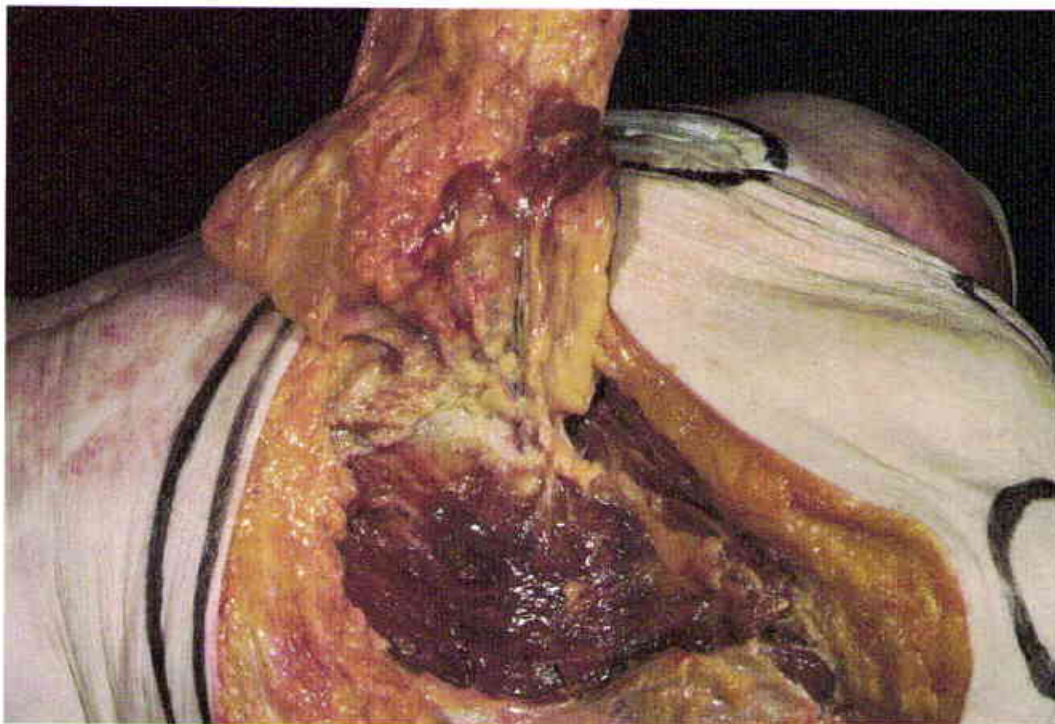
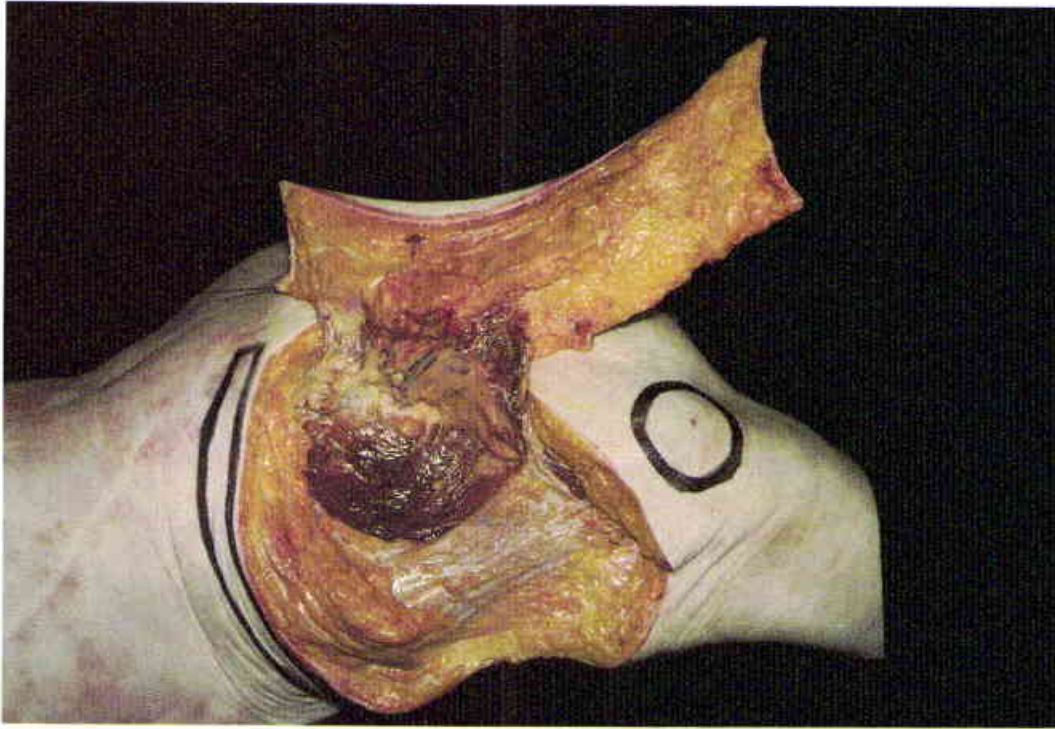
The "island" flap can also be rotated inferiorly to cover the ischium. It is rarely used for this purpose.



9

Outline of the upper gluteus maximus myocutaneous flap. The cutaneous segment (red) overlies the cranial or superior half of the gluteus maximus muscle and extends well beyond the anterior crest. An ulcer of the lower sacrum is outlined

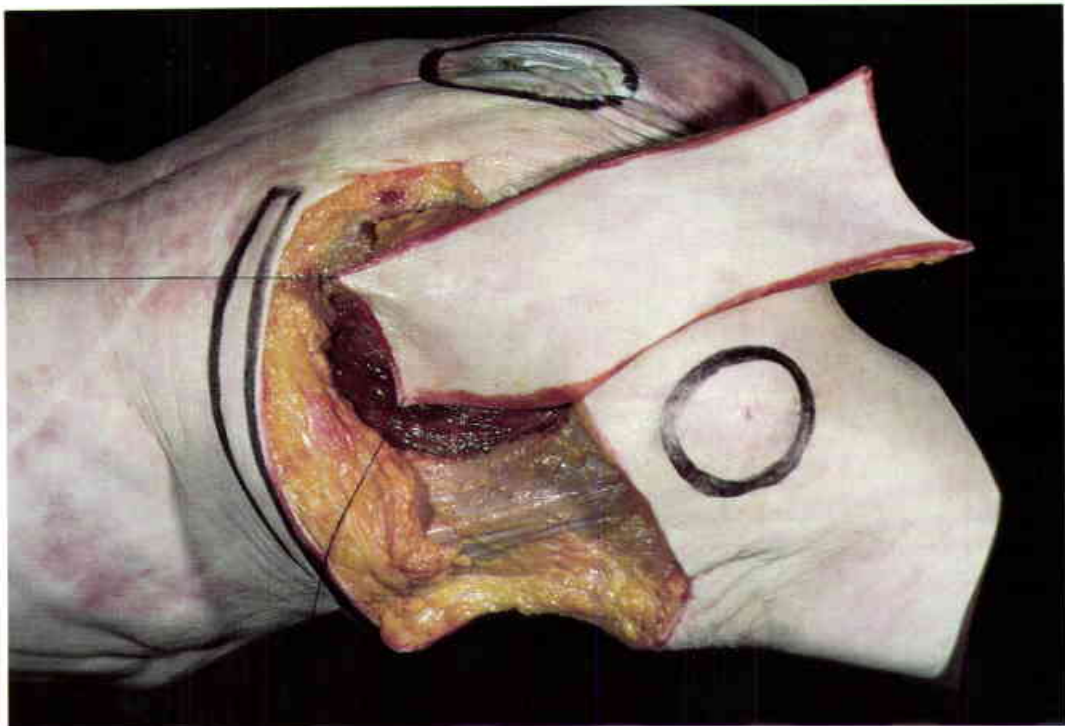
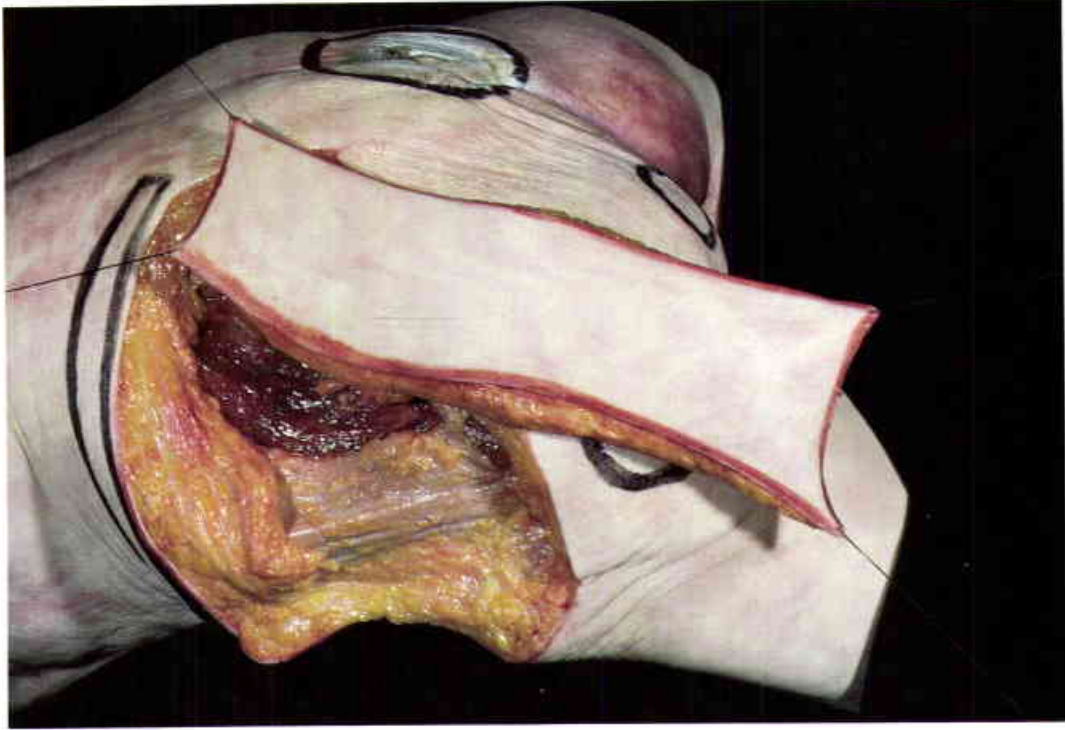
in black along with the locations of the ischial tuberosity and the greater trochanter. Flap elevation is begun by dividing the deep fascia. Note the anterior extent of the flap.



10

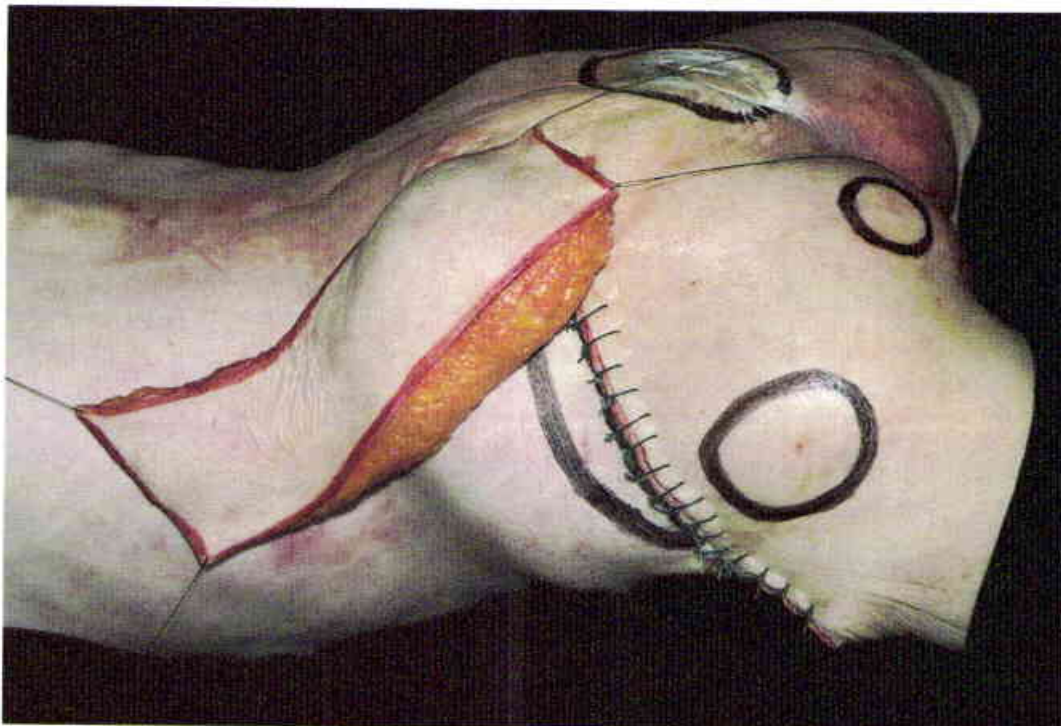
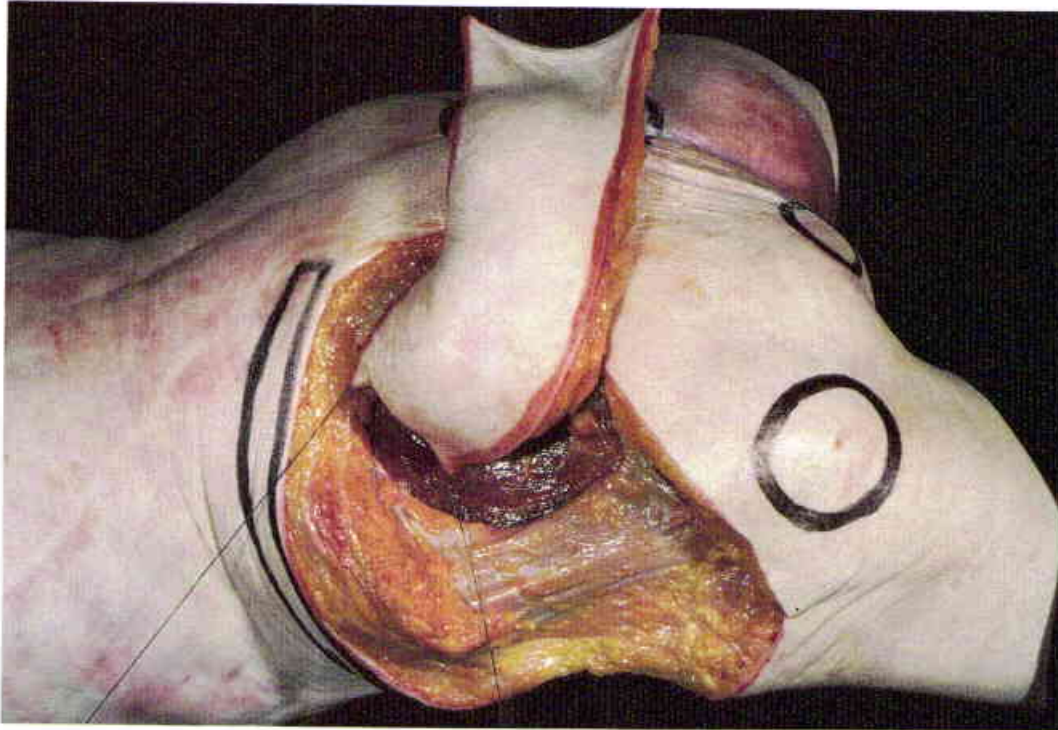
The gluteus maximus muscle is first separated from its origin at the iliotibial tract and elevated away from the vertically oriented gluteus medius muscle. The superior gluteal vessels are seen on the under-

surface of the cranial half of the gluteus maximus muscle, which has been "split" from the caudal half of the muscle. The "island" flap is completed by dividing the fascial attachments to the sacrum.



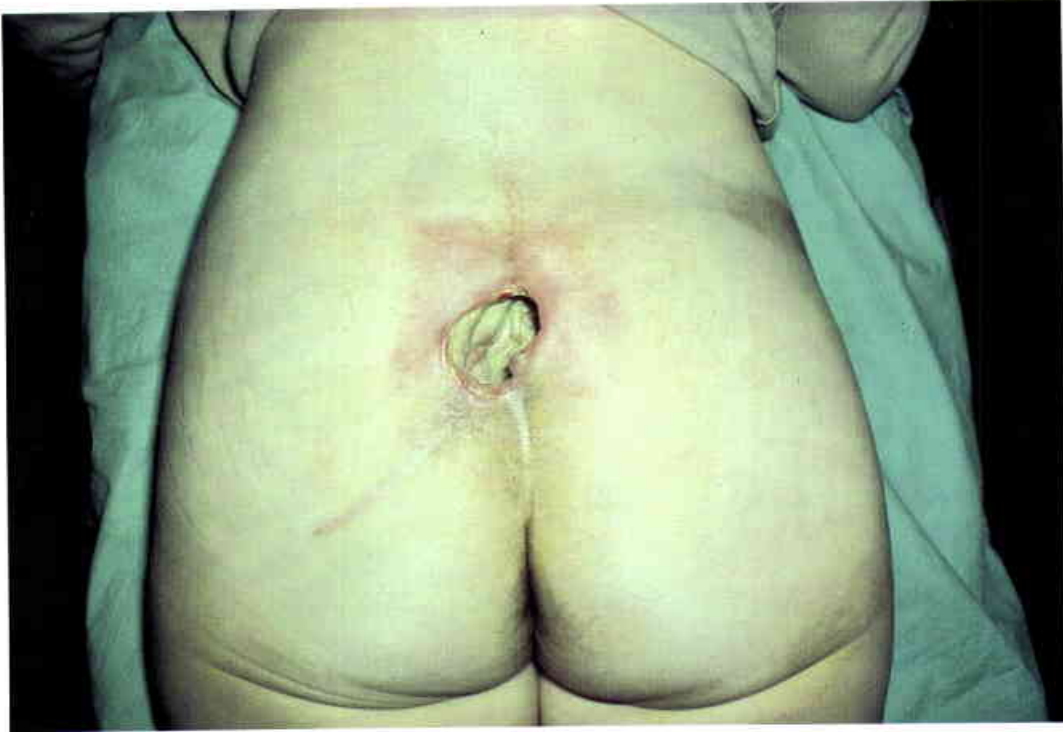11

The flap is transposed inferiorly to cover the greater trochanter and the ischial tuberosity.



12

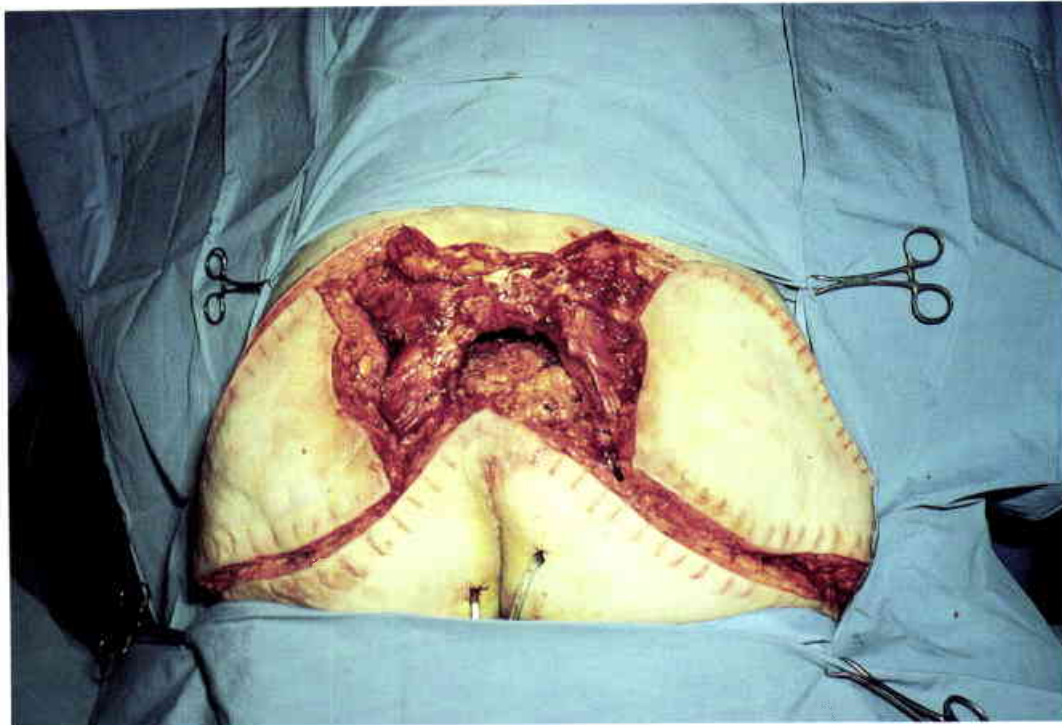
Rotation of the upper gluteus maximus myocutaneous flap onto the sacrum and the lower chest wall. The vertically oriented flap will also cover the lumbar area. The donor site is closed primarily.



13

Fifty-four-year-old female with a recurrent chondrosarcoma following three major excisions and extensive irradiation to the sacral area. Note the scar on the left

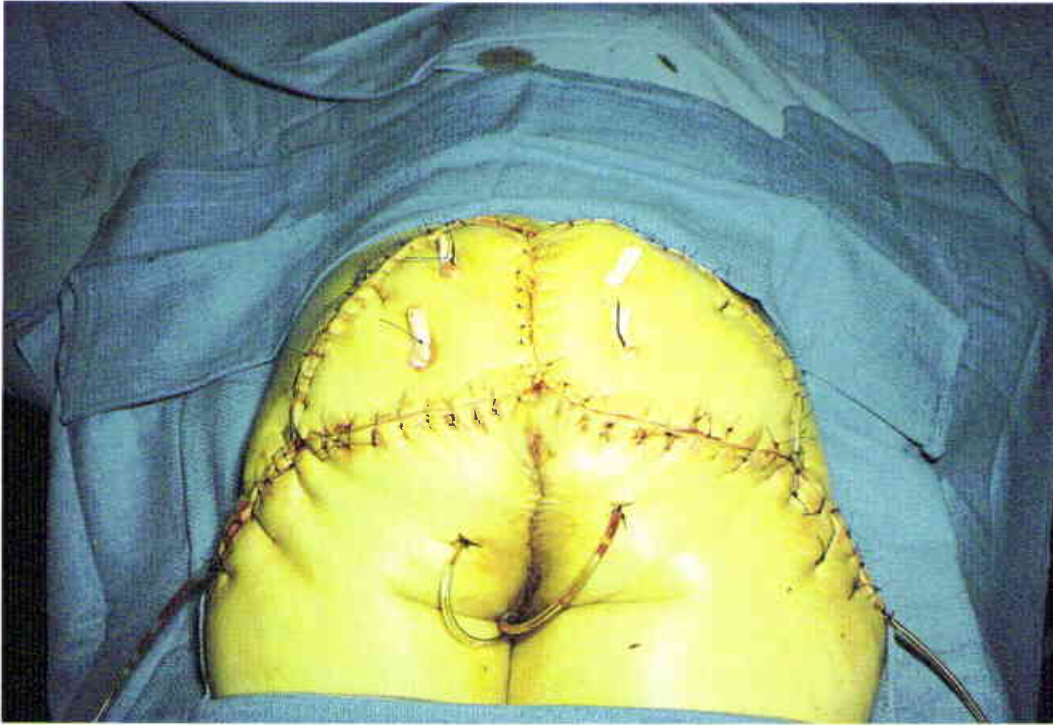buttock which will be included in the gluteus maximus myocutaneous flap. (Case of P.G. Arnold)



14

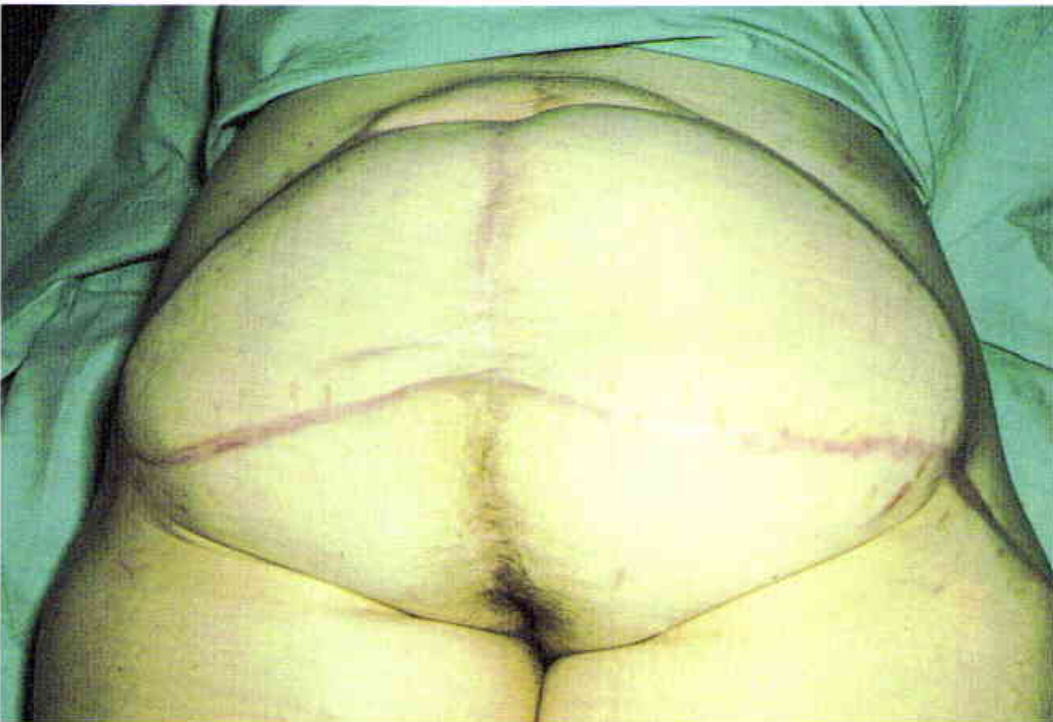Bilateral gluteus maximus flaps were incised at the time of an abdominoperineal resection three days earlier. In this second operation the recurrent sarcoma of the sacrum was widely excised and repaired

with V-Y gluteus maximus advancement myocutaneous flaps. The cutaneous "delay" was unnecessary, but it was still a reasonable "test" of the flaps in this precarious situation.



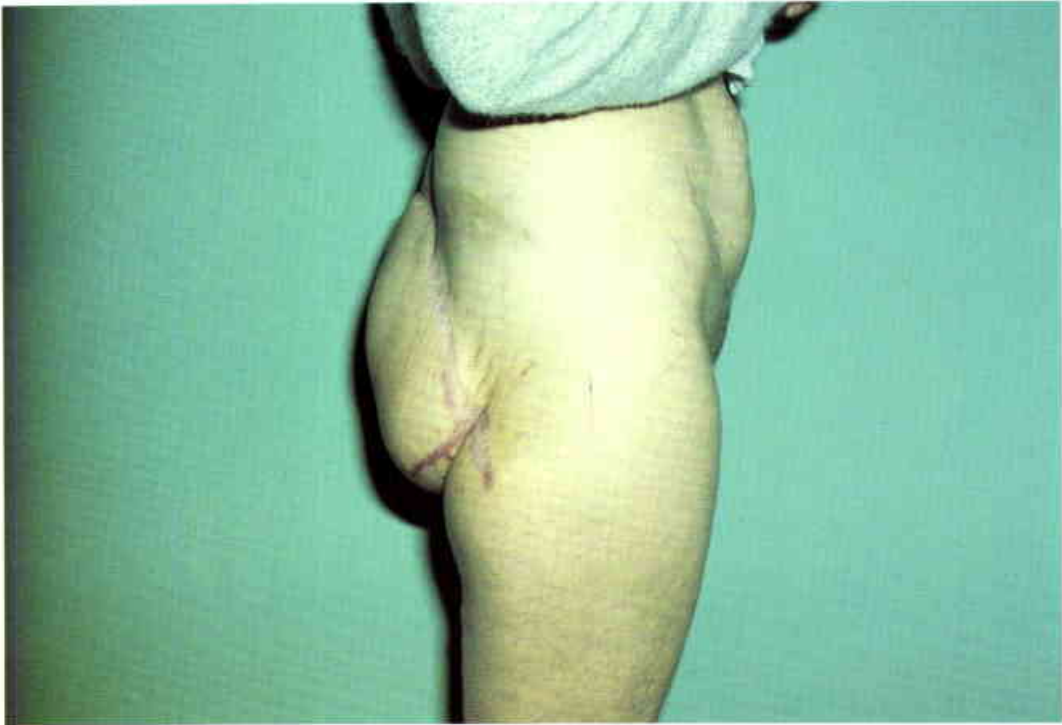15

The gluteus maximus flaps were advanced to the midline. Fluorescein examination predicted complete flap viability. Large surface sutures were used to avoid using deep absorbable sutures.



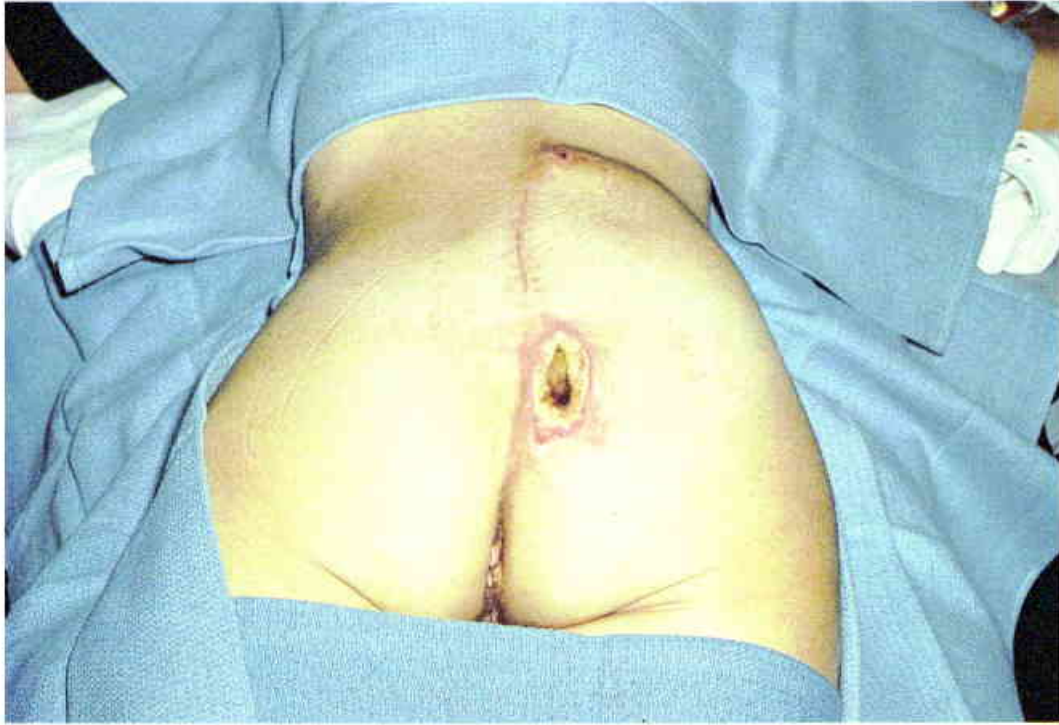
16

Healed V-Y flaps at six months.



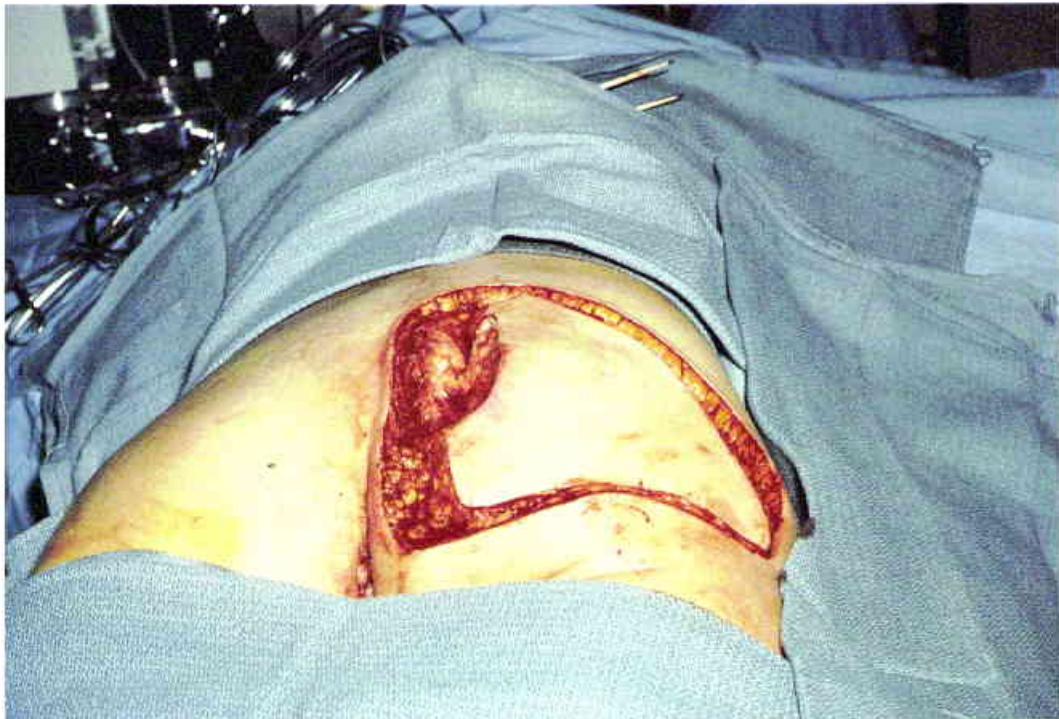17

Lateral view at eight months. The patient is still able to ambulate, swim, and play golf without difficulty. The closure remains stable at six years.



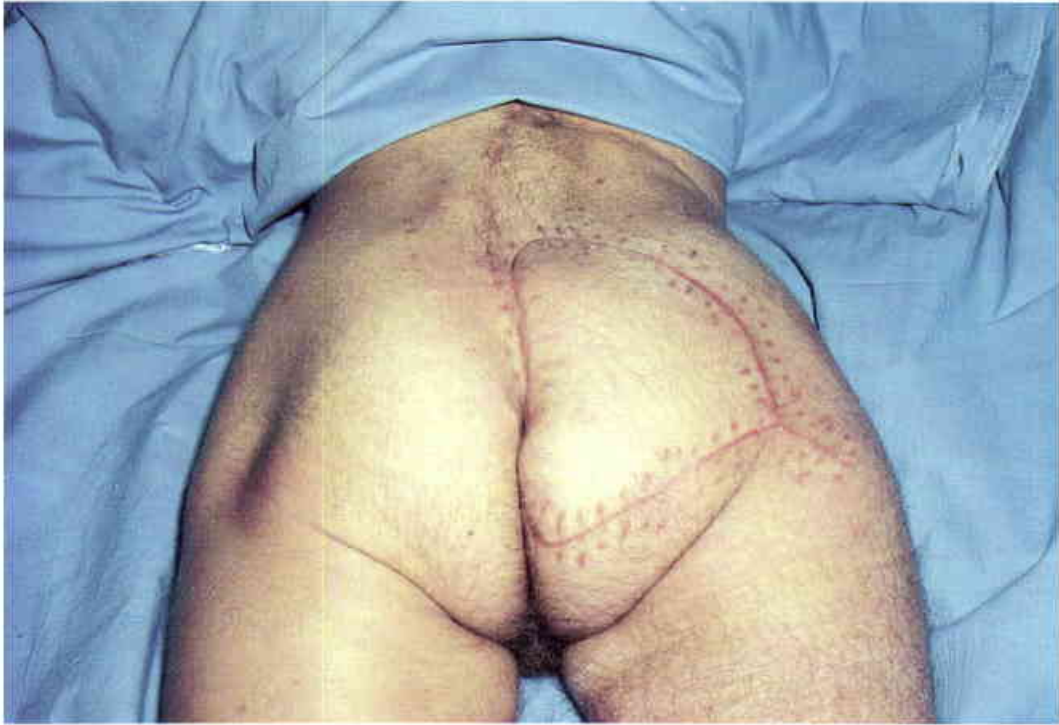18

Thirty-eight-year-old female with a pressure sore following an extensive resection of an osteogenic sarcoma of the lumbosacral area. (Case of P.G. Arnold)



19

The pressure sore was excised, and a single gluteus maximus myocutaneous flap was prepared for V-Y transposition and primary closure. Note that the V-Y flap is significantly wider than the area of excision to incorporate both vessels and to ensure the flap's viability.



20

Healed V-Y gluteus maximus transposition at four months. The wound has remained healed for five years.

GLUTEUS MAXIMUS

- Baek, S.M., Williams, G.D., McElhinney, A.J., and Simon, B.E. "The gluteus maximum myocutaneous flap in the management of pressure sores." *Ann. Plast. Surg.* 5(6): 471, 1980.
- Baker, D.C., Barton, F.E., and Converse, J.M. "A combined biceps and semitendinosus muscle flap in repair of ischial sores." *Br. J. Plast. Surg.* 31: 26, 1978.
- Becker, H. "The distally-based gluteus maximus muscle flap." *Plast. Reconstr. Surg.* 63(5): 653, 1979.
- Block, I.R. "Levator ani as substitute puborectalis sling." *Surg. Gynecol. Obstet.* 141: 611, 1975.
- Brandesky, G. and Holschneider, A.M. "Operations for the improvement of faecal incontinence." *Prog. Pediatr. Surg.* 9: 105, 1976.
- Bruining, H.A., Box, K.E., Colthoff, E.G., and Tolhurst, D.E. "Creation of an anal sphincter mechanism by bilateral proximally based gluteal muscle transposition." *Plast. Reconstr. Surg.* 67(1): 70, 1981.
- Chantraine, A., Lloyd, K. and Swinyard, C. "The sphincter ani externus in spina bifida and myelomeningocele." *J. Urol.* 95: 250, 1966.
- Chittenden, A.S. "Reconstruction of anal sphincter by muscle slips from glutei." *Ann. Surg.* 92: 152, 1930.
- Daniel, R.K., Terzis, J.K., and Cunningham, D.M. "Sensory skin flaps for coverage of pressure sores in paraplegic patients." *Plast. Reconstr. Surg.* 58: 317, 1976.
- Daniel, R.K., Kerrigan, C.L., and Gard, D.A. "The great potential of the intercostal flap for torso reconstruction." *Plast. Reconstr. Surg.* 61: 653, 1978.
- Davis, W.M., McCraw, J.B., and Carraway, J.H. "Use of a direct transverse thoracoabdominal flap to close difficult wounds of the thorax and upper extremity." *Plast. Reconstr. Surg.* 60(4): 526, 1977.
- Dibbell, D.G. "Use of a large island flap to bring sensation to the sacral area in young paraplegics." *Plast. Reconstr. Surg.* 54: 221, 1974.
- Dibbell, D.G., McCraw, J.B., and Edstrom, L.E. "Providing useful and protective sensibility in patients with meningocele." *Plast. Reconstr. Surg.* 64: 796, 1979.
- Erk, Y., Spira, M., Parsa, F.D., and Stal, S. "A modified gluteus maximus musculocutaneous free flap based on the inferior gluteal vessels." *Ann. Plast. Surg.* 11(4): 344, 1983.
- Fisher, J., Arnold, P.G., Waldorf, J., and Woods, J.E. "The gluteus maximus musculocutaneous V-Y advancement flap for large sacral defects." *Ann. Plast. Surg.* 11(6): 517, 1983.
- Ger, R. "The surgical management of decubitus ulcers by muscle transposition." *Surgery* 69: 106, 1971.
- Ger, R. and Levine, S.A. "The management of decubitus ulcers by muscle transposition: an 8 year review." *Plast. Reconstr. Surg.* 58: 419, 1976.
- Hang, Y.S. "Contracture of the hip secondary to fibrosis of the gluteus maximus muscle." *J. Bone Joint Surg. (Am).* 61(1): 52, 1979.
- Hentz, V.R. "Construction of a rectal sphincter using the origin of the gluteus maximum muscle." *Plast. Reconstr. Surg.* 70(1): 82, 1982.
- Hill, H.L., Brown, R.G., and Jurkiewicz, M.J. "The transverse lumbosacral back flap." *Plast. Reconstr. Surg.* 63: 177, 1978.
- Hurwitz, D.J. "Closure of a large defect of the pelvic cavity by an extended compound flap based on the inferior gluteal artery." *Br. J. Plast. Surg.* 33: 256, 1980.
- Hurwitz, D.J., Swartz, W.M., and Mathes, S.J. "The gluteal thigh flap: A reliable, sensate flap for the closure of buttock and perineal wounds." *Plast. Reconstr. Surg.* 68: 521, 1981.
- Jacob, E.T., Shapira, Z., Bar-Natan, N., and Berant, M. "Total anorectal reconstruction following congenital anorectal anomaly: report of a case." *Dis. Colon Rectum.* 19(2): 172, 1976.
- Janecki, C.J. "The gluteus maximus femoral insertion: a guide in surgery about the hip." *Clin. Orthop.* 123: 16, 1977.
- Joseph, J. and Williams, P.L. "Electromyography of certain hip muscles." *J. Anat.* 91: 286, 1957.
- Labandter, H.P. "The gracilis muscle flap and musculocutaneous flap in the repair of perineal and ischial defects." *Br. J. Plast. Surg.* 33: 95, 1980.
- Little, J.W., III, and Lyons, J.R. "The gluteus medius-tensor fasciae latae flap." *Plast. Reconstr. Surg.* 71(3): 366, 1983.
- Maruyama, Y., Nakajima, H., Wada, M., Imai, T., and Fujino, T. "A gluteus maximus myocutaneous island flap for the repair of a sacral decubitus ulcer." *Br. J. Plast. Surg.* 33: 150, 1980.
- Maruyama, Y. and Tajima, S. "Gluteus maximus muscle island flaps for repair of sacral radiation ulcers." *Keio. J. Med.* 27(2): 53, 1978.
- Mathes, S.J., Vasconez, L.O., and Jurkiewicz, M.J. "Extensions and further applications of muscle flap transposition." *Plast. Reconstr. Surg.* 60: 6, 1977.
- McCraw, J.B., Dibbell, D.G. and Carraway, J.H. "Clinical definition of independent myocutaneous vascular territories." *Plast. Reconstr. Surg.* 60: 341, 1977.
- Minami, R.T., Mills, R., and Pardoe, R. "Gluteus maximus myocutaneous flaps for repair of pressure sores." *Plast. Reconstr. Surg.* 60(2): 242, 1977.
- Mustarde, J.C. "Reconstruction of the spinal canal in severe spina bifida." *Plast. Reconstr. Surg.* 42: 109, 1968.
- Nahai, F. "The tensor fascia lata flap." *Clin. Plast. Surg.* 7: 51, 1980.
- Nahai, F., Hill, L., and Hester, T.R. "Experiences with the tensor fascia lata flap." *Plast. Reconstr. Surg.* 63: 788, 1979.
- Napier, J. "The antiquity of human walking." *Sci. Am.* 216: 56, 1967.
- Orgel, M.G. and Kucan, J.D. "A double-split gluteus maximus muscle flap for reconstruction of the rectal sphincter." *Plast. Reconstr. Surg.* 75(1): 62, 1985.

GLUTEUS MAXIMUS

- Parkash, S. and Banerjee, S. "The total gluteus maximus rotation and other gluteus maximus musculocutaneous flaps in the treatment of pressure ulcers." *Br. J. Plast. Surg.* 39: 66, 1986.
- Parry, S.W. and Mathes, S.J. "Bilateral gluteus maximus myocutaneous advancement flaps: sacral coverage for ambulatory patients." *Ann. Plast. Surg.* 8(6): 443, 1982.
- Perez-Gurri, J.A., Temple, W.J., and Ketcham, A.S. "Gluteus maximus myocutaneous flap for the treatment of recalcitrant pilonidal disease." *Dis. Colon Rectum*, 27(4): 262, 1984.
- Prochiantz, A. and Gross, P. "Gluteal myoplasty for sphincter replacement: principles, results and prospects." *J. Pediatr. Surg.* 17(1): 25, 1982.
- Ramirez, O.M., Hurwitz, D.J., and Futrell, J.W. "The expansive gluteus maximus flap." *Plast. Reconstr. Surg.* 74(6): 757, 1984.
- Ramirez, O.M., Orlando, J.C., and Hurwitz, D.J. "The sliding gluteus maximus myocutaneous flap: its relevance in ambulatory patients." *Plast. Reconstr. Surg.* 74(1): 68, 1984.
- Rees, R.S., Reilley, A.F., Nanney, L.B., and Lynch, J.B. "Sacral pressure sores: treatment with island gluteus maximus musculocutaneous flaps." *South Med. J.* 78(10): 1147, 1985.
- Salibian, A.H., Anzel, S.H., and Rogers, F.R. "The gluteus medius-tensor fasciae latae myocutaneous flap for infected gridstone procedures: Report of two cases." *J. Bone Joint Surg.* 66(9): 1466, 1984.
- Scheflan, M., Nahai, F., and Bostwick, J., III. "Gluteus maximus island musculocutaneous flap for closure of sacral and ischial ulcers." *Plast. Reconstr. Surg.* 68(4): 533, 1981.
- Senior, H.D. "The development of the arteries of the human lower extremity." *Am. J. Anat.* 25: 55, 1919.
- Shaw, A. and Futrell, J.W. "Cure of chronic perineal sinus with gluteus maximus flap." *Surg. Gynecol. Obstet.* 147(3): 417, 1978.
- Shaw, W.W. "Breast reconstruction by superior gluteal microvascular free flaps without silicone implants." *Plast. Reconstr. Surg.* 72(4): 490, 1983.
- Simonsen, O.S., Stolf, N.A., Aun, F., Raia, A., and Habrgama, A. "Rectal sphincter reconstruction in perineal colostomies after abdominoperineal resection for cancer." *Br. J. Surg.* 63(5): 389, 1976.
- Skef, Z., Radhakrishnan, J., and Reyes, H.M. "Anorectal continence following sphincter reconstruction utilizing the gluteus maximus muscle: a case report." *J. Pediatr. Surg.* 19(6): 779, 1983.
- Stallings, J.O., Delgado, J.P., and Converse, J.M. "Turn-over island flap of gluteus maximus muscle for the repair of sacral decubitus ulcer." *Plast. Reconstr. Surg.* 54(1): 52, 1974.
- Stern, J.T., Jr. "Anatomical and functional specializations of the human gluteus maximus." *Am. J. Phys. Anthropol.* 36(3): 315, 1972.
- Twisk, R. van and Borghouds, J.M.H.M. "The gluteus maximus musculocutaneous flap as bilateral V-Y sliding flap or as pendulum flap for closure of sacral and ischial pressure sores." *Acta. Chir. Plast.* 8: 215, 1986.
- Uszynski, H., Jethon, J., and Towpik, E. "Muscle and myocutaneous flaps in the treatment of pressure sores in paraplegics." *Acta. Chir. Plast.* 27(3): 185, 1985.
- Vasconez, L.O., Schneider, W.J., and Jurkiewicz, M.J. "Pressure sores." *Curr. Probl. Surg.* 14: 1, 1977.
- Wheatley, M.D. and Jahnke, W.D. "Electromyographic study of the superficial thigh and hip muscles in normal individuals." *Arch. Phys. Med.* 32: 508, 1951.
- Wingate, G.B. and Friedland, J.A. "Repair of ischial pressure ulcers with gracilis musculocutaneous island flaps." *Plast. Reconstr. Surg.* 62: 245, 1978.