

McCraw and Arnold's Atlas of Muscle and Musculocutaneous Flaps



John B. McCraw
Phillip G. Arnold



Global-HELP
Publication

SMALL MUSCLES OF THE FOOT

ABDUCTOR HALLUCIS AND FLEXOR DIGITORUM BREVIS

ANATOMICAL CONSIDERATIONS

Surface Markings

The abductor hallucis muscle is located on the medial aspect of the foot and parallels the first metatarsal bone. It is easily palpated and consistent in its location. The flexor digitorum brevis (short flexor) muscle fans out from the midportion of the os calcis and parallels the long flexor tendons in its course to the toes.

Origin and Insertion

The abductor hallucis muscle originates from the medial aspect of the calcaneus and is adherent to the first metatarsal bone throughout its length. The muscle inserts into the medial condyle of the proximal phalanx of the great toe. The short flexors originate from the medial process of the calcaneus as well as from the plantar fascia. These small muscles individually insert into the middle phalanges of the second through fifth toes. Both the abductor hallucis and the short flexor muscles are completely expendable from a functional standpoint.

Adjacent Muscles

Although the abductor digiti quinti muscle may be large enough to use as a muscle flap, the adequacy of its volume must be confirmed by exploration. It can be used to cover a small lateral heel defect, if it is converted into a pure "island" flap, but it certainly does not reach the dorsum of the foot nor the lateral malleolus as has been diagrammatically suggested by others. An "island" extensor digitorum brevis muscle flap usually can be transposed from the dorsum of the foot to the lateral malleolus, but the length of the vascular leash is variable.

Vascular Pattern

As expected from their anatomical locations, the abductor hallucis muscle is supplied only by the medial plantar vessels, while the flexor digitorum brevis muscle is supplied by both the medial and lateral plantar vessels. The abductor hallucis muscle has a secondary vascular leash which penetrates the midportion of its muscular

belly, but this can be sacrificed without fear of harm to its viability.

Motor Nerve

Medial plantar nerve.

Sensory Nerve

Medial plantar nerve.

USES

The abductor hallucis and the flexor digitorum brevis muscles are the two muscles which are consistently available for the transposition in the foot. These two muscles have limited arcs of rotation and can only be used to close small wounds, but they are quite helpful in certain situations. They have the added benefit of maintaining some pressure sensibility which is important in the ambulatory patient. They can also be used to augment the viability of local flaps of sole skin. For the most part the flexor digitorum brevis muscle flap is used for heel coverage and the abductor hallucis muscle flap is used for defects which lie between the medial malleolus and the heel. Neither muscle will consistently reach the Achilles area nor the flair of the medial malleolus.

REGIONAL FLAP COMPARISONS

These muscle flaps are best compared to the dorsalis pedis axial flap and the vascularized sole flap, which may or may not include the short flexor muscles. These cutaneous flaps offer the distinct advantage of providing surface sensibility but their donor sites usually require a skin graft. The dorsalis pedis flap provides the most predictable coverage for the medial and lateral malleoli which are beyond the reach of the small muscles of the foot. The dorsalis pedis flap is similarly useful for innervated heel coverage when the arterialized sole flap is unavailable. Unlike any other local foot flap, the "island" dorsalis pedis flap

can reach the Achilles tendon area. In children up to the age of ten, an ipsilateral buttock flap can be used because the knee joint in young children can be immobilized for two to three weeks and then rapidly remobilized. The donor site of this flap is good, but the gymnastics of the flap manipulations are not well tolerated by even young patients.

Although "free" microvascular transfers should always be considered as an option for these difficult foot defects, there are several unsolved problems. Flap viability is only 85% to 95% in good hands, usually because of the unsatisfactory nature of the recipient vessels. "Free" sensory innervated skin flaps have also been disappointing in the quality of their sensibility, which has generally not been good enough to protect the flap from late ambulatory loss. "Free" muscle transfers seem to be more durable than "free" skin transfers, even though they are less sensate. The conventional explanation for this is that the "shear" effect, which is normally prevented by the fibrous septa of heel skin, is more damaging to transferred subcutaneous fat than it is to transferred muscle. The "free" muscle transfer does become densely adherent to the os calcis, and perhaps this helps cushion any damaging "shear." There is little doubt that "free" transfers will become routine procedures in the future, but their anticipated advantages over local flaps have not yet been realized.

DISADVANTAGES

These transposed intrinsic muscles of the foot do not carry normal surface sensibility and they must be covered with a skin graft. Their dissection is tedious because they are intertwined with the sensory nerves of the sole of the foot. It should be recognized that they cover only small defects and certainly do not reach the dorsum of the foot nor the malleoli. These small muscles are frequently too atrophic to be usable at all in the denervated foot.

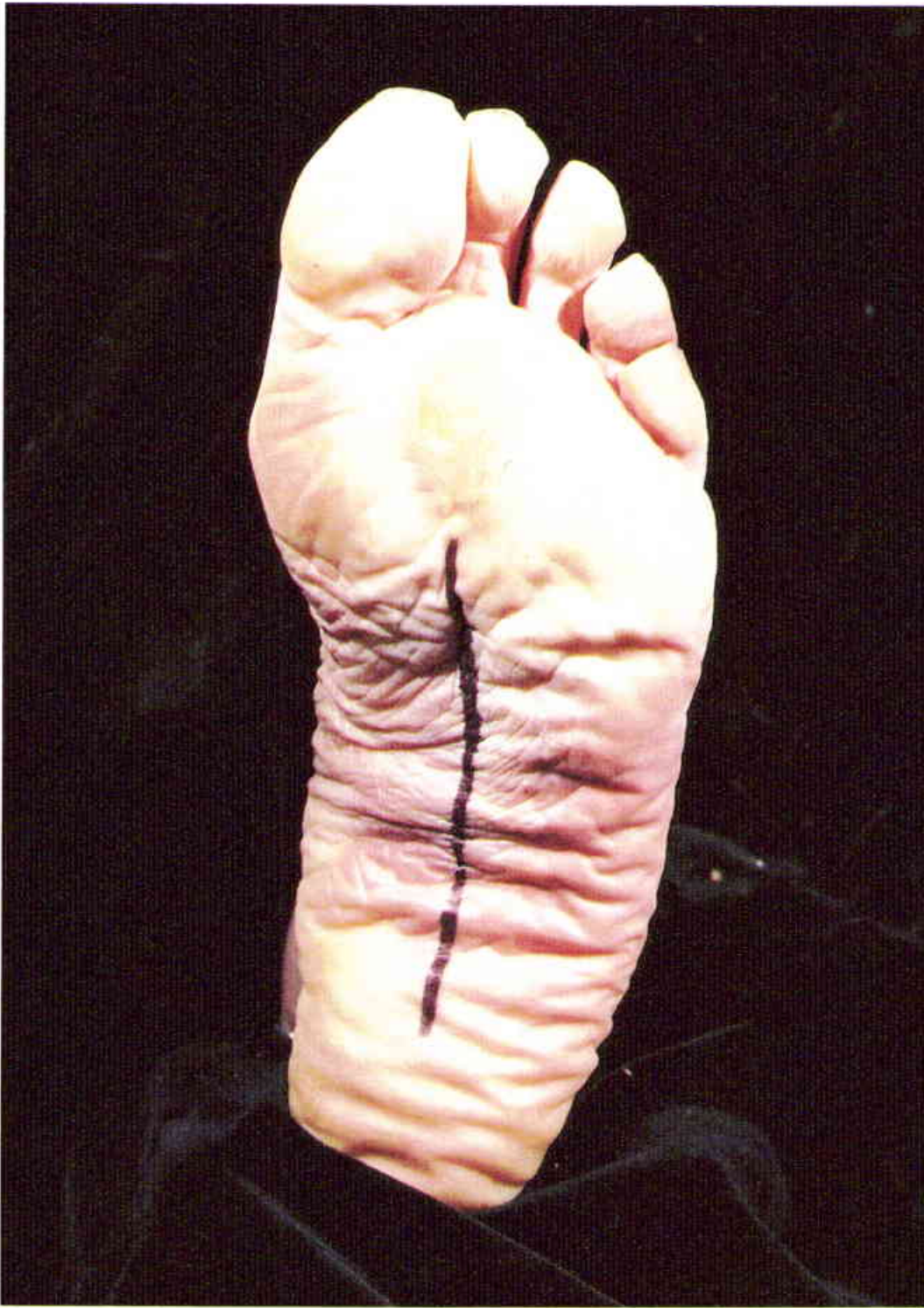ADVANTAGES

The intrinsic muscles of the sole of the foot find their primary applications in the correction of heel ulcerations or in osteomyelitis of the os calcis. Even though their dissection is difficult, they provide a much simpler operation than most of the usual alternatives, such as the dorsalis pedis flap or a "free" microvascular transfer. Even though the local "island" cutaneous flaps provide better sensibility, these small muscle flaps maintain enough deep pressure sensibility to protect the walking surfaces of the foot.

COMPLICATIONS, PITFALLS, AND DONOR SITE

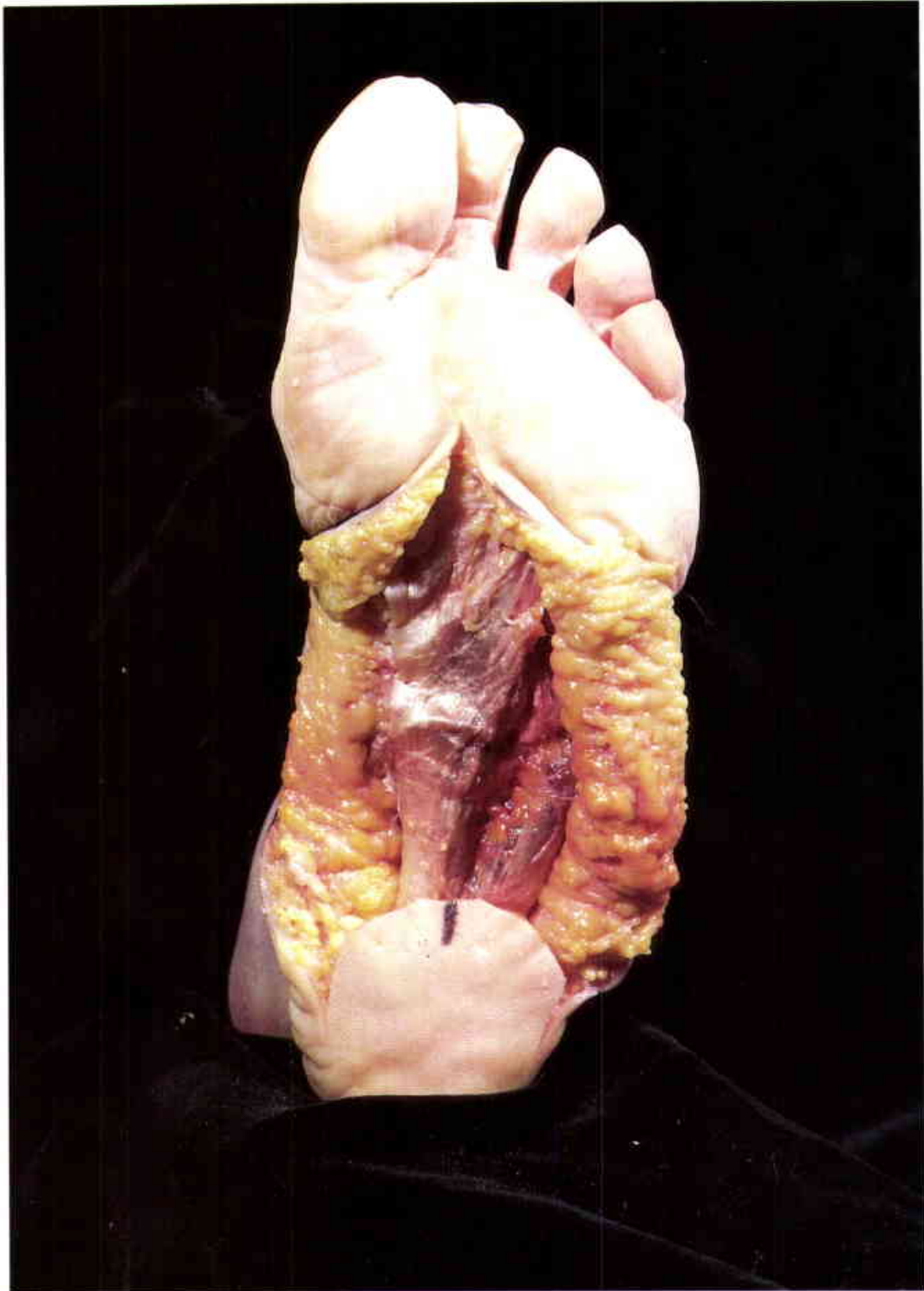The safe dissection of these muscles depends on adequate exposure. In general a direct incision over the muscle belly is the most expeditious choice. Fortunately, the resulting scar is well tolerated in normal ambulation. The elevation of the abductor hallucis muscle is straightforward since it is primarily a dissection of the muscle away from the first metatarsal bone and the medial plantar nerve. The short flexors are more difficult to elevate because they need to be carefully separated from the intertwined digital nerves. The plantar fascia should always be elevated with the short flexors, to provide a fascial layer for suturing and to hold the small muscles together as a cohesive unit.

The donor site is inconsequential, unless a skin graft is required. The plantar skin flap donor site can frequently be primarily closed if enough of the os calcis is removed, but it is usually necessary to place a skin graft on the non-weight-bearing surface of the foot. The remaining weight-bearing skin will usually cornify and thicken enough to protect the ambulatory foot. The compound myocutaneous flap is preferred in the denervated foot since the small muscles of the foot may be atrophic to the point that they are difficult to identify.



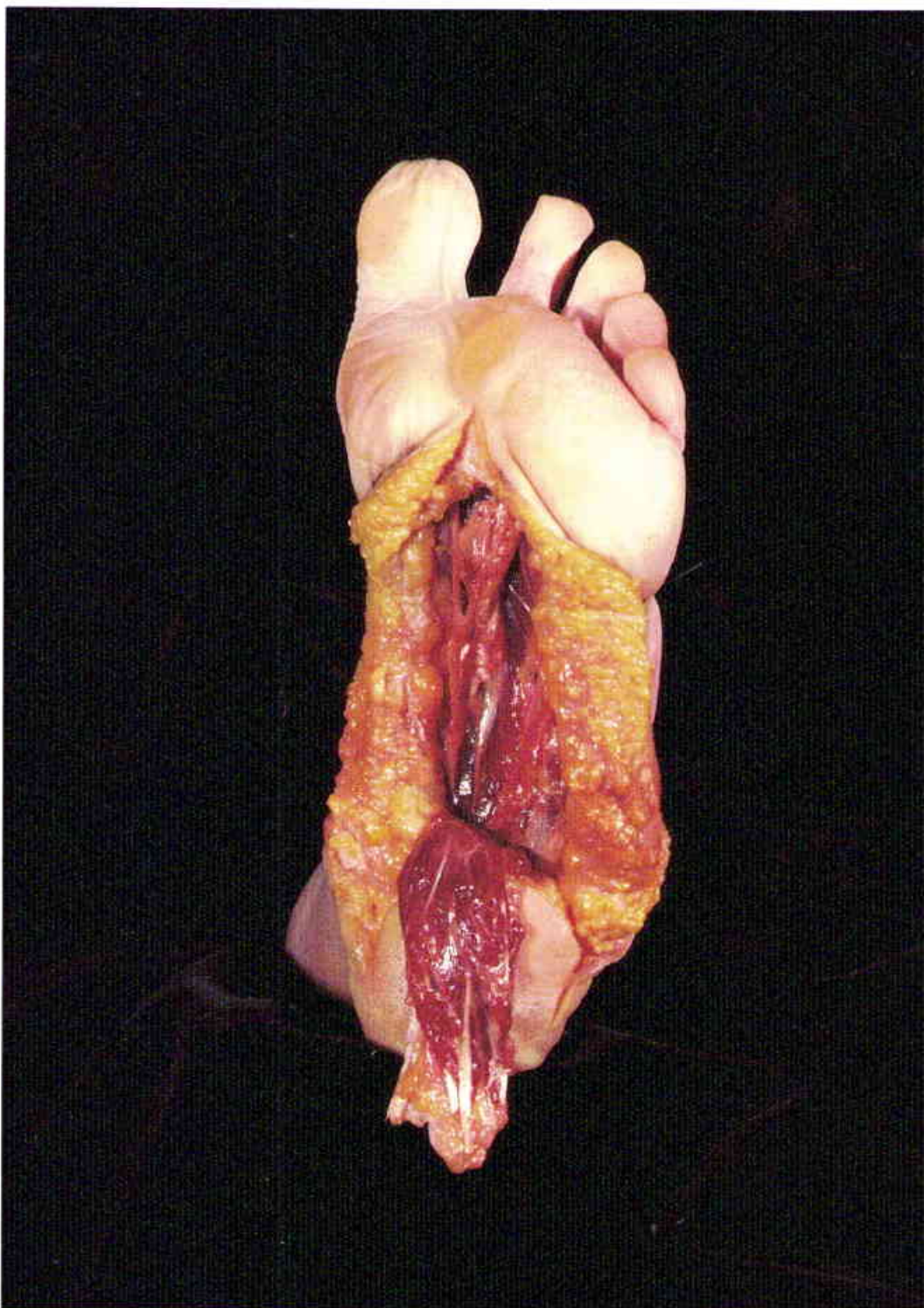
1

Midline plantar incision for retrieval of the flexor digitorum brevis muscle in a cadaver.



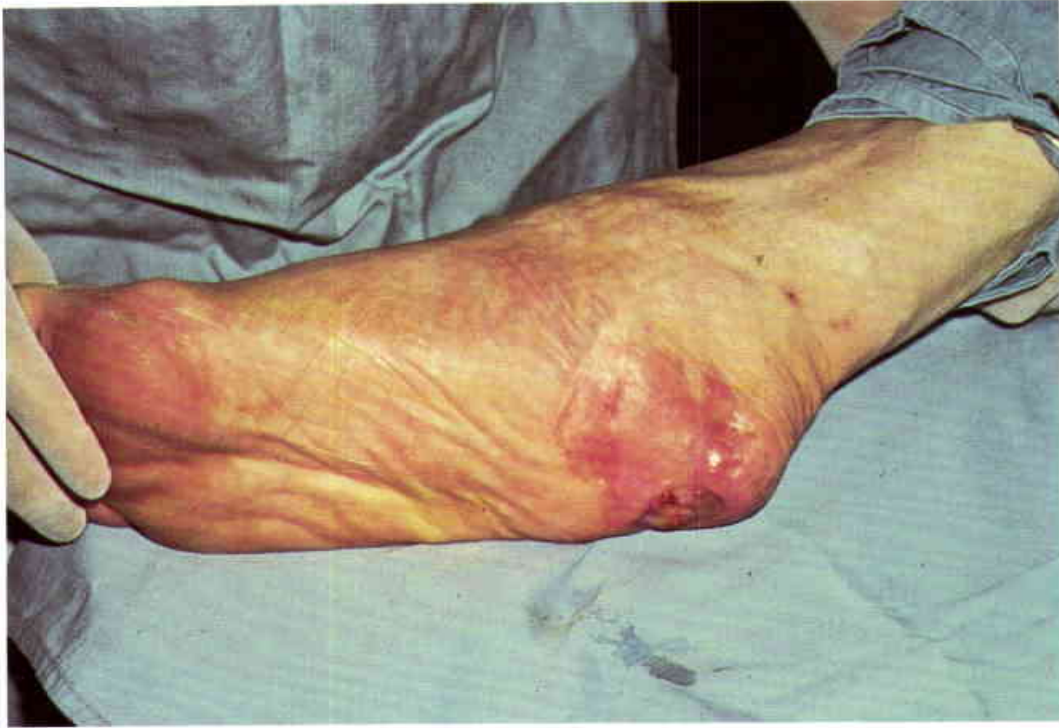2

The plantar fascia is left attached to the surface of the flexor digitorum brevis muscle. Note how the muscle fans out from its os calcis origin to the distal insertion.



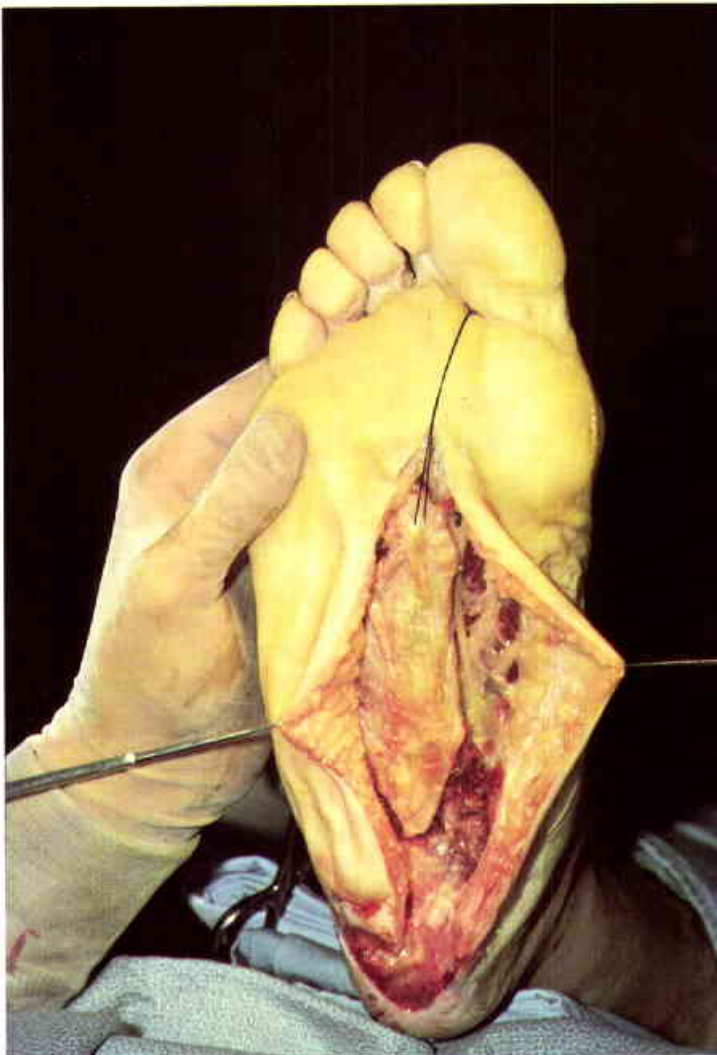
3

Short flexors transposed to the heel. The plantar nerves and vessels are protected in the course of the flap elevation.



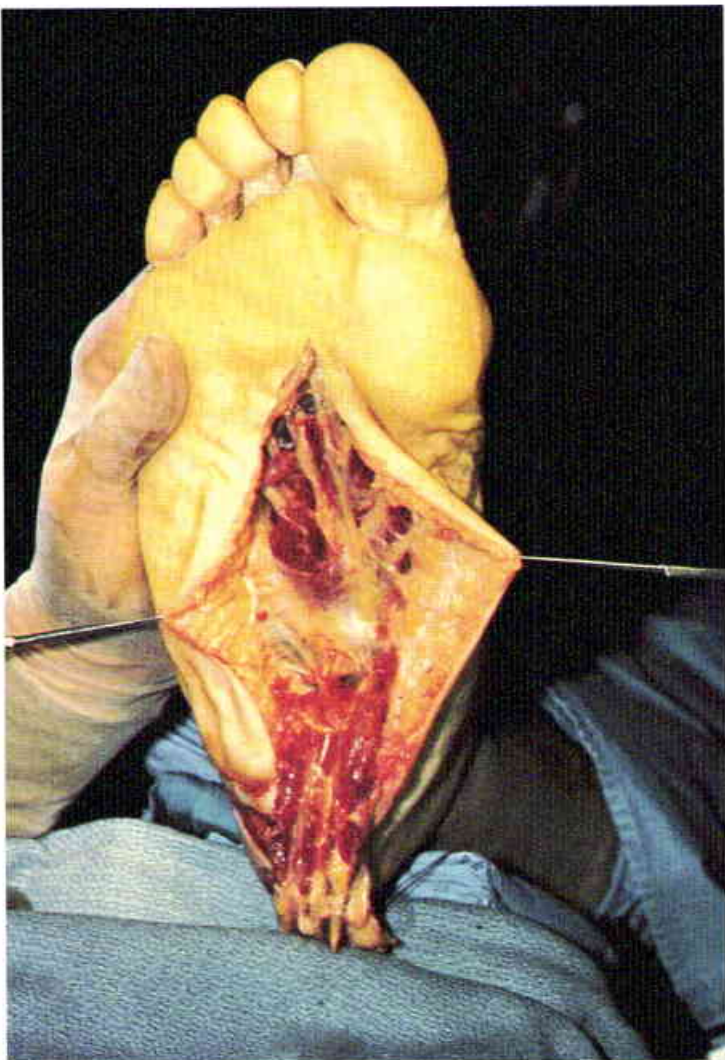
4

Chronic osteomyelitis of the os calcis in a fifty-seven-year-old male. Multiple debridements failed to correct the osteomyelitis, and the skin-grafted heel was subject to constant ulceration. (Case of P.G. Arnold)



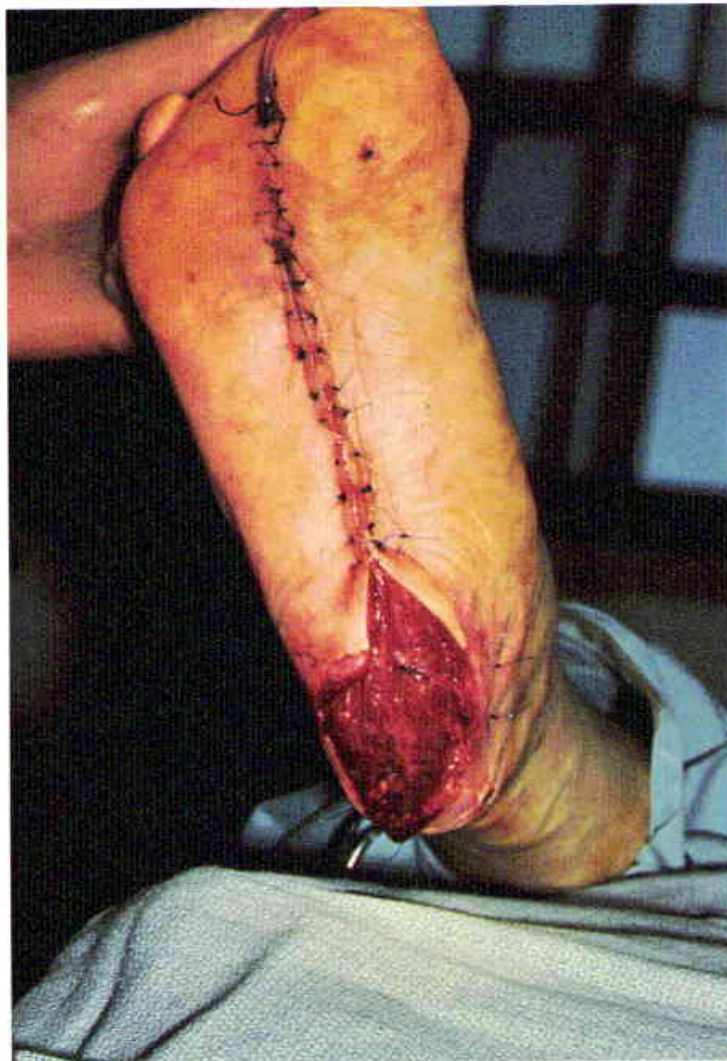5

The short flexors are exposed through a midline plantar incision. The plantar fascia is left attached to the muscle.



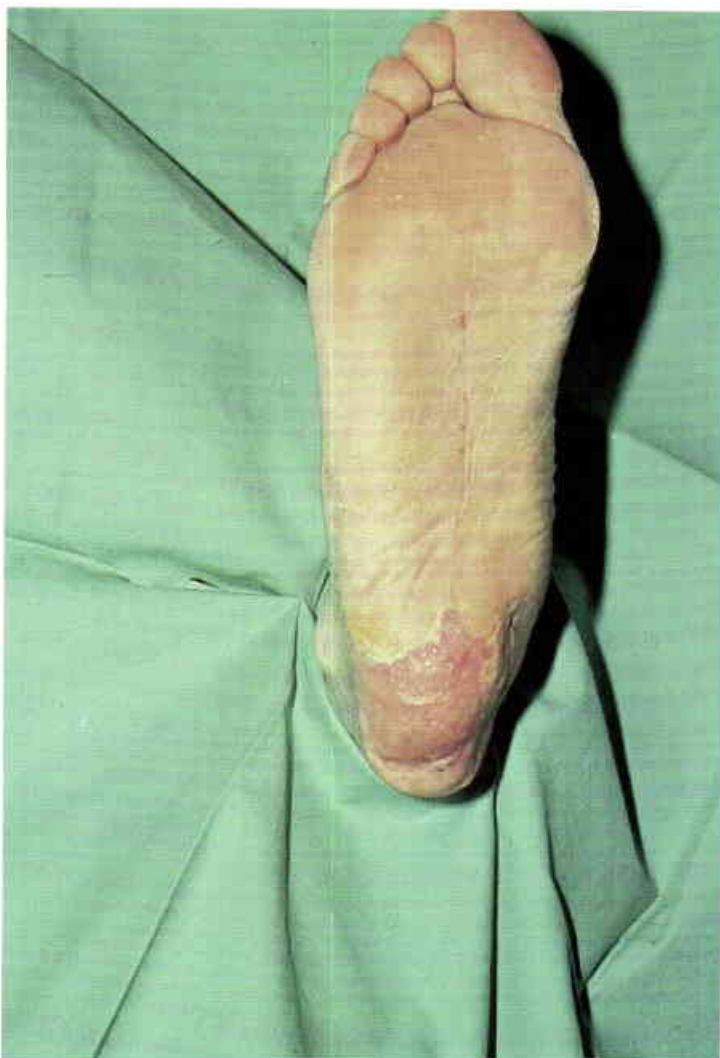6

Short flexor muscle transposed to the heel. Note the medial and lateral plantar nerves and vessels above the lumbrical muscles and long flexor tendons.



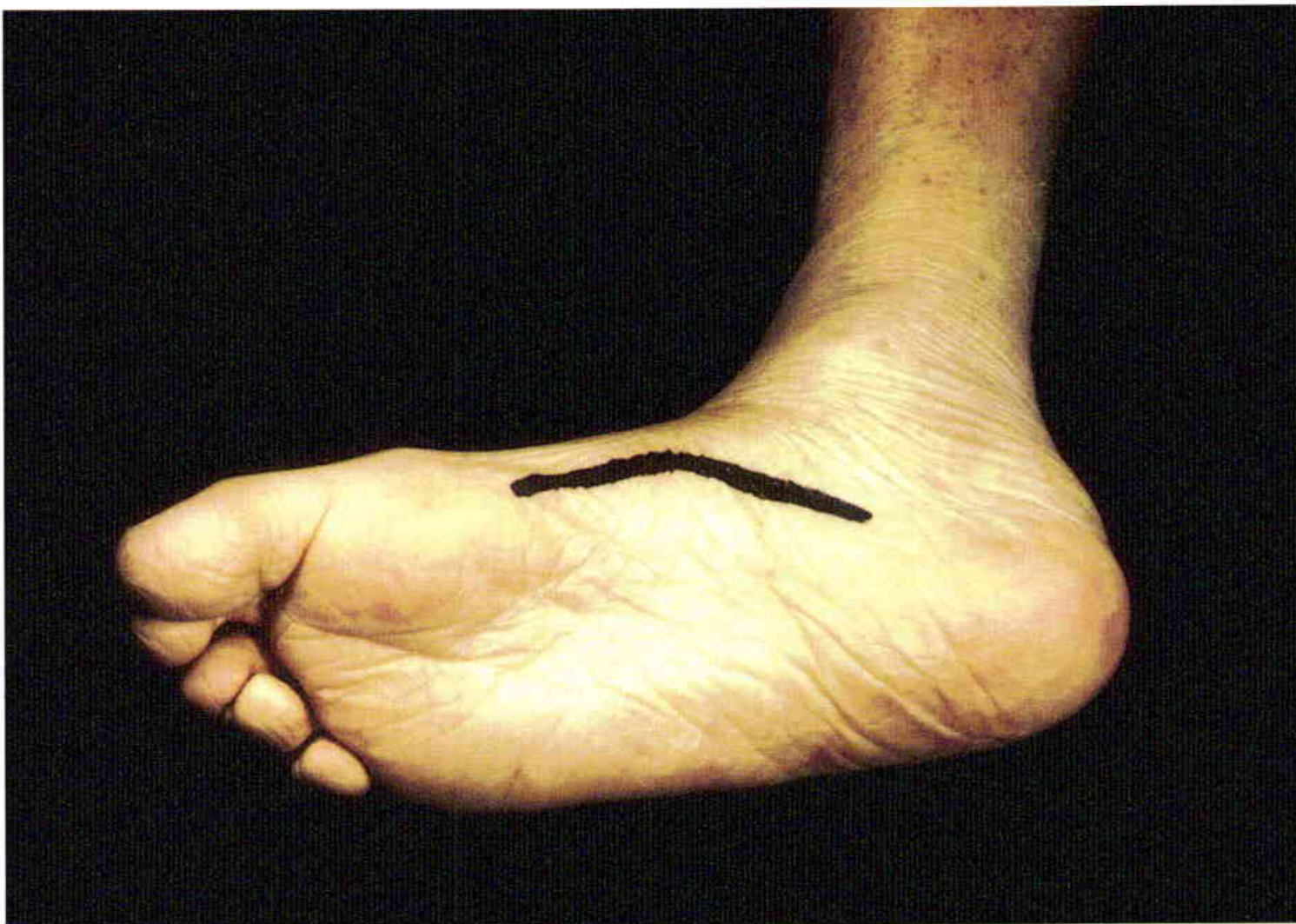7

Appearance of the flexor digitorum brevis muscle flap after forty-eight hours, at the time of skin grafting.



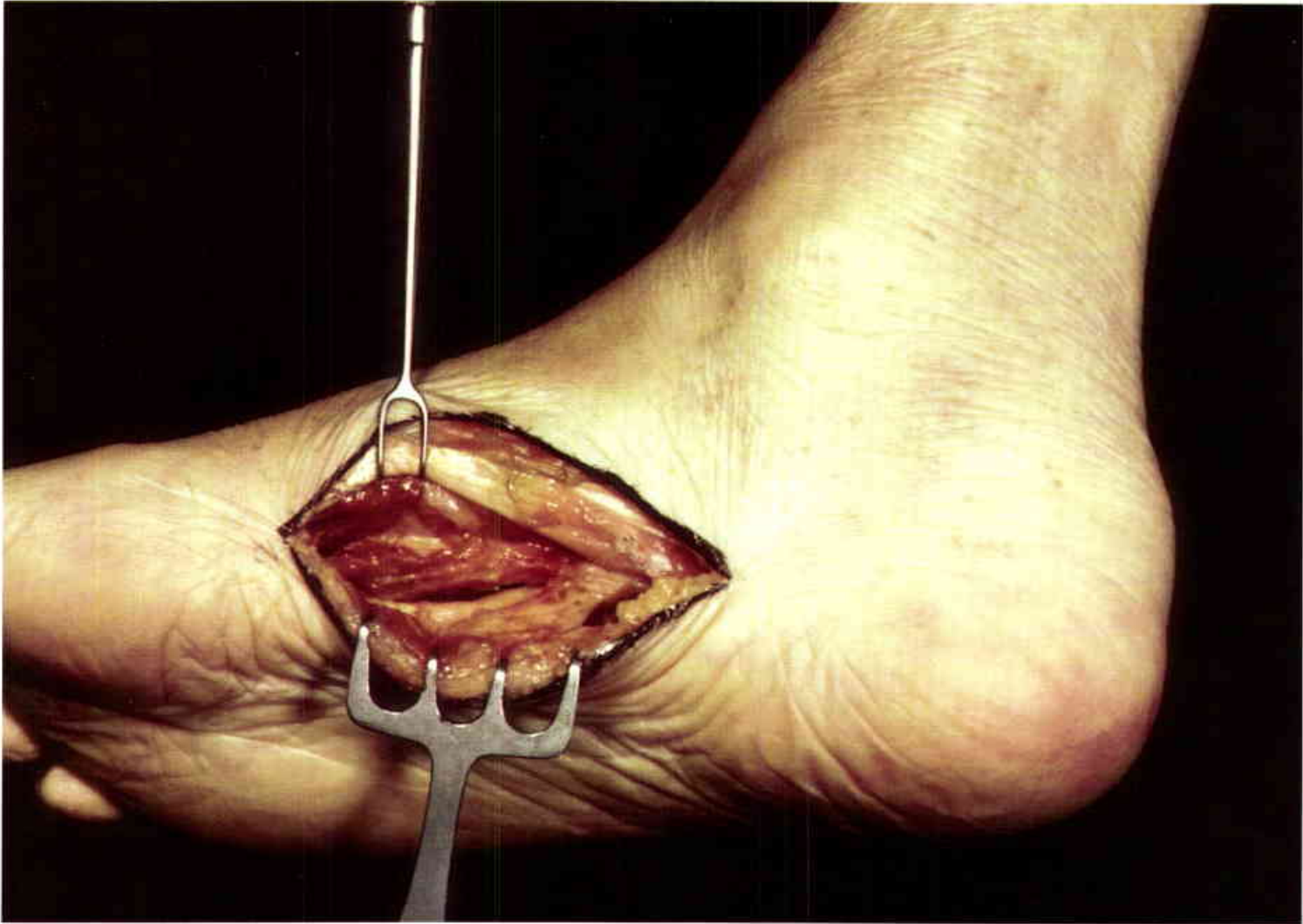
8

Eighteen months following the closure. The osteomyelitis has not recurred, and the patient has been able to work as a machinist without further ulceration. Note the midline donor site scar.



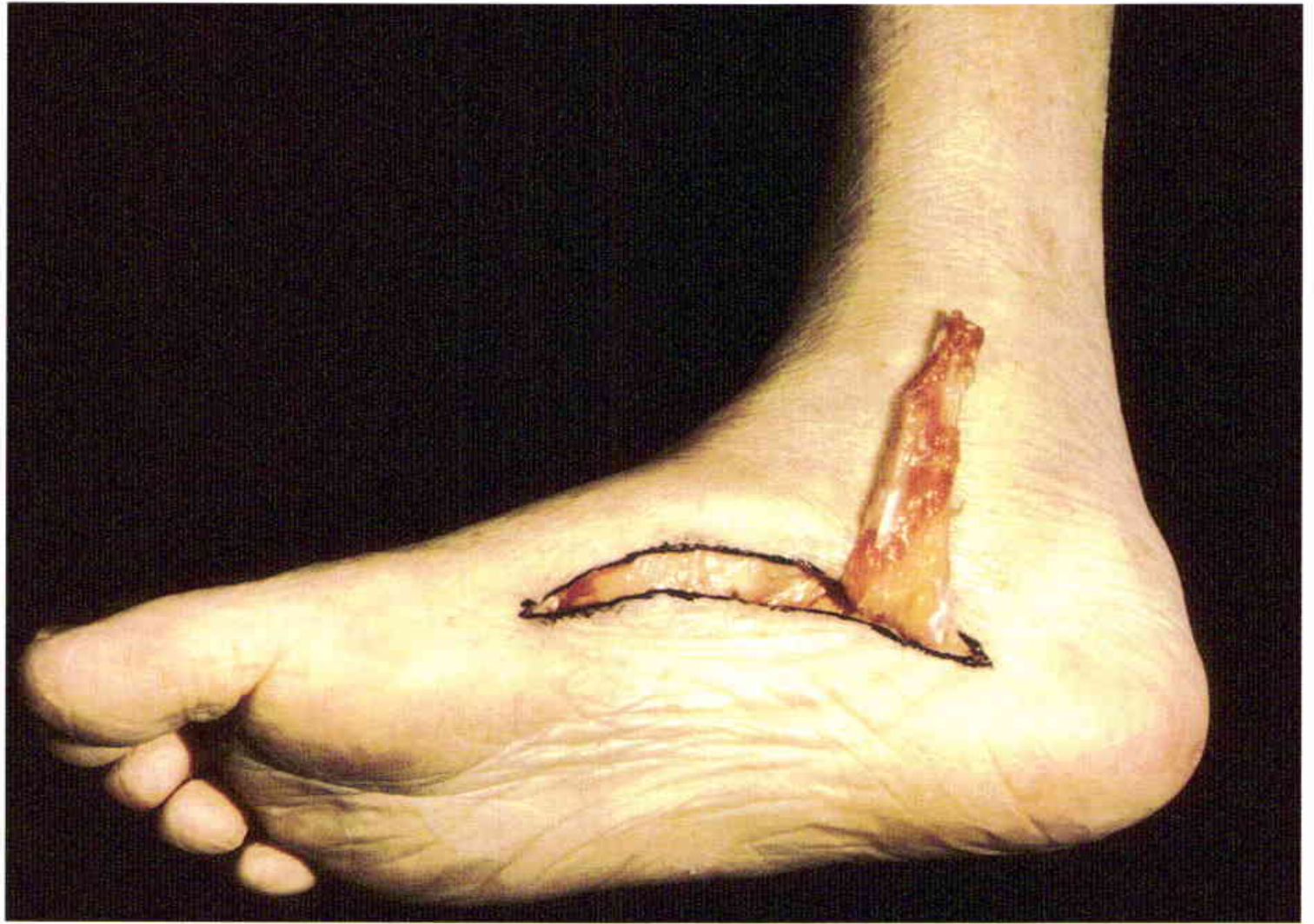9

The usual incision for the retrieval of the abductor hallucis muscle is demonstrated in a cadaver.



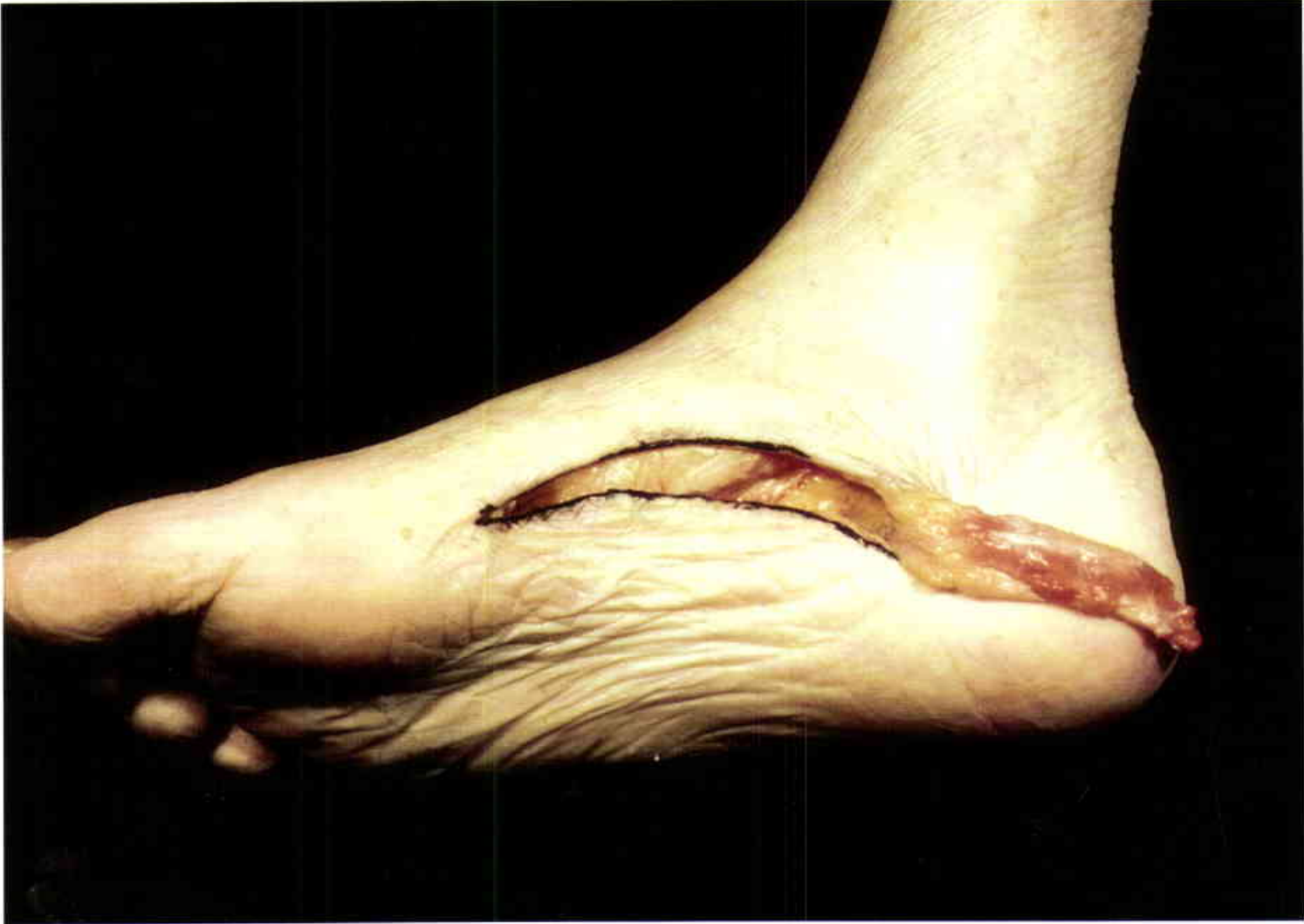10

The abductor hallucis muscle is retracted superiorly. The short flexor muscle is exposed by retracting the plantar fascia inferiorly.

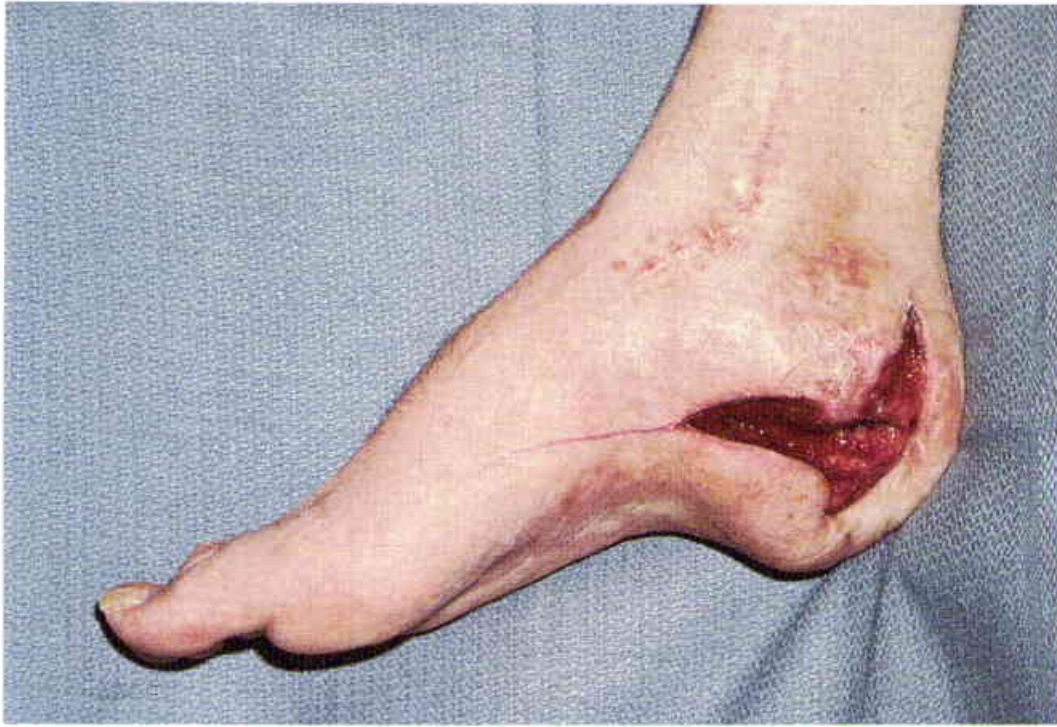

11

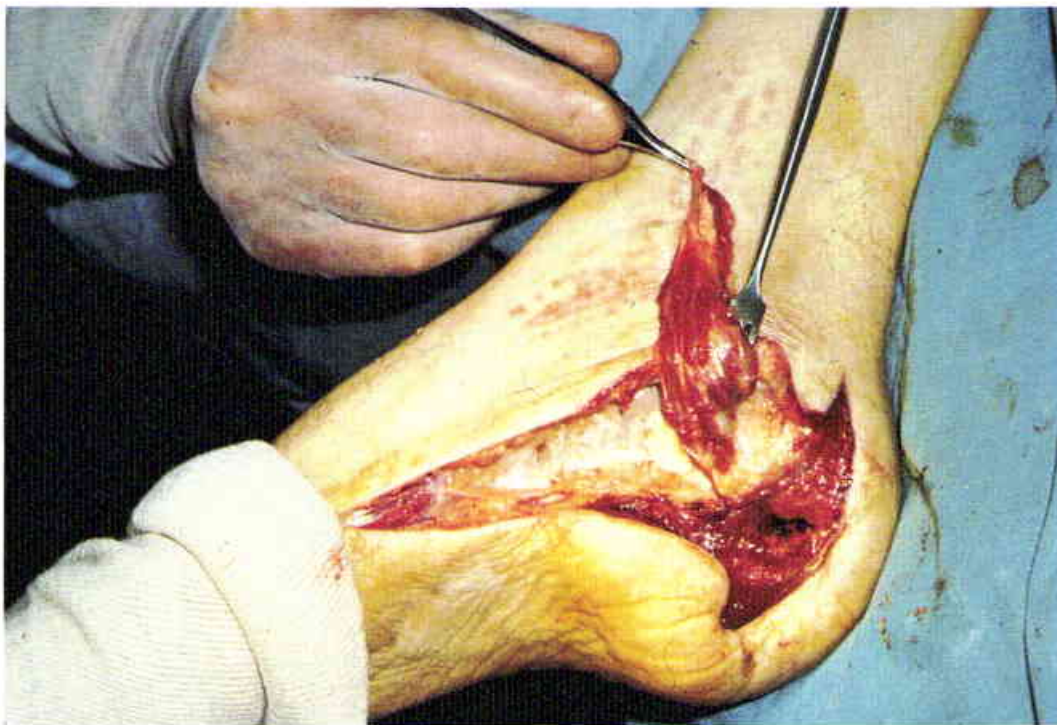The small abductor hallucis muscle barely reaches the medial malleolus.

**12**

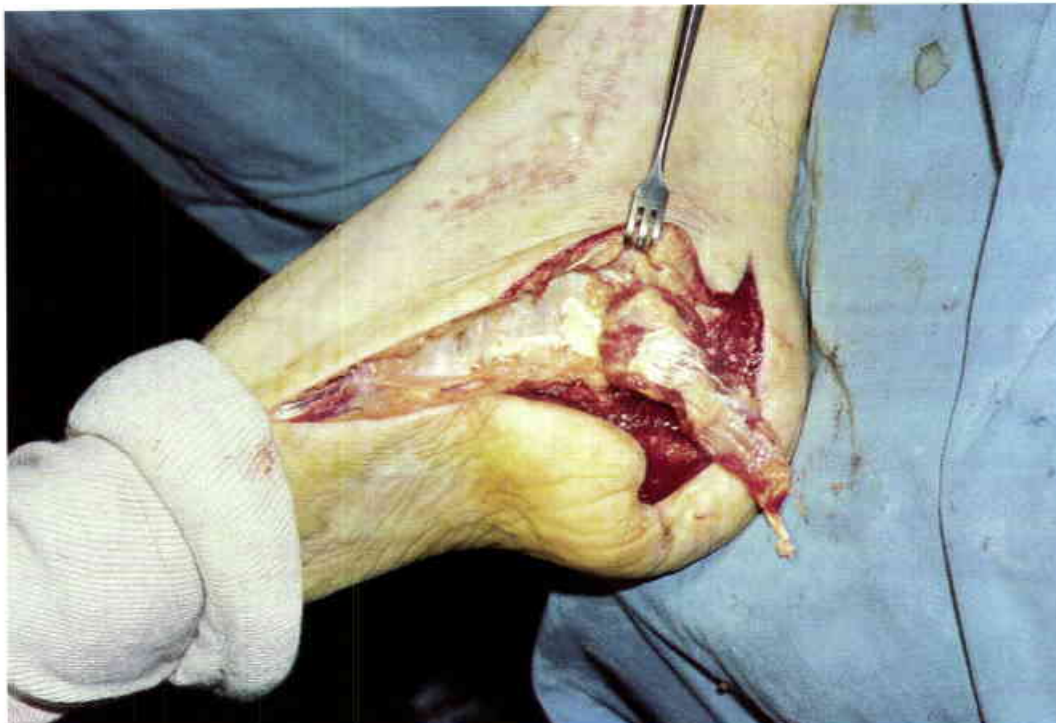Posterior rotation of the abductor hallucis muscle. The size of this intrinsic muscle is variable and must be determined at exploration.

**13**

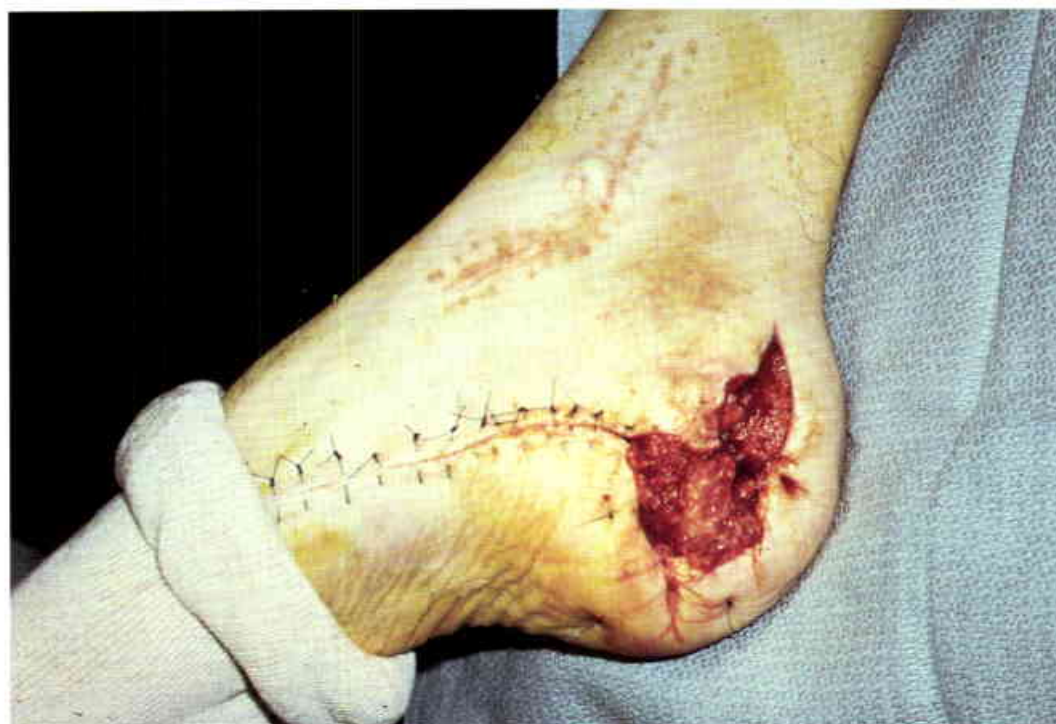Osteomyelitis of the os calcis in a thirty-four-year-old airline pilot. The defect will be extended anteriorly to expose the abductor hallucis muscle. (Case of P.G. Arnold)

**14**

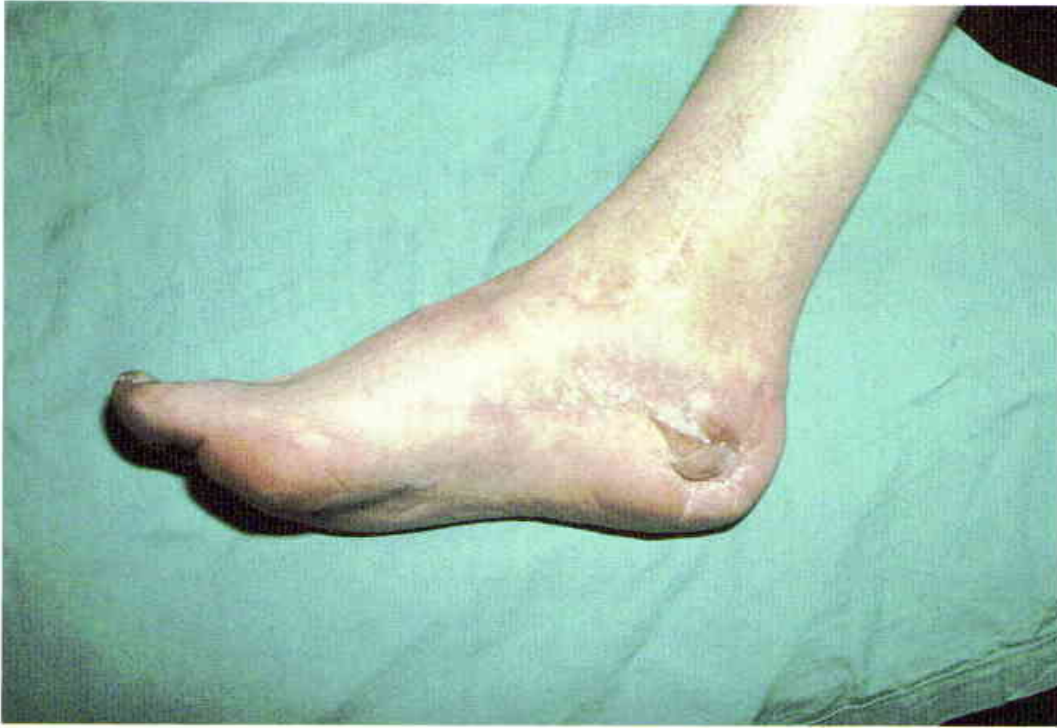Elevated abductor hallucis muscle flap. The punched out sequestrectomy defect of the os calcis is seen centrally.



15
Muscle flap transposed into the bony defect.

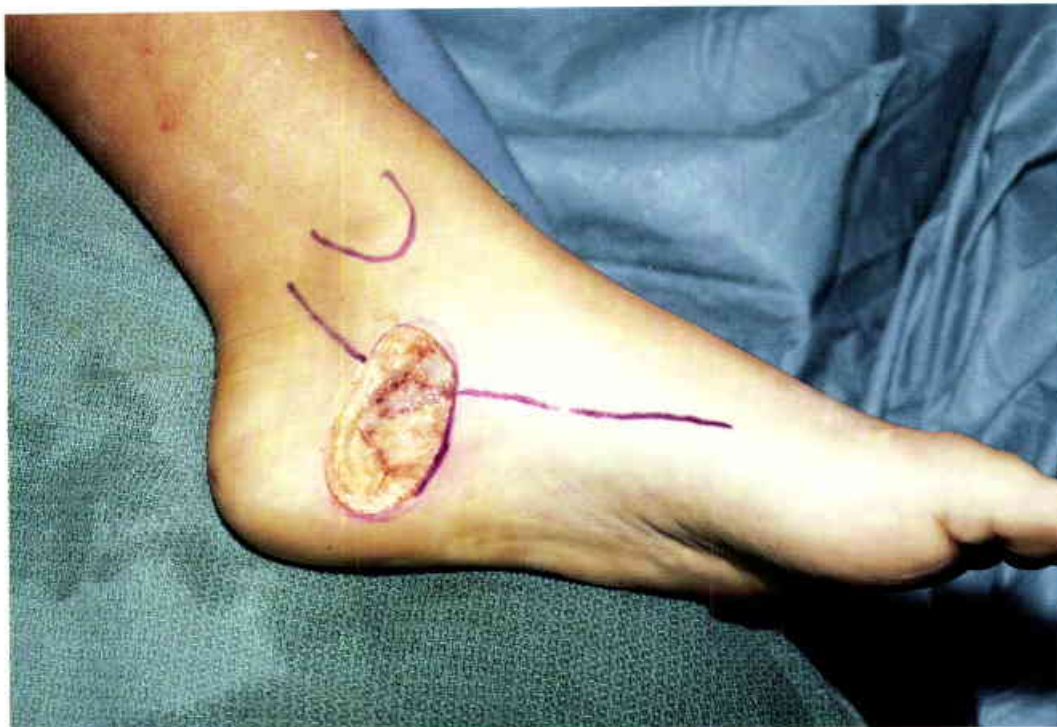

16
Appearance of the muscle flap at the time of delayed skin grafting.

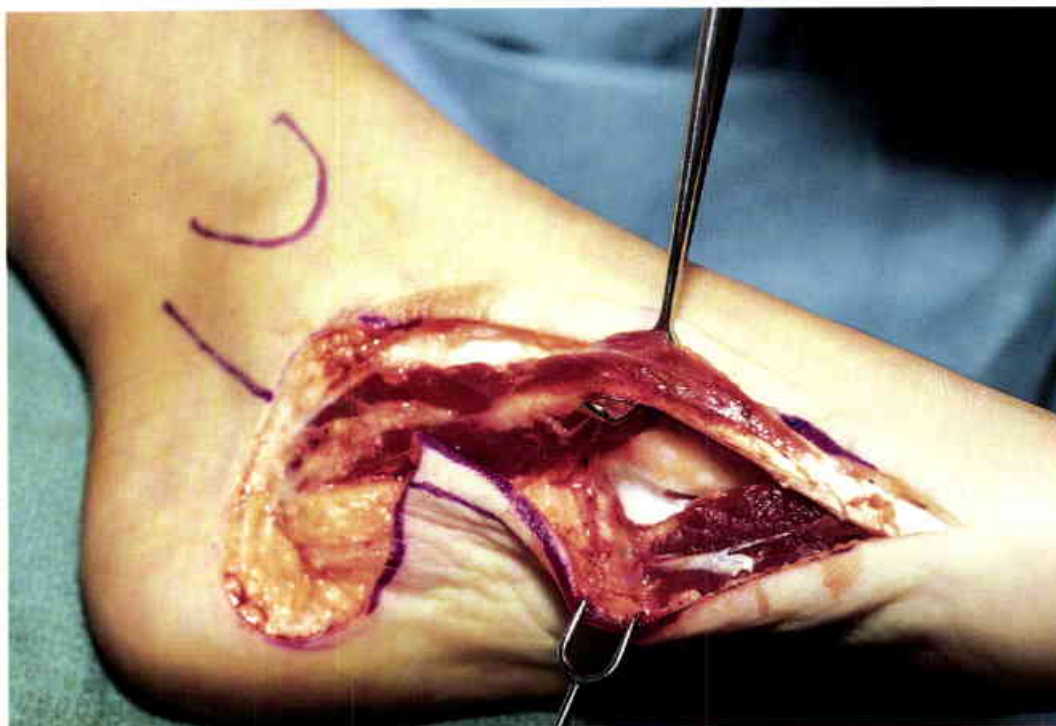

17

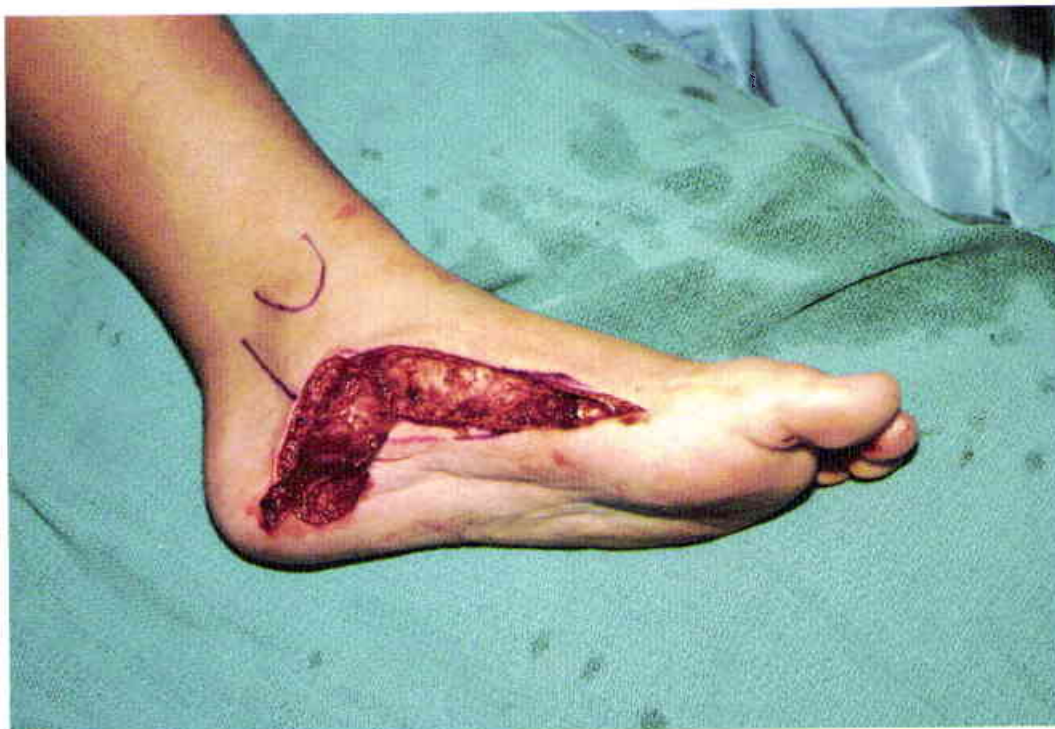Five years following surgery. The patient wears a normal shoe, and the wound has remained healed for eight years.



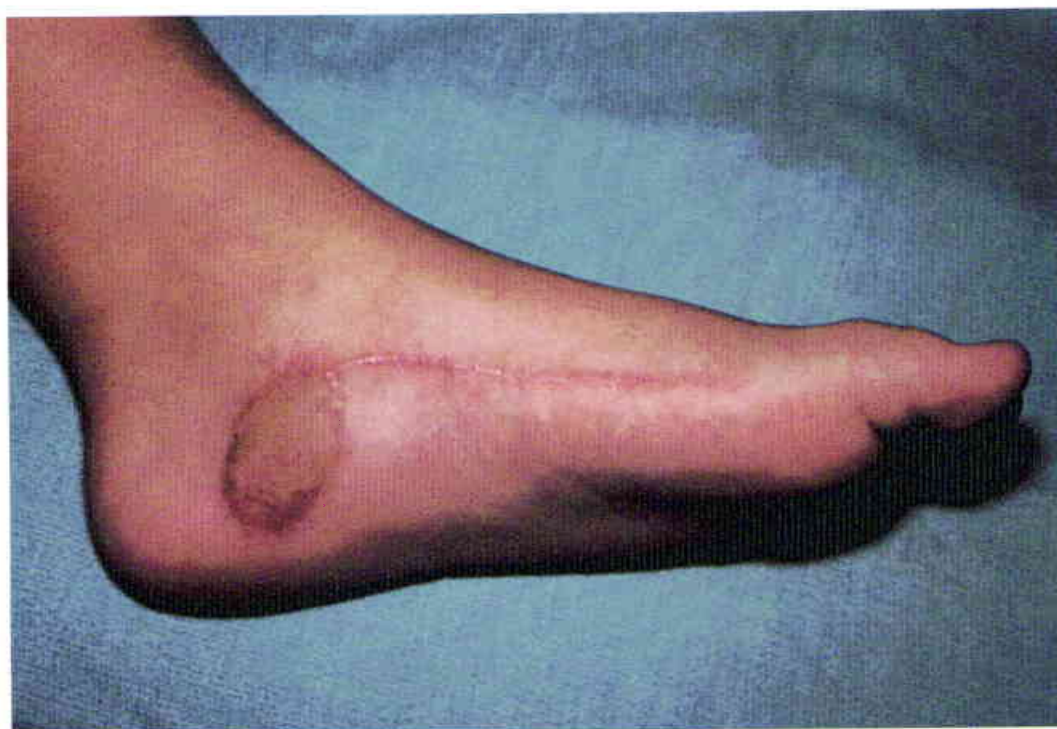18
Resected hemangiopericytoma of the heel
in an eight-year-old girl. (Case of J.B.
McCraw)



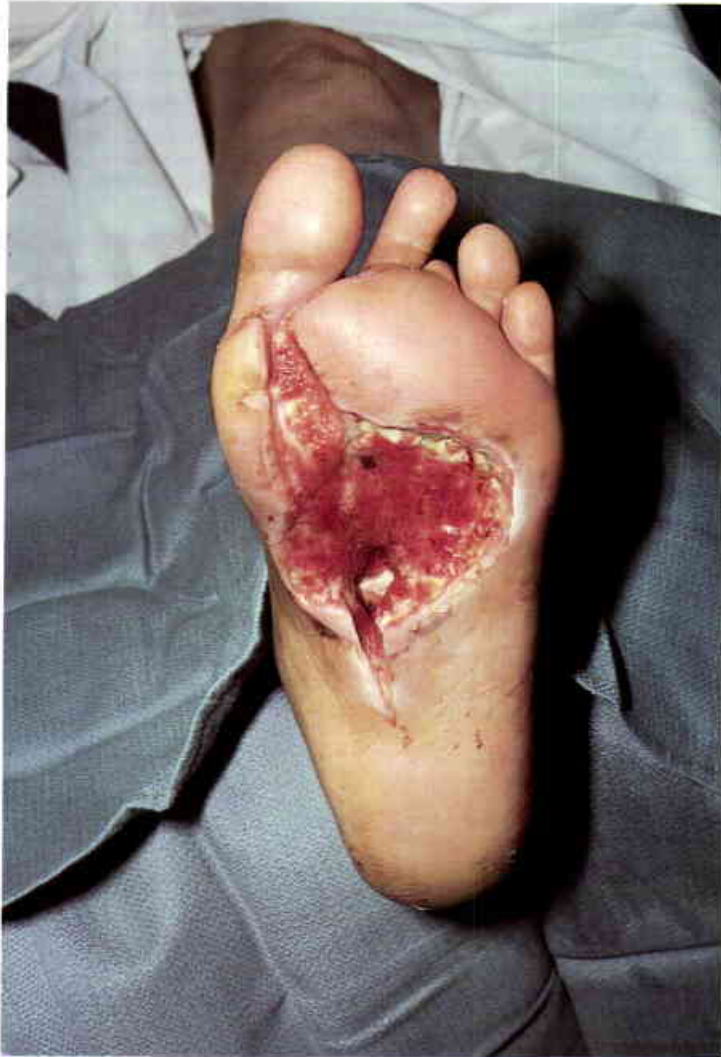19
Retracted abductor hallucis muscle.

**20**

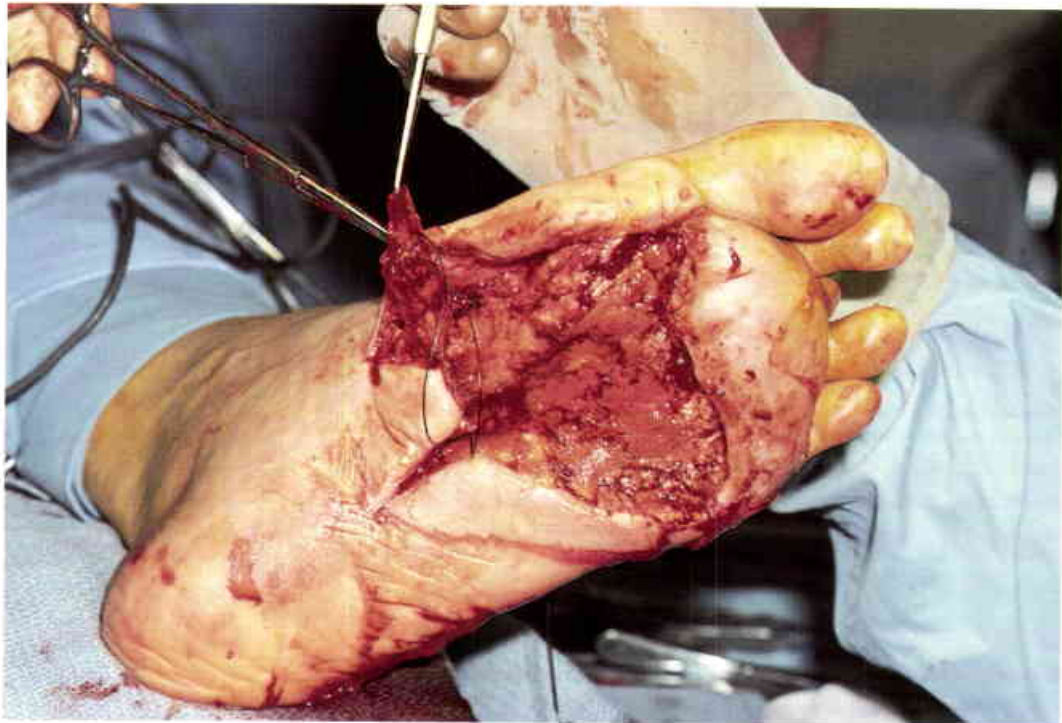
Abductor hallucis muscle transposed posteriorly.

**21**

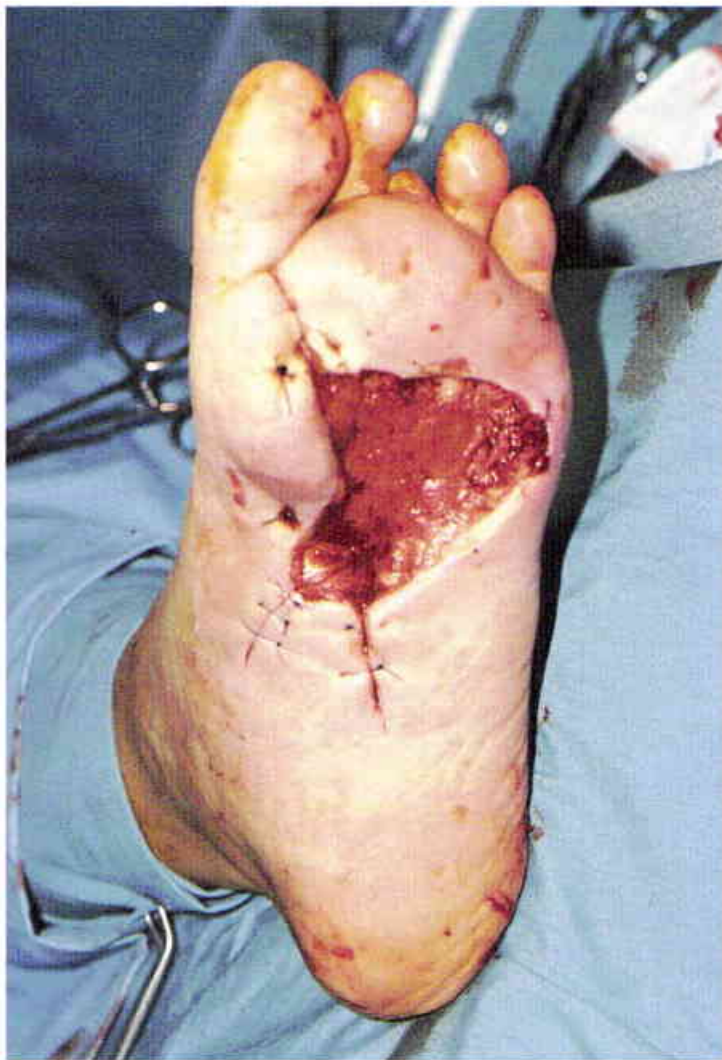Skin-grafted muscle flap at four months. The full-thickness skin graft was harvested from the groin. Good pressure sensibility has been maintained in the muscle flap.

**22**

Fifty-year-old diabetic female with osteomyelitis of the proximal first and second metatarsal bones following a deep plantar abscess. (Case of P.G. Arnold)

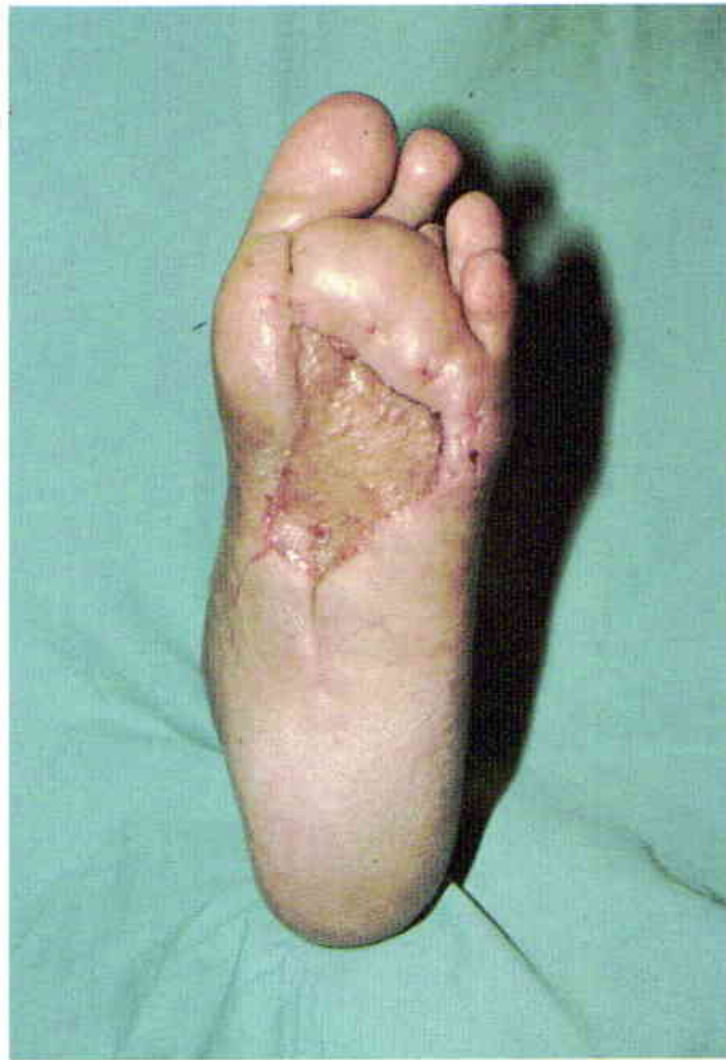**23**

Elevated abductor hallucis muscle. The debrided distal sole wound will be skin grafted. The muscle flap will be used to obliterate the proximal metatarsal bone defects.



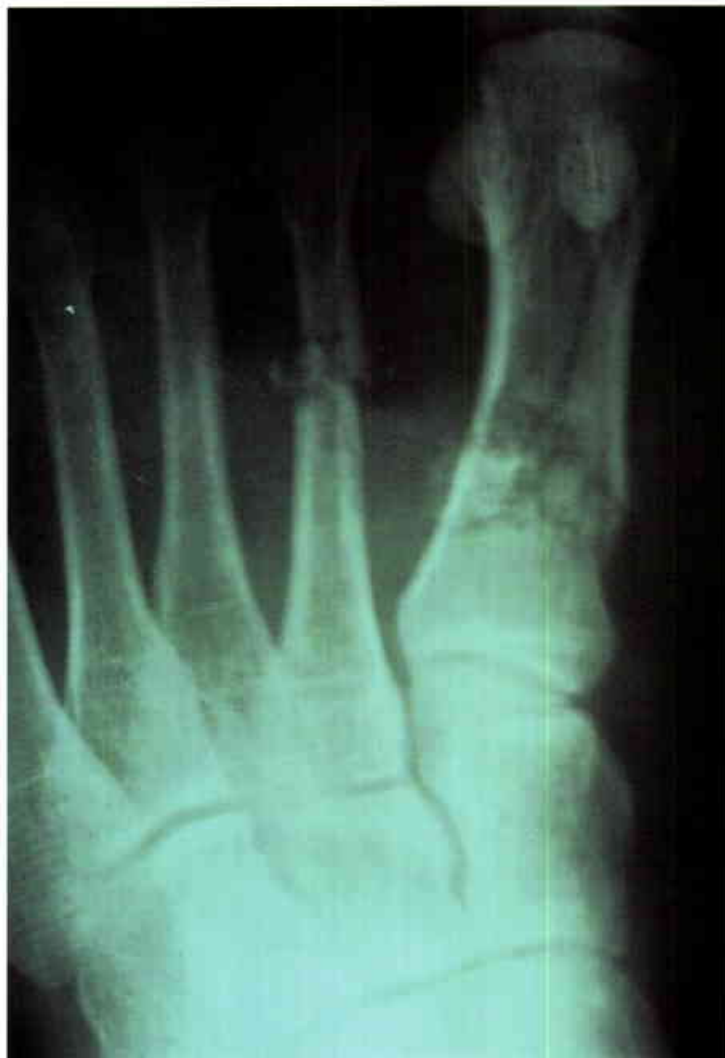24

Abductor hallucis muscle transposed over the base of the second metatarsal bone. Skin grafting was delayed for forty-eight hours.

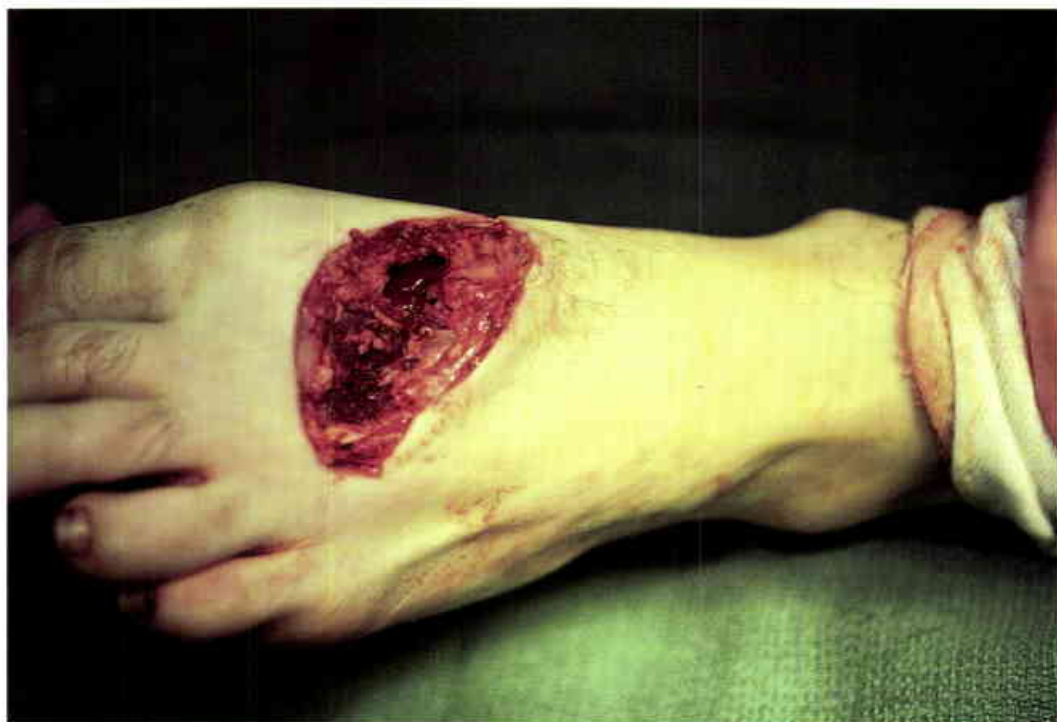

25

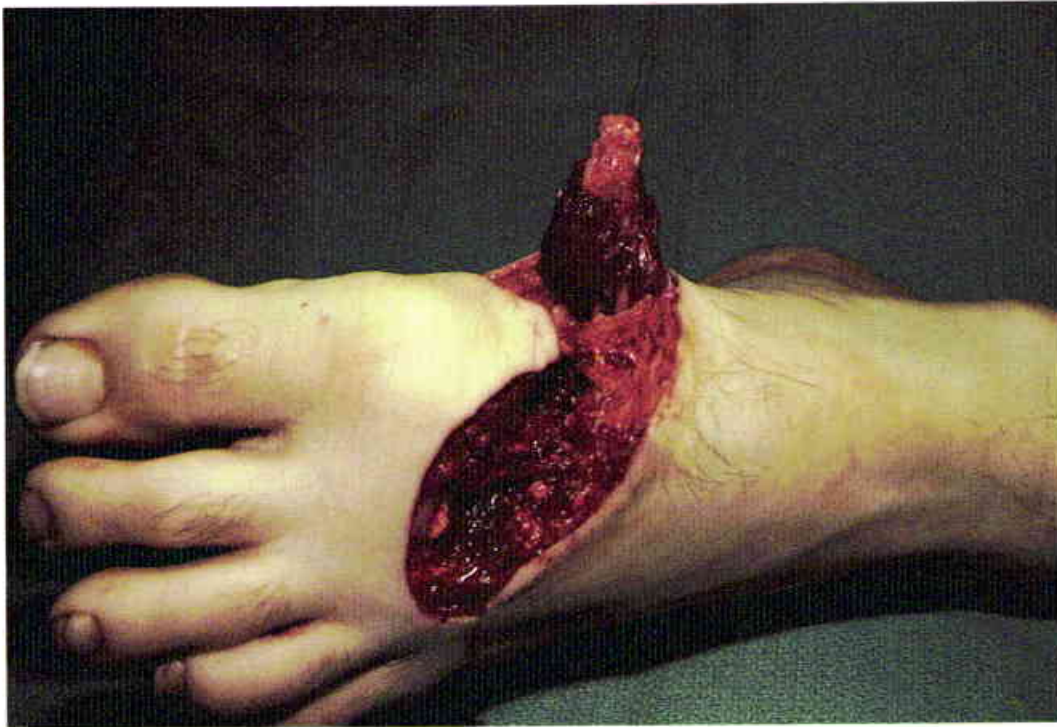The osteomyelitis has not recurred, and the wound has remained healed for six years.

**26**

Open fractures of the first and second metatarsal bones from a riding lawnmower injury. (Case of J.B. McCraw)

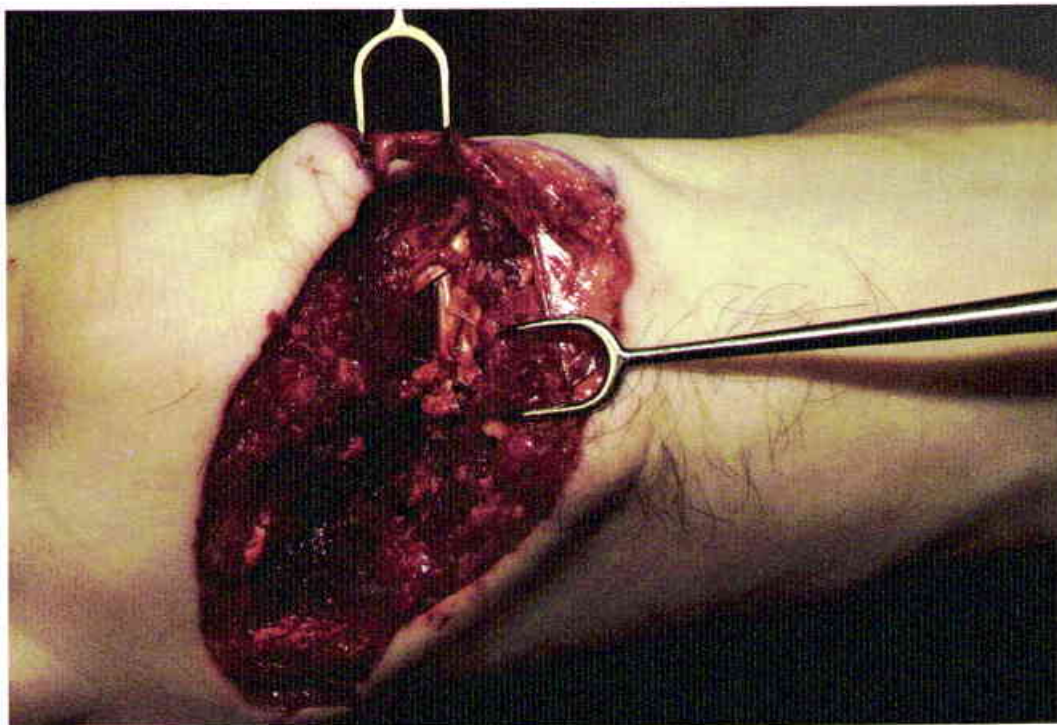**27**

The anterior surfaces of the metatarsal bones were destroyed by the lawnmower blade. There was no loss of the dorsal foot skin.



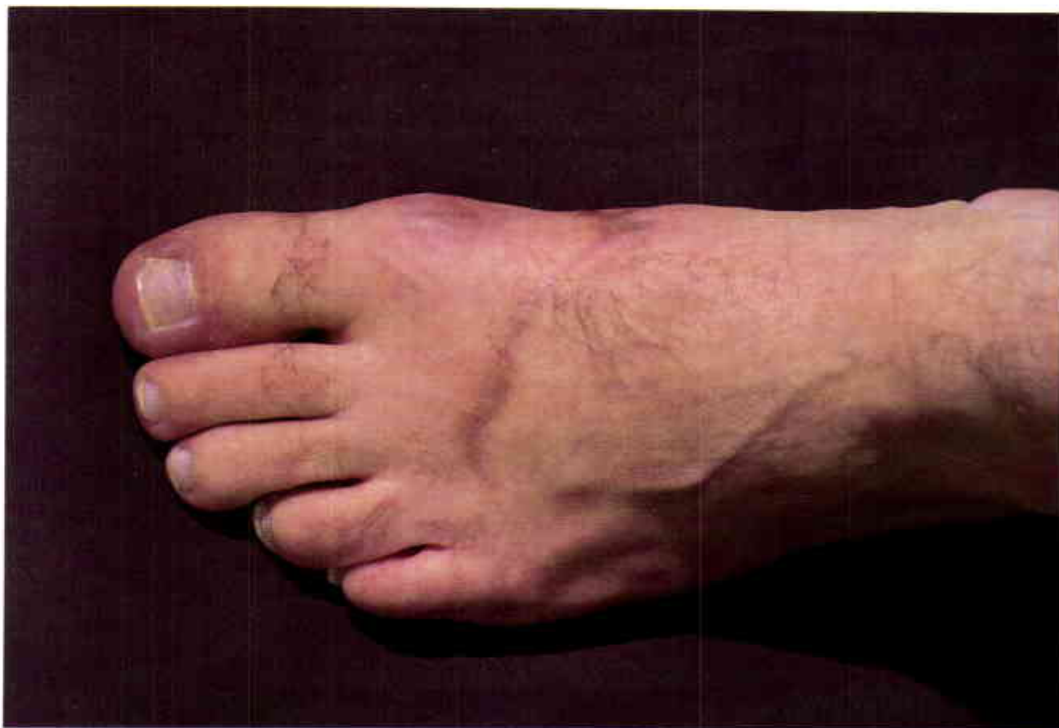28

Abductor hallucis muscle elevated to cover the dorsal surface of the metatarsal bones. An immediate muscle flap was used to revascularize the contaminated fractures.



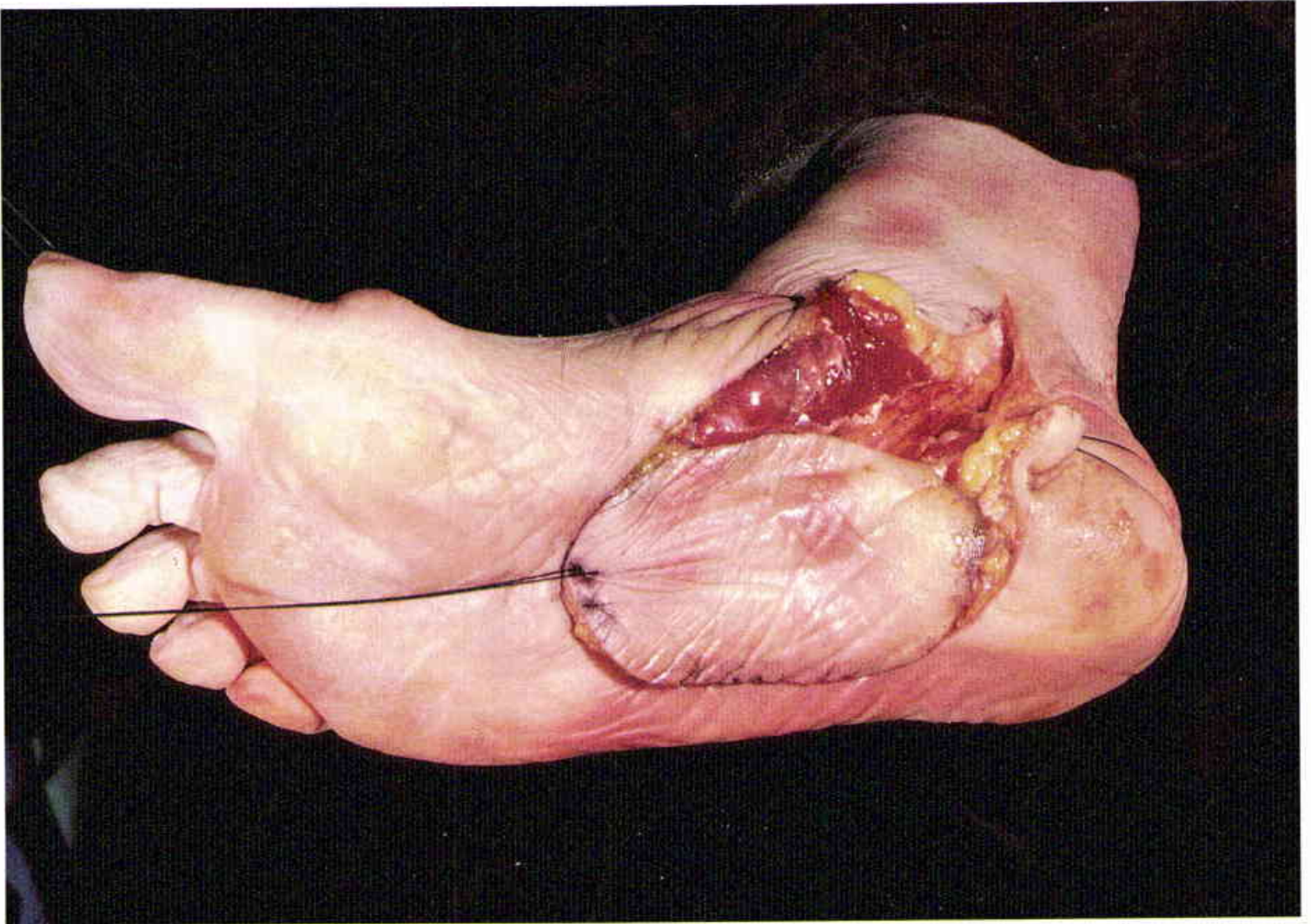29

Transposed muscle flap. The fractures were stabilized with Kirschner wires.



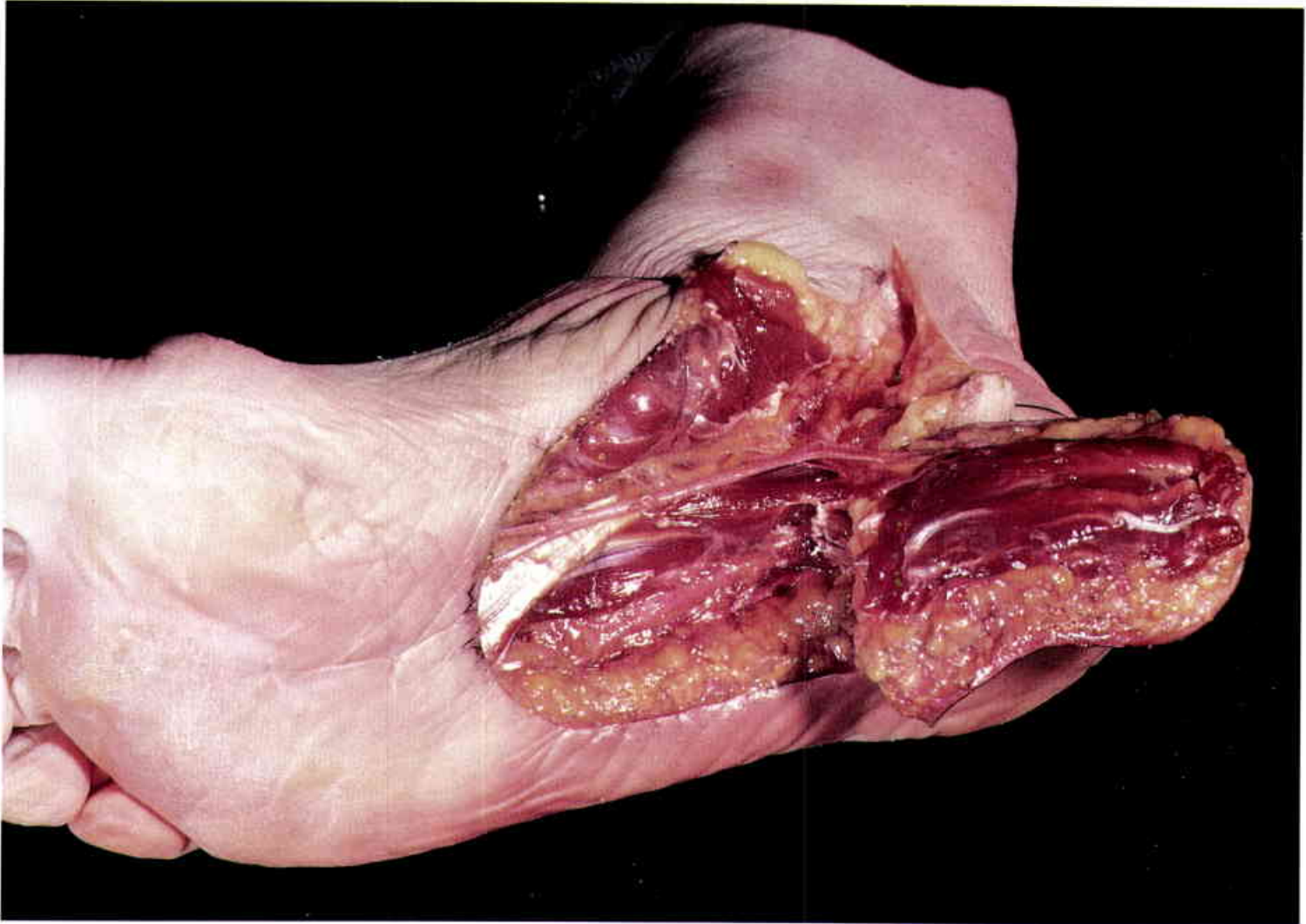
30

Healed wound at one year. The patient returned to normal activities.



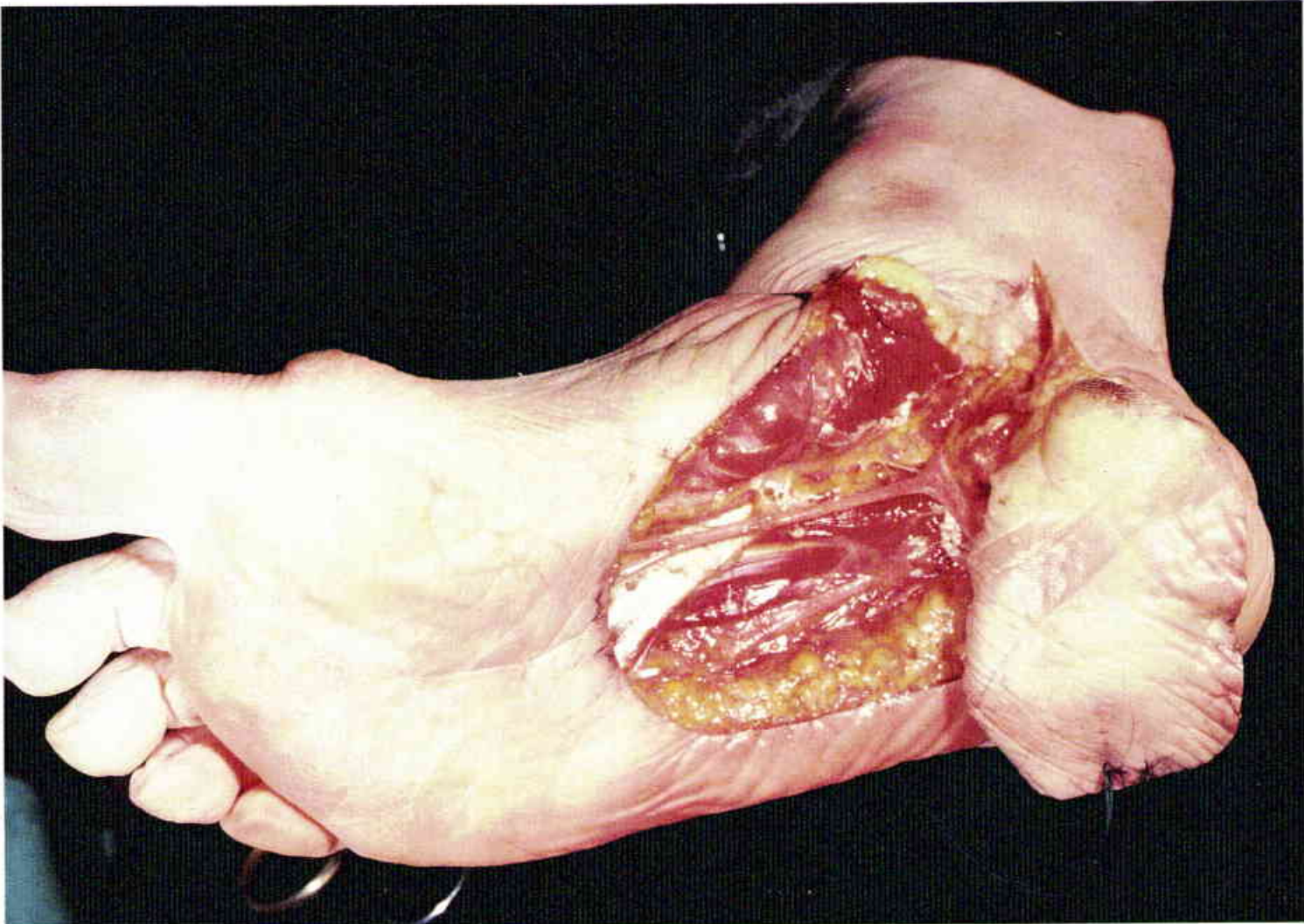
31

Cadaver dissection of the compound flexor digitorum brevis sole flap, which is based on the medial plantar artery and nerve. The posterior tibial nerve and vessels are first identified in the "tarsal tunnel" prior to elevation of the short flexor muscle and the sole skin.



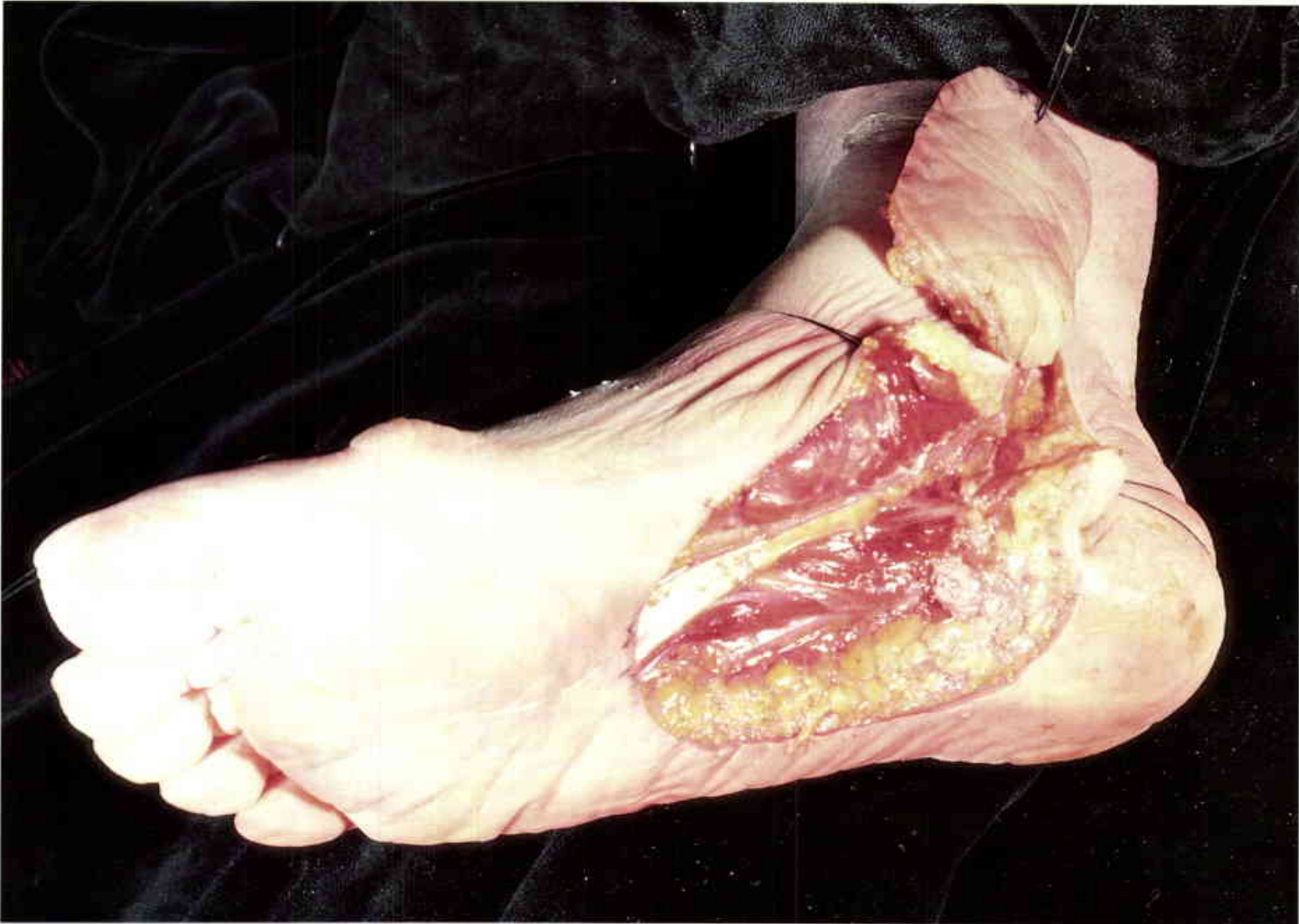32

The compound flap is elevated with the plantar fascia and the flexor digitorum brevis muscles. Note the branch of the medial plantar nerve which enters the flap medially.



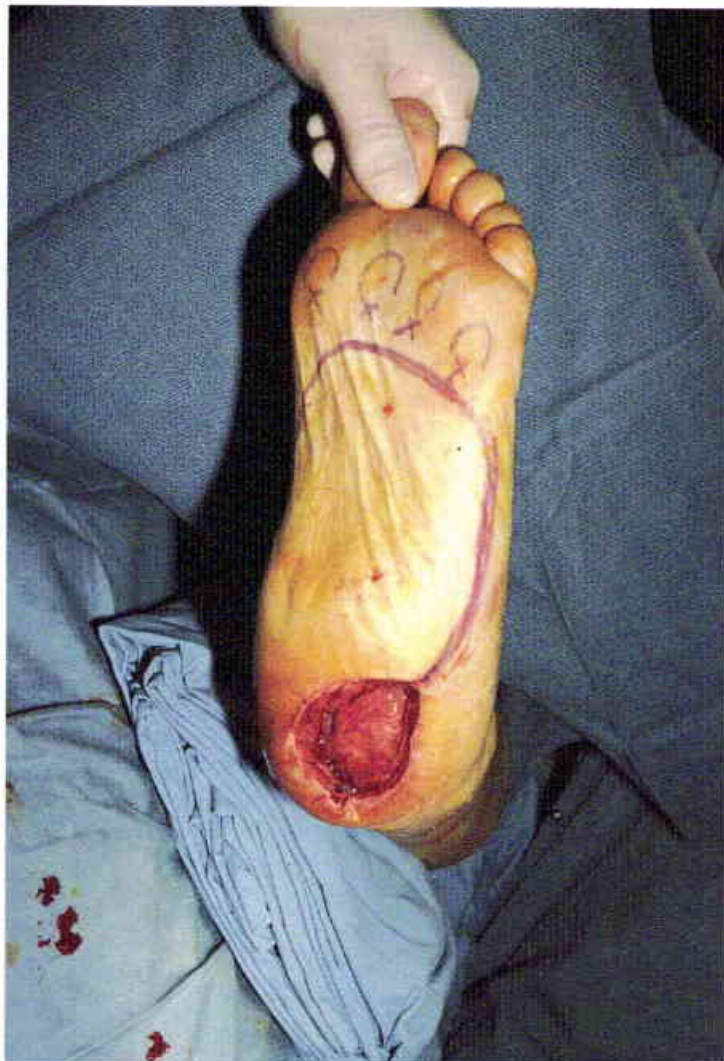33

Transposition of the "island" flap to the heel as a sensory innervated flap.

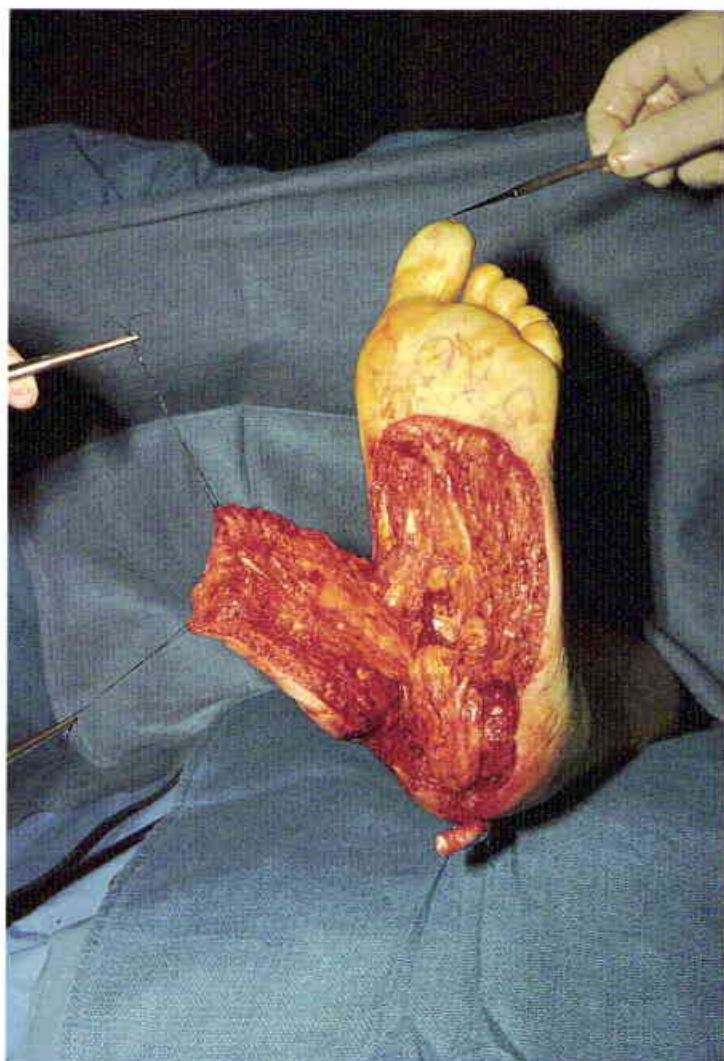


34

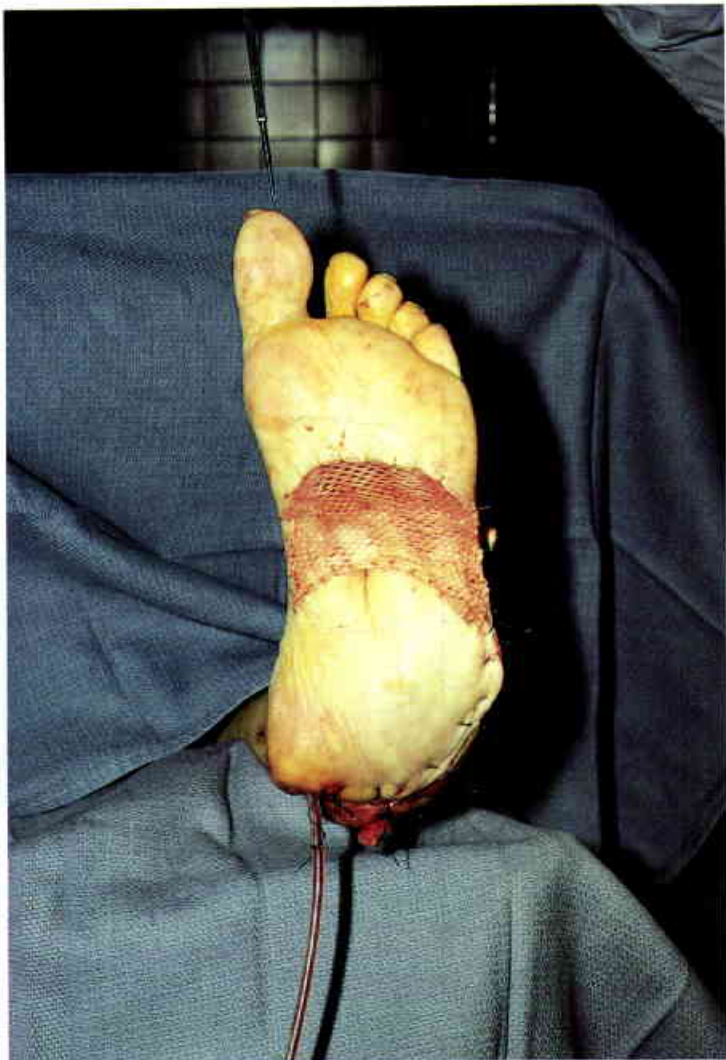
The "island" flap will reach the medial malleolus.



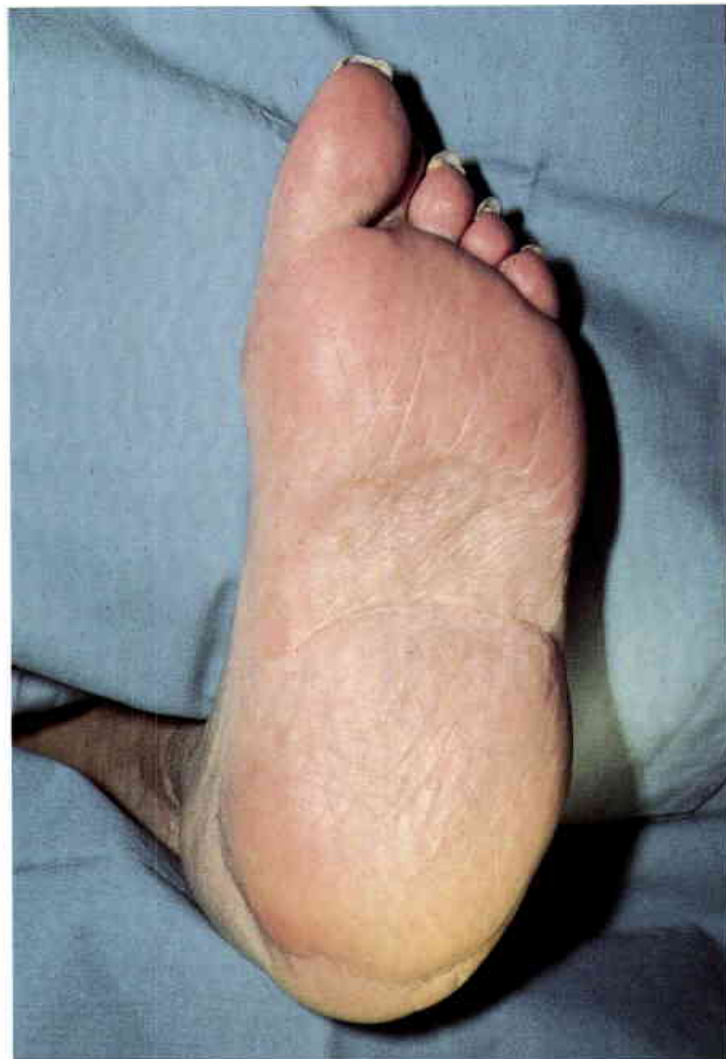
35
Fifty-nine-year-old paraplegic with a longstanding pressure sore of the heel. Outline of the medial plantar flap. (Case of P.G. Arnold)



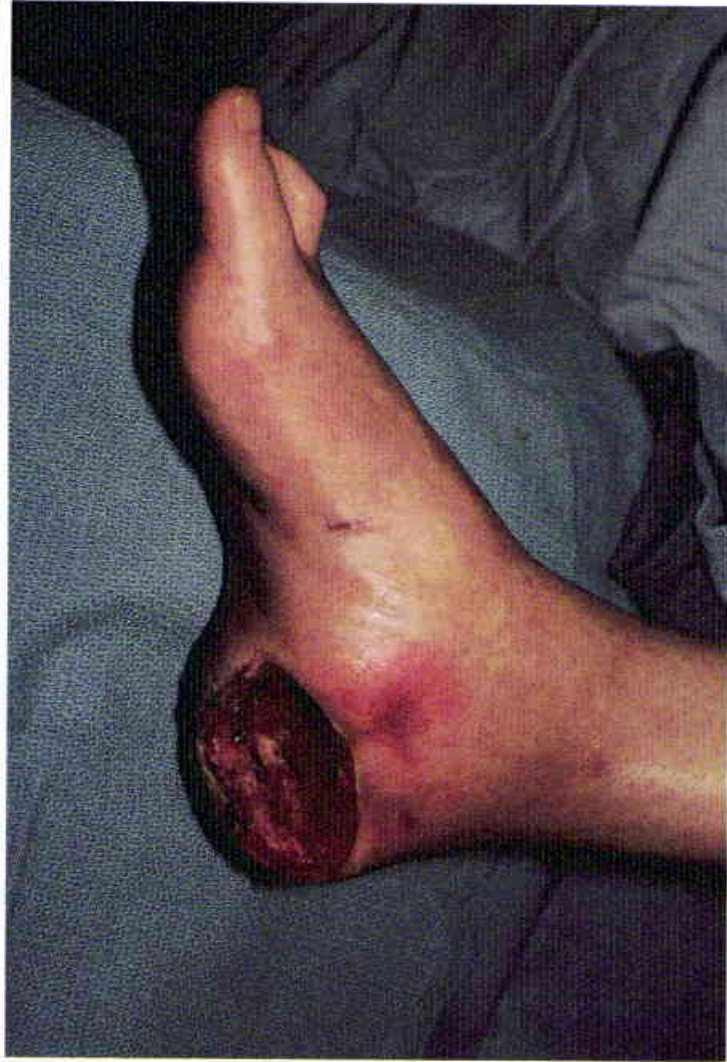36
The short flexor muscles were first rotated into the os calcis defect. The innervated medial plantar fasciocutaneous flap was used for the overlying surface coverage of the heel.

**37**

A meshed skin graft was used to cover the donor site. In an ambulatory patient more of the lateral weight-bearing surface of the foot would have been left in the in-step area, but this was not a consideration in this paraplegic patient.

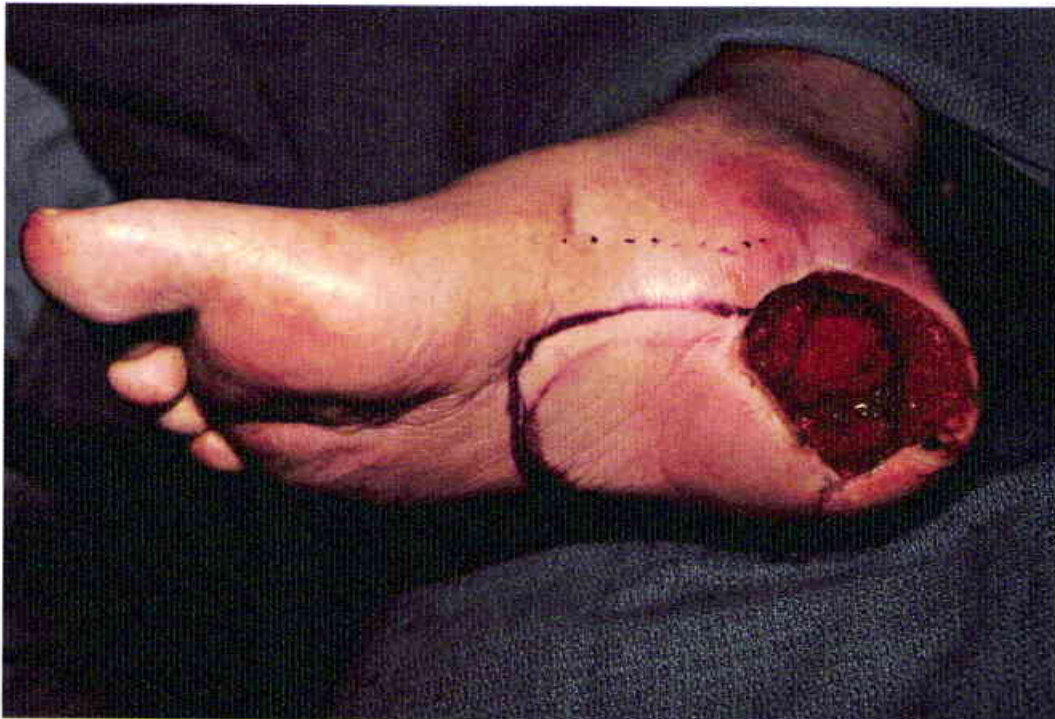**38**

Four months following the closure. The flap and the donor site skin graft have remained healed for six years.



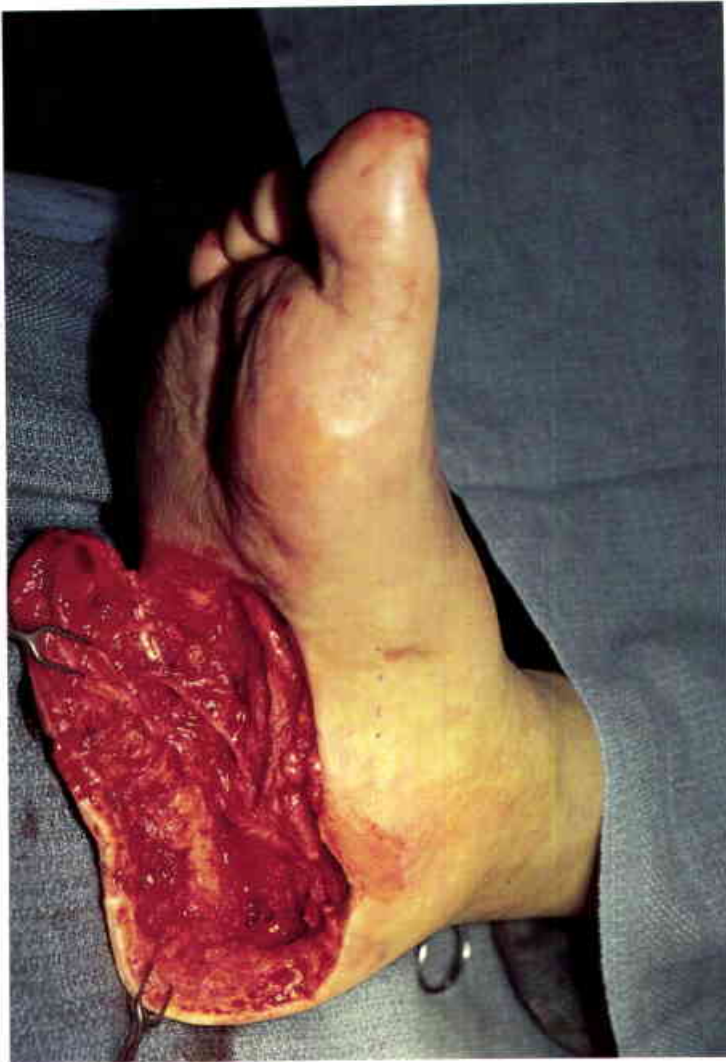39

Osteomyelitis of the os calcis in a sixty-two-year-old diabetic patient with extremely poor sensation in the sole of the foot. The patient had been hospitalized elsewhere for over seven months for this heel problem, and multiple skin grafts had failed. (Case of J.B. McCraw)



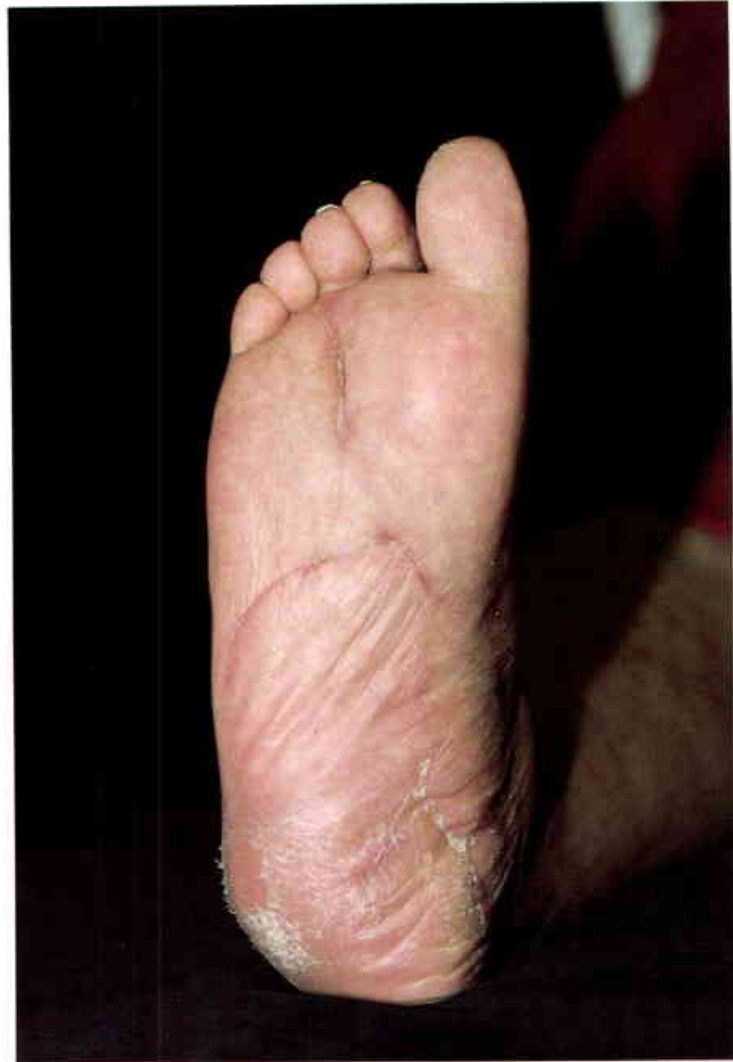40

Appearance after one debridement of the heel ulcer. A laterally based flap was chosen because of the medial location of the heel defect.



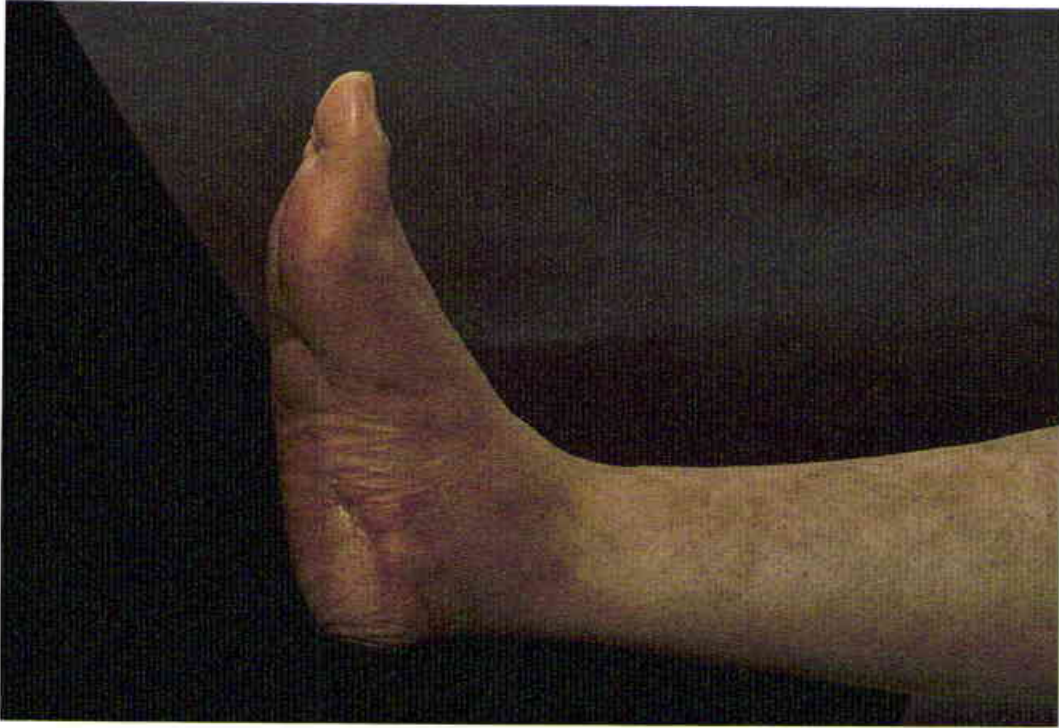41

The sole flap included the lateral plantar vessels and nerve, which are visible near the lateral aspect of the flap. It was necessary to excise approximately one-half of the os calcis in order to eradicate the osteomyelitis.



42

Primary wound closure was possible because of the extensive removal of the os calcis.



43

The lateral view demonstrates the reduced volume of the os calcis. The os calcis resection had no significant effect on ambulation with the use of special shoes. The osteomyelitis has not recurred during the six year follow-up period.

FOOT FLAPS

- Bennett, J.E. and Kahn, R.A. "Surgical management of soft tissue defects of the ankle-heel region." *J. of Trauma* 12(8): 696, 1971.
- Bostwick, J., III. "Reconstruction of the heel pad by muscle transposition and split skin graft." *Surg. Gynecol. Obstet.* 143(6): 973, 1976.
- Buncke, H.J., Jr. and Colen, L.B. "An island flap from the first web space of the foot to cover plantar ulcers." *Br. J. Plast. Surg.* 33: 242, 1980.
- Colen, L.B. and Buncke, H.J., Jr. "Neurovascular island flaps from the plantar vessels and nerves for foot reconstruction." *Ann. Plast. Surg.* (4): 327, 1984.
- Daniel, R.K. and Taylor, G.I. "Distant transfer of an island flap by microvascular anastomosis: a clinical technique." *Plast. Reconstr. Surg.* 52: 111, 1973.
- Drabyn, G.A. and Avedian L. "Ipsilateral buttock flap for coverage of a foot and ankle defect in a young child." *Plast. Reconstr. Surg.* 63: 422, 1979.
- Duncan, M.J., Zuker, R.M., and Manktelow, R.T. "Resurfacing weight bearing areas of the heel: The role of the dorsalis pedis innervated free tissue transfer." *J. Reconstr. Micro.* 1(3): 201, 1984.
- Ger, R. "Surgical management of ulcerative lesions of the leg." *Curr. Prob. Surg.* (3): 1, 1972.
- Ger, R. "The management of chronic ulcers of the dorsum of the foot by muscle transposition with free skin grafting." *Br. J. Plast. Surg.* 29: 199, 1976.
- Ger, R. "The surgical management of ulcers of the heel." *Surg. Gynecol. Obstet.* 140: 909, 1975.
- Grabb, W.C. and Argenta, L.C. "The lateral calcaneal artery skin flap (the lateral calcaneal artery, lesser saphenous vein, and sural nerve skin flap)." *Plast. Reconstr. Surg.* 68(5): 723, 1981.
- Gulyas, G., Mate, F., and Kartik, I. "A neurovascular island flap from the first web space of the foot to repair a defect over the heel: case report." *Br. J. Plast. Surg.* 37: 398, 1984.
- Harii, K. and Ohmori, K. "Free groin flaps in children." *Plast. Reconstr. Surg.* 55: 588, 1975.
- Harrison, D.H. and Morgan, B.D.G. "The instep island flap to resurface plantar defects." *Br. J. Plast. Surg.* 34: 315, 1981.
- Hartrampf, C.R., Jr., Schefflan, M., and Bostwick, J., III. "The flexor digitorum brevis muscle island pedicle flap: a new dimension in heel reconstruction." *Plast. Reconstr. Surg.* 66(2): 264, 1980.
- Holmes, J. and Rayner, C.R.W. "Lateral calcaneal artery island flaps." *Br. J. Plast. Surg.* 37: 402, 1984.
- Huber, J.F. "The arterial network supplying the dorsum of the foot." *Anat. Rec.* 80: 373, 1941.
- Ikuta, Y., Murakami, T., Yoshioka, K., and Tsuge, K. "Reconstruction of the heel pad by flexor digitorum brevis musculocutaneous flap transfer." *Plast. Reconstr. Surg.* 74(1): 86, 1984.
- Kaplan, I. "Neurovascular island flap in the treatment of trophic ulceration of the heel." *Br. J. Plast. Surg.* 22: 143, 1969.
- Leitner, D.W., Gordon, L., and Buncke, H.J. "The extensor digitorum brevis as a muscle island flap." *Plast. Reconstr. Surg.* 76(5): 77, 1985.
- Lichtblau, S. "Section of the abductor hallucis tendon for correction of metatarsus varus deformity." *Clin. Orthop.* (110): 227, 1975.
- Littler, J.W. "Neurovascular skin island transfer in reconstructive hand surgery." In *Transactions of the International Society of Plastic Surgeons*. Baltimore: Williams & Wilkins, 1960.
- MacLeod, A.M. and Robinson, D.W. "Reconstruction of defects involving the mandible and floor of mouth by free osteocutaneous flaps derived from the foot." *Br. J. Plast. Surg.* 35: 239, 1982.
- Maisels, D.O. "Repairs of the heel." *Br. J. Plast. Surg.* 117, 1961.
- May, J.W., Lakash, F.N., and Gallico, G.G. "Latissimus dorsi free muscle flap in lower extremity reconstruction." *Plast. Reconstr. Surg.* 68: 603, 1981.
- McCraw, J.B. "On the transfer of a free dorsalis pedis sensory flap to the hand." (Letter) *Plast. Reconstr. Surg.* 59: 738, 1977.
- McCraw, J.B. and Furlow, L.T., Jr. "The dorsalis pedis arterialized flap." *Plast. Reconstr. Surg.* 55(2): 177, 1975.
- Mitchell, G.P. "Abductor hallucis release in congenital metatarsus varus." *Int. Orthop.* 3(4): 229, 1980.
- Moberg, E. "Evaluation and management of nerve injuries in the hand." *Surg. Clin. North Am.* 44: 1019, 1964.
- Morain, W.D. "Island toe flaps in neurotrophic ulcers of the foot and ankle." *Ann. Plast. Surg.* 13(1): 1, 1984.
- Morrison, W.A., Crabb, D., O'Brien, B., and Jenkins, A. "The instep of the foot as a fasciocutaneous island and as a free flap for heel defects." *Plast. Reconstr. Surg.* 72(1): 56, 1983.
- O'Brien, B.M., et al. "Successful transfer of a large island flap from the groin to the foot by microvascular anastomosis." *Plast. Reconstr. Surg.* 52: 271, 1973.
- Panconi, B., Vidal, L., Bovet, J.L., et al. "The use of the medial plantar flap to cover heel defects." *Ann. Chir. Plast. Esth.* 30: 78, 1985.
- Reiffel, R.S. and McCarthy, J.G. "Coverage of heel and sole defects: a new subfascial arterialized flap." *Plast. Reconstr. Surg.* 66(2): 250, 1980.
- Schefflan, M., Nahai, F., and Hartrampf, C.R., Jr. "Surgical management of heel ulcers — a comprehensive approach." *Ann. Plast. Surg.* 7: 385, 1981.
- Shah, A. and Pandit, S. "Reconstruction of the heel with chronic ulceration with flexor digitorum brevis myocutaneous flap." *Lepr. Rev.* 56(1): 41, 1985.

FOOT FLAPS

- Shanahan, R.E. and Gingrass, R.P. "Medial plantar sensory flap for coverage of heel defects." *Plast. Reconstr. Surg.* 64(3): 295, 1979.
- Shubailat, G.F., Ajluni, N.J., and Kirresh, B.S. "Reconstruction of heel with ipsilateral tensor fascia lata myocutaneous flap." *Ann. Plast. Surg.* 4: 323, 1979.
- Shubailat, G.F., Ajluni, N.J., Shahateet, M.A. "Repair of a lower leg defect with an ipsilateral gracilis myocutaneous flap." *Plast. Reconstr. Surg.* 64: 560, 1979.
- Skef, Z., Ecker, H.A., Jr., and Graham, W.P., III. "Heel coverage by a plantar myocutaneous island pedicle flap." *J. Trauma* 23(6): 466, 1983.
- Snyder, G.B. and Edgerton, M.T. "The principle of the island neurovascular flap in the management of ulcerated anesthetic weightbearing areas of the lower extremity." *Plast. Reconstr. Surg.* 36: 518, 1965.
- Sommerlad, B.C. and McGrouther, D.A. "Resurfacing the sole: long-term follow-up and comparison of techniques." *Br. J. Plast. Surg.* 31: 107, 1978.
- Stark, R.B. "Blood supply of cross-leg pedicle flaps." *Plast. Reconstr. Surg.* 3: 694, 1948.
- Stark, R.B. "The cross-leg flap procedure." *Plast. Reconstr. Surg.* 9: 173, 1952.
- Taylor, G.A. and Hopson, W.L.G. "The cross-foot flap." *Plast. Reconstr. Surg.* 55(6): 677, 1975.
- Thatte, R.L. "One-stage random-pattern de-epithelialised 'turn over' flaps in the leg." *Br. J. Plast. Surg.* 35: 287, 1982.
- Thatte, R.L., Dhami, L.D., and Patil, U.A. "De-epithelialised turn-over flaps for 'salvage' operations." *Br. J. Plast. Surg.* 36: 178, 1983.
- Vann, H.M. "A note on the formation of the plantar arterial arch of the human foot." *Anat. Rec.* 85: 269, 1943.
- Vasconez, L.O., Bostwick, J., III, and McCraw, J.B. "Coverage of exposed bone by muscle transposition and skin grafting." *Plast. Reconstr. Surg.* 53(5): 526, 1974.
- Watson, J.S., Brough, M.D., and Orton, C. "Simultaneous coverage of both heels with one free flap." *Plast. Reconstr. Surg.* 269, 1979.
- Woltering, E.A., and co-workers. "Split-thickness skin grafting of the plantar surface of the foot after wide excision of neoplasms of the skin." *Surg. Gynecol. Obstet.* 149: 229, 1979.