

## THE ABDOMINAL WALL

# 11 Methods for abdominal surgery

## 11.1 Before a major operation

A patient is much more likely to withstand major surgery successfully if he is fit. So do all you can to get him into the best possible condition first. For example, if you find that he is anaemic, malnourished, or suffering with tuberculosis, and the operation is not urgent, correct these things before surgery.

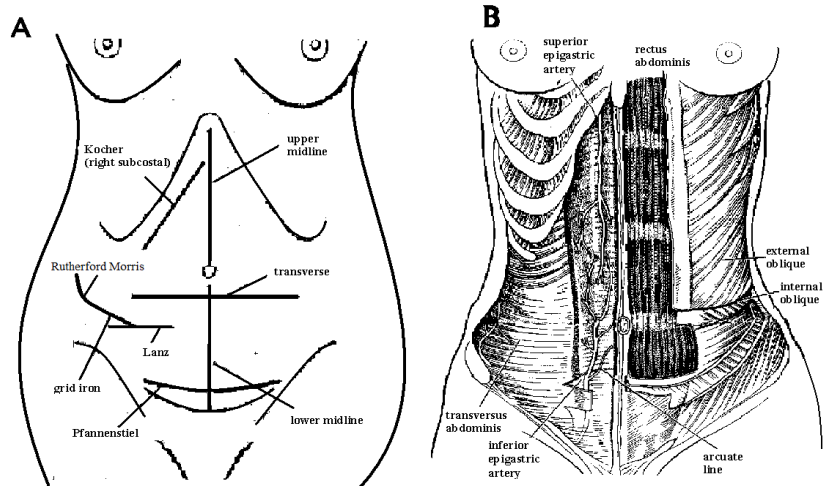
Severe malnutrition will greatly reduce his ability to withstand the operation. Above all, *do not operate on a patient who is dehydrated*; you must correct this.

Assess the need for surgery, the best time for it, and the risks it will involve. If a particular procedure risks being too much to cope with, ask yourself if there is a lesser alternative, or whether you could do something under LA, or what will happen if you do nothing? If there is a choice of procedures, do the simplest and safest thing, for example, colpotomy for a pelvic abscess rather than a laparotomy (10.3).

Consider whether you need to perform the operation straight away, or after fluid resuscitation, urgently but at a more convenient time, or electively. Consider the help you need: are the people you have available actually present? Are there other demands on your time: are these really important?

### Follow these rules:

- (1) *Do not start an operation without thinking it through step by step before you start.* If you are not familiar with the patient's case, make sure you go through the notes and review the indications for surgery carefully *yourself*.
- (2) Monitor a patient closely for 48hrs after any emergency or major operation.
- (3) Prevent aspiration of stomach contents, and treat respiratory depression immediately.
- (4) The most common postoperative complications are respiratory, and the answer to most of them is vigorous chest exercises (11.12).
- (5) Correct any dehydration and make sure enough IV fluids are infused peri-operatively to obtain a urine output of 1ml/kg/hr.
- (6) Discuss the case beforehand with your anaesthetist, mentioning possible hazards and blood loss.
- (7) The operation may be routine to you, but it is sure to be a major event in the patient's life, so try to establish a good relationship with him and his family. Tell him why you are operating, and explain what to expect afterwards, particularly how much pain he will have, and when he will recover.



**Fig. 11-1 THE ANTERIOR ABDOMINAL WALL.**

**A, Abdominal incisions.** After Kirk RM, Williamson RCN, *General Surgical Operations*, Churchill Livingstone 1987 p.42, Fig.4.1.2. **B, Anatomy of the anterior abdominal wall.** N.B. Below the arcuate line, the posterior rectus sheath is absent. After Maingot R, *Abdominal Operations*, HK Lewis 4<sup>th</sup> ed 1961 Fig. 1, with kind permission.

For example, if you might have to remove a testis or make a colostomy, discuss this before you operate. Further, if you promise to close a colostomy eventually, be sure to do so.

## PREOPERATIVE PREPARATION

**HISTORY AND EXAMINATION.** What previous illnesses has the patient had? Is he taking any medicines? Is he allergic to anything, particularly to streptomycin, sulphonamides, penicillin, or chloroquine?

Assess the degree of wasting. Ask about a cough, fever, chest pain, dyspnoea, and smoking. How fit is he? Can he climb hills, or do a day's work in the fields? Can he step up and down off a chair for half a minute without becoming short of breath? Or, can he hold his breath for 20secs? Can he get out of bed independently on one side, walk round the bed, and get in again on the other side? (This tests co-ordination, mental faculties, as well as cardiac output!) Look for signs of anaemia. Feel the strength of his grip (this is a good predictor of surgical risk in men, less so in women).

**ASK ABOUT TUBAL LIGATION.** *Always* remember to ask any pre-menopausal lady over 30yrs who has had 2 or more children if she is interested in having a simultaneous tubal ligation. Most women either forget or are too afraid to ask but always regret not having done so. If the lady is agreeable, remember to add the procedure to the consent form *and* the operation list!

**SPECIAL TESTS.** Measure the Hb or haematocrit. If sickle-cell disease is common in your area, test for this routinely. Test the urine for albumin and sugar, and examine its deposit. This will exclude any serious disease of the urinary tract, and help you to diagnose renal colic, which may present as an acute abdomen. Test the blood group, and if necessary cross-match blood. Remember to test for HIV. If you suspect heart or lung disease, obtain a chest radiograph and/or ultrasound scan.

**ASSOCIATED DISEASE.** If necessary, and if time allows, try to improve the patient's general health, especially his nutrition and hydration. Look for tuberculosis, chronic renal disease, and signs of HIV disease.

**If the patient is dehydrated,** make sure you provide enough fluid (usually IV) so that he has a good urine output.

**If the patient is malnourished,** especially if he is a child, and the disease permits, feed him by mouth or by nasogastric tube, even for as short a period as 2wks before you operate. If he is anorexic, feeding him will be difficult, so try nasogastric feeding (11.10).

**If there is pyrexia,** consider the possibility of malaria, HIV or typhoid fever, in addition to the possible surgical causes of fever.

**If there is anaemia,** consider the urgency of the operation in relation to the severity of the anaemia. Most 'routine' operations can be done with a Hb as low as 8g/dl. If it is 6-7g/dl, only do urgent procedures. For example, you can transfuse a woman with a Hb of 3g/dl who is bleeding slowly from an ectopic pregnancy overnight with 20ml/kg of blood from her abdominal cavity (5.3), if necessary adding 1mg/kg of furosemide. If an operation is less urgent, for example a hysterectomy for chronic anaemia due to fibroids, treat with iron sulphate for 4-6wks. For non-urgent surgery where you expect bleeding, you can take a unit of blood 4wks and 2wks before a planned major operation, and store the blood.

**If there is jaundice,** it will greatly increase the risks of surgery, but not operating may worsen liver failure. Treat with vitamin K 10mg IM od and repeat this if the jaundice is severe. Exclude hepatitis and malaria first, especially in the acute stage, when anaesthesia can be dangerous.

**If there is much purulent sputum brought up,** arrange chest physiotherapy and a course of antibiotics prior to surgery, if possible. Use appropriate anaesthesia, using LA or regional blocks where possible. If there is a common cold, cancel anything but an emergency operation.

**If the patient is diabetic,** check the glucose level. If the diabetes is out of control, start a 'sliding scale' régime of soluble insulin IV qid, with the total adjusted according to the total dose, if any, of insulin being taken. If oral hypoglycaemics are being used, omit these on the day of surgery. If insulin is taken bd, reduce the preoperative evening dose by 20%; omit the insulin on the morning of operation and start a 5% Dextrose IV infusion. Check the glucose again just before operation and try to operate on him first on the list.

**CHEST PHYSIOTHERAPY** before and after the operation will reduce the risk of lung complications (11.11,12), especially for the bronchitic, the smoker and the elderly.

**SKIN PREPARATION.** If the skin is very dirty, wash the operation site several times. If there are pustules, boils, or eczematous patches near the site of your proposed incision, treat them before you operate. Bacteria from them may infect the wound, so if you must operate urgently, use delayed primary closure (11.8).

**NASOGASTRIC SUCTION.** Insert a nasogastric tube (4.9) before all stomach or bowel operations, and in emergencies if you do not know when the patient last ate or drank. The danger of aspiration pneumonitis is even greater if there is intestinal obstruction or ileus.

It is especially present when the patient is relaxed before intubation. Aspirate the stomach contents before you go to theatre. The risks of aspiration are greater if the patient is lying down or sedated. Get an assist to apply cricoid pressure before and during intubation; aspirate the stomach contents from time to time during the operation.

**URINARY CATHETERIZATION.** Insert a catheter into the bladder for pelvic and long operations, where monitoring of the urine output during the operation is helpful, or in an elderly man with a large prostate where you fear urinary retention post-operatively.

*Do not insert a catheter routinely!*

**PERIOPERATIVE ANTIBIOTICS** may be lifesaving (2.9); *distinguish between prophylactic and therapeutic use!*

**DO NOT OPERATE ON A  
SEVERELY DEHYDRATED PATIENT:**

**RESUSCITATE TILL YOU OBTAIN  
YELLOW COLOURED URINE.**

## 11.2 Laparotomy

A laparotomy for an acute abdomen will be a major test of your surgical skill. It will be important to know what to do when you open the abdomen; if you are not sure, be humble enough to have this book in theatre to help you. Try to make a correct diagnosis before you start, *but do not delay just because you are not certain what you will find.* Before you start, get a proper consent and discuss the operation with the patient and his family, and if he is to have drainage tubes or a colostomy for example, make sure they understand what they entail.

*N.B.* In some societies the presence of a drain or colostomy may appear to indicate imminent death, *so take time to explain details such as these carefully.*

Try to avoid complications by making an appropriate incision, handling tissues carefully, and closing accurately. Make an incision which is big enough; a common mistake is to make it too short. Incisions heal from side-to-side, not from end-to-end, *so do not be afraid of making a long incision.*

### If an incision is too small:

- (1) *you will not be able to dissect safely*, and
- (2) *your assistant will have to exert excessive traction on its edges*, which will kill tissue, and increase the risk of wound sepsis and breakdown.

### Which incision?

The ideal incision is one which gives adequate exposure, is quick to make, easy to close, and provides a secure cosmetically acceptable abdominal wall afterwards. So, *avoid an incision in the wrong place!*

If possible, make a transverse incision in children <12yrs because it heals better, and gives less respiratory problems. The transverse incision also heals better in adults, and is less likely to develop hernias than the midline, but you need to be careful with good haemostasis.

In an adult a midline incision will enable you to get access to everything in the abdomen. You can start with the middle part to begin with, and extend it from the xiphisternum to the pubis, if necessary. If exposure is particularly difficult, you can extend the incision laterally to make a 'T' incision. Many patients prefer an incision going straight through the umbilicus rather than going round it: ask them.

A midline incision above the umbilicus is quick, simple, and bloodless. But access to the organs at the sides of the abdomen is not easy. Even so, midline incisions are usually best for trauma, for Caesarean Sections where you are not familiar with a Pfannenstiel incision or other pathology is expected, and almost everything else. If you are planning a purely exploratory laparotomy, and do not know what you are going to find, make a midline incision in the correct half of the abdomen, upper or lower.

**If you are reopening the abdomen**, cut out the old skin incision. Extend it so that you can enter the abdominal cavity above or below where any adhesions to the under surface of the abdominal wall are less likely. Work your way up or down carefully, dividing any adhesions you find, so as not to injure any adherent bowel. *Do not make a 2<sup>nd</sup> incision parallel to an earlier one or crossing an earlier one at an acute angle*, because the skin in between will have no sensation and may become ischaemic.

**A McBurney (grid-iron) or Lanz incision** gives good but limited access to the appendix: only use it if you are sure of the diagnosis of appendicitis with local inflammation alone.

**A Kocher (right subcostal) incision** gives good access to the gallbladder, but not much else. A left subcostal incision gives good access to the spleen, and may be extended as a chevron (gable) on the opposite side.

**A lower oblique (Rutherford-Morrison) incision** is good for the ureters and ascending (right) and descending (left) colon.

**A Pfannenstiel incision** is ideal for gynaecological and prostate operations and **a left thoraco-abdominal incision** ideal for operations on the gastro-oesophageal junction.

*N.B. A paramedian incision* (parallel but 2-3cm lateral to the midline) *does not have any benefit over a midline incision*, and is more bloody and difficult to do properly.

**CAUTION!** If you are in doubt, make the 'incision of indecision' in the midline 5cm above and 5cm below the umbilicus. Enter the abdomen and then extend it in the most useful direction.

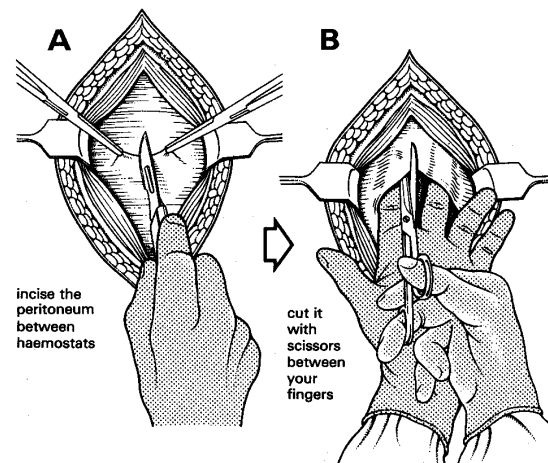
**When you get inside**, you will have to decide what to do. Here, only experience can tell you what is normal and what is not. For example, some *ascaris* worms inside a child's bowel may feel so abnormal as to convince you that they must be the cause of the symptoms, when in fact they are normal for the community.

**Be gentle**, bowel is highly sensitive. If you handle it roughly, especially if it is obstructed, ileus will follow as sure as night follows day. Bowel does not like being frequently drawn out of a wound. So, if you need to draw it out, do so only once, and hold it with a moist swab. While it rests on the abdominal wall, keep it covered with warm moist packs or towels, or place it in a large sterile plastic bag. If it is grossly distended, even the most gentle handling may burst it, so decompress it (12-6).

Break down adhesions gently (12-8).

*N.B. Remember, in an emergency, do what has to be done as efficiently as you can: do not be tempted to do unnecessary things!* It is often best to wait 48hrs to stabilize a patient and return when the condition has improved.

## ENTERING THE PERITONEAL CAVITY



**Fig. 11-2 ENTERING THE PERITONEAL CAVITY.**

**A**, incise the skin and divide the anterior rectus sheath. The posterior rectus sheath and peritoneum form a single layer. Pick this up with a haemostat, and then apply another one 5mm from it. With the peritoneum still tented up, make a small incision between the 2 haemostats. Air will enter the peritoneal cavity, and the viscera will fall away. **B**, put your fingers into the incision to make sure that there are no adhesions to the undersurface of the abdominal wall, and then extend the incision with scissors.

## LAPAROTOMY (GRADE 3.1)

**RESUSCITATION.** Make sure that there is a functioning infusion with a large cannula. You can infuse approximately 85ml/min through a 18G cannula, but >200ml/min through a 14G. Make sure the IV line is secure and not kinked: you may have to splint the arm on an armboard. If significant bleeding is possible, have blood cross-matched and a 2<sup>nd</sup> IV cannula in place

**RADIOGRAPHS.** A chest radiograph is most useful; have the films available in theatre. Make this hospital routine.

### ANAESTHESIA.

(1) GA, preferably with relaxants, is the norm. Ketamine 1mg/kg IV is very useful if the blood pressure is low. *Do not induce anaesthesia with thiopentone in a shocked patient:* the blood pressure may crash!

(2) Subarachnoid (spinal) or epidural anaesthesia is useful for the lower abdomen, but requires good hydration and a fluid pre-load IV.

(3) LA may be safer in a gravely ill patient: mix 10ml of 2% lidocaine with 40ml of saline to give 50ml of 0.4% solution. To this add 0.5ml of adrenaline 1:1000. Inject 1ml of this solution into each of five sites in the rectus muscle on either side of the midline to block the segmental nerves. Use another 20ml to infiltrate the midline. Use the remaining 20ml to infiltrate the root of the mesentery if you need to resect the bowel and top up infiltrations as required.

**If you have to perform a more extensive procedure,** use ketamine rather than struggling to work with LA alone, and if the patient is critical, do the minimum necessary (10.1). *N.B. Unconscious patients often need no GA at all!*

**POSITION.** For most abdominal operations, lie the patient supine with the bare buttock or thigh in contact with the diathermy pad (if you have one).

**If your table does not tilt from side to side,** and you want to turn the patient to one side, place pillows under his back on each side, or use a wedge block under the mattress.

**If you are operating on the pelvic organs,** you will find the Trendelenburg (head-down) position helpful. It will allow the bowel to fall towards the diaphragm, so that you get a better view into the pelvis. You will need well-padded shoulder rests to prevent the patient sliding downwards. *Do not tip the patient too steeply,* or the pressure on the diaphragm will impair his breathing. If he is in >10° of Trendelenburg, you must intubate him, keep him on relaxants, and control his ventilation.

**If you need access to the rectum or pelvic organs,** put the legs up on lithotomy poles or on Lloyd-Davies stirrups.

Use one arm for a blood pressure cuff and the other for an IV line, unless you need 2 IV lines. Keep the hands by the side, or out on arm boards, or folded on the chest with suitable ties; *do not place them under the buttocks or under the head.*

### EXAMINATION.

Once anaesthetized and relaxed, feel the abdomen carefully. You may feel a mass which you could not feel before because of guarding

### PREPARATION.

Shave the abdomen (2.3). Make sure the operation light is correctly positioned and directed. Drape the abdomen and fix the drapes with towel clips. Cover these with a large windowed sheet, and add additional sterile towels as necessary. Make sure you have suction and diathermy connected, clipped to the drapes, switched on, and tested, with a foot pedal within reach.

## A MIDLINE INCISION

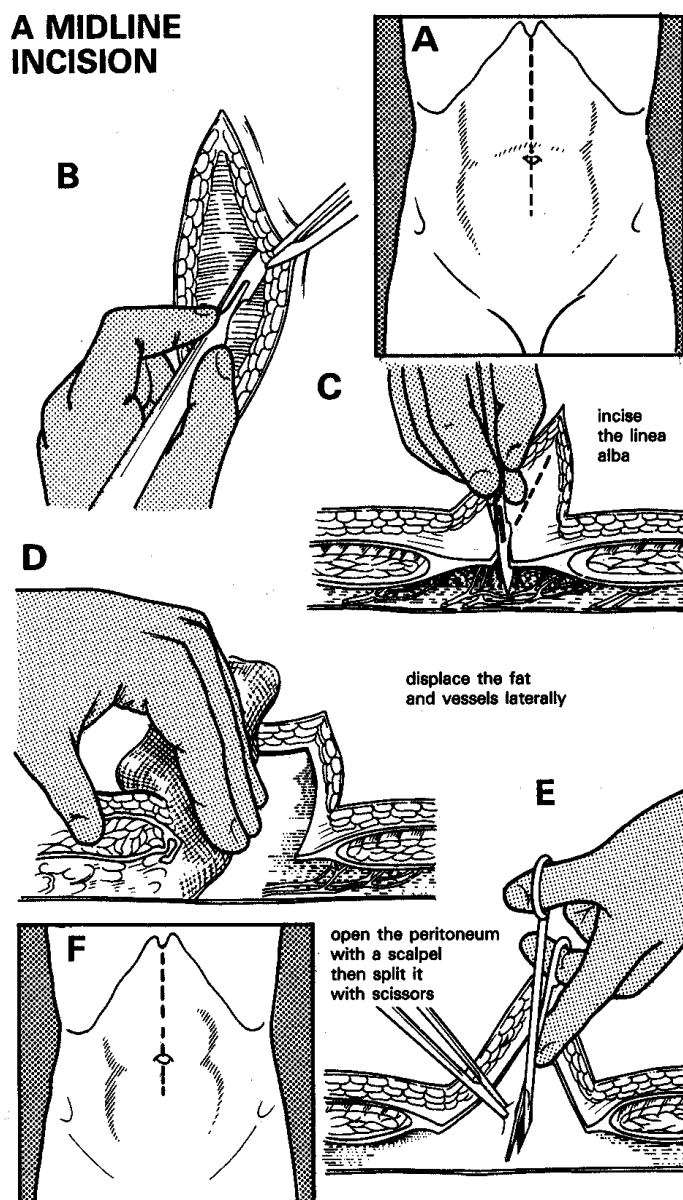


Fig. 11-3 MIDLINE INCISION.

A, the site. B, cut down to the *linea alba*, and then carefully dissect the fat for 1cm on either side, using the flat of the knife. C, incise the *linea alba* to expose the underlying fat and peritoneum. D, displace the fat and vessels laterally by blunt gauze dissection. E, pick up the peritoneum, incise it with a knife and divide it with blunt-ended scissors. F, if you want to continue the incision downwards, there is no need to go round the umbilicus.

After Rob C. *Operative Surgery: the Abdomen*. Butterworth, 1977  
Permission requested.

### UPPER MIDLINE INCISION.

Use the xiphoid and umbilicus as landmarks, keep strictly to the midline, and *do not cut into the rectus muscle on either side*. Cut down to the *linea alba* and cut through it gently to expose the extraperitoneal fat. Pick up the *linea alba* with straight forceps, and cut gently with the knife in the midline till you see the posterior rectus sheath and peritoneum. Lift this up with 2 straight forceps, feel it with your fingers, making sure you have not also picked up underlying bowel. It is a good idea to release one of the forceps, and re-apply them to let anything caught the first time slip away. Cut into the peritoneum with the knife (11-2A) and so allow air to enter the peritoneal cavity; the viscera will then fall away, allowing you to put in 2 fingers to check if there are any adherent underlying structures, tent up the peritoneum and divide it with blunt-ended scissors (11-2B).

*N.B. You can easily open bowel by mistake if:*

- (1) it is obstructed,
- (2) it has stuck to the scar from a previous operation,
- (3) you are hasty or rough,
- (4) you use diathermy to open the abdomen.

*N.B. Do not use the paramedian incision: it has no real advantages.*

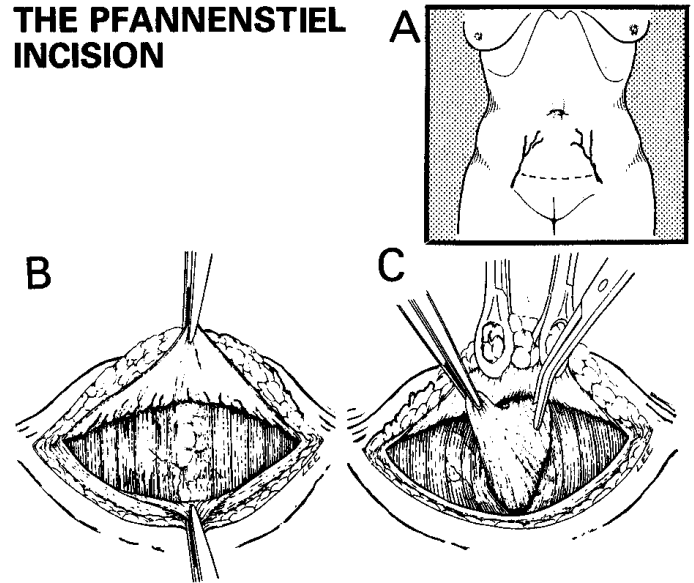
**LONG MIDLINE INCISION.** Do not hesitate to open the abdomen from top to bottom *e.g.* for advanced generalized peritonitis (10.1). You can go straight through the umbilicus: it leaves a neater scar than going round it, but remember to clean it thoroughly beforehand. You can also get a little more length by incising between the xiphisternum and the costal cartilage.

**LOWER MIDLINE INCISION.** Make this in a similar way to the upper midline incision. If you cannot see exactly where the midline is between the *rectus* muscles, split them apart gently. Make sure you use haemostats or diathermy on bleeding vessels. You will see the *pyramidalis* muscle at the lower end of the wound. Note that below the umbilicus, in the lower  $\frac{2}{3}$  of the midline, below the arcuate line, the peritoneum is attached only to *transversalis fascia*.

**TRANSVERSE INCISION.** Make a cut 3cm above or below the umbilicus and cut through the anterior rectus sheath, and underlying muscle; you should have diathermy available to control bleeding from vessels in the muscle layer. Then go through the posterior rectus sheath and open the peritoneum. You can extend the incision in a curve upwards laterally, if you need access to the spleen or liver.

**PFANNENSTIEL INCISION.** Make a slightly curved transverse incision 2cm above the *symphysis pubis*. Cut through the anterior rectus sheath and hold upper and lower flaps with straight forceps. Gently lift this sheath off the underlying *rectus* muscle, and split this longitudinally to expose the peritoneum in the midline.

### THE PFANNENSTIEL INCISION



**Fig. 11-4 THE PFANNENSTIEL INCISION.**

**A, incision:** the inferior epigastric arteries lie at the ends of the incision on the deep surface of the rectus muscles. **B, reflect** the anterior layer of the rectus sheath. **C, part the rectus muscles; prepare to enter the abdomen.**

*After Dudley HAF (ed), Hamilton Bailey's Emergency Surgery, Wright, 11<sup>th</sup> ed 1986 p.446 Fig 42.1 with kind permission.*

### GET ADEQUATE EXPOSURE AND A GOOD LIGHT.

*You cannot do good work if loops of bowel are always getting in the way, or if the light is bad, so adjust it as best you can.* Sterilizeable light handles are very useful; otherwise make sure someone else in the theatre knows how to move and direct the light. Alternatively use a head-light. Get one or two assistants to help you.

*Make an adequate incision.* If necessary, extend it or close it (*e.g.* if you find a Lanz incision for appendicectomy inadequate) and make a good midline incision. If you are working on a lateral organ through the midline, make a long incision. Or, make a lateral T-shaped extension.

Get good retraction. A self-retaining retractor may not be enough by itself. Use Deaver's retractor, or any large right-angled retractor, and make sure your assistant knows what you want him to do with it. *Do not become cross with him when the position of the retractor slips if he cannot see properly!*

Get the patient into the best position. You will never get adequate exposure in the pelvis unless the body is tilted in the Trendelenburg position. Similarly, if you are working on the upper abdomen (as when exposing the oesophagus), tilt the head up a little. Extending the back by breaking the table or by putting a pillow under the back will also help. If you want to draw the splenic flexure and small bowel towards you, consider rolling the patient to the right, either by tilting the table or by using sandbags, or a wooden wedge under the mattress. If you are operating on the kidney, a kidney bridge or folded plastic-covered pillows will bring it forwards.

**DON'T MAKE THE INCISION TOO SHORT:  
ALWAYS BE READY TO EXTEND IT!**

**If loops of small bowel (or anything else) get in your way,** pack them away. This may save you much time, but *do not forget to remove the packs afterwards!* Anchor each pack by its tape or corner to a large haemostat hanging outside the abdomen.

Make sure the scrub nurse checks and counts the packs and instruments *with you* at the end of the operation. *Avoid leaving loops of bowel hanging outside the abdomen exposed, especially under hot theatre lights:* they easily get desiccated and the weight of bowel contents may impair its mesenteric blood supply. Keep the bowel covered with warm wet packs.

**FOLLOW A ROUTINE.** Take note of the smell, look at the fluid, gently divide adhesions, minimize the risk of sepsis, decompress the bowel, and make a thorough examination of the abdomen (10.1). How extensively you do this will vary. Limit your exploration to what is easily practicable if:

- (1) there is localized sepsis and you aim to limit its spread to the rest of the abdomen,
- 2) there is an inoperable carcinoma, or
- (3) you are operating on a known problem.

However, even then it is good practice to take the opportunity to make a full examination. *Decide carefully though if the bowel is very stuck together whether you will do more harm than good by separating all the adhesions* (10.1).

Explore the abdomen in an orderly way: look at the diaphragm, liver, intra-abdominal oesophagus, spleen, stomach, duodenum, gall-bladder, and then the whole small bowel. Draw each loop out of the wound, looking at both sides, and at the mesentery. If the bowel is distended, trace it distally to find the cause. Look at the large bowel from caecum to rectum. Feel the major vessels and kidneys, look at the appendix, ureters, bladder, uterus, Fallopian tubes, and ovaries. Finally look at the hernial orifices from inside. If necessary, look into the lesser sac through the greater omentum; or behind the duodenum by 'kocherizing' it (13.3); or at the oesophageal hiatus by dividing the attachments of the left lobe of the liver to the diaphragm.

*Do not forget to record your findings: even negative ones, which can be most helpful later.*

**THE SPECIMEN.** If you have removed tissues from the patient and want to examine them, hand them to someone else. Ask him to open them away from the patient who will then not be contaminated by infection or malignancy.

#### DIFFICULTIES WITH A LAPAROTOMY

**If you cannot do an operation through one incision,** make another. Keep your original one open until you have finished: it may be useful!

**BLEEDING** can be difficult. You must know how to:

- (1) tie vessels in the depth of a wound (3.2),
- (2) place ties, without letting go of the thread (3.2),
- (3) use curved and angled forceps,
- (4) secure temporary tape control over major vessels.

**If a surface is merely oozing,** consider applying haemostatic gauze (3.1).

**If the bleeding is annoying, rather than brisk,** you may be able to suck it away while you go on working.

**If you have diathermy,** consider applying it to the bleeding point with a fine-tipped dissecting forceps. You should do this with pin-point accuracy.

#### **If there is a constant ooze during the operation:**

- (1) There may be an excess of citrate after transfusion of many units of blood. This will not happen if you add 10ml of 10% calcium gluconate after every 4<sup>th</sup> unit (500ml) of blood.
- (2) There may be disseminated intravascular coagulation (DIC), or some other clotting defect. If possible transfuse at least 2 units of fresh blood to replace clotting factors. Check the blood clotting time.

**If bleeding becomes unmanageable, do not panic:** apply pressure, then packing. Either ligate or repair a major vessel (3.1,2)

#### **CAUTION!**

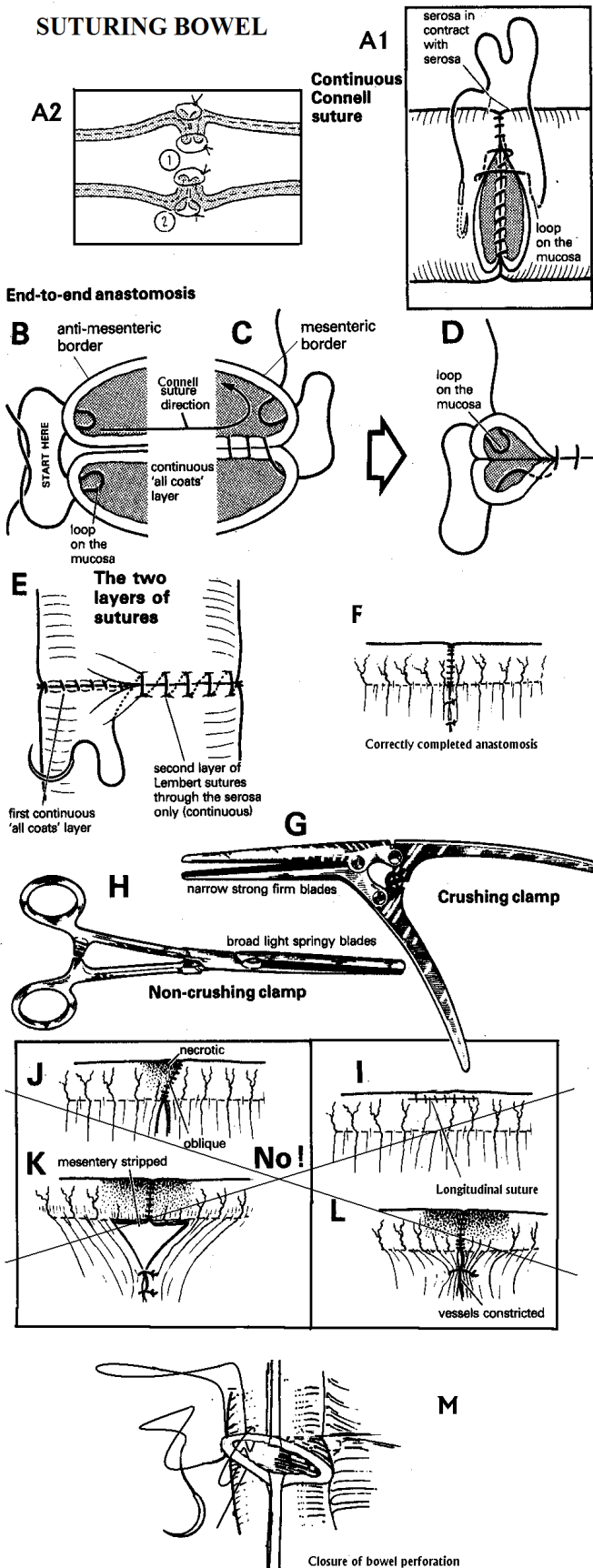
- (1) *Do not stab blindly with a haemostat in a pool of blood!*
- (2) Similarly, *do not apply diathermy through a pool of blood:* it won't work!

**If you accidentally perforate a loop of bowel, do not try to stop the leak of bowel contents with gauze.** Pinch it closed between your fingers while someone gently places non-crushing clamps proximally and distally. Suction any spillage. Surround the injured loop with packs to prevent the contents of the bowel flooding into the peritoneal cavity. Repair the perforation (14.3); if there are  $\geq 2$  perforations near each other, it is best to sacrifice a segment of bowel and make one anastomosis (11.3) rather than attempt to repair several holes.

**If you open the pleura by mistake,** there is a danger that the lung may collapse and cause marked hypoxia, because only one lung is being ventilated, and also because blood is passing through the collapsed lung unaltered. If the patient is not intubated, stop operating to make it easier for the anaesthetist to pass a cuffed tracheal tube using suxamethonium. Intubation is not essential, but chest drainage usually is. To do this you may have to move the patient. As soon as the tube has been inserted, close the hole in the pleura with a continuous multifilament suture. As you insert the last suture ask the anaesthetist to blow up the lung so that it almost touches the pleura. At the end of the operation insert an intercostal water seal drain (36.1) and leave it in place for at least 48hrs. Obtain a chest radiograph, and once the lung is fully expanded, remove the drain, usually at 2-5 days.



## SUTURING BOWEL



### 11.3 Resecting & anastomosing bowel: end-to-end anastomosis

A laparotomy will often mean resecting bowel. This is one of the most critical procedures you will have to undertake, and if you are inexperienced, one which will give you much anxiety. It is one of the few surgical methods which you can usefully practise before you operate on a living human patient. So go to the butcher's, get some animal bowel, and practise anastomosing that. The penalty for failure in the patient will be peritonitis or a fistula.

You will usually anastomose bowel end-to-end, but there will be occasions when you will have to do it end-to-side, (as in a Roux loop) or side-to-side (as in a gastro-enterostomy, or cholecysto-jejunostomy)

*Do not be worried by the complexity of the methods which follow.* The really important points are to:

- (1) Make sure that you start with 2 nice viable pink bleeding ends.
- (2) Empty the bowel as best you can.
- (3) Get their serosal surfaces together. If you do this, they will soon unite. If you bring only the mucosal surfaces together there will be no strength in the join and a leak is likely.
- (4) Close the bowel in 2 layers using round-bodied needles. If you rely only on one layer, you need to be extremely neat and accurate. Beware of mucosa pouting out after the first layer; it can easily do this at the mesenteric border. *Everted mucosa leaks*. So if it does evert as a 'dog ear', push the 'ear' back and close it over with the serosal layer.
- (5) Do the suturing outside the abdominal cavity on a towel, or pack away the rest of the abdominal contents. Contamination will then be less likely and clamps less important.
- (6) Wash the bowel with warm fluid after you have done the anastomosis.
- (7) Gently squeeze the bowel on either side to test the anastomosis for leaks.

Fig. 11-5 SUTURING BOWEL.

A1, suture bowel with continuous Connell sutures, showing the principle of 'the loop on the mucosa' inverting the bowel. A2, anastomose bowel end-to-end with 2 layers of sutures: an 'all coats' layer & a layer of Lembert sutures through the serosa only. B, method of anastomosing bowel end-to-end (11-7) using Connell sutures. This starts on the ante-mesenteric border to the mesenteric border C, where it turns round to close the anterior layer the bowel and D meets the beginning of the suture again back at the antimesenteric border. E, 2 layers of sutures: the 1<sup>st</sup> continuous absorbable 'all coats' layer & the 2<sup>nd</sup> continuous serosal or Lembert layer. F, anastomosis correctly done. G, Payr's crushing clamp, with firm, narrow blades. H, Lane's non-crushing clamp with springy, broad blades.

*N.B. Pitfalls:* I, bowel closed longitudinally (which will result in stricture formation). J, bowel cut obliquely in a way which reduces the blood supply to an area on the ante-mesenteric border of one loop. K, bowel partly deprived of its mesentery, and thus of its blood supply. L, mesentery bunched together with a suture which occludes the vessels supplying the bowel. M, closing a bowel perforation, starting at one corner with a Connell suture.

If you follow the 7 points above you won't go far wrong. Note that any sutures which go right through the wall of the bowel (and so might leak) are usually infolded by a 2<sup>nd</sup> layer of sutures which go through serosa and muscle only; these are called Lembert sutures. Put the first layer through all its coats: this is the 'all-coats' layer. Make the Lembert sutures of the 2<sup>nd</sup> layer bring the serosa of one loop into contact with the serosa of the other loop. Only put them through the outside peritoneal layer, the muscle, and the submucosa (the strongest layer of the bowel), and do not go through the mucosa into the lumen of either loop.

Use a continuous suture: it is easier, cheaper, and probably more reliable than using interrupted sutures, even with large bowel. *Avoid catgut*: it dissolves just when the bowel is healing, and so needs a 2<sup>nd</sup> layer of sutures for protection. If your stocks are limited, preserve some longer lasting absorbable sutures (e.g. polyglycolic acid) specially for bowel (4.6). *Avoid cutting V-shaped needles on bowel* as these can produce a leak.

You will need to hold the bowel with stay sutures, Babcock forceps (4.4) or clamps while you work on it. It is also desirable to hold it shut so that its contents do not leak out. Clamps do this best but you can use a cloth tape. There are 2 kinds of clamp: non-crushing ones and crushing ones.

*Non-crushing clamps*, such as Lane's or Kocher's have thin, wide, flexible blades, and a ratchet with several teeth, so that you can adjust the way you close them to the thickness of the bowel. Use non-crushing clamps to hold bowel without injuring it; hold them between your fingers and 'milk' the bowel contents away from the area you are working on. Apply only as many 'clicks of the ratchet' as you need to stop the contents of the bowel from escaping, and blood from flowing from the cut ends. You can use Bulldog vascular clamps for baby bowel.

*Crushing clamps* have narrower, stiffer blades, a ratchet with fewer teeth, and sometimes interlocking ridges on the blades to grip the bowel more firmly. Crushing clamps prevent leaking completely. 'Milk' the contents of the bowel away from the area to be crushed, and then apply a crushing clamp with its jaws protruding well beyond the edge of the bowel, because bowel widens as you crush it. Close the jaws tightly. Crushed bowel dies, so *cut the crushed bowel away with the clamp before making an anastomosis*. Cut the bowel strictly transversely, *not obliquely* (11-5J). As you do this, be sure there is a non-crushing clamp applied to stop the contents of the bowel spilling out. Crushing clamps are thus always used in conjunction with non-crushing ones.

You will often have to operate on bowel when it is distended and full of intestinal content: this fluid has millions of bacteria, particularly anaerobes. Spillage into the peritoneal cavity will cause septicaemia very quickly because the peritoneal layer is such a good absorptive surface. So, in this situation, you will have to use clamps; however, if you then join bowel which is full of intestinal fluid, this will all have to pass the anastomosis! The chance of leakage is then high.

*Avoid this disaster by emptying the bowel* every time you make an anastomosis. You will need to make sure that the bowel reaches outside the abdomen, and emptying it does not contaminate the peritoneal cavity, the very thing you want to avoid! Therefore before you empty the bowel, pack away the abdomen as a protective measure. If you can't make the bowel reach outside the abdomen, use a strong sucker to decompress it. This will not work in the distal small bowel or colon because the content is usually too thick, but that is where it is more important to empty it!

You will then have to allow the bowel content to pour out into a bowl, getting an assistant to hold both bowel and bowl carefully so as not to spill the fluid, whilst you milk the content out. Once you have done this, clamp the ends of the bowel and clean them with swabs held in sponge forceps ('swab-on-a-stick'). Finally, dab the bowel ends with betadine.

You can decompress bowel *via* a nasogastric tube if the content is very fluid, and your anaesthetist is ready to suck out the contents. The danger is spillage into the mouth, and from there into the lungs, especially if the endotracheal tube is uncuffed: *do not use this method therefore with children!*

*FORCEPS*, intestinal, non-crushing, flexible blades, Kocher's, Doyen's or Lane's, 75mm. Use these to hold the bowel while you anastomose it. Non-crushing clamps have been designed to exert the right pressure without being covered with rubber tubes. If you fit them with rubber, they may crush too tightly.

*CLAMP*, Payr's, intestinal crushing, lever action, medium size, 110mm. These are the standard crushing clamps.

*CLAMP*, Payr, intestinal crushing, lever action, small size for pylorus, 60mm.

## **VIALE BOWEL ENDS MUST BE NICE AND PINK**

### **MINIMIZE CONTAMINATION**

THE CHOICE OF THE METHOD depends on the nature of the operation, your skill, and the equipment you have.

#### **IS THE BOWEL VIALE? TO RESECT OR NOT?**

CAUTION! For any method of anastomosis the bowel must be viable, which also means that its blood supply must be good enough.

Wait to decide if the bowel is viable or not until you have removed the cause (divided an obstructing band, or untwisted bowel which has twisted on its mesentery). You can usually tell if bowel is going to survive or not. Base your decision on several of these signs, *not on one only*.

#### **Bowel is viable if:**

- (1) its surface is glistening,
- (2) its colour is pinkish, or only slightly blue,
- (3) it feels resilient like normal bowel,
- (4) it contracts sluggishly (like a worm) when you pinch it,
- (5) you can see pulsations in the vessels which run over the junction between it and its mesentery.



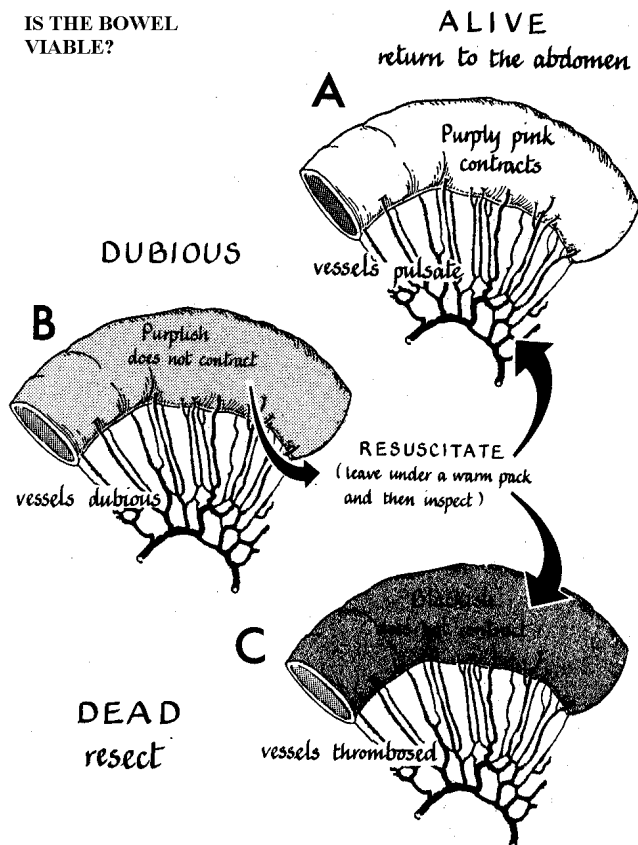


Fig. 11-6 IS THE BOWEL VIABLE?

A, it is viable if: (1) its surface is glistening, (2) its colour is pinkish, or only slightly blue, (3) it feels resilient like normal bowel, (4) it contracts sluggishly (like a worm) when you pinch it, and (5) you can see pulsations in the vessels which run over the junction between it and its mesentery.

B, if in doubt, remove the cause of the strangulation, apply a warm, moist pack to it, and wait 10mins. If it is viable, its colour will change from dusky to its normal pink.

C, it is dead and not viable if: (1) it tends to dry out and its surface is no longer glistening, (2) it is greyish purple, or a dark purplish red (or even black), (3) it feels like blotting paper, (4) it does not contract when you pinch it, (5) the blood vessels over it are not pulsating or are filled with black clot.

#### Bowel is not viable if:

- (1) it tends to dry out and its surface is no longer glistening,
- (2) it is greyish purple, dark purplish red or even black,
- (3) it feels like blotting paper,
- (4) it does not contract when you pinch it,
- (5) its blood vessels are not pulsating or are clotted.

**If you are in doubt,** remove the cause of the strangulation, apply a warm, moist pack to it, and wait 10mins. If it is viable, its colour will change from dusky to its normal pink. If this happens, it is alive even if you cannot feel the pulsations of the mesenteric vessels. It may be alive if some areas remain purplish because of bruising. But if these areas are large, or do not improve in colour, consider all the discoloured bowel to be non-viable.

**If a section of bowel is obviously non-viable,** resect it and make an end-to-end anastomosis, making sure the ends you wish to join together are viable.

**If only part of the wall of the bowel is non-viable,** as with a Richter's hernia (18-2), you may be able to invaginate it. If you are going to do this, the non-viable bowel must:

- (1) not be perforated,
  - (2) not extend over more than 30% of the circumference of the bowel,
  - (3) not extend to the mesenteric border, because suturing here may interfere with its blood supply,
  - (4) be surrounded by a border of healthy bowel.
- Use 2 layers of absorbable suture to bring the serosal surfaces of the healthy margins together in the transverse axis, so as to invaginate the non-viable segment into the lumen of the bowel where it can safely necrose. It may actually be easier to cut out the non-viable portion, and close the V-shaped defect with invaginating Connell sutures.

If it does not satisfy these criteria, resect the non-viable portion formally.

**If there is a completely encircling narrow band of greyish white necrosis,** resect it and make an end-to-end anastomosis otherwise it will turn into a Garré stricture of the bowel later.

**If you release a loop of bowel from a constriction ring,** be especially careful. The loop of bowel itself may be viable, but *there may be a narrow band of necrosis at both the afferent and the efferent ends*. It may slough at these narrow areas. Experts would resect the bowel. But, if you are not expert at bowel resection, oversewing the necrotic areas with Lembert sutures may be safer. If so, make a note of what you have found and done. A Garré stricture may form anyway, and the obstruction may recur.

#### IS THE BLOOD SUPPLY GOOD ENOUGH?

**If the mesenteric vessels of the bowel you are going to anastomose are not pulsating,** trim it back boldly until its edge bleeds with healthy red blood. If this does not happen immediately, try waiting a few minutes. If the flow is not pulsatile, it may become so if you wait a few minutes. Pick up the bleeding vessels with 4/0 absorbable suture, and *do not rely on your anastomotic sutures to control bleeding*.

You can use what we describe here as 'the 2 layer method' or you can use 'the one layer method'. Both methods are usually done with clamps, but can if necessary be done without them. Both the descriptions here assume you are doing an end-to-end anastomosis.

#### END-TO-END ANASTOMOSIS WITH 2 LAYERS USING CLAMPS (GRADE 3.3)

Using bowel clamps (11-7) is the standard method, because it causes the least contamination of the peritoneal cavity. You have first to join the back of the bowel (as it lies in front of you) and then the front. The important places for leaks are the 'corners', where the back and the front parts of the anastomosis join one another, at the mesenteric and the ante-mesenteric borders of the bowel.

## RESECTION AND ANASTOMOSIS OF BOWEL

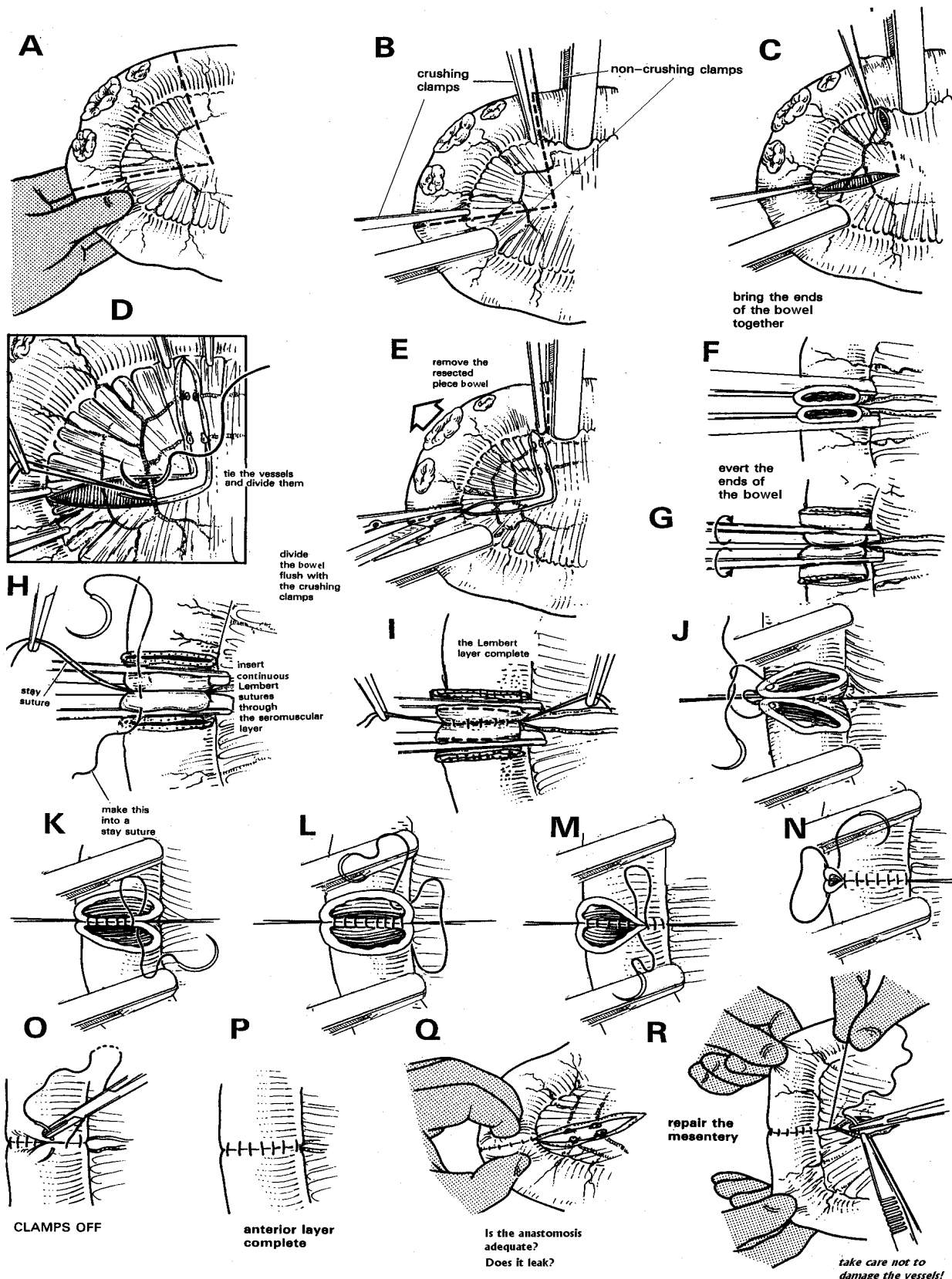


Fig. 11-7 RESECTION AND END-TO-END ANASTOMOSIS IN 2 LAYERS WITH CLAMPS.

This method uses 2 crushing clamps; it can be done without any clamps using stay sutures or tapes instead.

Apply non-crushing clamps in Step B and keep them on until Step N. Remove the crushing clamps with the loop of bowel in Step E. The critical parts of this anastomosis are the inverting Connell sutures in steps J-N.

If serosa of one loop is to be in contact with serosa of the other loop at these critical points, invert the bowel here. The suture which does this best is the Connell (11-5B,C). The principle of this is that the suture starts outside the serosa and comes out into the mucosa; it then goes back into it again, and it comes out of the serosa of the one end of bowel. It then goes back into the serosa again on the other end of bowel to be anastomosed. It makes a 'loop on the mucosa' (11-5D). It is this loop which makes the mucosa invert. The bigger the bite on the outside (serosa) and the smaller on the inside (mucosa), the better the bowel ends will invert.

Decide the length of bowel you want to resect (11-7A). Apply 2 crushing clamps at each end of the non-viable bowel to be resected, including a small portion of viable bowel, and non-crushing clamps 2cm away on the viable parts of bowel to be joined together (11-7B). *Do not place clamps over the mesenteric vessels.*

**If the mesentery is too thick for you to see the vessels clearly through it**, even when the mesentery is held up against the light, (as in the sigmoid colon, and the small bowel mesentery in moderately fat patients, especially distally), divide the peritoneal layer covering the mesentery carefully with fine scissors nearest to you to outline the vessels (11-7C). Dissect the vessels, place a small artery forceps on each and ligate them one by one, using a 2/0 or 3/0 suture (or smaller for children & babies). To save suture material you can leave the haemostats untied on the part of bowel to be resected. Pack away the other abdominal contents, and place one of 2 large abdominal swabs under the bowel to be resected. Make sure you protect the abdominal wound edges from contamination.

Divide the bowel on the outside of the crushing clamps (11-7E), using a sharp knife to give a clean cut. Empty the bowel of its content into a bowl, or using a guarded sucker. Bring the non-crushing clamps together (11-7F) and evert them (11-7G).

Insert a continuous Lembert suture through the seromuscular coat of the posterior layer of the bowel (the one which is furthest from you) starting at the anti-mesenteric border (11-7H), leaving one end long to act as a stay suture (11-7I), and continue till the mesenteric border, leaving the suture to hang. *Do not cut it off, or its needle: you will use it again!* Start the all coats continuous inner layer at the anti-mesenteric border with a loop on the seromuscular layers of both ends of bowel, leaving one end long as a 2<sup>nd</sup> stay suture (11-7J): you can differentiate this from the first stay suture if you are using the same thread by putting a loop on it, and continue by passing inside the lumen as a single all coats suture (11.5B-C). Continue as a simple over and over suture until you reach the mesenteric end (11-7K). Make sure you get your assistant to keep the right tension on the suture and let it snug down nicely on the bowel wall, so that you cannot insert a small artery forceps between the suture points.

**If the sizes of the bowel ends differ**, calculate taking more widely spaced bites on the bigger bowel end than on the smaller end, so that you reach the mesenteric ends of both bowel ends simultaneously. This takes some practice.

(Alternatively, use interrupted sutures: place stay sutures at the ante-mesenteric border of both ends of bowel, and tie these together; likewise do the same at the mesenteric border of both ends of bowel. Then place a suture midway between the 2 sutures on one end, and again midway between the 2 sutures at the other end, and tie them together. Continue with another suture midway between the first ante-mesenteric stay suture and this last one placed in the middle of the bowel, and so divide the bowel wall distance each time in half. That way, you will not end up with excess bowel on the distended side.)

Then, *using the same suture*, pass through from inside to outside the serosa (11-7L) and continue as an all coats inverting Connell suture on the anterior layer (11-5A, 11-7M), till you join the beginning of the same suture at the ante-mesenteric end again (11-7N). Tie the 2 ends of the inner continuous suture together and cut them, leaving 5mm ends. Now remove the non-crushing clamps. You may immediately see a defect; the tension may be released by removing the clamps and make the final outside suture easier.

Continue with the first continuous Lembert suture which you left hanging long on the mesenteric border, and go round till you end at the ante-mesenteric border (11-7O). Tie the 2 ends of the outer continuous suture together and so complete the circle (11-7P). Test the patency of the lumen with your fingers (11-7Q). Massage some of the bowel contents past the anastomosis to test for leaks. If you are worried, place the anastomosis under water and squeeze: look for gas bubbles; if there are none, your anastomosis is sound.

Close the defect in the mesentery with continuous 2/0 or 3/0 suture, taking great care not to occlude the vessels.

#### END-TO-END ANASTOMOSIS BY A SINGLE LAYER SUTURE (GRADE 3.3)

The important feature about this method is that it uses a single layer suture.

Essentially this method is like the '2 layer' but uses a single all coats layer, dispensing with the outer seromuscular layer; you need to be very careful to place the loops of the suture accurately and close enough together. These sutures cannot be made too neatly.

If the suture line is snug and inverted, stop at this stage. If not, complete the anastomosis with a final layer of Lembert 4/0 monofilament seromuscular sutures. This converts the one-layer method into a partial 2 layer method. You should be able to get most of the way round the bowel, but you may not be able to suture its mesenteric border.

## BOWEL SUTURING METHODS

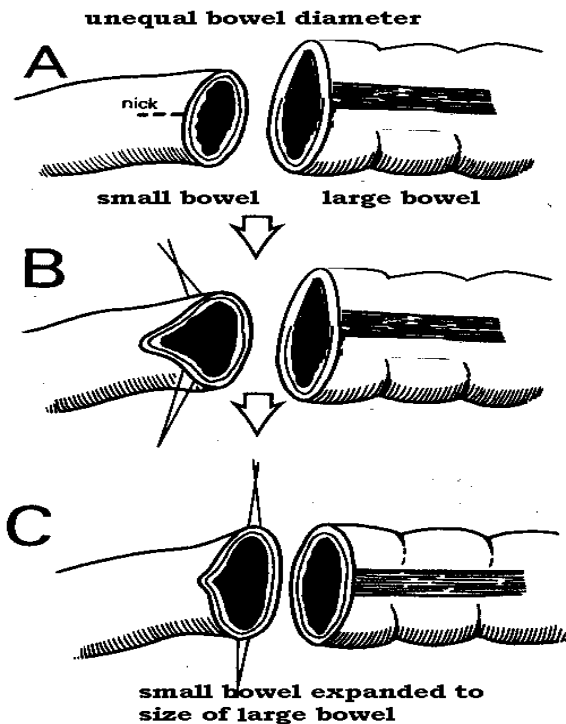


Fig. 11-8 SOME BOWEL SUTURING METHODS.

A, If the bowel that you want to anastomose end-to-end is unequal in size, B, make a cut in the ante-mesenteric border of the smaller piece, so C, it enlarges to the same size.

After Turnbull RB Jr. Ethicon, permission requested.

## END-TO-END ANASTOMOSIS BY THE OPEN METHOD (GRADE 3.3)

This method is indicated:

- (1) When you do not have any clamps.
- (2) When you cannot get clamps on to the bowel, as when joining large bowel to rectum after a Hartmann's procedure (12.10).
- (3) In infants and small children, because all clamps crush their delicate bowel to some extent, although bulldog vascular clamps are less traumatic. Hold the 'corners' of the bowel by stay sutures, and suture the posterior walls together by an all-coats suture. Instead of starting at the antemesenteric border, you may find it easier to start posteriorly opposite where it is easiest to finish. Place 2 separate Connell sutures at this point, and with each, work round anteriorly, finally tying both sutures together. The open method does however increase the risk of contaminating the peritoneal cavity and it is therefore essential to empty the bowel completely before starting.

**Which parts of the bowel can you safely anastomose to which and when?** You can anastomose large bowel safely if it is empty: give bowel preparation and enemas beforehand for the elective cases, or empty the bowel as described for emergency cases. If the colon is perforated or gangrenous, and particularly when there is heavy faecal soiling of the peritoneal cavity, *this is not safe especially if you only have catgut*. You should then make a diversionary colostomy (11.6).

**If you are not happy that you have made a satisfactory anastomosis** (no anastomosis is ever quite 'watertight'), you can bring up a loop of omentum and suture this loosely over the place which you think will leak. This is optional; there are certain occasions when it is very useful, notably the repair of a perforated peptic ulcer (13-11).

You should use preferably long-lasting absorbable sutures for the inner layer or in the one-layer method; the outer layer can use any type of suture, but long-lasting absorbable (especially in children) is best.

Remember to close the defect in the mesentery after you have completed the anastomosis, in order to prevent an internal hernia. Do this carefully so as not to pick up any blood vessels in the mesentery and damage the blood supply to the anastomosis (11-5L).

**If, when you have completed the anastomosis, the bowel is not viable ('purplish'), resect its ends and start again!**

**If the loops are very unequal in size** (as when anastomosing small to large bowel), you can make a small cut in the ante-mesenteric border of the smaller loop (11-8A,B,C). The end-to-side or side-to-side anastomosis is a poor alternative, and probably more likely to leak.

**If you do not have time** (because the patient is too sick: damage control) **or cannot make an anastomosis** (because you have not practised), you can temporize by closing the bowel ends with tape and returning for a 2<sup>nd</sup> look laparotomy (10.1) in 48hrs. Alternatively, secure both ends of bowel over a piece of tubing connecting the two, especially if the proximal bowel is very distended. Plan a 2<sup>nd</sup> look laparotomy as before.

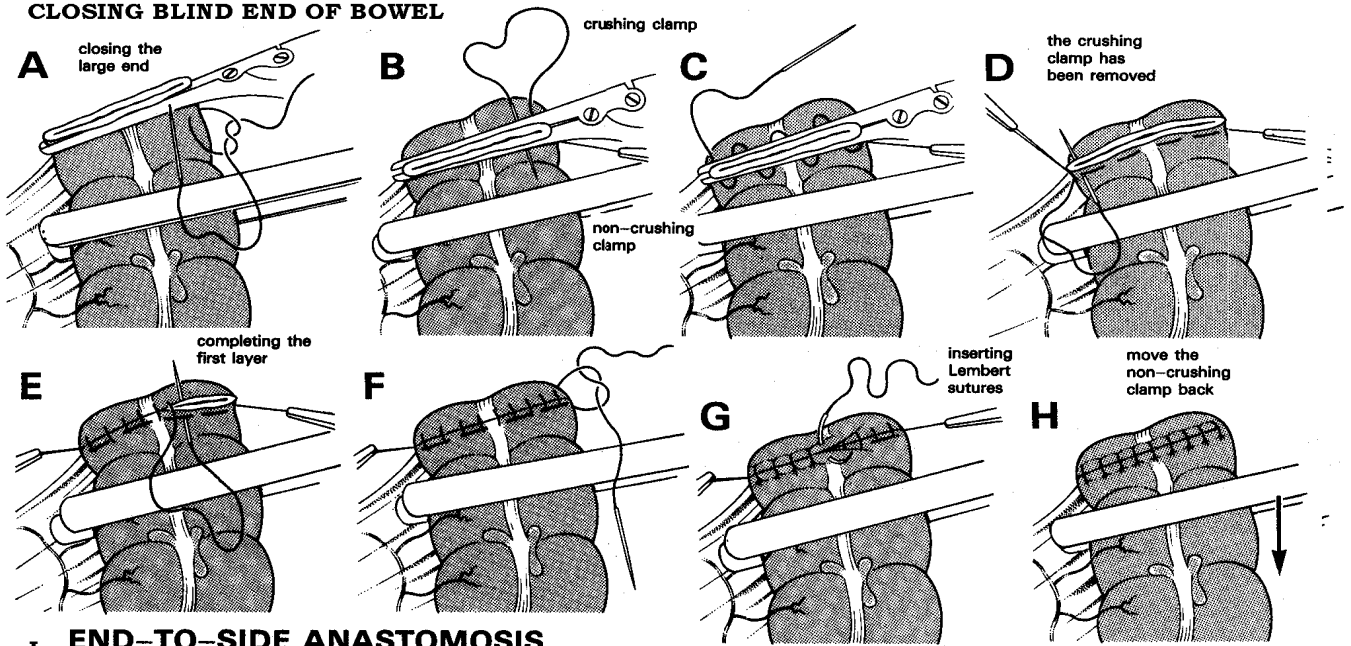
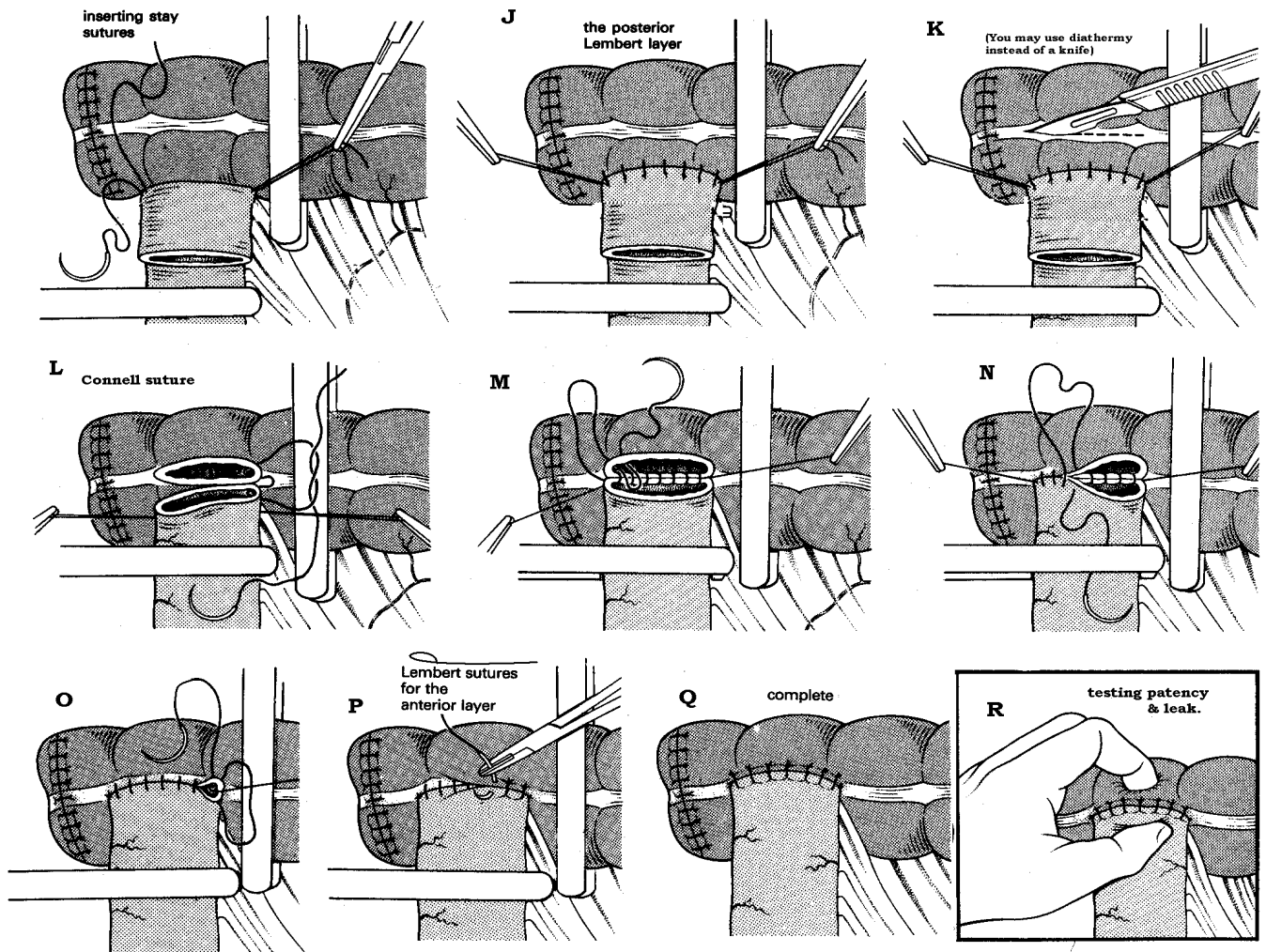
## PURSE STRING SUTURES

A purse string suture is an invaginating suture around a circular opening, and can be used to fix a caecostomy tube (11.6) or prior to draining the gallbladder (15-1B). Use it also to bury the necrotic base of an inflamed appendix (14.1)

Place a continuous Lembert suture through the serosa and muscle only, all round the appendix. Tie the first hitch of a reef knot, pull the ends of the suture upwards, and push the stump of the appendix downwards. If necessary, ask your assistant to pull up the opposite side of the purse string as you do so. If you happen to penetrate all layers of the bowel, reinforce the purse string with some more inverting sutures.

## ENTEROTOMY AND CLOSING A BOWEL PERFORATION (11-5M) (GRADE 3.2)

An enterotomy is an opening in the bowel. You may have to make one to decompress the bowel (12.4), make a stoma (11.5), to inspect the bowel to see where bleeding is coming from (13.4), or to remove *ascaris* worms (12.5) or a foreign body (12.15). Make a longitudinal opening in the anti-mesenteric border of the bowel.

**CLOSING BLIND END OF BOWEL****I END-TO-SIDE ANASTOMOSIS**

**Fig. 11-9 CLOSING A BLIND BOWEL END AND END-TO-SIDE ANASTOMOSIS.**

A-D, close the blind end of the bowel. E-H, invert the previous layer of sutures. I, insert stay sutures. J-K, insert posterior Lembert layer. L-M, insert the posterior all-coats layer

N-O, insert the anterior all-coats layer. P-Q, then the anterior Lembert layer. R, test its patency and check if there is a leak.

*Don't close an inflamed small bowel perforation: a leak will be certain. Resect the involved segment or drain it!*

Close the hole transversely in 2 layers as if you were anastomosing bowel. In this way you will not narrow its lumen. Start with a seromuscular suture just beyond the hole, leaving one end long as a stay. Continue this as a Connell all-coats suture till you have closed the hole, and tie a knot again leaving the end long as a stay. Cover this suture with a continuous seromuscular Lembert suture from just beyond the 1<sup>st</sup> knot to just beyond the 2<sup>nd</sup>, thus inverting the first layer completely. Test the closure with your fingers by milking intestinal content past it.

#### CLOSING A BLIND END OF BOWEL (11-9A-H, GRADE 3.2)

Using a straight or curved needle, close the end of the bowel with continuous atraumatic sutures working from side-to-side from one end to the other (11-9B,C). When you have got to the other end, pull the suture tight and remove the clamp. Work back to the end where you started, this time making over and over sutures (11-9D,E). Tie the ends of the suture and cut them off 5mm from the knot (11-9F). Cover the closed end of the bowel with a layer of inverting Lembert 2/0 sutures through the seromuscular coat (11-9G).

### 11.4 End-to-side & side-to-side anastomosis

#### END-TO-SIDE ANASTOMOSIS (GRADE 3.3)

##### INDICATIONS.

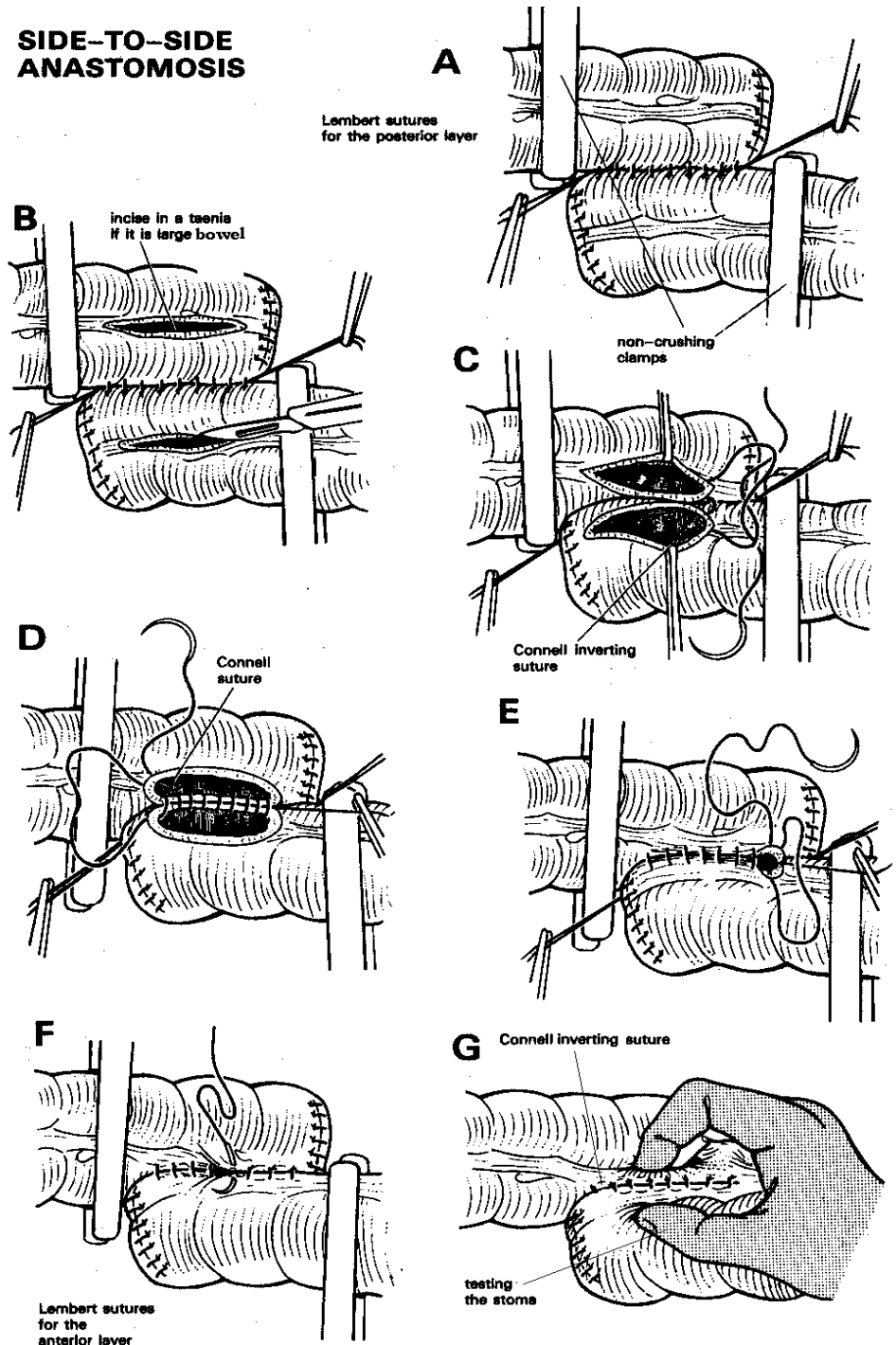
- (1) Constructing a Roux loop
- (2) Bypassing an inoperable colon tumour, septic or tuberculous adhesions, or as an alternative to ileocaecal resection.
- (3) When there is a big difference in the size of 2 loops of bowel to be anastomosed (though the method of 11-8B is better).

**Fig. 11-10 SIDE-TO-SIDE ANASTOMOSIS** is useful for creating a bypass without resecting bowel. A, hold the bowel loops with stay sutures and join them with the Lembert sutures that will form the posterior layer of the anastomosis. B, open both pieces of bowel. C, start the posterior all-coats layer with a Connell suture. D, the posterior all-coats layer has reached the other end, so now continue anteriorly as a Connell suture. E, complete the Connell suture. F, insert the anterior Lembert layer. G, test the anastomosis for patency and for a leak.

**METHOD.** Bring the clamped loop of bowel close to the other viscus, and insert stay sutures through the seromuscular layers only (11-9I). Complete the layer of interrupted seromuscular sutures (11-9J).

Clamp the other viscus and open it preferably with diathermy so as to make a stoma equal in size to the small bowel (11-9K). Trim the loop of bowel if necessary. Start the inner all coats layer with a Connell inverting suture (11-9L). Continue this as an over-and-over suture to the other end, and return using a continuous Connell suture for the anterior layer (11-9N).

#### SIDE-TO-SIDE ANASTOMOSIS





When you reach the end tie the 2 ends of the continuous all coats suture together and leave the ends 5mm long (11-9O).

Insert a layer of interrupted inverting seromuscular Lembert sutures (11-9P-Q). Test the lumen for its patency and any leakage: it should admit 2 fingers (11-9R). Repair the defect in the mesentery with 2/0 or 3/0 suture.

### SIDE-TO-SIDE ANASTOMOSIS (GRADE 3.3)

#### INDICATIONS.

- (1) Gastrojejunostomy (13-16)
- (2) Cholecystojejunostomy (15-5)
- (3) Bypass without resecting bowel.

**METHOD.** Bring the clamped bowel close to the other viscus as before and insert a layer of continuous Lembert sutures through the seromuscular coats of both of them, starting with stay sutures at each end about 1cm from the line of your proposed incision (11-10A).

Clamp the other viscus and incise both bowel and viscus for about 3cm (11-10B) with diathermy if possible. Starting with a Connell inverting suture (11-10C), use absorbable to join the posterior cut edges of the bowel with an all coats continuous over-and-over suture (11-10D). When you reach the other end continue as a Connell inverting suture along the anterior layer of the anastomosis (11-10E). Finally, complete it and tie the ends of the suture together, leaving 5mm cut ends. Insert an anterior layer of Lembert seromuscular sutures (11-10F). Test the lumen of the stoma with your fingers (11-10G) and move the bowel contents over the anastomosis to check for leaks.

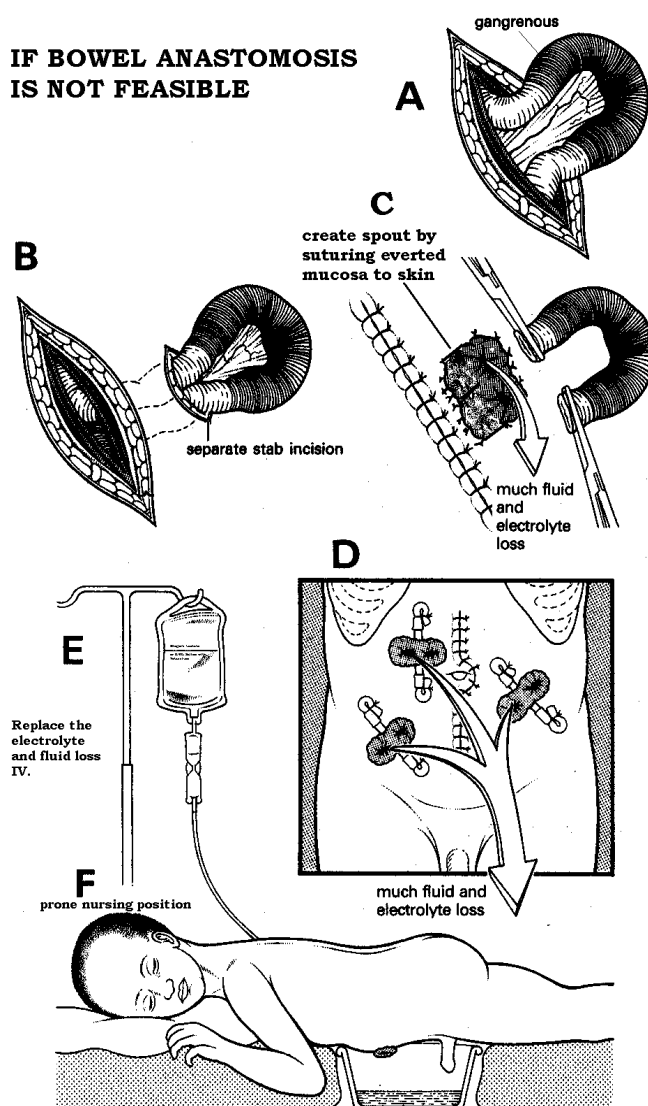
## 11.5 Stomas

In the upper part of the bowel, the purpose of a stoma (gastrostomy, or jejunostomy) is usually to allow input of food and fluid for nutrition; in the lower part (ileostomy, caecostomy or colostomy) it is to let the bowel contents drain outside the abdominal wall. The bowel can become obstructed at any point. It is possible to by-pass such an obstruction by making such a stoma (opening) proximally. If it is not safe to make an anastomosis, it is best to fashion such a protective stoma, and close it later when bowel continuity is restored.

There are 2 main ways of making a stoma:

- (1) Bring a loop of bowel to the surface and make a stoma at its apex, without resecting any bowel.
- (2) Bring the affected loop of bowel out of the abdomen through a special opening and then resect the loop. This leaves a proximal and distal end-stoma. If you are not skilled, it is useful way of resecting gangrenous or injured bowel, and making a stoma without soiling the abdominal cavity.

### IF BOWEL ANASTOMOSIS IS NOT FEASIBLE



**Fig. 11-11 IF BOWEL ANASTOMOSIS IS NOT FEASIBLE, e.g. in a typhoid perforation, bring the gangrenous segment (A) out through a separate incision (B), cut it off so as to make an ileostomy with a spout (C), and suture all coats of the bowel to the skin of the abdominal wall with interrupted sutures. D, there may be several stomas. E, there will be much fluid and electrolyte loss, which you must replace IV. F, nurse the patient like this.**

*E, F After Ian Hulme-Moir.*

In many cultures having a stoma is abhorrent. So you may have to use your best persuasive skills to encourage your patient to tolerate one. Show the patient what the stoma bags look like, and *mark the site for the stoma preoperatively*. This should be away from natural skin creases (*which may only appear on lying down, sitting or standing up*), scars, the umbilicus, and away from bony points. It should preferably be within the rectus muscle below the belt line, but be readily accessible *and visible* to the patient, so should then be above the level of the umbilicus and *not on the underside of a fat pendulous abdomen!*

There should be about 6-7cm around the stoma of smooth abdominal skin to stick the stoma bag. Mark the correct site pre-operatively with indelible ink, or henna paste. *Never fashion a stoma inside a laparotomy wound!* (This would be like siting a toilet in the kitchen!)

Commercial bags come as one-piece or two-piece systems, with a flange to attach the bag. The advantage of the two-piece is that the stoma can be examined easily and the skin adhesion is not disturbed: they are more expensive and need a flat surface to stick nicely. They are difficult to manipulate by the elderly and by those with arthritis.

Different manufacturers' flange sizes are not usually interchangeable: pouches of the wrong size which do not attach to the flange are then useless!

The biggest problems are leaks: it helps to have sealant pastes and skin barriers, adhesive tape and supporting belts. Make sure the opening of the bag fits exactly on the stoma: measure it with a paper template.

Fortunately, most stomas are usually only needed temporarily.

#### TYPES OF STOMA

**A gastrostomy** (13.9) is an opening made in the stomach for feeding.

**A jejunostomy** (11.7) is usually used also for feeding, but by inserting a tunnelled fine tube through the wall of the jejunum.

**The common sites for distal bowel stomas** (11-12): (1) the terminal ileum. (2) the caecum. (3) the right side of the transverse colon. (4) the sigmoid colon.

**An ileostomy** is usually made by bringing an end loop of terminal ileum through the abdominal wall. Because of the liquid bowel content full of enzymes at this point, spillage onto the skin causes rapid excoriation. To avoid this, fashion the ileostomy carefully by everting it as a spout. You still need to evert the ileostomy stoma if you are making a loop ileostomy, unless you have very good stoma appliances.

**A spout ileostomy** is normally sited in the distal ileum. It can be used as a conduit for urinary diversion.

**A loop ileostomy** can be used for bowel diversion, but is more difficult to manage than a colostomy

**A caecostomy** can be made by placing a tube in the caecum and letting the liquid faeces drain. This is easier than doing a transverse colostomy, but:

- (1) The risks of soiling the peritoneum are greater.
- (2) A caecostomy often does not work well, and needs much washing out, so it is difficult to manage postoperatively.
- (3) It diverts little of the faecal stream. But, provided the tube is not too small, it may do this adequately.
- (4) It can only be temporary. A caecostomy is useful if a patient is desperately ill, and you can, if necessary, fashion one under LA without exploring the whole abdomen.

**A transverse colostomy** can be made as a loop, or double barrelled, or as a spectacles colostomy. Always make it in the right side of the transverse colon. This should not be difficult unless the colon is very distended, or the mesocolon is short.

**A sigmoid colostomy** is an alternative to a transverse colostomy. Here again you can make a loop, or adjacent or end colostomy (as in the Hartmann operation, 12.9)

#### STOMAS

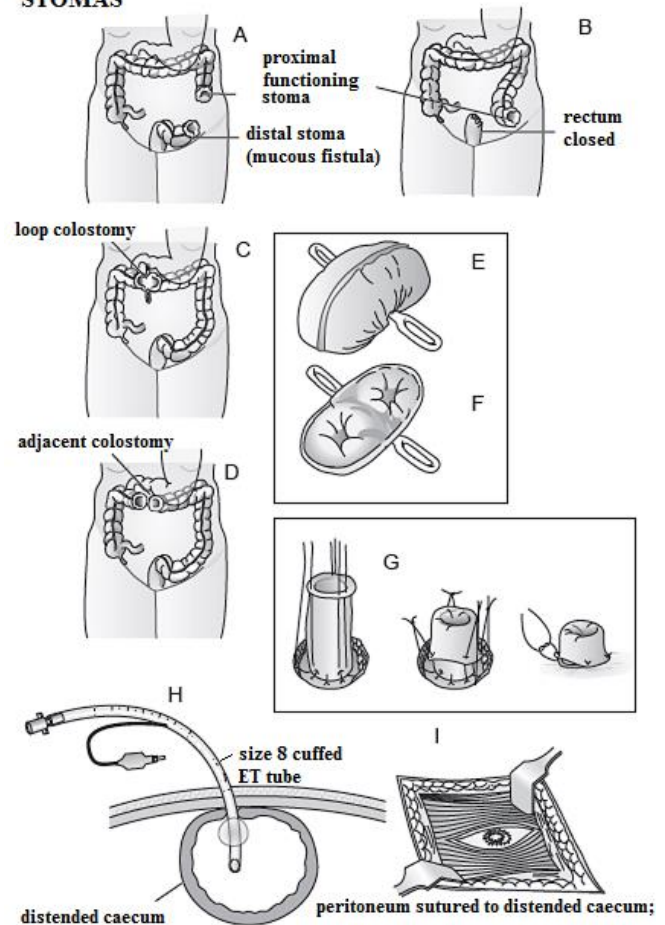


Fig. 11-12 STOMAS.

A, proximal descending colostomy and distal mucous fistula. B, Hartmann's operation: rectum closed. (*In an abdomino-perineal resection, the rectum is removed.*) C, loop transverse colostomy. D, adjacent (double-barrelled) colostomy. E, loop colostomy prepared over a rod. F, loop colostomy opened with mucocutaneous sutures. G, Brooke ileostomy: (1) advance the bowel through the abdominal wall and secure it to the anterior rectus sheath; (2) place sutures through the cut edge of bowel, with a seromuscular layer at skin level and subcutaneous tissue to evert the spout; (3) completed ileostomy with mucocutaneous sutures. H, caecostomy using a size 8mm endotracheal tube. I, purse string and suture fixing the caecum to the peritoneum. After Hampton BG, Bryant RA. *Ostomies and Continent Diversions*, Mosby 1992 p.359-67

There are various types of loop or end colostomy:

**A loop colostomy** brings a loop of bowel out of the abdomen over a short length of rubber tube, or a glass rod. This is the easiest stoma to make and close, and is suitable for most purposes. However, it does not completely defunction the distal colon.

**A double-barrelled colostomy**, is a loop colostomy modified by suturing the last few centimetres of its limbs together inside the abdomen, so that they resemble a double-barrelled shotgun. You can then later crush the spur (wall) between the 2 loops to make the colostomy easier to close, *but this method has dangerous complications.*

A '**spectacles colostomy**' has limbs that are separated by a small bridge of skin (11-14E). It is useful: (a) if a patient needs a colostomy for a long time, and (b) during the repair of a rectovaginal or vesicovaginal fistula, when work on the rectum and bladder has to be completed before the fistula can be closed.

An **end (terminal) colostomy** forms the 'end' of the bowel after excision of the sigmoid in Hartmann's operation (12.9) or excision of the rectum.

A **mucous fistula (colostomy)** is a stoma of the distal defunctioned large bowel, discharging only mucus.

**Closing stomas** can be more difficult than making them. A tube caecostomy will usually close by itself once the tube is removed, but a surgical procedure is needed to close a loop transverse or sigmoid colostomy, or ileostomy. Reversing Hartmann's operation is much more difficult (12.10). Leaving a stoma permanently may be safer for the patient, although much less popular.

## 11.6 Fashioning & closing stomas

There are some important general principles: always try to bring a stoma out through a separate smaller incision, and not through a laparotomy incision, because the wound is much more likely to become infected, and perhaps burst. Remember that there will be psychological adjustment necessary, centred around the problems of *sight, smell, sound, sex, stigmata* and *secretiveness*.

### ILEOSTOMY (GRADE 3.3) INDICATIONS.

- (1) A gangrenous caecum.
- (2) As diversion in very severe inflammatory colitis or megacolon.
- (3) In exteriorization for ileocolic intussusception (12.7)

**METHOD.** Mark the site for the ileostomy beforehand. Cut out a 3cm circular disc of skin and subcutaneous fat with a knife, picking up the centre with a tissue forceps. Make an incision in the rectus sheath, split the rectus muscle 4-5cm wide, and open the posterior sheath and peritoneum.

**For an end-ileostomy**, exteriorize 6-8cm of clamped ileum with its mesentery intact through the hole in the abdominal wall. Make sure the clamp does not come off! (If you do not have small clamps that will pass through the hole, tie the bowel with a tape). Evert the bowel as a spout projecting 3cm from the abdominal wall (11-12G), and join the bowel and skin edges with interrupted absorbable sutures.

**For a loop ileostomy**, bring out a loop of ileum, without disturbing its mesentery. To do this, it is easiest to pass a thin lubricated rubber sling through a small hole in the mesentery adjacent to the bowel, and pull gently on this through the hole in the abdominal wall while simultaneously manoeuvring the bowel from inside.

Check that the mesentery is not twisted or strangulated by the rectus muscle. Fix the ileum to the rectus sheath with some seromuscular absorbable sutures.

After closing the abdomen, remove the clamp or tape off the ileum and trim it clean.

Apply a bag, making sure the opening is *exactly* the size of the stoma, *otherwise it will inevitably leak*.

### CAECOSTOMY (GRADE 3.2) INDICATIONS.

- (1) Penetrating injuries of the caecum.
- (2) A grossly distended caecum about to burst.
- (3) An obstruction proximal to the mid transverse colon, if you feel unable to perform a right hemicolectomy.
- (4) Large bowel obstruction, if the patient is *in extremis* and too ill for a colostomy, or if you are inexperienced.

**RADIOGRAPHS.** Before you start, make sure exactly where the caecum is. Look for its gas shadow on the radiograph. It can be surprisingly high. Percuss the abdomen to make sure.

**EQUIPMENT.** An 8 or 9mm cuffed endotracheal tube. (*This is wider and less floppy than a catheter, so blocks less and is easier to insert, and causes fewer leaks.*)

### METHOD.

*In extremis*, this operation can be done under LA. If the abdomen is not already open, with the greatest possible care, make a gridiron incision well laterally over the dilated caecum: *you can easily burst it*. Put packs round the wound inside the abdomen to minimize the consequences of spillage. Have suction instantly available.

Partly deflate the caecum by wide bore needle aspiration: this releases air under tension (after placing a purse string suture). As soon as you have done this, its walls will become thicker and more vascular.

*N.B. Do not expect at this stage to evacuate faecal matter.*

Try to mobilize the caecum to deliver part of it out of the abdomen, assisted by Dennis Browne forceps if necessary. *Beware, though, if it is very thin and likely to burst! If you cannot do this easily, do not attempt to do so.* Suture the cut edges of the peritoneum around the caecum, leaving enough space to insert a 2/0 atraumatic purse string 5cm diameter circle on the caecum itself (11-12H,I). Pick up its seromuscular layer only. *Do not penetrate its mucosa.* Leave the sutures long, hold them in haemostats and leave them untied.

With suction immediately ready and attached to the tube and the surrounding area carefully packed off, make a small cut in the centre of the purse string taking care not to cut the suture itself. Grasp the 8mm size endotracheal tube and, using a screwing movement, quickly push it through the cut in the centre of the purse string. Immediately tighten the purse string to secure the tube in place.

Inflate the balloon and gently pull on the tube to bring the caecum to the abdominal wall (11-12H).

**CAUTION!** Make sure the tube can drain *via* the suction off to the side, so that it does not flood the abdomen.

Close the muscle layers of the abdominal wall, but leave the skin open as the wound is likely to become infected. Suture the tube to the skin to prevent it being pulled out, cut it to a convenient length and connect it to a drainage bag or bottle. After 36hrs, flush it out with 1-2l saline, which need not be sterile, at least bd. After 10-14days, the tissues will become adherent enough for you to remove the tube. The caecostomy will close on its own provided there is no longer any distal obstruction.

#### DIFFICULTIES WITH A CAECOSTOMY

**If the caecum bursts** with a puff of gas as you open, suck vigorously. This will not be a major disaster if you have previously sutured the cut edges of the peritoneum to the caecum, and so isolated the peritoneal cavity; pass the caecostomy tube into the tear in the burst caecum, provided it is not necrotic or gangrenous, and secure it as before.

**If the caecum bursts as you are opening the abdomen**, suck vigorously and quickly grab the caecal wall in order to introduce the tube, or exteriorize it. If you fail, perform a formal laparotomy.

**If the caecum is gangrenous but has not yet perforated**, perform a formal laparotomy and resect it. You can either make an end-to-end ileocolic anastomosis or you can close the distal colon, perform an ileostomy and then close this 3wks later. You will have to correct the subsequent ileostomy fluid and electrolyte loss.

#### TRANSVERSE LOOP COLOSTOMY (GRADE 3.3)

##### INDICATIONS.

- (1) Obstruction of the distal  $\frac{2}{3}$  of the transverse colon.
- (2) A penetrating injury of the transverse colon.
- (3) Gangrene of part of the transverse colon owing to strangulation or interference with its blood supply.
- (4) To divert faeces prior to repair of a rectovesical or rectovaginal fistula.
- (5) Protecting an anastomosis for sigmoid volvulus after resection.
- (6) To defunction the bowel for Hirschsprung's disease (33.7).

A transverse colostomy is not difficult to fashion, and is better than a caecostomy. There are 3 types:

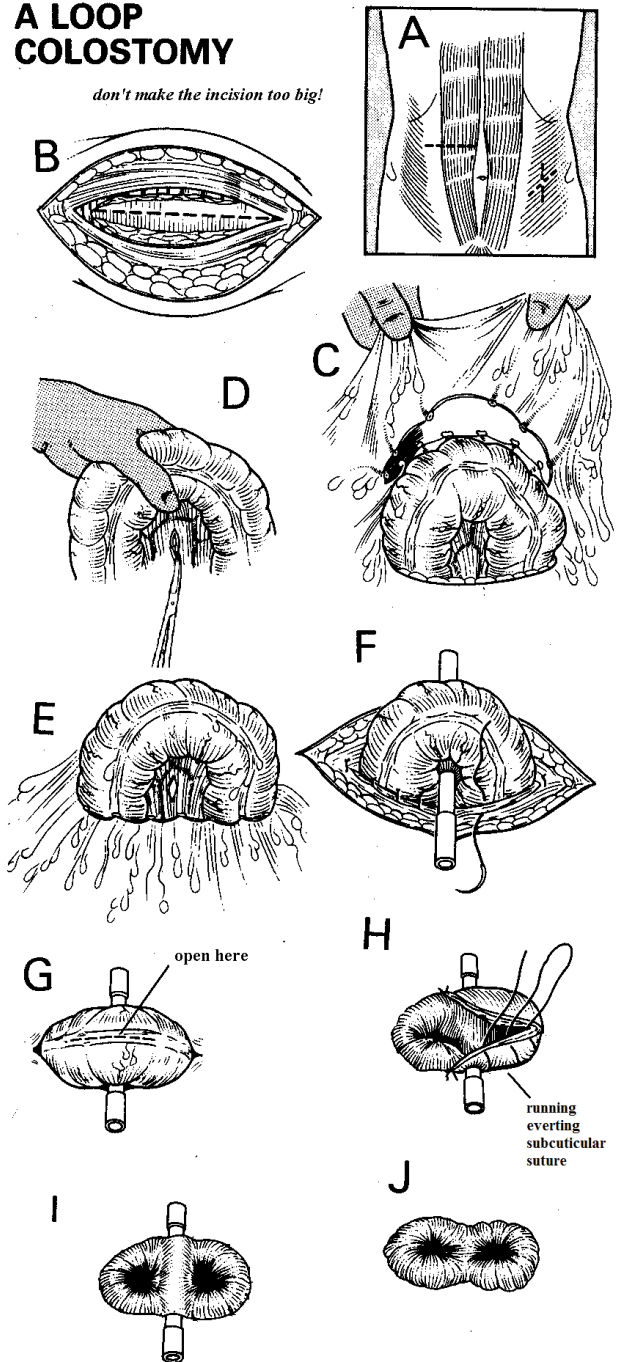
- (1) A plain loop.
- (2) An adjacent colostomy.
- (3) A 'spectacles colostomy' (11-14).

##### CAUTION!

- (1) Make the incision well to the right.
- (2) It must be high enough to avoid the umbilicus, and not so high that the transverse colon cannot reach it.
- (3) Make it just large enough to take the loop comfortably.
- (4) Make sure you have picked up the transverse colon and not the stomach or the sigmoid colon! The transverse colon has *taeniae* (unlike the stomach), and is attached by a short omentum to the greater curvature of the stomach.

## A LOOP COLOSTOMY

*don't make the incision too big!*



**Fig. 11-13 LOOP COLOSTOMY.**

A, make these incisions for a transverse or sigmoid colostomy. For a transverse colostomy: B, incise the rectus muscle. C, incise the greater omentum. D, incise the mesentery. E, bring the colon through the greater omentum. F, push a piece of tube or a glass rod through the hole, and fix the colon to stop it falling back. G, close the wound. H, open the colon and suture it to the edges of the skin wound. I, complete the colostomy. J, after healing of the wound.

After Goligher JC. *The Surgery of the Anus, Rectum and Colon*. Baillière Tindall 4<sup>th</sup> ed 1974 Figs 347-361 with kind permission.

Choose an area of the transverse colon to the right of the midline. Trim off the omentum attached to 7-10cm of its anterior surface so as to make a gap in it (11-13C). Try to avoid tying any small vessels that may be present. Deliver a loop of the transverse colon through this gap. Make a small window in the transverse mesocolon next to the mesenteric border of the colon (11-13D).

Do this by pushing a large blunt haemostat through the mesentery close to the wall of the bowel, while you open and close its jaws. *Avoid injuring the branches of the middle colic artery as you do so.* Pass a rubber sling through the window you have made, and grasp both its ends with a haemostat. Test the colon for mobility again. If it is very tense and distended, decompress it.

**CAUTION!** You must be able to deliver the loop of colon you have isolated through the transverse incision comfortably. If you cannot do this, mobilize the colon more; a poor alternative is to open the colon, and suture the bowel edges directly to the abdominal wall skin.

This is a '**blow-hole colostomy**'. To prevent the bowel from detaching, fix it to the inner abdominal wall with 4 sutures. If you are still uncertain about its fixation, insert a Foley catheter into the stoma, blow up the balloon sufficiently to hold the bowel against the abdominal wall and apply a little traction on the catheter.

#### METHOD.

Mark the site for the colostomy beforehand. Make a 6-7cm separate transverse skin incision above and to the right of the laparotomy incision (11-13). Divide the anterior rectus sheath in the same line as the skin. Stretch the rectus muscle transversely to admit 2 fingers only. Open the posterior rectus sheath and peritoneum.

Push a 2nd haemostat through the transverse abdominal incision, and grasp the sling you have placed round the colon. Release the first haemostat, and by pulling with one hand and pushing with the other, withdraw the loop of colon, so that it comes out through the incision and rests on the abdominal wall.

**If the wound is loose enough to let you insert a finger alongside the loop of colon**, there will be no risk of the lumen occluding, and the colostomy should function satisfactorily. If the colon is not loose enough, extend the incision.

Once you have closed the abdomen, pass a short piece of thick rubber tube, or a short glass rod attached to a piece of rubber tube, through the window occupied by the catheter (11-13F), and keep it there with 2 sutures anchored to the skin. Fix the bowel to the fascia of the abdominal wall with 2-4 seromuscular sutures. Leave the rod *in situ* 5-7days.

**CAUTION!** Before you place these sutures, make sure the colon is not twisted, and that it runs transversely, as the transverse colon should.

Open the colostomy immediately, by making an incision longitudinally along a *taenia* (11-13G,H). It will open to form 2 stomas (11-13I). Evert the bowel wall and join the open edges of bowel to the skin with continuous absorbable sutures (11-13H,I), putting them through the full thickness of the bowel wall, but subcuticularly in the skin.

(This ensures the bowel edge overlaps the skin and bowel content cannot flow under it). Push a finger down the afferent loop to make sure that it is patent; a gush of gas and faeces is an encouraging sign. Apply a colostomy bag (11-15).

## SIGMOID COLOSTOMY (GRADE 3.2)

#### INDICATIONS.

- (1) Wounds of the rectum.
- (2) Chronic inoperable obstructive rectal lesions including carcinoma.
- (3) To divert faeces prior to repair of a rectovesical or rectovaginal fistula repair.
- (4) To defunction the bowel for imperforate anus (33.6).
- (5) To divert faeces in uncontrollable faecal incontinence, especially because of HIV disease.

**METHOD.** Mark the site for the colostomy beforehand. Proceed as for a transverse colostomy (though there is no greater omentum to draw the sigmoid through) pulling out a loop of sigmoid colon: this is usually readily mobile.

#### SPECTACLES COLOSTOMY & END STOMAS

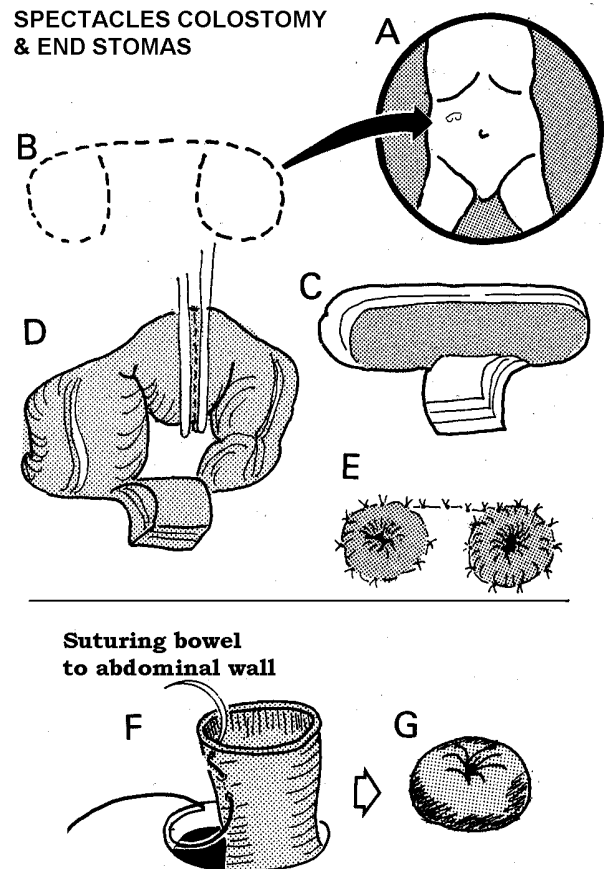


Fig. 11-14 SPECTACLES COLOSTOMY & END STOMAS.

A, site of incision for a spectacles colostomy. B, spectacles incision. Remove the skin inside each loop. C, turn back the flap. D, exteriorize the transverse colon and clamp it with 2 non-crushing clamps. E, colostomy completed. F-G, secure method of everting colon onto the abdominal wall.

**To make a spectacles colostomy**, for complete faecal diversion, make the incision (11-14B) and remove the skin inside each loop. Turn back the flap (11-14C), and divide the clamped colon (11-14D) to make the colostomy with separated loops (11-14E)

## END (TERMINAL) COLOSTOMY (GRADE 3.3)

### INDICATIONS.

- (1) As part of Hartmann's operation (12.9).
- (2) A permanent colostomy, as in an abdomino-perineal resection of the rectum.
- (3) In exteriorization of an ileocolic intussusception (12.7).

### METHOD.

Mark the site for the colostomy beforehand. Draw out the end of the bowel with a clamp or tape attached to avoid spillage. Before you close the abdomen, put in a few absorbable sutures between the seromuscular coat of the bowel, and the anterior rectus sheath of the abdominal wall to reduce the risk of prolapse and to stop the bowel falling back into the abdomen after you have closed it! Make sure that there will be 1½cm of healthy bowel protruding beyond the skin. Try to close the lateral space between the colostomy and the abdominal side wall; then close the abdomen.

To open the colostomy, cut off the crushing clamp with a sharp scalpel. Control bleeding. Suture mucosa to skin all round with continuous absorbable sutures which take a bite of the full thickness of the colon, and run subcuticularly in the skin. You will find the colostomy will evert itself beautifully (11-14G). *Do not attempt to dilate the stoma with 2 fingers!*

**If a baby with imperforate anus has a grossly distended colon,** make the incision as before and put gauze swabs around the incision edges. Place a purse-string, preferably over the *tinea*, and decompress the bowel with a stab incision at the centre of the purse-string. The bowel will then collapse and become easy to manipulate.

### DIFFICULTIES WITH COLOSTOMIES

**If the colostomy 'runs like a river',** this is likely to be a good sign in the early stages, because it means that the obstructed bowel is emptying itself. If it happens later, treat with kaolin mixture with 30-60mg codeine phosphate tid, and advise against drinking orange juice.

**If the colostomy does not work,** put a finger into the afferent loop to make sure that it has not become occluded. Twist your finger round gently inside the bowel lumen beyond the level of the rectus muscle to irritate the bowel. If this fails to start it 30-60mins later, get the patient to drink orange juice and mobilize. If this also fails, put a glycerine suppository into the afferent loop, or instil enema solution in using a Foley catheter with the balloon gently inflated to prevent the irrigation spilling out. If it is still not working after 3days, check abdominal radiographs to see if there is proximal obstruction.

**If an abscess forms next to the colostomy,** drain it (preferably under LA) and allow it to drain into the stoma bag.

**If the bowel forming the colostomy necroses,** and becomes dark purple you probably damaged its mesentery by stretching or compressing it into too small a hole. Put a glass tube into the stoma and shine a light onto it to see how deep the necrosis extends. (You can get a better view if you pass an endoscope down the stoma.)

**If it is more than superficial,** return to theatre, enlarge the opening in the abdominal wall, and make a fresh colostomy by bringing out more bowel, and resecting the necrotic black or purple part. *Do not delay doing this, hoping the bowel will improve:* the risk is of further bowel necrosis and peritonitis resulting.

*N.B.* Take care you distinguish necrosis from *melanosis coli*, the blackish appearance of bowel from anthracene laxative abuse (*e.g. senna*). This bowel bleeds if you pinch it with forceps; *necrotic bowel does not.*

**If the colostomy retracts,** it will contaminate the peritoneum and cause faecal peritonitis if the bowel separates completely. You then need to re-open the abdomen to correct this. Retraction occurs because of:

- (1) the mucocutaneous sutures giving way.
- (2) chronic peristomal skin infections.
- (3) inadequate mobilization of the bowel mesentery.
- (4) too early removal of the rod supporting a loop colostomy.
- (5) excessive weight gain. Retraction makes it difficult to get a bag to stick.

**If the colostomy stenoses,** dilate it gently with sounds, using a lubricant, *not with 2 fingers*. It may be that the fascia or skin is too tight; if so, release it under local anaesthesia. If it is the result of a severely retracted stoma, refashion it. Check for recurrent inflammatory bowel or malignant disease at the stoma site.

**If the skin around the colostomy becomes oedematous and inflamed,** necrotizing fasciitis of the abdominal wall has developed because of leakage of faeces into the subcutaneous tissues. Return immediately to theatre to debride the affected skin and fascia widely, and refashion a colostomy in a different site.

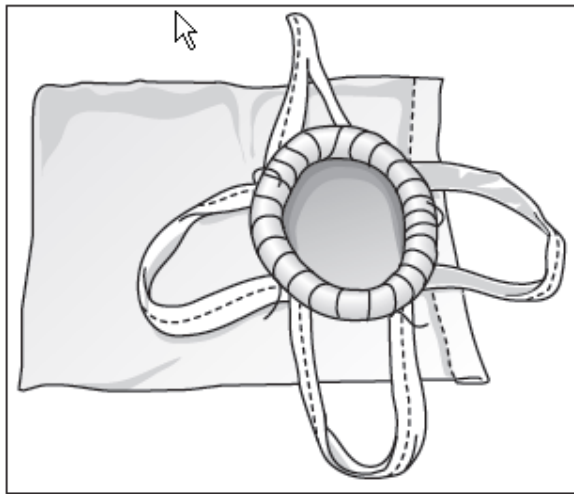
**If a hernia forms around the colostomy,** it will probably only be a little bulge, and is unlikely to grow big. It has occurred because the opening for the colostomy is too big or the stoma has been placed lateral to the rectus muscle. You may be able to close the colostomy opening better by inserting sutures from fascia to the seromuscular layer of the bowel, but this is rarely necessary. Occasionally a hernia comes through at the side of a colostomy: this needs revision (18.13).

**If signs of intestinal obstruction develop** (12.4), adhesions may be forming inside the abdomen at the site where the colostomy emerges, or from the original disease process. They are no different from the adhesions developing after any other abdominal operation. Explore the abdomen if there is no improvement.



## HOME MADE COLOSTOMY BAG

A. The completed pouch with ring wrapped by plastic-lined cloth, and straps attached to the flanges of material.



B. The bag being worn (the upper flange is not being used in this case).

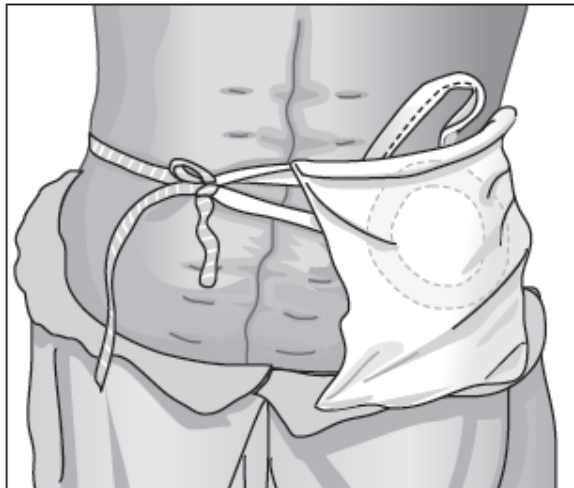


Fig. 11-15 A HOME-MADE COLOSTOMY BAG.

You can make a functioning colostomy bag from an ordinary plastic shopping bag, a rubber ring and cloth. A, make a pouch 10x12cm and line its inside with a plastic bag: this can be open at one end or, better, closed around its 4 sides. Outline on the pouch a circle the size of the stoma, which should be protruding from the abdominal wall, and cut this out making a hole. Attach 4 flanges of cloth to a rubber ring 1cm larger than the patient's stoma. Place the ring over the hole, and roll the cloth/plastic surface over the ring and secure this with elastic bands, making sure the plastic is on the outside. It is best that the rubber ring is malleable so that it can be moulded onto the abdominal wall around the stoma. Karyo gum will help seal the skin of leaks. B, attach straps to the flanges to hold the pouch in place around the abdomen, and if necessary over the shoulder.

After Zafar A, Malik E. Hand-made colostomy bag. *Tropical Doctor* 2002; 32(4):241, with permission.

**NB.** Neonates do not need a colostomy bag; the ordinary nappy will suffice, but it still needs changing every time the baby passes a stool!

**If the colostomy prolapses**, it will look just like a prolapse of the rectum. Bowel protrudes as an intussusception; you can usually push it back. This is quite common, especially in infants, and embarrassing. It is caused by too large an opening or inadequate fascial support for the colostomy.

**If you cannot reduce it**, put fine-ground or icing sugar on the prolapsed bowel for 2-3 days: it will then reduce in size and allow you to reduce it. Hyaluronidase (1,500U in 10ml water) injected into the stoma will also reduce the oedema and allow you to reduce the stoma. Persistent prolapse or necrosis will require a revision of the colostomy.

**If the skin excoriates around the colostomy**, try to reduce the fluidity of the output with kaolin and codeine phosphate. Make sure the bags fit nicely and do not leak: use sealant pastes.

**If some varices develop around the colostomy**, this is a sign of portal hypertension (usually due to cirrhosis or *schistosomiasis*).

## CLOSING A COLOSTOMY (GRADE 3.3)

Do this 4-6wks later, when the wound is healthy and there is good recovery from the original operation. Check that any distal anastomosis or repair is sound by introducing dilute Barium contrast through the distal stoma loop, or *via* the rectum, and taking radiographs.

### CAUTION!

- (1) The patient will be hoping for this as soon as possible. *Do not let him persuade you to do it too early.*
- (2) It is not an easy operation.
- (3) Make sure there is a loop colostomy and *not an end-colostomy* by examining it carefully with your fingers, feeling for the afferent and efferent loops.

Wash out the bowel proximally, and distally through the rectum. Repeat this daily for 2-3 days before the operation. Treat with magnesium sulphate 10g to help empty the proximal bowel and to make sure that the next faeces passed will be soft. Use gentamicin, or chloramphenicol and metronidazole, as perioperative prophylaxis (2.9).

To minimize bleeding infiltrate the skin and subcutaneous tissues around the colostomy with LA solution containing adrenalin 1:200,000. This infiltration is also valuable in demonstrating tissue planes.

Insert traction sutures round the colostomy (11-16A). Make an elliptical incision round it (11-16B). Use sharp scissors to dissect it free from the surrounding skin and fascia, and from the muscle of the abdominal wall (11-16C). (You can keep a finger in the lumen to tell you when you are getting dangerously close to it.) Raise the ellipse of skin from the abdominal wall (11-16D). Using sharp dissection, clean the sheath of the rectus muscle until you reach the edge of the opening through which the bowel is passing. Change any soiled gloves.

Free the parietal peritoneum round the circumference of the opening. Divide any adhesions that may be present. Draw the colon gently out of the incision, and place packs over the wound. Trim away the everted edges of the bowel (11-16E). Close it transversely with Connell sutures (11-16G,H).

#### CLOSING A COLOSTOMY

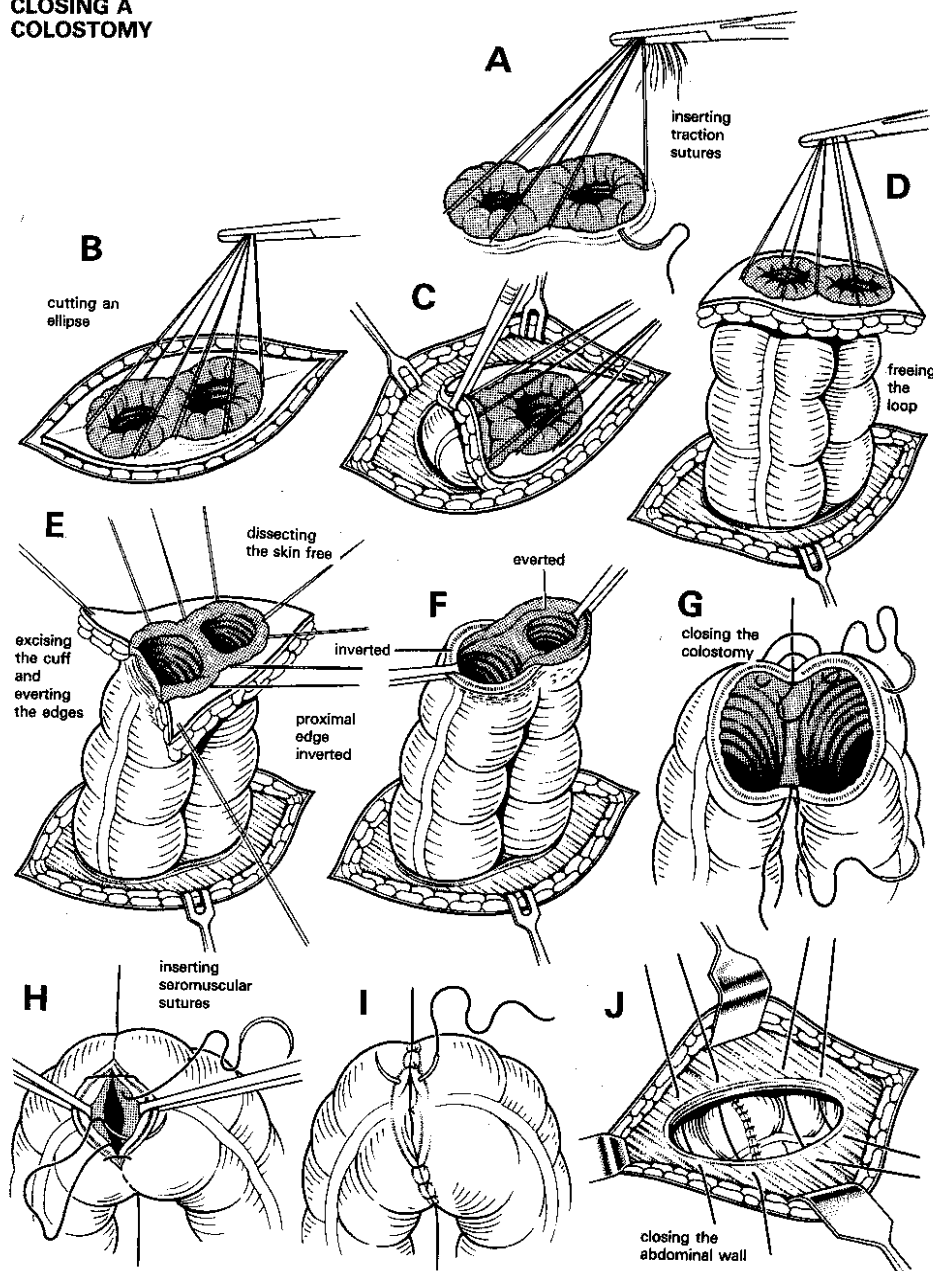


Fig. 11-16 CLOSING A LOOP COLOSTOMY.

A, insert traction sutures. B, raise an ellipse of skin round the colostomy. C, dissect an ellipse of skin free from rectus sheath. D, free the colostomy loop. E, excise a cuff of skin and evert the bowel edges. F, evert the proximal bowel edge; the distal bowel edge is still inverted. G-H, close the colostomy with Connell loop-on-mucosa sutures. I, insert a 2<sup>nd</sup> layer of seromuscular Lembert sutures. J, close the muscles of the abdominal wall in one layer.

After Maingot R. *The Management of Abdominal Operations*, HK Lewis, 4<sup>th</sup> ed 1961 Figs 396-404 with kind permission.

Start by placing 2 atraumatic sutures through all the coats of the bowel where the proximal and distal colon meet. Tie the knot in the lumen, and work from each side. Finish with a seromuscular continuous Lembert suture (11-16I). Test the patency of the lumen with your fingers and return the colon into the abdomen. Repair the defect of the rectus sheath (11-16J), and close the stoma opening with a subcuticular purse-string suture: this allows a small hole to drain fluid and prevents infection and gives a neat scar avoiding 'dog-ears'.

#### DIFFICULTIES WITH COLOSTOMY CLOSURE

**If you are not sure what sort of colostomy there is**, put a gloved finger (or two) into the stoma. *Make sure you do not close an end colostomy!* This needs anastomosing to the distal colon or rectum (12.10).

**If there is a 'blow-hole colostomy'**, insert a Foley catheter into the bowel and inflate the balloon to hold onto the colon and prevent it falling into the abdomen and leaking content during closure.

**If you perforate the colon whilst mobilizing it**, mark the defect with a tissue forceps or suture and continue full mobilization of the loops of colon. Resect down to intact well-vascularized bowel, and make a formal end-to-end anastomosis (11.3)

**If you cannot mobilize the colon because of adhesions**, make a formal laparotomy to divide the adhesions from inside. You will need a good light and an assistant providing good retraction.

**If the wound leaks faecal matter**, there is a fistula (11.15). Open the wound, clean it thoroughly and apply a bag. Restrict the oral intake initially to fluids, and later to a low-residue high-calorie diet. The fistula should close in 3-4wks.

## 11.7 Feeding jejunostomy

Occasionally, you may need to make a feeding stoma to allow enteral nutrition if there is proximal obstruction. This is an alternative to a gastrostomy (13.9). Feeding jejunostomies are seldom needed, but they can be life-saving: for example, when a suture line in an injured duodenum needs protecting. To reduce the danger of a leak, introduce the tube into the bowel through a long oblique track.

You may occasionally use a feeding jejunostomy in a high-output fistula, using Foley catheters (11.15).

### FEEDING JEJUNOSTOMY (GRADE 3.2)

#### INDICATIONS.

- (1) An oesophageal obstruction which is correctable.
- (2) To protect a suture line in the duodenum following an injury or operation for duodenal atresia.
- (3) To protect a suture line in the stomach which has leaked.
- (4) A pancreatic abscess.

#### METHOD.

Make a small laparotomy in the upper abdomen. Find the upper jejunum by following it downwards from the ligament of Treitz. Confirm you have found the duodeno-jejunal junction by identifying the inferior mesenteric vein along its left border and feeling it emerge from its fixed position behind the peritoneum. Take a loop about 25cm from the duodeno-jejunal junction, and make an incision on its ante-mesenteric border through the longitudinal muscle layer for about 8cm. At the distal end of this make a hole through into the lumen. Insert a feeding catheter (Ch18 for an adult), or a long Ryle's tube, through this hole for about 10cm. Close the bowel around it with continuous absorbable suture (11-17C).

If the bowel wall is thin and you are afraid of tearing it, make a hole in the jejunum for the feeding tube, and then create a tunnel to bury it by suturing together the bowel wall longitudinally over it.

Make a 2<sup>nd</sup> incision in the abdominal wall at least 8cm lateral to the midline (to avoid the epigastric vessels) above where this loop of jejunum will comfortably lie. Draw the end of the tube back through the abdominal wall. Fix the jejunum longitudinally to the inside of the abdominal wall together with an absorbable suture, so that the jejunal suture line is now extra-peritoneal, *taking care not to create a space for an internal hernia*. Close the abdomen and anchor the tube to the abdominal wall with a 'Saxon stocking' type of anchoring suture (11-17E), attached to a purse string.

To remove the tube, snip the ligature anchoring it to the skin, and pull. The long oblique tunnel through the mucosa and submucosa will seal rapidly. The purse string anchoring it to the peritoneal wall will prevent the jejunal contents soiling the peritoneal cavity.

#### DIFFICULTIES WITH JEJUNOSTOMY

The tube readily blocks, especially if it is of narrow bore. Always flush it with water after use. *Do not introduce crushed tablets down the tube*: they will block it. If this has happened, try passing a long guide-wire gently down the tube, if flushing it does not clear the blockage. Make sure the tube is not kinked or twisted. Carbonated drinks or hydrogen peroxide may succeed in flushing the tube, if water does not. Otherwise, introduce some gastrografin down the tube and take a radiograph to see where it is blocked. In the last instance, you may have to replace it.

**If the patient has persistent diarrhoea after feeds,** you may have placed the feeding tube in the ileum. Insert some contrast material down the tube and take some abdominal radiographs quickly afterwards to see if its passage in the small bowel is very quick and short.

### A FEEDING JEJUNOSTOMY

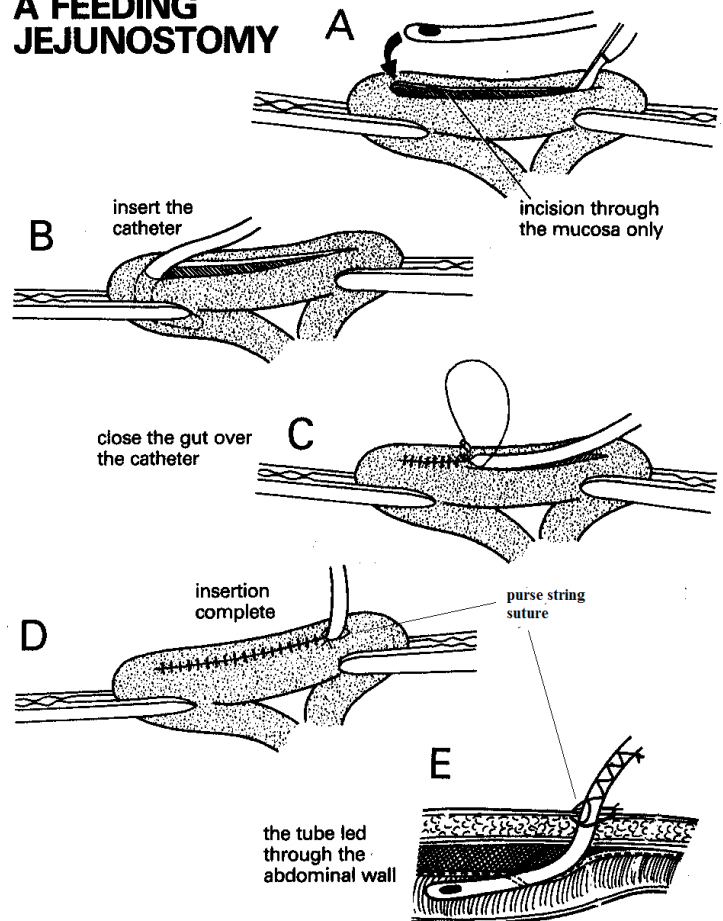


Fig. 11-17 MAKING A FEEDING JEJUNOSTOMY.

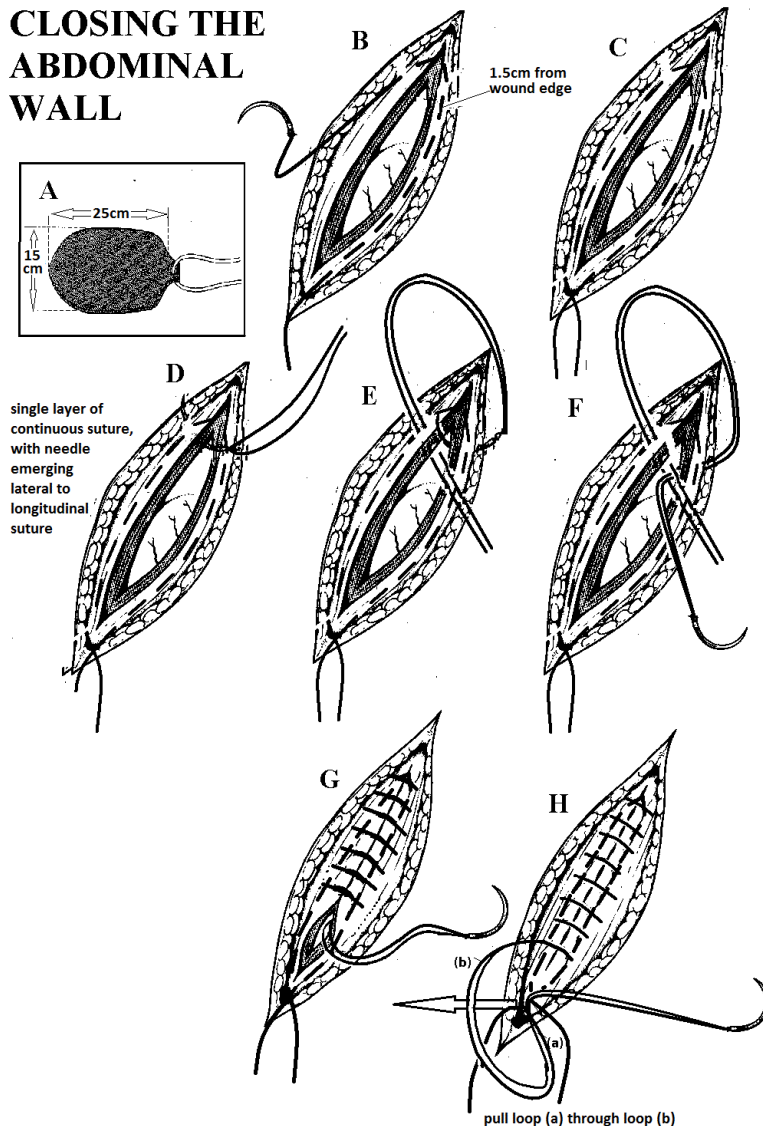
A, the incision. B, insert the tube. C, close the jejunum over the tube with a continuous absorbable suture. D, fix the tube in the bowel. E, lead the tube out through the abdominal wall, and fix the jejunum longitudinally to it, with a purse string.

Rarely, a type of necrotising enterocolitis occurs after feeding is started via a jejunostomy (14.4).

## 11.8 Draining & closing the abdomen

After a laparotomy consider if you wish to close the abdomen primarily. Leave it open (11.10), if closure would be too tight because of bowel distension or packs left in the abdomen, or if you plan a 2<sup>nd</sup> look laparotomy (10.1). Occasionally, even if you cannot safely close the fascia, you can close the skin: in this case do so with interrupted mattress sutures. This is easier to handle post-operatively.

### CLOSING THE ABDOMINAL WALL



**Fig. 11-18 CLOSING THE ABDOMEN. EVERETT'S METHOD:** A, a rubber 'fish' to press down on bowel to prevent it getting in the way. B,C, inserting the longitudinal subcuticular suture 1.5cm from the wound edge: (you may prefer to put this suture in last). D, inserting the deep continuous suture lateral to the longitudinal one. E,F, making a buried knot, or alternatively pulling the thread through a loop. H, catch the loop in subsequent bites as a locking suture, taking sufficient width of sheath. Prepare for the Aberdeen knot closure (4.13) and tie this. With the anterior & posterior rectus sheaths closed, you may leave the skin open for secondary closure if there is much sepsis. Partly after Agharwal A. et al. Reinforced Tension Line Suture Closure After Midline Laparotomy in Emergency Surgery. Tropical Doctor 2011;41(4):193-6.

Normally though you have 2 layers to be closed: the peritoneum, which is fused to the posterior rectus sheath and the anterior rectus sheath. Close these layers together in a mass closure by the modified Everett method, which leaves knots within the muscle layer where they cause no discomfort. An ideal suture is a long-lasting absorbable monofilament such as PDS (4.6).

Consider leaving the skin open if there is severe sepsis. This will reduce the risk of wound infection in high-risk cases in the same way as in wounds of other kinds. Antibiotics are less effective than leaving the skin wound open for a few days (see below). Otherwise close it as a separate layer.

A subcuticular skin suture leaves a neater scar, and probably is less prone to infection because the needle does not go through the skin surface; however, it is liable to dehiscence if there is anything to cause abdominal distension or bleeding postoperatively. So *do not use it if there is a lot of ascites, thrombocytopenia, or severe infection. Do not insert subcutaneous fat sutures: they serve only as foreign bodies and are unnecessary.*

#### LAVAGE.

Before you close the abdomen, make quite sure that, if it is contaminated, you wash it out *completely* with warm water (10.1).

**DRAINS** are not useful, except for localized abscesses, or leaks of bile, pancreatic juice or urine (4.9), or draining extraperitoneal spaces.

#### FINAL CHECKS. (1.8)

Check the operation site thoroughly before you close the abdomen to make sure that you have restored the anatomy as you wish, that there is no bleeding, and no leakage from hollow viscera. Close any mesenteric defects. *Make sure that you have left no instruments, swabs, or packs behind.* It is reckless to rely only on a swab count! *Never use small gauze pieces or sponges inside the abdomen: they too easily get lost!*

#### PREVENTING ADHESIONS.

Bring the greater omentum down so that it underlies the incision. This will help to prevent adhesions forming between the viscera and the abdominal wall.

The **MODIFIED EVERETT MASS CLOSURE METHOD** should be your standard way of closing the abdomen. It is best to use a looped suture; if you don't have a ready-made one, take a piece of #1 monofilament 6 times the length of the incision, thread onto it a 65mm ½ needle, fold it in half, and tie a 'figure-of-8' knot at its end, thus creating the looped suture. Alternatively, use a single strand, *but make sure the knot is secure when you tie it.*

Make sure the abdominal wall is relaxed: if the patient is pushing, ask the anaesthetist to increase his relaxation, or if you are operating under ketamine, add diazepam IV. Press down on the bowel with a 'fish' (11-18A) to make sure you don't catch a loop of bowel in your suture. This is a piece of stiff rubber sheet (such as that from a car tyre inner tube) with a tail on it. Alternatively use a specially constructed curved bowel depressor or the handle end of a Morris retractor. *Do not use your assistant's hands as retractors while you are putting in deep sutures!* Put your hand inside after every suture to check nothing is caught. *Do not put sutures in 'blind'.* Insert a longitudinal suture using a 65mm ½ circle needle parallel to the *linea alba* (11-18B), starting at the lower end of the incision, as a continuous suture on both sides (11-18C), after first clearing the fat c.2cm from it. Hold the ends of this suture by haemostats inferiorly.

Then place the continuous suture using again a 65mm ½ needle, taking care the points are introduced lateral to the longitudinal suture (11-18D) by passing the needle from between the anterior and posterior layers of the rectus sheath out anteriorly, then going from the outer surface of the anterior rectus abdominal muscle inwards (11-18E) on the opposite side of the wound. Thread the needle through the loop if there is one (11-18F).

Otherwise, tie the knot carefully and securely with multiple throws so as to bury the knot between the layers. Proceed all the way along the wound like this taking deep bites and not pulling too tightly (11-18G). Place the sutures about 1cm apart. At the end of the wound come out anteriorly, pull one loop through another (11-18H) and tie an Aberdeen knot (4-13), burying the end of the suture between the layers.

Then pull the longitudinal suture taut and tie it, taking care not to pull it excessively as the function of this suture is to distribute the pressure on the tissue. Too much tightening will lead to bow stringing. *Take care that no bowel loops are caught within either suture.*

The longitudinal suture is an added safeguard in emergency surgery: however, for a clean elective procedure, you may omit it.

**If you have made a transverse incision**, close the peritoneum with the posterior rectus sheath, and then the anterior rectus sheath in 2 separate layers.

**If you have made a Pfannenstiel incision** (11-4), close the sheaths transversely.

**SKIN CLOSURE.** Now either close the skin with subcuticular absorbable or with continuous or interrupted monofilament; subcuticular closure leaves a neater scar and probably is less prone to infection because the needle does not pass through the outer skin surface. Use skin clips if you have them. Alternatively if the wound is very septic, leave it open for a few days for delayed primary skin suture later.

**CAUTION!** If you use interrupted sutures,  
(1) *do not take the bites too close to the wound edges,*  
(2) *do not make the sutures too far apart, &*  
(3) *do not make them too tight.*

#### DELAYED PRIMARY SUTURE FOR POTENTIALLY INFECTED ABDOMINAL WOUNDS

**INDICATIONS.** Severe sepsis which contaminates the abdominal wound puts the patient at risk, especially from:  
(1) Caesarean Section in the presence of infected amniotic liquor.

- (2) Appendicitis.
- (3) Perforation of the ileum.
- (4) Perforations of the colon.
- (5) Excision of gangrenous bowel.
- (6) Generalized peritonitis.

**METHOD.** Use this where there really is a lot of sepsis with litres of purulent fluid in the belly, *not just for the localized case.* Close the muscles of the abdomen as above. Make the sutures just tight enough to bring the muscles of the abdominal wall together and prevent the bowel escaping. Test this as you go along by feeling the inside of the wound with your finger, as if it were a loop of bowel trying to escape. Then put a betadine dressing on the wound. Use antibiotics only if the condition you are operating for demands their use.

At 3-5days, examine the wound. If it is clean, close it by delayed primary closure. If it is infected, apply hypochlorite, saline or betadine dressings regularly until it is fit for secondary suture, or secondary skin grafting. Occasionally, you will find the wound already healing so well, that it will close spontaneously. If so, let it do so.

#### CAUTION!

- (1) *NEVER close the fascia or muscle of the abdominal wall with catgut or short-acting absorbable.* It will be absorbed too soon, and increase the risk of early bursting and later herniation.
- (2) *Do not use braided silk*, which increases the risk of sinuses.
- (3) Make the sutures just tight enough to bring the edges of the muscles together; *do not strangle them.*
- (4) *Avoid closing the peritoneum with non-absorbable sutures*, as there is a higher risk of adhesions.
- (5) Take care to pick up the posterior rectus sheath and peritoneum in the lower abdomen, as it might retract laterally so be difficult to see; otherwise an incisional hernia will result.
- (6) *Do not try to close the abdominal wall and skin in a single layer.*
- (7) *Do not close the abdomen if bringing the abdominal edges together is a struggle:* the abdominal compartment syndrome will result (11.10). Instead, place a vacuum dressing over the open abdomen (11-20).

#### DIFFICULTIES CLOSING THE ABDOMEN

- (1) Get the patient fully anaesthetized.
- (2) Make sure you decompress the bowel (12-4) and make sure a nasogastric tube is in place.
- (3) Consider whether you should leave the abdomen open (11.10) rather than closing it.



## 11.9 After an abdominal operation

If you have struggled hard to save a patient in the theatre, it is tragic for him to lose his life in the ward afterwards. If you are working under difficult conditions, postoperative care can be at least as difficult as surgery. You will find an ICU very useful for any ill patient, and particularly for someone who is recovering from a major operation. The staff of even the simplest ICU should be able to check the vital signs, keep an accurate fluid balance, and watch for postoperative bleeding: careful monitoring is not difficult: it just needs care and frequent visits from you. If your nurses are not yet appropriately trained, you will gain much by taking time to explain and teach how to do this, initially doing much yourself. If you do not have an ICU, gather critically ill patients near the nurses' station in an ordinary ward, so that the senior nurse can watch them. The list below of the things she should check is a long one, but most of the checks are quick. Make sure the nurse has an appropriate chart to fill in observations. Above all, try to anticipate complications before they occur.

### POSTOPERATIVE CARE

**THE RECOVERY POSITION.** Nurse the patient on the side in the recovery (lateral) position. Turn him 2hrly.

### MONITORING.

**If a patient is critically ill**, make sure that, during the first few hours, some competent person checks every 15mins:

- (1) The level of consciousness.
- (2) The pattern of the respiration.
- (3) The peripheral circulation; the warmth of the extremities.
- (4) The capillary circulation in the nail beds.
- (5) The pulse and blood pressure.
- (6) The temperature.
- (7) The urine output.
- (8) The degree of pain, (in children, look at their face) and any improvement or worsening of pain.
- (9) Any bleeding and discharge from the wound.
- (10) Abdominal distension.

The nurses in the ICU must be on the look out for *any deterioration* and call for urgent help if they notice:

- (1) snoring, respiratory obstruction, depression or arrest,
- (2) bronchospasm,
- (3) aspiration of gastric contents,
- (4) rising pulse rate and falling blood pressure.
- (5) failure of the nasogastric suction to work properly,

*N.B. Nausea is usually due to hypotension.*

Later, during recovery, attention can change to:

- (1) Fluid balance.
- (2) Coughing and breathing exercises.

**IV FLUIDS.** Maintenance needs are c.3-4l/day for an adult; on top of this you can assume there is a fluid deficit from operative loss, intestinal ileus, and exposure. So use 2-3l Ringers lactate or 0.9% saline alternating with 1l 5% Dextrose per 24hrs.

**If there is any doubt about the adequacy of fluid replacement**, be sure to monitor the urine output. Only a very ill patient and some women need an indwelling catheter; remove it when it is not absolutely necessary. A Paul's tube (condom catheter) is often adequate in men.

**If you did not adequately replace the blood lost at operation**, the blood will be diluted by the first day, so measure the Hb or the haematocrit, and transfuse as appropriate.

**NASOGASTRIC SUCTION** will prevent the aspiration of vomit; it will remove gas and fluid and relieve distension (4.9), but will not reduce the duration of ileus.

**BOWELS.** If the patient is taking a high-fibre diet, he will probably have no difficulty with the bowels once any initial ileus has subsided. He is more likely to have difficulty if he is on a low-fibre diet and is not mobilizing. Start oral intake in small, gradually increasing amounts, as soon as post-operative nausea and abdominal distension settles.

**If he has passed flatus, but no stool by the 5<sup>th</sup> day**, administer a rectal suppository or enema.

**If he does not pass flatus and the abdomen remains distended**, suspect abdominal sepsis or a leaking anastomosis.

**PAIN.** Remember, though a wound heals side-to-side, it hurts end-to-end! If there is severe pain, use ½ the standard dose of pethidine or morphine IV initially, and then the other ½ 10mins later if the first was not enough. This is *much* more effective *and safer* than IM use. (*IM drugs are not absorbed rapidly enough.*) A useful method is to add further doses to the IV fluids 4hrly. Or, better, run it in continuously with the IV fluids. This makes sure that analgesia is continuous without a need to call the nurses. Morphine 5mg qid is an average dose for a fit adult. Use ½ or ¼ of this if the patient is very sick, thin or malnourished. By 3-5days he should have no need of injectable opioids, so taper them off, and occasionally, if necessary, replace them by an oral opioid.

*N.B. If the patient is restless, it is more likely to be due to hypoxia than pain! Treat this with oxygen. Do not use opioids if the respiration is shallow, or the systolic blood pressure <100mmHg.*

Tilidine oral drops (x1 per year of age up to 10) 4-6hrly are very useful for children.

### OTHER DRUGS.

- (1) *Do not use a hypnotic for 5-7 days*; it will not help while there is pain.
- (2) *Do not use an antiemetic without looking for a cause.* It may help if there is an inoperable carcinoma.
- (3) *Do not use an antibiotic*, unless there is an established infection.



**AMBULATION.** Encourage movement of the legs in bed. Do all you can to mobilize your patient early. Dependant immobile legs have a higher incidence of deep vein thrombosis than raised ones. This is more likely to occur lying in bed or sitting still in a chair than sitting still in bed.

### 11.10 Non-respiratory postoperative problems

Many complications can interrupt recovery, but you can prevent most of them. Important problems involve the lungs (11.11). Infections are more likely if there is cachexia, HIV disease (5.6), or diabetes.

In order to recover uneventfully from an abdominal operation, the bowel must start to work soon. The passage of flatus and bowel sounds show that the small bowel is starting to work; the large bowel starts 1-2 days later. If all goes well, eating should start in 2-3 days. This will be delayed after peritonitis, an anastomosis of the stomach or upper small bowel, or because of ileus (12.16), or anorexia from any cause, such as burns or severe sepsis. Unfortunately, the common IV fluids provide little energy and no protein, and you are unlikely to have the necessary solutions of proteins and amino acids for parenteral nutrition. However if you can provide some nutrition, as described below, it may be crucial. Most patients with sepsis are in a catabolic state and so need *greatly increased* levels of nutrition; if you cannot feed them, they will lose much weight very quickly.

#### POSTOPERATIVE BLEEDING AND SHOCK

Bleeding may be obvious but minimal, or hidden but catastrophic. *Don't make the mistake of failing to check for signs of circulatory failure* (3.5, 11.9).

#### POSTOPERATIVE VOMITING

**If there is vomiting immediately after the operation,** turn the patient on his side. It may be due to the anaesthetic, especially ether, or to morphine or pethidine. He is likely to recover quickly. If he vomits >8hrs or copiously at any time, start nasogastric aspiration.

**If there is vomiting after 48hrs,** this is likely to be more serious, cause severe fluid loss and may result in tracheal aspiration. It may be due to ileus, postoperative bowel obstruction, or rarely acute gastric dilatation. If you do not replace the fluids and electrolytes IV, severe hypovolaemia and hypokalaemia will ensue. Start nasogastric drainage to avoid aspiration of vomit.

**If there is vomiting with a distended, silent abdomen,** this is an ileus (12.16), which may be due to postoperative peritonitis (10.1) which also causes pain, fever, and toxæmia. The nature of the previous operation, such as a pelvic abscess or an injury to the large bowel, usually suggests its site. Later, watch for a localized abdominal collection, especially subphrenic (10.2). If the patient's condition deteriorates, think of the abdominal compartment syndrome.

#### POSTOPERATIVE URINE OUTPUT FAILURE

**If there is no urine output, or only a little, and the bladder is not distended,** look for:

- (1) Dehydration.
- (2) Hypovolaemia.
- (3) Renal tubular necrosis resulting in renal failure, caused by a period of low blood pressure during the operation.

*N.B.* Some urinary suppression is normal for 24-60hrs after major surgery, as a normal response to stress.

**If there is a little urine of high specific gravity, with obvious dehydration,** infuse 1-2l of saline as rapidly as you can. If the urinary output does not improve, check the central venous pressure; only if this shows adequate hydration, use a diuretic such as 0.5-1l of mannitol IV, or 40-80mg of furosemide IV. If this produces a diuresis, there was severe dehydration causing renal shut-down, but which is now recovering. If the kidneys produce no flow, there may be tubular necrosis and renal failure.

**CAUTION! Do not overhydrate a child.**

- (1) Treat him with 30ml/kg of fluid for the first 2hrs, and repeat it over the next 3-4hrs if necessary.
- (2) Before you diagnose anuria, make sure that the Foley catheter is not blocked and is properly situated in the bladder!

**If there is no urine passed, and the bladder is distended (dull to percussion),** this is urinary retention. It is common after perineal operations especially in elderly men. Try to initiate micturition by getting the patient to stand by the edge of the bed, and walk about if possible. Open a water tap: the sound of running water may make the urine flow; alternatively, put the patient in a warm bath: the warm water may help him relax. Stimulating the skin of the upper inner thigh may also help. If all this fails, introduce a urinary catheter.

#### POSTOPERATIVE FEVER

Most patients have a mild fever (<37.5°C) for 1-4 days after a major abdominal operation. This is insignificant.

**If there is significant fever postoperatively,** consider pulmonary collapse (11.11), pneumonia, wound sepsis (2.10, 11.13), urinary tract infection (especially if you have used a catheter), drug reaction, malaria, further intra-abdominal sepsis either under the diaphragm (10.2) or somewhere else, septicaemia or septic shock, or deep vein thrombosis.

**If there is persistent fever, and the general condition is not improving,** suspect that there is sepsis somewhere in the abdomen, especially if you operated for peritonitis, there was inadequate lavage of contaminants (pus, faeces or bile) during the operation, or an anastomotic leak. In this case you should re-open the abdomen before 48-72hrs (12.16). Examine the patient carefully every day. Sepsis after a clean abdominal operation suggests a serious problem, which you should deal with earlier rather than later.

**If there is, after 3-5 days, also a raised diaphragm and fluid in the costophrenic angle on a chest radiograph,** there is a subphrenic abscess until proved otherwise (10.2). Get an ultrasound scan (38.2K). If there is also diarrhoea with the passage of mucus, a pelvic abscess (10.3) is probably present. The passage of mucus is a particularly valuable sign.

Avoid 'blind' antibiotic treatment unless the condition is critical. It may merely mask the problem which will become worse later. Attempt to drain an abscess under ultrasound guidance. Try to get to the abscess extra-peritoneally if at all possible. *Do not contaminate a clean area of the abdomen with pus from an abscess which was walled off before!*

**If there is no evidence of peritonitis, no abscess on ultrasound, and you have no good idea of where the sepsis is coming from, do not launch into a difficult repeat laparotomy.**

**If there is obvious peritonitis, sepsis from a source unknown,** or details of previous surgery are unsure, perform a re-laparotomy.

#### POSTOPERATIVE FEEDING DIFFICULTIES

**If the return to normal eating is much delayed,** considerable weight loss will ensue. Encourage eating of the staple diet, such as rice, maize, or potatoes, and supplement this with nasogastric feeding (4.9), using the high-energy milk feed that you usually provide for malnourished children. Convenient mixes for 1l of feed are:

Dried skim milk	443ml	'Nespray'	86g	Evaporated milk	118g
Sugar	67g	Sugar	67g	Sugar	65g
Oil	52ml	Oil	86ml	Oil	54ml
Water	48ml	Water	811ml	Water	813ml

This provides 1370kcal/l. Using this alone needs at least 2l and preferably 3l od. You can add rice, maize or corn as well if you have a liquidizer. Watch the fluid balance, and add 10mmol K<sup>+</sup> od. Look for hidden sepsis which can destroy the appetite!

**If fluid intake by mouth is impossible,** pass a small nasogastric tube and start feeding with 200ml of a ¼-strength feed every 3hrs. Increase this to the limit of nausea and diarrhoea, up to 2-2½l of full-strength feed in 24hrs.

**If there is gross cachexia,** and you intend to perform an operation on the stomach or duodenum, fashion a feeding jejunostomy (11.7).

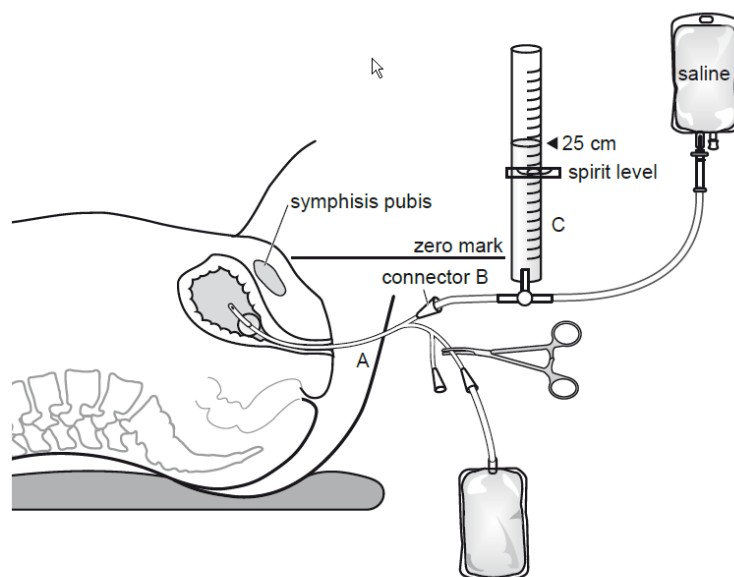
#### ABDOMINAL COMPARTMENT SYNDROME (ACS)

**If the abdominal closure is tense** because of oedematous or distended bowel (*especially in sepsis or after omphalocele closure*) or a too tight wound approximation (e.g. after an incisional hernia repair), rapidly increasing ascites or haemorrhage, there is congestion of the kidneys, inferior vena cava, diaphragm and mesenteric vessels.

This results in further abdominal distension, fall in urine output, pressure on the diaphragm, hypoxia and shock. ACS is a common life-threatening condition which is often not recognized, and often complicates abdominal sepsis. It can also happen in burns, especially of the abdominal wall, and after laparoscopic insufflation of the abdomen with gas.

You can diagnose ACS by emptying the bladder and then instilling 50ml (or 1ml/kg for children <20kg) of saline or warm water into it through a clamped catheter, and hold the fluid bag up vertically. Let the meniscus settle and wait at least 1min to allow for detrusor muscle relaxation; measure its height above the pubic symphysis with the patient lying supine at end-expiration. It does not give a reliable reading if there is a neurogenic or contracted bladder. A more reliable method, useful for continuous monitoring, is illustrated (11-19).

#### INTRA-ABDOMINAL PRESSURE MANOMETER



**Fig.11-19 MEASUREMENT OF INTRA-ABDOMINAL PRESSURE** A, bladder catheter. B, connecting tubing. C, manometer. Make sure the bladder is empty. Prime the circuit with fluid (*the flush solution doesn't need heparin*). Connect the tubing to the urinary drainage tube via a 16G cannula. Clamp the distal outflow, and instil 50ml into the bladder, and turn the 3-way tap so fluid flows into the manometer. Ensure this tube is vertical and open at its top and the zero level is at the level of the mid-axillary line or symphysis pubis (with the patient lying flat), then measure the pressure (in cm H<sub>2</sub>O).

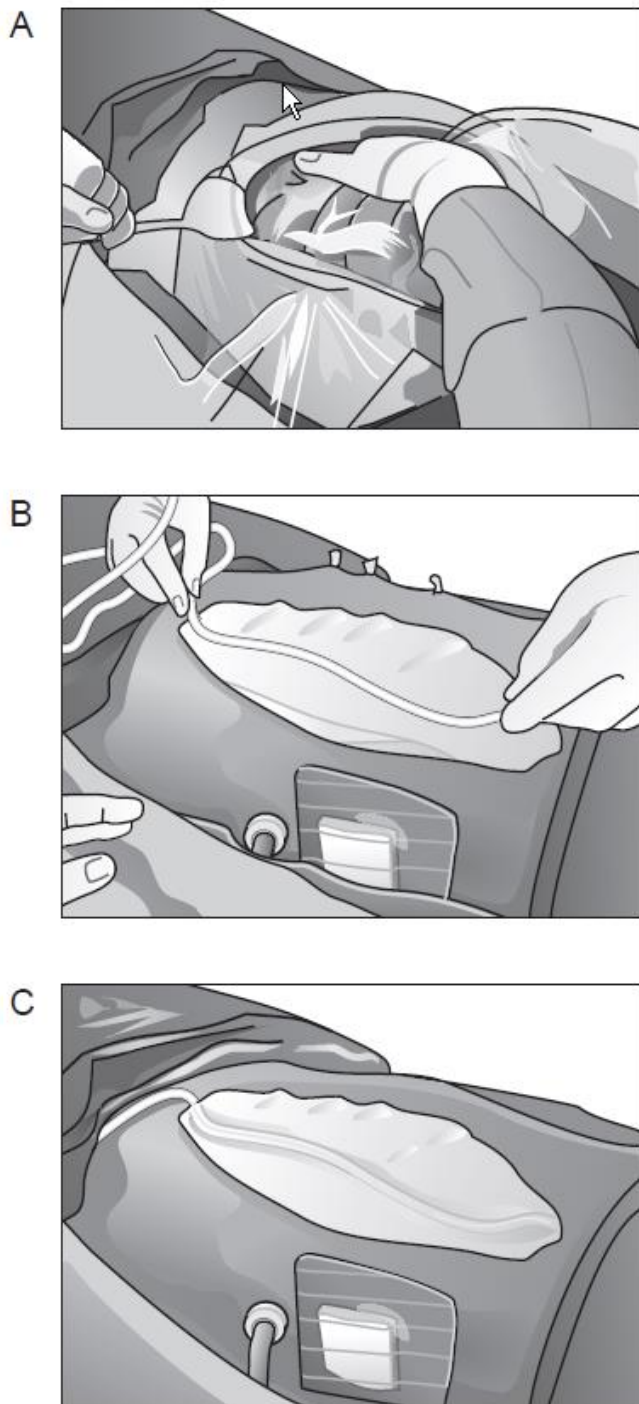
*N.B. A 2-way catheter avoids the need to connect the pressure tubing to the urinary outlet connections.*

**If the pressure is >16cm water (12mmHg),** there is intra-abdominal hypertension. Keep the catheter in to monitor the pressure 4hrly. Improve analgesia, sedate the patient, reverse any head-down position, insert a nasogastric tube, empty the rectum by an enema or manually if necessary, remove ascitic fluid by paracentesis if in gross quantities, and administer diuretics IV if the fluid balance is positive. Try metoclopramide or erythromycin to improve gastric emptying.

If the pressure is  $>27\text{cm water (20mmHg)}$ , ACS is confirmed.

*N.B. These measures may not be accurate in the presence of ascites, pregnancy, abdominal packs, obesity, active abdominal contractions or a neurogenic bladder!*

#### VACUUM ABDOMINAL DRESSING



**Fig. 11-20 VACUUM ABDOMINAL DRESSING.**

A, place a plastic over the bowel, and tuck it 10cm at least under the abdominal wall laterally. B, lay sterile gauze (or sponge) on top of the plastic. C, place 1-2 low-grade suction tubes within the gauze and seal the whole assembly with adhesive. *N.B. The other tube in B,C is an intra-peritoneal drain, separate from the vacuum dressing tube.*

You must, if ACS is confirmed, re-open the abdomen urgently, *and leave it open* (laparostomy). Avoid this scenario by leaving it open in the first place. Do this by placing a sterile plastic (11-20A) over the bowel and tucking this at least 10cm laterally under the abdominal wall edges, adjusting it so that no excess pressure is exerted by the plastic. On top of the plastic, place layers of gauze or sterile sponge (11-20B), and in the midst of these place 1-2 suction tubes (11-20C).

Attach to the tubes low-grade suction (5cm water). Seal the assembly with sticky tape making it air-tight.

Get an abdominal radiograph to check how many swabs and instruments are left inside.

If possible, keep the patient ventilated mechanically till you perform the 2<sup>nd</sup> look laparotomy (10.1); however, you do not need to continue ventilation long term normally. Change the dressings every 48-72hrs (nitrous oxide is usually all you need for sedation) till you can approximate the wound edges easily and close the abdomen.

Maintain nutrition by nasogastric or jejunostomy feeding and correct the fluid and electrolyte losses by carefully charting them.

*N.B. Covering the abdominal defect with a plastic (Bogotá) bag, sutured to the abdominal wall edges, without a suction appliance, is really only useful as a temporary measure because of hypergranulations, sutures cutting out, wound leakage and sepsis. The vacuum suction method is much more effective.*

### 11.11 Respiratory postoperative problems

If the respiratory tract is to function normally, it has to be clear of secretions. Frequently, this clearing mechanism fails, with the result that secretions accumulate, become infected and get into the lung. This may prove fatal. So you must encourage coughing, to bring up the sputum that might otherwise block the smaller bronchi and cause lung collapse.

Facilitating coughing is the purpose of most chest physiotherapy (11.12).

You can assess Peak Expiratory Flow Rate with a Peak Flow Meter (11-21): this is a simple device which will show how severe the bronchospasm or bronchoconstriction is. It is useful if you do not have a pulse oximeter.

Anything which will help mobilization will help the chest. This may not be easy, but any activity is better than lying in bed. Antibiotics are less important, but there may be a need for ampicillin, or chloramphenicol, if the chest infection does not resolve with physiotherapy, or is very severe initially.

## PEAK EXPIRATORY FLOW RATE - NORMAL VALUES

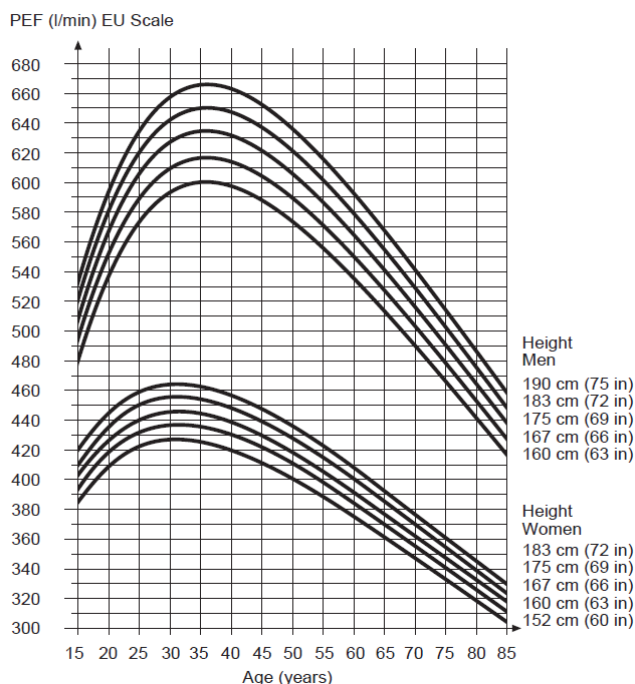


Fig. 11-21 PEAK EXPIRATORY FLOW RATE.

Measure this pre- and post-operatively especially if there is asthma, emphysema, or chronic bronchitis. Get the patient to take in a big breath and exhale forcibly into the Peak Flow Meter: use the best of 3 readings.

If coughing remains inadequate and breathing shallow, there are various ways in which you can suck out the sputum. Cricothyroid irrigation, tracheobronchial suction, and tracheostomy or 'mini-tracheotomy' (29.15) are heroic measures of the last resort but may be surprisingly successful.

## RISK FACTORS.

Respiratory difficulties are more likely if there is:

- (1) HIV disease.
- (2) Emphysema or chronic bronchitis.
- (3) A painful operation site, particularly in the upper abdomen or chest, which makes coughing painful, and so prevents expectoration of sputum.
- (4) Excessive opioid or barbiturate use.
- (5) Slow recovery from anaesthesia.
- (6) High spinal anaesthesia.
- (7) A history of smoking.
- (8) Dehydration, which makes sputum thick and more difficult to cough up.
- (9) Postoperative immobility as with a fractured femur or paraplegia.
- (10) Head injury or polytrauma.
- (11) Severe debilitation.
- (12) Sick-cell disease when cold or dehydrated, or an Hb <8g/dl

N.B. Babies always have greater risks of respiratory problems.

## COMPLICATIONS.

**If respiration is depressed**, and a tracheal tube is still in place, keep the patient in the recovery room until breathing is deep and regular. Anaesthesia may have been very deep, or the patient may be very ill. Attach a self-inflating bag to the tube and inflate the lungs. If this fails, the tube may be blocked with secretions (especially in babies): remove the tube, re-intubate and continue ventilation. *Otherwise, do not remove the tube until spontaneous breathing is adequate.* If the tube has been withdrawn, pull the tongue forward and insert an oropharyngeal airway. If this does not restore normal breathing, attach a mask and a self-inflating bag. If you treat postoperative respiratory depression vigorously, the lungs are less likely to collapse. If you have a ventilator, use it.

**If there is cyanosis, wheezing, or an expiratory stridor; or rapid breathing and tachycardia, or vomit on the lips**, suspect INHALATION OF GASTRIC CONTENTS.

Place the patient in the head-down lateral position. Suction out as much gastric content and secretions as you can. When you have the equipment prepared, intubate the trachea under direct laryngoscopy.

Pass a sterile suction catheter into the trachea and bronchi and aspirate through this. Turn the patient to one side, then the other, and then suck the fluid out again. Repeat this until the breathing is easy and quiet. Or, better, use a bronchoscope, and aspirate through this (29.14). Treat him with oxygen. If respiration is still poor, continue mechanical ventilation.

**If there is bronchospasm**, treat this with aminophylline 250mg slowly IV.

N.B. Bronchospasm can also be due to the inhalation of vomit, see above.

**If there is respiratory failure with cyanosis**, treat with oxygen through a face mask with 2 side holes for the air being exhaled. Continue oxygen after tracheal intubation.

## CLEARING THE RESPIRATORY TRACT

The following 3 situations need an antibiotic *and* physiotherapy to clear secretions from the chest.

**(1) If there is a cough, confusion, restlessness, fever, tachycardia, cyanosis, rapid or irregular or grunting breathing, with flaring of the alae nasi**, there is a serious postoperative lung complication.

**(2) If, in addition**, there is dullness to percussion over the bases of the lungs, usually on the right, with decreased breath sounds and bronchial breathing, low-pitched rhonchi, and radiographs show basal segmental areas of increased density, thick mucus has plugged the smaller bronchi, and caused the lung distal to them to collapse.

**(3) If, in addition to the above signs of lung collapse**, there are mucopurulent sputum, rhonchi, and toxemia, this is bronchitis, bronchiolitis, or pneumonia.

**CRICOTHYROID IRRIGATION** will usually stimulate coughing. Under LA, push a needle and cannula combination ('intracath') on a syringe through the cricothyroid membrane in the midline. Aspirate to make sure that you withdraw air, and then remove the syringe and push the catheter in another 2cm to be sure it is well inside the trachea. Suture it in place, and plug the opening to make sure that air does not go in or out. Instil 2-3ml of saline several times a day to stimulate the cough reflex.

**TRACHEO-BRONCHIAL SUCTION** is useful if there is a 'bad chest' and you think that chest complications are likely after surgery. Leave the tracheal tube in for 24-48hrs, so that you can suck out the chest through it. Vigorous coughing will not be possible, but you will be able to aspirate the chest frequently.

Before you aspirate, turn the patient to one side and instil 5-10ml of saline into the trachea. This will help to liquefy the sputum and will make suction easier. Turn the patient to the other side and repeat it.

Make sure there is a Y-connection on the suction tube. Release your thumb from the side arm intermittently to prevent you aspirating too much air, and making the bronchi collapse.

If you have a flexible bronchoscope with efficient suction, you can pass this through the tracheal tube and aspirate under direct vision.

**If you have already removed the tracheal tube that was in place during the operation**, and have done everything you can to initiate coughing, consider passing a nasotracheal tube, and sucking out the chest through that.

**TRACHEOTOMY.** If other methods of aspiration, including bronchoscopy (29.14) fail; or you need to continue intubation for >5days, perform a tracheostomy (29.15), and suck out the bronchi through this. If you have bypassed the nose with anything but a mini-tracheotomy tube (see below), humidify the air, if necessary with a steam kettle. It will help facilitate coughing. If you have a steam room, use that for the 1<sup>st</sup> wk.

'**MINI-TRACHEOTOMY**' is the most practical way to suck out the trachea. Use a small (4mm) tube (preferably a disposable 'portex' one). Using LA with adrenalin solution, insert it through the cricothyroid membrane using a guarded scalpel and an introducer. Failing this, use a 4mm paediatric tracheotomy tube and pass a Ch10 suction catheter down it. A tube of this size is not large enough to obstruct the respiratory tract, and there is little bleeding.

You will avoid the complications (particularly stenosis) of the cricothyroid approach using a large tube. It will then be possible to speak, cough, eat, and drink. Use humidified inspired air normally without the need for sedation or anaesthesia. The wound heals quickly with little scarring.

## 11.12 Respiratory physiotherapy

Some simple physiotherapy will often prevent the complications described in the previous section. If a high-risk patient (11.11) is to have an elective operation this physiotherapy should start *before* the operation. You may have no physiotherapist, so you may have to learn these skills yourself, and teach them to your nurses and to the relatives.

### CHEST PHYSIOTHERAPY CAN BE LIFE-SAVING

**PRE-OPERATIVELY**, take the patient through the motions of breathing in deeply through the nose and mouth. Either, sit him up at 70° well supported from behind by a back support, and with a bolster to prevent the knees slipping down. Or, lay him on his back with the knees bent. Put your hands on the chest during breathing efforts. Recommend about 6 breaths only at a time, otherwise dizziness may result.

**CAUTION!** Be sure to explain why these exercises are so necessary.

### PHYSIOTHERAPY

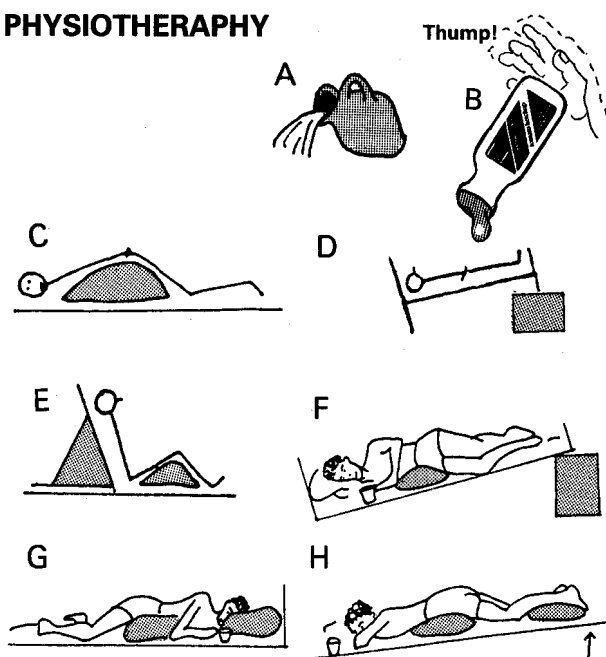


Fig. 11-22 CHEST PHYSIOTHERAPY.

A, if secretions are sufficiently liquid you can pour them out of the chest. B, if they are viscid, you may have to shake them out of the bronchi by percussing the chest in the same way that you can percuss tomato ketchup out of a bottle! C, you can lay a patient with his hips on pillows, so that the hips are higher than the shoulders. D, you can raise the foot of the bed. E, you can sit the patient against a back-rest with pillows under the knees. F, you can raise the foot of the bed and put a pillow under the hips. G, if the patient is too weak to sit up, you can rest him against a pillow and lay him on the side. H, you can use the prone position with a pillow under the hips and the foot of the bed raised. After Hardinge E, Wilson PMP. *A Manual of Basic Physiotherapy*, TEAR Fund 1981.



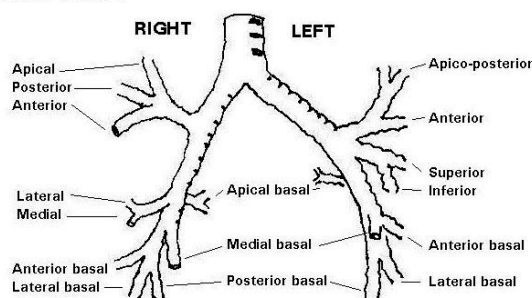
POSTOPERATIVELY, adequate analgesia is a big help. Encourage proper deep breathing, moving about in bed, and getting up as soon as possible.

Position is important; *avoid the semi-recumbent 'slumped' position*, because this restricts movement of the diaphragm, and promotes the collapse of the lower lung lobes. Encourage sitting up with a back support. Insist on early mobilization by the 2<sup>nd</sup> day, if you can, even if there is an IV line, catheter or chest drain to trail around. Encourage the exercises already learnt. An 'incentive spirometer' is very useful.

**COUGHING.** Distinguish between an effective deep productive cough (which is what you want) and a noise in the throat, which is useless. Several short expiratory 'huffs' before coughing will help to loosen the secretions. Suggest taking a deep breath after each cough, and *not to cough continually without pausing*.

**If there is an abdominal wound**, it is essential to bend the knees, hold the wound, maybe with a pillow, and then to take a deep breath and cough. Give reassurance that the wound will not split open (if your closure is adequate!). If you can, use vibration during coughing.

#### A BRONCHIAL TREE



#### B BRONCHO-PULMONARY SEGMENTS

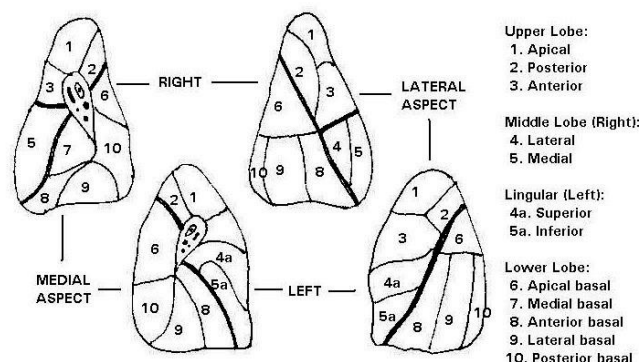


Fig. 11-23 BRONCHO-PULMONARY SEGMENTS. The bronchial tree leads to separate bronchial segments.

**HUFFING.** A 'huff' is a rapid forced expiration without a cough. Huffing, when the lungs are in full inspiration, will dislodge secretions from the larger airways. Huffing, when they are half full, will dislodge secretions from the smaller airways. So encourage huffing in both phases, with periods of relaxation and abdominal breathing between them. Do this every hour from the day of operation; make checks bd for the 1<sup>st</sup> 48hrs.

**CAUTION!** To be effective a 'huff' must be long and controlled, using the abdominal wall, and not spasmodic. The noisiest 'huff' is not necessarily the best.

**PERCUSSION AND VIBRATION.** Percuss the thorax over a towel or blanket with your cupped hands for periods of about 1min. Then rapidly shake the chest during expiration. Relax during inspiration, and follow this with some deep breathing. Repeat this 2-3 times.

**POSTURAL DRAINAGE** will be useful if there is much fluid in the bronchi. Listen carefully to the chest, and examine the chest radiograph. Decide where the secretions are worst, and arrange the patient so that this affected part is uppermost, using the appropriate position (11-24). Encourage deep breathing for 10mins, vibrate and slap the chest for 10mins, then repeat the breathing. If there is established collapse or infection repeat this bd/tds.

**If the patient is too ill for the hips to be raised**, lay him on his side. If the secretions are viscid, ideally he needs inhalation therapy to 'loosen' them prior to physiotherapy: steam with Friar's balsam or saline with mucolytics from a nebulizer.

#### POSTURAL DRAINAGE

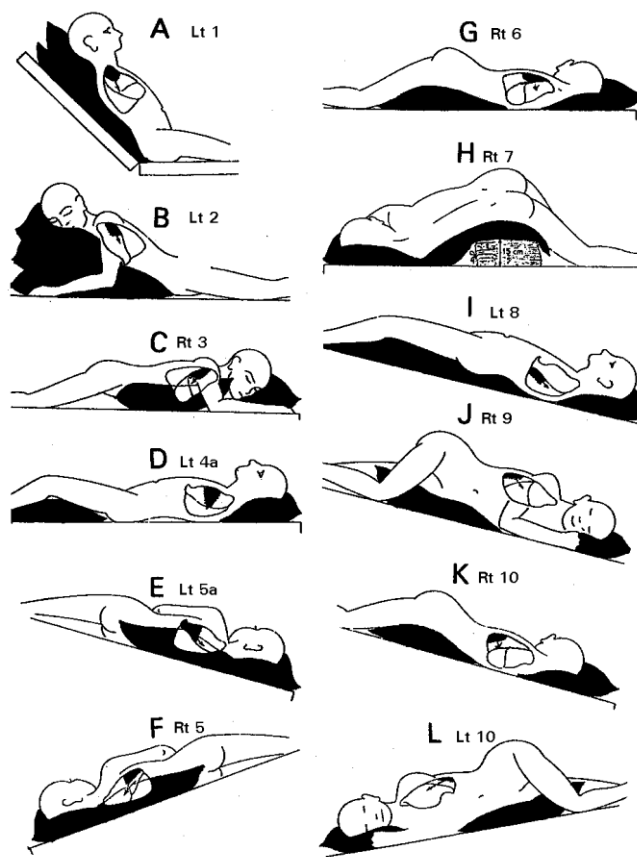


Fig. 11-24 POSTURAL DRAINAGE. Positions which allow gravity to promote the drainage of secretions from particular parts of the lung. Study the chest radiograph, and decide which position will be best. Positions correspond to the following segments: A, left upper apical 1. B, left upper posterior 2. C, right upper anterior 3. D, left superior lingular 4a. E, left inferior lingular 5a. F, right middle medial 5. G, right lower apical 6. H, right lower medial 7. I, left lower anterior 8. J, right lower lateral 9. K, right lower posterior 10. L, left lower posterior 10.

Kindly contributed by Lynne Wilson



### 11.13 Abdominal wound infection

A laparotomy wound usually remains tender for 7-10 days after an operation. If it is abnormally tender and indurated, associated with fever, it is probably infected. Infection may also be elsewhere: in the abdominal cavity, in the chest, or elsewhere. Sometimes the site of infection may be unclear.

Be guided by the severity of the symptoms. More severe anorexia, fever, and malaise, should all make you suspect an abdominal abscess, for example. Consider whether a wound infection is a sign of deeper trouble.

**If many of your wounds become infected**, look at your sterile procedures and leave any but completely clean wounds open (11.8).

#### POSTOPERATIVE WOUND INFECTION

**If the wound is red, painful, and tender, and discharges pus**, it is infected, so start by removing 1-3 skin sutures on the ward. This will show you the extent of the infection. Take a Gram stain of the pus. If it seems to be deeper, but is still extraperitoneal, use sedation with pethidine, ketamine or diazepam, and press the sides of the wound, and probe suspicious areas with sinus forceps. *Do not open up the deeper layers of all infected wounds from top to bottom, or remove the deeper sutures.* The peritoneum will probably have healed in spite of the infection, but the sutures in the fascial layers will probably pull away. If pus flows adequately, drainage should be adequate. Irrigate the wound with ¼ strength hydrogen peroxide, or hypochlorite solution. It's best to use a 10ml syringe with a 24G needle attached: break off the needle from the plastic hub: the resulting apparatus will produce the ideal spray. Pack it with dry gauze, or gauze soaked in a mild antiseptic, and change this 1-3 times daily. You can speed up the cleansing of a wound by applying a suction dressing; commercial vacuum sponge dressings are available but expensive. You can make your own by simply placing a fenestrated drainage tube, attached to a suction device, between layers of gauze and sponge, and sealing the whole assembly against intact skin with adhesive ('opsite' is best). The seal must be air-tight, and you therefore need to make sure the surface is quite dry before trying to stick any adhesive. Use a suction pressure of 50-125mm Hg.

#### CAUTION!

- (1) Make a wide enough opening to release the pus.
- (2) Test the glucose and HIV status if the wound infection occurs after clean surgery.
- (3) *Do not resort to antibiotics unless there is cellulitis present:*

**If the surrounding area is inflamed**, there is cellulitis. (6.22) Treat this with IV gentamicin (if you suspect Gram-ve organisms), or cloxacillin (for Gram+ve organisms).

**If the wound smells putrid**, suspect an ANAEROBIC INFECTION. Treat with oral metronidazole and chloramphenicol. If there is abdominal tenderness near-by, suspect peritonitis and re-open the abdomen; otherwise check for development of a faecal fistula (11.15). Remember if you have inadvertently caught bowel in a suture closing the abdomen, this is how the problem usually firsts presents.

**If you see necrotic muscle or fascia, when you remove skin sutures**, debride the dead tissues urgently and lay open the wound widely. Sepsis can spread very quickly and be fatal (6.23).

**If the wound is tense, swollen & bruised, with old blood exuding from between the sutures**, suspect a haematoma. Under sedation, remove a few of the skin sutures, and wash out old blood and clot with water.

Lift out more clots with a swab. Irrigate the wound with hydrogen peroxide, and leave it open. If it is clean after 5 days, consider secondary suturing.

**If the wound discharges a little brownish fluid which smells mousey**, suspect GAS GANGRENE (6.24). This is commoner than you probably think. Obvious gas in the tissues is uncommon, so that gas gangrene is often missed. Remove all of the skin sutures, make a Gram film of the exudate, and look for Gram+ve bacilli. Treat aggressively with IV benzyl penicillin 10MU qid for 5 days and with metronidazole 1g PR or IV tid. Debride the wound, remove any dead tissue, and make sure you isolate this patient from other patients.

**If the wound discharges chronically**, there is probably a foreign body *in situ*. This is most likely a non-absorbable suture: infiltrate LA, widen the sinus and use a crochet hook to remove the suture knot. If the discharge persists, there may be a fistula (11.15) or a swab left inside the abdomen! Take a radiograph (most abdominal swabs should have a radio-opaque marker), and re-explore the abdomen carefully. Bowel may be caught in the swab, and need resecting *en bloc* (11-7). If there is neither foreign body nor fistula, check the glucose & HIV status.

### 11.14 Burst abdomen (Abdominal dehiscence)

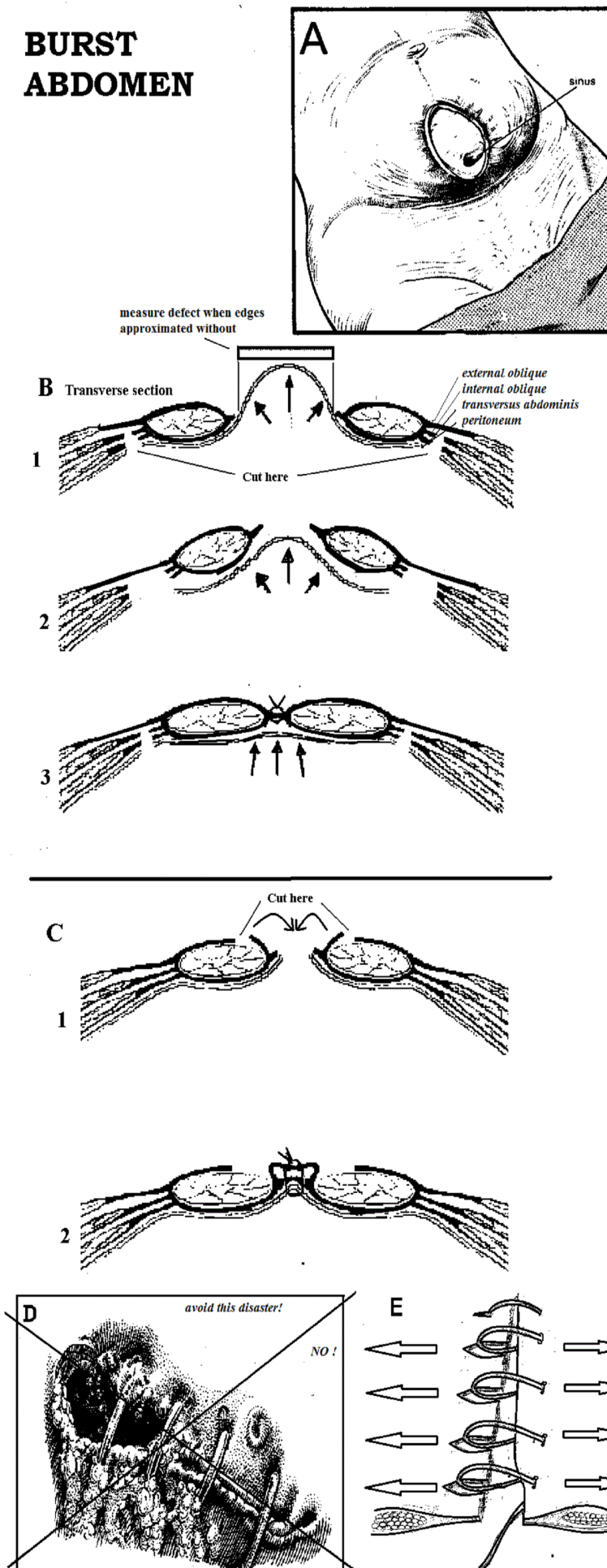
An abdominal dehiscence may occur because you should not have closed the abdomen in the first place! A burst abdomen results because either:

- (1) your suture breaks,
- (2) your knots slip, or
- (3) your suture cuts out through unhealthy tissues.

The abdomen is likely to burst if:

- (1) You have sutured the fascia with absorbable suture, especially if this is of low quality or out of date, or quickly absorbed, as with sepsis.
- (2) Your knotting technique is faulty.

## BURST ABDOMEN



(3) If there is significant abdominal distension due to ileus, intestinal obstruction, or a large tumour.

(4) There is severe intra-abdominal sepsis, such as an infected Caesarean Section, typhoid peritonitis, or a perforation of the large bowel.

(5) There is poor healing due to HIV disease, malnutrition, carcinomatosis, uraemia, or obstructive jaundice.

(6) There is a chronic pressure on the wound from prolonged coughing, asthma or chronic obstructive airways disease.

An abdomen which bursts some days after you have sewn it up is a tragedy, because it is often preventable, and because there is a 30% chance of death if subsequent treatment is delayed. Dehiscence is much rarer if:

(1) You suture the abdomen with non-absorbable, such as steel, nylon, or polyethylene.

(2) You close its muscles with interrupted through-and-through sutures, which are not too tight and take wide bites of tissue (11.8).

(3) You use a transverse rather than a midline incision.

**DIAGNOSIS.** If the wound is painful about a week after the operation, and there is a thin reddish-brown discharge, the abdomen is probably going to burst. **If you can see loops of bowel through the wound, it has already burst!** *Initiate treatment before it bursts!* Decompress the bowel by inserting a nasogastric tube, administering a rectal enema. Reduce oedema, if present, with diuretics. Measure the intra-abdominal pressure (11-19). Place a vacuum dressing over the wound.

**CLOSURE BURST ABDOMEN.**  
(GRADE 3.3)

**If there is a complete dehiscence** (with bowel spilling into the bed) examine the patient in theatre under GA unless he is very unfit. In this case, close the skin only under LA if it is not infected, knowing that an incisional hernia will remain. Otherwise, prepare for a laparotomy. Remove the skin sutures in the area where you suspect the burst. Remove the dressings and gently explore the depths of the wound.

**Fig. 11-25 CLOSURE OF BURST ABDOMEN.**

A, measure the defect after debridement, and approximating the wound edges without excessive tension. B & C, incise the *transversus abdominis* and *internal oblique* with diathermy along a line between the mid-axillary and anterior axillary line. D, recurrent burst abdomen and an intestinal fistula. E, the tension sutures are not helpful: the wound has broken down. (Detail from 11-26; after Esmat ME, *New technique in Closure of Burst Abdomen*. *World J Surg* 2006;30(6):1065) E, tension sutures cutting out as the intra-abdominal pressure rises.

Open it down its whole length by removing all the skin sutures. You will soon find out what has happened. If you confirm a burst abdomen, remove all sutures from the fascial layers. Gently separate the parietal peritoneum and the underlying bowel and omentum. Take care you do not damage bowel. Check if there is any evidence of intra-abdominal sepsis, and wash out the abdomen, and deal with its cause.

**If there is any tension when you try to pull the abdominal wound edges together,** measure the width.

*Do not try to force the abdomen closed under tension:* an abdominal compartment syndrome will result (11.10). There are 3 options but unless you have diathermy the first 2 will be too bloody to be safe:

**Option 1:** Make a long relieving incision *inside* the abdomen longitudinally (11-25B) between the anterior axillary and mid-axillary lines from the costal margin to the iliac crest, preferably with diathermy.

If you go through the *transversus abdominis* and *internal oblique muscles* only, without cutting the *external oblique*, no lateral hernia will form. You will gain 2cm for each side. If you need more, dividing the *external oblique* in addition at a position not directly above the previous incision will give you another 1cm each side; dividing the subcutaneous fascia in addition will give a further 1cm each side. You will therefore be able to close a defect 8cm wide without tension; for a bigger defect, use a vacuum dressing (11.10).

**Option 2:** Divide the anterior rectus sheath longitudinally in the midline *and* slightly laterally separating it from the muscle bulk (11-26C); then advance both sheaths towards the midline and close them with one continuous #1 non-absorbable suture.

**Option 3:** Place a vacuum dressing over the open abdomen, leaving it as a laparostomy: this requires you to decompress the bowel, return it to the abdominal cavity, and cover it with omentum onto which you place the dressing and suction drains (11.10).

**If there is no tension, and no sepsis present,** re-suture the abdominal wall with #1 interrupted steel or monofilament sutures. Suture from within outwards through the peritoneum, posterior rectus sheath, rectus muscle, and anterior rectus sheath, *but not through the skin*. Hold all the sutures out on haemostats until you have placed the last one.

## 11.15 Intestinal fistula

An intestinal fistula is an abnormal track, usually lined by granulation tissue, between the bowel and the skin. Fistulae are unusual but serious complications of abdominal surgery, and in HIV, tuberculosis, actinomycosis or Crohn's disease arise spontaneously. They may result from a neglected strangulated hernia. Beware of postoperative fistulae:

- (1) After you have divided adhesions for intestinal obstruction, especially if you have opened the bowel by mistake, and closed it inadequately, or if it is obstructed distally.
- (2) After an anastomosis done inaccurately, or in the presence of tension, a poor blood supply, or local disease.
- (3) If bowel is caught in the sutures, when you close the abdomen.
- (4) After appendicectomy especially when the base of the appendix was inflamed (caecal fistula).
- (5) If you use diathermy close to the bowel.

SUDHA (25yrs), a young housewife had an operation in a district hospital for 'appendicitis' through a McBurney incision. Five days after the operation the wound discharged large quantities of pus, and then liquid faeces and gas. She was fed on a low-residue diet, and the skin round the fistulous opening was painted and protected with zinc oxide paste. Absorbent dressings were changed tid and her distal colonic obstruction due to constipated faeces was treated with glycerine suppositories and a plain water enema. The fistula healed in 2wks and she went home.

LESSON Some fistulae will close on non-operative treatment.

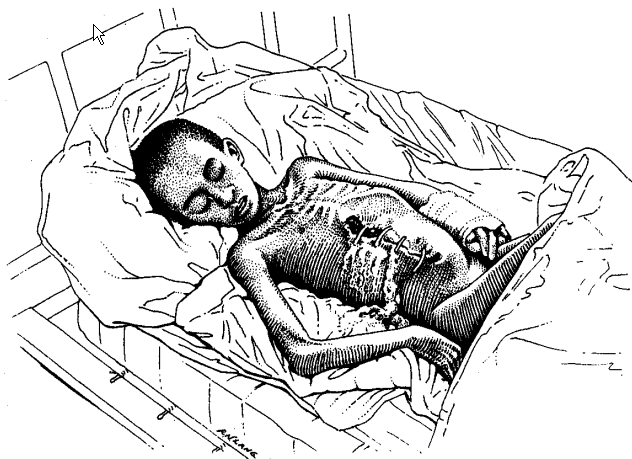The mortality rate of a high output fistula (>1000ml/24hrs) is 70%, and a low output one (<200ml/24hrs) is 30%. The repair of a fistula is one of the most difficult operations in surgery. *Do not be tempted to operate!*

**If intestinal content discharges from the main wound, or the site of a drain postoperatively,** there must be a bowel perforation. If the patient says that gas comes out, this confirms it; if you are in any doubt, get the patient to swallow some diluted methylene blue dye, and watch for it to appear in the wound or in the dressings. The speed at which it comes out may give you some idea of whether the perforation is high in the GI tract.

**If there is a localised discharge of bowel content,** insert a fine soft catheter into the track and inject 10-20ml of water-soluble contrast medium (take some plain abdominal films: a fistulogram) and you may be able to delineate from where the fistula arises, though static films are difficult sometimes to interpret.

Perform an ultrasound scan (38.2K) to detect any fluid collections in the abdomen.

## AN INTESTINAL FISTULA



**Fig. 11-26 AN INTESTINAL FISTULA.**

This patient was operated on for obstruction of the small bowel by *Ascaris* worms, and a length of it was resected. The anastomosis broke down; a fistula developed. He died a few hours later.

*Lesson (1): do not anastomose bowel in the presence of severe sepsis or ascaris. (2) do not close the abdomen under tension. This child would be better nursed as in 11-11.*

TREATMENT is supportive.

**Replace fluid and electrolytes**, orally, intravenously, or by jejunostomy (11.7). Large quantities of electrolytes as well as calcium, magnesium and phosphates may be necessary.

**Maintain nutrition**, orally, or by jejunostomy. You are unlikely to have IV protein and energy-rich fluids to treat the patient, but you can make up low-residue high-protein, high-calorie feeds to use enterally. The patient needs c.3-4 times the normal energy intake. *Restrict oral intake initially only whilst you are cleaning up the wound*, and then slowly increase fluid intake unless the fistula is so high that fluid pours out directly.

**If there is a proximal high-output fistula** and you can see or locate the bowel ends using a soft catheter and contrast medium, you can try to initiate feeding through the distal (efferent) loop using a small Foley catheter with the balloon inflated to 5ml only, and at the same time draining proximal intestinal fluid through another Foley catheter in the proximal (afferent) loop.

Unless there are further fistulae distally, you can allow this fluid to pass back into the distal part of the small bowel, thus by-passing the fistula. Antacids or anti-H<sub>2</sub> blockers will often be helpful.

**Care for the skin**, by applying karaya gum or zinc oxide carefully around the fistula so that the liquid intestinal juice, which is full of digestive enzymes, is kept from contact with the skin. At the same time, ensure free drainage either by nursing the patient prone (11-11F), or applying a well-fitting stoma bag, or applying a vacuum dressing with continuous suction (11.13). Milk or magnesium trisilicate applied to the skin will soothe the burning effects of small bowel effluent. Pure honey will help heal excoriated skin.

**Control infection** with antibiotics and drainage when necessary.

**Correct anaemia** with ferrous sulphate, vitamin B and folate. Transfuse blood if the Hb is <7g/dl.

**Keep the distal colon empty**, with enemas and glycerine suppositories on alternate days.

An intestinal fistula will close provided there is:

- (1) adequate nutritional support.
- (2) no foreign body involved.
- (3) no untreated inflammatory or malignant bowel disease.
- (4) no epithelialization of the track.
- (5) no distal obstruction.

*Do not be tempted to reopen the abdomen, unless there is frank peritonitis: it will prove to be a disaster worse than the first!*

**If there is frank peritonitis**, re-open the abdomen, exteriorize the bowel, and lavage the peritoneal cavity with copious warm fluid. *Don't try any more surgical heroics: the chances of your patient surviving are slim. Try to correct his physiology in an intensive care unit.*