

# 13 The stomach and duodenum

## 13.1 Peptic ulcer

Indications for surgery on a peptic ulcer in the stomach or duodenum include:

- (1) Closing a perforation.
- (2) Performing a gastrojejunostomy or pyloroplasty if the pylorus stenoses.
- (3) Stopping bleeding.
- (4) Performing an elective truncal vagotomy and pyloroplasty or gastrojejunostomy if there is a chronic disabling duodenal ulcer which has resisted medical treatment.

Peptic ulcers are a common cause of epigastric pain in most parts of the world. The underlying cause may well be *Helicobacter pylori*. You will need to take a careful history to diagnose and manage peptic ulcer disease. This can be difficult, so enquire how the patients in your community express their ulcer symptoms. They are unlikely to give you a clear history that their pain is relieved by food, or by antacids, for example, and their physical signs may be minimal. So, in spite of the limitations of the history, it may be the only way you have of making the diagnosis. When a patient presents with the surgical complications of peptic ulcer disease, you may have to enquire carefully to find out that there have been any previous ulcer symptoms.

The decision to abandon medical for surgical treatment will often depend on the social circumstances; omeprazole, cimetidine and antacids may cost more than the patient's salary if symptoms are chronic, so operation may be a reasonable cost-effective alternative.

*Do not forget that tuberculosis and burns can cause chronic gastric or duodenal ulcers, often leading to fibrosis and stricturing.*

**HISTORY.** Is there heartburn, dyspepsia, haematemesis or epigastric pain? If, so, how long for, and has it recently got worse? Does it have the features of peptic ulcer pain: epigastric, dull, boring, worse at night and when the stomach is empty; relieved by food, milk, antacids, vomiting, and belching; and aggravated by coffee, alcohol, and smoking? The periodicity of the symptoms is important at first. Is there any reason for stress, in the family or at work? Is there weight loss? Or black tarry stools?

### EXAMINATION.

Tenderness in the epigastrium may be the only physical sign. Look for other signs suggesting other diagnoses: tenderness over the gallbladder (cholecystitis), hepatomegaly (cirrhosis/hepatoma), oral candidiasis (oesophageal candidiasis), pancreatitis and epigastric hernia.

### MEDICAL TREATMENT.

No smoking, no alcohol, and frequent small meals may help the symptoms. Treatment with cimetidine 400mg bd or ranitidine 150mg bd for 4wks will cure 70% of duodenal ulcers. Extend this for 6wks for gastric ulcers, and 8wks for NSAID-induced ulcers.

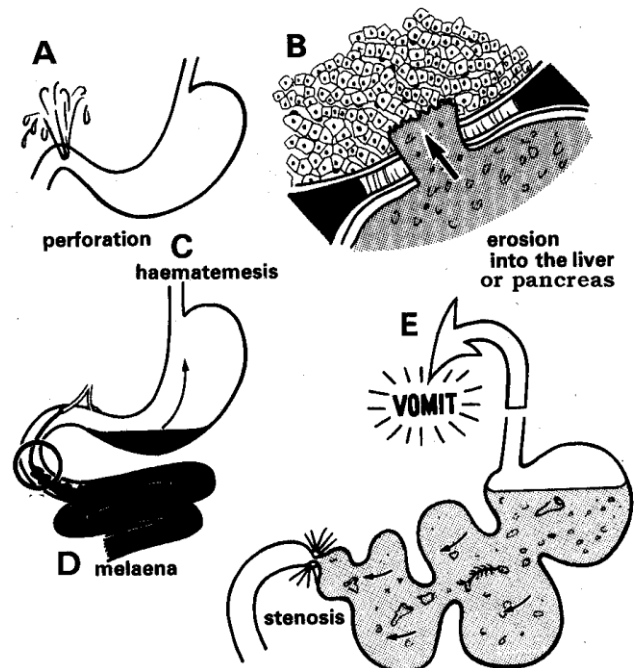
Treating with Magnesium or Aluminium compounds in addition will reduce the absorption of anti-histamines and so is not logical. Dietary restrictions are unnecessary. Bismuth compounds are often useful, as they 'coat' the mucosal surface, allowing it to heal.

**If *helicobacter* is common** (it usually is), a week's course of ranitidine 400mg, amoxicillin 1g, and metronidazole 400mg bd will eradicate it in c.90% and may be worth administering 'blind'. (Unfortunately, though, in some places, e.g. India, there may now be resistance to metronidazole.) Remember a breath or stool test may be negative unless you stop proton-pump inhibitors 2wks beforehand!

For proven ulcers which recur after proper treatment with cimetidine or ranitidine, it is worth trying proton-pump inhibitors: esomeprazole 40mg od, lansoprazole 30mg od, omeprazole 20mg od, pantoprazole 40mg od, or rabeprazole 20mg od for 4-8wks.

Alternatively misoprostol 200µg bd up to qid will help especially in the elderly who need NSAID's.

## COMPLICATIONS OF PEPTIC ULCER



**Fig. 13-1 COMPLICATIONS OF PEPTIC ULCERATION.**

A, anterior perforation of a duodenal ulcer. B, penetration into the liver or pancreas. C, haematemesis and melaena. D, pyloric obstruction. Note the hyperperistalsis and undigested food in the stomach.

## 13.2 Oesophagogastrroduodenoscopy (OGD)

You may be fortunate enough to have an upper GI endoscope; if you are, it is such a useful diagnostic tool, you should learn how to use it and care for it. As it is expensive and easily damaged, instruct a dedicated nurse to look after it, and *do not leave it to anyone*. It is very frustrating to find that your machine does not work when you need it urgently. Store the endoscope hanging up in a locked cupboard where it can remain dry. *Do not keep it in its case* which is easily stolen and where the flexible fibres can be damaged.

Keep the additional pieces carefully in a box, and the biopsy forceps from being tangled up or caught in doors. Store the light source and suction carefully from accidental damage.

You should try to find a room dedicated to endoscopy; this should have two trolleys for patients and one for the instruments. For endoscopy to be successful, you need:

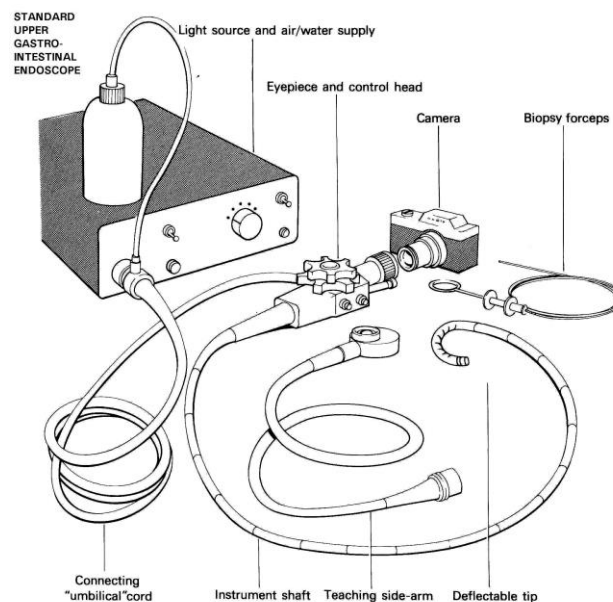
- (1) the endoscope,
- (2) a light source, with an air/water supply with a special water bottle,
- (3) a suction machine and tubing,
- (4) lubricating jelly,
- (5) local anaesthetic spray,
- (6) biopsy/polypectomy accessories,
- (7) cleaning brushes,
- (8) disinfectant and washing dishes,
- (9) IV sedation,
- (10) a mouthguard,
- (11) disposable gloves,
- (12) biopsy containers with formalin.

Hydrogen peroxide is useful for unblocking channels. A monitor and oxygen should be available. *Simple endoscopes do not require a TV screen.*

You also need an assistant, who ideally will be familiar with the instrument and has checked it before you start.

The endoscope has 2 controls which deflect the viewing tip up and down, or right and left; it also has 2 buttons for suction and blowing in air, and lastly a channel for passing a biopsy forceps or guidewire. It connects into the light/air source in a specific way; connection to the water bottle must be air-tight. Normally the endoscope is end-viewing, but some are side-viewing: these are rather more difficult to manipulate. The suction tubing connects to a specific spout. To be able to blow, which is essential, switch the light/air source on and switch it to 'blow'.

Test this by pressing the lower button with the endoscope tip in a bucket of water. Then test the suction by pressing the upper button. Make sure the biopsy channel is free by passing a lubricated wire or biopsy forceps through it.



**Fig. 13-2 STANDARD UPPER GASTRO-INTESTINAL ENDOSCOPE,**

*After Cotton PB, Williams CB, Practical Gastrointestinal Endoscopy, Blackwell 2<sup>nd</sup> ed 1982 p.2 Fig 2.1*

### TROUBLE-SHOOTING

**If there is no light**, make sure the mains fitting is working and the cable properly connected. Check the fuse box and the bulb: if necessary, replace them. If the view is dim through the endoscope and you see a mesh-like lattice pattern, the fibre-optic cables are worn and need replacing.

**If it is not blowing**, check the light/air source connecting 'umbilical' cord is properly pushed in, the switch turned to blowing mode and the water bottle connected air-tight with fluid in the bottle.

If all is well, remove the buttons, connect the cleaning device and flush with water. If this does not work, pass a brush down the blowing channel. If this also fails, flush the channel with compressed air. There may be some debris under the protective cap, at the end of the endoscope, through which the air bubbles out: clean this out with a fine needle. Take care when removing it not to drop it down the sink!

**If it is not sucking**, check the vacuum at the machine and that the tubing is properly connected and not collapsing. Remove the buttons as above, and flush and brush.

### METHOD.

Explain the procedure to the patient: you are more likely to get co-operation if he understands what is to happen. Make sure he is starved and the consent signed. *Do not attempt endoscopy if you suspect he may have a perforation!*

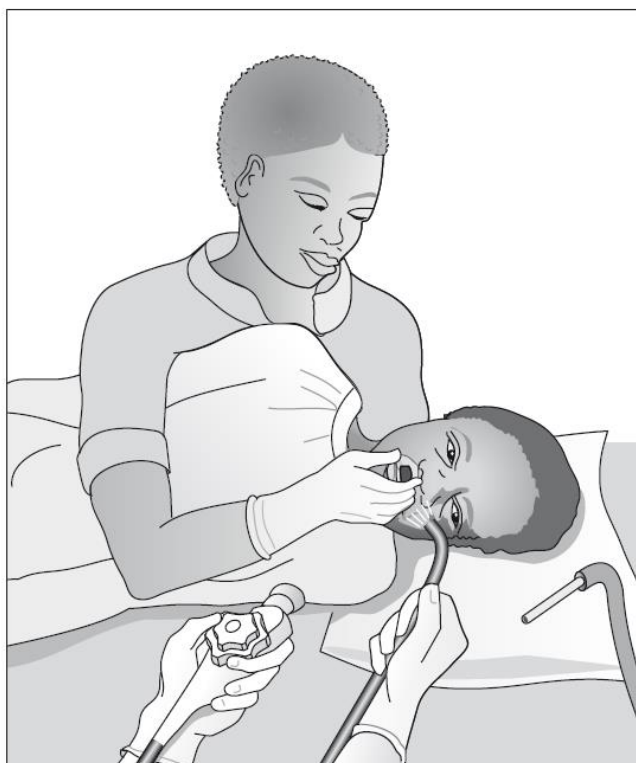
Spray the throat with LA and ask him to gargle and swallow. Use a sedative unless he is severely debilitated or has respiratory problems: diazepam 5-10mg IV is usual; if you add pethidine 50mg IV you can reduce the amount of diazepam. (Midazolam 10-15mg IV gives a faster recovery). *Beware: diazepam may make a young alcoholic more agitated!* Ketamine is ideal in children.

**If you are looking for a source of bleeding,** and the patient is haemodynamically stable, either wash out the stomach with 500ml/hr tepid water till the nasogastric aspirate is clear, or administer 250mg erythromycin IV over 20mins and perform the OGD 30min later, or use both methods of preparation.

In an elderly or sick patient, attach a monitor (or have an assistant to check pulse and blood pressure) and add oxygen by nasal prongs.

Quickly introduce the mouthguard between the teeth, asking him to bite on it: do this before he becomes too drowsy with the sedative, especially if you use ketamine. Turn him onto the left lateral position, with the head and neck supported comfortably on a pillow. Ask the assistant to hold the mouthguard in place, and put her left hand behind the head and right arm over the patient's chest to restrain him gently (13-3).

#### NURSE POSITIONING PATIENT



**Fig. 13-3 NURSE POSITIONING.** Gently restraining the patient and holding the mouthpiece. After Cotton PB, Williams CB, *Practical Gastrointestinal Endoscopy*, Blackwell 1982 2<sup>nd</sup> ed p.25 Fig 4.8

Holding the endoscope with the left hand, with the thumb free to manipulate the viewing controls, and the index and middle fingers on the suction and blowing buttons, pass the lubricated tip gently through the mouthguard.

Curve the endoscope over the tongue, which should be kept down inside the mouth, and into the pharynx keeping in the midline. Straightening the endoscope by deflecting the up/down control wheel, advance it behind the larynx, and with *slight* forward pressure, ask him to swallow. The endoscope then passes effortlessly down the oesophagus as resistance of the *cricopharyngeus* is lost: you can easily feel this.

This is the difficult part for the patient, so be encouraging and *do not get impatient*. If he coughs, suction secretions and straighten out the curve of the scope: *you are too far anterior*. If he fails to swallow the endoscope after 3-4 attempts, pull it out and try again, making sure your controls and orientation are correct.

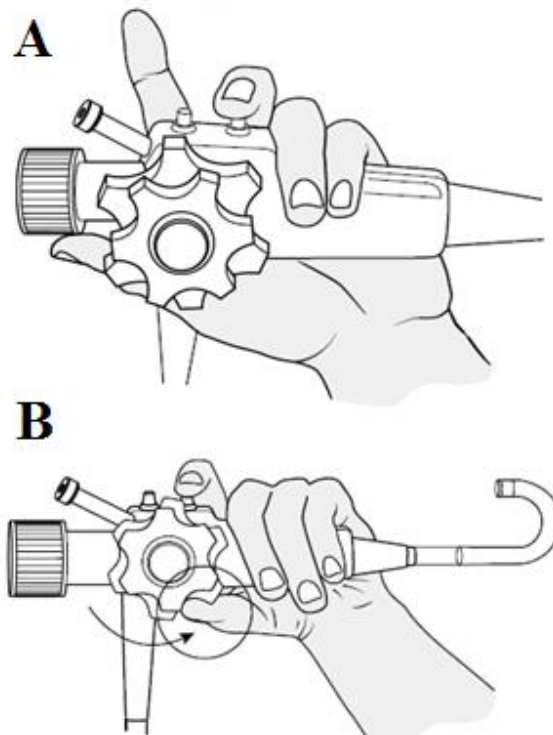
(If you are passing the endoscope on an anaesthetized patient lying supine, you can use a laryngoscope to guide the tip down into the oesophagus.)

As you go down the oesophagus, suck out any secretions and look at the mucosa; note any irregularities, deposits of whitish *candida*, redness or stricturing. You will need to blow in a bit of air if you have used the suction. You will see the oesophago-gastric junction as the mucosa turns from pale pink to red; *where this is in relation to the diaphragm is not really relevant*: the degree of oesophagitis is.

Just as you pass the *cardia*, blow some air in and turn the scope slightly down and left (as the oesophago-gastric junction is at a slight angle), and blow air into the stomach so you can see its lining.

*Do not advance if you can't see!* If the view is red (unless the lumen is full of blood), the endoscope tip is against the mucosa, so withdraw it and blow air in.

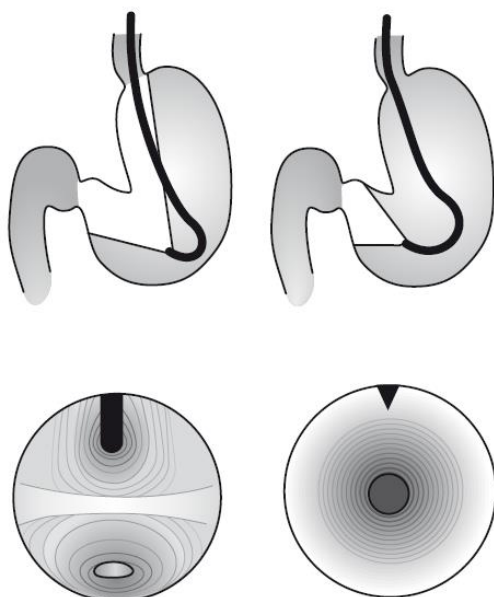
#### GRIPPING THE ENDOSCOPE



**Fig. 13-4 GRIPPING THE ENDOSCOPE.**

A, use the middle finger for suction and blowing air. B, use the left thumb for the up/down and the index finger for the left/right controls.

## ENDOSCOPIC VIEW OF THE STOMACH



A Angulus view

B Pylorus view

**Fig. 13-5 ENDOSCOPIC VIEWS OF THE STOMACH.**

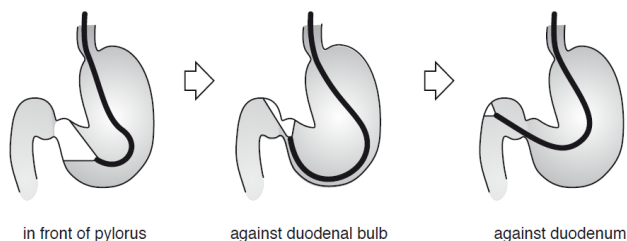
**A, angulus view. B, pylorus view.**

After Cotton PB, Williams CB, *Practical Gastrointestinal Endoscopy*, Blackwell 2<sup>nd</sup> ed 1982 p.29 Fig 4.16

You should see a small pool of gastric juice in the posterior part of the body of the stomach: suck this out and blow air in. You then will notice a ridge ahead (the *incisura*, or *angulus*) above which is a view of the lesser curvature:

Below this is the *antrum*, leading to the pylorus. You may be surprised by the very short distance there seems to be between the *incisura* and the pylorus such that the endoscope tip may 'jump' out of the pyloric opening back over the *incisura* into the body of the stomach. You need then to try to pass the endoscope tip through the pylorus which appears as a black hole; this may seem like driving a truck with your hands off the steering wheel into a moving tunnel entrance! (13-5)

Be patient: *do not suck or blow air in excessively* because this may irritate the patient. If he is very lively, hyoscine 20mg IV will reduce spasm at this stage. Keep one hand on the endoscope controls and the other on the instrument tip and wait till the pylorus opens; then quickly pass the endoscope tip through. It will tend to slip past against the bulb of the duodenum, and so need withdrawing a little:



in front of pylorus

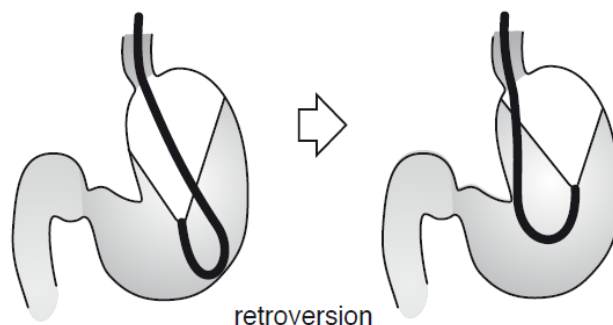
against duodenal bulb

against duodenum

**Fig. 13-6 ENDOSCOPIC POSITIONS IN THE STOMACH.**

**A, in front of pylorus. B, against duodenal bulb. C, against duodenum.** After Cotton PB, Williams CB, *Practical Gastrointestinal Endoscopy*, Blackwell 2<sup>nd</sup> ed 1982 p.30 Fig 4.23

Pass the endoscope round the duodenal angle, but *do not force it* because if the duodenal cap is distorted from old scarring, this is where you can perforate it! You rarely will need to go past the 2<sup>nd</sup> part of the duodenum, and anyway then you will need a side-viewing endoscope.



retroversion

**Fig. 13-7 ENDOSCOPIC MANIPULATION. Retroversion.**

After Cotton PB, Williams CB, *Practical Gastrointestinal Endoscopy*, Blackwell Oxford 2<sup>nd</sup> ed 1982 p.29 Fig 4.19

Now scan the areas you have missed on the way in (13-7): gently withdraw the endoscope and look carefully at the first part of the duodenum, and then at the pylorus. An ulcer shows as a yellowish sloughy area, which may bleed slightly on touching with the endoscope tip. You can use this moment to take biopsies for *helicobacter* near the pylorus and examine the mucosa of the stomach. Make sure you look at the fundus by retroversion of the endoscope looking towards the *cardia* where you will see the black tube of the instrument coming through. As you pull the instrument out, you will be able to see the *cardia* close up; look again at the oesophagus and pharynx as you come out.

## DIFFICULTIES WITH OGD

**If the patient becomes distressed**, check the monitor and add oxygen by nasal prongs. If this fails, withdraw the instrument and try again later. If he is agitated because of alcohol misuse, diazepam may make him worse: use 50mg pethidine IV.

**If you have done an inadvertent bronchoscopy**, he will usually be coughing profusely. Withdraw the instrument, and suction at the same time, and when he has recovered, try again to introduce the endoscope into the oesophagus.

**If severe abdominal or chest pain develops**, abandon the procedure: There is either a perforation or a myocardial infarction. Resuscitate appropriately (13.3)

**If you get lost, or only see red**, blow air in so you can orientate yourself. If you find yourself seeing the instrument coming through the *cardia*, he will start belching. Withdraw the endoscope tip and turn it towards the left, and advance again provided *you can see where you are going!* You should find the *incisura* and then find the pylorus. Remember there may be gross pathology to confuse you: achalasia, large diverticulum, duodenal deformity, pyloric stenosis, previous surgery, e.g. a gastroduodenostomy, or congenital malrotation (with or without dextrocardia!)

**If there is excess food residue**, the patient may not have starved or he may have an outlet obstruction; if you can ride the endoscope above the food you may be able to see a cause. However, there is a risk of regurgitation and aspiration, so *do not persist* and try again after nasogastric suction. *Beware*: food particles and thick *candida* can block the endoscope channels and damage them.

**If you can't withdraw the endoscope**, check that the viewing control ratchet is free and manipulate them so the instrument is straight. Check that the patient is not biting on the endoscope!

#### APPEARANCES ON OGD

**Oesophagus.** Early OESOPHAGITIS has a fine vascular pattern of the mucosa disappearing with oedema; it then becomes red and friable, bleeding on contact. Patches of exudate and frank ulceration with a yellow slough then result, usually in the long axis of the oesophagus.

A MALLORY-WEISS TEAR is a longitudinal 5-20mm split in the mucosa. A BENIGN STRICTURE is symmetrical and smooth, usually with normal mucosa proximally. A MALIGNANT STRICTURE is asymmetrical with exuberant abnormal mucosa and raised ulcer edges but a gastric carcinoma may infiltrate under the mucosa from below. CANDIDIASIS looks like white spots or plaques which may become diffuse: these do not wash off with a jet of water. VARICES are bluish mounds in the long axis of the oesophagus. DIVERTICULA and FOREIGN BODIES are obvious. ACHALASIA shows no abnormality except excessive food residue which may look like candidiasis.

**Stomach.** The redness of GASTRITIS may not have clinical significance and biopsies may be more helpful. GASTRIC ATROPHY is seen as greyish white patches and associated with intestinal metaplasia. Erosions start as umbilicated polyps and then develop into smooth-margin GASTRIC ULCER. Irregular margin, base and surrounding mucosa suggest a GASTRIC CARCINOMA. However, a submucosal malignancy will not show any mucosal changes. *Biopsy all gastric lesions for a correct diagnosis.*

**Duodenum.** Persistent deformity of the pyloric ring indicates current or past ulceration; a DUODENAL ULCER appears as a break in the mucosa with an oedematous smooth raised edge and yellowish slough in the centre. You can highlight lesions more easily by spraying the surface with a little methylene blue or ordinary ink, with an injection device passed through the biopsy channel. Minor changes of 'duodenitis' are of doubtful significance.

**Bleeding ulcers.** During endoscopy you may see active bleeding or evidence of recent bleeding; the Forrest classification gives you an idea of who is likely to re-bleed and therefore who needs intervention:

Type		RISK OF RE-BLEED
IA	Pulsatile arterial haemorrhage	100%
IB	Oozing haemorrhage	>50%
IIA	Vessel seen	>40%
IIB	Clot over bleeding point	>20%
IIC	Haematin-covered flat spot	10%
III	No signs	5%

#### PROCEDURES

**Biopsy.** (GRADE 1.5) It is best to use a forceps with a central spike; check that the biopsy forceps is working, the correct width, and long enough and thread it through the biopsy channel. *Do not force it through at the tip*: it may not pass if the endoscope is very retroverted or of course if it is too big! Take specimens under direct vision by instructing an assistant how and when to open and close the forceps, and shake them directly into a container with formalin. You will need to take at least 3-6 specimens. Frustratingly, many biopsy forceps will work outside the instrument but not when passed through the biopsy channel when the cable is damaged: this happens easily if the endoscope case is closed on top of it, so *take care* to store these delicate accessories carefully.

**Dilation.** (GRADE 2.3) Balloon dilators can be used for oesophageal and pyloric strictures. If you don't have these, dilators which you can pass over a guide wire are an alternative. This is a great advantage over rigid oesophagoscopy under GA as patients are generally frail, wasted and dehydrated. However, if you are not experienced you may need longer than diazepam alone will allow; add ketamine or pethidine.

Pass the guide wire *under direct vision* via the biopsy channel through the stricture. You need good suction to clear the debris above the stricture to find the opening: *do not force the wire if it snags against tumour, a hiatus hernia or a pseudo-diverticulum*. With the tip of the guide wire nicely beyond the stricture, gently withdraw the endoscope, pushing the wire in as you pull the instrument out. When it becomes visible at the mouth, ask your assistant to hold it firmly, and remove the endoscope. Dilators are either of increasing size (Eder-Puestow type) or of stepped graduation (Celestin type); pass them over the guide wire past the stricture and then withdraw them. Warm the Celestin type in boiling water to make it flexible; use the Eder-Puestow type as bougies in increasing size from Ch21 to 40. When you have passed the dilator, introduce the endoscope again to check the stomach.

**If the patient has severe pain, cannot swallow or has subcutaneous emphysema or peritonitis afterwards**, you have probably perforated the oesophagus (30.7), or pylorus.

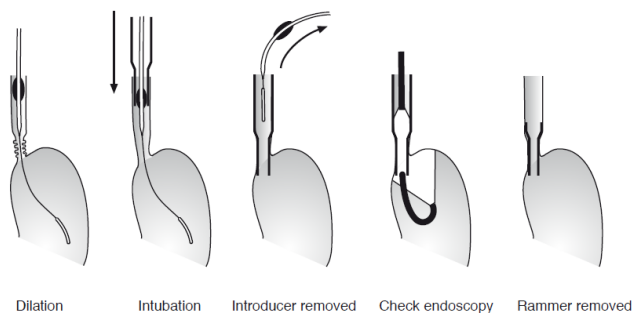
*Such dilation will unfortunately not help in achalasia (30.6), which needs a special balloon distended to 300mmHg.*

**Oesophageal stenting** (GRADE 2.3). Make sure you have measured the position of the malignant stricture. After successful dilation, you can pass a prosthetic tube, well lubricated, over the dilator of appropriate size and guide this together with an introducer (which can be home-made) into the correct position. The prosthetic tube must have a distal flange or rim to prevent upward displacement. Remove the dilator and guide wire whilst holding the tube in place with the introducer. Then pass the endoscope through the introducer to check the position of the tube; if all is well, disconnect the introducer with a twisting motion and withdraw it.



*N.B.* If you have self-dilating stents, these are a big improvement on the basic fixed tube described.

DILATION & INTUBATION

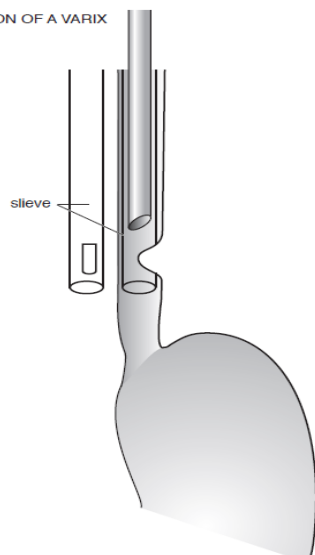


**Fig. 13-8 DILATION & STENTING.** A, dilation. B, stenting. C, introducer removed. D, check endoscopy. E, rammer and endoscope removed. After Cotton PB, Williams CB, *Practical Gastrointestinal Endoscopy*, Blackwell Oxford 2<sup>nd</sup> ed 1982 p.53 Fig 5.8

**Injection.** (GRADE 2.3) Pass an injection device through the biopsy channel; when you see a gastro-oesophageal varix, inject 0.5-2ml of absolute alcohol as sclerosant into the varix or just around it.

To prevent bleeding, it is best to have a plastic sleeve, specially made for the purpose from suitable tubing, with an oval window cut out at its tip, and pass this over the endoscope. Inject sclerosant through the window, and then rotate the plastic so that the tube presses against the varix and stops the bleeding. Put in up to 5 or 6 injections till you have satisfactorily dealt with all the varices; this may need several procedures. If bleeding persists, sedate the patient and leave in the overtube for 1hr.

INJECTION OF A VARIX



**Fig. 13-9 VARIX INJECTION.** Using an endoscope sleeve. After Cotton PB, Williams CB, *Practical Gastrointestinal Endoscopy*, Blackwell 2<sup>nd</sup> ed 1982 p.59 Fig 5.15

**Foreign bodies.** (GRADE 2.3) Depending on what sort of gadgets are available, you may be successful in removing foreign bodies in the stomach or oesophagus, but rigid oesophagoscopy under general anaesthesia gives more scope for manipulating objects, especially if they are sharp (30.2). Remember most foreign bodies in the stomach will pass normally. An overtube, as used for varix injection, is useful to protect the oesophagus and pharynx; pass it beyond the *cardia* and then grasp the foreign body and pull it into this protecting tube; then remove the whole lot together.

When you see an actively bleeding vessel in a duodenal ulcer, you can inject 1ml of absolute alcohol, adrenaline or hypertonic saline adjacent to the bleeding point. The problem is that you may not actually see the bleeding point if the stomach is full of blood, so make sure you have passed a nasogastric tube beforehand and sucked it out.

If you have the more sophisticated equipment, you may be able to clip a bleeding vessel.

## CLEANING AND STERILIZING.

Physical cleaning of the instrument is essential: disinfectant may solidify mucus and actually make its removal more difficult if not impossible. *Do not leave this task to an untrained member of staff. Do not put off this job till hours after the endoscope has been used!*

After finishing each examination, leave the instrument tip in warm detergent with the light source still on, aspirate and blow air down the channel to loosen mucus, blood and debris. Do this till the channels seem clear. Clean the tip with a toothbrush. *Do not wet the control head of the instrument.*

Remove the rubber valve on the biopsy channel, and soak it in disinfectant. Pass the cleaning brush through the channel, and clean the bristles after they emerge from the instrument before pulling the brush back. You may need to repeat this several times. Connect the washing adaptor to the biopsy port and aspirate disinfect into the channel, leaving it there for 2mins. Soak biopsy forceps likewise in detergent.

Connect a bottle of disinfectant in place of the water bottle and flush this through the air/water channel, and then clean it with water and air. Rinse the insertion tube and biopsy channel with clean water. Remove the washing adaptor, suck hydrogen peroxide and then 30% alcohol through the biopsy channel, and then dry the instrument in air.

Wipe the tip and outside of the instrument with a gauze soaked in 30% alcohol and leave it to dry. It is then ready for the next patient.

For the first case, though, a full 10min disinfectant soak period is required. Remove the air/water and suction valves; clean these and lubricate them with silicone jelly before putting them back.

## STORAGE

Hang endoscopes vertically in a lockable cupboard with good ventilation; they should not be stored curled up in their transportation case. Biopsy forceps wires easily get tangled, and caught in doors; make sure they hang on separate hooks.

## DOCUMENTATION

Produce a regular form (13-10) with patient details, instructions, consent, indications for the procedure, and findings. Make sure you fill these correctly for each patient.

## ENDOSCOPY FORM

Patient's Name.....  
 Date of Birth.....  
 Hospital Number.....

I hereby agree to the examination of my bronchus/stomach/colon by means of a telescope and to have sedation to enable this to be done and agree to minor procedures which have been explained to me by:

Dr..... Signed: .....

Date of procedure:.....  
 Indication.....  
 Sedation used & dose.....

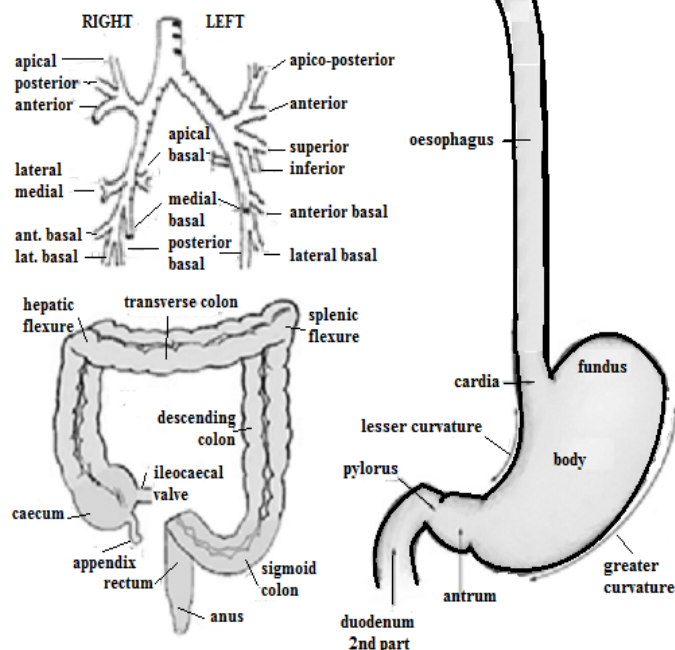


Fig. 13-10 ENDOSCOPY FORM.

Make sure you fill in all the relevant details: pictograms are best at demonstrating what you've seen.

### 13.3 Perforated gastric or duodenal ulcer

Classically, when a peptic ulcer perforates, it floods the peritoneum with the acid contents of the stomach, and results in sudden agonizing pain. The patient can often tell you the exact moment the pain began; it is constant, it spreads across the entire upper abdomen and later all over, and is made worse by deep breathing or movement. Usually, he lies still in excruciating pain, and breathes shallowly without moving the abdomen. He is pale, sweating, usually with a fast pulse and is hypotensive but has a normal temperature, and an abdomen which is not distended.

Typically, it has a board-like rigidity, unlike that in any other disease, which may be so complete that you cannot elicit tenderness, except when you examine him rectally.

After 3-6hrs the pain and rigidity lessen, he feels better and a 'silent interval' begins. Then, at about 6hrs, signs of diffuse peritonitis develop, accompanied by abdominal distension and absent bowel sounds.

There are difficulties:

- (1) So many patients have dyspepsia, that a previous dyspeptic history is not much help.
- (2) You may have difficulty in distinguishing severe gastritis or the exacerbation of a peptic ulcer from a subacute perforation (a small sealed leak).
- (3) Fluid may track down the right paracolic gutter and cause pain and tenderness in the right iliac fossa, simulating appendicitis.
- (4) In a patient taking corticosteroids, who is immunocompromised, or elderly, the dramatic onset may be absent. Instead, he may merely 'take a turn for the worse', a tachycardia with diminished respiratory effort and splinting of the right hemidiaphragm.

**If there is a perforation**, an urgent laparotomy is needed. If the patient is fit, and you operate within 6hrs, the result will be good. If you delay 12hrs, the chances of survival fall greatly. If he survives, there is a 50% chance of needing further peptic ulcer medical treatment, but <10% will require further major surgery.

Although the standard treatment is an urgent laparotomy to close the hole in the duodenum or stomach, and to wash out the peritoneal cavity, there are some indications for treating non-operatively, as described below. This is less demanding technically, but it needs careful clinical observation, and you will need good judgement to know:

- (1) when you have made a wrong diagnosis, and
- (2) when non-operative treatment is failing, so that you need to operate.

The rule in all emergency surgery is to do only what is necessary. Closing the perforation is not difficult, but be sure to wash out the peritoneum when it has been contaminated. For this you will need plenty of warm fluid.

#### DIFFERENTIAL DIAGNOSIS.

The main diagnostic difficulty is pancreatitis or appendicitis, which is important because the first needs no operation and the second needs a different incision.

**Suggesting perforation:** referred shoulder pain, usually on the patient's right, the absence of fever (this develops late in a perforation), shock (when generalized rigidity is the result of appendicitis, shock is unusual), and >1l of stomach aspirate.

**Suggesting pancreatitis (15.13):** referred back pain, the absence of fever, shock, and a history of alcohol ingestion.

**Suggesting appendicitis (14.1):** central abdominal pain initially moving to the right iliac fossa, fever, a small stomach aspirate of mucoid or bile-stained fluid.

**Suggesting oesophageal perforation (30.7):** vomiting for any reason with sudden severe epigastric and lower retrosternal pain, or spreading between the shoulders.

## RADIOGRAPHS.

Take an erect *AP chest* radiograph. (*Abdominal views are no use, especially when the diaphragms are not fully seen.*) Make sure the patient is upright and the Xray tube is horizontal. Look for a thin linear gas shadow between the diaphragm and the liver or stomach. If he cannot sit or stand, take a film semi-erect propped up in bed: this is better than a lateral decubitus film where you have to look for air under the anterior abdominal wall.

## CAUTION!

- (1) If the ulcer has perforated into the lesser sac, you may see a large irregular gas shadow in the centre of the upper abdomen, with an outline which is different from that of a loop of bowel.
- (2) The absence of gas does not exclude the presence of a perforated ulcer.
- (3) Gas can also come from ruptured small or large bowel, the appendix, or gas-forming organisms in severe PID.
- (4) Free gas can be seen after a laparotomy or a penetrating stab wound, *so do not be misled if you see it on a chest radiograph taken post-operatively!*

## NON-OPERATIVE TREATMENT FOR A PERFORATED PEPTIC ULCER

### INDICATIONS.

- (1) A perforation which appears to have sealed itself already as shown by diminished pain and improved abdominal signs.
- (2) Severe heart or lung disease, which increase the surgical and anaesthetic risks.
- (3) A late presentation almost moribund with diffuse peritonitis.

### CONTRAINDICATIONS.

- (1) An uncertain diagnosis.
- (2) The absence of really good nursing by day and night.
- (3) The seriously ill patient, with a short history, whose only hope is vigorous resuscitation and an urgent laparotomy.

**If you do decide that such a patient is 'not fit for surgery',** wait until vigorous resuscitation has failed: *do not make the decision when he is first admitted.*

### METHOD.

Treat with morphine 5-10mg IV. As soon as this has had time to act, pass as wide a radio-opaque nasogastric tube as he will tolerate. Then get AP erect radiographs of the chest and abdomen. These should show that there are no fluid levels in the stomach, and that the tube is well placed. If not, adjust it and take more films. Look for subdiaphragmatic gas to confirm the diagnosis.

Start broad spectrum antibiotics: gentamicin 240mg od and metronidazole 500mg tid IV.

Back in the ward, ask a nurse to aspirate the stomach every 30mins initially, making sure the tube is cleared by injection of 5ml of air before aspiration. Infuse IV saline or Ringers lactate, and monitor the pulse and blood pressure hourly. *This is active management and needs careful observation!*

There is good progress if the pain eases, if there is no more need for analgesia after 8hrs, if another erect chest radiograph 12hrs later (optional) shows no fluid level, and if there is no increase in amount of gas under the diaphragm. Continue to keep him nil orally on nasogastric drainage for 4-5days, until the abdomen is no longer tender and rigid, and the bowel sounds return.

**If pain persists, or the gas under the diaphragm increases,** try to confirm that the perforation persists by passing some gastrografen (*never barium*) into the stomach and duodenum and take radiographs to demonstrate the leak. If it is present, operate.

### For a moribund patient unlikely to survive GA because:

- (1) the presentation is >72hrs late,
- (2) shock (BP <80mm Hg systolic) persists despite good resuscitation,
- (3) there is severe cardiorespiratory disease,
- (4) there is carcinomatosis, jaundice, or severe immunodeficiency,
- (5) advanced age,

Insert a wide bore drain through both flanks under LA into the peritoneal cavity. You can irrigate the abdomen through the drains with warm water. He may improve enough to avoid surgery altogether, or to allow you to operate definitively.

## LAPAROTOMY FOR A PERFORATED PEPTIC ULCER (GRADE 3.3)

### PREPARATION (10.1)

Pass a nasogastric tube and aspirate the stomach (4.9). Much fluid will be lost into the peritoneal cavity, so correct at least ½ of the fluid loss before you operate. Correct dehydration or hypotension by infusing 1-3l Ringer's lactate rapidly. If >12hrs have elapsed since the perforation, infuse even more. Operate soon, but not before proper resuscitation. *Unless there has been bleeding (rare), do not transfuse blood.* Pre-medicate with IV morphine.

### INCISION.

Make a midline incision (11.2). The escape of gas as you incise the peritoneum confirms the diagnosis of perforation (but *not necessarily a peptic ulcer*). You will probably see a pool of exudate under the liver, with food and fluid everywhere, and an inflamed peritoneum. The fluid may be odourless and colourless with yellowish flecks, or bile-stained especially if the perforation is in the 2<sup>nd</sup> or 3<sup>rd</sup> parts of the duodenum.

**If you see patches of fat necrosis,** this is due to acute pancreatitis (15.13).

**If there is no fluid or little fluid,** the perforation may have walled off: *do not disturb it!* Look in the right paracolic gutter and draw the stomach and transverse colon downwards: you may see flecks of fibrin, and perhaps pieces of food.

**To expose the stomach and duodenum,** place a self-retaining retractor in the wound. Place a moist abdominal pack on the greater curvature of the stomach.



Draw this downwards, and ask your assistant to hold it; at the same time ask him to hold the liver upwards with a deep retractor. Put an abdominal pack between the retractor and the liver to protect it. If necessary, get the help of a second assistant. If access is difficult, enlarge the incision.

Suck away any fluid, looking carefully to see where it is coming from. Search for a small (1-10mm or more) circular hole on the anterior surface of the duodenum, looking as if it has just been drilled out. Feel it. The tissues around it will be oedematous, thickened, scarred, and friable.

**If the duodenum is normal**, look at the stomach, especially its lesser curve. If the hole is small, there may be more to feel than to see. Sometimes, a gastric ulcer is sealed off by adhesions to the liver. Remember that a gastric ulcer may be malignant: take a biopsy if this does not make closure difficult. You should not attempt to excise a malignant gastric ulcer as an emergency unless it is very small. Look quickly if there is a second perforation. Open the lesser sac through the lesser omentum. Feel the posterior surface of the stomach. An ulcer high up posteriorly may be difficult to find. Feel for it carefully, and if you still cannot find it, pass diluted Methylene blue dye through the nasogastric tube and watch where it comes out.

### PERFORATED PEPTIC ULCER

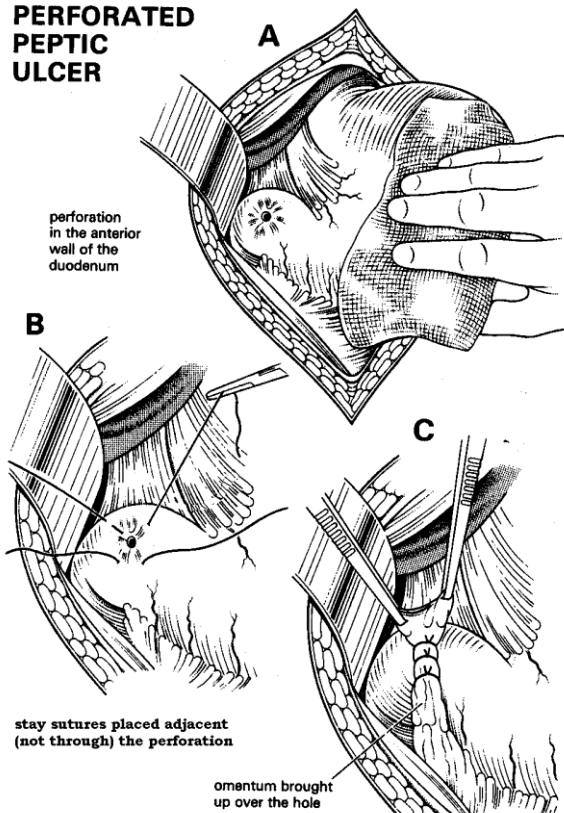


Fig. 13-11 CLOSING A PERFORATED PEPTIC ULCER.

A, retract the stomach and expose a perforation on the anterior of the duodenum. B, place interrupted stay sutures of 0 or 2/0 silk or absorbable on an atraumatic needle adjacent to (but not through) the perforation, C, in order to pull a fold of omentum over the hole.

Kindly contributed by Gerald Hankins.

**If the stomach and duodenum are normal**, feel gently downwards towards the appendix, and pelvic organs in a female. Then look at the small bowel from end to end. If this is normal, examine the gallbladder, pancreas and finally the colon.

To close the perforation, place 0 or 2/0 long-acting absorbable sutures on an atraumatic needle superior and inferior to the hole (13-11B); then tie these sutures over an omental fold onto the stomach or duodenum thus covering the hole (13-11C). A hole so covered is unlikely to leak.

*Do not try to bring the ulcer edges together:* if the sutures cut out, the hole will be much larger than before. With a large hole, you can use the omentum actually to plug it, but *this does not safely close perforations >2cm diameter* (see below). Check if the hole is sealed by passing some dye (e.g. diluted methylene blue) down the nasogastric tube, and confirming no dye is leaking out.

Wash out the peritoneal cavity. This is absolutely critical, and may be more important than closing the hole. Tip a litre of warm fluid into the peritoneal cavity, splash it about well, and then suck it out again. Repeat this several times till the draining fluid is clear, and try to wash out every possible recess in the upper abdomen. Mop the upper surface of the liver.

*Don't perform a vagotomy:* this is an unnecessary procedure in a sick patient. *Don't leave a drain.*

### POSTOPERATIVELY.

Nurse the patient sitting up straight in bed. Breathing will then be easier, chest complications less likely, and any exudate will gravitate downwards. Continue with nasogastric suction and IV fluids (11.9). Replace the gastric aspirate with IV saline (4.9). Chest physiotherapy is vital if he is asthmatic, a smoker, immune-compromised, elderly, or if there is widespread soiling in the abdomen. Treat him with antibiotics for *helicobacter* as >80% of perforated ulcer patients have it. Start an H<sub>2</sub>-blocker or proton-pump inhibitor immediately (dilute crushed tablets with water and introduce this via the nasogastric tube, and then clamp it for 1hr) and continue oral treatment for 6wks.

### DIFFICULTIES WITH A PERFORATED PEPTIC ULCER

**If the ulcer is eroding into the pancreas or liver**, separate the stomach or the duodenum from the pancreas or liver by pinching between them with your finger and thumb. If this is difficult, or it is leaking into the peritoneal cavity, cut around it, and leave its base fixed. Then plug the hole with omentum.

**CAUTION!** *Do not put your finger through the ulcer into the liver, it will bleed severely.*

**If the ulcer is huge, leaving only a small part of duodenum normal**, closing it will be impossible or result in stenosis; mobilize the duodenum by dividing the peritoneal attachment along its convexity (the Kocher manoeuvre) as much as you can, and insert an omental plug as above.

Then pass 2 Ch16 Foley catheters, one into the stomach and one to the 2<sup>nd</sup> part of the duodenum, securing them with a purse-string suture, and inflating the balloon so that no fluid leaks out. Bring both tubes out through separate stab incisions in the abdominal wall, label them clearly, and secure them firmly. Perform a gastrojejunostomy (13.16).

Keep the patient nil orally till his nasogastric aspirate has settled, and then try oral fluids with some dye. If this comes out through the stomach Foley drain, wait and try again later. Eventually the area of ulceration will close by scarring.

**If there is concurrent bleeding**, there is probably a large circular or 'kissing' ulcer: try to undersew the bleeding vessel first. You will need to make a large Y-shaped incision including the perforation and then try closing it making a V-type pyloroplasty (13.5, 3-12).

If this is impossible, use an omental plug, with a retrograde tube duodenostomy and feeding jejunostomy as above.

**If there is also gastric outlet obstruction**, which is not relieved by the pyloroplasty you perform on closure, add a gastrojejunostomy (13.8).

**If an 'hourglass stomach' perforates**, it is from stricture due to acid ingestion (13.10); perform a Polya gastrectomy (13.10).

**If there is gross peritoneal soiling, or suspicion of re-perforation**, consider a laparostomy (11.10) for further wash-out after 48hrs.

**If there is a perigastric abscess** in Morison's pouch or the lesser sac, drain it by a separate incision in the flank.

**If pyrexia ensues in the 2<sup>nd</sup> week post-op**, suspect there is a subphrenic abscess or other localized collection of pus (10.2).

**If you continue to obtain much gastric aspirate**, there is probably a pyloric stenosis aggravated by the duodenal closure. If it continues for >10days, perform a gastrojejunostomy (13.8).

### 13.4 Bleeding from the upper gastrointestinal tract

In most of the world, a bleeding peptic ulcer is the commonest cause of bleeding from the upper intestinal tract, but in certain parts bleeding varices as the result of portal hypertension are more common.

Other causes of bleeding include stress ulcers, haemorrhagic gastritis, uraemia, gastric carcinoma, a tear in the lower oesophagus following a forceful vomit (the Mallory-Weiss syndrome, 30.7).

In all these conditions the patient vomits bright or altered blood ('coffee grounds'), or he passes melaena stools, or occasionally bright blood, if the bleeding is brisk, from the rectum. Your task is to:

- (1) resuscitate the patient,
- (2) make the diagnosis,
- (3) assess the risk status, and
- (4) control bleeding.

Try to make the diagnosis epidemiologically and clinically, especially if you do not have a fibre-optic gastroscope, or you cannot do barium studies (38.1). The important distinction is whether or not bleeding is from gastro-oesophageal varices, because you will not want to operate on these, whereas you may need to operate for most of the other causes. A large spleen is a most useful sign. Ultrasound will demonstrate portal venous distension (38.2A). Endoscopy is very helpful (13.2). However, even the best surgical centres cannot find a cause for the bleeding in about 10% of cases. You may need plenty of blood for transfusion.

### UPPER GASTROINTESTINAL BLEEDING

**HISTORY.** A history of peptic ulceration is suggestive only. Confirmation is often lacking. There is at least a 25% chance that the patient has a peptic ulcer and no symptoms. Has he been taking NSAIDs, or steroids? These can cause haemorrhagic gastritis and ulcers.

### EXAMINATION.

Look for signs of shock. A pulse of  $\geq 120$  is a reliable sign of recent blood loss (*but remember that  $\beta$ -blockers will mask a tachycardia*). Note sweating, restlessness, mental slowing and oliguria. Falling blood pressure is a sign that you may be losing the patient! Examine for epigastric tenderness, and rectally to make sure that a history of black tarry stools is correct. *If the blood is bright red, and the patient is not shocked, the bleeding does not come from the upper GI tract.* Look for signs of malignancy. Measure the blood urea, bleeding and clotting times. If there is vomiting blood and you have no reason to suspect severe oesophageal varices, pass a nasogastric tube and monitor the amount of bleeding into the stomach by flushing the tube with warm water from time to time.

**DIAGNOSIS.** The following 3 conditions account for 90% of cases. Other causes are rare.

**Suggesting bleeding gastro-oesophageal varices:** a large spleen, a firm enlarged irregular liver, or a small hard one; abnormal vessels around the umbilicus, ankle oedema. Ascites is common in cirrhosis, less common and often not marked in periportal fibrosis, and very uncommon in extrahepatic obstruction. Spider naevi, and palmar erythema are often not seen. The patient may be drowsy or in coma from hepatic encephalopathy (made worse by the digestion of the blood in the bowel). Liver function tests are abnormal in cirrhosis, but often normal in portal fibrosis.

**Suggesting haemorrhagic gastritis (mucosal erosions):** the recent ingestion of alcohol or analgesic tablets.

Use the history and physical signs to form some estimate of how much blood has been lost, and over how long. Decide if the blood loss has been mild, moderate, or severe. Anaemia on arrival suggests chronic blood loss.

**Suggesting a duodenal or gastric ulcer:** a history of epigastric pain and dyspepsia, and especially NSAID use.

**RESUSCITATION.** Cross-match 2-4 units of blood depending on the severity of the bleeding. Sedate the patient heavily with diazepam 5mg qid IV, or chlorpromazine 25mg, or use ketamine. Avoid morphine.

**If the patient is in shock,** set up 2 IV infusions of 0.9% saline or Ringer's lactate, with large-bore cannulae. If there is severe bleeding, infuse 1-4l of fluid rapidly, or more, until the blood pressure returns to 100mmHg. You may need at least 3 units of blood and possibly many more. If you have a colloid plasma expander, infuse 1-2l while you wait for blood.

**If you do not have blood,** nor enough blood, *do not hesitate to infuse large quantities of saline or Ringer's lactate:* the great need is for fluid to fill the vessels, but remember then that your threshold for operative intervention will be lower. Try to keep some blood in reserve in case bleeding resumes.

**If you think gastro-oesophageal varices are unlikely,** pass a large nasogastric tube. This will tell you if bleeding is continuing, and whether the blood is fresh or altered. If you aspirate clots, irrigate the stomach to wash them out. Then run into the stomach 200ml ice-cold saline containing 8mg noradrenaline and leave it for 30mins; aspirate and repeat this for 4hrs or until bleeding stops. *Beware that you don't make the patient hypothermic!*

#### MONITORING.

Measure and chart the pulse, the blood pressure, and the peripheral circulation ½hrly. A rising pulse or a sustained tachycardia are more important than isolated readings. Monitor the urine output, and, if possible, the central venous pressure if the patient is very ill. Measure the haemoglobin and haematocrit as a baseline.

Continued bleeding is suggested by: persistent nausea, tachycardia, pallor, restlessness, bright red fluid aspirated through the nasogastric tube, and the rapid fall in Hb or its failure to rise in spite of transfusion (a useful sign). Monitor glucose levels in liver disease, and liver function tests if possible. Correct coagulation problems if present.

**ENDOSCOPY (13.2).** This is most useful, if you can do it, but it will be almost impossible during heavy active bleeding unless you have very effective suction, and resuscitation facilities where you plan to perform the endoscopy. Once it has settled, it will allow you to inject gastro-oesophageal varices (13-9), or inject around a bleeding point in a duodenal ulcer.

**OUTCOME.** Several things can happen. A gastric ulcer or gastro-oesophageal varices are more likely to continue to bleed than a duodenal ulcer.

Melaena alone is not as serious as haematemesis, but beware of continuing melaena and unaltered blood in the stools, which indicate persistent bleeding.

(1) **Bleeding may stop** either before admission, or with the above treatment, and not occur again (75% chance).

(2) **Bleeding may continue moderately,** but responds to transfusion. Small melaena stools or small bloody vomits continue, so that the haematocrit drifts downwards. The resting pulse may only be 90/min, but the least exertion may send it up to  $\geq 120$ /min. Non-operative treatment is dangerous if this continues for  $>72$ hrs or you have transfused  $>5$  units of blood.

(3) **Bleeding may stop completely and start again** in a few hrs, or a day or two later. This also is dangerous.

(After 3days, however, re-bleeding is unlikely.)

(4) **Bleeding may continue severely,** with vomiting of bowlful after bowlful of fresh or clotted blood, each bleed being accompanied by a wave of weakness and sweating. The passage of large tarry stools persists. A *rapid* fall in Hb 8hrs after an initial bleed indicates *continued* bleeding.

MANAGEMENT depends on the risk status.

Remember Moshe Schein's dictum:

**"When the blood is fresh and pink, and the patient is old, it is time to be active and bold;**

**When the patient is young and the blood is dark and old, you can relax and put your knife on hold."**

(Schein M, Rogers PN, (eds). *Common Sense Abdominal Emergency Surgery*, Springer 2<sup>nd</sup> ed 2005 p.139)

**For the low risk patient,** put him to bed, treat him with antacids, H<sub>2</sub> antagonists, or PPI inhibitors whichever is available: the best are, alas, the most expensive. Later, if possible, perform endoscopy, or a barium meal.

**For the high risk patient,** (the indicators are: haematemesis as well as melaena, pallor, loss of consciousness, age  $>45$ yrs, BP  $<100$  mmHg, pulse  $>120$ /min), management depends on whether you suspect varices (13.7) or not (13.5). Ideally every patient with an upper gastro-intestinal haemorrhage should have an endoscopy. Unless you have good suction, however, you will not be able to see much. Look for adherent blood clots in an ulcer, a visible vessel 'standing up' in the ulcer base, or active oozing or spurting from a vessel.

Endoscopy gives you the chance, if necessary, of sclerotherapy for varices and injection or clipping of vessels in bleeding ulcers (13.2), but this is quite specialized practice and needs the technology and some experience.

Remember *Helicobacter pylori* is almost always present where ulcers bleed, so use antibiotics (13.3).

### 13.5 Surgery for a bleeding peptic ulcer

There is about a 25% chance that conservative or endoscopic treatment is going to fail. At this point you will have to decide whether or not to operate in the hope of saving life. The patient needs surgery in the case of bleeding outcomes (2, 3 or 4), described previously (13.4); without surgery, there is about a 50% chance of death, especially if he is >45yrs. If you operate skilfully, the chances of death are only about 10%. In spite of the limitations of your services, about 90% of your patients with severe bleeding should live, most of them as the result of your efforts. One of your main difficulties may be to get enough blood: in this case operate earlier rather than later!

The purpose of emergency surgery is to save life, so decide when your patient is more likely to die if you do not operate than if you do. Try, especially, to judge the best time to operate, but *do not put off the decision!* When you do operate, try to find where the blood is coming from, and stop it. Obviously there is a big advantage if you can perform emergency endoscopy. Doing an operation which will prevent bleeding recurring is a lesser priority, because you may be able to arrange for a definitive operation later.

Remember though that surgery should be a controlled risk whereas further haemorrhage is an uncontrolled risk. If you have seen an adherent blood clot, or a vessel 'standing up' in an ulcer base on endoscopy, re-bleeding is very likely. If the patient is not suitable for surgery, or for some reason you decide not to operate, *do not give up*: continue ice-cold saline/noradrenaline lavage.

A gastric ulcer has stopped bleeding when the aspirate is no longer bloody. If this has not happened after 4hrs, abandon this method. If there is a duodenal ulcer, blood may not be returned in the nasogastric aspirate, so you will have to rely on the pulse and peripheral circulation to know when bleeding has stopped.

**If you can effect endoscopic injection** (13-9), try this first!

**If you decide to operate**, open the stomach and duodenum. If you find a bleeding duodenal or gastric ulcer, the simplest way to stop it bleeding is to undersew it.

Perform a pyloroplasty: *just remember not to close a pylorotomy longitudinally* otherwise gastric outlet obstruction will result.

Surgery for gastrointestinal bleeding is difficult. The 2 common mistakes are:

- (1) To choose the wrong type of patient to operate on.
- (2) To operate at the wrong time: if you wait too long, you risk the patient's life, but if you operate too soon, the risk may be equally great, *especially if you operate before you have restored the blood volume.*

Be much more ready to operate on the patient who is bleeding repeatedly, moderately or severely, needing >4 units of blood.

The bleeding point may be difficult to find, and when you have found it, blood may obscure it, so that controlling it will be difficult. You will need a generous gastrotomy, a good assistant, a good light, and good suction.

Expect respiratory complications (11.11), and wound breakdown (11.14).

#### SURGERY FOR A BLEEDING PEPTIC ULCER (GRADE 3.5)

**PREPARATION.** Make sure a large bore nasogastric tube is in place, blood and clots are suctioned out of the stomach, and blood is ready: you may need 4 units or more. Try to restore the blood pressure, but do not pour in fluids at one end only for him to bleed from the other end! Keep the systolic BP around 80mmHg. Get 2 assistants to help you.

#### INCISION.

Make a high midline incision extending up to the xiphisternum. Open the abdomen, and insert a self-retaining retractor in the abdominal wall. Insert a deep retractor under the liver, so that your assistant can retract it upwards. Gently draw the greater curve of the stomach downwards.

**Suggesting peptic ulceration:** a scarred, deformed first part of the duodenum or a puckered, thickened, hyperaemic area on the stomach, especially on the lesser curve. There may be nothing to feel if a posterior ulcer is eroding into the pancreas, or the liver.

**Suggesting bleeding gastro-oesophageal varices:** a firm or hard, shrunken, irregular liver, and dilated veins on the stomach. If you find this, and there are no signs of an ulcer also, think about an oesophageal transection, and treat the varices (13.7). Treat for schistosomiasis if this is common in your area.

*N.B.* Sometimes a patient has varices *and* an ulcer.

**If there is no obvious bleeding site**, feel every part of the stomach between your thumb and forefinger, and go right up to the gastro-oesophageal junction. Open the lesser sac by dividing the greater omentum between the lower edge of the stomach and the colon. Feel the whole posterior surface of the stomach.

**If you still cannot find the source of the bleeding, and there is melaena**, check the small bowel first. Blood might be coming from anywhere from the duodeno-jejunal flexure to the caecum. If you are not sure if the contents of the bowel are blood or bile insert a needle obliquely and aspirate. Look for a bleeding leiomyoma or gastro-intestinal stromal tumour of the stomach or small intestine, Kaposi sarcoma or a bleeding Meckel's diverticulum. Then check the colon for ileocaecal tuberculosis, carcinoma, amoebic colitis, and intussusception.

**If, even after you have done this, you cannot find the source of the bleeding after a haematemesis,** the chances of the patient surviving are small unless you continue to try. If you have not been able to perform an endoscopy beforehand, do so now. You may not be able to see your way clearly because of a lot of blood clots in the stomach: in this case, unless there is continued massive bleeding and you simply do not have enough time to do this, evacuate the blood clots by water irrigation using a wide-bore tube through a small high gastrotomy. Then pass the endoscope through this same opening, fastening it tight with a purse-string suture to make it air-tight in order to look for the bleeding site. (You can use a rigid cystoscope to do this, if you have no flexible endoscope).

If this is unhelpful, or you are faced with catastrophic haemorrhage, open the stomach and duodenum. *There is no substitute for having a good look.*

#### OPENING THE STOMACH AND DUODENUM IN GASTROINTESTINAL BLEEDING

Insert moist packs to seal off the abdominal cavity. You have a choice of 2 incisions, depending on the degree of fibrosis of the duodenum:

**If the scarring and fibrosis of the duodenum is mild or absent,** make a linear incision (13-12A) with  $\frac{2}{3}$  of it in the stomach, and  $\frac{1}{3}$  in the duodenum.

**If the scarring and fibrosis of the duodenum is severe,** make a Y-shaped incision (13-12E).

Make your linear or Y-shaped incision through the serous and muscular coats of the anterior wall of the stomach, starting 4cm proximal to the pylorus, and extending over the front of the 1<sup>st</sup> and 2<sup>nd</sup> parts of the duodenum for 3cm beyond the pylorus. If there is an ulcer, centre the linear incision on this, and make it about 1cm above the lower border of the stomach and duodenum, (13-12A).

Use tissue forceps and a scalpel to make a cut through the mucosa of the gastric end of the incision, so as to open the stomach. Enlarge the opening a little with scissors or diathermy. Slowly cut through the remaining mucosa with scissors. Pick up bleeding points as you reach them, or bleeding from the incision will obscure everything. If there are too many haemostats, run a continuous layer of absorbable suture along each side of the incision, and tie the bleeding points.

Inspect the inside of the stomach and duodenum. Mop out clots, and suck out fresh blood, trying to see where it is coming from. Evert the mucosal layer with Babcock forceps.

Place a deep retractor in the upper end of the opening in the stomach and ask your assistant to expose as much of its interior as he can. If necessary, extend the incision 2-5cm proximally. Is there blood trickling down from anywhere? Feel the inside of the stomach. You may see or feel:

- (1) An artery spurting from an ulcer on the posterior wall of the 1<sup>st</sup> part of the duodenum (the common site), or round the corner in its 2<sup>nd</sup> part.
- (2) An ulcer anywhere in the stomach.
- (3) Shallow erosions, high on the lesser curve.

**If there was a haematemesis and you cannot find any abnormality:** put the tip of the sucker, or a swab on a holder, into the second part of the duodenum, to make sure that there is no bleeding from a post-bulbar ulcer.

**If you still cannot find any cause for the bleeding,** try to pass the flexible endoscope through the duodenal opening distally.

**If you find an acute ulcer, a solitary erosion, no longer bleeding, or multiple small bleeding erosions,** close the duodenal opening with a pyloroplasty. Postoperatively, *advise against NSAID drugs.*

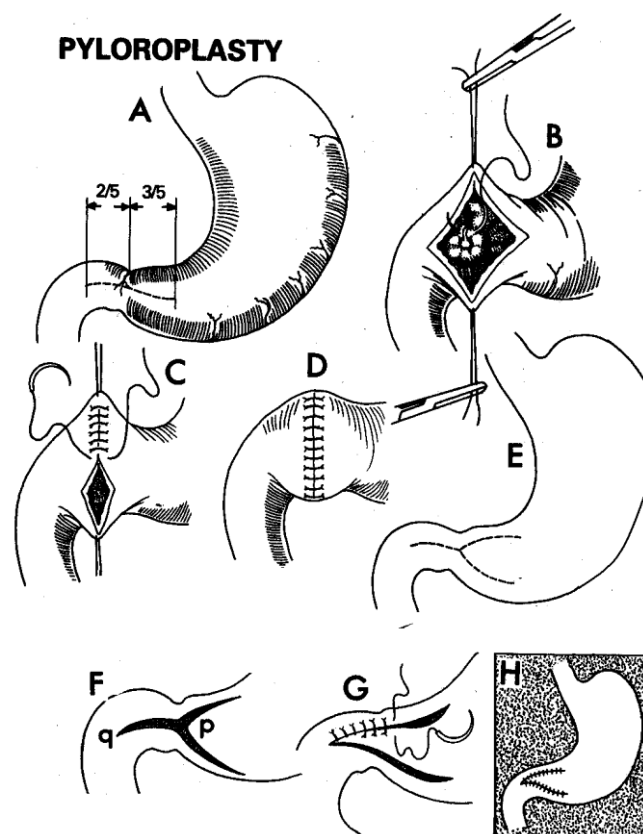


Fig. 13-12 PYLOROPLASTY (Heinicke-Mikulicz).

A, incision when there is only moderate fibrosis. The incision into the stomach is slightly longer than that into the duodenum. B, hold the incision open with stay sutures, held in haemostats, while you undersew a bleeding ulcer. C, pull on stay sutures, so as to elongate the incision transversely. Close it with close absorbable sutures of 2/0 through all coats. D, pyloroplasty completed. E, if there is severe pyloric stenosis, which makes suturing in the transverse direction impossible, make a Y-shaped incision. F, flap of the incision ('p') is going to be sutured into the duodenum ('q') so as to make a 'V'. G, suturing has begun. H, alternative pyloroplasty completed, effectively a Y-V plasty.

**If you find a bleeding ulcer,** control bleeding by undersewing the vessel. Retract the edges of the V-shaped pyloroplasty incision. Using non-absorbable suture on a curved needle, pass 2-3 sutures deep to the ulcer, (13-12B). Tie the sutures so that you stop the bleeding. Ask your assistant to keep the area dry, and be sure to go deep enough to include the walls and base of the ulcer, but not so deep that you catch important structures, such as the common bile duct. Tie the sutures tight, but *not so tight that they cut out.*



**If bleeding continues**, put ligatures transversely across the pancreaticoduodenal artery above and below the centre of the ulcer, *taking care not to damage the pancreas or bile duct in the process.*

**If the ulcer is in the distal duodenum**, mobilize it, and make a small duodenotomy, and undersew the bleeding point as before.

#### PYLOROPLASTY (GRADE 3.4)

##### METHOD.

First make sure bleeding is controlled as described above. The kind of pyloroplasty you should make will depend on the kind of incision you made, which in turn depended on the severity of the fibrosis you found.

If you made a linear incision, because there was only mild fibrosis, hold it open with stay sutures. Pull on these so as to elongate it, and close it *transversely* with 2/0 absorbable sutures through the mucosa and serosa.

**If you made a Y-shaped incision**, because there was much fibrosis, sew it up as a 'V' (13-12G-H).

Finally, with both incisions, bring up a tag of omentum and fix this across the suture line with a few sutures which pick up only the seromuscular layer.

*N.B. Vagotomy for peptic ulceration is really only rarely indicated for proven recurrent peptic ulceration that fails to respond to medical treatment, or, occasionally, where medical treatment is so expensive or just unavailable. This is however an operation for an expert. Consider first if, in your circumstances, a partial gastrectomy might not be a better option, even if you have to refer the patient for this.*

#### DIFFICULTIES WITH GASTROINTESTINAL BLEEDING

**STRESS ULCERATION & HAEMORRHAGIC GASTRITIS** can occur after a burn, head or other injury, major surgical operation, or after alcohol or NSAID medication. These are usually superficial erosions in the stomach or typically in the second or third parts of the duodenum. They are usually multiple, shallow, and irregular. They usually give little pain, and severe bleeding is likely to have been the first sign. Minor harmless gastric bleeding is common after an alcoholic binge. Ulceration of this kind may ooze severely, so that there are melaena stools for several days. Treat with antacids ½hrly, and try a noradrenaline in saline lavage (13.4) and, if possible, IV cimetidine 400mg for 1hr repeated after an interval of 4-6hrs. (Alternatively use a continuous infusion at 100mg/hr over 24hrs, maximum 2-4g od.) Add tranexamic acid 1g IV and then 8hly.

*Do not operate unless the situation is critical.* In this case, you need to devascularize the stomach by ligating both gastro-epiploic arteries as well as the left and right gastric arteries near the gastric wall. This effectively means an emergency gastrectomy! The chances of the patient dying are high, whatever you do.

**If bleeding started after a severe episode of vomiting**, from some other cause, such as a drinking bout, suspect that there is a tear in the oesophagus at, or just above, the gastro-oesophageal junction (the Mallory-Weiss syndrome), *which almost never requires surgery* (30.7).

**If you tear the oesophagus** (*which should never happen!*), repair the tear with a gastric patch bolstered by a fundoplasty (30-6). Leave the nasogastric tube in position, and feed the patient through this later.

**If the bleeding point in the duodenum is obscured by blood**, apply warm packs and pressure, and wait 10mins.

**If bleeding re-starts** after the operation, manage this non-operatively; *do not try to re-explore.*

**If you find what looks like a malignant gastric ulcer**, adapt what you do to the size of the lesion (13.10): if it is small, make a local excision with a 2cm margin, and repair the defect in two layers. If the lesion is advanced, and it is no longer bleeding, take a biopsy, and if it has not metastasized to lymph nodes or the liver, try to get more radical surgery done later if you can. If the lesion is still bleeding, try a figure-of-8 suture with haemostatic gauze, or as a desperate measure, devascularize the stomach as above. (Then arrange a salvage gastrectomy quickly.)

#### DIFFICULTIES WITH PYLOROPLASTY

**If the duodenum is friable and cannot take sutures**, close the gastric and duodenal stumps and so isolate the diseased part of the duodenum. Leave an adjacent drain and a wide-bore nasogastric tube *in situ*. If you can operate quickly, fashion a gastrojejunostomy (13-16); otherwise close the abdomen and return 48hrs later to do so.

**If you cannot close the pyloroplasty without tension**, mobilize the duodenum by dividing its attachment to the posterior peritoneum laterally, after drawing down the hepatic flexure of the colon. (This is the Kocher manoeuvre.)

**If the spleen starts to bleed** during the operation, you have probably pulled too hard on the crus. Pack around the spleen and wait to see if bleeding stops. Then finish the rest of the procedure, and if there is no more bleeding, carefully remove the pack. If further bleeding ensues, depending on your experience, either replace the pack and perform a 2<sup>nd</sup> look laparotomy, or proceed to splenectomy.

**If peptic ulcer symptoms recur**, try to do an endoscopy to confirm this. You will have to resort to medical treatment, especially with proton-pump inhibitors or misoprostol (13.1). Make sure you have eradicated *Helicobacter pylori*. Exclude hypercalcaemia and the Zollinger-Ellison syndrome (gastrinoma, usually of the pancreas).

### 13.6 Hypertrophic pyloric stenosis

In young children, hypertrophic pyloric stenosis is *not* due to duodenal ulceration. It presents as forceful bile-free vomiting, with constipation rather than diarrhoea, in a baby of about 3-6wks; the range can be 5days to 5months. It is more common in boys than in girls, and in the firstborn. To begin with the child vomits 1-2 feeds each day, but as the obstruction gets worse, the vomiting becomes more constant and more projectile. Occasionally, he vomits brownish 'coffee grounds'. If he is not treated, he becomes dehydrated, alkalotic, hypochlorhaemic, hypokalaemic, and *constipated*; he loses weight, and becomes malnourished. Pyloric stenosis is not diagnosed as often as it should be, and is too often thought to be yet another case of 'gastroenteritis'. But *there is no diarrhoea*! Misdiagnosis is a tragedy, because surgery is not too difficult and is very effective.

You should be able to feel the hypertrophied pylorus *with warm hands* as a smooth olive-shaped swelling in the right epigastrium. If the baby cries you certainly won't be able to feel it, so sit him on his mother's lap, and feel for it while she feeds him from the breast. If you have difficulty, return a few minutes later, while she is still feeding him. Sit opposite her, look for waves of gastric peristalsis passing from the baby's left upper quadrant towards the right. As they do so, the pyloric swelling will harden under your finger. Feel for the lump again. *If you are persistent*, you should be able to feel it in all cases: it establishes the diagnosis.

Ultrasound is a key diagnostic tool if you can interpret the images: muscle thickness should be  $>4\text{mm}$  and the pyloric channel length  $>16\text{mm}$  with failure of relaxation.

#### RAMSTEDT'S OPERATION (GRADE 3.3)

**RESUSCITATION.** You can correct minor degrees of dehydration with 60ml boluses of oral Ringer's lactate, but a child with severe dehydration and electrolyte imbalance needs IV fluids: infuse 20ml/hr 5% dextrose in half-strength saline, and reduce this to 10ml/hr when he is passing urine. *Do not administer  $>180\text{ml/kg/24hrs}$ .*

This is not a very urgent emergency and it is best to correct electrolyte loss and dehydration over a period of 24-48hrs before operating. The child will usually stop vomiting as soon as the stomach is empty. If not, aspirate it through a nasogastric tube. After you have corrected any severe dehydration, and the urine outflow returns, add 20-40mol  $\text{K}^+$  to the IV fluid, depending on how ill he is. You should have a  $[\text{HCO}_3^-] < 28\text{mM}$  and  $[\text{Cl}^-] > 100\text{mM}$  for safe recovery from anaesthesia.

#### RAMSTEDT'S PYLOROMYOTOMY

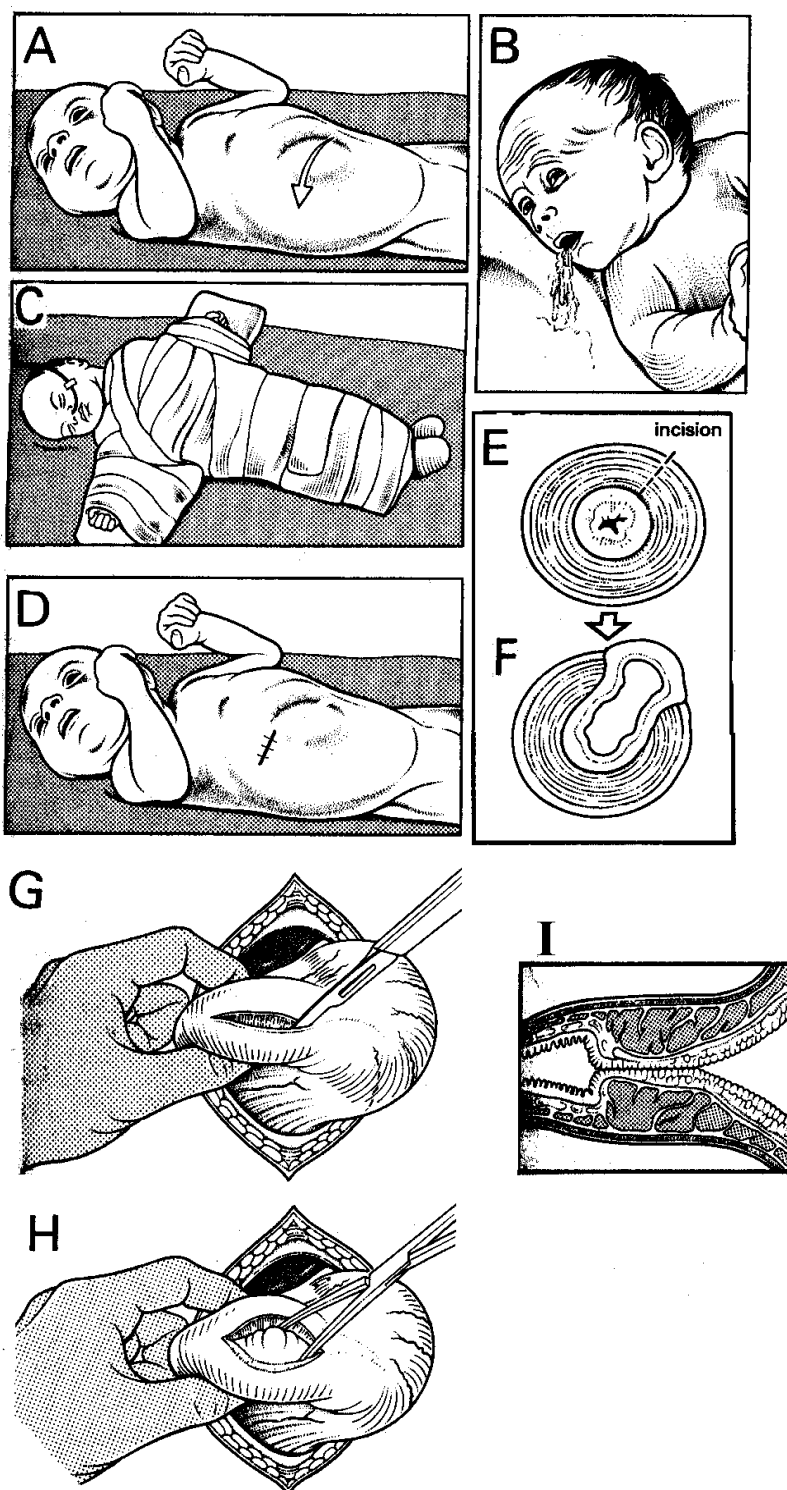


Fig. 13-13 RAMSTEDT'S PYLOROMYOTOMY for hypertrophic pyloric stenosis in young children.

A, waves of visible peristalsis passing across the abdomen. B, projectile vomiting. C, child anaesthetized on a Dennis Browne crucifix. Note the nasogastric tube. Cover the chest loosely and expose the abdomen. D, make a small right upper transverse incision. E, thickened muscle of the pylorus, showing the site of the incision. F, intact mucosa pouting out of the incision. G, incise the pylorus. H, open the incision in the muscle to reveal the mucosa. I, longitudinal section of the pylorus before surgery.

Partly after Harlow W. *An Atlas of Surgery*, Heinemann 1958 Figs 50-51, with kind permission

**INCISION.**

Open the abdomen through a transverse incision, centred over the swelling to the right of the midline (33-3D); it is usually half way between the xiphisternum and the umbilicus. Divide all the tissues in the line of the incision.

Open the peritoneum. Make the incision long enough (3-4cm) to deliver the swelling into the wound. Retract the liver gently upwards and try to find the pyloric swelling. It may be quite difficult to find at first, because it may lie deep, partly covered by the transverse colon. Feel it with your finger. A small retractor may help to deliver it into the wound: it is always mobile.

You can gently pick up the stomach with Babcock forceps to help you find the pylorus, *but do not try to pick up the pyloric swelling with forceps as it will tear*. Hold the swelling between the thumb and index finger of your left hand. Keep your left middle finger against the distal extremity of the swollen pyloric muscle. Turn this so as to expose its antero-superior border.

Cut 1-2mm deep through the circular muscle along the length of the pylorus (33-3F). Start on the top of the swelling and continue just proximal to the white line (the junction of the pylorus and duodenum); at this point (the distal end of the swelling) the wall of the bowel suddenly becomes extremely thin. At this point, make your incision more oblique, or even V-shaped, and keep your cut very superficial. Extend the incision along the whole length of the thickened pylorus and onto the stomach (the proximal end is less clear, because the stomach wall is also thickened). Spread its circular muscle using a haemostat with its concave curve upwards, without harming the submucosa, which should bulge out of the incision. Still using the tip of the haemostat, separate the fibres distally on the duodenal side, under the white line, so as to divide all the circular fibres without perforating the duodenal mucosa (33-3G).

Whilst spreading the muscle, continue to mark and protect the duodenum with the middle finger of your left hand.

**CAUTION!**

- (1) *Do not cut the white line at the site of the pyloric vein*, or you may open the duodenum.
- (2) *Do not sew up the muscle incision*.
- (3) Make sure you have made an adequate myotomy.
- (4) Check for escape of bile or air by massaging air from the stomach distally, or inject air via the nasogastric tube, whilst holding the pylorus under water.

**If you find you have opened the duodenal mucosa**, close it with a 4/0 or 5/0 absorbable suture, *taking care not to occlude the lumen*: you may also suture omentum to cover the hole made by incising the muscle layer. If you have made a V-incision, you can use the distal part to cover the perforation as a transposition flap.

**If a vessel bleeds**, press with gauze for a few minutes; if this fails transfix it with 4/0 multifilament. *Do not use diathermy* as this may damage the mucosa.

Return the stomach to the abdomen, and place omentum over the operation site. Close the abdomen *en masse* with continuous long-acting absorbable sutures.

**POSTOPERATIVELY**, if you have not perforated the duodenal mucosa, remove the nasogastric tube 2hrs post-operatively. If you have made a perforation, leave the tube down for 24hrs, before you remove it and start feeding. If the child is alert, provide sugar water orally by a spoon; if he tolerates this well, start breast-feeding at 6hrs. Proceed with feeding slowly: increase the volume of feed by 50% every 2hrs but leave off for 2hrs if he vomits: the stomach may simply not be ready.

**If the child vomits frequently during the first 24hrs**, wash out the stomach to remove the excess mucus.

**If the child is not taking enough fluid by mouth to maintain an intake of 100ml/kg/day**, infuse 5% dextrose in half-strength saline IV.

**If the child continues to vomit after 48hrs**, you may not have divided the hypertrophic pylorus adequately. If necessary, operate again. Wait however for 1wk to see if he is able to feed; but remember that it is better to operate earlier than allow him to become severely malnourished

### 13.7 Bleeding gastro-oesophageal varices

Bleeding from gastro-oesophageal varices will be a formidable challenge; stopping the bleeding may prove impossible. If there is advanced cirrhosis, the prognosis may be so bad, and you will use up so much blood, that you may not feel it is justified using all your precious resources on this one patient.

Because oesophageal veins communicate with the portal and systemic venous system, they tend to dilate when there is elevated pressure in the portal venous system. The common causes are:

- (1) cirrhosis of the liver,
- (2) periportal fibrosis due to *Schistosoma mansoni* infection,
- (3) non-cirrhotic portal fibrosis,
- (4) portal vein thrombosis.

Death is from loss of blood and liver failure. The final cause of death may be hepatic encephalopathy, due to the failure of the liver to detoxify metabolites from blood absorbed in the bowel, either because its cells have failed, or because blood has been shunted from the liver. Liver failure commonly complicates cirrhosis, but *not* the other causes.

Your aim is to:

- (1) stop the bleeding,
- (2) restore the blood volume,
- (3) prevent encephalopathy.

**ACTION.**

Get the patient to swallow 200ml ice-cold water and if this halts bleeding, repeat after 2hrs. Administer Vitamin K 10mg IV od for 3days, correct hypoglycaemia, and add 10mg propranolol IV over 10min or 20 units Vasopressin in 200ml saline or 5% dextrose over 20min. This may give rise to the side-effects of abdominal cramps, headache, and palpitations. It will also raise the blood pressure for a short time.

*N.B.* Vasopressin loses its activity in the heat, so, if there are absolutely no abdominal cramps, it may well be inactive. Arrange endoscopic sclerotherapy (13-9) if possible.

**If bleeding continues**, insert a Sengstaken tube for 24hrs, then deflate the balloon. If bleeding recurs, repeat the drugs and re-inflate the balloon.

### INSERTING THE SENGSTAKEN TUBE. (GRADE 2.4)

Measure the capacity of the two balloons, and check that neither of them leak. The distal gastric balloon of a large tube holds about 120ml. Inflate the oesophageal one to 30mm Hg, checked against an ordinary sphygmo-manometer. Add the contents of 2 ampoules of 45% 'hypaque' (or a similar contrast medium) to 250ml of saline. Make sure sedation is adequate: ketamine is useful. In an unstable patient, especially with encephalopathy, endotracheal intubation is safer.

Have a sucker available. LA in the nostril, mouth and pharynx is helpful. Lay the patient on his side, and pass the well-lubricated tube quickly through the mouth (or better, the nose); then get him to swallow the tube into the stomach. Advance the tube to the 50cm mark. Inflate the gastric balloon with the saline/'hypaque' mixture.

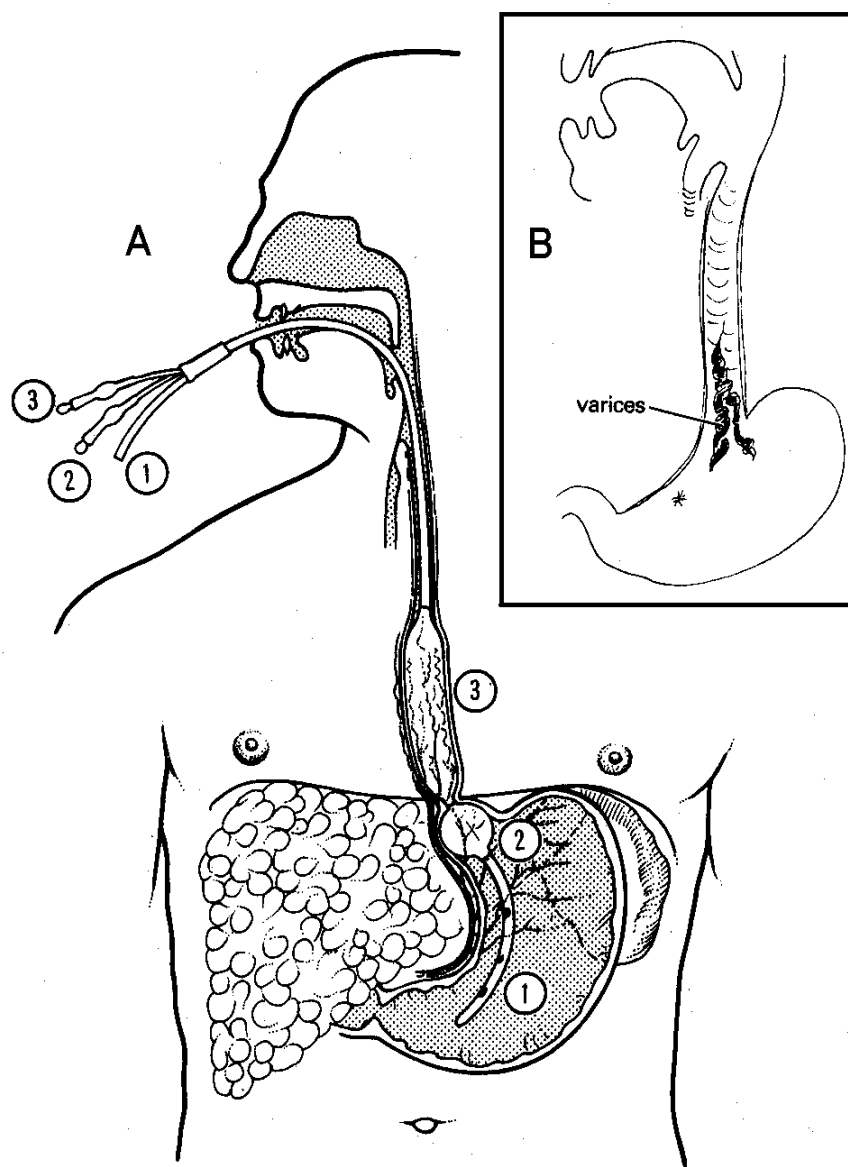
Withdraw it until it impacts against the cardia, and fix it by tape or suture under slight traction tension, *e.g.* to a baseball cap. Inflate the oesophageal balloon to 30mm Hg (c. 50mL). Clamp and check this hourly. Tie a thread round the tube opposite the lips to mark the correct position of the balloons. Take a well-penetrated radiograph to check its position.

Aspirate intermittently from the gastric tube: this will show you if bleeding has stopped. Swallowing saliva will be impossible, so use the lateral position and aspirate continuously from the oesophagus; the Minnesota tube has an extra channel for this very purpose.

After 12-24hrs deflate the oesophageal balloon, then the gastric one, and continue to aspirate the stomach.

**If bleeding starts again** (20% chance), you can apply the tube for a further 12hrs, but this is a sign that surgery is necessary, so try to refer if possible.

## THE SENGSTAKEN TUBE



**Fig. 13-14 THE SENGSTAKEN TUBE.**

A, has 3 channels: (1) to aspirate blood from the stomach. (2) to inflate a balloon in the stomach to anchor the tube. (3) to inflate another balloon in the oesophagus to compress the varices.

B, varices that the balloon tries to compress.

(The Minnesota tube has 4 channels which may be more useful.)

### CAUTION!

(1) If the tube displaces upwards, it may obstruct the glottis, causing respiratory obstruction. Warn the nurses about this, and tell them to remove it quickly if it does so.

(2) *Do not use it in children* because the balloon can compress the trachea.

(3) Deflate the tube after 48hrs. *Do not leave it in any longer*, because the mucosa will necrose.

(4) If you continue to aspirate fresh blood, reconsider your diagnosis: it may be coming from the stomach or duodenum after all.

(5) *Do not take a needle biopsy of the liver whilst in the acute bleeding stage.*

**PREVENT ENCEPHALOPATHY.** Use a saline purge, or magnesium sulphate 10g through the Sengstaken tube. Empty the large bowel with an enema. *Do not allow any protein orally*, but provide glucose through the gastric tube.

#### DIFFICULTIES WITH BLEEDING VARICES

**If you do not have a Sengstaken or Minnesota tube**, use a Foley catheter although this is less satisfactory, except in children. Pass this through the nostril into the stomach, inflate the balloon with 30ml contrast, and draw it upwards so that it presses against the varices at the gastro-oesophageal junction. Either tape the catheter to the cheek or, better, tie it to a weight suspended from a pulley. Get a radiograph and aspirate as above.

**If there is repeated bleeding after you have removed the tube**, the prognosis is not good, but varies with the cause of the varices. If there is cirrhosis, prognosis is bad. Try endoscopic sclerotherapy (13.2): this is difficult unless bleeding has stopped, so try to pass the Sengstaken tube one more time.

**If this fails**, and you have a small size (25-27mm) anastomosis staple gun (4.10), and prothrombin & clotting times are satisfactory, as a rather desperate effort, try an:

#### OESOPHAGEAL TRANSECTION (GRADE 3.5).

##### METHOD.

Make a left subcostal incision, and carefully expose the oesophago-gastric junction. You may need to clear the oesophagus of large vessels by ligating them individually: take your time! Mobilize enough of the oesophagus to be able to get a sling round it. Retract the posterior and anterior vagus nerves out of the way if possible.

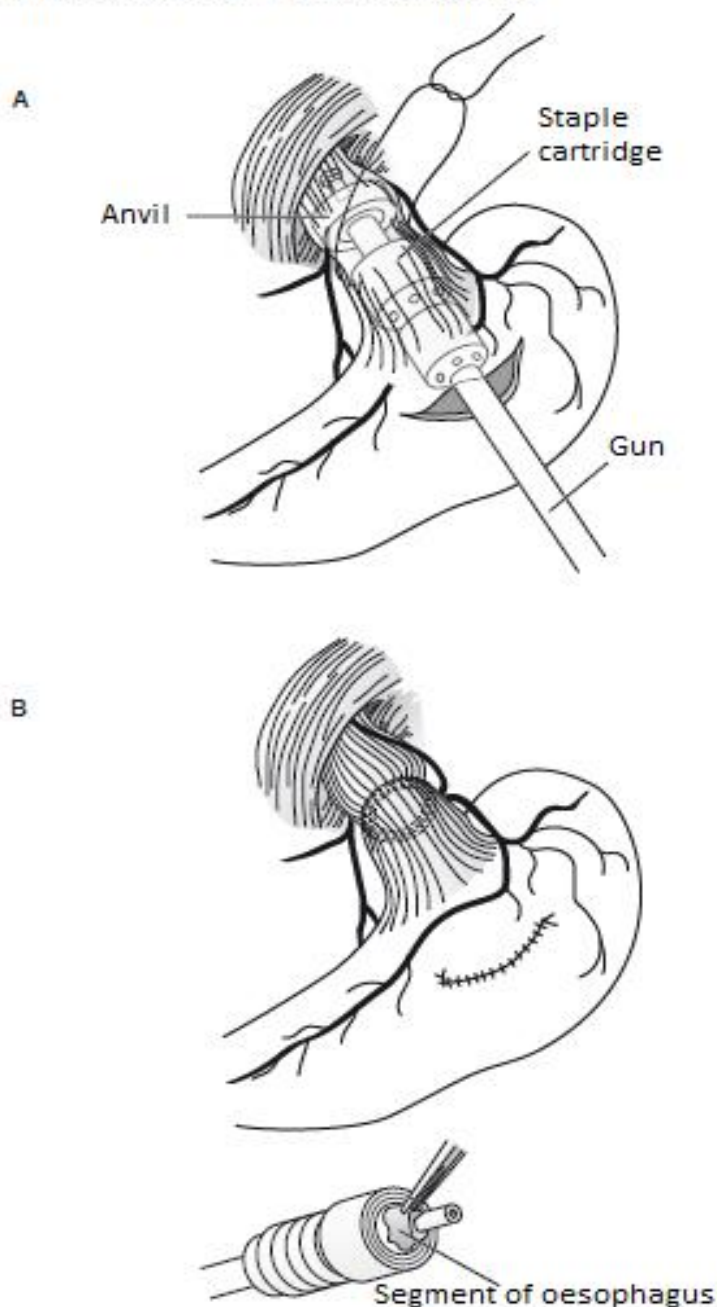
Make an anterior gastrotomy, and pass the opened stapling device through the gastro-oesophageal junction; position the opened end where you intend to transect the oesophagus and tie a strong silk ligature around the stem of the device, screw it closed and fire the gun.

This transects the varices and re-anastomoses the oesophagus (13-15). Then close the gastrotomy, and if possible, tie off the left gastric vein.

This is heroic surgery and *may well not be what you should attempt in your setting without help!*

*N.B.* The varices will be likely to recur unless you can alleviate the problem of portal hypertension. Simple treatment of schistosomiasis, in an endemic area, may however achieve this.

#### TRANSECTING THE OESOPHAGUS



**Fig. 13-15 OESOPHAGEAL TRANSECTION USING THE ANASTOMOSIS STAPLING GUN.**

**A**, pass the instrument into the lower oesophagus via a gastrotomy, with the anvil separated and a strong ligature tied around the entire oesophagus. **B**, after firing the gun and closing the gastrotomy.

*After Kirk RM, Williamson RCN. General Surgical Operations Churchill Livingstone 2<sup>nd</sup> ed. 1987 p.208 Fig 11.6a,b*



### 13.8 Gastric outlet obstruction

Scarring from a chronic duodenal ulcer, TB or ingestion of caustic sometimes causes pyloric obstruction (stenosis). Obstruction may also be caused by carcinoma of the distal stomach (13.10). The patient may come to you saying that he has been vomiting for days or weeks. He may only vomit once a day or he may say that he vomits 'everything he eats'. The vomit may contain food that he ate days before. Or, he may not actually vomit, but merely feel abnormally full and bloated after only small amounts of food. He may be burping, and he may have taught himself to vomit to relieve the symptoms. He loses weight. Continued vomiting depletes the extracellular fluid, and causes hypochloraemic alkalosis, and hypokalaemia; eventually he becomes dehydrated, wasted and oliguric.

Try to confirm the diagnosis either by endoscopy (13.2) or Barium meal. A biopsy is necessary to differentiate between malignant and benign causes. TB may need deep 'well' biopsies. Rarely there is a pyloric web. Very occasionally, the stomach is distended by a huge bezoar (13.11) or by chronic binge eating (bulimia).

To relieve the obstruction, if you cannot perform an endoscopic dilation (13.2), a gastrojejunostomy is the answer: this is anastomosing the jejunum side-by-side to the gastric antrum. As the pylorus is usually badly scarred, or infiltrated by tumour, *do not perform a pyloroplasty*.

*In infants, hypertrophic pyloric stenosis is a different entity altogether (33.4).* In Chagas disease, the myenteric plexus may be involved, giving rise to achalasia of the pylorus (30.6): this results in pyloric obstruction without any visible stenosis. You can perform a pyloromyotomy (as in the infant) to deal with this.

**EXAMINATION.** Lay the patient down and look for visible gastric peristalsis, as the stomach struggles to empty itself through a narrowed pylorus. Look for slow waves moving from the left hypochondrium towards and beyond the umbilicus. Rock the patient from side to side. You may hear a succussion splash even without a stethoscope. You may also hear it if you depress the epigastrium sharply with your hand; (*beware:* a splash may be normal after heavy drinking or a large meal).

#### PREPARATION

**WASHOUTS** will empty the stomach, remove debris, and provide some relief of colic. With luck, the inflamed and oedematous pylorus will open up. Washouts will also reduce the risk of postoperative infection.

Find a funnel, a *large* (Ch36, 10mm diameter) stomach tube or a catheter, and a longer piece of rubber connecting tube the same size. With the patient prone with the head supported over the end of the bed, pass the well-lubricated stomach tube through the mouth and encourage him to swallow it. Connect the stomach tube via the other tube to the funnel. Hold up the funnel and pour in 500ml of tepid water (250ml in a child).

Before the last drop has left the funnel, lower it over a bucket (to prevent air entering). The stomach contents will run out. Repeat the process, this time using 11 water. Go on doing this until the fluid returns clear. Finally, leave 500ml inside the stomach. Repeat this daily, for 3days, or until he is fit for surgery, whichever is later. *Do not perform the wash out on the day of operation!*

**CAUTION!** Check the volume of water you have run in and out: a marked discrepancy indicates the stomach has perforated.

**RADIOGRAPHS** are useful if the diagnosis is in doubt. Take an erect abdominal film, and look for a large fluid level in the left upper quadrant. A drink of barium will produce a mottled shadow showing that the gastric outline is much enlarged. Little or no barium passes the pylorus. *Do not administer a large quantity*, because it may be difficult to wash out, and the patient may vomit and aspirate.

**REHYDRATION** may be necessary over several days to restore the extracellular fluid volume. Treat with 0.9% saline or Ringer's lactate. If necessary, correct the potassium loss with up to 80mmol of potassium od, or use Darrow's solution ( $[K^+]=34mM$ ). Be guided by the volume and specific gravity of the urine output.

#### GASTROJEJUNOSTOMY FOR PYLORIC STENOSIS (GRADE 3.4)

##### INDICATIONS.

- (1) Pyloric obstruction causing dehydration and weight loss, or other long-standing obstructive symptoms as described above.
- (2) Duodenal ulceration with sufficient scarring to contraindicate pyloroplasty; combine it with a truncal vagotomy.
- (3) As a palliative procedure for stenosis caused by an antral carcinoma or gastric outlet obstruction by pancreatic carcinoma.

##### EXPOSURE.

Make an upper midline incision. If you find a large thick walled stomach, the diagnosis of pyloric stenosis is confirmed. Ask your assistant to retract the liver upwards with a deep retractor, and to draw the stomach downwards at the same time. Make sure there is enough room, because traction may tear the spleen.

**Is the cause malignant?** If there are hard nodules, enlarged hard lymph nodes, and perhaps an ulcer crater, just proximal to the pylorus, suspect a gastric carcinoma.

**If there is a mass in the head of the pancreas pressing on the duodenum from behind**, suspect a pancreatic carcinoma. Biopsy a node, and perform an anterior gastrojejunostomy.

**Is the cause benign?** If there is:

- (1) Puckered scarring on the front of the first part of the duodenum, perhaps with adhesions to surrounding structures.
- (2) An indentation on the posterior wall of the stomach extending into the pancreas to which it is fixed, suspect a chronic peptic ulcer, or tuberculosis.

Carcinoma rarely affects the first part of the duodenum, so that lesions there are almost certainly benign.

## METHOD.

**If you are not sure what is obstructing the outlet of the stomach,** perform a gastrojejunostomy and biopsy a regional node. *Do not biopsy the stomach or pancreas itself* unless you intend to resect it.

## GASTROJEJUNOSTOMY

Apply a non-crushing clamp (13-16C), to hold  $\frac{2}{3}$  of the width of the bowel, and another non-crushing clamp to hold the stomach. Insert stay sutures through the seromuscular coats of the stomach and jejunum at each end.

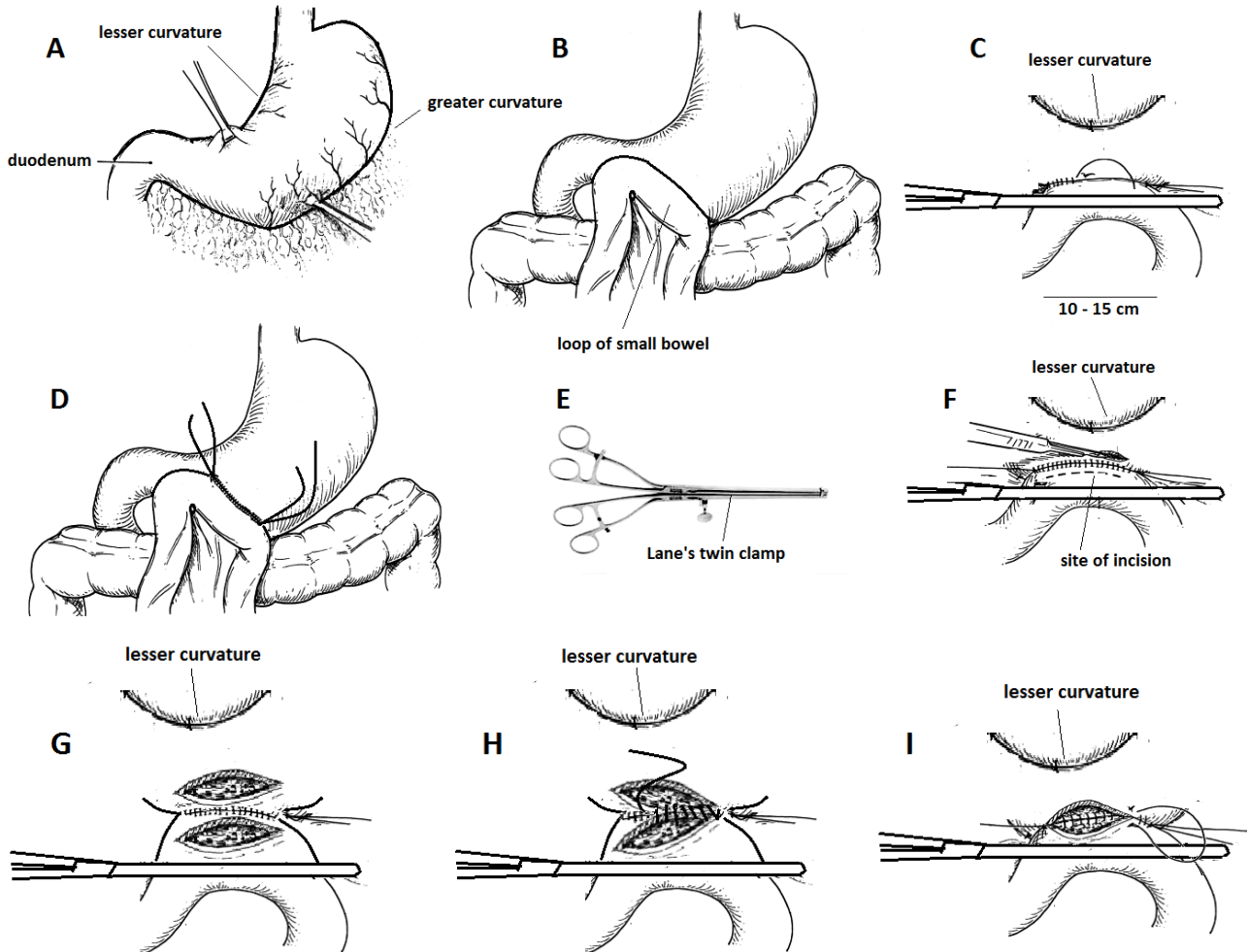


Fig. 13-16 GASTROJEJUNOSTOMY.

A, hold the stomach distally with Babcock forceps. B, pull up a proximal loop of jejunum with no tension. C, apply a non-crushing clamp to the jejunum. D, finish the posterior seromuscular (Lembert) layer. E, Lane's twin clamps are double non-crushing clamps which click together and simplify the anastomosis (especially without an assistant). F, open the stomach and jejunum (you can use cutting diathermy for this). G, stomach and jejunum opened. H, start the inner posterior all-coats layer. I, continue this as a Connell inverting suture on the anterior layer. Then remove the clamps and finish the outer anterior layer, and test the anastomosis digitally.

Grasp an 8cm segment of distal stomach, though far enough from any pathological lesion, and apply Babcock's forceps about 6cm apart (13-16A). Find the upper jejunum and apply Babcock forceps similarly (13-16B).

The first should be about 8cm from the duodeno-jejunal flexure, and the second about 6cm distal.

The stomach wall is likely to be thick, perhaps very thick, if the pyloric stenosis is long-standing. Complete the layer of continuous seromuscular sutures using 2/0 long-acting absorbable (13-16D).

(If you have Lane's twin clamps (13-16E), these will hold stomach and jejunum in position for you to operate without an assistant.)

Open the stomach by cutting parallel to the seromuscular suture line for 5cm (13-16F); then, open the jejunum for an equal length, half way between the suture line and the clamp (13-16G). Use 2/0 atraumatic absorbable suture for the 'all coats' inner posterior layer (13-16H), starting at one end and continuing with an inverting Connell suture anteriorly (13-16I), in the same way as for a side-to-side anastomosis (11-10). Then complete the outer anterior layer. Remove the clamps. Feel the size of the stoma: it should admit 2 or 3 fingers. Cover the anastomosis with omentum.

**CAUTION!**

(1) Be sure to include all layers of the stomach wall in the anastomosis. If it is hypertrophied, the cut edges of its mucosa will curl away. If you fail to include them in your sutures, they may bleed, or the suture line may leak.

(2) *Take care not to rupture the spleen, or the gastrosplenic vessels* by pulling on the stomach too much: make sure you have adequate exposure.

Make sure a nasogastric tube is in place; if the patient is severely hypoproteinaemic, pass the tube into the jejunum through the gastrojejunostomy, and start enteral feeding as soon as bowel sounds resume.

*N.B.* There is no real advantage of performing a retrocolic gastrojejunostomy: *do not do this for malignant disease.*

**DIFFICULTIES WITH A GASTROJEJUNOSTOMY**

**If aspiration  $\geq 11$  fluid continues after the operation,** the stoma is not functioning, or there is paralytic ileus. Bowel sounds and the absence of abdominal distension will exclude ileus.

The stoma will be less likely to obstruct, if you make it big enough to take three fingers. It may remain obstructed for 2wks especially if the patient is hypoproteinaemic. Continue nasogastric suction, unless there is an indication to re-operate, and correct fluid losses. The stoma is almost certain to open eventually. You may be able to encourage it to function by passing an endoscope through it, or inserting a feeding tube into the jejunum.

**If, some time after the operation, there is bilious vomiting,** reassure the patient. Bile and pancreatic juice are accumulating in the afferent loop, and when they are suddenly released into the stomach, he vomits. The symptoms will probably improve with time. If they do not do so after 2yrs, consider a revision procedure.

**If there is persistent very loose diarrhoea and vitamin deficiencies develop,** you may have made a gastro-ileostomy in error: perform a Barium meal to check. If you have, reopen the abdomen, take down the anastomosis, resect the portion of ileum you inadvertently used, and perform a gastrojejunostomy!

**If a recurrent ulcer on the stoma develops** (which you will probably only find by endoscopy), treat it medically in the first instance; re-do surgery is complicated.

**If there is malignant gastric outlet obstruction,** perform a gastrojejunostomy, proximal enough to avoid the tumour (13.10).

**DIFFICULTIES WITH CHRONIC DUODENAL ULCERATION**

If medical treatment fails, or is too expensive, you may be able to help a poor patient by operating. If there is uncontrollable pain and dyspepsia, or if the quality of life has been spoilt over the years by nagging pain, heartburn, and indigestion, there may be still a place for a truncal vagotomy and gastrojejunostomy or pyloroplasty.

*Do not wait until there is severe haemorrhage, or the overwhelming vomiting of pyloric obstruction.* Try by all means, however, to confirm the diagnosis before laparotomy, because the real diagnosis may be a chronic pancreatitis, liver disease, cholecystitis, or other abdominal pathology, or actually be psychosomatic!

**13.9 Gastrostomy**

**If the oesophagus is obstructed,** swallowing food is impossible and so starvation results. Saliva cannot descend, so it drips from the mouth. You can feed such a patient through an opening in the stomach, but this will not help him to swallow saliva. This is such a disabling symptom, that there is little to be gained by prolonging life merely to endure it. There is thus seldom an indication for doing a gastrostomy for inoperable carcinoma of the oesophagus or pharynx. The possible indications for it are given below. For many of them a jejunostomy (11.7) is a better alternative. Otherwise, you may be able to introduce a feeding gastrostomy percutaneously with the aid of a gastroscope: this is difficult without the right gadgets, and may well give you big complications. So attempt it only if you have mastered the use of the endoscope and you have all the necessary equipment available.

**INDICATIONS.**

(1) Temporary feeding during recovery from bulbar palsy or curable pharyngeal disease (*e.g.* retropharyngeal abscess).

(2) Temporary postoperative drainage of the stomach, when a nasogastric tube is impractical, *e.g.* where there is severe respiratory embarrassment.

(3) Treatment of a duodenal fistula: one tube is used for gastric aspiration, and another passed into the jejunum for feeding.

*N.B.* A feeding jejunostomy (11.7) is preferable to a gastrostomy prior to oesophageal reconstruction.

**GASTROSTOMY (GRADE 3.2)**

**METHOD.** Under LA or GA make a small upper midline incision. Pick up the cut edges of the peritoneum and draw them apart. You will probably find that the stomach is small and tubular, so that the first thing that you see is the greater omentum or transverse colon. Pull this downwards and deliver the upper part of the stomach into the wound.

**CAUTION!** Check that you really have found the stomach, and not the transverse colon by mistake! **If you have opened the colon,** close the perforation in two layers (14.3), and continue the operation *unless there was massive soiling.*

Make a small stab incision lateral to the midline and use a haemostat to pull a Ch20 or Ch24 Malecot or Foley catheter through it. Make the gastrostomy high on the anterior wall of the stomach, midway between its greater and lesser curves, and as far from the pylorus as you can. Hold the stomach with two pairs of Babcock's forceps, and draw it upwards and forwards into a cone.

## GASTROSTOMY

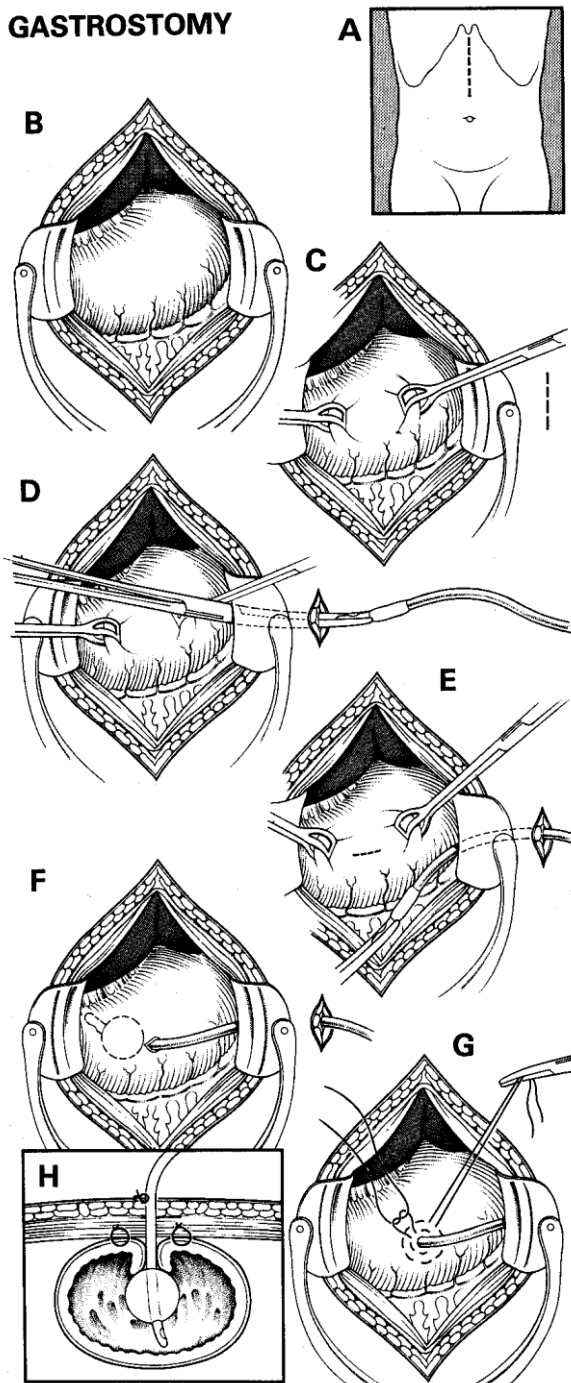


Fig. 13-17 GASTROSTOMY.

A, incision. B, expose the stomach. C, pick up the stomach with Babcock forceps. D, introduce the catheter through the abdominal wall. E, incise the stomach. F, introduce the catheter. G, purse string sutures. H, invaginate the stomach wall.

Make a small incision between the forceps, aspirate the gastric contents and push the catheter through this. Encircle it with 2 purse string sutures, and invaginate the stomach wall as you tie them

### CAUTION!

(1) Take the bites of the inner purse string suture through the full thickness of the stomach wall, so as to control bleeding: the main dangers are haemorrhage and leaking.

(2) The gastrostomy must be leak-proof, so that gastric juice does not enter the peritoneal cavity, so test it by flushing water through the tube. If there is no leak, anchor the stomach above and below the tube to the posterior rectus sheath. Close the tube with a spigot, and fix it to the skin with an encircling suture. Before the patient leaves the theatre, instil some fluid through the tube, to make sure it is patent.

### DIFFICULTIES WITH A GASTROSTOMY

**If stomach content leaks early around the tube,** inflate the balloon more, or insert a larger sized catheter.

**If stomach content leaks later around the tube,** and there is no abdominal pain, this may be due to some pressure necrosis of the gastric wall from the balloon, or infection of the adjacent abdominal wall. Try a course of gentamicin; if the leak persists, remove the tube and allow the gastrostomy to drain naturally. It will start to close, and before the stoma is completely shut, re-insert a catheter if the gastrostomy is still needed.

**If the gastrostomy tube falls out or is blocked,** re-insert a new one through the same track, if necessary with a guide wire. If you can, check by endoscopy that it is in the stomach. If you use a paediatric gastroscope or uroscope, you can pass this through the stoma to view the stomach directly.

**If there is bleeding from the gastric tube,** it is probably due to irritation from small vessels around the stoma; insert and inflate a larger catheter balloon to tamponade these vessels. If this fails, perform an endoscopy to rule out gastric ulceration, and treat this with cimetidine or omeprazole.

**If there is persistent vomiting after gastric tube feeds, or the upper abdomen swells, or undigested food comes out via the tube,** the tube and its balloon has probably migrated and got stuck in the pylorus. Deflate it, and re-inflate it just after its entrance into the anterior wall of the stomach.

**If there is excess granulation around the stoma,** apply silver nitrate.

**If faecal matter comes out via the gastric tube,** this is probably because the tube was inadvertently inserted into the stomach through the colon! This requires a laparotomy to disconnect the stomach from the colon, which will not be easy.

**If peritonitis develops,** there may be a leak into the abdomen from the open stomach, or a perforation of a gastric ulcer, or another cause. Perform a laparotomy.

**If necrotizing fasciitis (6.23) develops around the stoma,** start broad-spectrum antibiotics, resuscitate with IV fluids and perform a wide debridement immediately.

**If you find a pneumoperitoneum on an erect chest radiograph (12-2),** and there are no signs of peritonitis, there is no indication for surgical intervention.

### 13.10 Gastric carcinoma

Carcinoma of the stomach presents usually in a male >40yrs with:

- (1) Dyspeptic symptoms which may last for months, before he presents with anorexia, nausea, and increasingly severe dyspepsia. The pain lacks the periodicity of peptic ulcer pain, and is not relieved by food.
- (2) Vague ill-health, anaemia, and weight loss.
- (3) Vomiting 'coffee grounds' (altered blood), or passing melaena stools.
- (4) Vomiting after food; a distal gastric carcinoma causes protracted vomiting, like that of pyloric stenosis due to a duodenal ulcer (13.8).
- (5) An upper abdominal mass, due either to the carcinoma itself, or to metastases in the liver.
- (6) Jaundice, usually due to malignant nodes in the porta hepatis.
- (7) Ascites as the result of peritoneal deposits.
- (8) Other symptoms of secondary spread.

Gastric carcinoma may take the form of:

- (1) a cauliflower type of growth;
- (2) a malignant ulcer with raised, irregular everted edges, especially in the distal third of the lesser curve;
- (3) diffuse infiltration, either in its antrum, causing pyloric stenosis, or more diffusely ('leather bottle stomach'). Lymphatic involvement and spread to the liver occur early. Late presentation is the norm.

*Radiotherapy and chemotherapy are not very useful.*

You may not be able to perform a partial or total gastrectomy, so try to:

- (1) Make the diagnosis as best you can.
- (2) Select out any resectable and potentially curable cases. These are mostly those with a small lesion seen on endoscopy or with a barium meal.
- (3) Perform a palliative gastrojejunostomy (13.8), if the pylorus is obstructed. This will make the patient's last days a little more bearable, stop him vomiting, and improve nutrition temporarily.
- (4) As always, palliate and comfort him as he dies (37.1).

#### EXAMINATION.

Look and feel for:

- (1) An enlarged hard supraclavicular (Virchow's) node.
- (2) A firm, or hard, slightly mobile, irregular epigastric mass, separate from the patient's liver.
- (3) An enlarged and often irregular firm to hard liver.
- (4) Signs that the stomach is not emptying normally: visible peristalsis, a tympanitic epigastric swelling, and a succussion splash.
- (5) Signs of advanced disease: cachexia, jaundice, and ascites (1-10).
- (6) Deposits in the rectovesical pouch: feel for a firm, fixed 'rectal shelf'.

**SPECIAL TESTS.** If there is a firm enlarged accessible node, especially in the supraclavicular fossa, biopsy it.

**RADIOGRAPHS.** If possible, get a barium meal. There will probably be a filling defect, or an ulcer, which you can see quite easily on screening. Inhibited peristalsis suggests a tumour.

**ULTRASOUND** will often show a mass in the region of the stomach, separate from the liver.

**DIFFERENTIAL DIAGNOSIS** is mainly that of 'dyspepsia'. Endoscopy is most helpful.

**Suggesting peptic ulceration:** a long history (>2yrs); periodic rather than constant pain.

**Suggesting non-ulcer dyspepsia:** diffuse tenderness, no mass, less weight loss, and a variable appetite.

#### MANAGEMENT.

If you think the tumour might be operable, try to evaluate it endoscopically. If the tumour is on the lesser curve, metastatic spread to lymph nodes occurs early. If the tumour is within 5cm of the gastro-oesophageal junction, excision may still be possible by an abdominal approach.

Before deciding on major surgery, remember that although a partial gastrectomy might be feasible, if you do not manage to remove all the tumour and metastatic nodes, you can only palliate the condition. Therefore *do not attempt gastrectomy unless your goal is clear: i.e. relief of intractable symptoms, stopping haemorrhage, or cure of the cancer.*

**If there are signs of progressive pyloric obstruction,** causing daily vomiting, with no signs of advanced disease (except perhaps metastatic cervical nodes), perform a gastrojejunostomy (13.8). Choose a part of the stomach wall near the greater curvature,  $\geq 5$ cm proximal to the mass. Make the stoma well away from the tumour, and make it big ( $\geq 5$ cm), in the hope that it will stay open until he dies. Make it on the anterior or posterior aspect of the stomach in front of the colon. Try to refer the patient afterwards for definitive surgery.

**If there is dysphagia because of obstruction at the cardia,** *do not try to insert a Celestin tube*, as for carcinoma of the oesophagus (30.5), because you may well perforate the oesophagus doing so, and it will be difficult to keep in place. The only feasible option is an oesophago-gastrectomy which is very major surgery.

#### PARTIAL (Polla/Bilroth II) GASTRECTOMY (GRADE 3.5)

#### PREPARATION.

Organize chest physiotherapy. Cross-match 2 units of blood. Empty the stomach with a nasogastric tube.

**EXPOSURE.** Make a midline incision that extends below the umbilicus; divide the *ligamentum teres* and falciform ligament. Explore the whole abdomen looking for metastases. Assess the mobility of the tumour.



**METHOD.** Make an opening in the gastrocolic omentum and lift the stomach gently off the pancreas and mesocolon. Clamp and divide the gastrocolic omentum in sections including the left gastro-epiploic vessels and first 2 short gastric arteries on the left side, and the right gastro-epiploic vessels on the right; do likewise with the right gastric vessels in the lesser omentum close to the lesser curve. Avoiding the biliary tree, free the first 1-2cm of duodenum, apply crushing clamps across it, and divide between them. Close the duodenal stump in 2 layers with long-acting absorbable suture.

Lift up the mobilized stomach and apply non-crushing clamps (preferably Lane's) proximally across it, and crushing clamps just distal to these; divide between them. Bring up a loop of proximal jejunum 10-12cm from the duodeno-jejunal flexure so that the afferent loop lies against the lesser curve, and apply non-crushing clamps. Approximate the gastric stump and jejunum and make an end-to-side anastomosis (11-9). Lavage the abdomen, examine the spleen for lacerations and close.

**POSTOPERATIVELY.** Treat the patient sitting upright in bed, and make sure he gets vigorous chest physiotherapy. There is no evidence that a nasogastric tube is helpful postoperatively. *Do not put one in after the operation*, because you may perforate the anastomosis with it!

#### DIFFICULTIES WITH GASTRECTOMY

**If there is significant bleeding after gastrectomy**, place a pack, press and wait 5mins. Look at the spleen: if it is badly damaged, remove it (15.17).

**If you cannot close the duodenal stump**, insert a Ch20 Foley catheter to produce a controlled fistula.

### 13.11 Gastric stricture

Swallowing a corrosive causes damage to the oesophagus (30.3) but ingestion of concentrated acid causes intense spasm of the pylorus, allowing the corrosive acid to pool in the body of the stomach. This produces an intense inflammatory reaction and subsequent scarring, resulting in a stricture of the terminal portion of the body of the stomach or antrum. If you use antacids in the acute situation, the acid is neutralized in a highly exothermic reaction which burns the gastric mucosa further. The resulting stricture may take months to develop; the vomiting of gastric outlet obstruction is frequently preceded by heartburn, epigastric pain and anorexia. Later carcinoma develops in the scar.

#### EXAMINATION.

Look for a gastric splash in a grossly cachectic patient who has a history of acid ingestion.

#### SPECIAL TESTS.

Barium meal shows a typically distended proximal stomach with a long narrowed stricture extending to the pylorus with complete loss of rugosity and lack of motility (hour-glass stomach).

Endoscopy will show a stricture not admitting the endoscope.

#### MANAGEMENT.

Because of gross malnourishment, perform a simple proximal gastrojejunostomy (13.8) unless you have done a feeding jejunostomy (11.7) beforehand. *Do not perform a pyloroplasty* because the thickened scarred pylorus does not hold sutures well. *Do not try a gastrectomy unless nutrition is satisfactory*; if gastric carcinoma has developed it is best to feed first by a jejunostomy and then arrange a partial gastrectomy (13.10) when body weight has been regained.

### 13.12 Gastric foreign bodies

Most ingested foreign bodies will pass through the pylorus and exit *via* the anal canal, although their passage is often missed unless stools are examined assiduously. However, large, long, sharp or multiple objects may impact at the pylorus. Most of the time these do not result in gastric outlet obstruction, but may cause obstruction in the small bowel. They may not pass if there is pyloric stenosis from another cause. Occasionally they may cause bleeding or even perforation, especially alkaline disc batteries, or potassium tablets.

**Bezoars** are concretions of ingested material: *trichobezoars*, principally hair (chewed by long-haired girls), or *phytobezoars*, (unripe persimmons or citrus fruits). These form a glutinous mass in the stomach which eventually can occupy the whole organ, and cause obstruction, as well as bleeding, anaemia, weight loss, mimicking malignancy.

#### INDICATIONS FOR EXTRACTION OF GASTRIC FOREIGN BODIES

- (1) Impacted foreign bodies at the pylorus,
- (2) Haematemesis and/or melaena,
- (3) Multiple foreign bodies accumulating in the stomach,
- (4) Danger of or actual gastric perforation,
- (5) Danger of toxic absorption of chemicals (*e.g.* heroin)

#### SPECIAL TESTS.

Plain abdominal radiographs will show metallic objects; remember to take these films just prior to any attempt at removal, because foreign bodies are notorious in moving on! A bezoar may show up as a mottled density, but is often not seen on Barium studies because the contrast infiltrates into the bezoar.

Endoscopy confirms the diagnosis.

## MANAGEMENT.

Allow smooth foreign bodies to pass naturally: be patient and wait 4wks if necessary. *Do not be tempted to perform an unnecessary gastrotomy.*

Endoscopy may not be so easy because you may have difficulty grasping the foreign body, and pulling it out may damage the oesophagus on the way through. It is best if you can pass a protective plastic sheath over the foreign body before pulling it out together with the endoscope *en bloc*, especially with ingested heroin packets which may rupture on removal causing sudden absorption of opioid.

Dissolving a phytobezoar is usually possible with oral cellulose, coca-cola, acetylcysteine, or papain; the latter can be given as papaya (paw-paw) fruit, followed by gastric lavage. Metoclopramide 10mg qid or erythromycin 500mg qid help in emptying the stomach afterwards.

If these measures fail, you may need to extract these objects *via* a gastrotomy

## GASTROTOMY FOR EXTRACTION OF FOREIGN BODIES

### INDICATIONS:

- (1) Where endoscopy has failed, is impossible or is unavailable.
- (2) Gastric perforation.
- (3) Trichobezoar.

### GASTROTOMY (GRADE 3.2)

**EXPOSURE.** Make sure the stomach is emptied with a nasogastric tube. Make a midline upper abdominal incision. Palpate for the foreign body in the stomach and examine the duodenum and small bowel for further foreign bodies, especially broken-up bezoars; if you find these, try to break them up and push them into the colon. Check if there is any evidence of perforation.

**METHOD.** Clamp the proximal stomach with a non-crushing clamp. Open the stomach longitudinally proximal to the pylorus, and extract the foreign body, taking care not to cause further damage if the object is sharp.

Beware of injury to yourself also! Close the gastrotomy transversely with long-acting absorbable suture. Continue nasogastric drainage postoperatively till the aspirate is no longer blood-stained. Treat with antacids when eating begins.

## 13.13 Gastric volvulus

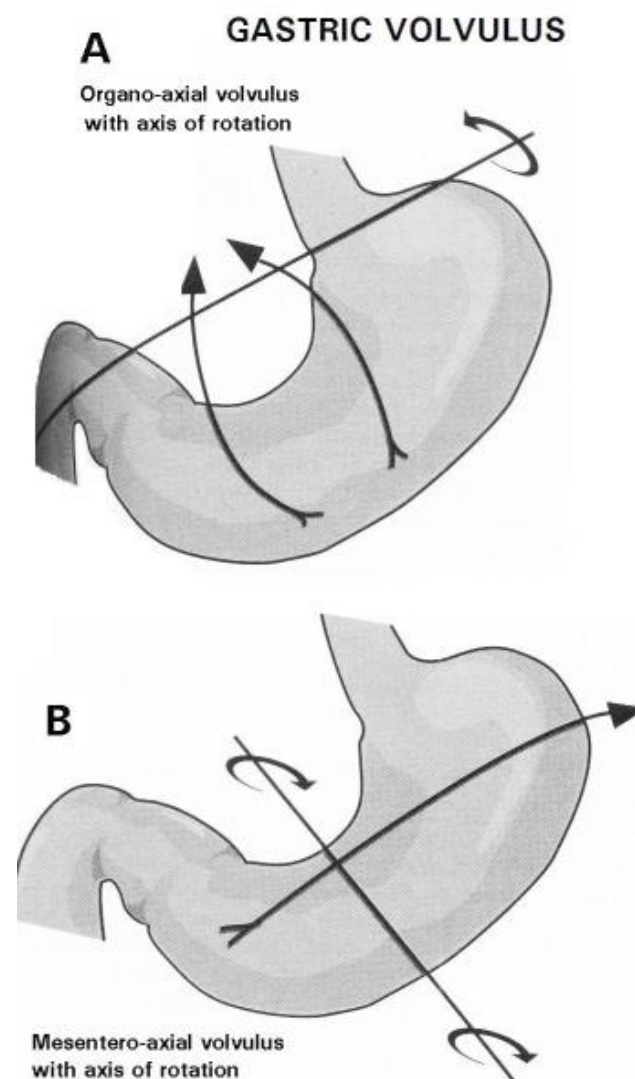
The stomach can twist around its long (organo-axial) or rarely, its transverse (mesentero-axial) axis if ligaments are lax or absent (13-18). This twisting may be complete or partial. There may be other pathology associated: peptic ulceration, gastritis and hiatus hernia, especially a diaphragmatic defect.

**If it is acute**, the result is non-productive retching after recent foods had been swallowed. Frothy retching of saliva is typical. Upper abdominal pain is intense, and circulatory collapse occurs early. A nasogastric tube does not usually pass into the stomach.

**If it is chronic**, there are episodic bouts of crampy upper abdominal pain and retching. There is usually dysphagia and an inability to burp. Gastric peristalsis is noisy after meals, but less so on lying down; the patient may need to adopt strange postures to get his food down. However, usually you will only make the diagnosis after contrast studies, or endoscopy.

### SPECIAL TESTS.

Abdominal radiographs show a grossly distended stomach with a double fluid level on an erect film. (The stomach may have herniated into the chest if there is a diaphragmatic defect, which is common in infants). An ECG is useful to differentiate from myocardial infarction.



**Fig. 13-18 GASTRIC VOLVULUS.**

**A, organo-axial. B, mesentero-axial volvulus.** After Morris PJ, Malt RA. *Oxford Textbook of Surgery*, OUP 1994 p.953 Figs 1,2.

*N.B. Barium studies are unhelpful in the acute case.*

Endoscopy however may be helpful and may allow spontaneous untwisting, but not in the chronic case because the abnormal orientation of the stomach is very difficult to interpret. Barium studies show the greater curve facing superiorly and the body of the stomach assuming a globular shape, if the volvulus is incomplete and some contrast passes into the stomach.

There may be associated motoneurone disease or similar myopathy in the chronic type.

#### MANAGEMENT.

Try passing a nasogastric tube to deflate the stomach: this will buy you time in a chronic or incomplete case.

At laparotomy you may have difficulty seeing the stomach as it is tucked away in the left hypochondrium; you will need to decompress the distended twisted stomach by a needle or small-bore suction tube before you can untwist it.

Simple gastrostomy (13.9) fixes the stomach, but this is not usually a permanent solution.

For organo-axial volvulus, fixing the greater curve to the duodeno-jejunal flexure seems to be successful. In Tanner's gastropexy you have to detach the transverse colon from the stomach, and place the colon under the left hemidiaphragm. Then fix the stomach to the edge of the liver and falciform ligament. A feeding gastrostomy helps to avoid gastric stasis postoperatively.