

18 Hernias

18.1 General principles

An external abdominal hernia is the protrusion of the contents of the abdomen (any abdominal organ, part of the omentum, or peritoneal fat) through an abnormal opening in the abdominal wall. The swelling varies in size from time to time, but tends to become larger.

If you or the patient can easily return the contents of the hernia to the abdomen, it is reducible, and you can arrange repair at the patient's convenience. A reducible hernia expands on coughing; any bowel in it may gurgle as you reduce it, and if it contains omentum, it feels doughy. A hernia may be congenital (existing at birth) or acquired (through increased intra-abdominal pressure from pregnancy, ascites or massive tumour, heavy lifting, coughing, straining to pass urine, or constipation)

There may be several consequences:

(1) **Irreducibility.** Coughing or straining may push omentum, or a loop of bowel, through the neck of the sac, after which oedema may prevent spontaneous reduction. This is more likely the *smaller* the hernia defect. Sometimes, you may find the hernia reduces spontaneously with sedation. Occasionally you may be able to effect reduction manually (taxis, 18.6). *This is dangerous if you use force.*

(2) **Obstruction.** A hernia is one of the commonest causes of intestinal obstruction (12.2, 12.3). Again this is more likely the *smaller* the hernia orifice is. Bowel outside the hernia can rarely also twist and obstruct (12.8, 12.9)

(3) **Strangulation.** Blood may be able to enter but not leave the organs in a hernia, so that they swell. This is more likely to happen in a hernia with a narrow neck, *i.e.* femoral, or inguinal. If the swelling persists for >6hrs, the arterial blood supply is cut off and the organs in a hernial sac become ischaemic (strangulated, 18-2A).

If this happens to the omentum or Fallopian tube, the risk is small. But if the bowel becomes gangrenous, peritonitis and septicaemia at worst, or a fistula and cellulitis at best, will follow. If more than a little of the bowel strangulates, it cannot propel its contents onwards normally, so it obstructs. Most strangulated bowel is therefore obstructed also (18.6). Important exceptions are Richter's, (18-2B), Littré's (18.3), Amyand's, and de Garengeot's (18.7) hernias.

N.B. Incarceration. This is an imprecise term. When a hernia strangulates, it suddenly becomes painful, tense, and tender, and loses its cough impulse. Even so, you will often find it difficult to know if a hernia is merely irreducible and obstructed, or whether it is strangulated, because pain and constipation are present in both.

Pain usually remains colicky until ileus and peritonitis develop, so the change from colicky to continuous pain is a bad sign. Occasionally, a strangulated hernia causes so little pain that a patient does not call your attention to it. Usually, however, the pain, the general condition, and the signs at the hernial site are reliable indicators.

Unfortunately, you have no way clinically of being certain what has been caught in a hernial sac, and neither can you be sure clinically that whatever has been caught has not strangulated. Obstruction is ultimately as dangerous as strangulation, because, if you leave it, strangulation usually follows. So, *be safe, and treat all painful, tense hernias as if they were strangulated.*

If only the omentum strangulates, there is localized abdominal pain, but the attacks of general abdominal pain and vomiting may stop, with subsequent normal bowel action. Gangrene is delayed, but after days or weeks the necrotic omentum may become infected, so that a local abscess or general peritonitis follows.

Common sites of abdominal wall hernia are: inguinal (18.2), femoral (18.7), umbilical (18.10), para-umbilical (18.11), and epigastric (18.12). Rarer sites are lumbar, Spigelian (lateral ventral, through a defect in the *transversus* aponeurosis and *internal oblique* muscles), obturator, perineal or gluteal. Any abdominal wall incision can result in an incisional hernia, but the commonest is the lower midline abdominal incision.

There are some rarer, but important, types of inguinal hernia:

If only part of the wall of the bowel is involved, this is a *Richter's* hernia (18-2B). This is particularly dangerous because:

(1) the bowel may strangulate without being obstructed, so vomiting may be absent and bowel action normal. Instead, there may be diarrhoea until finally peritonitis develops.

(2) the local signs of strangulation may not be obvious.

If the peritoneal lining of the hernial sac is incomplete, and an abdominal organ (laterally, the caecum on the right, and sigmoid colon on the left, or the bladder medially), forms part of its wall, this is a *sliding* hernia (18-2C,D).

If two loops of bowel herniate, the central segment between the 2 loops *within* the abdomen may strangulate. This is a Maydl (or W-shaped) hernia.

If the caecum and terminal ileum herniate, because the caecum is more mobile than normal, a loop of ileum may prolapse through a hiatus below the lateral paracolic peritoneum thereby created. This causes strangulation of the proximal bowel *inside* the abdomen. This is Philip's hernia.

Apply the principles of hernia repair:

- (1) define the sac, separating it from adjacent tissues,
- (2) open the sac (herniotomy),
- (3) examine the sac contents and deal with them as appropriate,
- (4) excise the sac, or close it,
- (5) reduce the hernia,
- (6) repair the defect (herniorrhaphy), restoring the anatomy as best as possible.

N.B. This part is not necessary in children (18.5).

You can perform the herniorrhaphy in several ways but we recommend making a darn closing the gap between the conjoint tendon (which is formed by the fibres of the *internal oblique* and *transversus*) and the inguinal ligament behind the cord.

This is a *tension-free* modification of the Bassini repair. Having done this, you then suture the external oblique aponeurosis in front of the cord. This is an alternative to what is now the standard in the developed world, the Lichtenstein repair, where a mesh is sewn in to strengthen the defect. The other 'definitive' operation, *the Shouldice repair*, is difficult to do correctly and is not recommended. The Lichtenstein method introduces a foreign material which is very hard to remove if it becomes infected. Fixing the mesh may cause a chronic neuroma, which is very painful. So you should be wary of using a mesh: use it only in special circumstances (18-13).

SITES OF ABDOMINAL HERNIAS

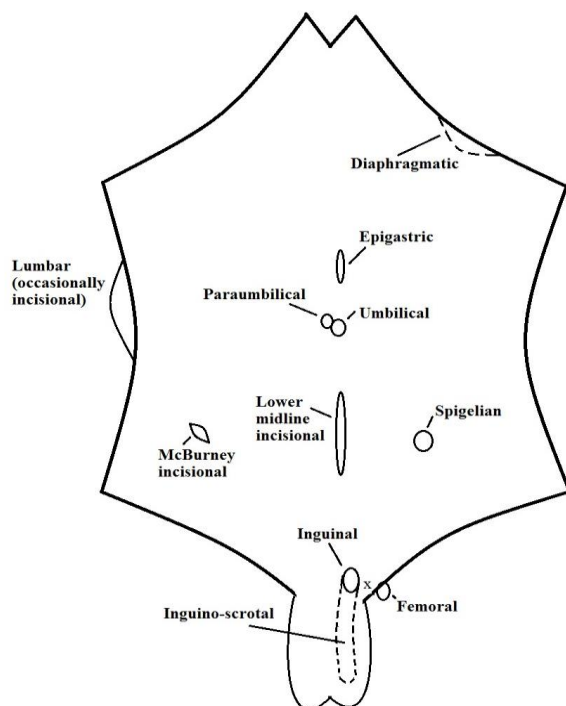


Fig. 18-1 SITES OF ABDOMINAL HERNIAS.
'x' marks the site of the left pubic tubercle.

Direct hernias represent a bulge in the posterior abdominal wall, and so there is rarely a hernia sac to dissect out. Their repair (herniorrhaphy) is usually simpler, unless they are very large. However, there may be problems:

- (1) The sac may have no obvious neck (unless it is a Busoga hernia, where there is a narrow defect), so that you do not excise it; instead, you tuck it in (18-10).
- (2) The weak area in a direct hernia is ill-defined, and tends to involve all or most of the posterior wall of the inguinal canal. Here a mesh is most useful: you can sterilize mosquito netting to give a perfectly acceptable alternative. You can strengthen this by suturing the external oblique aponeurosis behind the cord; *something you should never do with an indirect hernia*.
- (3) A patient with a direct hernia is likely to be older with poor tissues, and perhaps prostatism, a urethral stricture, dyspnoea, a cough, or constipation, all of which will stress the hernia repair.
- (4) The bladder may enter the hernia, and is easily injured.
- (5) A direct hernia is twice as likely to recur as an indirect one, especially if it is a sliding hernia.

The common mistakes are:

- (1) To forget to examine the hernial sites of anyone with an abdominal pain or vomiting, especially if the hernia lies under an apron of fat.
 - (2) To forget the possibility of a Richter's hernia (18-2), which may confuse the diagnosis by causing diarrhoea instead of constipation.
 - (3) To persist in using taxis (18.6) when a hernia should be operated on.
 - (4) To delay surgery, especially in children.
 - (5) To repair a hernia, especially a direct one, before dealing with the cough, asthma, constipation or poor urinary flow that have provoked it.
- N.B.* If you are experienced, and no suprapubic catheter has been used, you may be able to carry out a prostatectomy and hernia repair at the same operation.
- (6) Not to transfix the neck of the sac high enough, so as to obliterate it completely; *a simple ligature on its own may slip off*.
 - (7) To fail to make sure the groin is well cleaned pre-op.

You will have many inguinal hernias to repair, so let them provide you with an unhurried opportunity to increase your anatomical knowledge and your surgical skills. As you'll find you spend much time operating on hernias, it is worth teaching an assistant to learn this procedure.

TREAT ALL PAINFUL HERNIAS AS IF THEY ARE STRANGULATED

18.2 Inguinal hernia

Common are indirect inguinal hernias in which the abdominal viscera slip down the inguinal canal, from inside the internal (deep) inguinal ring, through the external (superficial) inguinal ring, and sometimes into the scrotum. The hernial sac is closely related to the spermatic cord, and lies in the same fascial planes.

SOME HERNIAS

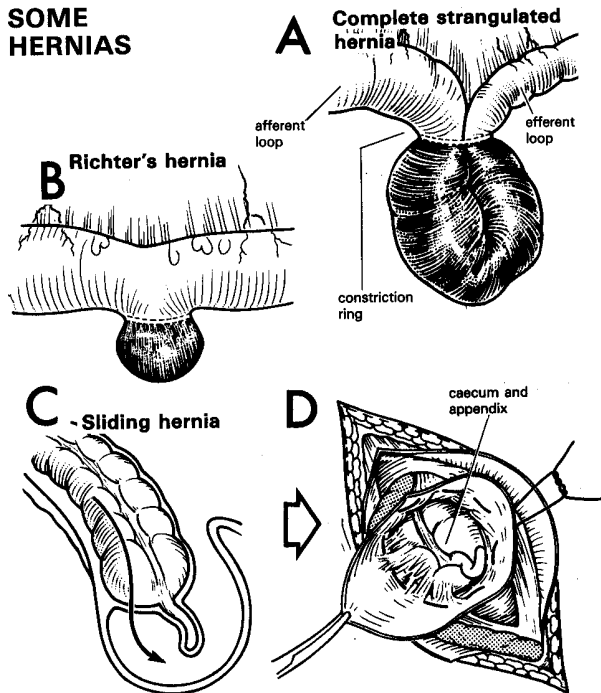


Fig. 18-2 PATHOLOGY OF SOME HERNIAS.
A, strangulated hernia. B, Richter's hernia. C, sliding hernia.
D, sliding hernia opened.

A few direct inguinal hernias bulge through a weakness in the posterior wall of the inguinal canal. They do not present through the internal ring, they lack any special relation to the cord, and they do not have the coverings from the cord that an indirect hernia has. Because of the way they arise, *the spermatic cord lies behind an indirect hernia, and in front of a direct one*, but differentiating between the two before operation is not easy and experts often get it wrong. Occasionally, a patient has a hernia of both kinds (18-12).

Indirect inguinal hernias are common in males. Women less often have indirect hernias, and seldom have direct ones. An indirect hernia presents a bulge in the groin, sometimes with a dragging feeling. It often extends into the scrotum. The patient may say that he felt something 'give' in the groin during lifting or coughing, just before the hernia appeared. Often the hernia has been present since childhood (congenital). An operation, which will remove the risk of strangulation, and possibly death, is almost always indicated for an obvious hernia.

Do not advise wearing a truss (a hernia support). This is expensive and difficult to get; it is unlikely to be understood that the hernia must be completely reduced before application, and it is likely to be very uncomfortable in a hot climate. *It also doesn't guarantee keeping the hernia orifice closed.*

Direct inguinal hernias are of two kinds:

(1) Ordinary direct hernias, which seldom strangulate (18-13). They may cause no symptoms, and remain the same size for long periods, and so may not need surgery.

(2) A special variety of direct hernia in which the patient has a narrow defect in the conjoint tendon, or in the *transversalis fascia* (18-10). This is a Busoga (or Gill-Ogilvie) funicular type of hernia; it is not uncommon in certain areas (hence the name, Busoga, in Uganda) and may predominantly affect women. The neck of the sac is small, so bowel *readily strangulates* in this type of direct hernia; it often does so in only part of the circumference of the bowel, producing a Richter's type of hernia (18-2B).

Recurrence is a problem with any inguinal hernia, especially if the patient is old and has weak muscles. Preventing recurrence needs care and skill, but curing a hernia that has recurred needs even more skill. Recurrence is less likely if you:

- (1) Repair a hernia early, before it has grown too large.
- (2) Tie off the neck of the sac close to the inguinal ring. If you leave the neck or fail to define the sac all round, a hernia is much more likely to recur.
- (3) Narrow a dilated internal ring by bringing the edges of the *transversalis fascia* together (18-8A).
- (4) Look to see if there is a coexisting direct hernia when there is an indirect hernia, or vice versa.
- (5) Put the sutures in the repair through the aponeurosis of the internal oblique, rather than through its muscle.
- (6) *Do not pull the darn sutures too tight.*
- (7) Use non-absorbable sutures.
- (8) Deal with asthma, a cough, urinary flow difficulties, or constipation *before the repair*.
- (9) Control bleeding carefully because secondary infection is usually related to haemorrhage, and both will weaken your repair.
- (10) Avoid sepsis by thoroughly cleaning and shaving the skin pre-operatively.

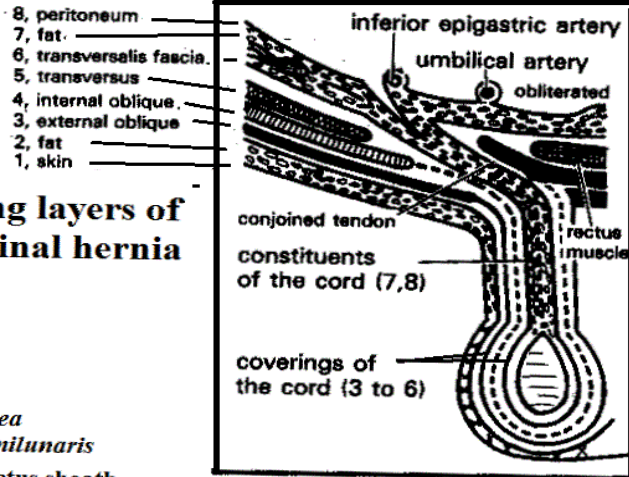
ANATOMY (18-3). The internal inguinal ring is a gap in the *transversalis fascia*, about a finger's breadth above the mid-inguinal point, midway between the anterior superior iliac spine and the pubic tubercle. The external (superficial) inguinal ring is an opening in the external oblique aponeurosis just above and lateral to the pubic spine. This aponeurosis forms the anterior wall of the inguinal canal: its posterior wall is formed by the *transversalis fascia*. As the spermatic cord passes down the inguinal canal, the muscle and tendon of the *internal oblique* and *transversus* arch over it, to form the conjoint tendon.

Divide the inguinal canal into thirds: in the lateral $\frac{1}{3}$, the *internal oblique* forms its lateral wall; in the central $\frac{1}{3}$ it forms its roof; in the medial $\frac{1}{3}$ (as part of the conjoint tendon), it forms its floor. A hernia deforms this normal anatomy, but you can always see that this was its original state. The inferior epigastric vessels leave the femoral artery and vein, and run longitudinally on the medial side of the internal inguinal ring. Direct hernias bulge medial to them, through the posterior wall of the inguinal canal, while indirect ones pass lateral to them through the internal ring. The inguinal ligament is attached to the antero-superior iliac spine laterally, and to the pubic tubercle medially. At its medial end a small curved ligament, called the *lacunar ligament*, joins it to the pubic bone. The lacunar ligament forms the medial boundary of the femoral canal. A few of its fibres continue laterally along the upper border of the pubic bone to form the *pectineal* (Cooper's) *ligament*. You can pass sutures through this when you repair a femoral hernia.

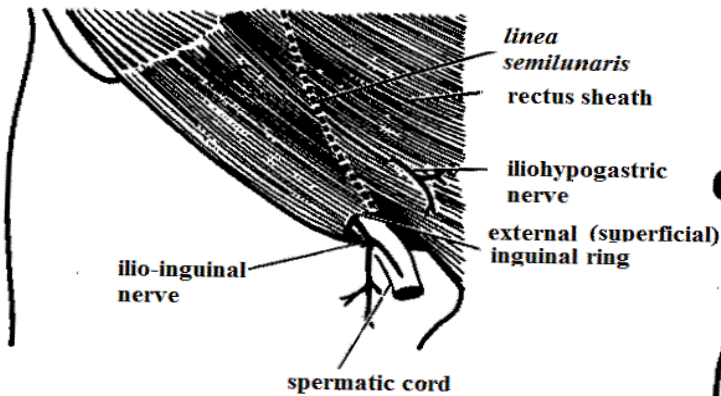
In an infant, the 2 inguinal rings overlie one another; in the adult they separate, although not always in some people. Inside the inguinal canal you will meet two very constant vessels, but you can easily control bleeding from them: they are the cremasteric artery, and the pubic branch of the inferior epigastric artery.

GROIN ANATOMY

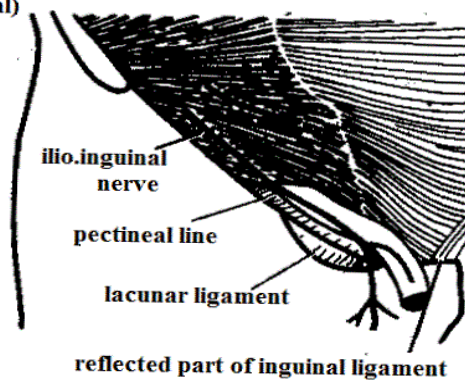
A Covering layers of an inguinal hernia



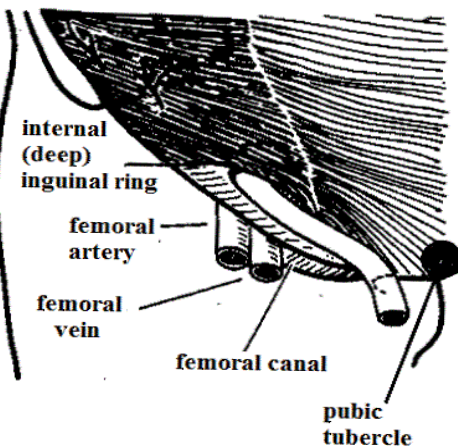
B External oblique



C Internal oblique



D Transversus abdominis



E Conjoint tendon

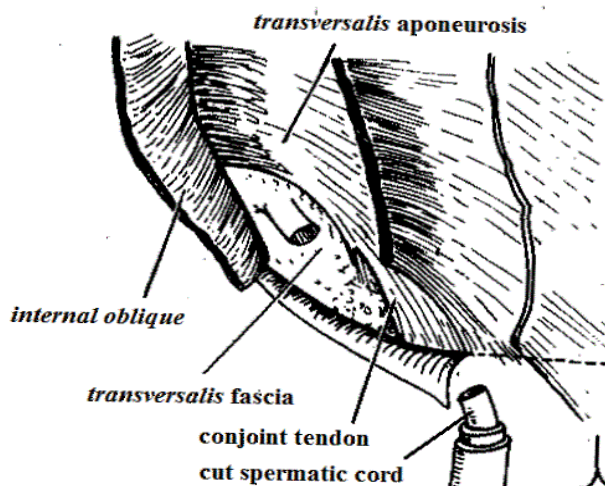


Fig. 18-3 SOME INGUINAL ANATOMY.

A, coverings of the spermatic cord, which also become the coverings of an inguinal hernia. The abdominal wall muscles are: B, *external oblique*; the *linea semilunaris* is the curved lateral tendinous edge of the *rectus abdominis*. C, *internal oblique*. D, *transversus abdominis*, lying deeper to the *internal oblique*. E, conjoint tendon, formed from the aponeurosis of the *internal oblique* and *transversus* as they arch over the spermatic cord; the *transversalis fascia* lies between the inner surface of *transversalis* and the parietal peritoneum.

After Basmajian JV, Grant's Method of Anatomy 9th ed 1975 p.183 Figs 217,219 with kind permission.

TRY TO TREAT ALL HERNIAS LIABLE TO OBSTRUCT WHILE THEY ARE STILL SMALL

UNCOMPLICATED INGUINAL HERNIAS IN ADULTS

DIAGNOSIS.

Ask the patient to stand, cough or strain to make the bulge appear. If it is already there, ask him to reduce it. Examine the patient lying down to see if it reduces easily, particularly with an audible gurgle. Does the hernia extend into the scrotum? Are both the testes present? Testicular atrophy is one of the complications of herniorrhaphy, and if one testis is already atrophic, you will have to be particularly careful. Take note of previous scars to see if it is a recurrent hernia.

If there is a history of a inguinal swelling that comes and goes, make a determined effort to demonstrate the hernia clinically.

If, however, it does not appear on standing, straining (i.e. a Valsalva manoeuvre) or coughing, do not operate. Review the situation later, and wait until you have actually seen or felt the hernia. It is worthwhile asking such patients to come for review in 3-6 months.

AN INDIRECT INGUINAL HERNIA

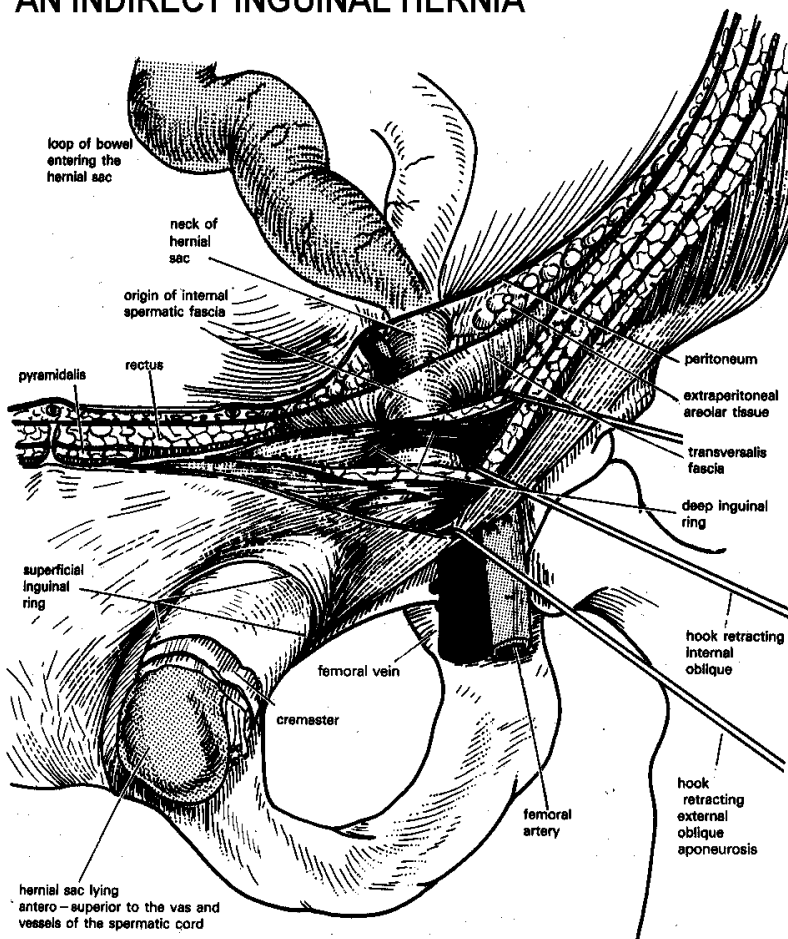


Fig. 18-4 INDIRECT INGUINAL HERNIA, showing the hernial sac passing through the internal and external rings, and lying antero-superiorly to the vessels of the cord. The narrow part is the neck and the distal part is the fundus. The sac takes a covering from each layer of the abdominal wall. Adapted from a drawing by Frank Netter, with the kind permission of CIBA-GEIGY Ltd, Basle Switzerland.

DIFFERENTIAL DIAGNOSIS

Suggesting a hydrocoele (27.24): a swelling with no cough impulse. If, with your finger and thumb squeezing on the spermatic cord, you can get above the swelling, no matter how large it is, it cannot be an inguinal hernia, because it cannot have come down through the external inguinal ring.

Suggesting a femoral hernia (18.7): the bulge is more globular, is below the inguinal ligament, and is just medial to the femoral vessels, whereas the inguinal hernia is above and lateral.

Suggesting inguinal lymphadenopathy: the swelling is constant, and below the inguinal ligament. (Femoral lymphadenitis may appear like a strangulated femoral hernia, but there will be no signs of obstruction).

Suggesting filariasis: a thickened oedematous spermatic cord, with no cough impulse (34.14).

Suggesting torsion of the testis, epididymis, or both (27.25): there is a tender *scrotal* swelling which you can get above.

Suggesting a varicocele: a soft swelling feeling like a 'bag of worms' in the spermatic cord, which fills from below, unlike the hernia which fills from above.

BILATERAL ADENOLYMPHOCOELES

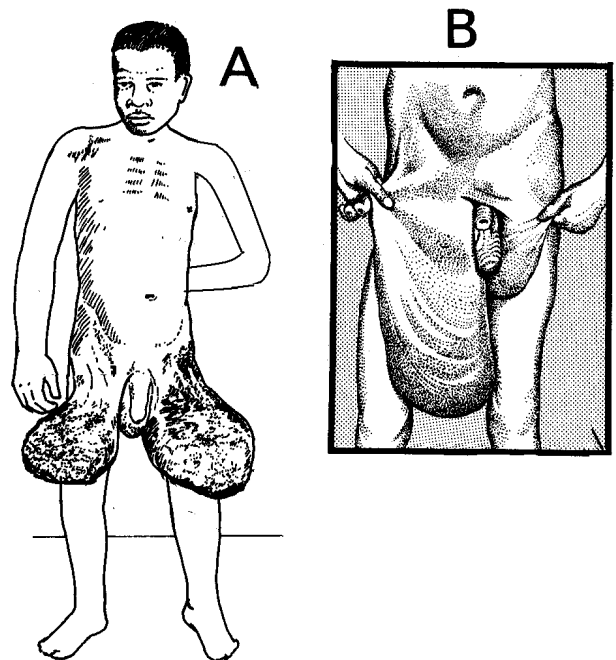


Fig. 18-5 ADENOLYMPHOCOELES or 'hanging groins' can occur in severe *onchocerciasis* or *schistosomiasis*. Do not confuse them with inguinal hernias. A, enormous swellings of similar sizes in an Ugandan patient. B, bilateral adenolymphocoeles of unequal size. Kindly submitted by Dr KT Cherry.

Suggesting an adenolymphocoele: this is a mass of oedematous fibrous tissue which hangs from the groin (usually bilateral) and arises from enlarged inguinal nodes as the result of progressive lymphatic obstruction. Where *onchocerciasis* (34.8) or *schistosomiasis* are endemic, expect to see these. Look for *microfilariae* or *schistosoma* eggs in skin snips. Treat the disease medically before you operate. Although adenolymphocoeles are easy to remove, the wound heals badly because so many lymph vessels are severed.

MANAGEMENT

INDIRECT INGUINAL HERNIAS IN ADULTS: HERNIORRHAPHY (GRADE 2.4)

An indirect hernia can only be treated effectively by surgery, but if it is small, easily reducible and not painful, and the patient is very old and frail, or has advanced HIV disease or malignancy, the risks may outweigh the advantages. You can use LA, however, so poor general condition is not an absolute barrier to operation.

In a teenager, or young adult with a small indirect hernia and good tissues, and minimal symptoms, do not interfere. If it does produce pain, all you need do is excise the sac and narrow the internal ring as it is usually a neglected congenital hernia. If it is large, repair the defect with a darn.

For bilateral hernias, discuss whether the patient wants both operated at the same time; recovery will be slower and the risk of urinary retention greater.

PREPARATION

Treat a cough, asthma, constipation or a urinary flow problem first. Persuade a smoker to stop; if the operation is elective, wait 3 months, and review the situation. Make sure the groin is washed and shaved. *Always mark the side to be operated upon beforehand.* Prepare the skin from umbilicus to mid-thigh, including the genitalia. If you are unsure of the anatomy, mark a line from the antero-superior iliac spine and the pubic tubercle with a marking pen: this is the line of the inguinal ligament.

LOCAL ANAESTHESIA FOR INGUINAL HERNIAS

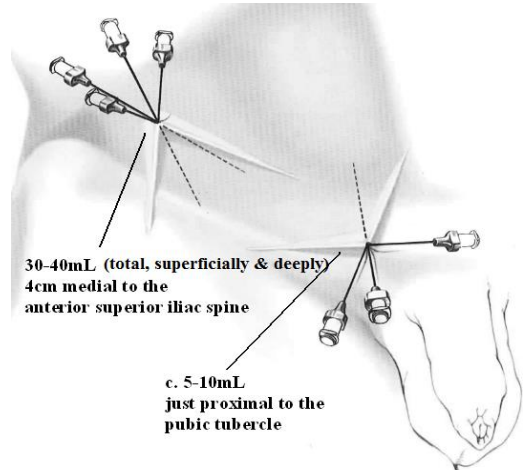


Fig.18-6 SITES OF INJECTION of LA for inguinal hernia repair.
After Eriksson E (ed). *Illustrated Handbook in Local Anaesthesia*,
Lloyd-Luke 2nd ed 1979 p.53 Fig 41.

ANAESTHESIA

(1) LA infiltration (18-6) is excellent for ordinary small and medium hernias. It will show up the tissue planes beautifully. It is also useful if the patient is old and feeble. *It is not satisfactory if the hernia is strangulated. Do not use it in children, or if the patient is tense and anxious.* Remember that pulling on the spermatic cord or peritoneal sac will still be painful!

(2) Epidural or subarachnoid (spinal) anaesthesia is excellent for all sizes of hernia, because relaxation is so good.

(3) Ketamine with relaxants or GA, preferably with relaxants.

INCISION

Make the incision 2cm parallel and above the inguinal ligament, from just lateral to the mid-inguinal point to just medial to the pubic tubercle. For small hernias it can be a little shorter, and for large ones a little longer (18-7A).

Find and tie securely or diathermy the superficial epigastric and superficial external pudendal vessels. If they bleed later, a postoperative haematoma results.

Apply straight haemostats to all bleeding points, and secure haemostasis. Cut through the two layers of the superficial fascia down to the shining fibres of the *external oblique* aponeurosis (18-7B).

Clear the upper skin flap from the underlying aponeurosis by swab dissection, to expose a wide area of aponeurosis above the internal ring.

Free the lower flap in a similar way to display the inguinal ligament, and its attachment to the pubic spine. Display the external ring, and identify the line of the inguinal canal. Insert a self-retaining retractor to separate the skin edges.

A. OPEN THE INGUINAL CANAL

Make a short split incision in the aponeurosis of the *external oblique* in the length of its fibres over the inguinal canal, and extend it with a half-closed blade of scissors laterally and medially opening up the external ring. Free the upper edge of the *external oblique* aponeurosis, including its extension as the *cremaster* muscle, from the underlying *internal oblique*, as far as the outer border of the rectus sheath.

Clip the upper and lower borders of the *external oblique* aponeurosis with straight haemostats. If you do this, you will not mistake them later for the curved haemostats you have used to control bleeding.

Lift each flap of aponeurosis and use gauze or sharp dissection to free it as far as the inguinal ligament inferiorly, which is the lower border of this aponeurosis. You will now see the *internal oblique* muscle, leading medially to the conjoint tendon. Re-apply the self-retraining retractor to separate the edges of the aponeurosis.

Look for the ilio-hypogastric nerve, and, a little below it, for the ilio-inguinal nerve on the surface of the *cremaster*, in front of and slightly below the spermatic cord.

SIMPLE HERNIOTOMY

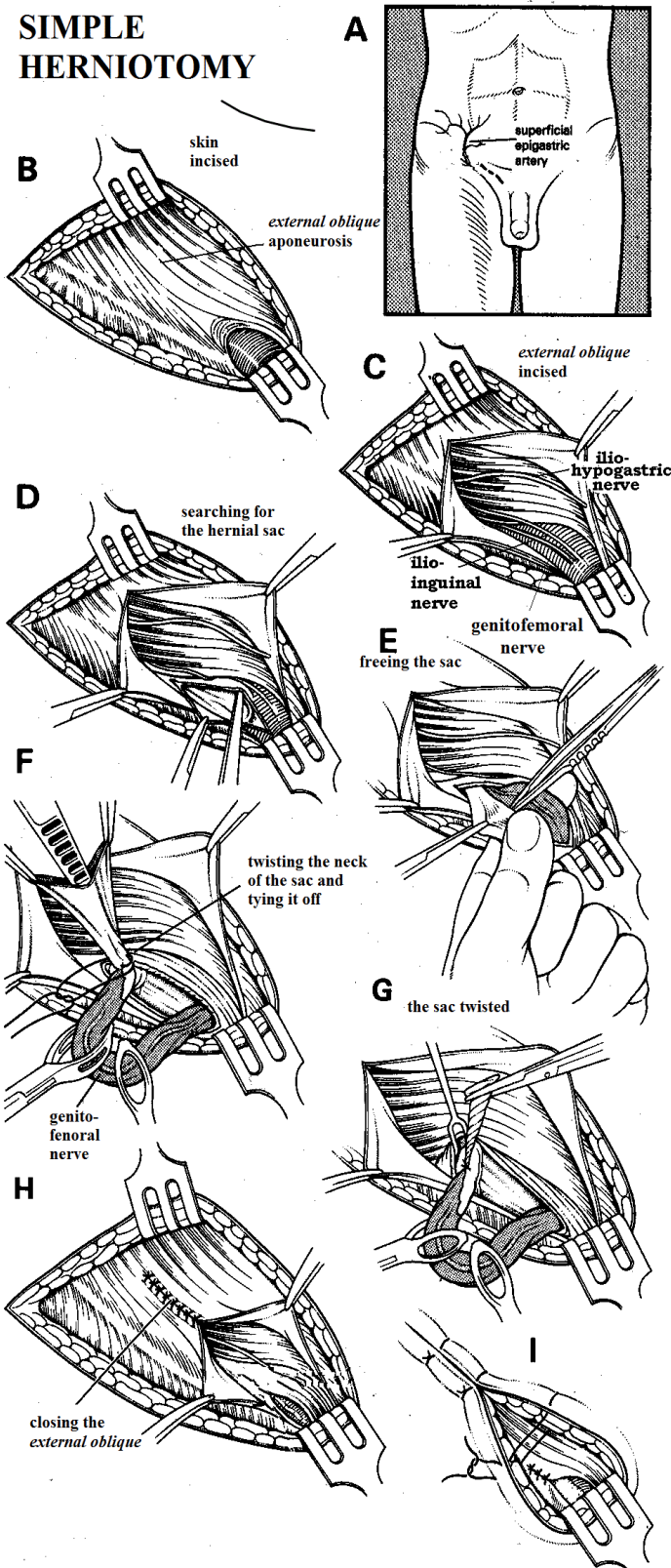


Fig. 18-7 SIMPLE HERNIOTOMY.

A, site of the incision. B, incise the skin and expose the *external oblique* aponeurosis. C, open the *external oblique* aponeurosis, from the external ring laterally, to expose the *internal oblique* with the *ilio-hypogastric* and *ilio-inguinal* nerves. D, open the spermatic cord to search for the sac. E, free the sac. F, open the hernia sac. G, tie the sac off and remove the excess. (If a repair is needed, it would be done at this point). H, close the *external oblique* aponeurosis. I, operation complete.

After Maingot R, *Abdominal Operations*, HK Lewis 4th ed 1961 p.874, 876, Figs 1,3 with kind permission.

Mobilize the *ilio-inguinal* nerve, and retract it behind the haemostat on the lower flap. Try not to crush or overstretch either of these nerves, or include them in a suture, because this may cause persistent postoperative pain. Pick up the cord where it crosses the pubic tubercle and gently free it posteriorly, dissect it out enough to put a sling or rubber catheter round it (kinder than the forceps shown in the figure, 18-7F), and retract it. With your left thumb in front and index finger behind, try to stretch the cord and identify the sac. This might be readily visible, but usually needs you to split the fascial layers of the cord to see the curved white edge of the sac. You will see this lying close to and in front of the spermatic cord, which contains the vas and the spermatic vessels.

CAUTION!

Do not try blunt dissection near the ring where landmarks are hard to distinguish, especially if there is much extraperitoneal fat.

At this point if you identify the vas and vessels, but no sac, examine the posterior wall of the inguinal canal for signs of a direct hernia. Examine also the conjoint tendon, where the *Busoga* type of direct hernia occurs. Look also for a femoral hernia (18.7).

If you have difficulty outlining a hernial sac, open it and insert the index finger of your left hand. Use this to help you define the rest of the sac for further dissection.

B. FIND AND FREE THE SAC.

If you are using local or spinal anaesthesia, ask the patient to cough. The sac will swell slightly. It may be easy to find, or difficult if fibrous tissue has formed round it. Catch an edge with forceps, and retract it upwards and outwards (18-7E).

Dissect the sac carefully, hold it with a haemostat, and keep close to its edge. Hold it at extra places as necessary. Usually, sharp dissection with scissors is better than using gauze, unless the tissues are very loose, because there will be less oozing. Free the sac from strands of the *cremaster* at their origin from the *internal oblique*. Separate it from the cord with non-toothed forceps by working transversely to its long axis, using a combination of scissors and gauze-on-finger dissection. If there is extraperitoneal fat round the sac, and it obscures your view, remove it.

CAUTION! Be sure to find and define clearly:

- (1) the vas,
- (2) the spermatic artery, and veins (usually 2-3).

N.B. You may accidentally divide all these during dissection. Avoid this by keeping close to the sac.

If the sac descends into the scrotum, open the sac and make sure your finger enters the peritoneal cavity easily through it. Then holding the proximal part of the sac, divide it (but not the cord!) and drop the distal part of the sac back into the scrotum. (Leaving it open prevents formation of a hydrocele.) Finally continue to dissect out the proximal part.

Dissect the sac free from connective tissue right down to its neck. You may see the inferior epigastric vessels running medial to its neck. Avoid them. If necessary, tie or diathermy any small branches. You will know that you have dissected as far as you should when you find:

- (1) the deep epigastric artery and veins on its medial side.
- (2) the constriction that forms its neck.
- (3) a collar of extraperitoneal fat around it.
- (4) its wider junction with the peritoneal cavity, visible when you pull it up.

TWO DETAILS OF HERNIA REPAIR

Narrowing the internal ring

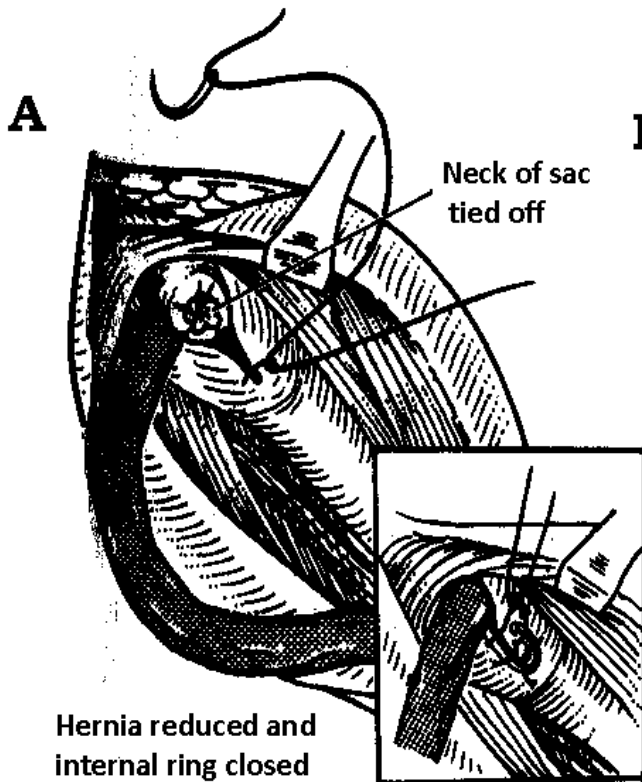


Fig. 18-8 TWO DETAILS OF HERNIA REPAIR.

A, narrowing the internal ring. In an adult a normal internal ring just admits the tip of your little finger. If it is larger than this, narrow it. Start medially and work laterally. B, bladder occasionally bulges forwards extraperitoneally on the inner side of a direct hernia, and you can easily injure it.

After Rob C. Smith R. *Operative Surgery*. Butterworth 2nd ed 1969 Vol 4 Part 1 p.223 Fig 8, p.229 Fig 25 with kind permission.

C. OPEN THE SAC.

Open its fundus (if you have not already done so) between haemostats, as if you were opening the peritoneal cavity. The sac has a moist shiny inside surface. Examine the neck of the sac (18-7F) and look through it into the peritoneal cavity to make sure the sac is empty, and no bowel or omentum remains inside. *Make sure no adhesions remain of omentum onto the sac.*

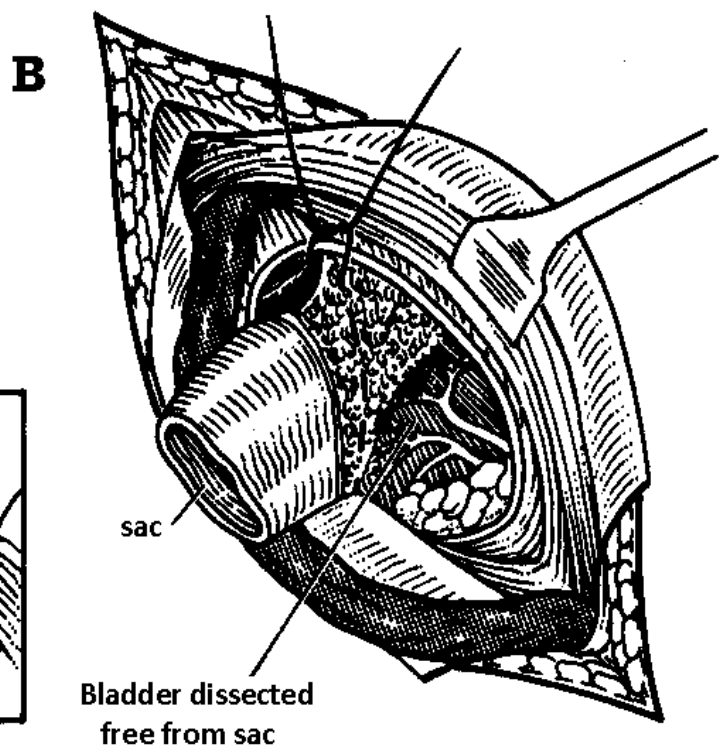
If the hernia is irreducible, beware: you can very easily open bowel as you open the sac!

If one side of the neck is thick, there may be bladder or bowel in its wall. This is more likely in a sliding hernia, either direct or indirect.

D. CLOSE THE SAC.

Twist its neck until the turns reach the internal ring (18-7G). If there is any bowel or omentum in the sac, this will force it back into the peritoneal cavity. Transfix the neck as far proximally as you can with absorbable suture and encircle the neck of the sac, tying it with a triple throw. Leave the ends of the knot long, and hold them with haemostats.

Dissecting the bladder off a direct hernia sac



If the neck of the sac is wide, place haemostats round it from outside, divide it distally, and close it with a continuous suture, as if you were closing the peritoneum of an abdominal wound.

Divide the stump 1cm distal to the ligature. Examine it. When you are sure that the ligature is not going to slip, or ooze, cut its threads. If it is loose, apply another ligature or a continuous suture. When you release the stump, it will quickly disappear from view under the arched fibres of the *internal oblique*.

CAUTION!

- (1) *Do not tie the sac distal to the internal ring* as the hernia is more likely to recur.
- (2) *Do not include the vas in your ligature.*
- (3) Leave the distal end open, if you need to divide the sac, or else a hydrocoele may result.
- (4) Avoid damaging small vessels; good haemostasis is essential to prevent a haematoma.

E. NARROW THE INTERNAL RING.

Feel the size of the internal ring. In an adult, a normal internal ring should not admit your index finger. If it is wider than this, it is dilated. If it is only a little dilated, narrowing it will be enough, as it is in children.

If the internal ring is only moderately dilated, suture it with monofilament nylon, starting medially, and suturing laterally, until the ring fits snugly around the cord *but does not strangle it* (18-8). Tie the inner and outer ends of the suture together to prevent the inner end of the suture line pouching forwards.

CAUTION!

- (1) *Do not leave the internal ring too wide*, or the hernia will be likely to recur.
- (2) *Do not constrict the internal ring too much*, or the testis may atrophy.

With experience you may narrow the internal ring as part of your repair, as described below.

In a female, an inguinal hernia is probably caused by a congenital sac which is firmly stuck to the round ligament. This is narrower and less vascular than the spermatic cord. The inguinal canal is smaller and you will hardly see anything to represent the *cremaster*. The hernial sac can extend only to the *labia majora*. Proceed as above, dissecting the sac from the round ligament. Use sharp dissection to free this, the sac and the vessels from the labium, or blunt dissection if the tissues are very loose.

Clamp, tie, and divide the round ligament close to its insertion. Then clean it and the sac as far as the internal ring. Open the sac, inspect its inside, and then probe it to make sure it is empty. Grasp the sac, the round ligament and their vessels.

Transfix, and tie them, leaving the ends of the ligature long. Then divide these tissues 1cm beyond the ligature.

Fig. 18-9 MOLONEY NYLON DARN REPAIR. Use #1 monofilament to make the darn. The first suture goes through the periosteum of the pubic tubercle.

After Maingot R Abdominal Operations, 4th ed 1961 p.879 Fig. 4 drawing 1. HK Lewis, with kind permission; Kirk, RN, Williamson, RCN General Surgical Operations, Churchill Livingstone 2nd ed 1987 p.29 Fig 3.2

N.B. The Desarda technique is another tension-free method: here you take an undetached strip of the *external oblique* aponeurosis from its normal anterior position to bolster the posterior wall by suturing it to the inguinal ligament.

Use the long ends of the ligature to anchor the stump to the aponeurosis of the external ring above and lateral to the internal ring.

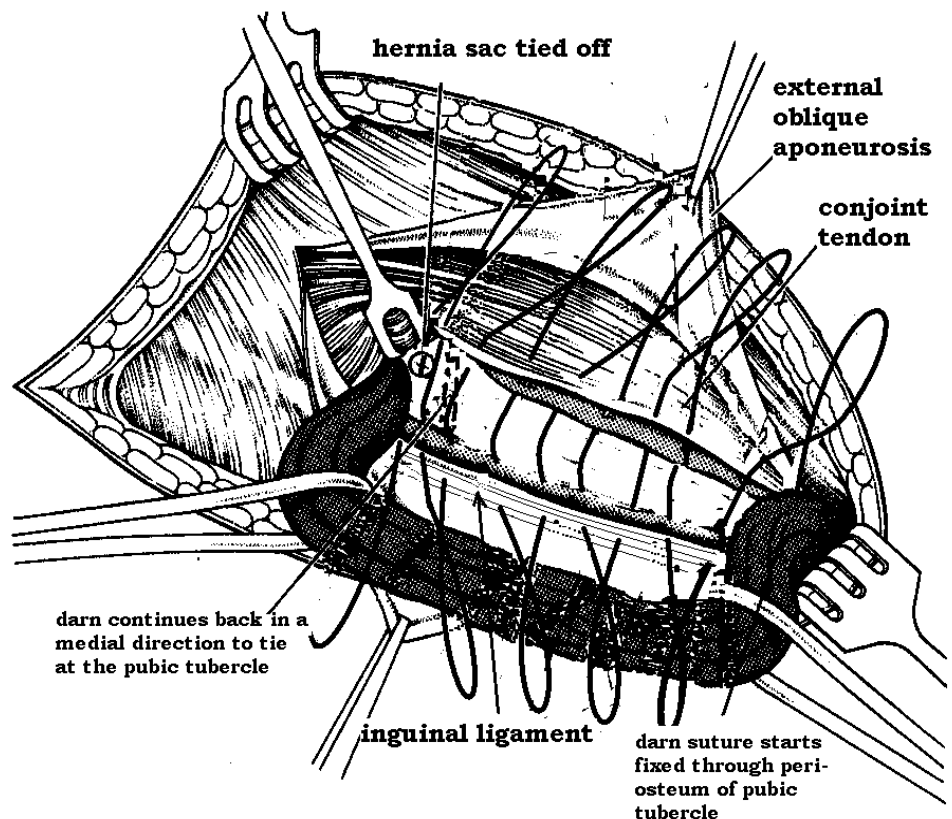
Obliterate the now empty inguinal canal with a few sutures joining the conjoint tendon and the *transversalis* fascia to the inguinal ligament. This is the so-called standard Bassini repair; *it is satisfactory only if there is no tension on the suture line*. Close the internal inguinal ring completely.

There is nothing to strangulate. If the muscles are weak, draw the upper edge of the external oblique aponeurosis toward the inguinal ligament with a darn: this is a modified Halsted repair.

F. REPAIR. Our recommended technique for the male is the Moloney nylon darn repair (18-9), which has been shown to be equivalent in strength and durability to the Lichtenstein mesh repair.

After you have completed the herniotomy, release the straight haemostat that you originally inserted on the lower flap of the *external oblique*, and replace it with the self-retaining retractor so that the cord lies behind the aponeurosis while you repair the posterior wall of the inguinal canal. This will keep the cord out of the way while you proceed with the repair. Alternatively, hold the cord with gentle traction using slings (18-9) or Babcock forceps, or *within* Lane's forceps.

NYLON DARN



Clean away all the areolar tissue from the upper surface of the inguinal ligament. Retract the fleshy arching internal oblique muscle upwards, and expose the aponeurotic part of the *transversus* and *internal oblique* muscles which form the conjoint tendon. Use this tendinous layer for reconstruction, not the overlying muscle layer, unless the aponeurosis is poorly developed.

Use 1/0 monofilament, or steel, on a round-bodied half-circle needle (*avoid a cutting needle as this is one of the most hazardous operations in terms of pricking yourself!*), to apply a continuous figure-of-8 loop (herring-bone) suture 8mm apart from the arching fibres of the conjoint tendon above, to the inner shelving margin of the inguinal ligament below (18-9). *Do not pull these structures tight: think of the darn as a patch to repair the defect.* Put a narrow retractor at the medial end of the wound, and take the first bite through the periosteum over the pubic tubercle and leave this end long. Proceed from the medial side laterally taking substantial (6-8mm) bites of the aponeurosis.

To avoid splitting the inguinal ligament, take bites which are alternately large and small. Space the sutures evenly, and *do not go too deep*, or you may puncture the underlying femoral vessels. When you reach the internal ring, return medially in the same fashion making a continuous figure-of-8 loop to finish and tie on the pubic tubercle.

CAUTION!

- (1) *Beware of the femoral artery and vein*, which lie just behind the inguinal ligament under the mid-inguinal point. Injuring the femoral vessels is the most serious potential complication of hernia surgery.
- (2) *Do not strangulate the cord with your most lateral suture.* Make sure you can still insert the tip of your forceps through the internal ring, alongside the emerging cord.
- (3) Use non-absorbable sutures only. *Do not use silk*; if it becomes infected, it will cause sinuses, and you will later have to pick out every piece.

ORDINARY DIRECT HERNIAS.

In a direct hernia, the posterior wall of the inguinal canal is weak and flabby and provides little resistance to your fingers as you press. There is usually an obvious bulge medial to the epigastric vessels. The cord almost always lies anterior to it.

If its medial wall feels thick and fleshy, suspect that there is bladder in it and there is a sliding hernia present. There is almost never a danger of strangulation, in contrast to the Busoga hernia.

Do not try to open, tie, or excise the sac of a direct hernia, unless it is of the funicular type. Push it inwards with a sponge dissector, and while you keep it pushed in, make a darn as before.

It may help to bring the layers of the *external oblique* aponeurosis together behind the cord (an anterior transposition of the cord), to strengthen the inguinal region. This is a modified Halsted repair. If it is convenient, overlap the flaps, suture the upper one to the inguinal ligament, and bring the lower one on top of it so as to overlap it about 2cm.

CAUTION! *Make quite sure that the unusual double (Saddle or Pantaloon) hernia, a COMBINATION OF A DIRECT AND INDIRECT HERNIA (18-12), is not present.* A few minutes looking for an indirect sac is time well spent!

BUSOGA (GILL-OGILVIE) DIRECT HERNIA

This is an unusual, but important, variety of direct hernia, peculiarly found quite frequently in certain areas of Uganda (and elsewhere), predominantly in women. Its importance is that it is a type of direct hernia where the bowel may strangulate, like a Richter's hernia (18-2B, 18-11).

BUSOGA HERNIA: anatomical features

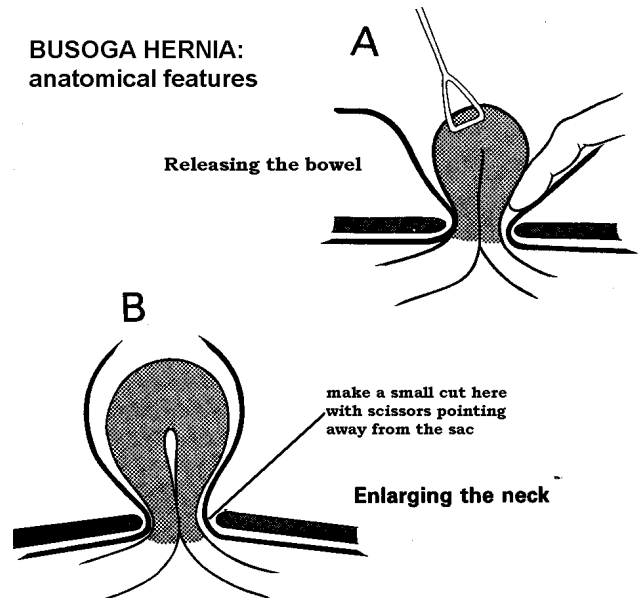


Fig. 18-10 BUSOGA (Gill-Ogilvie) HERNIA: Anatomical Features. A, release a strangulated Busoga hernia. As soon as the sac is opened, grasp a loop of trapped bowel gently with Babcock forceps. As you do so, gently but firmly stretch the neck of the sac with the tip of your little finger. B, sometimes you have to make a small cut in the fibrous edge of the ring. You can release a femoral hernia in much the same way. *Kindly contributed by Brian Hancock.*

You will see a tight bulge of bowel coming through the conjoint tendon medially (18-11) or *transversalis fascia* (18-12B). Hold the bulging bowel lightly with Babcock forceps to prevent it slipping back (18-10A). Cut the edge of the tight ring in the conjoint tendon with a half-open scissors cautiously (18-10B).

Dilate it with your finger alongside the sac. Open the sac. Withdraw the bowel and assess it by the criteria of viability (11-6).

BUSOGA HERNIA: operation

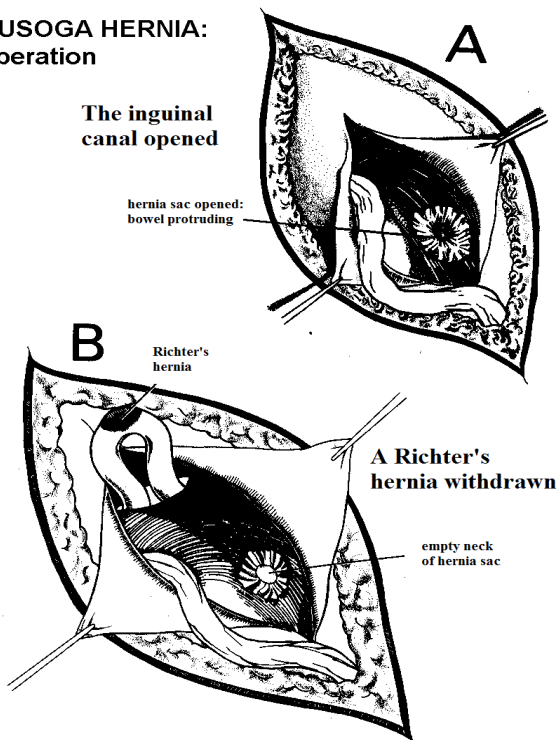


Fig. 18-11 BUSOGA HERNIA OPERATION

A, Open the inguinal canal to show a small defect in the conjoint tendon and a hernia bulging through it; open the sac. B, if the bowel slips back while you are operating, extend the incision in the *external oblique* laterally, then split the *internal oblique* and *transversus*, as in an appendicectomy (14.1). Withdraw the bowel. In this way you avoid enlarging the neck of the sac and weakening the conjoint tendon.
Kindly contributed by Brian Hancock.

If the bowel is viable, return it to the abdomen.

If the bowel is dubiously viable, leave it for 10mins covered with a warm, wet swab.

If the bowel is not viable, you will have to decide whether to invaginate or resect it:

Invaginate the necrotic area of bowel by using two layers of 2/0 or 3/0 absorbable to bring its healthy borders together in their transverse axis, so as to push the ischaemic segment safely inside the lumen, where it can safely necrose.

Do this *only* if it is:

- (1) A typical Richter-type strangulation which has produced a 'coin like' area of necrosis with a sharp margin.
- (2) The necrotic area has not yet perforated.
- (3) It does not extend over >50% of the circumference of the bowel.
- (4) It does not extend on to the mesenteric border of the bowel, because invaginating it may interfere with its blood supply.
- (5) The bowel at the edge of the necrotic area is healthy and pliable.

If any of these criteria are not fulfilled, resect the necrotic segment of bowel and perform an end-to-end anastomosis (11-7).

If you need to enlarge the defect to get better access to the bowel, extend the incision in the skin a little more laterally. Then split the *internal oblique* and *transversus abdominis* about 5cm above the internal ring, level with the iliac spine, exactly as in the standard approach for appendicectomy. Open the peritoneal cavity, and withdraw the bowel for inspection, invagination, or resection. Alternatively, perform a formal laparotomy through a midline incision. Finally, excise the sac, and close the *transversalis fascia* with a few monofilament sutures.

SLIDING HERNIAS (not uncommon).

If you find a boggy thickening in the wall of a hernia sac, suspect that some viscus has slid into it partly behind the peritoneum (18-2C,D). On the right the caecum and appendix can slide into an inguinal hernia on the lateral side. On the left the sigmoid colon can do the same (unusual). The bladder can do so on either side medially, more commonly in a direct hernia.

DIRECT & INDIRECT HERNIA IN THE SAME PATIENT

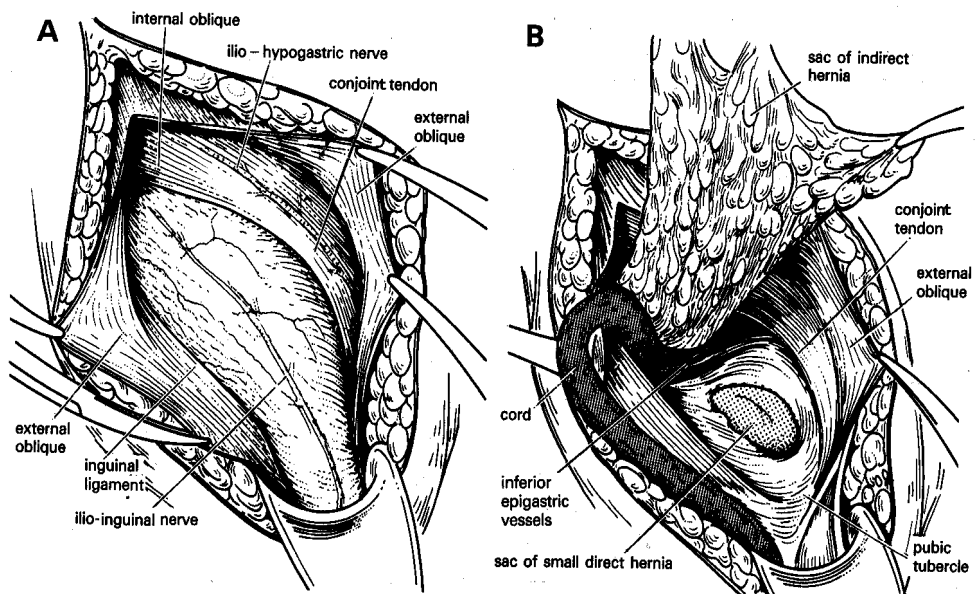


Fig. 18-12 DIRECT AND INDIRECT HERNIA in the same patient (Saddle or Pantaloon hernia). A, split the *external oblique* in the line of its fibres. Expose the cord with the ilio-inguinal nerve on its surface. Free the aponeurosis of the *external oblique*, medially to its fusion with the *internal oblique*, and laterally to the inguinal ligament. B, free the spermatic cord and retract it. Free the sac of a large indirect hernia, with some fat attached to it, from the cord up to the internal inguinal ring. Expose the pubic tubercle. (A small direct hernia protrudes through the *transversalis fascia*). N.B. Obesity may make dissection difficult! After Maingot R, *Abdominal Operations*, HK Lewis 4th ed 1961 p.889 Figs 15,16 with kind permission.

A LARGE DIRECT INGUINAL HERNIA

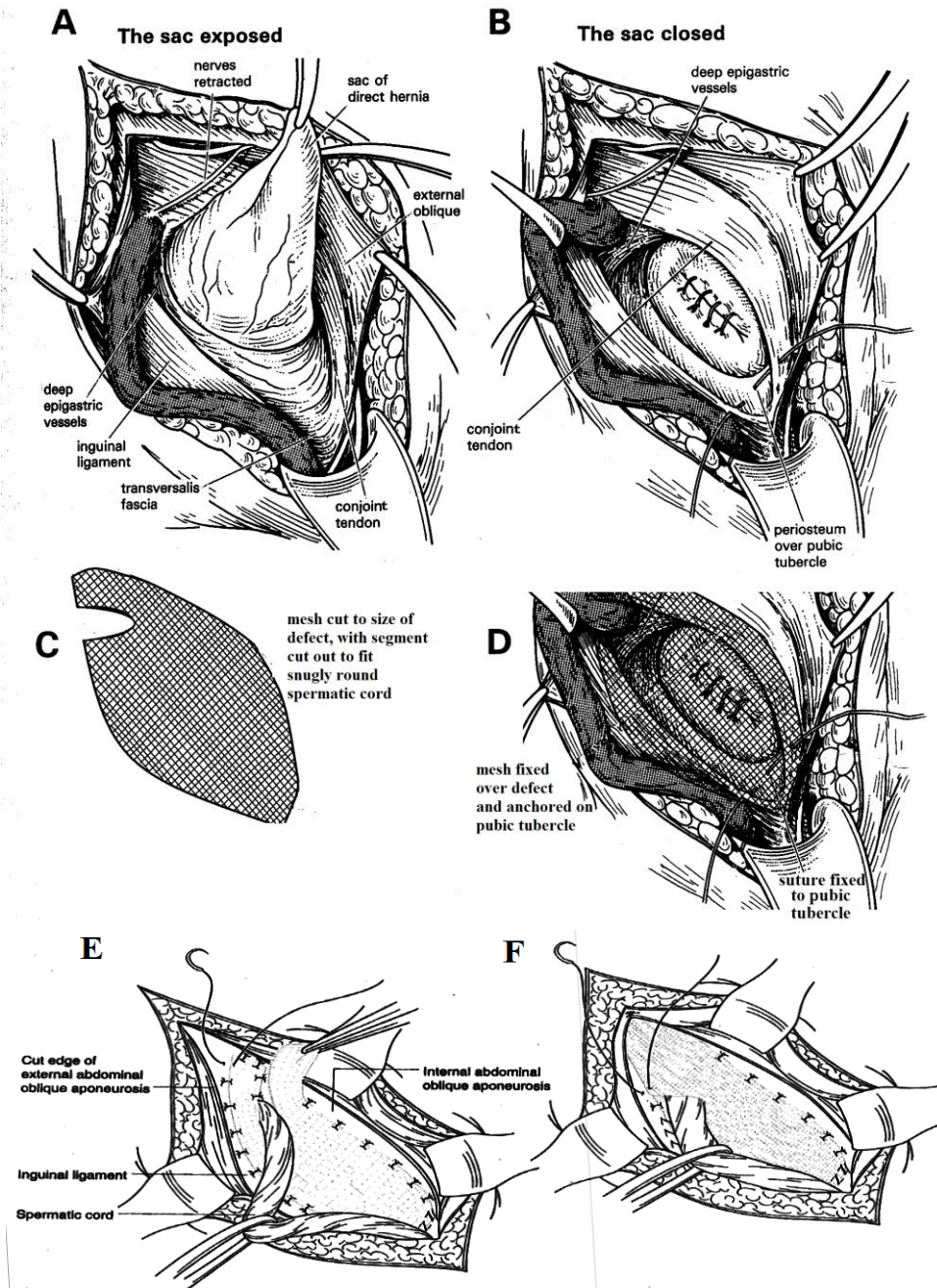


Fig. 18-13 REPAIRING A LARGE DIRECT HERNIA OF THE ORDINARY KIND. (For enormous or giant hernias, see 18.4)

A, large direct hernia protruding through most of the posterior wall of the inguinal canal. B, having reduced the hernia, close the orifice in the *transversalis* fascia. Insert the first suture in the conjoint tendon. C, cut the mesh to fit, with a defect for the spermatic cord. D, suture the mesh in place, anchoring it on the pubic tubercle. E, mesh sutured in place to the conjoint tendon and inguinal ligament. F, window around the spermatic cord closed snugly. After Maingot R, *Abdominal Operations*, HK Lewis 4th ed 1961 p.890 Figs 17-20 with kind permission.

CAUTION! If you cut through a thick part of the wall of the sac, you may enter the viscus.

You may feel something irreducible in the sac which you cannot return to the abdomen. When you open it you find that the internal margins of the sac are impossible to identify along one side, because there is some viscus in the way. Dealing with a hernia like this can be difficult.

Therefore *do not attempt to separate the sac from the viscus forming its wall*, and after you have reduced any other hernia contents, close the sac with continuous 0 absorbable sutures. Push the viscus with the stump of the sac into the abdominal cavity. Proceed with the herniorrhaphy.

VERY LARGE HERNIAS

If the hernia is extremely large, you will not get a satisfactory repair with the standard Nylon Darn (and certainly not with a Bassini repair). Insert a mesh: you can make one with ordinary autoclaved polyethylene mosquito netting (18-13C).

This has a breaking strength of c.150 Newton prior to autoclaving and c.350 after.

N.B. Do not use insecticide impregnated mosquito netting! (Permethrin used is neurotoxic and may be carcinogenic).

Suture the mesh carefully to the inguinal ligament and conjoint tendon (18-13E), leaving an opening you have cut out for the cord to pass through. Close this window with 2-3 non-absorbable sutures around the cord, placing the mesh neatly to make a snug fit.

If the tissues are very weak and stretched, you may be able to 'double-breast' the layers (fold the stretched ligaments on top of themselves) to increase their total strength: this is probably preferable to cutting away excess ligament.

Do not simply suture the mesh to *weak tissues*, because the herniation bulge will just be shifted to below (or above) the mesh.

RECURRENT HERNIAS (not uncommon)

If the recurrence is an indirect hernia, usually because of inadequate closure of the internal ring, or a direct hernia, insert a darn as before. Take time to make a neat dissection. If a non-absorbable material has been used previously, and there is only a local defect, close this and leave the sound parts undisturbed.

If the tissues are very weak, put in a mesh as for a large hernia.

If the recurrence is a direct hernia, check if the ligaments are of adequate strength, and attach a mesh to these structures.

CLOSING THE WOUND AFTER ANY INGUINAL HERNIA REPAIR. Now that you have narrowed the internal ring, and done a repair, you can replace the cord. Put it back in the inguinal canal, and make sure the testis rests well down in the scrotum. Use continuous absorbable suture to repair the *external oblique* in front of the cord (unless there is a direct hernia when you can use it to strengthen the repair behind the cord), starting from the lateral side and working medially. When you reach the external ring, reduce it to a size that will transmit the cord comfortably.

Repair the well-defined layer of superficial fascia with 2/0 continuous absorbable, and the skin with 2/0 subcuticular absorbable. Insert 5-10ml of long-acting local anaesthetic into the wound.

CAUTION! Postoperative bleeding is particularly likely to occur in the inguinoscrotal region. So control all bleeding vessels carefully. Any hernia repair can be spoilt by a haematoma, especially if it becomes infected. If haemostasis is not perfect, insert a Penrose drain.

POSTOPERATIVELY, mobilize the patient, start eating and walking the same day. Check if he is passing urine well. If he is bronchitic, treat him with chest physiotherapy. If he smokes, persuade him to stop. If he is a manual worker, he should avoid lifting weights >5kg or straining for 3 months, and if possible, give up heavy work. Treat him with a laxative if he has a tendency to constipation. You should advise him to avoid sexual intercourse for 3wks. There is no restriction on driving a car after 1wk unless the groin wound remains painful.

18.3 Difficulties with inguinal hernia

PRE-OPERATIVE DIFFICULTIES WITH INGUINAL HERNIAS

If there is a hydrocoele and a hernia, deal with the hernia as usual. Open the hydrocoele and leave its distal end open, evert the testis and replace it outside the *tunica vaginalis* (27.24).

If there is also an undescended testis, perform an orchidopexy (27.27) or orchidectomy if it is atrophic. **OPERATIVE DIFFICULTIES WITH INGUINAL HERNIAS**

If the testicle is twisted, perform an orchidopexy after untwisting it (27.25), or an orchidectomy if it is non-viable (27.26)

If you cannot find the sac, and you are operating under LA, ask the patient to cough. If that does not demonstrate the hernia, lift the cord and dissect it out carefully, using scissors to spread it proximally. Examine it carefully between your finger and thumb. Look for something like the finger of a glove, but made of tissue like amnion. That's the sac! If tissues are very scarred because of a previous hernia repair or frequent temporary irreducibility, dissect out the spermatic vessels and vas: the sac must be in the remaining tissues which you can safely tie off. If you still cannot find it, look for a direct hernia, or a femoral hernia (18.7, 18.8). If you still cannot find a sac, just narrow the internal ring. If the hernia recurs, next time, consider operating under spinal anaesthesia or GA.

SOME SCROTAL SWELLINGS

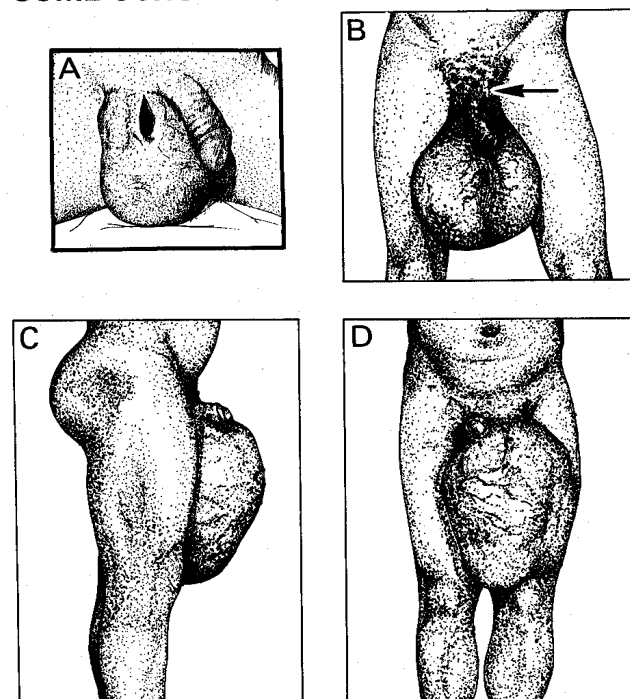


Fig. 18-14 SOME SCROTAL SWELLINGS.

A, if a strangulated hernia presents so late that the scrotum is oedematous, you may be justified in puncturing the mass to form a faecal fistula, as a temporary measure, as has been done here. B, bilateral giant hydrocoeles. If, with a finger and thumb you can get above a scrotal swelling, as you can here, as shown by the arrow, it cannot be a hernia. *N.B. transillumination does not work well with dark-skinned patients, and needs a dark room and strong light source!* C,D, giant indirect inguinoscrotal hernia. Repair will be more secure and recurrence less likely if the patient will allow you to divide the cord.

A-C, after Wosornu L. *External hernia – inguinal hernia. Tropical Doctor* 1973;3(4):165-170. D, after Bowesman C. *Surgery and Pathology in the Tropics*, Livingstone, 1960 with kind permission.

If the sac tears at its neck, so that there is no longer anything to twist and tie off, try to free the peritoneum from the abdomen to close the defect that exists. *If you don't do this, a recurrent hernia is inevitable.*

If the sac is large and reaches the scrotum, dissecting it out distally will be difficult. Dissect it out proximally as usual, and clamp and transfix its proximal end. Divide it and leave its distal end open. If you close its distal end, a hydrocoele may form. You may occasionally have to divide the cord (18.4) in an elderly man to obtain a secure repair. If the defect is very large, use a mesh to repair it as above.

If you have mistakenly passed your needle through a major vessel, continue and tie it tight. If bleeding continues and you think you have gone through the FEMORAL VEIN, remove the needle and press the bleeding area for 5mins until the puncture seals itself. If it does not, you have a major problem. Open the inguinal area about 2cm distal to the inguinal ligament and try to clamp the vein on both sides of the hole. If bleeding is controlled, try to close the hole with fine 4/0 or 5/0 monofilament set 1mm apart; otherwise use an aneurysm needle to encircle it with '0' silk, and tie it off. The leg will be oedematous postoperatively, but this is usually only temporary. *Do not tie the saphenous or profunda femoris veins*, because these will not control bleeding from the femoral vein.

If you think that you have injured the bladder, repair its mucosa, and its muscle with absorbable suture. Tuck it back and continue with the repair. Drain the wound and leave in an indwelling catheter for 2wks.

If you find an inflamed appendix in the hernial sac (Amyand's hernia), excise the appendix (14.1). Close the wound by delayed primary closure (11.8), because of the high risk of infection, and use prophylactic antibiotics as usual.

If the hernial sac contains pus or blood, which has drained from the peritoneal cavity, perform a laparotomy (11.2).

If a piece of bowel has a white ring on it, a (Garré) stricture may develop later at the site of the ring if you return it to the abdomen. So, if you can, resect this segment of bowel.

If a loop of bowel escapes into the peritoneal cavity, and you are not sure if it is viable or not, make a midline incision and examine it. This will be much safer than leaving it.

If you find a Meckel's diverticulum in the hernia sac (Littre's hernia), amputate the diverticulum and close the bowel with absorbable suture.

If the ovary & Fallopian tube appear in the sac (rare), untwist them. If they are viable, return them. If they are gangrenous, tie their pedicle and excise them.

POSTOPERATIVE DIFFICULTIES WITH INGUINAL HERNIAS

If a haematoma forms, you probably failed to tie the superficial vessels adequately, or used blunt dissection forcefully. Next time, prevent this by delicate technique and carefully controlling bleeding at every stage. Release blood from the haematoma by removing skin sutures, and ease the wound open with sinus forceps.

If the scrotum swells (common), you can reassure the patient that the swelling will probably only be transient, provided you have not tied off the lower end of the sac of an inguinoscrotal hernia. Swelling often follows the repair of such a hernia, and may be due to venous obstruction.

If the testicle swells (not uncommon after a difficult hernia repair), this is usually due to thrombosis of the spermatic veins. This usually settles and leaves a normal testis. Alternatively, it arises from infection relayed through the vas or blood stream. It is then worth using an antibiotic.

If the testis atrophies, you have probably interrupted the circulation in the spermatic artery by handling it roughly, or strangulated it with sutures at the internal ring. *You will not be able to revive the testis*, so remember the problem when operating the next time.

If urinary retention develops, insert a urinary catheter; remove the catheter when the patient is eating, walking, and pain free.

If deep infection in the inguinal canal persists, it may not resolve until the non-absorbable suture is removed: swallow your pride, reopen the wound and take out the darn, trying not to disrupt the natural fibrosis around it, and leave the wound open to granulate.

If you have used a mesh and infection persists, you may have to remove this to allow the infection to settle. This will prove to be a messy and difficult operation, so have some blood ready and take your time. The result will be a severe weakness in the inguinal area, which will need another mesh to repair it much later!

If a faecal fistula results, you have injured the bowel. This is a serious problem but if there is no obstruction, wait; it will probably close (11.15). Otherwise open the abdomen (11.2).

If symptoms of intestinal obstruction persist or peritonitis develops after you have reduced a hernia, you may have reduced it 'en masse': the hernial sac has slipped back into the abdomen with its constriction ring, so that the hernia is not properly reduced. This is unusual, and occurs with a hernia previously already strangulating bowel (18.6).

Perform a laparotomy. Isolate the loop of bowel trapped in the constriction ring with packs, and resect the affected segment of bowel (11-7). Repair the internal ring with 2 monofilament sutures from inside the abdomen.

If groin pain radiating to the scrotum persists months after the operation, you may have caught the ilio-inguinal, ilio-hypogastric or branches of the genitofemoral nerves (18-7C) in the repair.

Typical neuropathic pain is stabbing, shooting, 'electric', or described as 'pins & needles'; tapping the course of the nerve exacerbates the pain, and a specific LA block of the nerve implicated removes the pain temporarily. If these criteria exist, re-open the wound, try to find the culprit nerve and free it, burying it within muscle (or excise it if it is hopelessly caught in scar tissue).

CAREFUL TECHNIQUE WILL REDUCE THE RISK OF RECURRENCE

18.4 Giant inguinal hernia

It used to be said that there were two kinds of inguinal hernias in the tropics: those above the knee and those below it! This section deals mainly with those below it, which may have been present for as long as 50yrs! They are, now however, not so common, but giant hernias even above the knee still pose a challenge. They may contain large intestine, stomach or so much of the abdominal content that reduction back into the abdominal cavity may cause excessive pressure on the diaphragm and subsequent respiratory distress.

Differentiate a giant hernia from a hydrocoele (18-14) or an adenolymphocoele (18-5).

If a patient has a very large indirect inguinal hernia, or a recurrent direct one, the posterior wall of the inguinal canal will be very weak and its anatomy deformed. It will be difficult to repair, and much more likely to recur. Repair will be more secure if you can divide and transfix the spermatic cord just below the internal inguinal ring, so that you can close it and reinforce the posterior wall of the inguinal canal more securely. You must increase the abdominal volume pre-operatively to accommodate all the contents of the hernia: this you can do by progressively injecting air into the peritoneal cavity.

PREPARATION.

Counsel the patient about probable loss of the testis on that side, and obtain consent for ligation of the spermatic cord. You can expand the abdomen over 2 weeks by introducing 500ml air every alternate day progressively into the peritoneal cavity through the *linea semilunaris* (18-3) using a long cannula, a two-way tap, and a 50ml syringe. This will allow easier return of abdominal contents. Wait 2wks more before surgery.

METHOD.

Start perioperative antibiotic prophylaxis. Use GA. Proceed as for a simple hernia repair (18.2); the posterior wall of the inguinal canal will be weak, so a mesh repair (18-13D) will be necessary. If you have permission, remove the testis, and tie and divide the cord at the internal inguinal ring. If you are obliged to retain the testis, but you can divide the cord, tie, transfix, and divide it as near the internal ring as you can. Leave its distal part untouched, so that you do not disturb the collateral vessels. Be gentle, or you will damage them, and the testis will atrophy.

You will probably need to excise some of the stretched scrotum; with the testicle pulled upwards, mark a suitable site on the scrotal wall and amputate its distal part. There will be considerable bleeding, so go slowly, securing haemostasis as you go along, and then close the scrotal wound in 2 layers with a continuous absorbable suture. Leave a drain in place.

One way of reducing the risk of scrotal haematoma is to use tape to secure the empty floppy scrotal sac for 48hrs to the anterior abdominal wall with 2 pieces of gauze between.

18.5 Inguinal hernia & congenital hydrocoele in infants and children

A baby's *processus vaginalis* (18-15) is usually open at birth, and closes <2yrs. If it is not completely obliterated it can leave a number of abnormalities (18-15). Note that a congenital hydrocoele is simply an indirect hernia containing fluid. *Never try to aspirate such a hydrocoele!*

When you see such, the hernia may be present, or it may have reduced itself, so you have to depend on the mother's history that there is a lump which comes and goes, and gets larger when the child cries. If you want to see it, find some way to make him cry or laugh!

Inguinal hernias in a child are always indirect. Unlike umbilical hernias, they do not become smaller spontaneously with age. Inguinal hernias seldom strangulate in childhood because the neck of the canal is fairly wide and the canal is so short, but they often become obstructed, especially in the 1st year. However, in 30% of premature babies these hernias *will* strangulate and these babies are most easily missed. Herniotomy is one of the most common operations in children, but it is not always easy. The sac is thin, delicate, and difficult to find, and you can easily injure a baby's vas.

At birth the inguinal canal is short, and if the hernia is large, the external ring may lie directly over the internal ring, which is convenient, because it allows you to dissect out the sac, without opening the *external oblique* aponeurosis. In young children, simply open the sac (herniotomy), and tie it off. *Herniorrhaphy is not needed.*

ABNORMALITIES OF THE PROCESSUS VAGINALIS

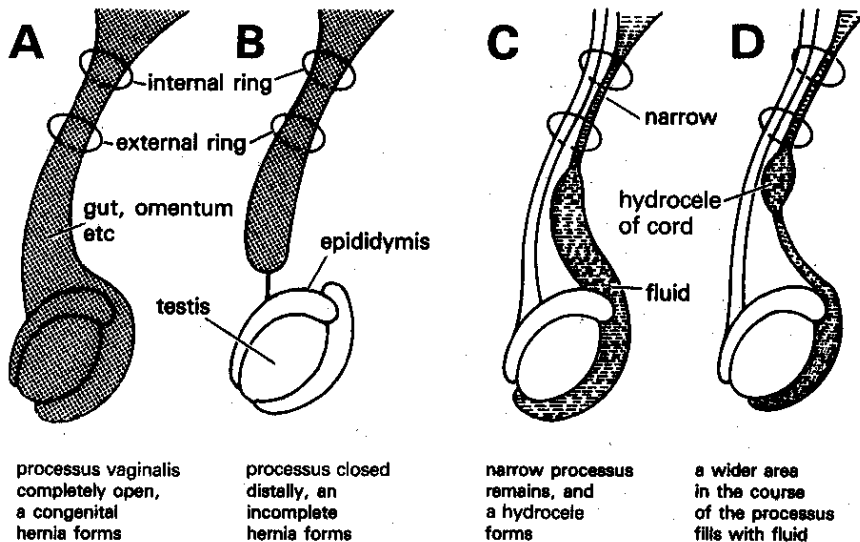


Fig. 18-15 ABNORMALITIES OF THE PROCESSUS VAGINALIS. A, when it remains completely open, a complete inguinal hernia forms. B, if it closes distally, and leaves the *tunica vaginalis* covering the testis, an incomplete inguinal hernia forms. C, when the *processus vaginalis* becomes narrow, but does not disappear, fluid passes down it from the peritoneal cavity and forms a hydrocele around the testis. D, if there is a wider area in the course of the *processus vaginalis*, it may form a hydrocele of the cord. Operate on a congenital hernia and on a congenital hydrocele: tie and divide the *processus vaginalis*. After McNeill Love WJ. *Bailey & Love's Principles & Practice of Surgery*, HK Lewis 15th ed 1975.

Wait to operate until a baby is 6 or preferably 9 months old, when anaesthesia and surgery will be easier. *Never apply a truss.*

The operation involves dissecting out the sac carefully (making sure that you do not damage the spermatic vessels or the vas), transfixing its neck at the external ring, and excising it.

There is no need to open the inguinal canal of a young child. You may occasionally need to narrow the internal ring of an older child.

You may find a sliding hernia of the bladder or colon, or of a girl's adnexae. Hernias are often bilateral in children: examine the other side carefully therefore to avoid the child having to return later for another operation. Always also look for maldescended or absent testes (27.27).

CAUTION! If you find bilateral inguinal hernias in girls, look for signs of ambiguous genitalia or intersex state.

MANIPULATION FOR CHILD INGUINAL HERNIAS

If a child's hernia is irreducible, sedate him, and put him into gallows (overhead skin) traction if he is <3yrs. There is a 50% chance that it will reduce spontaneously, or with a little *gentle* manipulation. *Do not induce pain, or use any force!* If this succeeds, operate as soon as it is convenient. If it fails, operate without delay.

HERNIOTOMY IN YOUNG CHILDREN (GRADE 2.3)

ANAESTHESIA. Ketamine or GA.
Do not use LA.

INCISION.

Make a 3cm incision in the *skin crease* above the inguinal ligament, more medially and superiorly than you would for an adult. Cut through the subcutaneous tissues, and pick up and tie the small superficial epigastric and external pudendal vessels with haemostats. Separate fat and superficial tissues by the 'push and spread' technique (4-8). *Do not split the external oblique aponeurosis: this is unnecessary.*

To find the hernial sac, which should be anterior to the cord, push with your little finger in the scrotum through the external ring. Gently separate tissues off the cord which appears as a distinctly blue structure and thereby free it. You should then be able to get behind it with a finger and so hold it between the thumb and index finger of your left hand. Dissect the sac very carefully away with gauze or scissors from the spermatic vessels and vas, which is a thin white strand. *Beware: it is all too easily damaged because it is so fine!*

Free the sac to the internal ring taking care not to tear it. Unless it is obviously empty, or just has hydrocele fluid in it, open it between haemostats, as if you were opening the peritoneum for an abdominal operation, and reduce the contents unless they need resection.

CAUTION!

- (1) Free the sac completely before you open it. In this way you are less likely to split it.
- (2) A girl's Fallopian tube and ovary may slide into the sac: *do not remove them as part of it.*
- (3) If you find the appendix in the sac, *do not remove it.*
- (4) A boy's vas is very small, *do not mistake it for a piece of fibrous tissue.*

Otherwise, divide the sac and transfix its neck with 3/0 absorbable suture, and tie it off.

CAUTION!

(1) Make sure you are cutting the sac only. You can easily cut the vas, because it is adherent to the posterior surface of the sac.

(2) *Do not split the sac lining.* If you do so accidentally, apply fine haemostats to the parts of the sac that are free and try to separate the sac off its underlying structures; this is difficult as it tends to tear further.

If you have pulled the testis out of the scrotum, be sure to return it properly, or else it may adhere in the groin; there will be some scrotal swelling afterwards, but reassure the parent this is *not a recurrence*.

INGUINAL HERNIAS IN OLDER CHILDREN

In a child >14yrs, assess the size of the internal ring. The internal ring of an older child is no longer under the external ring. It will have started to migrate laterally. Try to put your finger through it into the peritoneal cavity. If it is big enough to let you insert your index finger (the internal ring is >1½cm wide), it probably needs herniorrhaphy.

Retract the cord laterally. Put the tip of your finger through the hole in which the stump of the sac has retracted. Feel the margins of the hole, put a haemostat on its medial margin, and lift it forwards. Bring the fine upper and lower edges together with 3/0 absorbable sutures, so as to wrap the *transversalis fascia* snug round the cord. You should still be able to pass the tip of your forceps through the ring alongside the cord. You may have to open the inguinal canal for about 5cm to get access to the internal ring: cut upwards and laterally from the external ring in the direction of the fibres of the *external oblique* aponeurosis as in an adult hernia operation.

DIFFICULTIES WITH CHILD INGUINAL HERNIAS

If there is a hernia and a hydrocoele that are separate, proceed as above, and open the *tunica* distally by pushing up on the hydrocoele: the patent *processus* is probably just too thin to allow the hydrocoele to drain (18-16C). Leave the tunica open distally to do so.

If the sac splits up to and perhaps through the inguinal ring, this is inconvenient. Be especially careful, as you search for something to sew together, that you do not tie the vas. If the hernia recurs, you will probably have to close the defect internally *via* a laparotomy.

If the hernia recurs, re-operation can be difficult: see above.

If there is a maldescended testis together with the hernia, separating the sac may be more difficult. Isolate the vas and its artery, the testicular artery, and pampiniform plexus to mobilize the testis to get it down to the scrotum (27.27).

If there is a strangulated hernia as a neonate, the sac will be very friable and will not take sutures; be content to close the internal ring by approximating the internal and external oblique muscles.

If the testis atrophies later, you have probably interfered with its blood supply. This is one of the commonest complications. The parents, who may have difficulty accepting that one testis can function as efficiently as two, will not be pleased. The other testis should however be normal, so reassure them.

18.6 Irreducible & strangulated inguinal hernia

You can relieve a strangulated inguinal hernia and resect bowel through the ordinary incision for an inguinal hernia. Unlike a femoral hernia, there is usually no need to open the abdomen through a separate incision to get better access.

DIFFERENTIAL DIAGNOSIS.

Suggesting torsion or inflammation of an inguinal testis: absence of the testis from the scrotum. A retained testis is often associated with an interstitial hernia (into the anterior abdominal wall).

Suggesting inflamed inguinal nodes: the swelling is more diffuse, there is sometimes redness and oedema of the overlying tissues. Vomiting and abdominal pain are minimal or absent.

TAXIS (MANUAL REDUCTION) FOR IRREDUCIBLE INGUINAL HERNIAS INDICATIONS.

An inguinal hernia which has only been irreducible for a short time, *and is not very tender to touch*.

CONTRAINDICATIONS.

Any hernia which is tender to touch

METHOD.

Use morphine and put the patient in a steep Trendelenburg position. Wait for at least ½-1hr. Often, a hernia reduces spontaneously. If it does not, use gentle manipulation, but *never* force. For children <3yrs use gallows traction (18.5).

CAUTION!

Do not apply pressure which may rupture bowel, or risk reducing the hernia contents 'en masse'. Watch carefully for signs that any nonviable tissue has been reduced. This is unlikely to have happened, and if it has, the tissue is more likely to be omentum than bowel. If you are in any doubt restrict oral intake, insert a nasogastric tube, administer IV fluids and observe for abdominal tenderness: if this develops, perform a laparotomy.

OPERATION FOR IRREDUCIBLE OR STRANGULATED INGUINAL HERNIAS

PREPARATION.

Use peri-operative gentamicin and metronidazole. Get consent for a laparotomy and possible bowel resection. Prepare all the skin of the abdomen and genitalia. Insert a nasogastric tube to drain the stomach well. Use analgesic sedation and GA.

BISTOURY, guarded. This is a curved probe with a cutting edge on its concave surface near the tip (18-18B). It is the safest instrument for enlarging a constricting hernia ring.

INCISION. Proceed as before (18.2) to open the inguinal canal.

A. OPEN THE SAC.

You will see a tense mass emerging from the internal ring and passing towards the scrotum. If oedema and congestion make identifying the overlying structures difficult, use blunt-tipped scissors and the 'push and spread technique' (4-9B) to incise the first 2 layers: the external spermatic fascia and the *cremaster* muscle. If they dissect off easily, good, if they do not, leave them, except for a small area near the fundus. Incise this between a pair of fine haemostats, just as you would if you were opening the peritoneum for a laparotomy.

CAUTION! Surround the operation site with large swabs to prevent the soiling of the wound by the septic contents of the hernial sac, which is likely to contain virulent aerobic and anaerobic organisms.

Pick up layer by layer in forceps, and carefully incise each layer till you reach the peritoneum when fluid will run out, and you will see bowel or omentum. Apply several haemostats to the peritoneal margins to prevent them retracting into the abdomen. Attach a Babcock forceps to the bowel or omentum to prevent them slipping inside the abdomen.

B. RELEASE THE CONSTRICTION RING.

Feel for the constriction with your finger. If you can insert an instrument through it and nick its lateral margin, do so. If not, retract its upper edge with a retractor, and cut down on it from outside. Alternatively, push your little finger into the ring. While your assistant holds the contents of the sac out of the way, push a large haemostat into the ring lateral to the neck and spread it open. Divide the lateral side of the ring with scissors or a bistoury (18-18).

Gently deliver the contents of the sac. If it extends to the scrotum, it may be easier to deliver the testis also. The bowel or omentum may be blue, purple, or black.

CAUTION!

(1) *Do not damage the spermatic cord as you open the sac.*
(2) *Do not incise the medial side of the internal ring, or you may cut the inferior epigastric artery. Do not cut the bowel!*

Examine the contents of the hernia. If the bowel has been trapped, withdraw a few centimetres of the afferent and efferent loops. Assess its viability (11-6).

If viable bowel or omentum is present, replace them into the abdomen by gently manipulating the bowel through the widened neck of the hernia. Be patient and manipulate small segments at a time. Make sure the patient is well relaxed.

If bowel is non-viable, or dubiously viable, resect it. Gently pull out adequate lengths of bowel on either side of the gangrenous portion. If this is difficult, widen the neck of the sac further; if there is still not enough length, perform a laparotomy *via* a midline incision. When the bowel anastomosis is complete, return it into the abdomen with extreme care, *so as not to disrupt the anastomosis*.

If omentum is strangulated, pass long haemostats across the healthy part, cut off the gangrenous part distal to them, transfix the healthy omentum with a needle, and then tie it off. You may need more than one haemostat and transfixion suture.

CAUTION! Be sure to control all bleeding before you return anything to the peritoneal cavity.

C. CLOSE THE SAC as before (18.2).

D. NARROW THE INTERNAL RING, because you have deliberately widened it!

E. REPAIR the defect with a darn unless there has been gross sepsis, in which case it might be best to advise a formal repair later.

F. *DO NOT CLOSE THE WOUND if there has been gross sepsis*: leave it open and use delayed primary closure (11.8). If there was obvious perforation, drain the canal through the scrotum.

DIFFICULTIES WITH IRREDUCIBLE OR STRANGULATED INGUINAL HERNIAS

If presentation is very late with oedema, cellulitis or abscess formation on the abdominal wall or scrotum, overlying the gangrenous contents of a strangulated inguinal hernia, a faecal fistula is about to form. Expect this beyond the 4th day of strangulation. It can form:

(1) in the inguinal region, where the prognosis is better, especially if the hernia is of the Richter type (18-2B) and the bowel obstruction is incomplete.

(2) in the scrotum, where the prognosis is worse.

In this situation, start IV gentamicin and metronidazole, and infuse 2l IV Ringer's lactate. Start nasogastric suction.

Open the groin, and identify the strangulated loop of bowel; doubly ligate both ends tightly with #2 silk as close as you can to the hernia neck. Pack off the area of the internal inguinal ring, remove the gangrenous bowel between the ligatures.

Curette the fistula track, taking care not to damage any local structures. Wash the groin wound thoroughly and leave it open applying betadine dressings bd. Exteriorize the bowel ends as ileostomies. *Do not attempt any hernia repair at this stage.*

Continue resuscitation till you are sure the patient is passing good volumes of urine, and then plan bowel anastomosis as below.

If there is an established small bowel fistula, following a strangulated hernia weeks or months ago, *do not attempt local repair*. Make sure the patient is well re-hydrated and his potassium deficit is corrected. Then perform a laparotomy: make a midline incision and apply non-crushing clamps on each loop (proximal and distal) of bowel where they enter the hernia orifice internally. Keep the clean laparotomy wound clear of the groin and explore this as above if you haven't already done so).

Now re-scrub and go back to the laparotomy. Withdraw the viable part of bowel out of the abdomen. Make an end-to-end anastomosis (11-7). Close the hernia defect internally with a #1 nylon purse-string suture. Wash out the abdomen thoroughly and close it.

If, in a Busoga hernia (18-10,11), you cannot bring bowel through the narrow opening in the conjoint tendon, extend the incision in the *external oblique* a little more laterally, and then split the *internal oblique* and *transversus* muscles about 5cm above the internal ring level with the iliac spine, as in the muscle splitting approach for an appendicectomy (14-1C). Open the peritoneal cavity, withdraw the bowel, and if necessary, invaginate or resect it. This approach is useful in a strangulated Busoga hernia and avoids enlarging the opening in the conjoint tendon and weakening it.

If, in a Busoga hernia (18-10,11), you find the sac necrotic, but no bowel in it, there is probably no need to open the abdomen and examine the bowel. If it has slipped back, it is unlikely to be seriously non-viable. Debride dead tissues. Postoperatively, continue careful observation for signs of peritoneal irritation and general deterioration.

If you cannot return the bowel to the abdominal cavity, tilt the table head downwards, make sure the patient is well-relaxed with a nasogastric tube *in situ*, put a retractor under the anterior lip of the wound to raise it. Then with extreme care, return the bowel to the abdomen, a little at a time, starting at one end and gently squeezing it between your finger and thumb. If this is absolutely futile, try the La Roque procedure: make a 2nd muscle splitting incision in the *external oblique* and enter the peritoneum laterally, and then pull the bowel down gently from inside.

If you find a gangrenous testis on opening the sac (especially in children), perform an orchidectomy (27.26) and make sure the other testis is present in the scrotum. If not, perform an orchidopexy (27.27) on that side.

18.7 Femoral hernia

A femoral hernia is more likely to strangulate than an inguinal, but is much less common. It is rare where people, especially children, walk barefoot because the resulting enlarged femoral nodes close the defect.

Whereas inguinal hernias are almost entirely a male disease, the sex incidence of femoral hernias is more nearly equal, with femoral hernias only marginally more common in men than in women in most communities.

A patient with a femoral hernia complains of a painful tense, slightly tender, spherical mass below the inguinal ligament, 2cm infero-lateral to the pubic tubercle. *Usually, you cannot reduce it*. If you can, you may be able to pass your finger upwards through the dilated femoral canal.

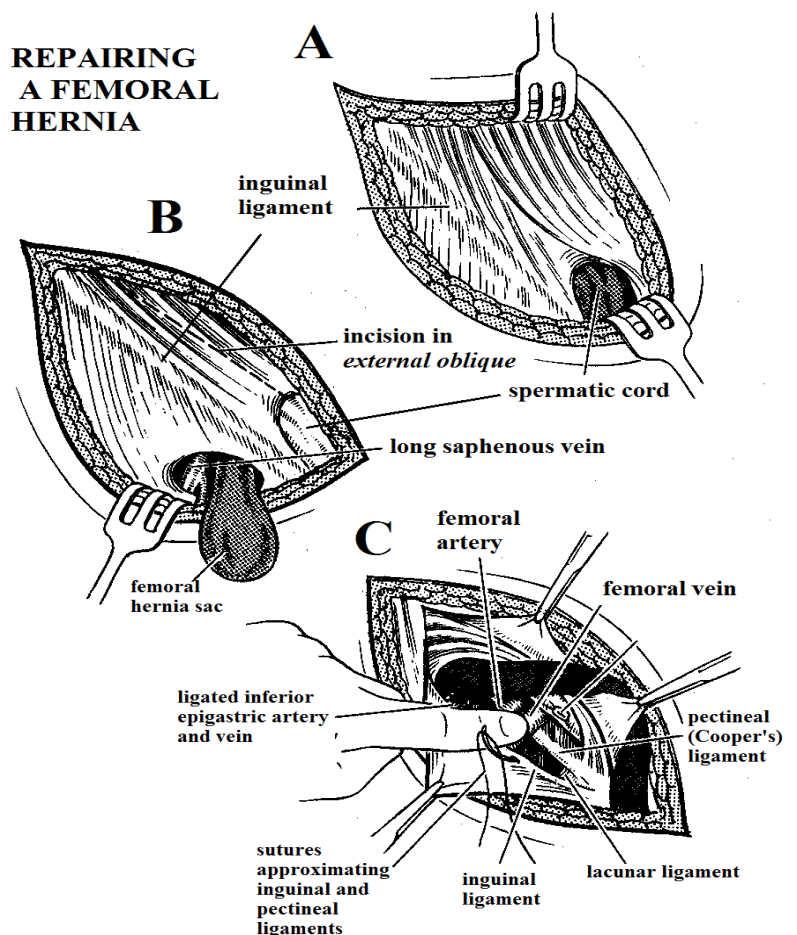


Fig. 18-16 REPAIRING A FEMORAL HERNIA.

A, expose the external inguinal ring. B, retract the lower flap and mobilize the sac. C, suture the inguinal ligament to the pectineal (Cooper's) ligament.

There is usually no cough impulse. Sometimes, a femoral hernia turns upwards, and may come to lie over the inguinal ligament, where you can mistake it for an inguinal hernia, or it can turn outwards or downwards. Repair is not difficult, and recurrence is rare. So operate; *a truss cannot control a femoral hernia*. The low approach to a femoral hernia is described here, and is satisfactory unless you need to resect bowel.

ANATOMY. A femoral hernia comes through the femoral canal. This is about 2cm long and is filled with fat and a lymph node (Cloquet's). *Anteriorly*, it is bounded by the inguinal ligament, and posteriorly by the pectineal (Cooper's) ligament, which is a thickened part of the pectineal fascia, and overlies the pectineal ridge of the pubic bone. *Laterally* lies the femoral vein, and *medially* lies the sharp edge of the lacunar ligament. A femoral hernia extends forwards through the *fossa ovalis* where the long saphenous vein joins the femoral vein.

Other rarer femoral hernias can emerge within the femoral sheath but anterior to vein and artery (Velpau's hernia), lateral to the femoral vessels (Hasselbach's hernia), or posterior to the femoral vessels (Serafini's hernia). Narath's hernia is posterior to the vessels and only visible when the hip is congenitally dislocated. In De Garegeot's hernia the appendix is within a femoral hernia.

Other rare hernias in this area come through the lacunar ligament (Laugier's hernia), the pectineal fascia (Cloquet or Callisen's hernia), and the saphenous opening (Béclard's hernia).

DIFFERENTIAL DIAGNOSIS

Suggesting enlarged lymph nodes: look for a septic focus on the leg, the lower abdomen, or the buttock or evidence of tuberculosis elsewhere. An enlarged deep inguinal lymph node may be almost impossible to distinguish from a femoral hernia, except for signs of intestinal obstruction.

Suggesting a varix of the long saphenous vein: a soft, easily compressible swelling (unless it is thrombosed), which fills up again when you release the pressure.

Suggesting a psoas abscess: a much larger fluctuant swelling associated with spinal TB or HIV disease

OPERATION FOR NON-STRANGULATED FEMORAL HERNIA (GRADE 2.3)

ANAESTHESIA.

- (1) LA, especially if the general condition is poor. Use the same method as for an inguinal hernia. Infiltrate a wide subcutaneous area, and infiltrate the neck of the sac as you dissect deeper.
- (2) Subarachnoid or epidural anaesthesia.
- (3) GA with relaxants.

INCISION.

Make a 6cm incision directly over the hernia below the groin crease. Deepen the wound through the subcutaneous tissue to expose the sac (18-16A). Tie the tributaries of the long saphenous vein. Use blunt dissection to mobilize the sac free from the tissues around it (18-16B). Trace it to its neck, where it disappears into the femoral canal.

Carefully incise the fundus of the sac. Cut through fat until you find the much smaller peritoneal sac. Expect to cut through many layers. Inspect its contents. This will usually be omentum, except in long-standing hernias. Reduce the contents completely, and divide any adhesions.

INGUINAL AND FEMORAL HERNIAS

Types of indirect hernia

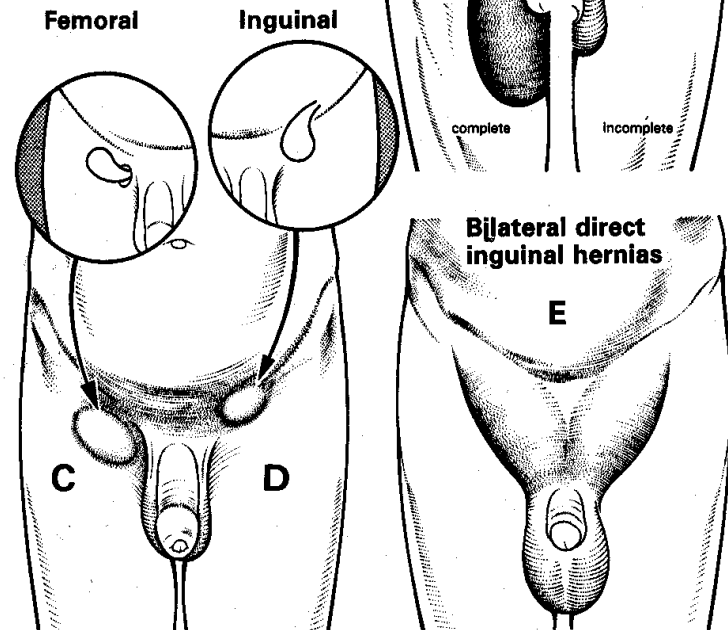


Fig. 18-17 INGUINAL AND FEMORAL HERNIAS.

A, complete indirect inguinal hernia reaching right down into the patient's scrotum. B, incomplete indirect hernia in which the *processus vaginalis* ends just above the testis. C, femoral hernia, showing how the sac extends upwards. D, small indirect inguinal hernia showing the sac extending downwards. E, bilateral direct inguinal hernias.

After McNeill Love WJ. *Bailey & Love's Principles & Practice of Surgery*, HK Lewis 15th ed 1975

When the sac and its contents are cleanly exposed, and you are quite sure that you have completely reduced its contents, twist it.

Transfix its neck proximally with thread as high up as you can, and excise the protruding sac, leaving a generous neck distal to the transfixing suture. The stump will disappear up into the femoral canal.

Then insert a few monofilament sutures, so as to approximate the inguinal ligament to the thickened part of the pectineal fascia, on the floor of the femoral canal. This is the pectineal (Cooper's) ligament (18-16C). Protect the femoral vein laterally with your finger, while you are inserting these sutures.

Close the wound in layers.

DIFFICULTIES WITH A FEMORAL HERNIA

If you cannot get good bites of the pectineal ligament as it lies on the pectineal fascia, get a short curved needle, or a fish-hook needle, and set it in a needle-holder in such a way that it points back at you. Insert this into the femoral canal, and try to hook the ligament on your way out.

If you injure the femoral vein, press on the bleeding point, arrange suction and obtain vascular clamps (18.3)

If you cannot return the contents of the sac easily, pass your finger gently outside it and dilate the femoral ring. If this fails, stretch the ring by putting a haemostat into it and opening it in an inferio-superior direction. Or, carefully enlarge the superomedial side of the femoral canal, but be careful of an abnormal obturator artery (18-18A).

If you find an inflamed or gangrenous appendix in the hernial sac (de Garengeot's hernia), excise the appendix (14.1). Close the wound by delayed primary closure (11.8), because of the high risk of infection.

If there is arterial bleeding as you enlarge the femoral canal, you have injured an abnormal obturator artery, which arises in about 25% as a pubic branch of the inferior epigastric artery.

This abnormal obturator artery may occasionally pass over the internal aspect of the femoral canal, or run in the edge of the lacunar ligament, where you can easily cut it (18-18A).

If so, open up the inguinal (*NOT femoral*) canal, open up its posterior wall between the inguinal ligament inferiorly and the conjoint tendon superiorly. This will expose the peritoneum. Push this up and you will find the abnormal obturator artery crossing the internal aspect of the femoral canal. Grasp it with a haemostat and tie it.

If you suspect strangulation, extract the bowel carefully from the femoral canal and examine it. If, after covering it with warm packs, it does not recover, it needs resecting (18.8).

18.8 Strangulated femoral hernia

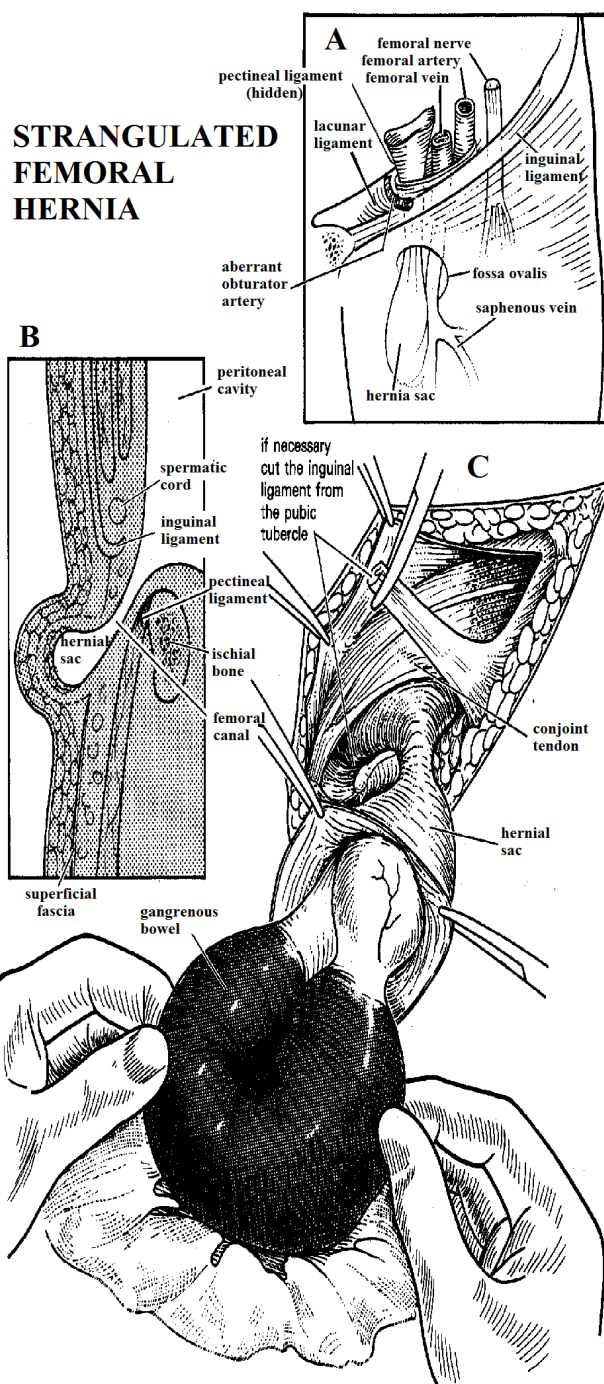


Fig. 18-18 STRANGULATED FEMORAL HERNIA.

A, anatomy of the femoral canal. *N.B.* The femoral vein lies laterally and the lacunar ligament (reflected part of the inguinal ligament) lies medially to the sac. An abnormal obturator artery may run in the edge of this ligament. B, side view of the femoral canal showing how a femoral hernia forms. C, opening a strangulated femoral hernia proximally. (Most femoral hernias are smaller than this. It is rarely necessary to divide the inguinal ligament.) C, adapted from a drawing by Frank Netter, with the kind permission of CIBA-GEIGY Ltd, Basle Switzerland.

A strangulated femoral hernia is more often misdiagnosed than a strangulated inguinal hernia:

- (1) It may be small, and lost in the thick fat of the groin.
- (2) Only the circumference of the bowel may be caught (Richter's hernia), so that you can hardly feel anything in the thigh.
- (3) When it is large, it may have a rounded fundus and a narrow neck, which allows the fundal part to move painlessly, so you may think there is no strangulation.

This makes it very important to explore any doubtful lump in the femoral region, when a patient has abdominal symptoms and especially intestinal obstruction, especially if femoral hernias are not uncommon in your area.

IF THERE ARE ABDOMINAL SYMPTOMS, EXPLORE ANY TENDER FEMORAL LUMP

There are 2 approaches to a strangulated femoral hernia, with some debate as to which is best:

- (1) the standard approach, which requires two incisions, one over the hernia and another in the lower abdomen, and
 - (2) the *Lotheissen* approach through a single incision in the posterior wall of the inguinal canal: this is more difficult.
- In the standard approach, cut down just above the patient's inguinal ligament and aim to:
- (a) Expose and isolate the sac.
 - (b) Open and inspect its contents.
 - (c) If the bowel is not viable, open the abdomen through a lower midline incision. Expose and if necessary enlarge the femoral ring from above.
 - (d) Amputate the bowel in between pairs of clamps.
 - (e) Remove non-viable bowel from the hernia sac.
 - (f) Excise the sac and leave the wound open.

OPERATION FOR STRANGULATED FEMORAL HERNIA (GRADE 3.3)

ANAESTHESIA.

- (1) Ketamine and LA: infiltrate the field widely. Inject more solution into the deeper tissues as you get to them.
- (2) Spinal or epidural anaesthesia if the patient is fairly fit.
- (3) GA and tracheal intubation with relaxants.

PREPARATION.

Pass a catheter and empty the bladder. Make sure the patient is well-hydrated. Use perioperative IV gentamicin and metronidazole.

INCISION (STANDARD APPROACH).

Make a transverse incision in the skin crease over the hernia itself. Divide the covering layers, including the deep fascia, and dissect them off the sac. Sweep your finger round the hernia to mobilize it, and define its neck. Clean it by dissection with your finger, and a swab and not-too-sharp-nosed scissors.

OPEN THE SAC by inserting retractors and packing off the sac while you carefully cut down on it. Like an onion, it will have more layers than you expect. As soon as you are inside it, there will be a warning spurt of turbid blood-stained fluid. The bowel is often gangrenous.

RELEASE THE STRANGULATION by holding the bowel in a swab between the finger and thumb of one hand. Meanwhile, try to widen the femoral canal by inserting the very tip of your finger into the hernia, just outside the sac itself. With your finger inside the femoral canal, move it around the neck of the sac and try to free it.

CAUTION! *Do not let go of the bowel at this point*, because if you lose it, you have to perform a laparotomy to retrieve it.

Now draw the bowel down out of the sac a bit more. If it does not quite come, repeat the dilating manoeuvre, but this time with your finger inside the sac, between it and the bowel.

If you still cannot deliver the bowel into the wound, clear the neck of fatty tissue. Enlarge the ring on its medial side by dividing the lacunar ligament, and the fibrous tissue in front of the ring.

Protect the contents of the sac while you divide the ligament by passing a grooved director up the medial side of its neck. Then carefully cut down on the director with one or two nicks of a scalpel. *Watch out for an abnormal obturator artery.*

With the bowel drawn down into the sac, wrap it in a warm wet swab, to see if it is viable (11-7).

If the bowel is viable, let it slip back into the abdominal cavity, and repair the hernia from the groin (18.7).

If the bowel is not viable, perform a lower midline (or Pfannenstiel) incision, and resect and anastomose the bowel from inside by laparotomy (18.6).

If protruding omentum looks as if it might not be viable, transfix it, tie it, and excise it.

If an area of necrosis only involves part of the wall of the bowel (Richter's hernia, 18-2B), bury it with invaginating seromuscular absorbable sutures. You need not resect it, *provided it follows the criteria for safe invagination* (18.2).

If you are in any doubt about the viability of the bowel, (including a Richter's hernia), excise the damaged portion and perform an end-to-end anastomosis (11-7).

CAUTION!

(1) Always open the sac and inspect its contents before you return them to the abdomen. They may be gangrenous. If there is a Richter's hernia, *be especially careful not to let it escape back into the abdomen.*

(2) *Take great care not to contaminate the peritoneal cavity.*

REPAIR. If you have opened the abdomen, it may be difficult and dangerous to reduce the hernia contents if they are incarcerated (and especially if they are strangulated). You might need to divide the bowel loops inside, and then remove the remainder outside (18.6).

CAUTION! Take care to free the sac of surrounding tissues before you excise it, or you may pass sutures into a protrusion of the bladder or colon.

Close the femoral canal by passing three interrupted monofilament sutures between the inguinal ligament and the pectineal ligament (18-16C). *Do not go too far laterally with these sutures*, or you may constrict the femoral vein.

DIFFICULTIES WITH STRANGULATED FEMORAL HERNIAS (see also 18.3,7)

If you cannot dilate up the femoral canal enough to mobilize the strangulated bowel, approach it from above via a laparotomy. Use blunt dissection to expose the neck of the sac medial to the femoral vessels.

If this is not successful, cut the lacunar ligament, the medial boundary of the femoral ring under direct vision. *Be careful*; you may meet an abnormal obturator artery (18-18A)!

If you still cannot dilate up the femoral canal enough, divide the inguinal ligament: this is very rarely necessary. At the end of the operation, suture its free end against the pectineal line, so as to obliterate the femoral canal. The danger with this is that, if the wound becomes infected, a hernia may form later which will be difficult to repair. Whatever you do, remember that the femoral vein lies on the lateral side of the femoral canal!

If you find a strangulated femoral hernia expecting an inguinal hernia, proceed as in the *Lotheissen* approach:

THE ALTERNATIVE LOTHEISSEN APPROACH THROUGH THE POSTERIOR WALL OF THE INGUINAL CANAL

Strangulated bowel and omentum may be more easily dealt with by this method, than by the 'standard approach'.

Make an incision 1-2cm above the inguinal ligament, as for a strangulated inguinal hernia (18.2, 18.6). Sweep away the superficial fatty tissue from the external oblique in the lower wound flap, until you come to the bulging femoral hernia below the inguinal ligament.

Deal with the hernia sac as above.

Open up the inguinal canal as for an inguinal hernia. Hold the cord out of the way, and incise its posterior wall (the conjoint tendon and *transversalis* fascia medially and the *transversalis fascia* only laterally). Make a 2½cm incision 5mm above and parallel to the inguinal ligament. Tie and divide the inferior epigastric artery and vein, that lie deep to the inguinal ligament in the medial border of the internal inguinal ring; then extend the incision laterally to 4cm. Apply haemostats to its upper and lower edges to hold them apart.

Look for the neck of the hernia from above by gauze dissection. You will find a tongue of peritoneum disappearing into the femoral canal. Working from above and below, and using the methods described above, reduce the hernia and the sac. Be careful to clear the sac from the bladder medially. Deal with strangulated bowel or omentum as above.

Transfix, tie, and excise the sac. Use interrupted monofilament to close the femoral canal, by passing sutures between the inguinal ligament and the pectineal ligament. Protect the femoral vein laterally with your finger while you place these sutures. Close the posterior wall of the *external oblique* aponeurosis as for an inguinal hernia.

18.9 Hernia of the umbilicus & anterior abdominal wall

There are several hernias in this region, and you must not confuse them:

- (1) The common true umbilical hernias of children, which rarely need surgery.
- (2) The much rarer paraumbilical hernias of adults through or beside the umbilicus, which usually need surgery.
- (3) Small and usually harmless epigastric hernias of the *linea alba* between the xiphoid and the umbilicus, which often do not need surgery, but which are easy to repair.
- (4) Hernias which follow incisions, particularly Caesarean sections, other laparotomies, appendectomy or kidney operations.
- (5) Rare lumbar or Spigelian hernias, which are direct hernias in the flank or 3-4cm above the inguinal ligament through the *linea semilunaris* (18-3).

If there is a large midline bulge in the upper abdomen, which feels muscular, this is a wide separation (divarication) of the *recti* muscles: you should not operate on this. Try to get the patient a corset for support.

Remember that, both in adults as well as children, an umbilical hernia will bulge with coughing or crying, and other causes of abdominal distension. The hernia itself is *not* the cause of the problem, and you should resist attempts of a patient or parent to get you to operate.

18.10 Umbilical hernia in children

In many areas of the world, a child commonly has a defect in the *linea alba* at the umbilicus through which a hernia forms (18-12A). These hernias rarely obstruct or strangulate, usually heal themselves without treatment, and seldom need repair. In areas where they are common, and accepted as being merely a variant of the normal, there will be little demand for surgery. Accept this and do not operate without good reason.

If you do have to operate, repair is usually straightforward. The child's umbilical scar is weak and the neck of the sac wide; it has one compartment, and is covered by skin, to which it may be closely adherent. It may contain small bowel, omentum, or large bowel, and rarely strangulates. *Strapping such a hernia in a child is useless.*

A large defect at birth (omphalocele or exomphalos) requires a different approach (33.4).

MANAGEMENT.

If a child is born with a small hernia, reassure his mother that it will become a little larger up to 3-5yrs; 90% will close spontaneously by 3yrs and 95% by 5yrs unless the defect is >2cm diameter.

If the parents blame a hernia for recurrent bouts of periumbilical pain, make sure that this is not due to hookworms or sickle-cell crises, or even a cough! The hernia will always bulge when the child cries, but it is usually not the cause!

An irreducible hernia will however often reduce under sedation or ketamine with *gentle* taxis (18.6).

UMBILICAL HERNIA REPAIR (GRADE 2.3)

OPERATIVE TREATMENT for an *uncomplicated* hernia is only indicated if a child has reached 6yrs, the hernia is more than 5cm across at its neck (rare), or he has previously had an incarcerated hernia reduced. Otherwise it is indicated for the irreducible or rare strangulated hernia, which may have inspissated thick hard faeces or undigested seeds caught in the herniated loop of bowel.

INCISION.

Preserve the umbilicus; only if the hernia is large you may have to excise it. Make a curved transverse incision, above or below the umbilicus (18-19A). Dissect down to the anterior rectus sheath and around the umbilicus, so as to reflect a lower or an upper flap to include it. If dissecting the fundus of the sac free from the umbilicus is difficult, leave it. Find and define the sac back to the *linea alba* (18-19B).

Reduce the contents of the sac, if it is not already empty, and open it between haemostats, as usual when entering the peritoneal cavity (11-2). Enlarge the opening with small lateral incisions. Close the sac with a purse string suture, or, transfix, tie, and excise it (18-19C).

Drop the stump back into the abdomen. Overlap the edges of the rectus with interrupted sutures (18-19D). Close the skin, and apply a firm dressing (18-19E).

AN INFANT'S UMBILICAL HERNIA

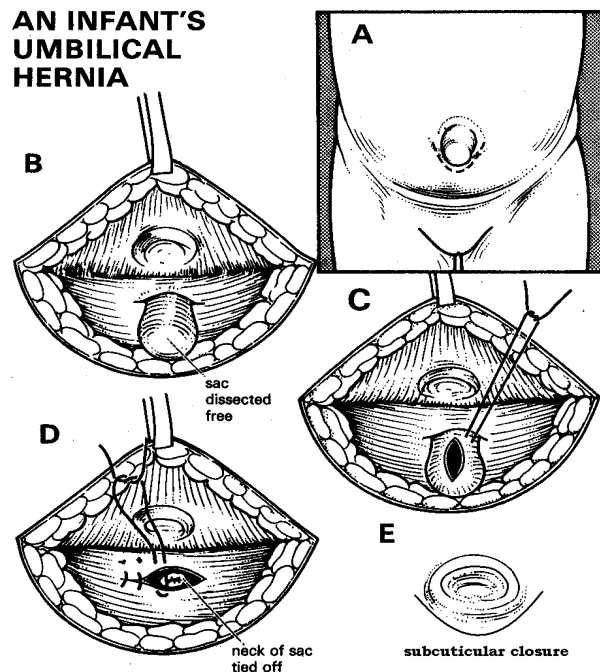


Fig. 18-19 INFANTILE TYPE OF UMBILICAL HERNIA.

A, make a curved incision just below the umbilicus. **B**, reflect a skin flap which includes it. **C**, open the sac at its neck, and close it with a purse string suture. **D**, close the opening in the *linea alba* with a few interrupted sutures. **E**, operation complete.

After Rob C, Smith R *Operative Surgery: Part I: Abdomen, Rectum and Anus*, Butterworth 2nd ed 1969 p.208 Figs 1-4. with kind permission.

DIFFICULTIES WITH UMBILICAL HERNIAS

If there is a discharge at the umbilicus, check for an inspissated keratin plug deep in the umbilicus: lift it out and clean the skin. Ask if it has been present since birth and look for vitello-intestinal or urachal remnants.

KAKAZI (14yrs), who had just received a letter admitting her to a secondary school, presented at a remote rural hospital with an obstructed, infected, ulcerated, gangrenous umbilical hernia the size of a small fist. She was vomiting and the abdomen was distended. There were no sterile drums, and no diesel with which to run the generator and operate the electrical sterilizer. There was no petrol for the ambulance, so she could not be referred. Equipment was sterilized on a charcoal stove. She was given the hospital's last bottle of intravenous fluid and anaesthetized with ether. There was no hernial sac to isolate, because infection had destroyed it. Gangrenous small bowel was resected and anastomosed, the abdomen was closed, she recovered completely, and did not lose her place at the school. **LESSON** Never give up!

Thanks to Dr Bosco Rwakimari.

18.11 Para-umbilical hernia in adults

Try to distinguish in adults whether a hernia in the umbilical region occurs above or below the umbilicus, through a weak place in the *linea alba*, rather than directly through the umbilicus itself. You may occasionally see a true umbilical hernia so huge that it can accommodate a pregnant uterus! This may arise from a healed exomphalos (33.4) where the defect was never repaired in childhood.

The patient is usually an obese multiparous woman, with a large multilocular hernia in the upper part of the umbilicus. Its margins are firm, so that obstruction and strangulation, particularly Richter-type strangulations of the large bowel (18-2), are common.

Repair of a small paraumbilical hernia is quite easy; but repair of a large hernia is difficult, because:

- (1) The viscera in the sac stick to its wall, and in freeing them you may damage bowel.
- (2) There are usually several loculi, divided by fibrous septa.
- (3) The sac often extends to the skin.
- (4) You need to raise flaps, under which blood and exudate can collect and become infected postoperatively. Minimize this risk by closing the dead spaces under any flaps you make, as best you can.

DIFFERENTIAL DIAGNOSIS

A hard lump at the umbilicus may not be an irreducible hernia.

If it bleeds at menstruation, it is endometriosis.

If it is stony hard, it is a Sister Joseph's nodule indicating widespread intra-abdominal malignancy.

If it is purplish with a tendency to ulcerate and bleed, it is Kaposi's sarcoma.

PARAUMBILICAL HERNIA REPAIR IN ADULTS (GRADE 2.4)

PREPARATION. If the patient is very fat, encourage him to lose weight before you operate. Obesity makes surgery difficult and recurrence much more likely. Clean the umbilicus carefully to remove all debris that might contaminate the wound. Warn the patient that, if the hernia is large, you may have to remove the umbilicus.

SMALL PARAUMBILICAL HERNIAS

These are hernias in which the lump (not the ring) is <5cm in diameter. Preserve the umbilicus if you can.

INCISION.

Put a plastic-covered pillow under the knees to help relax the abdomen. Make an elliptical incision 1cm above or below the umbilicus. Above, make the incision concave downwards; below, make it concave upwards. Extend it so that it goes 2cm beyond the lump on either side.

Deepen the incision down to the *linea alba* and the rectus sheath on either side of the hernia. Reflect a flap above if your incision was below the umbilicus, so that you can see all round the hernia.

Control bleeding carefully with diathermy. Define the margins of the neck of the hernia. This is seldom as neat as in other hernias. You may not be able to grasp the fundus if it is firmly attached to the umbilicus, so define the neck on all sides, and ignore the fundus initially.

PARA-UMBILICAL HERNIA REPAIR

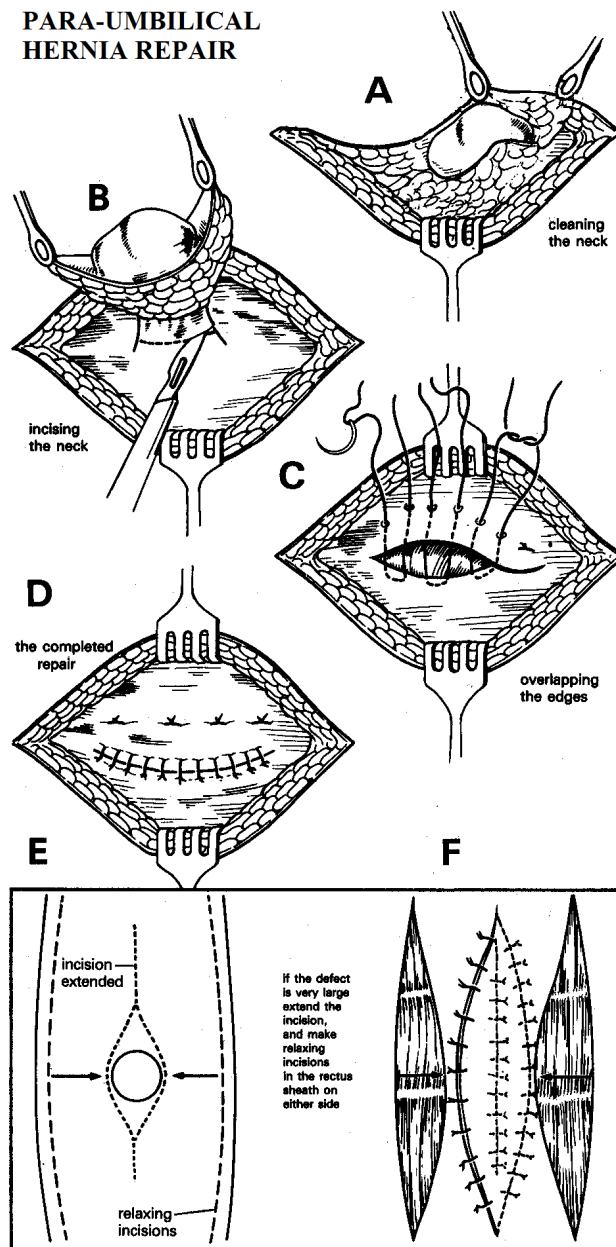


Fig. 18-20 MAYO'S OPERATION FOR PARAUMBILICAL HERNIA. A, undermine the upper flap and clear the tissues towards the neck of the sac. B, cut round the neck, and reduce the sac. C, insert mattress sutures, so as to pull one flap under the other. D, complete repair. E,F, if the defect is very large, you may have to extend it longitudinally, make relaxing incisions in the rectus sheath on either side, and then overlap the aponeurosis at its edges.

If the hernia is small and truly umbilical, try to dissect under the skin around the umbilicus. You can then pass a sling around it and pull it forward. Open the sac close to its neck, because this will be free of adhesions. Do this between haemostats, as if you were opening the peritoneum (11-2).

Continue to open the sac with blunt-tipped scissors, working from the neck towards the fundus. As soon as you have made a sufficient opening, put your finger into it and feel for adhesions. Cut round the circumference of the sac with scissors (18-20B). Carefully examine the contents of the sac.

If a loop of bowel has stuck to the sac, pass your finger up beside it. Find a part of the sac wall which is free of adhesions, and open this up as best you can: it is better to leave a piece of sac adherent to the bowel than to injure it.

If the omentum has stuck to the sac, clamp, transfix, tie, and divide small sections of it at a time, and then return it to the abdomen.

Turn the sac inside out, so that you can see its contents and peel them away. Remove adherent omentum along with the sac, and separate adhesions between loops of bowel. Finally, cut the umbilical skin off the fundus of the hernia.

Enlarge the opening in the abdominal wall laterally, without trying to separate the peritoneum as a separate layer. The rectus muscles will probably be so widely separated, that you will not need to open their sheaths. If necessary, incise the anterior rectus sheath at the ends of these incisions, but do not *injure the rectus muscle*.

You will probably be unable to separate the peritoneum as a separate layer, so suture it with the *linea alba*, which is likely to be broad. Overlap the upper and lower edges of the defect. Clear the under surface of the superficial flap free of as much fat as you can. Then insert several mattress sutures of #1 monofilament (18-20C). When these have drawn one flap under the other, insert some simple interrupted sutures (18-20D) to 'double-breast' the repair. Ensure haemostasis. Close the skin incision, and apply a pressure bandage over the wound.

LARGE PARAUMBILICAL HERNIAS

Under GA, proceed as above, making a longitudinal elliptical incision to include and excise the umbilicus. Dissect down to the fascia above and below the umbilicus on either side. Open the sac at its neck. Expect it to have several loculi, and be prepared to find firmly adherent transverse colon. Evert the sac, and carefully free the viscera from the loculated pockets of the sac.

You may be able to overlap the edges of the sac longitudinally. Make a long midline incision and lateral relaxing incisions in the rectus sheath (18-20E,F). Overlap the sheaths and suture them with #1 monofilament. If this is inadequate, use a mesh (18.13).

Suture the superficial fascia to the anterior rectus sheath. If possible, insert suction drains. Apply pressure dressings, and hold them in place with an abdominal binder, or plenty of adhesive strapping.

DIFFICULTIES WITH PARAUMBILICAL HERNIAS

If a paraumbilical hernia discharges faeculent fluid, a loop of large bowel has strangulated and perforated, and caused a faecal fistula. General peritonitis is usually prevented by the tight fit of the neck of the sac, which seals off the rest of the peritoneal cavity. The differential diagnosis includes other causes of a discharging umbilicus, carcinoma of the transverse colon or stomach, and a persistent vitelline duct. A patent urachus will discharge urine.

You can deal with this electively: perform a laparotomy taking care not to soil your operative field. Resect the colon with the hernia *en masse* and close the abdominal wall, but leave the skin open.

SOME MORE HERNIAS

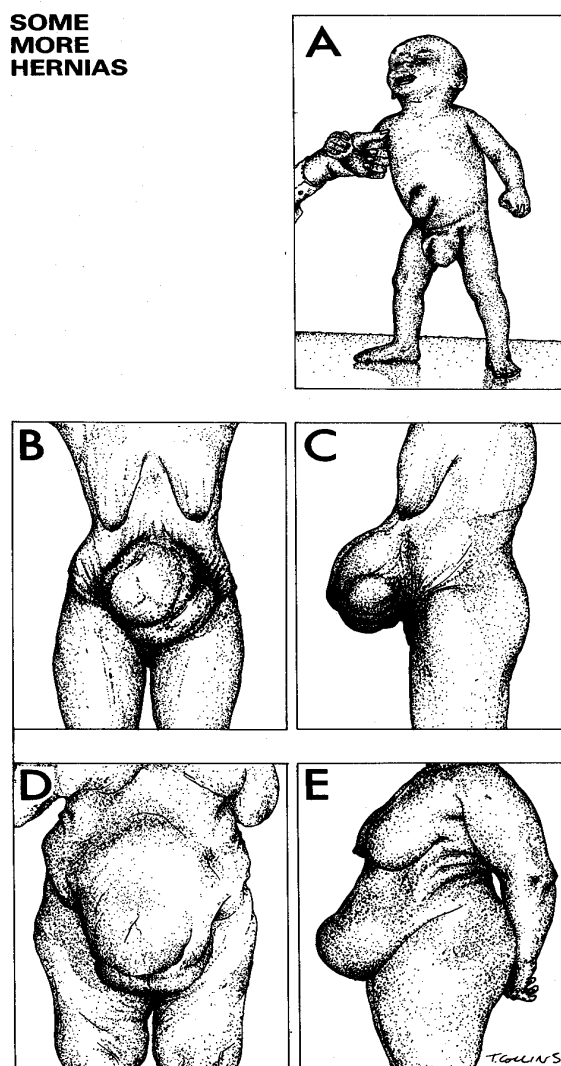


Fig. 18-21 SOME MORE HERNIAS.

A, umbilical and inguinal hernia in boy of 3yrs. The inguinal hernia will need repairing, but the umbilical one will not. B,C, paraumbilical hernia containing most of the patient's bowel and omentum. Note the healed ulcer on the fundus. The mass is knobby because of visible peristalsis. D, incisional hernia following midline laparotomy. E, incisional hernia following Caesarean Section.

After Worsornu, *External hernia - ventral hernia and summary*. *Tropical Doctor* 1975;5(2):56-61, with kind permission..

18.12 Epigastric hernia

A patient with an epigastric hernia complains of attacks of pain and a lump, or occasionally more than one lump, which may be surprisingly painful. You will find a small, soft, rubbery, globular, and sometimes lobulated lump, somewhere along the *linea alba*, between the xiphoid process and the umbilicus. Extraperitoneal fat has bulged through a small ($\leq 10\text{mm}$) cleanly punched-out hole. It may be so close to the umbilicus as to resemble an umbilical hernia. Because the fat in it is tightly wedged, it has no cough impulse, and you cannot reduce it. You can easily mistake it for a lipoma, although it is more firmly fixed. The key to the diagnosis is its position. *Many such patients have been treated for a long time with antacids because they have never been examined!* Repair is usually straightforward. These hernias rarely strangulate.

If the whole length of the upper abdominal midline bulges on sitting up, this is a divarication of the *recti* (18.11), and rarely needs surgical correction (which is anyway not easy).

EPIGASTRIC HERNIA

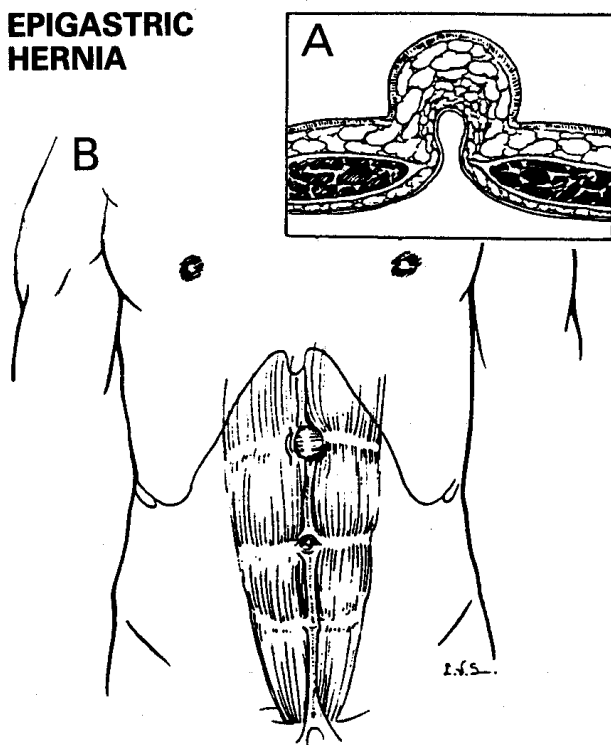


Fig. 18-22 EPIGASTRIC HERNIA. Note that this has occurred through the *linea alba* above the umbilicus.

After Dumphy JE, Way LW. *Current Surgical Diagnosis and Treatment*. Lange Medical 3rd ed 1979 Fig. 36-7 with kind permission.

EPIGASTRIC HERNIA REPAIR (GRADE 2.2)

If you find an epigastric hernia incidentally and it is small and painless, leave it. If the lump is more than 3-4cm, and is causing symptoms, repair it.

ANAESTHESIA. Infiltrate with 0.5% lidocaine with adrenaline.

INCISION. Make a small vertical incision and dissect out the mass.

Clean and mobilize the sac. It will probably dissect off easily. The contents are usually fat or omentum, rarely transverse colon, and extremely rarely small bowel. Reduce the mass by massaging it back inside the abdomen with your fingers. Repair the defect with a monofilament suture.

If you cannot reduce the hernia, enlarge the defect in the *linea alba* by extending the incision. Remember there may be 2 separate hernia defects.

If the hernia is tender (very rare), open the hernia sac and examine its contents, and act accordingly.

18.13 Incisional hernia

These range from a small bulge at the site of a stab drain, to the huge multiloculated swelling that follows the breakdown of a major incision, usually a lower midline laparotomy. Incisional hernias are more likely in the following circumstances: poor suturing, particularly with catgut (11.8), missed repair of the posterior rectus sheath, infection either in the wound or from generalized intra-peritoneal sepsis, a chronic cough, constipation, ascites, HIV disease, advanced malignancy or malnutrition.

Incisional hernias are, however, avoidable! They are, by definition, lumps or bulges under the scar of a previous abdominal incision. If they grow very large, the bowel may only be covered by peritoneum and skin, which may be paper-thin and adherent to the bowel itself. If they are long-standing, the rectus muscles may have separated widely, so that the abdominal contents flop outside the belly. The commonest lower midline incisional hernias are not too difficult to repair but often recur if the repair is not done carefully.

Although recurrence is common, strangulation is not, so *do not operate on these hernias unless you have to*, especially if the hernia is large, and below the umbilicus. Obesity makes repair even more difficult.

EXAMINATION. With the patient supine, put your hand through the weakened area in the abdominal wall to feel the size and shape of the hernia. It may be elliptical, or irregular, and there may be more than one defect.

Ask him to raise his head and shoulders off the couch without using his arms. This will fill the sac and show you its true size.

If so, you should be able to repair the hernia without too much difficulty.

MANAGEMENT.

Unless you are experienced, *do not operate on difficult recurrent, large, incisional hernias*, especially with HIV or other systemic disease present (*including obesity*); advise wearing a corset if the hernia is completely reducible and symptomatic.

If you are experienced, you can sew in a mesh (best over the posterior rectus sheath layer (the sublay method): you can use sterilized mosquito netting. Take precautions to prevent infection: if this ensues, you'll have to remove the mesh. You must make sure that the mesh is sutured carefully to the sheath at least 2.5cm beyond the edge of the defect. *Do not put the mesh directly over the bowel* (inlay method), because it may erode into the bowel wall and produce terrible fistulae.

PREPARATION. Encourage an obese patient to lose weight. If there is infected intertrigo, prepare the skin with special care some days beforehand.

ANAESTHESIA. You will need good relaxation, so use subarachnoid (spinal) anaesthesia, or GA with relaxants. While the abdomen is relaxed under anaesthesia, feel the margins of the defect carefully.

LOWER MIDLINE INCISIONAL HERNIA REPAIR (GRADE 2.5)

INCISION. Make an elliptical incision in the long axis of the hernia, wide enough to include a $\frac{1}{3}$ - $\frac{1}{2}$ of the bulging skin, and extending 4cm beyond the defect at each end. Design the ellipse so as to remove the original scar and to produce a new one, without redundant skin or a tense suture line.

Define the margins of the defect. Use sharp dissection to free the peritoneum, and the anterior rectus sheath, from the fleshy fibres of the rectus muscles, which are sandwiched between them. The posterior rectus sheath, which has often been missed out in the previous closure, may have retracted quite a long way laterally.

Control bleeding, which may be troublesome, and try to repair the lower abdominal wall, layer by layer. Make flaps at either side, so that the skin and subcutaneous tissue (if there is any) are undermined for at least 4cm to allow for tension-free closure.

Try to find a plane of cleavage between the peritoneum and the skin, without button-holing either of them. Undermining will be easier if you insert tissue forceps at the skin edge, and ask your assistant to exert traction on them, while you dissect the skin from the underlying sac.

If freeing the ellipse of skin from the underlying hernial sac is difficult, because the hernia is subcutaneous in the centre of the sac, leave the ellipse attached to the sac.

AN INCISIONAL HERNIA

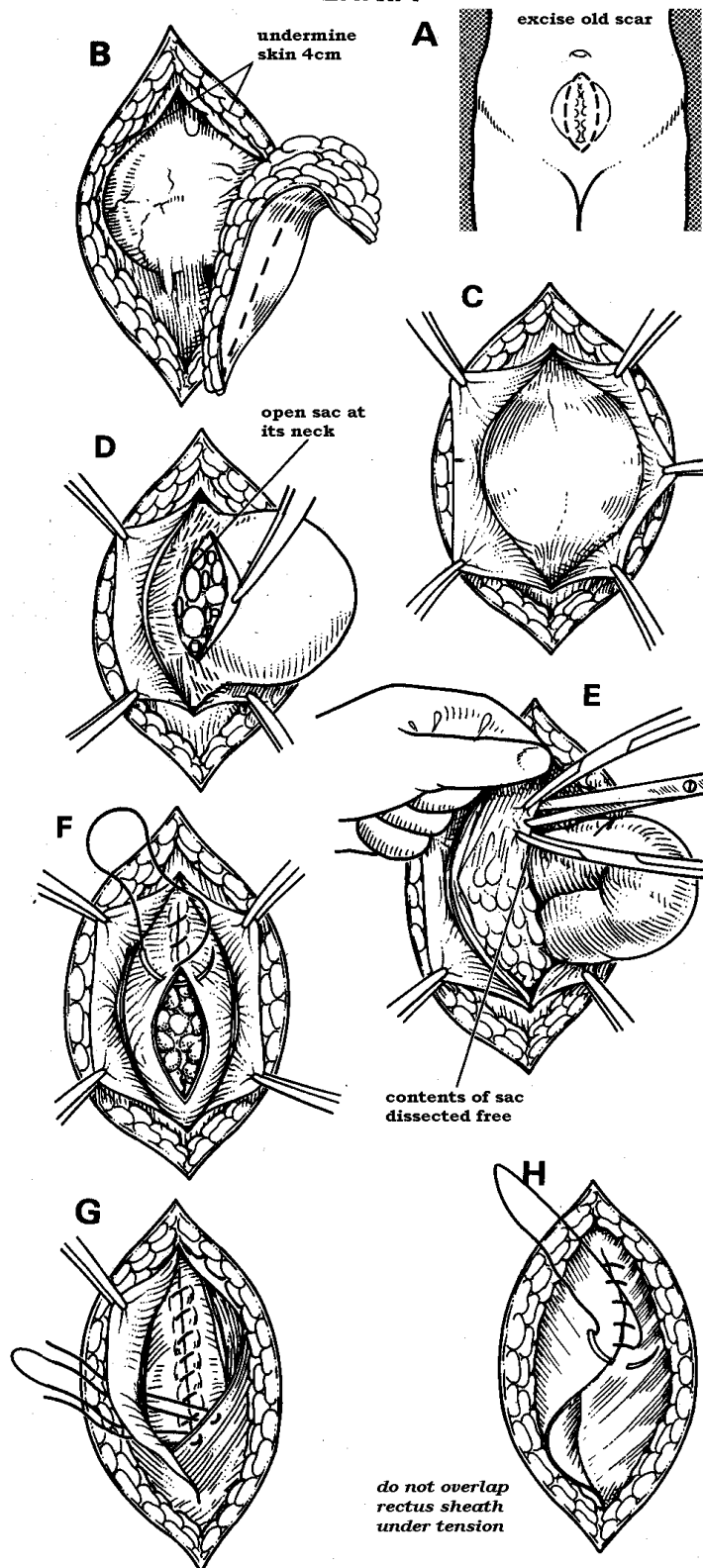


Fig. 18-23 INCISIONAL HERNIA.

A, remove skin ellipse with the old scar. B, undermine skin edge 4cm. C, dissect flaps of stretched aponeurotic tissue from the sac. D, open hernia sac at its neck. E, free adherent contents of the sac. F, close peritoneum and posterior rectus sheath. G, H, overlap anterior rectus aponeurosis. *If there is tension, insert a mesh.*

After Rob C, Smith R. *Operative Surgery: Part I: Abdomen, Rectum and Anus*, Butterworth 2nd ed 1969 p.212 Figs 1-9 with kind permission.

Proceed to raise flaps of scar tissue as described below, and excise the ellipse and part of the sac together. Take care to control all bleeding points carefully.

Raise flaps of aponeurotic scar tissue from the covering of the sac on either side (18-23C)

The neck of the sac will probably be diffuse, and not easy to define. Open it between haemostats, as for a laparotomy (18-23D), and incise the peritoneum far enough to see if there are adherent loops of bowel. Free these adhesions and the omentum (18-23E), and return the bowel and omentum to the abdomen.

If you cannot easily free the bowel and omentum from the fundus of the sac, leave them attached to it; free it from the skin, if you have not already done so, and fold the sac inwards into the abdomen. Check the viability of the bowel (11.3, 11-6), and resect any non-viable part.

Excise the redundant part of the sac (*i.e.* the peritoneum), and close this layer, taking good bites of the retracted posterior rectus sheath with continuous monofilament (18-23F).

Dissect and trim the scarred flaps of aponeurosis, to expose the edges of the rectus muscles on either side. If these have been stretched and thinned out, trim these flaps away to leave a broad strip on one side, and a narrow strip on the other. Overlap these strips so as to bring the rectus muscles to the midline (18-23G).

Otherwise, if they do not come together easily, *do not overlap them*: you must avoid tension in your repair. You can use continuous or interrupted #1 monofilament sutures. Take close small bites making sure you get a suture length-to-wound length ratio of 4:1, and *do not tie the sutures so tightly* that they strangle the tissues. In this way, a double-thickness layer of fibro-fascia will replace the *linea alba*. Insert a few absorbable sutures between the superficial and the deep fascia, in order to obliterate any potential spaces where blood might collect.

Insert a multiple perforated tube through a stab wound, let it lie under the flap, and attach it to a low-grade suction apparatus. Suture the skin edges, apply a firm pressure dressing, and *do not disturb it until the sutures are to be removed*. A many-tailed bandage (an oblong piece of cloth with cut strip tied or overlapped and pinned around the abdomen) will provide physical and psychological support.

CAUTION! If a cough develops postoperatively, it is likely to disrupt the repair. Teach supporting of the wound by pressing the hands on the sides of the abdomen. Use a corset.

DIFFICULTIES WITH INCISIONAL HERNIAS

If you cannot overlap the aponeurotic layers, make parallel relieving incisions 10cm laterally into the sheath only, but beware this is likely to be bloody, so have diathermy ready.

If the defect is so large so that you cannot bridge the defect, you will need to suture in a mesh to close the defect. You can use sterilized insecticide-free mosquito netting; if you do not have any mesh; *do not try to make a repair under tension*.

Put the mesh in under the rectus muscle, but over the posterior rectus sheath (**under-lay method**); you need to dissect the rectus sheath quite far out laterally, inferiorly and superiorly to secure the mesh, and this really needs diathermy. Use prophylactic cloxacillin intra-operatively. Close the mobilized anterior rectus sheath, and advise wearing a corset. *Do not lay mesh directly on bowel*.

N.B. You can put the mesh over the rectus muscle, under the anterior rectus sheath, though this may be very deficient and tempt you to use the mesh as a sort of fill-in graft for the defect (**only method**), this is simpler but much less effective, and if the wound becomes infected, you may end up having to remove the mesh to control the sepsis!

If there is a recurrent incisional hernia, repair is likely to be very difficult indeed. If she is comfortable in a corset treat her non-operatively.

If the pregnant uterus bulges through an incisional hernia, consider doing the repair immediately after delivery, and tying the tubes.

If there is a persistent wound infection after a mesh repair, remove the mesh. Sometimes this gets 'swallowed' by intestine, resulting in a fistula: you will then have to resect the affected portion of bowel as well as removing the mesh: this is difficult surgery!

PERISTOMAL HERNIAS

Stomas inevitably leave a weak area in the abdominal wall, through which bowel may herniate either alongside the stoma itself, or into the layers of the abdominal wall. If the weakness in the abdominal wall is just a bulge, owing to weakness of the muscles themselves, *do not attempt any repair* (11.6). If there is a true bowel herniation, you will probably need to re-site the stoma and repair the old defect. Make sure you select the new stoma site carefully pre-operatively (11.5)

Perform a formal laparotomy; start by mobilizing the stoma as for its closure (11-16) till it is free, then deal with the herniated bowel, and finally re-fashion a new colostomy at the new site, making sure you have mobilized the bowel enough to reach its new position. Then carefully close the old stoma defect layer by layer.

You may be able to approach the defect extra-peritoneally and repair it successfully by dissecting around the stoma: this is difficult, and to be effective, probably needs insertion of a mesh.

OTHER INCISIONAL HERNIAS

Any abdominal incision repair may give way and result in herniation, but this is very rare indeed in Pfannenstiel or Kocher's (subcostal) incisions; an appendicectomy incision (grid-iron or Lanz) (14.1) may leave a small defect through which bowel may herniate. This needs repair because strangulation can occur suddenly.

The lumbar incisional hernia found after operations on the kidney through the flank, however, rarely needs repair.