

# 32 Orthopaedics

*N.B. Trauma is dealt with in volume 2*

## 32.1 Muscle & joint contractures

A contracture is a deformity which prevents the movement of a joint through its normal range. Structurally, contractures are the result of shortening of the soft tissues of a limb, and/or tightening of the ligaments of a joint. This can happen as the result of:

- (1) Ischaemia, which can occur in compartment syndromes due to neglected crush injury, burns, tourniquets, or snake bite.
- (2) Soft tissue or bony injuries, especially burns and fractures,
- (3) Neuropathies, including leprosy,
- (4) Poliomyelitis, and other lesions affecting peripheral nerves (lower motoneurone), which weaken one muscle group more than another,
- (5) Spastic paralysis of an upper motor neurone lesion, *e.g.* after a cerebrovascular accident (stroke), cerebral birth injury, encephalitis, or any head injury,
- (6) Osteomyelitis (7.2),
- (7) Arthritis (7.16),
- (8) Soft tissue infections (6.22) and other unknown causes, *e.g.* Dupuytren's contracture (34.2)

That 'prevention is better than cure' is never more true than with contractures. If a joint is to remain useful, it must move regularly through its full range. Anything which prevents it from doing this eventually causes a contracture. The soft tissues surrounding a disused joint become shorter, and less elastic, and its muscles waste and will not extend normally.

Ultimately, its bones change their shape, and become deformed; it lacks a full range of movement, or becomes fixed near one end of its range, usually flexion.

The two important principles in prevention are:

- (1) Most importantly, to keep all joints moving whenever you possibly can. For example, a patient lying prone for several weeks, may keep the elbows flexed, and never move them. The result will severe contractures in both elbows, which were perfectly normal on admission. A burnt child may develop contractures in joints unaffected by the burns simply because he did not move them. Contractures like these happen quite unnoticed, and when you do notice them, *it may be too late.*
- (2) When movements are temporarily difficult, or inadequate for any reason, prevent deformity by splinting or skin traction, as with the burnt child.

Treatment starts with a careful assessment, so begin by deciding:

(1) **Which tissues** are causing the contracture? If the joint is merely stiff, exercising it should not be too difficult. If only the skin, subcutaneous tissues, and muscles are involved in a contracture, you should be able to release them.

Contractures involving the tendons, or nerves (as in the popliteal fossa), are more difficult. Involvement of a joint can be due to:

- (a) Mild or dense adhesions.
- (b) Shortening of capsule or ligaments.
- (c) Destructive changes, as the result of past infection.
- (d) Ankylosis (fixed joint due to fibrous or bony tissue growth).

If the bones are deformed, an osteotomy will be necessary.

(2) **What range of movement** is there in the joint? Record the movement still present.

(3) **How much power** is there in the muscles? This is important if there is a lower motor neurone lesion, such as that following polio, or an upper motor neurone lesion as the result of spinal cord injury.

**Muscle power** is graded from 0 to 5. The important grade is 3, because this is the grade at which a muscle is just able to do its work against gravity. It varies with the muscle; the quadriceps, for example, has to lift a heavy leg against gravity, whereas the extensor of the little finger has only a finger to lift. Any muscle which can lift its part of a limb against gravity, must have a power of at least 3. Charting is difficult to do accurately (32-1), especially in young children. In an older patient tremors, rigidity owing to Parkinsonism or a patient pretending disability can easily deceive you.

Try non-operative methods first. You have several choices:

- (1) You can use active and passive movements. These might seem the simplest, but they need a determined physiotherapist, or someone, such as a nurse, with some physiotherapy training.
- (2) You can apply skin or skeletal traction.
- (3) You can manipulate a joint.
- (4) You can apply serial corrective casts. Manipulation and casts can often be usefully combined. For example, you can manipulate a joint, and then apply a cast almost at the limit of its range of movement. Later, you can manipulate the joint again, and replace the cast with another one, in which the joint is nearer to the limit of its normal range of movement. If manipulation is to be thorough, you will have to use GA. The danger is that, during manipulation, a joint may bleed, or a contracture split and ultimately cause more adhesions. You can easily break a bone when you manipulate it, so follow the instructions we give, which are designed to prevent this happening. You can also introduce an angle in a cast, by putting in a wedge, and combine it with manipulation by applying a ratchet.
- (5) You may be able to release soft tissues surgically. Polio contractures are easier to release than the contractures which follow burns, because there is less scar tissue, and no skin loss.

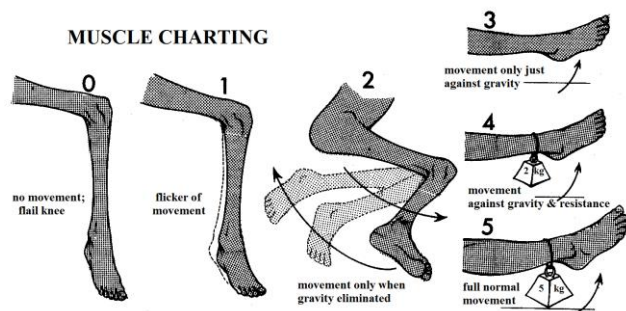


Fig. 32-1 MUSCLE CHARTING.

Grade 3 is the critical level, because this is the grade which allows a patient to lift the limb against gravity. You can test all other muscle groups in the same way. Kindly contributed by Ronald Huckstep

## PREVENTING CONTRACTURES IS EASIER THAN TREATING THEM

PREVENTION. Most contractures can be prevented by:

- (1) Putting the joints through their full range of active and passive movement, several times a day, as with paraplegia. This is such a simple measure; yet it is so often forgotten. You may not have physiotherapists, but this is something that all nurses can do; so, show them how.
- (2) Appropriate splinting, as for burns, tuberculosis of the knee (32.3), or a radial nerve palsy (causing wrist drop).
- (3) Skin traction for burns.
- (4) Early movements in bone and joint injuries, as with Perkins extension traction using a Steinmann pin through the upper tibia.
- (5) Early drainage of pus, as with septic arthritis of the hip, which readily causes a flexion contracture (7.18).
- (6) Early grafting of wounds and burns over joints.
- (7) Early manipulation and immobilization, as for neonatal club foot (32.10).

Practice several of these preventive measures at the same time: e.g. combine splinting with active and passive movements.

In polio, start to assess the power of the muscles (32-1) as soon as tenderness allows, usually about 3wks after the start of paralysis. Assess the degree of recovery regularly, you will then be able to judge how far full recovery is likely. The joints must be stretched in the direction opposite to that in which a contracture might form, preferably qid (e.g. stretch an *equinus* ankle contracture dorsally, 32.9). Fit a calliper (32-13), as soon as the tender muscles will allow. In the acute stage, leave this on for most of the day and the night. Or, use a plaster gutter splint. After 3months from the onset of paralysis, you will know whether long-term callipers are necessary or not.

## ASSESSMENT

Where relevant, make the assessment lying, sitting, standing, and walking. Remember that abduction is movement away from the midline, and adduction is movement towards it. *Varus* is a deformity where the distal part is more medial than it should be and *valgus* (32-11A) where the distal part is more lateral.

In an *equinus* deformity of the ankle the foot points downwards, like that of a horse, in a *calcaneus* deformity the foot points upwards so that the calcaneus bone is pointing downwards.

**RANGE OF MOVEMENT.** In the anatomical position all joints are at 0°, so record the movement there is from this position, and state whether they are active or passive.

For example, the range of movement for a normal hip could be: flexion 0°/120°, that is from 0° to 120°. Its other movements might be extension 0°/10°, abduction 0°/40°, adduction 0°/30°, external rotation 0°/60°, internal rotation 0°/30°. 'Normal' people vary somewhat.

A patient with a flexion contracture might have: flexion 30°/110°, extension -30°/-30° (this means that there is no extension in the hip, movement starts at -30° of extension and ends there), abduction 0°/20°, adduction 0°/20°, internal rotation 0°/10°, external rotation 0°/40°. This means that the hip is flexed, but will not extend at all; it will flex a bit more, but not as much as normal. In other directions its movements are slightly limited.

## MUSCLE POWER:

Grade 0	no power, not even a flicker.
Grade 1	a flicker of movement, but no more.
Grade 2	movement with gravity eliminated.
Grade 3	movement is just possible against gravity.
Grade 4	movement is possible against gravity and some resistance.
Grade 5	full normal power.

**PARTICULAR JOINTS.** A contracture of one joint can affect movement in another, so take this into account.

**Hip.** If you are assessing a flexion contracture of the hip, flex the other hip as far as it will go. This will correct any lumbar lordosis, which may disguise as much as 60° of fixed hip flexion. Extend and abduct the hip, because a tight adduction contracture may be responsible for most of the deformity.

**Knee.** If you are assessing a flexion deformity of the knee, do so with the hip in both neutral and the flexed positions. Assess a *varus* or *valgus* deformity from the line of the shaft of the femur. Assess backward, or lateral subluxation of the tibia on the femur as mild, moderate, or severe. Assess external rotation of the tibia on the femur with the knee extended as much as possible. Be careful to assess whether an immobile stiff straight knee may be more of a hindrance in a rural setting than a fixed flexed knee.

**Ankle.** If you are assessing an *equinus* deformity of the ankle, do so with the knee flexed and extended, because this will help in deciding management. If the deformity is in the ankle joint, it will be the same whether the knee is flexed or extended. But if the deformity is in the *gastrocnemius* muscle (35-20B), which spans both knee and the ankle, as in polio, the range of movement in the ankle will vary with the position of the knee. So, if this is short, an *equinus* deformity of the ankle will be less if the knee is flexed, than if it is extended, because the *gastrocnemius* is not being stretched by an extended knee.

## RADIOGRAPHS.

If you think the contracture involves more than muscle, X-ray the bones and joints involved. Look for: deformity of the joint surfaces, evidence of active disease, and the degree of osteoporosis.

## TREATMENT FOR CONTRACTURES

The need for treatment usually means that prevention has failed. Intervene when contractures result as a result of burns (34.2), polio contractures (32.7,8) and paraplegia.

## ACTIVE AND PASSIVE MOVEMENTS FOR CONTRACTURES

These may gradually stretch shortened soft tissues and correct the deformity. If possible, encourage active movements, or alternatively passive movements (done by someone else). Most useful are assisted active movements: (1) Support the limb while the patient gently moves it himself. This eliminates gravity and gives him a greater feeling of security.

(2) At the extremes of movement use a little passive movement in addition to active movement. Chart the range of its movement weekly.

## TRACTION FOR CONTRACTURES

If satisfactory correction is not possible by exercises alone, consider skin, or skeletal traction.

## MANIPULATION FOR CONTRACTURES.

This is often combined with casting.

## INDICATIONS.

- (1) Joints in which active and passive movements or traction have failed, or are not possible because the deformity is too great.
- (2) Hip contractures of  $<45^\circ$
- (3) Knee contractures of  $<30^\circ$ .
- (4) Ankle contractures of  $<20^\circ$ .

**METHOD.** Press firmly for at least 5mins in a direction opposite to that of the contracture. If necessary, repeat the manipulations every 2wks.

**CAUTION!** Before you begin, remember that a bone which has not been moving is osteoporotic and breaks easily. To prevent this, reduce the leverage that you can exert, by holding the bones close to the contracted joint (32-2).

## HIP.

Flex the opposite hip to eliminate a lumbar lordosis (bent back). Press the upper  $\frac{1}{3}$  of the thigh backwards, to bring the leg down on the table in slight abduction. This will also stretch the adductors, which will probably be tight.

Laying the patient prone is a very useful nursing procedure for preventing and treating flexion contractures of the hip. If tolerated, use the prone position with a pillow under the lower thigh. This uncomfortable position is more acceptable if the head faces towards the middle of the ward, rather than the wall.

## KNEE.

Hold the knee close to the joint; otherwise you may break the tibia or the femur, displace the epiphyses, or sublux the tibia on the femur.

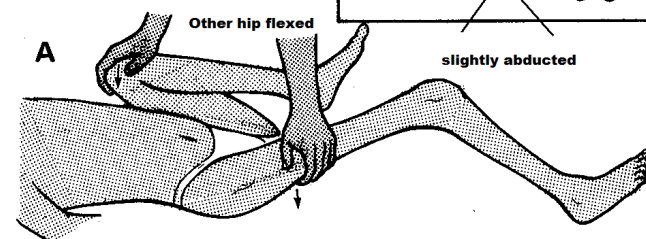
**CAUTION!** Do not try to release contractures of the knee too forcibly; you may injure the popliteal nerve, or damage the joint.

## ANKLE.

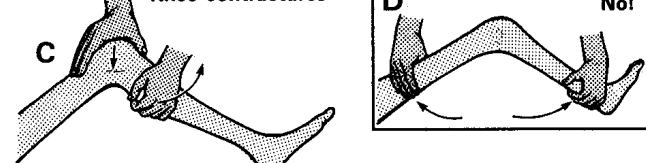
If there is an *equinus* deformity, support the ankle, and firmly dorsiflex the foot. If there is a *varus* deformity, or an adduction deformity of the forefoot, be especially firm and gentle. Do not push up the forefoot only; this may merely extend the mid-tarsal and tarso-metatarsal joints, without extending the ankle.

## MANIPULATING CONTRACTURES

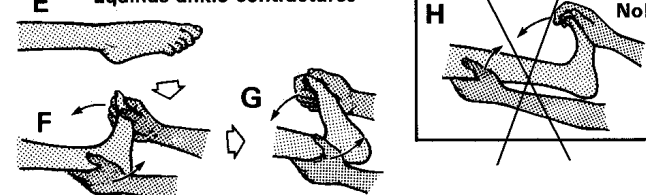
### Hip contractures



### Knee contractures



### Equinus ankle contractures



### Varus foot

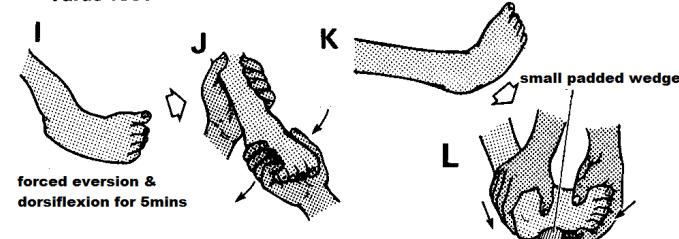


Fig. 32-2 MANIPULATING CONTRACTURES.

When you manipulate a joint under anaesthesia, always exert pressure close to a joint, or you may break a bone or displace the epiphyses. A, when you manipulate the hip, flex the opposite hip, and grasp the thigh. Push it down in extension and slight abduction. B, do not push down on the knee! C, exert pressure near the knee, and not as in D! For an equinus deformity of the ankle (E), grasp it near the ankle, and dorsiflex it. (F, and G), not as in H! For a varus deformity of the foot (I), evert it and dorsiflex it for at least 5mins. (J). Manipulate an adduction deformity of the forefoot firmly and gently over a wedge (K,L). Kindly contributed by Ronald Huckstep.

## CASTING FOR CONTRACTURES.

Apply a well-padded plaster cast, close to but not at the extreme range of movement of the joint. If you do, pressure on its cartilage may cause necrosis and osteoarthritis later. So let it relax a little, before you apply the cast. A few weeks later, if necessary, manipulate the joint again, and replace the cast with another one, in which the joint is nearer to the limit of its normal range of movement.

**CAUTION!**

(1) *Never put a joint, especially a knee, into a cast under tension.*

(2) *Do not wedge a cast to correct a knee contracture.*

Both mistakes may cause an early painful osteoarthritis, in what was previously a painless mobile joint. These are both very important rules. Fortunately, osteoarthritis and painful joints are rare in polio; it is tragic to create them unnecessarily.

**OPERATIVE METHODS FOR CONTRACTURES**

You can release the soft tissues if there is a burns contracture or Dupuytren's (34.2). If there is polio, you can release the tendons of the ankle (32.9), the knee, or the hip (32.8). If the contracture is severe and long-standing, try to arrange a release combined with a myocutaneous flap, or by an osteotomy.

**CONTRACTURES CAN FORM IN A FEW DAYS****32.2 Managing leprosy paralysis**

The best way to deal with leprosy is to recognize it early, and treat it adequately. If this fails, surgery is necessary, because leprosy affects the nerves. Destruction of their sensory fibres makes the surface of the body anaesthetic, and thus liable to injuries that result in open wounds and ulcers. Destruction of their motor fibres causes paralysis, wasting, and sometimes contractures of the muscles. Most nerves are mixed, so that both things happen at the same time, with the result that the arms and legs become paralysed and anaesthetic. Because there is little sensation of pain, injury is not noticed. This results in neglect of the painless surface injuries, so that they become steadily progressive ulcers. The contractures, ulcers, and deformities that result are not an inevitable part of leprosy. In a well-conducted leprosy program, there should be few such complications when patients first present, and none later.

Leprosy most commonly involves the legs, but it can also involve the hands (32.18) and the eyes (28.17). Pyogenic organisms readily enter through the lesions that leprosy causes in the skin, so that you may need to drain abscesses (6.2), treat bone, joint, and tendon sheath infections (8.12), and enucleate the eye when its globe has become infected (28.14). Admit leprosy patients to the general ward. If your staff behave naturally towards them, other patients will do so too. Leprosy is not contagious and not particularly infectious.

Obtain a firm diagnosis with a split skin smear made from 6 sites (ear lobe, forehead, buttock, arm, knee and suspect lesion). Clean the skin fold with alcohol, pinch it to reduce blood flow, and incise it with a sterile blade. Turn the blade through 90° and scrape the skin, putting tissue on a slide and staining it by the Ziehl-Neelsen method. Examine using a x100 oil immersion lens and grade smears as paucibacillary or multibacillary.

Follow WHO treatment guidelines:

Type of Leprosy	Monthly supervised dose	Daily dose	Duration
Paucibacillary (TT)	Rifampicin 600mg	Dapsone 100mg	6 months
Multibacillary (LL)	Rifampicin 600mg + Clofazimine 300mg	Clofazimine 50mg + Dapsone 100mg	12 months or more
Paucibacillary (TT) single lesion	Rifampicin 600mg + Minocycline 100mg + Ofloxacin 400mg		single dose

Surgically, your task is to:

- (1) Care for the primary and secondary impairments.
- (2) Set and record measurable objectives for preventing and limiting the disabilities, and plan how you are going to reach them.
- (3) Provide protective footwear and aids.
- (4) Teach self care to prevent further disability.
- (5) Teach the rest of the health care team how to do these things. Most leprosy work should be done by paramedical workers, and the present trend is for vertical programmes, with a specialized cadre of leprosy assistants, to be replaced by horizontal ones which manage many diseases. Much of what is described here can be done by paramedics, if you teach and encourage them.

If patients have good T-cell immunity, they get a milder disease, tuberculoid (TT) where the nerves are involved early as in borderline tuberculoid (BT) leprosy, and later and less severely in lepromatous (LL) leprosy. Here there is poor T-cell immunity and the presence of nodules & plaques. This involvement can be slow, progressive, and irreversible, or can occur suddenly in a Type I reaction.

Paralysis, whether slow or sudden, involves the nerves selectively:

- (1) the facial nerve, so that the eye does not close (lagophthalmos).
- (2) the ulnar nerve at the elbow or wrist, so that the hand becomes clawed.
- (3) the median nerve at the wrist, so that the thumb cannot be opposed.
- (4) the radial nerve, so that the wrist drops (in the arm, the ulnar nerve is most often affected, then the median, then the radial).
- (5) the lateral popliteal nerve at the neck of the fibula, so that the foot cannot dorsiflex and so there is a 'foot drop'.
- (6) the posterior tibial nerve behind the ankle, so that the intrinsic muscles of the foot become paralysed, the toes clawed, and the sole anaesthetic.

Both kinds of lepra reaction can cause paralysis, but need different management:

**Type I lepra delayed hypersensitivity reactions** (reversal) often cause sudden reversible paralysis in treated borderline forms, BT, BB, BL (immunologically unstable) leprosy. They make all the leprosy lesions in the skin and nerves swell acutely. The nerves become suddenly paralysed, and feel large and soft. They may be painless, or tender. Skin lesions may ulcerate, and resulting fibrosis may lead to contracture, unless you start physiotherapy.

Suppress these reactions with prednisolone 40mg od (or 60mg od in severe cases) for 2wks, or as long as there is activity. Then as soon as the acute stage has subsided, reduce the dosage by 5mg monthly, even if there is no sign of nerve-function returning. The total duration of treatment takes 6 months but may be more in BL patients.

**Type II 'erythema nodosum leprosum' (ENL) reactions** occur in LL and BL patients. During 2-3hrs a crop of painful erythematous papules develop, typically on the extensor surfaces of the limbs, but in severe attacks over much of the body except the scalp. The skin may be thickened, especially over the backs of the hands and on the legs, where contractures may form. There is a high fever, malaise, headache, and anorexia with uveitis, swollen joints and testicles. Meanwhile, the nerves are painful, and become steadily paralysed. Unfortunately, they are less likely to recover than after a Type I reaction. ENL frequently recurs, even up to 7yrs. Suppress a severe reaction with prednisolone 60mg od, reduced rapidly within 2-4wks. Treat mild reactions with aspirin. Use thalidomide 10mg/kg for recurrent reactions, reducing to 100mg od (but *remember this drug is teratogenic!*). Use clofazimine 300mg od for maintenance once the acute phase has settled, reducing by 100mg every 2 months.

Continue antileprotic drugs in both types of reaction. The nerves may start to recover within 3wks, or they may not improve for 3 months, or a year, or longer. Meanwhile, manage them as described below.

#### PHYSIOTHERAPY IN LEPROSY

A limb which is paralysed by leprosy needs physiotherapy to strengthen its muscles and prevent contractures, especially if paralysis is recent, actively progressing, or possibly only temporary, as in either type of leprosy reaction. As long as there are signs of weakness, someone, or preferably the patient himself, must put all the paralysed joints through their full range of movement each day, even if they cannot be actively maintained in their positions of function.

Protect the paralysed muscles by splinting the joints in their positions of function during sleep, and never allow a muscle to be overstretched. Make sure active exercises continue in order to retain mobility in all the joints. Even if all the intrinsic muscles of the hand are paralysed, it will still be more functional if its joints are kept mobile with daily exercises. Start this protection the first day you diagnose a reaction.

When there are signs of recovery, as shown by pain decreasing, nerves becoming softer, and sensation and motor function returning, the patient must increase the range of active movement and strengthen the muscles with carefully graded active exercises; and practise any skilled coordinated movements that he will need later when he returns to normal life. Start exercises as soon as the acute symptoms of neuritis have subsided. Begin by doing each exercise 5 times, increasing to a maximum of 30 times, repeated 3-5 times daily.

Teach the exercises for the patient to do himself at home: but if you plan reconstructive surgery, he may need more intensive activity.

### 32.3 Tuberculous bones and joints

When TB involves the skeleton, it is the involvement of the joints that matters most: the spine, hips, knees, feet, elbows, wrists, and shoulders, in this order of frequency, and occasionally other joints also. Bacilli reach the joints usually from some focus elsewhere. So look for lesions in the lungs, and for signs of TB in other parts of the body, especially lymph nodes (17.4).

The patient is usually a young adult, or a child >6yrs, although children as young as 1yr and older people can also be infected, especially with HIV disease. One or more of the joints has become progressively painful and stiff during the previous few weeks. If the leg is involved, the first complaint is a limp. The infected joint fills with fluid, and the muscles round it waste. There is usually only mild to moderate pain, except on forced movement. Tuberculous arthritis is 'cold', which means that the skin over the infected joint is the same temperature as the normal skin. (The joint is not 'hot', as it is in septic arthritis). Sometimes there are systemic symptoms, such as mild fever, night sweats, or loss of weight or appetite. Pain and fever may be quite marked. There may also be signs of tuberculosis in the chest, or a family history of it.

In a synovial joint (or diarthrosis, where the fibrous joint capsule is continuous with the periosteum), the disease starts within the synovium and spreads slowly over the cartilage; it then extends through the cartilage into the underlying bone, which decalcifies. In the spine, disease starts in a disc. If you start treatment before the cartilage is destroyed, the joint will recover fully, or nearly so. If you start later, the articular cartilage will be destroyed, so that even if the disease is arrested, the joint will develop a fibrous ankylosis (except in the spine, when ankylosis is always bony, 32.1). Sometimes, cold abscesses form, become secondarily infected, and may track for a considerable distance to produce a sinus far from the original lesion. If a tuberculous joint is secondarily infected, the ankylosis that results is always bony. The diseased limb develops a flexion contracture, and its joints may subluxate or dislocate, especially the hip, knee, shoulder, or elbow.

You can treat tuberculous joints successfully and cheaply; if you make the diagnosis in the first few weeks. But even if treatment starts late, when joint surfaces have already been destroyed, you can expect a fairly good result, if you can prevent deformities and contractures.

There are no certain diagnostic signs, so the secret is always to be suspicious. Whenever you see any chronic bone or joint disease, ask yourself whether this could be TB. Taking an aspirate or biopsy of a node or the synovium will confirm the diagnosis in about 50% of cases.

If you cannot send tissue for biopsy, you will probably have to rely on the characteristic radiographic changes. Even so, your error rate is likely to be small. Try to:

- (1) Use the drugs needed in adequate doses for an adequate period: much the most important.
- (2) Rest the joint; if the arm is involved, you can usually treat it in a sling, but if there is tuberculosis affecting the leg, you will need to provide in-patient care.
- (3) If there is disease of the hip or knee, apply traction. This will overcome spasm, prevent the softened bone from collapsing, and keep the inflamed joint surfaces apart. You may have to refer to experts to remove or drain a tuberculous lesion, or promote ankylosis.

## TUBERCULOUS ARTHRITIS

**RADIOGRAPHS.** Look for:

- (1) Generalized rarefaction: the whole joint is less dense than it should be. The earliest stage is a lack of definition; the joint is not as sharp as it should be.
- (2) Localized areas of erosion or decreased density, caused by caseous lesions in the bone.
- (3) Abnormally narrow or wide joint space.
- (4) Irregular joint space, in late cases.

**CAUTION!** *Joint destruction in TB is always more severe than the radiographic appearances suggest.* Remember to X-ray the lungs.

## SPECIAL TESTS.

- (1) A +ve tuberculin test is only of limited value (5.7).
- (2) If a joint is swollen, aspirate it (7.17), and examine the fluid. With great patience, you may occasionally find AAFB's in a stained film of the exudate.
- (3) If there is any enlarged lymph node that might be tuberculous, aspirate (17.2) or biopsy one. Biopsy of synovial tissue is indicated in special cases only. Taking a biopsy from the spine is difficult, but you may be able to take one from the hip. Use the anterolateral approach, as for septic arthritis (7.18). Biopsy the knee (7.16). When you take a biopsy, use the opportunity to examine the articular cartilage. A biopsy is useful for distinguishing tuberculosis from late, imperfectly-treated staphylococcal arthritis.

**CAUTION!** Biopsies are fallible, so accept a 'negative' biopsy result with caution. About 50% of cases of tuberculous synovitis are reported as 'non-specific chronic inflammation'.

## DIFFERENTIAL DIAGNOSIS.

**Suggesting septic arthritis (7.18):** a history of onset over hours or days, not weeks; a 'hot' joint, which is acutely painful to move in any direction. There is a high fever with a leucocytosis. Aspiration produces frank pus, rather than slightly cloudy fluid. Bacteria (usually *staphylococci*) are visible in a Gram-stained film. If septic arthritis has been partly treated, diagnosing it may be difficult. If the hip is involved, flex the knee to 90° and then flex the hip. If the leg moves into external rotation, as you do this, (7-17), it is a sign that the upper femoral epiphysis is slipping. This is much more likely to happen in septic arthritis (or spontaneous slipping of the epiphysis, than in TB.

Both tuberculous and septic arthritis eventually involve pelvic bone. If it is already involved when you first see the patient, this suggests tuberculosis.

**Suggesting trauma:** a history of injury, a haemarthrosis: the radiograph may be normal, or showing widening of the joint.

**Suggesting other forms of arthritis:** a history of dysentery, brucellosis, or gonorrhoea.

**Suggesting HIV-disease or rheumatoid arthritis:** presenting in a single joint; looks like tuberculosis, but tests are often non-specific. Other joints may flare up later. If possible, take a biopsy, aspirate fluid for a PCR test. *Remember that TB is commoner than mono-articular rheumatic disease in most parts of the world.*

**Suggesting Perthes disease (32.14), or a slipped epiphysis:** the patient is a child and the hip is involved. Look for unavoidable passive external rotation of the hip when the patient tries to flex it (Drehmann's sign: 7-17)

**Suggesting osteoarthritis:** in the old, or with a previous injury; look for osteophytes, areas of increased density (eburnation), and sometimes associated cysts (especially in the hip).

## TREATMENT

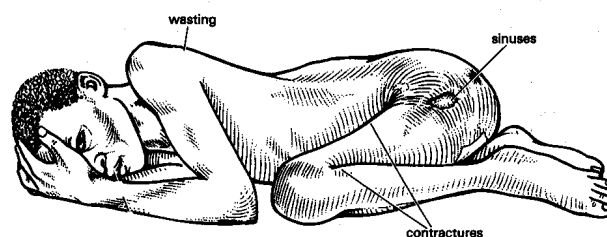
Admit the patient in order to:

- (1) Confirm the diagnosis.
- (2) Advise that the disease is curable, but that this needs long-term treatment.
- (3) Apply traction to the lower limb, if this is needed.
- (4) Start standard TB therapy (5.7) and screen for HIV disease. Do all you can to continue treatment to the end. Review regularly. When the course of treatment is completed, warn that the joint may flare up again at any time. If so, further treatment will be necessary.

**POSITION OF FUNCTION.** The range of movement of the joint may be limited or absent, so make sure that it is kept in the position of function (7-16).

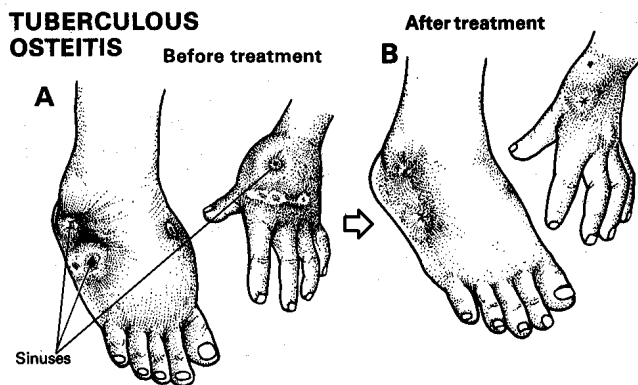
**ANKYLOSIS.** A fibrous ankylosis may be acceptable, even in the leg, especially in a child. It is also acceptable in the arm, provided it is near the optimum position of function.

## UNTREATED TB OF BOTH HIPs



**Fig. 32-3 NEGLECTED TUBERCULOSIS OF BOTH HIPs for 29yrs.** This patient could not even crawl. He dragged himself along in a sitting position, with both knees and hips fully flexed. *Kindly contributed by Ronald Huckstep.*





**Fig. 32-4 TUBERCULOUS OSTEITIS** in this patient improved rapidly on TB treatment, and the sinuses healed.  
*Kindly contributed by Gerald Hankins.*

#### PARTICULAR JOINTS INFECTED BY TUBERCULOSIS

**SHOULDER.** Aim for a loose fibrous ankylosis. Rest the arm in a sling, and then gradually encourage movements without it. If this is still painful at the end of treatment, refer him; an arthrodesis is necessary. This will not be a significant disability because of remaining scapulo-humeral movement.

**ELBOW.** An elbow fixed in the position of function (7-16), is likely to be better than a stiff painful one. If non-operative treatment fails to produce a pain-free elbow, an excision/arthroplasty is necessary. This will provide a considerable range of movement, but little stability. Fusion is rarely necessary.

**HIP.** In children presenting with a painful hip or a limp (32.14), symptoms may start slowly, but ultimately become serious with severe illness, and painful restriction of the movements of the hip. To begin with it is flexed and abducted; later it is flexed and adducted, the leg is shortened, the thigh is wasted, and there may be abscesses in the buttock or groin. There is loss of joint space, and a characteristically severe rarefaction of the bone round the hip. If possible, aspirate or explore the hip, so as to confirm the diagnosis bacteriologically. Start TB treatment and rest the hip, at first in bed only, and then, when pain is a little less, apply skin traction.

**If there is abscess formation**, and the whole of the head of the femur is necrotic (uncommon in TB), its removal is necessary (7.19).

**If the hip is in spasm** (as diagnosed by rolling the leg), or the hip or knee show any flexion deformity, apply extension traction for 6wks. This will control pain and prevent a flexion contracture.

**If there is only narrowing of the joint space**, and no bony destruction, mobilize, usually after 2months, and allow cautious use of the leg, starting with partial weight bearing, using crutches and a patten (raised shoe) on the normal leg to keep the diseased one off the ground. Skin traction should have corrected any flexion contracture (if present) by this time.

**If there is considerable bony destruction**, especially of the head of the femur, there is still some hope of a reasonably functioning joint. Do not worry about whether the ankylosis is fibrous or bony. Apply skin traction for 3months and then mobilize on crutches.

**If, after 4-6months, there is still a painful joint** with very limited movement or no movement, except under GA (unusual), an arthrodesis of the knee, or of the hip is necessary. Do both operations during the first 2yrs, while the patient is still on TB treatment.

**KNEE.** Presenting with a limp, mild pain, a swollen knee, marked wasting of the quadriceps, limitation of movement (especially extension), and a flexion deformity.

Rest the knee in a straight (Thomas) splint, or by extension skin traction, for at least 3months, and then allow gentle weight-bearing on crutches. Gradually increase this until the patient is walking as well as he can. If the disease is advanced, or if the pain continues, fit him with a long leg plaster cylinder; otherwise avoid this.

**If a child requires an arthrodesis of the knee**, try to delay this until after adolescence, so as not to hinder growth.

**ANKLE.** Apply a short leg walking cast.

**TENDON SHEATHS.** If a chronic swelling of the tendon sheaths of the hand, or bursae round the shoulder develop, do not forget that tuberculosis can also involve any of the synovial membranes.

#### DIFFICULTIES WITH A TUBERCULOUS JOINT

**If the symptoms are mild so that diagnosis is difficult**, you can:

(1) Wait 4-6wks, before committing yourself to long-term treatment, provided you are sure you are not missing acute untreated septic arthritis. During this time some diseases (transient synovitis and rheumatic fever) will settle, while others may reveal themselves (partly-treated septic arthritis). Tuberculosis will not advance much during this time.

(2) Explore the joint, biopsy the synovial membrane, and remove a lymph node for biopsy. An ESR may also be useful.

Alternatively, and less satisfactorily, you can start a trial of treatment with streptomycin and isoniazid for a month. If your diagnosis was correct, the spasm in the muscles round the tuberculous joint will become less, and the general symptoms will improve.

**If you are not sure if there is septic arthritis or tuberculosis**, even after opening the joint, treat for both, and review later when a histological report is available.

**If deformity prevents satisfactory walking**, corrective surgery is essential. If an arthrodesis is needed (more likely in the knee than the hip), it is usually best done 6-8wks after treatment starts.

**If an old tuberculous joint is injured**, observe closely. fibrous ankylosis is always unsafe, and can flare up at any time. If pain and inflammation continue, and there is no bony injury and no ligament rupture, start another full course of TB treatment.

If a **COLD ABSCESS DEVELOPS**, leave it, unless it is very big and is causing pain and discomfort: this mostly settles on TB treatment within 12 months. Aspirate it repeatedly with a wide-bore needle, introducing the needle through a long oblique track, so that a sinus is less likely to form. **If the abscess is very large**, explore it, clear out its contents, and close the wound to prevent the secondary infection.

**CAUTION!** *Do not leave a drain in a cold abscess, as you risk secondary infection.*

**If a sinus develops**, it is the result of an abscess opening on to the skin, and occurs in immuno-compromised patients. Sinuses are rare once TB treatment has started, although an old sinus may re-open up temporarily. TB treatment will usually close it. A sinus may become secondarily infected, but does not require specific treatment. *A biopsy from the track is unlikely to confirm tuberculosis*, because non-specific granulation tissue lines it.

**If a joint becomes warm & tender**, with deteriorating radiographic signs, and there is fever and malaise, this is a flare-up. This is unlikely to happen if the course of treatment is completed, and is a sign that TB treatment has failed. Consider some other disease, such as septic arthritis, gonococcal arthritis, mono-articular rheumatism, or gout.

**If the leg becomes significantly shortened**, provide a shoe-raise.

## ANY CHRONIC JOINT INFLAMMATION IS TUBERCULOUS UNTIL PROVED OTHERWISE

### 32.4 Tuberculosis of the spine

The spine is the most common and the most dangerous site for skeletal tuberculosis.

Symptoms are mild. Infection usually starts in the anterior part of a disc (7.15), and spreads to the adjacent surface of the body of a vertebra, or to two adjacent ones. It seldom involves the lamina. The result is that, as the bodies of the vertebrae collapse, the spine angles forwards to produce a *kyphus* (an increase in the normal convex curve of the spine; a *scoliosis* is a lateral curvature). The shape of the spinal deformity depends on how many vertebrae are diseased. Commonly, as the deformity gets worse, a sharp angle (*gibbus*, 32-5B) appears. Uncommonly, the destruction is not symmetrical, so that the spine rotates. Symptoms are more severe; several of the vertebrae are involved widely in the spine (including perhaps some in the neck), and the disc spaces may not be narrowed.

The first symptom is pain in the back, and the first sign is increasing kyphosis. Later, pus from the diseased vertebrae may track along tissue planes to present as a cold abscess in unexpected places, particularly in the groin (psoas abscess). Paraplegia may develop (32.5). Persistent localized pain at a specific place not relieved by rest or NSAIDs after 4-6 wks should arouse a suspicion of TB.

### TUBERCULOSIS OF THE SPINE

The common presenting sign is backache in an unfit patient. A gibbus is a late sign.

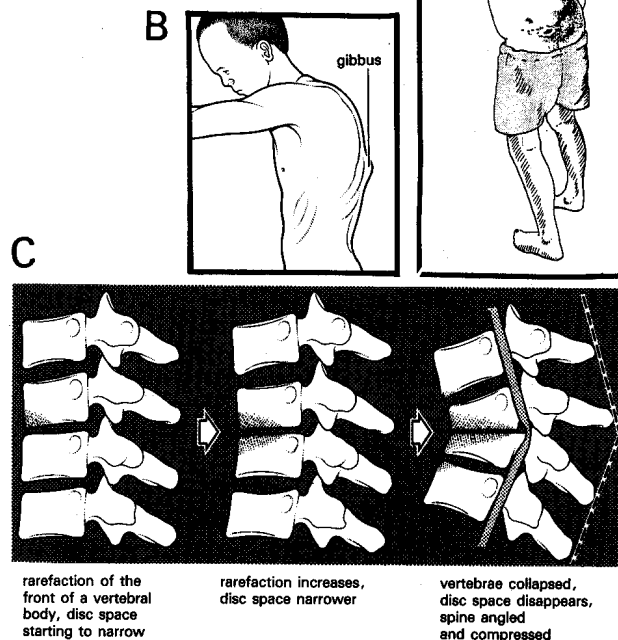


Fig. 32-5 TUBERCULOSIS OF THE SPINE.

A, boy from Nepal. B, another patient with a *gibbus*. Note that in both se patients the lower thoracic region is involved (the common site). C, radiographic signs (see text).

A, kindly contributed by David Nabarro.

In a child spinal tuberculosis is an important cause of back pain, especially if associated with malaise and weight loss. There may be tenderness over the low thoracic or upper lumbar spine, and any of the signs seen in adults.

Start TB treatment as an outpatient, without applying a plaster jacket.

**Idiopathic kyphoscoliosis** is one of the differential diagnoses of a tuberculous spine. It is a disease of unknown cause, in which a child's spine slowly develops a curve. It may start as early as 3 yrs, but it more often starts at 7-8 yrs; it progresses most rapidly from 12-14 yrs, and gets worse until he stops growing. If possible, fit a back (Milwaukee) brace, and if necessary get the spine fused at the appropriate time. If this is not possible, reassure the parents that, although the back will always be bent, spinal compression is rare, but a moderate or severe lesion will affect the function of the lungs by reducing the size of the thoracic cage.

#### EXAMINATION

Examine from the side; look and feel for:

- (1) a *kyphus*,
- (2) reduced movement of the lumbar spine,
- (3) cold abscesses in the neck, paraspinal area, lumbar region and groin,
- (4) sinuses.

Test the reflexes in the legs, and their tone, power, and sensation (32.1,6).



Look in the throat for a retropharyngeal abscess (6.8).

RADIOGRAPHS are critical (32-5). Remember to get chest films too. Look for:

(1) Narrowing or obliteration of a joint space, involving at least 2 vertebral bodies and the disc between them (this is the typical late picture). Sometimes several vertebrae disappear into the space normally occupied by only 1 or 2. So count the vertebral spines, because these may be all that is left when the vertebral bodies have been destroyed.

(2) Look for forward collapse of the spine.

(3) You may also see the shadow produced by a paravertebral abscess in the thoracic region (this strongly suggests tuberculosis, but it can be produced by staphylococcal and other forms of bacterial osteitis), and calcification in the psoas sheath, showing that a psoas abscess is forming. Evidence of a paravertebral abscess increases the probability of tuberculosis being the cause, but is not necessary for diagnosing it.

(4) Osteophytes and bridging (rare). If you do see bridging, it is more likely to be due to late staphylococcal infection.

#### SPECIAL TESTS.

ESR may be very high. A falling ESR is a useful indication of response to treatment, but is less important than an improvement in the clinical condition, as indicated by decreasing pain and tenderness. Aspirate accessible abscesses with a 14G needle and look for AAFB's.

#### DIFFERENTIAL DIAGNOSIS

**Suggesting pyogenic osteitis or spondylodiscitis (7.15):** a more rapid onset, less bone destruction, and a higher temperature. Confirming the diagnosis may have to depend on the aspiration and examination of pus from the spine, or on costotransversectomy,

**Suggesting poliomyelitis:** weak, wasted, flaccid legs. If polio involves the spine, it is almost sure to involve the legs too. You will see scoliosis rather than kyphosis.

**Suggesting idiopathic scoliosis:** the curve is smooth, with no *gibbus*, or muscle-wasting. Apart from the curved shape of the spine, there are no other signs; the radiographs are normal, and no vertebrae are destroyed. The disease starts in childhood.

**Suggesting a congenital lateral hemivertebra causing scoliosis or dorsal hemivertebra causing kyphosis** (usually mild): half of one of the vertebrae is missing. On a radiograph this is almost triangular, its edges are smooth and well formed, and there are no signs of disc destruction in the vertebra above or below. This kind of deformity does not progress with age, and needs no treatment.

**Suggesting kyphoscoliosis due to lung disease:** a previous history of empyema, other causes of lung fibrosis, or pneumonectomy. When the lung collapses, a collapsed thoracic cage may result. The spine itself needs no treatment.

**Suggesting Burkitt's lymphoma:** a child in endemic areas where this is the commonest cause of paraplegia (17.6).

**Suggesting metastatic disease:** involvement of the bodies of the vertebrae without involvement of their discs. The serum alkaline phosphatase is raised. If the primary is in the prostate, the acid phosphatase and PSA will be raised also.

**Suggesting a senile kyphosis:** an old woman with osteoporosis of all, or most, of the spine, and normal discs, which bulge into the softened vertebrae. The *kyphus* is gradual. Treatment is difficult (32.6).

#### TREATMENT.

Start TB treatment (5.7). Screen for HIV disease. If walking is possible, encourage this. Warn that treatment must continue, and that it will take some months to have much effect. During this time, the kyphoscoliosis getting worse, before it stabilizes. Do all you can to trace defaulters by keeping good records.

#### DIFFICULTIES WITH A TUBERCULOUS SPINE.

**If the cervical spine is involved,** treat with an orthopaedic collar, or failing this, a plaster corset and TB treatment. The spinal canal is larger in the neck than in the thoracic region, so the spinal cord is less likely to be compressed.

**If there is clumsiness, weakness or incoordination,** paraplegia is imminent (32.5).

### 32.5 Tuberculous paraplegia

If a patient with spinal tuberculosis complains of clumsiness, weakness, or incoordination of the legs, paraplegia is imminent. Later, the voluntary power of the legs is reduced, their muscle tone is increased, and the plantar responses become extensor. Later still, there are flexor spasms, and finally contractures.

Paraplegia is the major complication of spinal tuberculosis. In early cases it is due to an inflammatory oedema round a paraspinal abscess, and later to compression. Paraplegia may be the presenting symptom, and is usually treatable. In most cases it is motor only (unless it comes on very rapidly), because the abscess presses on the anterior columns (grey matter, or motor neurones) of the cord rather than on the posterior columns (white matter, or sensory neurones). Although tuberculous osteitis affects the various regions of the spine in the following order of decreasing frequency: low thoracic, lumbar, upper thoracic, and cervical, you will see tuberculous paraplegia most commonly in the thoracic region, sometimes in the cervical region, and seldom in the lumbar region. This is because the spinal canal is wide there, and the *cauda equina*, a loose bundle of nerves & nerve roots from L2-S5 and nerves is less readily affected than the solid cord by TB.

There are 2 types of tuberculous paraplegia:

(1) The common early type is due to inflammatory oedema which responds well to TB treatment, and surgery, if this is necessary.

(2) A less common later type, due to pressure and stretching from a bony deformity, when bony union has not occurred. It is the result of late, incomplete, or no treatment at all.

Its prognosis is poor with TB treatment alone, and even with specialized surgery, it is not good. Obviously if there is untreated HIV disease, and maybe also HIV neuropathy, the prognosis is poor.

PROGNOSIS AND MANAGEMENT are different in the 2 forms of the disease. The bowels and bladder are sometimes involved in later stages; their improvement mirrors that of the limb muscles.

**If the paralysis is fairly recent (<3months) and the deformity is <60°** (common), inflammatory oedema is the likely cause, and if the indications for surgery are followed, the prognosis is good. Even if there is >60° of deformity, this is worth managing as if oedema was the cause, but the prognosis will not be so good.

(1) If the muscle power (32.1) is fair (grade >3), it is almost sure to recover fully.

(2) If the power is significantly weak (grade <3) but without muscle spasms, it will probably recover.

(3) If the power is poor with extensor spasms, there is >50% chance of a full recovery, and if not, there will probably be a partial recovery.

(4) If the power is poor with flexor spasms, you can expect little or no recovery, and there is little chance of walking without special aids.

**If the paraplegia is due to pressure or stretching from a bony deformity of the neural canal** (uncommon in most areas and usually of late onset), the clinical picture is the same, except that the onset of paraplegia is late when kyphosis is marked.

However, even if there is marked bony deformity with no paraspinal abscess visible on radiographs, the paraplegia may possibly still be due to inflammatory oedema, surgery may still be useful but surgery of this kind of paraplegia is difficult. Otherwise give TB treatment alone.

#### TREATMENT FOR TUBERCULOUS PARAPLEGIA

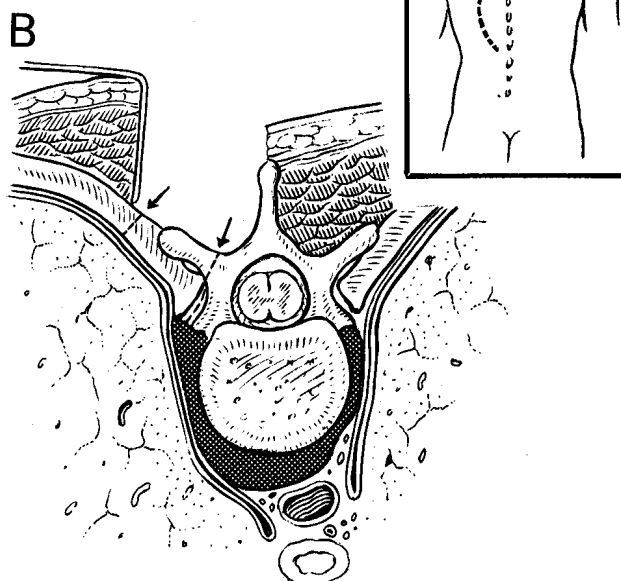
##### NON-OPERATIVE TREATMENT.

If TB treatment (5.7) and bed rest do not cause neurological improvement in 6wks (unusual), review him. Screen him for HIV disease if you have not done so. Your diagnosis may be wrong, but if you are sure that there is TB, consider costotransversectomy.

NURSING CARE is the same as for traumatic paraplegia: so manage the patient's morale, the skin (pressure areas), the urine, and the bowels.

*If you don't do this properly, there is no use in operating!*

## COSTO-TRANSVERSECTOMY



**Fig. 32-6 COSTOTRANSVERSECTOMY** for a tuberculous or a pyogenic paraspinal abscess. A, incision. B, approach to the ribs and transverse processes.

After Campbell WD, Edmonson AS, Crenshaw AH, (eds) *Operative Orthopaedics*. CV Mosby 6<sup>th</sup> ed 1980 Fig. 13.10, with kind permission.

#### COSTOTRANSVERSECTOMY (GRADE 3.3)

##### INDICATIONS.

Osteomyelitis of the spine (7.15).

(1) Paraplegia due to osteitis (usually tuberculous), provided you can demonstrate a paraspinal abscess (tuberculous or pyogenic) on ultrasound or radiography.

(2) A large paraspinal abscess (tuberculous or pyogenic) when there is no paraplegia.

(3) To obtain tissue for histology, when the cause of an osteitis is still in doubt, after considering the clinical condition and the radiographs.

##### POSITION.

Anaesthetize, intubate the patient and lay him prone with the chest supported on pillows, and mechanical ventilation, or lay him in the right lateral position.

##### PREPARATION.

Have 2 units of blood in reserve. Diathermy is useful.

Find the vertebra or vertebrae most markedly involved, by noting the site of any *gibbus*, and examining the radiographs carefully. To make sure you choose the right level, get a radiograph done with a marker placed on the rib selected for removal: leave this marker in place.

##### INCISION.

Make a 10cm incision centred on the affected vertebrae, curved to the left, and reaching the spinous processes at each end. Raise a flap of skin and subcutaneous tissues, and turn this medially, to expose the supraspinous ligament.

**CAUTION!**

(1) Approach the abscess from the left, so as to avoid the azygous vein (at some levels) and the vena cava. The aorta, being thicker is much less easily damaged.

(2) Later, gentle dissection near the vertebral bodies will help you to avoid damaging the pleura and entering the pleural cavity.

With a knife, divide the posterior spinal muscles in the line of the skin incision, and strip the muscle mass with a stout periosteal elevator from the lamina of the vertebra and laterally from the back of the transverse process. When you have cleared the transverse process fully, divide it at its base with a sharp osteotome.

Clear the attached rib of muscle laterally to 8cm from the midline and then cut the periosteum of a rib longitudinally on its back, and strip it from the bone with a curved periosteal elevator all round, keeping close to the bone. This will help to separate it from the tissue covering the underlying pleura, and protect the intercostal vessels and nerve.

Then cut the rib with rib cutters (or carefully with bone cutters), at the lateral extremity of the incision. *Avoid damaging the pleura.*

Then grasp the outer end of the rib, and by a twisting movement remove it with the severed part of the transverse process at its base.

Now look for the paraspinal abscess. Insert your index finger along the side of the vertebral bodies, and separate the tissues gently. You may need some sharp dissection with scissors; if so keep very close to the bone. This will lead you to the abscess, and *not the pleura!* Tuberculous pus is watery, with debris in it. Pus from osteitis is yellow and creamy. Drain and culture what you find. Pass your finger round the anterior surface of each vertebra, up and down to ensure thorough drainage.

*N.B. Do not perform a laminectomy (i.e. dividing the posterior arch of the vertebra) as this may cause the spine to subluxate.*

**If you find no pus**, check the radiograph, you may have chosen the wrong level. If so, re-examine the radiographs and remove a further transverse process and its related rib and feel again.

**If you still find no abscess**, take some tissue from the disc space for histology. The best place to biopsy is felt more easily than seen. Use cervical biopsy forceps, or dissecting forceps and a #15 blade mounted on a long handle.

**CLOSURE.** Preferably use suction drainage (4.9). There is no need for an intercostal drain, unless you damage the pleura. Approximate the muscles to the spine by sewing the spinal muscles to the supraspinous ligament with absorbable sutures. Close the skin with continuous 2/0 monofilament. Apply a dressing.

**POST-OPERATIVE CARE.**

Insist on changing the patient's position 2hrly. He should be able to turn the upper part of the body by 48hrs, but he will still need 2hrly assistance with turning. He may show no improvement for up to 6wks. If there is no improvement by this time, the outlook is poor. If improvement starts by 6wks expect it to continue for 6months. It will be hastened and improved by the drainage of a significant abscess.

**If the paraplegia continues**, treat with attention to possible complications.

**CAUTION!** *Avoid an indwelling catheter.*

Try using intermittent sterile catheterization if necessary!

**DIFFICULTIES WITH COSTOTRANSVERSECTOMY**

**If you damage the pleura**, insert an intercostal drain (9.1).

**32.6 Back pain & lumbar disc lesions**

**Backache** is a very common symptom. Your task, as often, is to sort out those patients who need specific and sometimes urgent treatment, from those whom you can only help symptomatically.

Most common causes are:

- (1) vertebral disc prolapsed
- (2) osteoarthritis and senile osteoporosis in the very old

Causes not to miss are, particularly in children:

- (3) pyomyositis (7.1),
- (4) osteomyelitis (7.15),
- (5) septic or tuberculous arthritis (7.16, 32.4).

Other causes include:

- (6) malignant deposits in the spine,
- (7) back injuries including ligamentous sprains,
- (8) spondylosis, spondylolysis and ankylosing spondylitis.

*Do not forget:*

- (9) pancreatitis (15.11),
- (10) pyelonephritis,
- (11) retroperitoneal abscesses (6.15),
- (12) a leaking aortic aneurysm (35.8)!

**Lumbar disc lesions** are due to the protrusion of the *nucleus pulposus* of an intervertebral disc through a weakened area in its *annulus fibrosus*. This is the ring of firm fibrous tissue that holds the softer *nucleus pulposus* in place. Prolapsed tissue from the *nucleus pulposus* may press on a nerve root, and cause pain down the leg (32-7B,E). Almost all lumbar disc lesions occur in the spaces L4/5 or L5/S1. Pressure on the S1 root causes pain down the back of the thigh, calf, and outer side of the foot (32-7D). Pressure on the L5 root causes pain on the lateral aspect of the thigh and leg, and the dorsum of the foot (32-7C).

A protrusion from the L5/S1 disc usually presses on the S1 root (not on L5), but a protrusion from the L4/5 disc may press on the S1, or on the L5 root. Occasionally, when the protrusion is central, other roots are involved, and these may cause urinary problems.

Disc protrusions are more likely to occur in a back which has been weakened by a sedentary occupation, and may follow sudden flexion of the spine, or bumping in a sedentary position, as with truck drivers and their passengers in the back on bad roads.

The patient is usually a younger to middle aged adult, who presents with sudden severe pain in the front of the thigh, the back of the thigh (sciatic pain, which is present in most patients), the calf, or the foot. Movement, coughing, or sneezing all make the pain worse. The dorsum of the foot may be numb, and its dorsiflexors weak, occasionally on both sides.

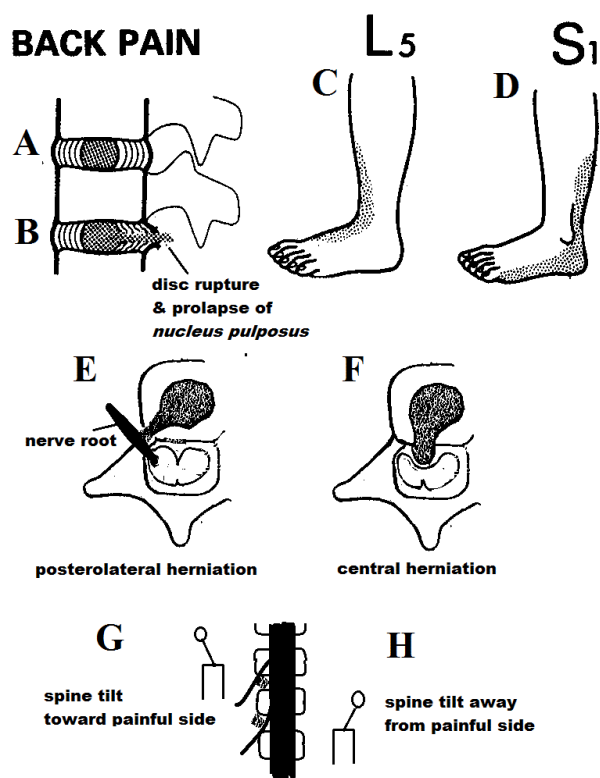


Fig. 32-7 BACK PAIN.

A, normal disc. B, ruptured annular ligament, with the *nucleus pulposus* protruding. C, L5 lesion causes loss of sensation on the dorsomedial aspect of the foot, and weakness of the dorsiflexors of the ankle, with sparing of the ankle jerk. D, S1 lesion causes loss of sensation on the lateral border of the foot, weakness of plantar flexors, and a diminished ankle jerk. E, prolapsed disc pressing on the large S1 nerve root; F, central protrusion risks involving S2, S3, S4 and S5 which control bladder function, G, if the disc protrudes medial to the nerve root, the patient tilts his spine towards the painful side to relieve pressure on the nerve root, whilst H, if the disc protrudes lateral to the nerve (at a lower level), he tilts away from the painful side. After Apley AG, Solomon L. *Apley's System of Orthopaedics and Fractures*. Butterworth 6<sup>th</sup> ed 1982 Figs 18.20,21,23.

#### EXAMINATION. (32-8).

Remember to examine, for metastases, the prostate rectally in a man, and the breasts in a woman.

Measure the length of both legs: in many cases they are different, and a simple shoe raise will solve the problem.

**In lumbar disc lesions**, the lumbar spine is flattened, with loss of its normal lumbar lordosis, and slight scoliosis. There may be tenderness over the interspinous ligaments, at the site of the lesion, or on gently tapping the spinous processes. Movement of the lumbar spine is usually severely restricted. Forward flexion is always restricted, and is accompanied by spasm. Lateral flexion may be free, in one or both directions.

Lay the patient flat and raise the leg by the ankle. Straight leg raising is limited and flexing the ankle makes it worse. The ankle jerk (S1) may be diminished or absent. There may be also diminished sensation in the relevant dermatomes.

You can usually diagnose a disc lesion clinically. Most disc lesions are benign and self-limiting, and can be managed non-operatively, although they often recur.

**PLAIN RADIOGRAPHS** rarely show confirmatory signs. Look for mild scoliosis, loss of the normal lumbar lordosis and narrowing of the disc space. Radiographs must be well centred to show this. *If you take films obliquely, any disc space will look narrow.* Perform a **MYELOGRAM** (38.1h) if sciatica is getting worse despite treatment, or if there is an acute cord compression, or deteriorating paraparesis. Obtain a chest radiograph especially in a smoker (looking for cancer) or if TB is likely.

#### DIFFERENTIAL DIAGNOSES

**Suggesting metastatic disease:** an older patient with persistent spinal pain, both when active and at rest. The radiographs of the spine may be normal initially. Typically, there is a patchy osteoporosis of the bodies, and/or the arches, of the vertebrae (some metastases are sclerotic, especially those from the prostate). There may be a pathological fracture, especially of a vertebral body. The discs are spared. Look for the primary in the prostate (27.22), the breast (24.4), the bronchus (29.19), the thyroid (25.6), and the kidney (27.35), and for signs of multiple myeloma (32.20).

**Suggesting an acute infective cause: pyomyositis** (7.1), or **osteitis of the spine** (7.15): an acute onset with fever in a child or young adult, who is obviously very ill.

**Suggesting tuberculosis** (32.4): a slow onset with loss of weight, malaise, mild fever, and a *gibbus*.

#### CAUTION!

- (1) Young children do not have disc lesions, so assume that all back pain in a young child is serious, until you have proved it is not.
- (2) Back pain and fever are a serious combination.
- (3) Think of TB.

#### TREATMENT.

Insist on bed rest in the most comfortable position, which is usually with the hips and knees flexed. Do not put pillows under the knees; they will immobilize the legs and promote deep vein thrombosis. Put boards under the mattress. Provide analgesia (if necessary, pethidine or morphine with NSAIDs for the first few days), and *do not let him get up, even to go to the toilet*. Make sure you turn a patient 2hrly if he cannot do so himself: do this with 3 assistants, rolling him keeping the spine from bending. *There is no evidence that steroids help in the long term.*

Many patients improve without traction. If not, tie a band round the pelvis, and apply a total of 7-10kg to both sides for a maximum of 3-5 days. Raise the foot of the bed to apply counter traction. Alternatively, apply 4-5kg of traction to each leg with adhesive strapping.

Start active and passive movements of the legs, as soon as the acute pain is over. When the pain is sufficiently improved, start back extension exercises. If symptoms improve, continue bed rest for 2-3 wks. Then allow mobilization to the toilet, keeping the back straight. *Do not allow bending down:* insist on crouching with the hips and knees flexed, keeping the back straight, to pick something from the ground.

#### INDICATIONS FOR SURGERY.

- (1) Neurological deficit: if there is perineal numbness, loss of an anal reflex or incontinence of urine or faeces, surgery is urgent, otherwise incontinence may become permanent. Sensory loss in the S1, L5 or L4 regions usually means surgery is needed sooner rather than later.
- (2) Significant weakness of the dorsiflexors (L5) or plantarflexors (S1).
- (3) Failure of the pain to improve, despite 3-4 wks in bed.

#### EXAMINING THE SPINE

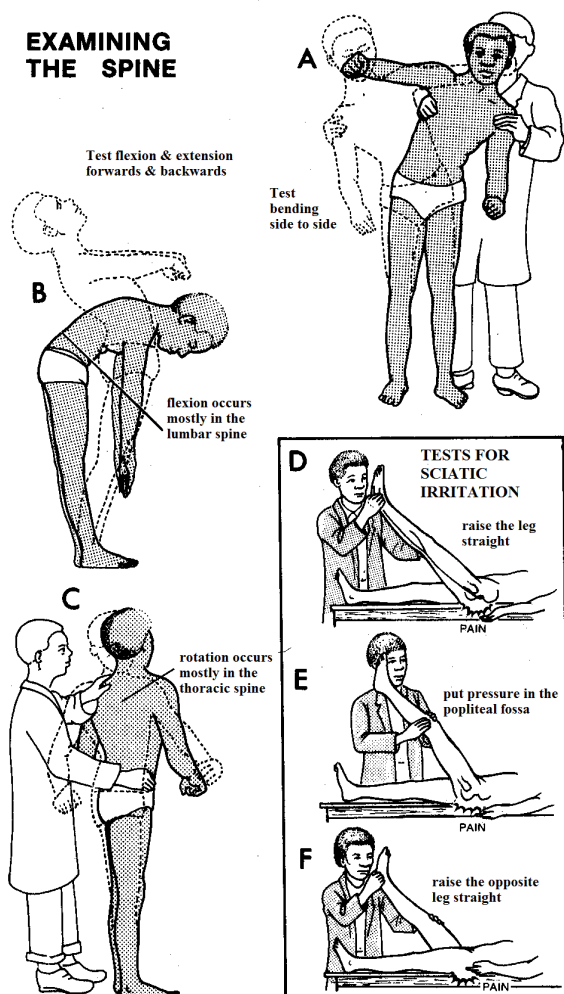


Fig. 32-8 EXAMINING THE SPINE.

A, flexion from side to side. B, flexion and extension forwards and backwards. C, rotation. D, straight leg raising to test for sciatic irritation. E, confirm this by pressing in the popliteal fossa, or dorsiflexing the ankle, which cause sciatic pain through stretching. F, if you raise the opposite leg, this may also cause pain.

#### CONTRAINDICATIONS FOR SURGERY

- (1) Be careful if the patient's neurological deficit does not correspond with the radiological findings; operation then, at the wrong site, obviously will fail to cure the problem!
- (2) Make sure the neurological deficit is of spinal, not peripheral, origin, e.g. arising from a neuropathy (e.g. diabetic or HIV), or nerve injury (for example, from IM injections).

#### DIFFICULTIES WITH BACK PAIN

**If an older patient has pain on sitting or standing, or following manual activities,** he is probably suffering from **OSTEOARTHRITIS**. Exclude other diseases. Keep the spine as mobile as possible with exercises. Encourage weight loss in obesity.

**If an old patient, especially female, has a marked kyphosis,** think of **SENILE OSTEOPOROSIS**, with a generalized loss of matrix and calcium, especially from the bodies of the vertebrae. The discs expand and compress the weak vertebral bodies. Painful pathological fractures are common, and there may be root pain. Treat symptomatically with analgesics, and encourage mobility, if necessary with the aid of a stick.

**If an adult or older child has back pain, worse on standing, and often episodic,** consider the possibility of **SPONDYLOLITHESIS**. In this condition the body of a vertebra (commonly L5) slips forwards on the vertebra below. It is often asymptomatic, and even if you find it, it may not be the cause of the pain, so exclude other causes. If you find it by chance, when there is no pain, do nothing. If there is pain, surgery may be necessary.

**If a young man has leg weakness but has minimal back pain,** consider HIV or schistosomal transverse myelitis, Guillain-Barré type neuropathy, or syphilis.

**If a young man has back pain and later stiffness, perhaps with inflammatory involvement of the other joints,** consider the possibility of **ANKYLOSING SPONDYLITIS** (common in India, 32-9), a disease of unknown aetiology. Typically, the pain disturbs sleep in the early hours of the morning, is relieved by getting up and walking, and, unlike most other pains, is made worse by rest. The upper legs may ache, but radiating pain is unusual. There may be malaise. Test for bilateral sacroiliac tenderness, and pain over the sacroiliac joints on springing the pelvis (both early signs). All movements of the lumbar spine are restricted, sometimes with muscle spasm. Chest expansion is also restricted (an objective early sign). Look for uveitis (28.5). The ESR is raised. The earliest radiographic sign is bony erosion of the lower  $\frac{1}{3}$  of both sacroiliac joints, followed later by secondary ossification and ankylosis of the whole joint. Early, the lumbar radiographs are normal; later there is a calcification of the intervertebral ligaments ('bamboo spine').

Teach exercises to help prevent severe curvature of the spine, and retain mobility. In the early painful stages, NSAIDs may help, e.g. indometacin 25mg tid.



Keep the major joints mobile, and if they do become fixed, try to ensure that this happens in the position of function (7-16).

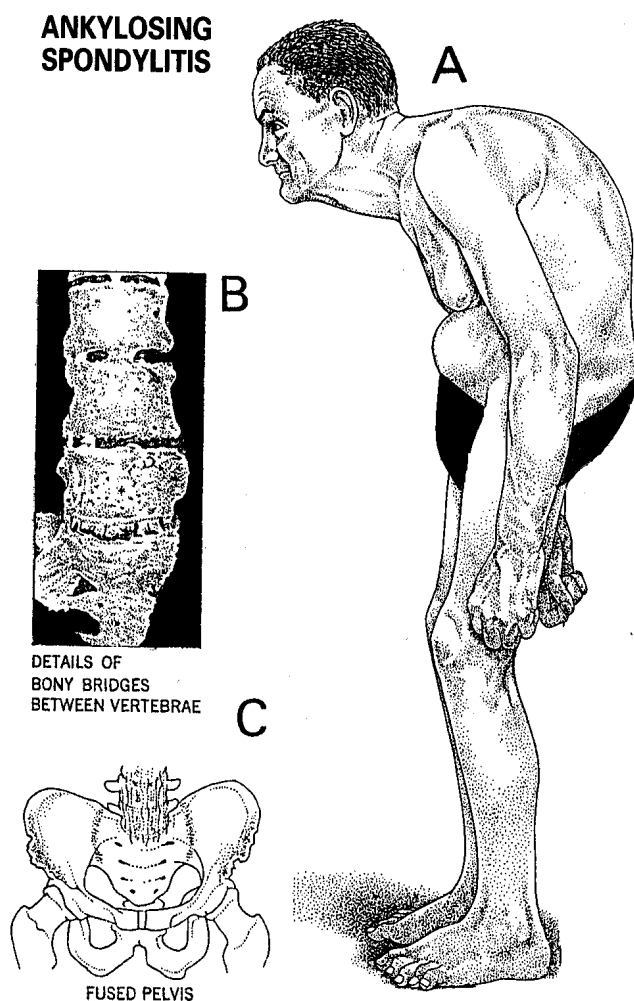


Fig. 32-9 ANKYLOSING SPONDYLITIS.

A, characteristic 'question-mark' posture of ankylosing spondylitis. B, bony bridges forming between the vertebrae. C, sacroiliac joints have fused and only the ghost of the old joint line is visible.

After Robin J in 'The Independent', permission requested.

## 32.7 Managing chronic poliomyelitis

Many children of the world have paid a high price for acquiring their natural immunity. Poliomyelitis is still found in Pakistan, Afghanistan, Madagascar, Myanmar and Central and West Africa, as well as war zones (Ukraine, Syria & Iraq). *In certain countries, there is an active effort to stop immunization, so this disease may soon acquire a re-birth.* Some cases of vaccine-derived polio have occurred in areas of inadequate vaccination and low immunity. The strategy to prevent this is to launch a high-quality high-coverage immunization.

The polio virus destroys the anterior horn cells of the spinal cord. This causes a flaccid lower motor paralysis, without impairing sensation.

The flexor and extensor muscles of a normal limb are arranged so that they oppose one another's action.

Polio can weaken both groups mildly or severely, equally or unequally. When, as is usual, the muscle groups are involved unequally, it is commonly the extensors which are most affected.

When this happens, the stronger flexors pull the limb into a flexion contracture. If all the muscles of the limb are weak, there is a flail limb.

In a child, growth will cause further deformity. All this can happen in varying degrees to the hips, the knees, or the ankles, on one or both sides, to cause many patterns of paralysis. The arms are less commonly affected, and are usually less of a disability.

Make sure you have ruled out other causes of paralysis, especially HIV disease.

Remember similar deformities may result from cerebral palsy. If you can correct physical deformities, mental deficiency will be much easier to handle.

These are your opportunities:

(1) Do all that you can to promote the immunization campaigns in response to WHO's expanded programme of immunization (EPI).

(2) Try to prevent contractures developing immediately after the acute phase of the illness.

(3) If they do develop, use serial plasters, traction, or tenotomies to release some of the milder ones. More complex operations, such as osteotomies, arthrodeses, and tendon transfers, are tasks for an expert, so are all operations on the arms and spine, on the rare occasions when these are necessary.

(4) Provide patients with the necessary callipers (32-13A), crutches, and plaster splints.

(5) Follow them up for many years, if necessary, and help them to find places in schools, and to find jobs. As always in medicine, but particularly in polio, consider the total needs. Never treat a single joint without considering the other joints in the limb, the other limb, and the adaptations the patient has already made to the disability.

Your results should be good if:

(1) you operate carefully on the right indications,

(2) you use simple callipers (32-13A),

(3) you are able to provide the necessary physiotherapy and follow-up.

These last two are likely to be your main constraints.

### THE HIP IN CHRONIC POLIO

**If an adult or child has an isolated flexion contracture of the hip of  $<30^\circ$**  due to weakness of its extensors and adductors, he is probably walking adequately, and *needs no treatment, provided there is no other serious contractures.* The stability of the hip may even be improved and shortening compensated by a small adduction and flexion contracture.

**If an adult or child has an isolated flexion contracture of  $>30^\circ$ ,** consider releasing it.

**If there is a flail hip** due to paralysis of all its muscles, provide a pair of crutches.



## CHRONIC POLIO

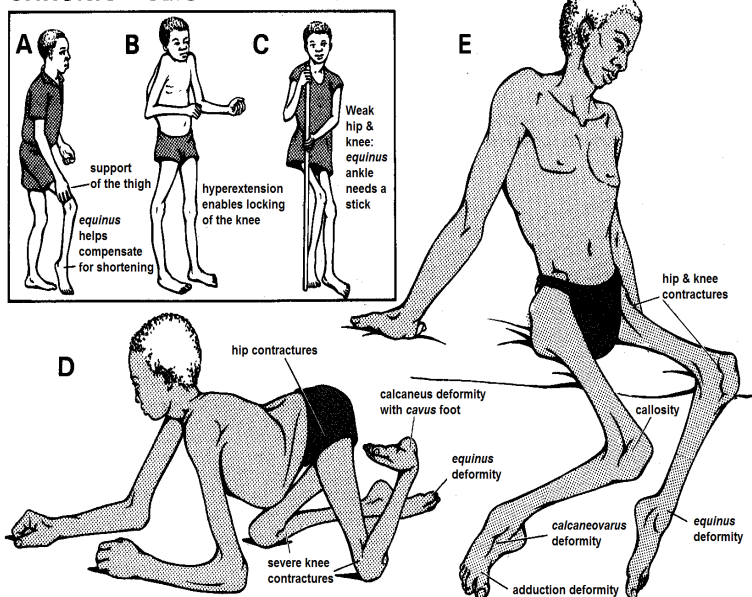


Fig. 32-10 CHRONIC POLIO. A, A patient with a weak hip or knee may be able to walk by putting his hand on the thigh, or B, by locking the hip in hyperextension, using the extensors of the hip. C, if the whole leg is weak, a stick will be necessary. D, if there is severe contractures of both knees, crawling on the ground may be the only way to get around. E, an adult 'crawler' seated. Note the large callosities on the knees. Kindly contributed by Ronald Huckstep.

If there is a hip dislocation or subluxation in a flail hip, reduce the dislocation, and apply an abduction plaster spica. Provide crutches. Occasionally, an osteotomy, an arthrodesis, or a psoas transfer is necessary. Reducing a dislocated hip can be difficult. It readily redislocates because there are no functioning muscles left around the hip to hold it in place. If the dislocation is recurrent, leave it alone.

### MORE POLIO DEFORMITIES

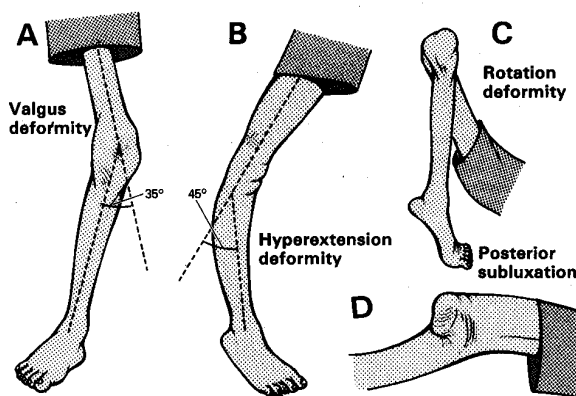


Fig. 32-11 MORE POLIO DEFORMITIES OF THE KNEE. A, valgus deformity. B, hyperextension deformity (*genu recurvatum*). C, rotation deformity. D, posterior subluxation. All these are much less easily treated than flexion deformities. Kindly contributed by Ronald Huckstep.

### THE KNEE IN CHRONIC POLIO

Not all weak knees need a complete calliper. Some patients may be able to manage with a knee splint.

If there is an isolated flexion contracture of the knee of  $<30^\circ$  due to weakness of its extensors, apply serial casts for a child (32.1), and skin traction for an adult.

**CAUTION!** Never put a cast on a knee (or any other joint) while it is held under tension, or osteoarthritis will result (32.1).

If there is an isolated flexion deformity of the knee of  $>30^\circ$  but  $<90^\circ$ , release it surgically (32.8) by a very limited open tenotomy (32-15). Do this only if you need a little more extension in order to apply skin traction, when the *biceps femoris* tendon is tight, but not the *semitendinosus* and *semimembranosus*, which are attached medially (35-18). Feel the tendons when the knee is extended to its limit. If all the tendons are tight and need surgical release, more complex surgery is necessary.

If there is a flexion deformity of  $>90^\circ$ , correction is going to be difficult, and a stiff painful knee may subsequently develop. If there is one contracted knee, either leave it alone, or consider an osteotomy or an arthrodesis. An adult with 2 contracted knees is best left alone.

If there is a valgus deformity of the knee, usually associated with a flexion contracture, a surgical release and a calliper are necessary. If necessary, bend the calliper, or fit it with a valgus knee strap, to prevent it rubbing against the knee.

If a small child has a severe valgus deformity of the knee, an osteotomy, or stapling of the medial epiphysis, by an expert, is necessary.

If there is lateral rotation of the tibia on the femur, or lateral subluxation of the knee, there is usually also a flexion contracture of the knee. Try to correct rotation and subluxation at the same time as the flexion contracture. More often, a late deformity is structural, and cannot be corrected by simple tenotomies. If rotation and subluxation are the only deformities, they are usually asymptomatic, and do not require specific treatment.

If a child has a hyperextended knee  $>10^\circ$  (*genu recurvatum*), due to early weight-bearing on a weak knee, fit an above knee calliper with a posterior strap.

If an adult has a hyperextended knee  $>30^\circ$ , an osteotomy may be necessary.

### THE ANKLE IN CHRONIC POLIO

If there is an equinus deformity of the ankle, owing to paralysis of its extensors, in a child, and flexing the knee allows you to bring the ankle up into the neutral position, correct the deformity by serial casting (32.1). If there is a greater degree of deformity than this, do a tenotomy.

In an adult, the decision as to whether an operation would be beneficial is difficult, and depends on:

- (1) the degree of equinus of the ankle,
- (2) the power in the knee and hip,
- (3) the condition of the other leg,
- (4) whether he can or cannot use crutches,
- (5) whether he will need callipers after surgery and can get them.

**If there is a *calcaneus* deformity of the ankle,** due to weakness of the calf muscles, a lace-up boot may be all that is necessary. Otherwise, fit a below-knee calliper with a front stop.

**If there is a *valgus* deformity of the ankle,** usually associated with some degree of *equinus*, correcting the *equinus* deformity and fitting a calliper will probably be enough. Otherwise a transfer of the peroneal tendons, and perhaps a triple arthrodesis will be necessary (32-26F).

**If there is a *varus* deformity of the ankle,** due to weakness of the evertors of the foot fit him with a below-knee calliper if the deformity is mild. Otherwise a soft tissue correction, or a triple arthrodesis will be necessary (32-26F).

**If there is an adduction deformity of the forefoot,** try several manipulations (32.1). Surgical correction will probably be necessary.

**If there is a *cavus* foot** (32-20A), a tenotomy, tendon transfer, or arthrodesis of the toes is necessary.

*N.B.* Apparent shortening is due to tilting of the pelvis, as the result of an adduction or abduction deformity of the hip. True shortening is a real shortening of the leg, and in polio is due to the failure of a paralysed leg to grow. If necessary, correct an abduction contracture of the hip, a flexion contracture of the knee, or an *equinus* contracture of the ankle. If the shortening makes walking difficult (usually >4cm), raise the short leg with a clog or with boots. If necessary, fit callipers.

#### DIFFICULTIES WITH CHRONIC POLIO

**If the femur or tibia fractures,** fit a cast, and use the opportunity to correct any deformity, and maintain walking. The knee and ankle are unlikely to be functional, so stiffness will not be a problem. An internal fixation is indicated to maintain alignment.

#### APPLIANCES FOR POLIO

When you have released the contracture, the muscles of the leg will still be weak, so you will probably have to provide a brace, or a crutch, or both. A weak hip needs crutches, a weak knee needs a long calliper (32-13A), and a weak ankle needs a short one. If you cannot provide callipers, *do not try to release the contractures!*

There are 4 types of orthopaedic appliances of increasing sophistication:

(1) Appliances of the traditional type, such as the pads, kneelers, sticks, peg legs (32-21B) and crutches, that are used in traditional societies everywhere. Unfortunately, there are no traditional callipers.

(2) Appliances of the Huckstep type (32-13). These can be made in a hospital workshop using locally available iron, galvanized wire, wood, and leather, and can be repaired by a bicycle mechanic, a cobbler, or a blacksmith. If they are properly made with hardwood, a child will usually outgrow them, and need a larger size before they wear out. If they are made of soft wood they wear out quickly.


(3) Appliances of an intermediate type are more durable. They are cheaper than appliances of type (4), and are technologically appropriate. An example is a modified Bata shoe with a metal tube to support the end of the iron bar (32-13B). If these shoes have an open toe, they will fit feet of various sizes, but are less durable in wet weather. The leprosy shoes (32-22,23) are of this kind.

(4) The expensive high-technology appliances that are standard in the industrial world. These need imported materials, particularly duralumin and special plastics, and can only be made and repaired by a skilled technician. Unfortunately, many prosthetists consider it a matter of professional pride to make only the most sophisticated appliances of this type, which patients cannot afford. Resist their efforts, and encourage them to make appropriate appliances in sufficient quantity.

If you cannot get ready-made appliances from an orthopaedic service, ask your hospital workshop to make those of types (2) or (3). All large or medium-sized hospitals, doing much surgery, need a workshop making a wide range of appliances of level (3). You will need above- and below-knee callipers, fitted when necessary with backstops or frontstops (32-13A). The callipers differ only in length, in the diameter of the ring, and in the presence of a knee piece in an above-knee calliper. Calipers of types (2) and (3) have irons each side of the leg. Although the single outside or inside irons of the callipers of type (4) look more elegant, they are weaker, they are more difficult to make and adjust, and they are usually less effective than double ones.

Use callipers to prevent deformities in a weak limb, and to straighten and support a child's leg after you have corrected the contracture. There are few indications for fitting callipers on an uncorrected contracture. Fit them as soon as walking starts, and replace them with a larger size with increasing growth. Encourage all children, who have muscle weaknesses which might lead to deformities, to wear callipers until they have stopped growing, even if they can walk without them. The indications for fitting an adult with a crutch, or a calliper, are the same as in a child, except the deformities are static.

#### PARALLEL BARS FOR POLIO



**Fig. 32-12 PARALLEL BARS FOR POLIO** are helpful when a child is learning to walk. Kindly contributed by Ronald Huckstep.

### ABOVE-KNEE CALIPER

If you are uncertain if a knee or ankle calliper is going to be useful or not, consider applying a suitable plaster cast of the same function for 4-6wks. If it is helpful, make a calliper. In this way you will avoid making callipers that do not help.

**INDICATIONS.** Fit a child with an above-knee calliper if:

- (1) The knee is so weak that lifting the leg against gravity is impossible (quadriceps power  $<3$ ).
- (2) He is likely to develop a contracture as the result of muscle imbalance.
- (3) There is a mild knee contracture of  $<30^\circ$  that a calliper could correct, if it is worn during the day or at night.
- (4) He is developing a hyperextended knee, as the result of trying to lock and stand on it.
- (5) There is weak quadriceps (35-18C), and at the same time too much *equinus* to let him swing the leg, and lock the knee.

### CONTRAINDICATIONS.

*Do not fit a calliper, or crutches, if:*

- (1) Walking is reasonably good with a flail ankle: walking may be easier without them.
- (2) Walking is reasonably good with a weak knee, using the hamstrings (35-18C) to extend the thigh, and lock the knee.
- (3) There is have enough power in the triceps, shoulders, or trunk to use crutches (needed because of weak hips).
- (4) You have not corrected the deformity (unless it is very mild, and the calliper is designed to correct it).

### FITTING.

Choose a calliper which reaches about 2cm below the groin on standing, make the straps fairly tight, and make sure that the knee piece gives the knee adequate support anteriorly. Make the posterior strap slightly loose, unless the knee is abnormally hyperextended (32-13A).

**If there is a mild flexion deformity of the knee,** fit an ordinary calliper with a loose posterior strap, and a tight knee piece, which may need to be padded.

**If the knee is hyperextended** (*genu recurvatum*), you can correct this easily, so apply only slight tension to the posterior strap.

**If there is a valgus knee,** bend the calliper to avoid the bony points, and fit an inner knee pad tied to the outer side of the callipers, to prevent the knee from rubbing against the inside iron, especially on weight-bearing. Fit it so that it presses on the medial side of the knee, and corrects the deformity on walking.

**CAUTION!** A long calliper keeps a knee straight, and allows walking. But, because the knee does not bend, it may become fixed in extension, and be a nuisance on sitting. So make quite sure that on removing the calliper, the knee is put through a full range of passive flexion. This should not be a problem, if the calliper comes off each night.

### BELOW-KNEE CALIPERS

#### INDICATIONS.

Provided there are no complications, fit a below-knee calliper if the foot is flail or drooping, or is tending to go into *varus* or *valgus*, provided the quadriceps power is  $>3$ . If it is  $<3$ , an above-knee calliper is necessary.

**FITTING.** Choose a calliper that will allow the knee to flex fully, with a socket which will fit firmly, and not allow too much movement. Always fit a supporting ankle strap.

**If the calf muscles are so weak that the foot dorsiflexes excessively,** fit a front stop.

**If there is little power in the dorsiflexors, so that the foot tends to equinus,** fit a backstop (32-13).

**If the ankle is inverted or everted,** fit the appropriate inner or outer T-strap.

**FOLLOW UP.** Try to review at least every 6 months. Replace the calliper with a larger one as the child grows. A long calliper is no use if it ends just above the knee! Make sure that the family understands that the child will need a calliper for life. Do all you can to help with education.

#### CRUTCHES.

You will need a variety of sizes. If possible, make them to measure. If necessary, you can use any straight stick with a handle and a bar for the axilla. A crutch will be useful if polio has weakened the hips. Allow a suitable trial period. The grip must be strong enough to hold it, the triceps must be strong enough to propel the patient forwards, and the spine must be strong enough to allow sitting without help.

A crutch is likely to help if:

- (1) Both legs are in callipers.
- (2) One leg is in callipers, and the opposite leg or the spine are weak.
- (3) One leg is in a calliper and is very weak, and the hip on the same side is weak.

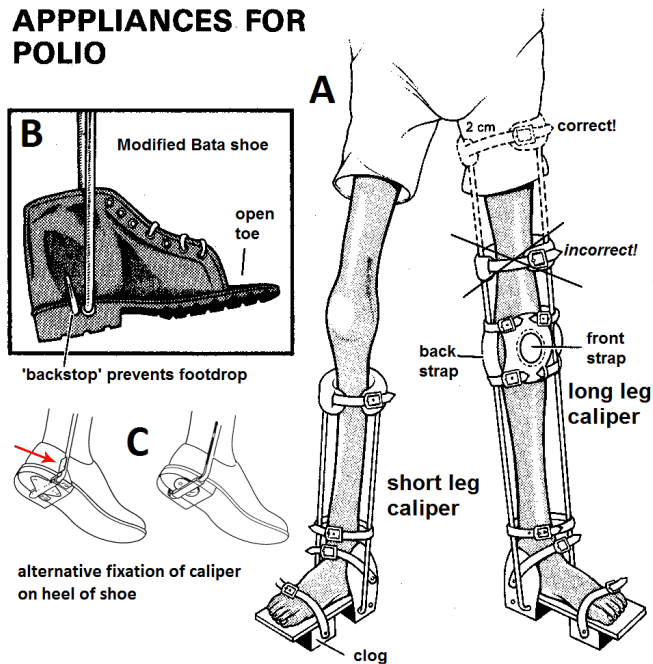
Fit crutches. The length and the position of the hand grip must be right. Many patients who are given crutches could manage equally well with a stick. If you try a stick, teach him to hold it on the opposite side to the weak or weakest leg. If his hands are too weak to hold ordinary crutches, forearm crutches may be useful.

**CAUTION!** Make sure that he does not lean on the crutches, while they are in the axilla. This may paralyse the radial nerve, or even all the nerves to the forearm and hand, and they may take 6 months to recover.

A **TOE SPRING** may be of great help if there is foot drop. Fix a suitable spring, or a piece of bicycle tubing to the toe of the shoe and to a strap below the knee (32-23). Alternatively, attach a back stop, which is easier to fit.

**AN ANKLE SPLINT** will be useful if there is danger of foot drop while in bed. Make a suitable splint from plaster, or padded boards, to keep the foot at  $90^\circ$  to the leg.

## APPLIANCES FOR POLIO



**Fig. 32-13 APPLIANCES FOR POLIO.** A, simple callipers. Note that long leg callipers should reach to 2cm below the groin. They will be useless if they only reach to just above the knee. B, modified shoe, as an example of an appliance of type 3. C, alternative calliper fixation to the heel of the shoe. Kindly contributed by Ronald Huckstep.

A RAISED SHOE will help if one leg is >4cm shorter than the other. Any cobbler will raise make a shoe-raise. Start with a shoe-raise of  $\frac{1}{2}$  the deficit in length. If there is <4cm of shortening, do not supply a shoe raise.

### 32.8 Contractures of the hip and knee

Before you decide on any operative treatment, assess the function of the limbs in detail, and what the particular social needs are. There may already be remarkable mobility, and although a straight leg may look better, it may not work better, especially if it needs callipers. However, if a child's legs are so weak and contracted that he crawls along the ground, even if it be at some speed, you must try to get him walking, because the psychological effect of doing so will be tremendous. But if he is an adult, consider the whole future carefully first. He may be able to crawl fast and cultivate the fields on the hands and knees, but if he can only walk slowly and stiffly in callipers, he may die of starvation. So a cultivator may be better crawling, especially if his arms are too weak to use crutches, whereas an office worker, for example, may benefit from callipers.

*N.B.* Sometimes an operation is an obvious disservice, e.g. lengthening the Achilles tendon for someone walking on the ball of an equinus foot.

A severe contracture can:

- (1) cause the skin over a joint to shrink,
- (2) shorten the muscles, intermuscular septa, nerves, and vessels,
- (3) contract the joint capsule,
- (4) deform the epiphyses.

Undoing all this is difficult, and may be impossible; so only try to relieve milder contractures, and follow the indications carefully, or you may damage important structures, or cause infection or skin loss. A child's contractures are easier to correct; he probably only needs a tenotomy, whereas an adult may need an osteotomy, or an arthrodesis.

The contractures of the hip and knee are often associated. You may have to release or lengthen:

- (1) The iliotibial band in several places down the thigh. In a young child, 1-2 incisions may be enough, and you may not need the complete set of 4 incisions described (32-14).
- (2) The tight structures on the front of the hip, particularly, the *iliopsoas*.
- (3) The tendon of the *biceps femoris* in the popliteal fossa.
- (4) The medial hamstrings (occasionally).

You can cut tight bands and tendons in 2 ways:

- (1) Push a long thin tenotomy knife through a small skin incision, and cut the bands by palpation. This is satisfactory for the less severe contractures, provided you do it correctly, and as extensively as necessary.
- (2) Cut tight structures under direct vision. In the thigh, this is the best method, especially for severe contractures, but it needs more skill and the wound may break down, so use the closed method. Behind the knee, the common peroneal nerve is very superficial, so the only safe way to divide the tendons there is by open operation.
- (3) Lengthen a tendon by a z-plasty incision. Slit the tendon longitudinally according to the length required, and extend this cut laterally proximally and distally in the form of a Z; then suture the two parts of the tendon together side-to-side to provide the extra length.

*N.B.* Do not try to treat a contracted hip by manipulation and serial casting in a spica; surgery is better.

The knee is the most difficult of the three joints on which you may have to operate, especially in an adult, whose tibia can be rotated backwards and laterally, as well as being flexed. Be safe, and do not try to release a contracture of >90°. If you try, the tight popliteal vessels and nerves may be stretched; and pain, paralysis, and even gangrene may follow. Even a contracture of <90° may be difficult. After you have released it as much as you can by tenotomy, you can obtain the final correction by daily increasing buckle correction. Insert a Steinmann pin through the upper tibia and incorporate this in a long leg cast, with a slit in the popliteal area. Fit a buckle ratchet attachment at the back of the knee. Apply traction to the Steinmann pin to avoid posterior subluxation of the knee, and adjust the buckle to give an extra 1mm extension per day (32-16).

**ANATOMY.** The common peroneal (lateral popliteal nerve) descends obliquely along the lateral side of the popliteal fossa to the head of the fibula, close to the medial margin of *biceps femoris*. It lies between the tendon of *biceps femoris* and the lateral head of *gastrocnemius*, and winds round the lateral surface of the neck of the fibula deep to *peroneus longus*.

## TENOTOMY

### INDICATIONS.

- (1) An isolated hip contracture of  $>30^\circ$  at any age.
- (2) A child with an isolated flexion contracture of the knee of  $>30^\circ$ .
- (3) An adult with an isolated flexion contracture of the knee of  $<90^\circ$ .
- (4) Combined hip and knee contractures of  $>30^\circ$ , provided there are no contraindications. If you have many patients, start by operating on the younger ones with lesser deformities first.

**CONTRAINDICATIONS** to any release operation are:

- (1) Weak arms. The patient will need crutches, so he must have 2 arms, especially if both legs and the trunk are weak. There are exceptions to this rule, and a really determined adult, or child, sometimes manages surprisingly well with limited weakness in one or both arms, provided the trunk is strong.
- (2) A patient with mild contractures, who is walking reasonably well, is probably best left as he is. This includes:

(a) a contracture of the hip alone of  $\leq 30^\circ$ , especially if it also has a mild abduction deformity, which may increase its stability and compensate for shortening.

(b) an isolated knee contracture in a child: treat with manipulations under GA every 2wks.

(3) An adult who is earning his living as a 'crawler', and is happy to go on doing so.

(4) *Do not operate on any patient unless you can provide him with callipers* (32-13).

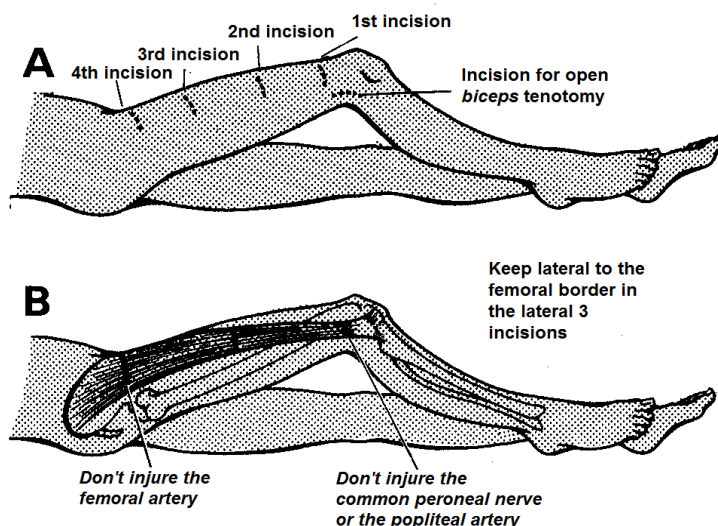
**CAUTION!** Scar tissue is not stable for at least 6months, so when you correct contractures, you must find some way of maintaining the position of the limb for at least 6months, or longer, if there is still muscle imbalance, or much scar tissue.

### ILIOTIBIAL BAND TENOTOMY (GRADE 1.3)

Use a narrow tenotomy knife, or an old cataract knife, or a #11 scalpel blade altered (32-17), so that only its tip is sharp. Operate under full sterile precautions, and prepare both legs, even if you are only going to operate on one of them. Squeeze all blood out of the incisions periodically during the operation, and at the end. The hip incision may bleed considerably.

Release the hip and knee before you release the ankle. The structures you are going to divide must be tense, as you divide them, so keep the hip in as much extension and adduction as you can, while you cut. Feel the tight structures through the skin, to make sure that you have left no tight bands undivided.

## CUTTING THE ILIOTIBIAL BAND



**Fig. 32-14 ILIOTIBIAL BAND TENOTOMY.**  
A, position of the incisions. B, structures to be cut.  
Kindly contributed by Ronald Huckstep.

### 1<sup>st</sup> incision.

Make this on the outer side of the thigh, about 2cm above the knee. You can usually feel the *tensor fascia lata* as a tight band. Push the knife horizontally into the outer side of the thigh, just behind the tight band, until it just touches the lateral side of the femur.

Rotate its blade, so that its cutting edge is upwards; then cut all the subcutaneous structures anterior to the blade, and lateral to the femur. Provided you make the incision in the right place, and only cut anteriorly, you will not cut anything important. *Do not cut posteriorly*, or you may cut the popliteal artery, or the lateral popliteal nerve.

### 2<sup>nd</sup> & 3<sup>rd</sup> incisions.

Make these  $\frac{1}{3}$  and  $\frac{2}{3}$  of the way down the outer side of the thigh. Feel for the *tensor fascia lata*, and push the knife in along its posterior border down to the bone, exactly as for the first incision. Then rotate the knife  $90^\circ$  and cut anteriorly and laterally to the outer side of the shaft of the femur.

If you cannot feel the *tensor fascia lata*, insert the knife where you think it should be and cut exactly the same way. There are other tight structures to be cut, including the *vastus lateralis*.

**4<sup>th</sup> incision** is the one which releases the hip.

Make it 2cm below the anterior superior iliac spine.

### CAUTION!

(1) *Do not damage the femoral vessels and nerve. Do not push the knife further medially than a point 2 cm lateral to the mid-inguinal point* (where you can feel the artery).

(2) Feel for the inguinal ligament, and take care not to divide that.

Push the knife in subcutaneously, below the anterior superior iliac spine, from a lateral to a medial direction, so that its flat surface is in the plane of the skin just caudal to the anterior superior iliac spine. Stop 2cm lateral to the mid-inguinal point. Then rotate it  $90^\circ$ , so that its edge faces backwards, and cut all the tight subcutaneous structures.



If the contracture is severe, cut all tight structures lateral to the branches of the femoral nerve. Cut right down to the front of the trochanter of the femur.

When you have cut the tight structures anteriorly, twist the knife so that it cuts laterally, and cut all the tight structures on the anterolateral side of the hip.

#### CAUTION!

(1) When the tip of the knife is deep, angle it caudally, so that its blade is parallel with the inguinal ligament, and will not cut it.

(2) Do not cut further back than the coronal plane of the anterior part of the hip joint. Leave the abductors posterior to this, to give lateral stability to the hip.

(3) Keep the hip in as much adduction and extension as you can, while you divide the tight structures. Feel them through the skin during the operation, and do not leave any tight deforming bands behind.

#### OPEN BICEPS FEMORIS TENOTOMY (GRADE 1.3)

INDICATIONS. This is only indicated if the knee contracture is  $>30^\circ$  but  $<90^\circ$ . The method which follows is a very limited open tenotomy suitable for a patient:

(1) who needs a bit more extension, so that he can be put into skin traction,

(2) whose *biceps femoris* tendon is tight, but not the *semitendinosus* and *semimembranosus* tendons, which are attached medially. Feel the tendons when the knee is extended to its limit. If all the tendons are tight and need surgical release, get expert help.

#### OPEN BICEPS TENOTOMY

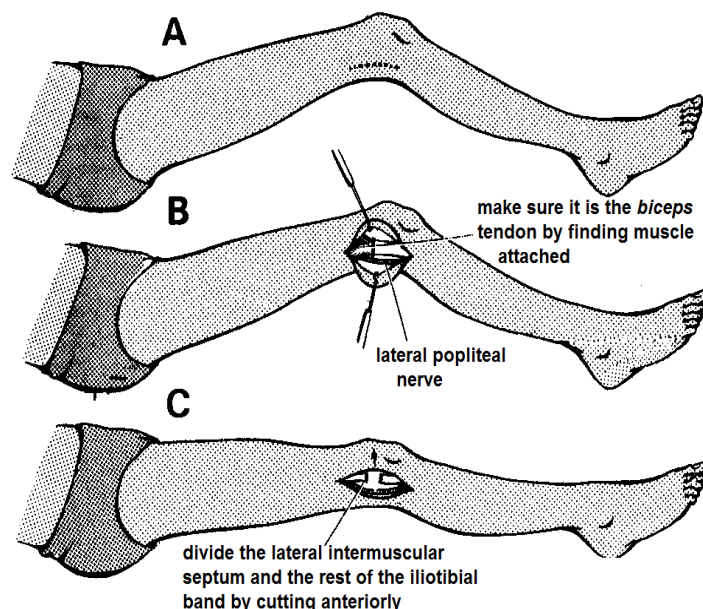


Fig. 32-15 OPEN BICEPS TENOTOMY to release a contracture of the knee. A, site of the incision. B, be quite sure you find the lateral popliteal nerve, before you cut anything. C, divide the *biceps femoris* tendon. Kindly contributed by Ronald Huckstep.

METHOD. Make an incision on the lateral side of the knee (32-15). Feel for, and find the biceps tendon under direct vision, hook it out of the wound, and cut it.

CAUTION! Be sure that it is the biceps tendon, and only the biceps tendon. Be careful you have not caught the lateral popliteal nerve with it: they both look very similar. Look for muscle fibres being inserted into the tendon before you cut it. Be sure the nerve has not stuck to the back of the tendon.

Put your finger into the wound, and feel for any other tight structures which need cutting. You may need to cut the posterior part of the iliotibial band, and the lateral intermuscular septum. Sometimes, the anterior part of the deep fascia lata also needs cutting.

Apply skin traction, or a well-padded cast.

CASTING AND MANIPULATION. If the contracture of the knee is  $<45^\circ$ , apply a well-padded cast with the knee just short of the full extension to which it is capable. It must not be under any tension, or it will be painful. If the contracture is  $>45^\circ$ , apply a pulley support keeping the knee elevated, with skin traction to the distal leg (Russell traction).

#### CAUTION!

NEVER put a knee into a cast under tension, or wedge a cast to correct a knee contracture, or its articular cartilage may necrose, and early painful osteoarthritis may follow, in what was previously a painless mobile joint.

Check the hip incision again (if you have released the hip at the same time), as soon as you have applied the cast, and squeeze out any clot which has formed, under full sterile precautions. Pad the incision and apply light adhesive strapping.

Every 2wks, remove the cast, and manipulate the hip and knee, until the knee is in at least  $5^\circ$  of hyperextension, and there is  $<10^\circ$  of flexion deformity ('fixed flexion') in the hip. Manipulate it (32.1), and spend 5-10mins on each joint. Be sure to flex the knee fully, and to rotate the tibia medially and laterally, to maintain these very important movements. Correct or avoid backward subluxation of the knee. If necessary, correct the lateral rotation of the tibia on the femur.

After each manipulation apply a well-padded above-knee cast, with the ankle firmly dorsiflexed. As always, do not put the knee under tension!

As soon as the flexion deformity in the knee is  $<40^\circ$ , fix a walking piece on the bottom of the cast, and encourage walking with crutches.

Leave the final cast on for 2wks, and then replace it by an above knee calliper, with its posterior strap loose. Advise wearing it day and night for 2-3wks, until the risk of recurrence of a flexion contracture of the knee is less. Later, daytime wear only, for up to 6 months, is necessary when the tendency for the contracture to recur will have passed, or indefinitely if the knee needs stabilization.

If possible, provide physiotherapy, or assisted exercises, after you have removed the cast. If the postoperative care is not properly done, you may end up with a stiff, painful knee, in which the tibia is subluxated posteriorly on the femur.



MOBILIZE and get the patient into a chair as soon as possible. For a child, you can usually do this in a few days. In an adult, full mobilization may take a month or two. Prop him up gradually in bed or a chair, before he tries to get up. He may need crutches or a calliper; crutches must fit properly.

#### DIFFICULTIES RELEASING CONTRACTURES OF THE KNEE

If the knee is painful & stiff, (which, so it is said, should never happen with proper treatment), reassure that the knee will slowly recover some, or all, its movement in a few weeks or months. The pain will probably go, even if the knee does not regain its full movement. If pain and stiffness persist, try intensive physiotherapy or Russell traction. An arthrodesis is necessary very occasionally.

#### BUCKLE KNEE EXTENSION DEVICE

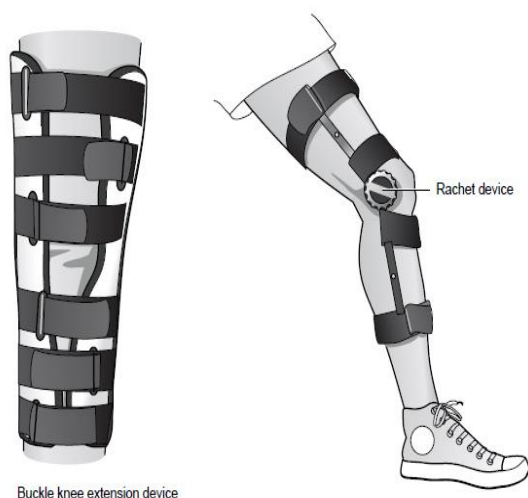


Fig. 32-16 BUCKLE CORRECTION FOR KNEE FLEXION DEFORMITY.

### 32.9 Equinus deformity of the ankle

This is the most common deformity in a child, and is fortunately the easiest to correct. Provided there is no severe *valgus* or *varus* deformity (32.1), you can correct a milder *equinus* deformity with serial casts, each of which will release the deformity a little more. If you are inexperienced, you will find serial casts very useful.

If a child has a more severe deformity, he needs the Achilles tendon lengthened. You can perform this by an open or closed method. The closed operation is simpler, and there is less risk of infection, or keloid formation. The advantage of the open method is that it is possible to divide the posterior capsule of the ankle joint, if this is necessary, as it may be in polio.

The risk in both methods is that you may cut the posterior tibial nerve and vessels, and cause gangrene of the toes, but this should never happen, if you are careful.

### CLOSED ACHILLES TENOTOMY

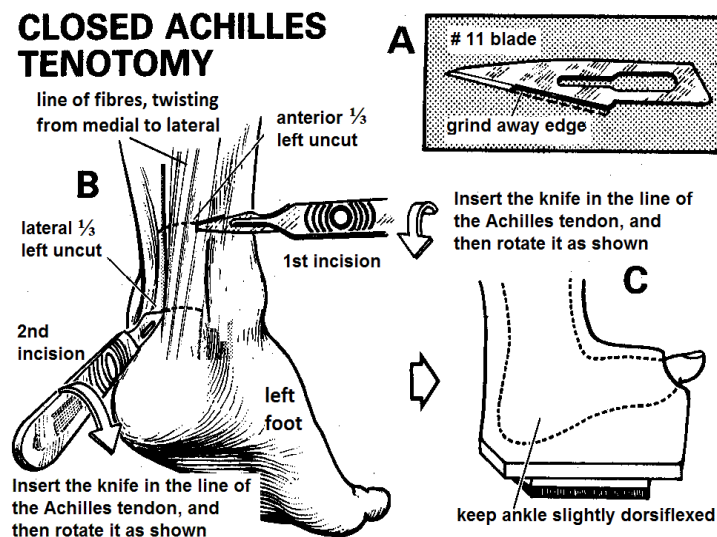


Fig. 32-17 CLOSED ACHILLES TENOTOMY. A, if you do not have a tenotomy knife, make one by grinding away a #11 blade. B, the 2 incisions: make only tiny incisions in the skin. Insert the knife with its blade in the plane of the fibres, and then twist it before you cut. Make the 1<sup>st</sup> cut from the medial side above the malleolus, and the 2<sup>nd</sup> posteriorly cutting medially. C, put the foot into a cast in gentle dorsiflexion. N.B. The fibres of the Achilles tendon twist from medial to lateral as they descend. Kindly contributed by John Stewart.

#### ACHILLES TENDON LENGTHENING:

##### SERIAL CASTING

##### INDICATIONS.

Mild degrees of *equinus* deformity: make sure that when you flex the knee as far as possible, the calf muscles relax enough so that the ankle comes into a neutral position (90°).

N.B. If both legs are involved, correct them one at a time, to avoid a long confinement to bed.

##### METHOD.

Do not use GA. Apply a below-knee cast, while the knee is flexed to 90°, to allow you to achieve more dorsiflexion of the ankle. You may not be able to get the foot into the neutral position on the first occasion. When the cast is dry, apply a walking heel, and allow mobilization. Encourage progressive knee extension. Once the patient is walking with the knee fully extended, repeat the procedure and apply a further cast, until the foot will reach the neutral position with the leg extended.

#### CLOSED ACHILLES TENOTOMY (GRADE 1.3)

##### INDICATIONS.

Where serial casting is inadequate, with also a minor *varus* or *valgus* deformity, provided it is not so severe that it will prevent you fitting callipers.

##### CONTRA-INDICATIONS.

In a child, tenotomy is contraindicated if:

- (1) The *equinus* ankle is helping to compensate for a short leg, or to stabilize an unstable knee, and so enabling satisfactorily walking.
- (2) He will never walk because his arms are weak.
- (3) The deformity is minimal, and he is managing well with a shoe or boot, with or without a calliper.
- (4) The feet are infected; if so, delay the operation.
- (5) There is a severe *valgus* or *varus* deformity which will make fitting a calliper impossible.

## METHOD.

*N.B. For club foot, use the method described in 32.10.*

Use a small tenotomy knife, or the improvised one (32-17). Use full sterile precautions, scrub up, gown yourself, use gloves, and apply a tourniquet (3.4).

**1<sup>st</sup> incision:** cut through the posterior  $\frac{2}{3}$  of the Achilles tendon, above the level of the malleoli. Do this by pushing the knife into the tendon from the medial side, in the line of its fibres, at the junction of the anterior third and the posterior two-thirds. Rotate the knife 90°, and then cut posteriorly, until you feel the knife cutting very easily, which shows that you have now cut the posterior part of the tendon.

**2<sup>nd</sup> incision,** push the knife into the tendon in the line of its fibres, at the junction of its lateral  $\frac{1}{3}$  and medial  $\frac{2}{3}$ , just above its insertion on the calcaneum. Then, rotate the knife through 90°, and cut medially.

## CAUTION!

(1) Use full sterile precautions, and drape with sterile towels.

(2) Use a gentle sawing motion, and *do not break the blade*.

(3) *Do not cut the posterior tibial vessels and nerves*, which lie anteromedial to the Achilles tendon (32-18).

(4) *Do not try to divide the tight posterior capsule of the ankle joint in this method.* This is not tightened in poliomyelitis, unless there is an associated *varus* deformity, which must be corrected at open operation.

To manipulate the ankle, flex it dorsally. Apply force as close to the joint as possible. *Do not apply force to the distal tibia*; you can easily break it. In a young child with polio, you should be able to achieve 20° of dorsiflexion (calcaneus); in an adult or older child you may get less. If necessary, manipulate it again 2wks later.

**If the ankle does not reach the neutral position (90°),** check that the tendon has been divided properly, by reinserting the tenotomy knife in the same 2 tenotomy sites. If the ankle is still not fully corrected to 90°, wait and plan to increase correction by applying serial casts every 2-3wks.

*N.B.* If necessary, release the ankle on the same occasion as the knee and the hip.

POSTOPERATIVELY, squeeze out all subcutaneous clot. Bleeding is usually slight. Apply a small dressing.

**If the knee is stable,** apply a well-padded below-knee walking cast, with the foot near the maximum correction, but not at the extreme limit of extension.

Elevate the leg, and encourage walking. Review a young child in 3wks, and an older child or adult in 6wks. Remove the cast and apply a below-knee calliper with a backstop (32-13B).

**If the knee is unstable and has no contracture,** apply an above-knee cast, and later an above-knee calliper instead of a below-knee.

## DIFFICULTIES WITH CLOSED TENOTOMY.

**If you have cut the whole Achilles tendon,** *do not be alarmed.* It will almost always heal satisfactorily in the lengthened position. *Do not try to repair it at this stage.*

**If the deformity recurs,** it probably did so because the patient did not wear a calliper, or wore one without a backstop (32-13B). *If he fails to wear one initially, the deformity is sure to recur.* He may be able to do without a calliper 6-12months later. Follow up carefully, so that you can decide about this.

**If you fracture the lower tibia** because you have manipulated it too vigorously, fit a cast.

## OPEN ACHILLES TENOTOMY (GRADE 1.3)

INDICATIONS. *Equinus* contractures of the ankle, in which there is a contracture of the posterior capsule of the ankle joint that requires release. This is an alternative to the closed method, especially when that has not achieved normal dorsiflexion.

METHOD. Using GA, apply an exsanguinating tourniquet to the thigh (3.4). Use the lateral position, with the leg to be operated on uppermost.

Make a longitudinal incision over the lower  $\frac{1}{3}$  of the leg, extending proximally from the attachment of the Achilles tendon to the calcaneus. Dissect out the Achilles tendon. You may see the small tendon of the *plantaris* (35-22I) on its anteromedial side.

Make 2 incisions half way across the Achilles tendon: the lower one 1cm above its insertion, either from the medial to the lateral side, or vice versa. If there is any *varus* deformity of the foot leave the lateral side intact. If there is any *valgus* deformity, leave the medial side intact. The aim of doing this is to help the distal attachment of the tendon to correct the deformity. At a suitable level, c. 4-10cm proximally (depending on the size and the degree of plantar flexion to be corrected), make a small incision opposite the first one (32-18A,B). Then push up the foot into normal dorsiflexion, without too much force: if the fibres of the Achilles tendon pull out, stop there.

**If you fail to put the foot into satisfactory dorsiflexion,** make a longitudinal incision down the middle of the tendon joining the two cuts. If this still does not correct the position of the foot, dissect down to the posterior aspect of the ankle joint, under direct vision. Divide the posterior capsule of the ankle joint transversely (32-18D), from lateral to medial, and open up the ankle, by dorsiflexing the posterior part of the foot.

## CAUTION! *Be careful not to cut:*

(1) the *flexor hallucis longus* tendon (35-22I),

(2) the posterior tibial nerve and vessels, which lie on the medial side of the posterior aspect of the ankle joint.

These structures are only in danger if you divide the posterior capsule.

If you have divided the Achilles tendon completely, bring its ends together with a special figure-of-8 suture. Close the skin with 2/0 monofilament. Pad the leg, apply a below-knee cast with the knee flexed to 90° and release the tourniquet.

## OPEN ACHILLES TENOTOMY

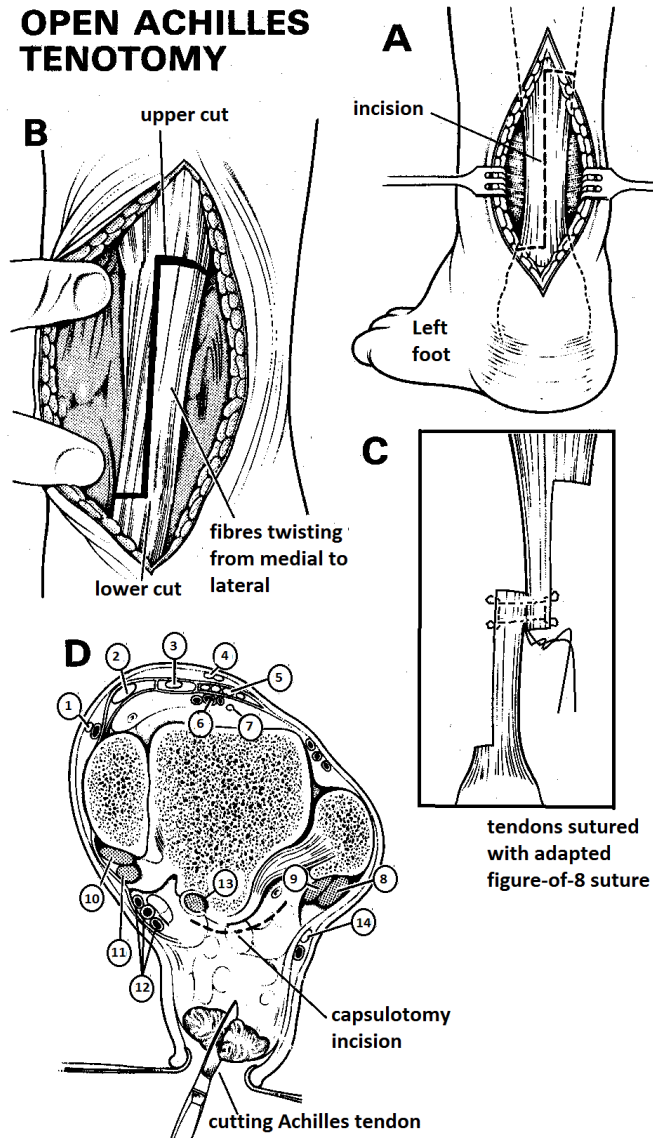


Fig. 32-18 OPEN ACHILLES TENOTOMY.

A, expose the Achilles tendon. B, divide the tendon, initially at the lower level, either on the medial side if there is *varus* deformity, or lateral if *valgus*; then vertically if necessary. C, repairing the tendon with a variation of the figure-of-8 suture. D, cross-section at level of mid-malleoli: (1) saphenous nerve and vein. (2) *tibialis anterior*. (3) *extensor hallucis longus*. (4) superficial peroneal nerve. (5) *extensor digitorum longus* and *peroneus tertius* in the inferior extensor retinaculum. (6) *dorsalis pedis* vessels. (7) deep peroneal nerve. (8) *peroneus longus*. (9) *peroneus brevis*. (10) *tibialis posterior*. (11) *flexor digitorum longus*. (12) posterior tibial artery & vein & tibial nerve. (13) *flexor hallucis longus*. (14) sural nerve. N.B. The fibres of the tendon twist from medial to lateral as they descend.

POSTOPERATIVELY, raise the foot of the bed, expose the leg on a pillow, and check the circulation in the toes hourly. Next day, add a 'shoe' to the cast. Provide crutches, and check the cast in 3wks. Remove it or change it at 6wks.

## REHABILITATION




Fig. 32-19 REHABILITATING DISABLED CHILDREN. With the kind permission of David Werner.

## 32.10 Club foot (Neonatal *talipes equinovarus*)

A child is sometimes born with shortening of the soft tissues of the flexor aspect of the leg, and the medial side of the foot, which causes the talus to point downwards (*equinus*), and inwards (*varus*). At the same time, the forefoot is adducted at its tarso-metatarsal joints, and the 1<sup>st</sup> metatarsal is plantarflexed to a greater degree than the 5<sup>th</sup> metatarsal (*cavus*). This may happen to one or both of the feet and is known as idiopathic club foot. The deformity is common and may arise 1 in 500 live births.

If the deformity is left to progress without correction, the navicular bone may be pulled medially, and sometimes even away from the front of the talus. An extreme result is a plantarflexed calcaneus and vertical talus, with dislocation of the navicular causing a 'rocker bottom foot'.

Manipulation and casting by the Ponseti method when properly done will correct this disability permanently; it is best if you can organize for your physiotherapy team to attend a course to learn to do this correctly; although the Ponseti method is not difficult, it is important to understand the anatomy, and avoid the pitfalls.

Occasionally, a child is born with the feet pointing in other directions or with other deformities: these may result in secondary, as opposed to idiopathic, club foot. Some cases of *talipes* are due to paralysis, for example those associated with MENINGOMYELOCOELE (33.11). These may be helped but are often resistant to conservative manipulation treatment.

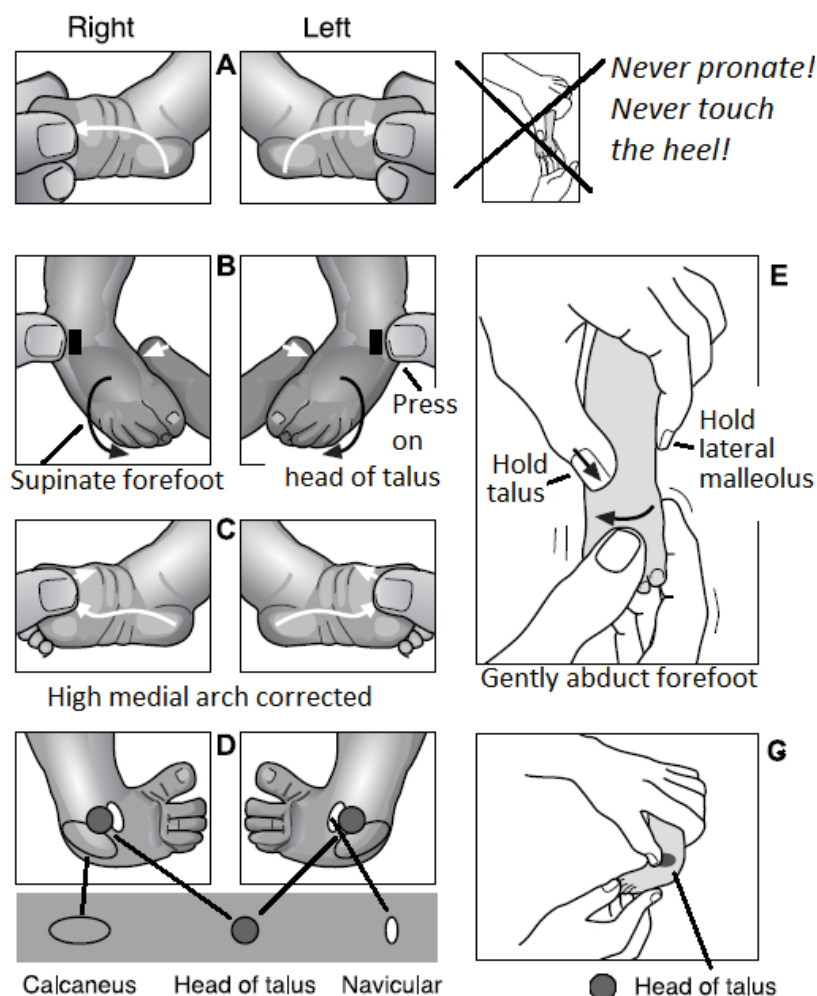
However, the feet of a child with **arthrogryposis** can be corrected by the Ponseti method, though recurrence is a problem. You need to use the Ponseti technique properly and carefully, but it has probably the *highest cost-benefit ratio* of any surgical procedure. It is most effective if you start before 9 months of age, but may still correct 85% of deformities if you begin even up to 12 yrs.

### THE PONSETI METHOD

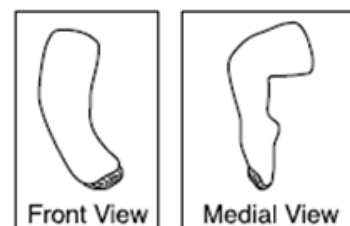
You have the best chance of correcting club feet permanently, so that a child will be able to walk normally in normal shoes, if you start treatment in the first days after birth. Manipulation weekly and applying plaster casts for 5 to 6 wks is normally successful. A tenotomy completes the correction, which is maintained with a foot abduction brace.

### PONSETI METHOD FOR CORRECTING CLUBFOOT . Goal:

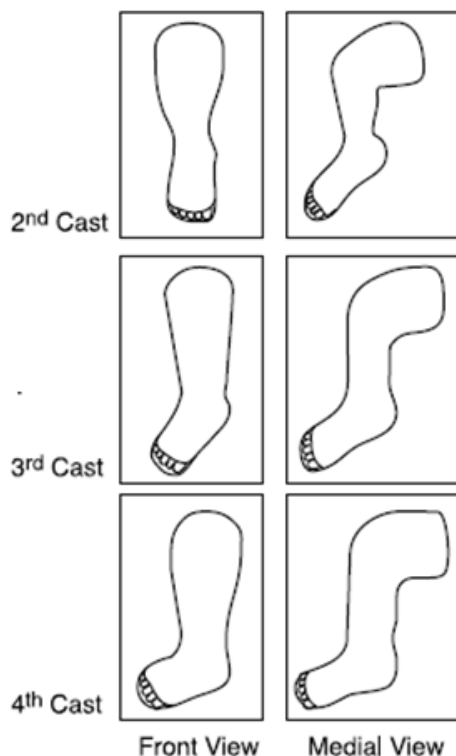
Get the forefoot in line with the mid foot in terms of supination.



### F 1st Cast: Correction of *cavus*



### 2nd - 4th Casts: Correction of midfoot inversion & heel *varus*



**Fig. 32-20 THE PONSETI METHOD FOR CORRECTING CLUB FOOT.** A, the arrows show *cavus*, the high medial arch, due to pronation of the forefoot in relation to the hindfoot. B, correct *cavus* by supinating the forefoot with pressure against the head of the talus. C, *cavus* (the forefoot adducted at its tarso-metatarsal joints) corrected. D, locate the head of the talus. E, correct *adductus* by gently abducting the forefoot whilst stabilizing the talus with your thumb and holding the lateral malleolus with your index finger. F, appearance of casts and the foot at each stage. G, apply padding while holding the maximum corrected position.

You should avoid other operations which tend to produce scarring and a chronically painful foot, until at least 2 yrs. You should aim to correct the components, *cavus* and *adductus*, of the clubfoot simultaneously, and *varus* when the entire foot is fully abducted. Lastly correct *equinus*.

*N.B.* Distinguish between inversion & eversion at the ankle, and pronation & supination at the forefoot!



## PLASTERING METHOD &amp; TENOTOMY for Ponseti Method

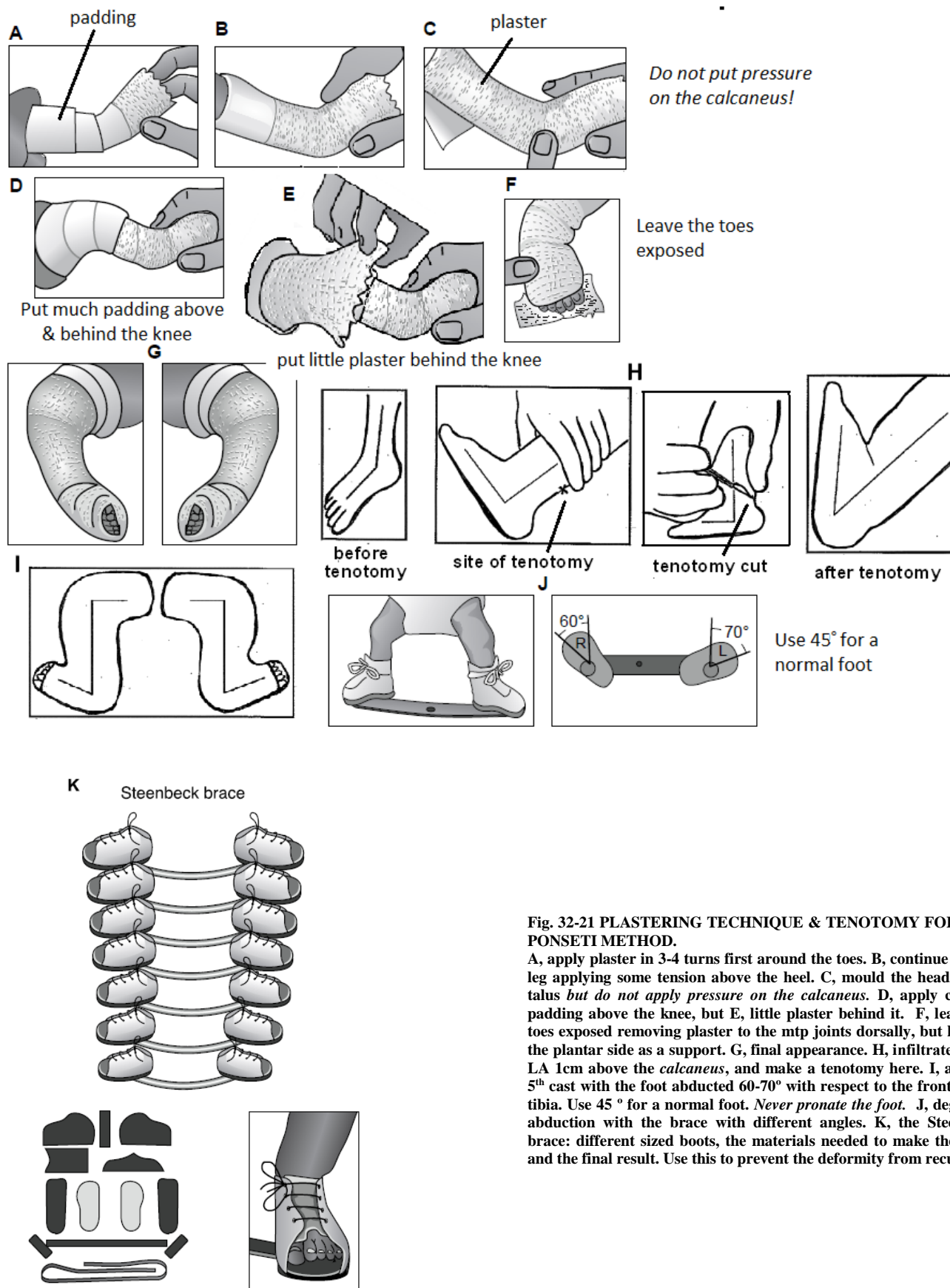
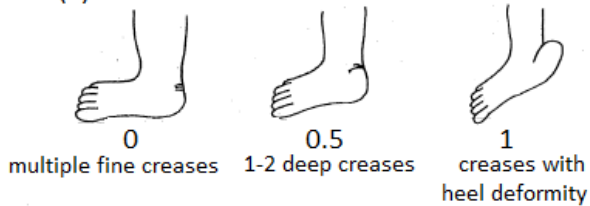


Fig. 32-21 PLASTERING TECHNIQUE & TENOTOMY FOR THE PONSETI METHOD.

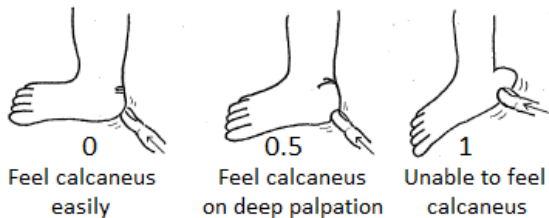
A, apply plaster in 3-4 turns first around the toes. B, continue up the leg applying some tension above the heel. C, mould the head of the talus but do not apply pressure on the calcaneus. D, apply copious padding above the knee, but E, little plaster behind it. F, leave the toes exposed removing plaster to the mtp joints dorsally, but leaving the plantar side as a support. G, final appearance. H, infiltrate 0.5ml LA 1cm above the calcaneus, and make a tenotomy here. I, apply a 5<sup>th</sup> cast with the foot abducted 60-70° with respect to the front of the tibia. Use 45° for a normal foot. Never pronate the foot. J, degree of abduction with the brace with different angles. K, the Steenbeck brace: different sized boots, the materials needed to make the boot, and the final result. Use this to prevent the deformity from recurring.

## COLUMBIAN FOOT SCORE (1) Hindfoot

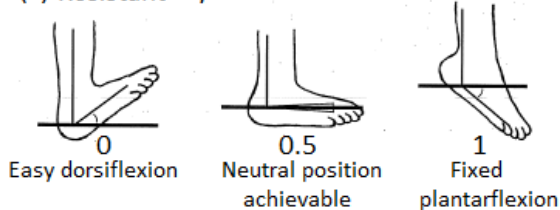
### (a) Posterior ankle crease



### (b) Empty heel

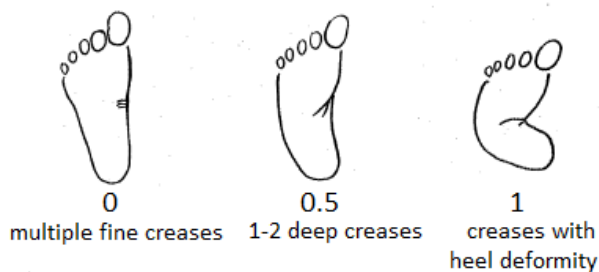


### (c) Resistant equinus

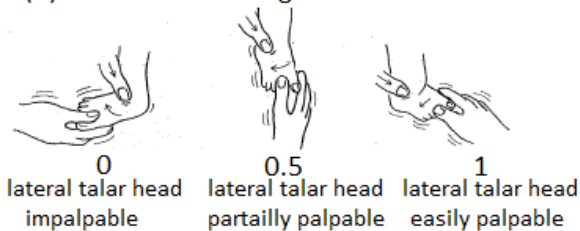


## (2) Midfoot

### (a) Medial sole crease



### (b) Talar head coverage



### (c) Lateral foot border curvature

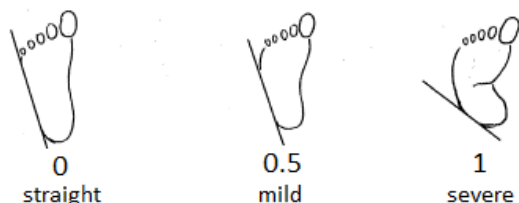


Table 32-1 Columbian club foot score

You should record the deformity objectively using the COLUMBIAN (Pirani) CLUBFOOT SCORE, giving 0 to no deformity, 0.5 to mild deformity and 1 to severe deformity:

	(a)	(b)	(c)
<b>Hindfoot</b>	Posterior ankle crease	Empty heel	Resistant equinus
<b>Midfoot</b>	Medial sole crease	Talar head coverage	Lateral foot border curvature

So, a normal foot scores 0 and a severe deformity 6.

*N.B.* The 'adducted metatarsus' has only a midfoot and no hindfoot contracture and is not a club foot

Correct *cavus* by supinating the forefoot and making a normal longitudinal arch (32-20A, 32-24J) and correct *adductus* by abducting the forefoot in proper alignment with the hindfoot. With the arch well moulded and the foot in slight supination, gently and gradually abduct the entire foot under the talus (32-24J) securing it against rotation in the ankle mortice by applying counter-pressure with the thumb against the lateral part of the talus head, using this as the pivot or fulcrum (32-20B,C), *not on the cuboid*.

So, make sure you can locate the head of the talus by first feeling for the lateral malleolus, and moving your thumb forward in front of the ankle mortice. The navicular (32-24J) is displaced medially to a position in front of the head of the talus, almost touching the medial malleolus. The anterior part of the calcaneus is beneath the head of the talus (32-20D). *Don't touch the heel at this stage.*

Gently abduct the forefoot, whilst stabilizing the head of the talus and holding the lateral malleolus, as far as you can without causing discomfort to the child. Hold this position with gentle pressure for 1min (32-20E) so that the big toe is almost straight, and apply a cast for 1wk. Continue further abduction, holding the position in the 2<sup>nd</sup> and 3<sup>rd</sup> casts, each for 1wk. Correct heel *varus* when you have corrected *adductus*, keeping the position in the 3<sup>rd</sup> and 4<sup>th</sup> casts (32-20F), again for 1wk.

Apply well-moulded, long-leg plaster casts after completion of each manipulation. The purpose of the casting is to immobilize the contracted ligaments at the maximum stretch obtained after each manipulation. Apply padding whilst maintaining the maximum corrected position (32-20G). Apply the cast with plaster of Paris in 3-4 turns first around the toes (32-21A), and continue up the leg, adding a little tension above the heel (32-21B). Keep some space around the toes by wrapping the cast around your assistant's holding fingers (32-21A)!

*N.B.* Do not force the correction with the plaster, and do not press continuously on the head of the talus, but rather, mould the plaster over the head of the talus and under the arch to avoid flatfoot. Do not put pressure or try to mould the calcaneus (32-21C).



Continue plastering above the knee, using copious padding (32-21D) but *avoid large amounts of plaster behind the knee* (32-21E). Trim the plaster dorsally up to the mtp joints, leaving the plantar surface intact to support the toes (32-21F).

Remove each cast just before you are ready to apply a new one. Soak the plaster in water for 20mins before removal. Start removing it at the thigh. *Do not allow a long interval between re-casting* because you may lose considerable correction thereby. (1)

Finally, correct *equinus* by dorsiflexing the foot. You will usually need to do a simple percutaneous(2) tenotomy of the Achilles tendon, unless the Pirani score is <1 for hindfoot and midfoot deformity and the talar head is easily palpable. (3)  
*Do not perform a tenotomy if the heel is in varus*, because this means you not have achieved adequate correction. (4)

Infiltrate 0.5ml LA (32-21H) after cleansing the skin(5) (*do not use too much LA* as you will then find the Achilles tendon difficult to palpate). Dorsiflex the foot to stress the Achilles tendon. Insert the blade longitudinally medial to(6) the tendon, turn the blade transversely and cut the tendon across 1cm above the calcaneus; you will feel a sudden 'pop' which will allow 10-15° extra dorsiflexion.(7) Apply a 5<sup>th</sup> cast with the forefoot abducted 60-70° with respect to the front of the tibia (32-21I). *Never pronate the foot*. Keep this cast in place for 3wks.

When you remove the cast, 30° of dorsiflexion should be possible in a well-corrected foot. The tenotomy scar is minute. Now apply an abduction brace for 23hrs/day at 3months (*i.e. all the time except when bathing*). You may have to adjust this brace as the child grows, and should review him monthly. Make sure the brace is fitted to open-toe high-ankle straight-laced shoes, with 75° external rotation and 10-15° dorsiflexion for the affected foot, and 45° for the normal foot (32-21J).

The bar is slightly curved convexly forwards. The knees are free so that the child can stretch the *gastrosoleus* tendon, and the bend in the brace helps to stretch the *gastrocnemius* (35-20B) and Achilles tendon. You can get a skilled cobbler to make the Steenbeek brace (32-21K) with readily obtained materials.

**If the deformity recurs after bracing**, you need to start again with serial casting, with possibly another Achilles tenotomy. Then maintain outward rotation in open shoes attached to a bar 12hrs at night and 2-4hrs in the middle of the day for 3-4yrs to prevent recurrence. The results, although anatomically not always perfect, are almost perfect functionally till late adult life. Bracing is essential: *if you don't follow the programme diligently, you will get an 80% recurrence rate*. Teach parents how to put on and take off the brace, and encourage the child to move both knees simultaneously. There should be no "negotiations" about wearing the brace with the child. Compliance is as necessary as with TB treatment.

To prevent the child kicking the shoe off, make sure the laces are well tied. Review the child at 2wks, 12wks, then every 4months till age 3, every 6 months till age 4, then every year till skeletal maturity.

#### DIFFICULTIES WITH THE PONSETI METHOD

Avoid these errors:

- (1) *Do not pronate or evert the foot* because this increases the cavus and does nothing to unlock the calcaneus locked under the talus, and will result in a 'bean-shaped' foot.
- (2) *Do not abduct the foot at the mid-tarsal joints by pressing on the cuboid with the thumb*, because this will make correction of varus of the heel impossible.
- (3) *Do not externally rotate the foot while the calcaneus remains in varus*, because this produces posterior displacement of the lateral malleolus.
- (4) *Do not forget to immobilize the foot* after each manipulation, with ligaments at maximal stretch.
- (5) *Do not apply below-knee casts*, because these do not hold the forefoot abducted and tend to slip.
- (6) *Do not correct equinus before correcting heel varus and supination*, because this results in a 'rocker-bottom' deformity.
- (7) *Do not perform an incomplete tenotomy*, because it will not give enough release and the tendon anyway heals rapidly in infants.
- (8) *Do not attempt to obtain a perfect anatomical correction*, because it is a functional correction that you want! *The radiographic appearances have no correlation with long-term function!*

**If there is an adductus or varus relapse**, recognized by supination of the forefoot (with the child walking towards you), and heel *varus* (with the child walking away), go back to manipulating and casting as from infancy.

**If there is an equinus relapse at 1-2yrs**, apply casts to get the calcaneus at least into a neutral position. You may have to repeat an Achilles tenotomy and follow this by 4wks of foot abduction in a long-leg flexed knee cast. Then go back to using the brace at night. If there is a late relapse at 3-5yrs, check if the foot dorsiflexes to 10° and perform a tenotomy as before. Otherwise more complex surgery is necessary.

**If there is persistent varus and supination during walking**, usually because of non-compliance, characterized by thickened lateral plantar skin, correct any fixed deformity with 2-3 casts and then refer for a *tibialis anterior* transfer. It is best to do this between 3-5yrs of age, but *always* after ossification of the lateral cuneiform (usually at 2½yrs).

**If no treatment has been started at all**, you should start the Ponseti method as for a newborn, but results are not as good, and depend on the delay starting treatment and the severity of the deformity.

**If other non-surgical treatment has already been started elsewhere before 28months**, you should start the Ponseti method as for a newborn: results are just as good.

**If treatment fails**, check for a neurological cause; the options are further casts, lengthening the Achilles tendon (32-18) or a *tibialis anterior* transfer operation.

### 32.11 Care of neuropathic feet

The feet are often just as important than the hands. Someone is able to work with a paralysed hand, but if he cannot walk, he will probably be unable to undertake the essential activities of daily life unaided. Many diabetics who are being adequately treated medically, are being allowed to walk about on ulcerated feet. The dressings that cover their ulcers do not prevent them from deepening, and widening, and involving the bones underneath. The quiet progressive destruction of these feet is not inevitable, and can be minimized. It may be a losing game, so play it as cleverly as you can, and try to retain the usefulness of the foot as long as possible.

Ulcers can be caused by:

- (1) Constant mild pressure, which causes necrosis by impairing the blood supply to the tissues, as in neuropathic ulcers. In a normal person ischaemia soon causes pain, so that the ischaemic part is moved, and its blood supply restored. In an insensitive foot there is diminished pain sensation (though some sensation to touch remains), so that the ischaemic tissue is allowed to become necrotic and ulcerates. Also, *an unnoticed fracture will produce deformity because the bone fragments are not immobilized.*
- (2) A strong force which cuts, shears or tears the tissues. In the foot, the strength of the force is less important than the small area over which it is applied.
- (3) The frequent repetition of moderate forces, which cause inflammation and so weakens the tissues. This is an important cause of ulcers, so try to minimize the pressure on a foot.
- (4) Forces which spread infection to soft tissues and bone. An infected foot is so painful to a normal person, that there is to rest it: *a patient with a neuropathy does not do this spontaneously.*
- (5) A previous ulcer. This is the commonest cause. If a patient has never had an ulcer, he may escape without one, if he is careful. If however he has already had many ulcers, he will probably not notice getting one more.

The key to preventing ulcers is:

- (1) to teach a patient how to prevent injuries to himself in the first place,
- (2) to teach him 'self care' for any injuries he does receive, in their earliest stages. All primary care workers should be able to teach this. When the tissues have been damaged, they will usually heal, if he rests them completely. Surgery is much less important than rest, at the right time, and for the right length of time. Antibiotics without rest will not heal ulcers.

Ulcers commonly start in the deeper tissues, and develop slowly over several days, so teach him to recognize an ulcer as a 'hot spot' in its 'pre-ulcer' stage, before the skin over it has been broken. A hot spot is a warm area of skin, usually with swelling, that occurs after activity, and persists during at least 2hrs of rest. In an anaesthetic foot, a hot spot may be the only indication of some underlying pathology, such as a fracture, disintegrating bone, a strain, or an abscess. Any of these may break through to the surface, and form an ulcer.

The patient, or a family member, must learn to look for hot spots, because they mean, "Stop!" He must take them seriously, and rest the foot until all signs of inflammation have gone. Rest at the hot spot stage is the only way to avoid the serious damage that starts the downhill road to amputation.

The risk of an anaesthetic foot developing an ulcer depends partly on the shoe (if there is one), and partly on how much it is injured by walking. Perhaps he can ride a donkey, or a bicycle? The kind of shoe he needs depends on the state of the foot, as defined by the 'degree of risk'. Many patients with moderate, or even high risk feet, can remain free from ulcers without moulded shoes (32-22) if:

- (1) they practise self care,
- (2) they have microcellular rubber insoles in their sandals or shoes (32-22A,B,C),
- (3) they limit their walking, and
- (4) they take small steps.

Moulded shoes are more difficult to make, and many hospitals manage without them.

With a little instruction a local cobbler should be able to make a suitable unmoulded shoe in the local style, with the necessary insoles and straps, and using only the local materials. If you want him to make a moulded shoe, he will need these special materials:

**MICROCELLULAR RUBBER.** This has a closed bubble structure, and is much more resilient than ordinary 'foam rubber'. Some shoe factories can provide it. It is not the same as the foam plastic used for cheap sandals, which is less resilient. Car tyres make good soles, and inner tubes can make uppers.

**FOAMED POLYETHYLENE,** 1cm thick. This is a light thermoplastic which a skilful cobbler can use to make a moulded shoe, for a moderate- or severe-risk foot. It resists wetting and is easily cleaned, but it does need an oven. Its main disadvantage is that it wears away in <6 months. Heat a piece of sheet to exactly 140°C in an oven and hold it at that temperature for five minutes: place it on a 10cm polyurethane foam pillow; and then ask the patient to stand still on it until it is cool, or let him sit while you force the foot down on it (32-23C). It will not burn him, and will set in the shape of the sole (32-23D,E). Be sure to support this moulded material with microcellular rubber, or cork and latex, built up to produce a flat sole; foamed polyethylene is not resilient enough to make an insole by itself.

#### LOOK FOR SWELLING AND REDNESS FEEL FOR 'HOT SPOTS'

'SELF CARE'. Teach a neuropathic patient to:

- (1) Recognize that his anaesthesia is abnormal.
- (2) Care for his anaesthetic limbs, and prevent injury.
- (3) Inspect the limbs daily, so that he can remove any thorns, and recognize and care for any wound, either open or closed, while it is still small, and before it gets worse.
- (4) Rest the limbs when they are injured.
- (5) Recognize and understand the seriousness of 'hot spots' and corn formation.
- (6) Treat the 1<sup>st</sup> ulcer as the calamity that it really is.

#### CAUTION!

- (1) Explain that it is injury to anaesthetic feet and not the disease itself which leads to ulceration and loss of tissue.
- (2) Walking must be limited if there is a hot spot, or an area of deep tenderness.

## EXAMINING AN INSENSITIVE FOOT.

Look for swellings, injuries and callosities. Are any of the toes pushed apart (with oedema from an injury)? Examine the arches of the feet on standing, and look for flattening. Feel the whole foot. Warmth or swelling suggest active pathology, and the need for extra care. Press deeply over the common sites of ulceration (32-24A,D,G). There may still be deep pain, when all ordinary sensation is lost. Assess the circulation, feel the peripheral pulses and the temperature of the skin. Time the capillary return.

## FOOTWEAR FOR FEET AT RISK

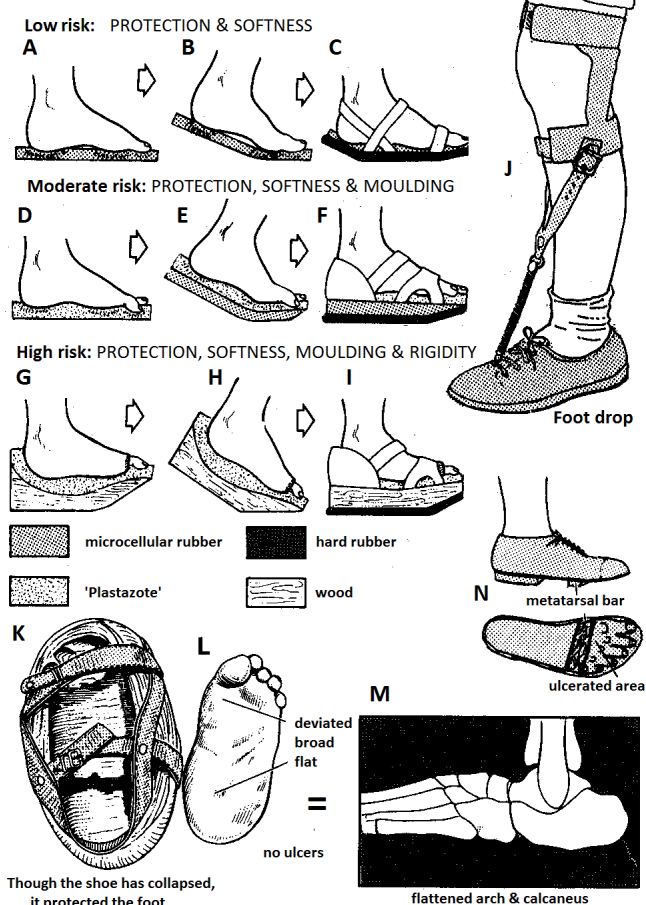


Fig. 32-22 FOOTWEAR FOR FEET AT RISK can be made by any cobbler if you are prepared to teach him.

**LOW RISK FEET.** A, microcellular rubber distributes the pressure. B, dark areas indicate where there is increased pressure on walking. C, car tyre sole applied.

**MODERATE RISK FEET.** D, first layer of 'plastazote'. E, layer of microcellular rubber. F, layer of car tyre.

**HIGH RISK FEET.** G, layer of 'plastazote' in a carved wooden clog distributes the weight evenly. H, when the patient walks, neither foot nor ankle flexes, and weight continues to be spread evenly. I, completed sandal. J, toe-raising strap for footdrop. *This is a very helpful device, so do not fail to fit one when it is needed.* If necessary, use canvas or plastic straps and make the 'spring' from a car inner tube. K, properly made shoe can protect a badly damaged foot. L, Note that it has no ulcers, even though it has lost its arches, and its toes are clawed and deviated. It has remained free from ulcers because the patient limited his walking, and because the shoe has a layer of microcellular rubber built up under a moulded 'plastazote' insole. N, the simplest modification for an ulcerated foot is a metatarsal bar, stuck or sutured to the outside of the sole, just behind the metatarsal heads, proximal to the ulcerated area.

After Bryceson A, Pfaltzgraff RE. *Leprosy*. Churchill Livingstone 2nd ed 1979 Figs 11.1-3. with kind permission.

**FOOTPRINT MAT**, also called a rubber Harris mat. This is a mat with little rubber ridges which you ink. Place a piece of paper on the inked mat and ask the patient to walk on it. The greater the pressure, the blacker the ink impression. If you are really interested in the care of leprosy feet, get a footprint mat.

Watch the patient walking barefoot. You can easily miss a dropped foot, if it is also short. Ask him to walk on his heels. He cannot do this if the *anterior tibial* or *peroneal* muscles are weak. Finally, *do not forget to look at his shoes!*

## DIFFERENTIAL DIAGNOSIS OF NEUROPATHIC FOOT

- (1) Diabetes mellitus,
- (2) HIV disease,
- (3) Peripheral vascular disease,
- (4) Syphilis,
- (5) Leprosy,
- (6) Spinal pathology,
- (7) Inherited neuropathies,
- (8) Peripheral nerve damage, *e.g. from badly located IM injections.*

## SKIN CARE.

Denervation of the skin reduces its natural secretions and makes it dry, so that it more easily cracks, fissures, and becomes infected. Softening dry skin reduces these dangers, and may allow any fissures that have formed to heal. So ask the patient himself to get plain water, without detergents, into the dry feet (or hands) by soaking them for 15-20mins at least twice a day. *Do not use warm water in case it is too hot!* If a fungal infection is present, add potassium permanganate to the soaks. Then ask him to cover the skin with petroleum jelly, or any kind of grease or oil (including car oil).

It is the water that is important, not the grease which keeps it in. *Beware cockroaches which like the oil:* advise a patient whose living conditions are poor to get a cat, or use insect repellents.

Pare away thick corn with a surgical blade, or ask the patient himself to rub it away with a pumice or other stone. Remove rough corns regularly, because it may split and crack, or cause ulcers by pressure.

## OTHER WAYS TO PREVENT ULCERS.

When necessary, remember to:

- (1) Correct deformities. If there is a foot drop, fit a toe raising strap (32-22J).
- (2) Advise taking short steps, which will reduce the pressure on the front of the foot and the heel.
- (3) Advise avoiding any hard edges or knots in the shoes or socks.
- (4) *Beware of newly healed ulcers.* The scar will not have had time to become supple, and is in danger from any shearing force applied to it.
- (5) *Avoid tight bandaging, and especially trying to compress a swollen or bandaged foot into a tight shoe.* Insist on wearing a thick sock. The best dressing substance is magnesium sulphate and glycerine paste, or simple syrup.
- (6) *Avoid hot water bottles on ischaemic cold feet, as burns are easily caused.*

### 'PRE-ULCERS'.

Try to recognize a 'pre-ulcer foot', because from 3days to 3wks of immediate bed rest at this stage may prevent a serious ulcer forming. Look for:

- (1) swelling of the sole,
- (2) separation of the toes (32-24C),
- (3) necrosis blisters at the side of the foot, caused by fluid which has tracked from the necrotic area above the plantar fascia (32-24E,F),
- (4) 'hot spots' (32.11),
- (5) redness,
- (6) pain (if there still is any sensation), especially pain on deep pressure.

### NEUROPATHIC FEET AT RISK

(A) **LOW RISK FOOT** is anaesthetic, but has little or no scarring. It needs protection and a resilient sole. The possibilities include:

- (1) A resilient insole in a shoe, which is one size larger than one usually worn. This may be enough. *Do not make the insole too thick*, and make sure the shoe is well fastened, so that it does not slip and produce blisters.
- (2) A car-tyre sandal with an insole of microcellular rubber.

(B) **MODERATE RISK FOOT** is anaesthetic, has multiple scars, and has lost some of the subcutaneous fat pad on its sole.

A shoe for a foot like this needs to be moulded, to take the weight off the metatarsal heads, and spread it evenly over the entire sole. Such a foot will however do fairly well in a simple car-tyre and microcellular rubber sandal, if the corn is kept well pared down. Or, make a piece of moulded 'Plastazote' as described above.

When the base has set firm, build microcellular rubber up underneath it, and then fit this to a car-tyre sole. If it is made as a sandal, it will need a retainer for the heel moulded into it. A shoe with a moulded sole is better than a sandal at preventing the foot slipping out, but it must have a well-fitting upper with buckles, laces, or straps, so that it remains in its correct relationship to the foot.

(C) **HIGH RISK FOOT** has, in addition, a mild deformity, such as flattening of the arches, and shortening, or loss, of toes.

It needs a shoe which is moulded to conform to it completely, and has a rigid sole. Build microcellular rubber up under a sole of moulded 'plastazote', and carve a wooden rocker clog to fit it; then fit this with a hard rubber sole. A clog is rigid, so its front end must be boat-shaped (32-22G). Some of these feet do well in microcellular rubber sandals, if their owner looks after them carefully.

(D) **DISINTEGRATED FOOT** has a major bony deformity such as fragmentation of its tarsal bones, or is 'boat-shaped', (32-24K) or has a dislocated ankle.

Rehabilitation is difficult; reconstructive surgery and an adapted orthopaedic boot (32-13B) may be necessary.

### PROTECTIVE FOOTWEAR

Instruct a cobbler to make the footwear described above, and to follow the local styles as much as possible.

Make the straps broad, and adjustable with buckles or laces, so as to allow for swelling or bandages. The simplest protection for an ulcerated foot is a metatarsal bar, stuck or sutured to the outside of the sole, just behind the metatarsal heads (32-22N).

#### CAUTION!

- (1) *Never use nails or wire to make or repair shoes:* glue and sew them.
- (2) If the foot is significantly supinated or pronated, only major surgery will allow satisfactorily walking.
- (3) New shoes need special care. Warn the patient to walk short distances only until the leather has become adjusted to the foot; meanwhile he should use the old ones most of the time.

### PROTECTIVE FOOTWEAR IN NEUROPATHY

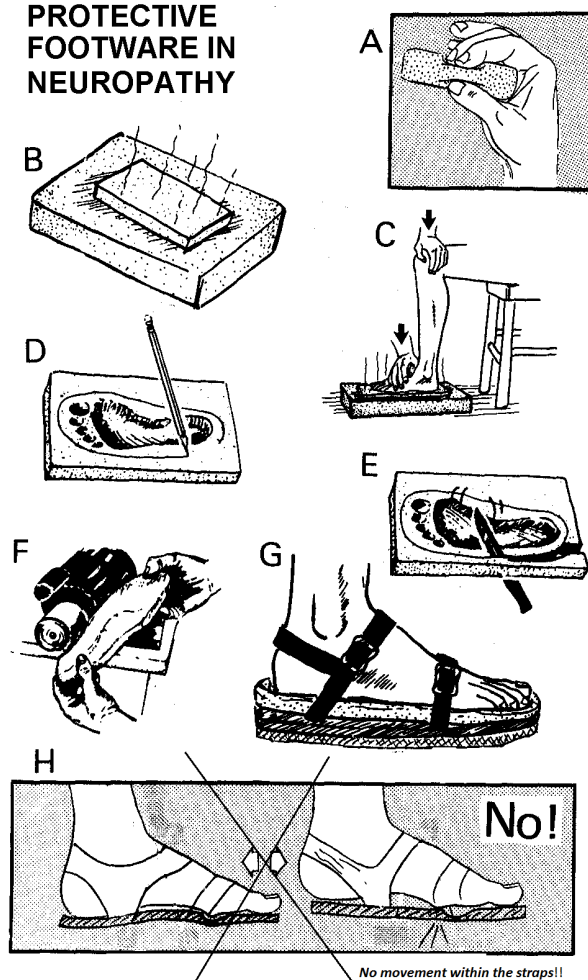


Fig. 32-23 PROTECTIVE FOOTWEAR IN NEUROPATHY.

A, right kind of microcellular rubber can be squeezed to half its thickness; if it is flatter than this it is too soft, if it is thicker it is too hard. B, sheet of hot 'plastazote' laid on soft foam. C, take the mould by applying even pressure and holding it for 3mins. Mark it out (D), and cut it (E), so as to project 0.5-1cm in front of the toes and behind the heel. Shape it (F), smooth it on a polishing disc, and support it with a layer of microcellular rubber and stick it to a hard rubber sole. G, completed shoe made from moulded 'plastazote' supported by layers of microcellular rubber, and soled with car tyre. H, the moulded shoe must be anchored to the foot and must not be allowed to move about.

After Brand P. *Insensitive Feet: A Practical Handbook on Foot Problems in Leprosy*. Leprosy Mission International, with kind permission.

## PARALYSIS OF THE FEET

**If there is a posterior tibial nerve palsy**, either:

- (1) Apply a firm bandage to limit friction at the back of the ankle. Combine this with a heel retainer, to minimize the use of the small muscles of the foot, and trauma to the anaesthetic sole; or,
- (2) Apply a padded plaster boot.

**If there is an acute common peroneal nerve palsy**, producing a flapping gait and foot drop, passive exercises will help to stretch the Achilles tendon and prevent a contracture:

- (1) Advise squatting with the heels flat on the ground.
- (2) Advise standing erect about 70cm from a wall, to keep the feet flat on the ground, and with the palms of the hands flat on the wall to do 'press ups' in the vertical position.

Some protective device is also necessary, with:

- (1) During the day, fit a toe-raising spring (32-22J). This will allow some work. By night, apply a posterior slab to hold the ankle in neutral position.
- (2) Or, apply a complete plaster cast, including the foot and leg up to the middle of the thigh, with 15° of flexion of the knee, and with the ankle in neutral position, taking care that the cast does not press on the nerve. Leave this on for 6wks.

**If there is a chronic common peroneal nerve paralysis**, he may be helped by lengthening the Achilles tendon, and transfer of the *tibialis posterior* tendon to the front of the foot to make it into a dorsiflexor (32.13). If this is impossible, or while waiting for surgery, fit a toe-raising strap.

**If there is also plantar ulceration with the foot drop**, be sure to use a posterior slab or a cast. If the ankle is not supported, the Achilles tendon is likely to contract on bed rest. Provide crutches while the ulcer heals, so that there is never any pressure applied on the ulcer.

**If there are clawed toes**, transfer the *flexor longus* tendon to the extensor expansion on each toe (32-27N,O).

## FIND OR TRAIN A CAPABLE SHOEMAKER TO HELP YOUR PATIENTS

### 32.12 Foot ulcers

An uncomplicated ulcer is only skin deep, does not involve bone or deeper structures, and usually heals easily if the patient rests the leg. A complicated ulcer has involved the bone underneath it. It has a deep sinus, or marked infection, and is much more difficult to heal.

The Wagner classification describes different stages:

I	simple ulcer
II	with cellulitis
III	with bone involvement
IV	with spreading infection
V	with gangrene

Simple plantar warts or corns from ill-fitting shoes can result in ulceration, especially if the patient cannot feel the discomfort properly. *Do not use LA to cut out plantar warts and shave corns*; you may go too deep and the injection is anyway usually unhelpful and more painful than the procedure!

Ulcers in a neuropathy patient are almost inevitable:

Help the patient himself to find the cause of the injury. Never let him accept that the cause was the disease. Was it caused by repeated stress, or by a blow, a puncture, or a burn? Concentrate all your educational energies on him. You can do much more for a patient with the 1<sup>st</sup> ulcer, than for one whose foot is already mostly destroyed.

If you can find some way of resting an ulcer it will usually heal. This means that the patient must 'not take one step' on it, until it has finally closed over, and all the scabs have fallen off. If it is uncomplicated, this takes 4-6wks. You can:

- (1) Try bed rest. Unfortunately, this is rarely successful because staff often do not understand fully the need for rest and neither explain or encourage this and there is no pain, and thus there is little incentive to stay in bed.
- (2) Allow the use of a splint and crutches continuously until the ulcer has healed. This is unlikely to be successful unless you educate and supervise the patient carefully.
- (3) Make a special curative shoe, with a rigid rocker bottom, and a specially moulded surface for the sole of the foot. This needs much skill, and is not described here.
- (4) Put the foot in a cast.

*N.B. Antibiotics are of no use.*

A plaster cast is one of the most practical ways of resting an ulcerated foot. It immobilizes the foot, it spreads the strain of weight-bearing, it is quick to apply, and it is easy and effective. You can apply one in a remote clinic and send the patient home, provided you tell him that he must absolutely avoid walking on the foot. If you apply a cast on the indications listed below, it will usually allow an ulcer to heal in 6wks.

Unfortunately, although resting a foot in a cast may heal an ulcer, it weakens the bones and ligaments, despite continuing walking in it. Bones only retain their normal strength if they are regularly used. Rest causes them to lose their minerals, and ligaments to lose their strength. The result is that when the cast is finally removed, the patient may be delighted to find that the ulcer is healed, but he may not realize that anaesthesia is preventing him from experiencing the stiffness and pain that protects a normal foot. Consequently, he may be tempted to use the anaesthetic foot too vigorously, with the result that it dislocates, or its tarsal bones fracture, and he ends up with a worse neuropathic foot. So use casts cautiously and remember their risks. When you remove one:

- (a) warn of the sad consequences of energetic early exercise,
- (b) start a programme of 'walking training', which will in a slow return to full activity during 7-10days,
- (c) be sure that to teach 'self care',
- (d) be sure also to watch carefully for 'hot spots' (32.11),
- (e) *most importantly*, supervise the patient for at least 1wk after you remove the plaster.



Bone damage is common, and serious, and may be the result of:

- (1) Sepsis spreading from an ulcer, particularly if the patient walks on it.
- (2) Mechanical strain, which is particularly likely to occur when the protective mechanism of pain is absent.
- (3) Disuse atrophy in bed, or in a plaster cast.
- (4) Osteoporosis, which may predispose to fractures.

*Get a radiograph of the foot early.*

The best way to minimize bone damage is to treat ulcers carefully, so that bone is not damaged in the first place. There are however also some additional principles:

- (1) Keep the weight-bearing surface of the sole as large as you can.
- (2) When you remove bone surgically, *do not do so unnecessarily*. Make sure it really is dead or infected. Dead bone is usually grey or black; it has no periosteum, and so feels rough to a probe. When you nibble it with forceps its fresh surface is pale, and not pink. Ideally, you should allow a *sequestrum* to separate before you remove it, but this takes 8-12wks, during which time the ulcer will not heal. You can shorten this time by removing dead bone.

When bone has been damaged, clean up the mess it has caused. For example, if there is a deep sinus under an ulcer with bone involvement, rest the leg for a few days to localize the infection.

Then remove the dead soft tissue and bone; perhaps one or more metatarsal heads, leaving the toes if you can.

The short *equinus* foot of leprosy is one of its end results, and is due to the absorption of bone, which may be due to: (1) Neglected ulcers and infections.

(2) Paralysis of the extensor muscles.

(3) Unduly radical surgery. Muscle imbalance may pull the heel up too much, or push the forefoot down too much, so that it increases the pressure on the metatarsal heads, and so causes worse ulceration and more shortening.

A boat-shaped foot is another of the late effects of neglected leprosy. The arch is destroyed, and instead of being concave, it becomes convex, often with ulcers and bony spurs on the convexity.

## MANAGEMENT OF ACUTE ULCERS

Insist on bed rest. Splint the foot and raise it to encourage drainage and prevent oedema. This is much the best treatment. Ambulant treatment seldom works. Forbid all walking except with crutches to reach the toilet. If necessary, fix a piece of wood to the dressings (32-26B) to prevent walking! *Do not apply a walking cast!*

## PLANTAR ULCERS WITH NEUROPATHY

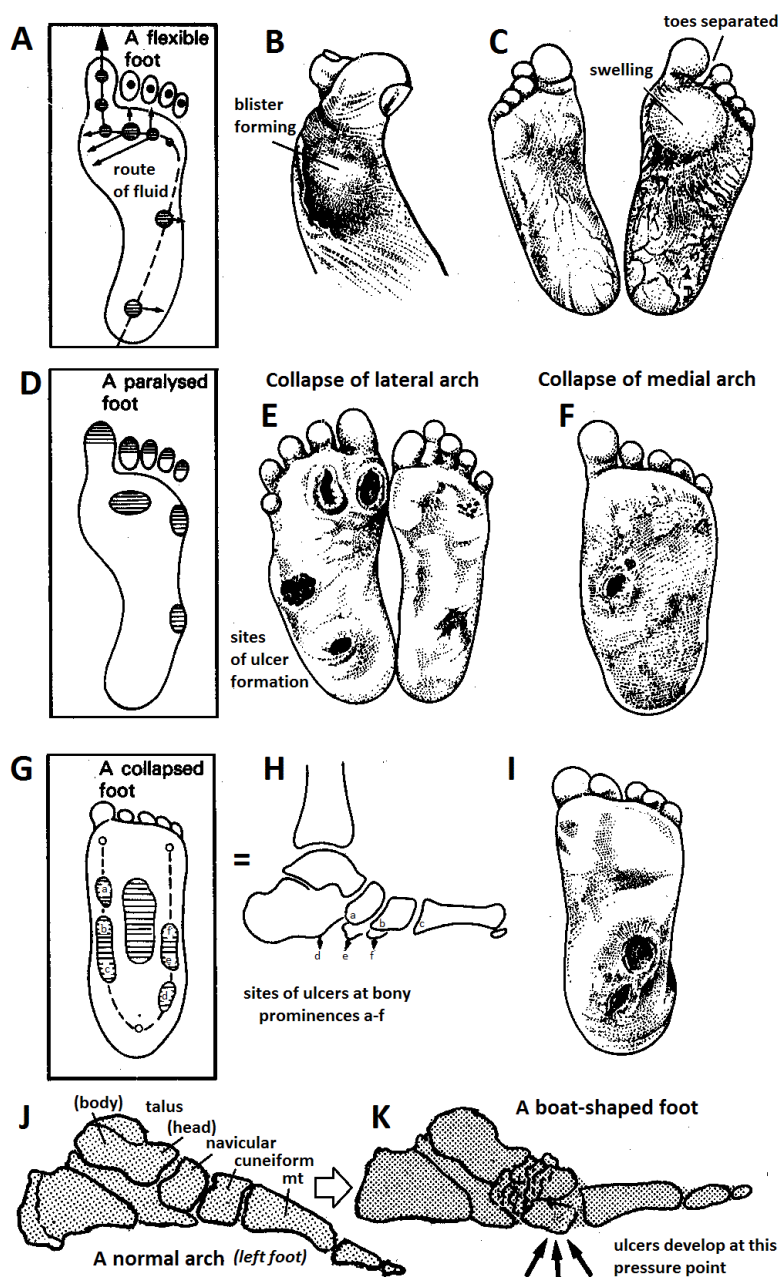


Fig. 32-24 PLANTAR ULCERS WITH NEUROPATHY.

A, where ulcers form in a flexible anaesthetic foot with intact muscles; the arrows show where fluid may track and B, where blisters form. C, fluid is forcing the toes apart and collecting under the ball of the foot. D, sites where ulcers form in a paralysed foot. E, if there is a peroneal nerve palsy, ulcers develop at the lateral side of the foot; if there is a complete foot drop the ulcers are anterior on the ball of the foot, under the metatarsal heads, or on the toes. F, if the medial arch collapses, the ulcers develop on the medial side. G, sites of bony prominences (a-f) in a collapsed foot, where ulcers form. H, the flattened radiographic appearance. I, shows the same foot with a collapsed arch. Each of its bony prominences (a) to (f) has produced an ulcer. J, 2 ulcers in just such a foot. J, radiology of a normal arch in the left foot. K, boat-shaped foot: the arch is reversed and ulcers form under the 'keel' of the boat.

After McDowell F, Enna CD, *Surgical Rehabilitation in Leprosy*. Williams & Wilkins 1973 Figs. 40-1,2,9, with kind permission. J,K, kindly contributed by Grace Warren.



Local applications to an ulcer make little difference, so there is no need to change dressings at frequent intervals. Dress the ulcer 2-3 times/wk with hypochlorite ('Eusol'), hypertonic magnesium sulphate, sugar (which is best used daily, honey, ghee or some mild antiseptic). Or, soak it, scrape it regularly to remove excess corn, oil it, and dress it daily. When the discharge stops, you can apply a cast, leave the dressing unchanged for 6 wks, and send the patient home, making sure he has learnt self care. If there is fever and other signs of generalized infection, such as a profuse discharge, or tender groin glands, use an appropriate antibiotic and elevate the leg.

**CAUTION!** *Antibiotics have no place in treating uncomplicated ulcers: what they need most is rest!*

When the acute stage is subsiding, and there is no sign of spreading infection, explore the ulcer with a sterile blunt probe to find out if there is exposed bone in its base.

**If bone is exposed**, feel if there are any loose pieces or sequestra, and remove them. Pack the ulcer with hypochlorite until it is healing well, and continue to rest the leg.

**If bone is not exposed and infection is controlled**, continue bed rest with a splint and crutches until the ulcer heals.

Probe ulcers: if you reach bone, the chances of osteomyelitis being present is c.70%.

*Pus swabs are, however, no help.*

#### A SHORT LEG WALKING CAST INDICATIONS.

A chronic *non-inflamed* ulcer, whose base is visible without any necrotic bone, tendon, or other dead or infected tissue, which you must remove before applying the cast.

#### CONTRAINDICATIONS.

- (1) Signs of inflammation or infection: heat or oedema of the dorsum opposite the ulcer, excessive discharge, or regional adenitis.
- (2) Involvement of a joint or synovial sheath (synovial discharge).
- (3) Dead bone or tendon or capsular sloughs in the base of the ulcer.
- (4) A long deep sinus with small openings whose base you cannot see.

#### METHOD.

Normally leave the toes will be open, unless you have to keep out stones and sand.

Measure the feet for shoes before applying the cast: when you finally remove it, allow no single step without these shoes being worn. Shape the Böhler stirrup (32-25D, walking iron) to the leg before you apply the plaster.

Dress the ulcer with dry gauze or a simple ointment. Cover, but *do not pack the wound*; discharge must be able to escape easily. Apply stockinette, a nylon stocking, or an evenly applied gauze bandage.

*Do not apply excessive padding to bony prominences.*

### A PLASTER CAST FOR NEUROPATHY ULCERS

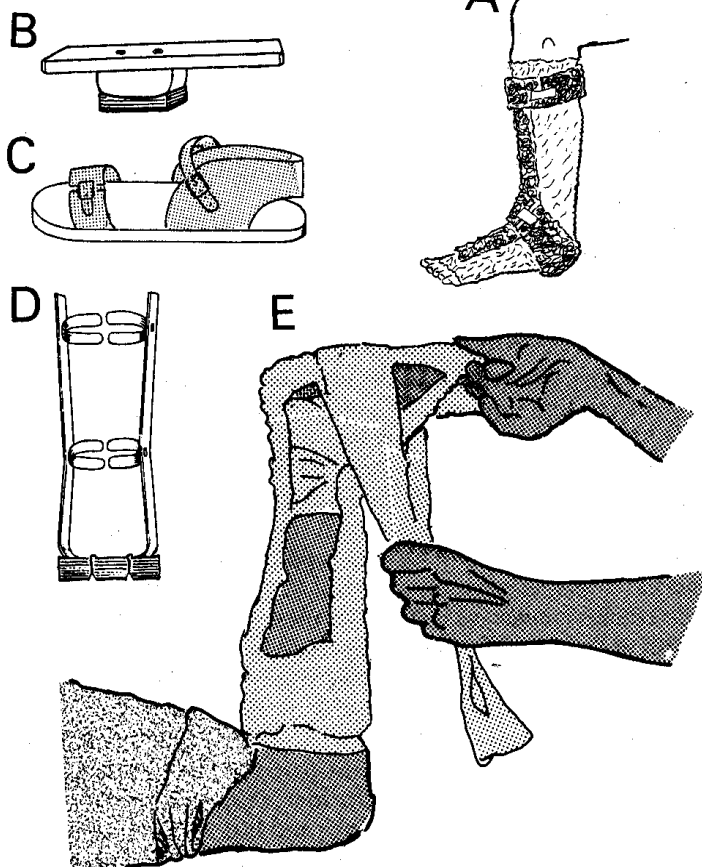


Fig. 32-25 A PLASTER CAST FOR NEUROPATHIC ULCERS.

A, put extra padding as shown under a plaster cast. B, wooden rocker shoe with car tyre. This has a single bar. If a patient has casts on both legs, double bars on the rockers will enable him to walk more easily. C, rubber-soled sandal with plastic straps to wear over a plaster cast. D, locally made Böhler walking iron shoe with car tyre. E, apply the cast in the prone position. Ask your assistant to hold the toes up and to pull downwards on a loop of bandage placed as shown. This will flex the ankle, and help to form a better arch if one is needed. Apply the plaster over the bandage.

*Kindly contributed by Grace Warren.*

Use strips of adhesive tape to fix 3 strips of padding (32-25A), but *do not apply the tape directly to the skin*. If you do not have padding, use many layers of bandage instead.

Use the prone position with the knee at 90° and the leg vertical. Apply a thick layer of plaster to the leg without pressure. End the cast 5 cm below the head of the fibula, to avoid pressure on the common peroneal nerve, and leave the toes open. Apply a back slab and circular reinforcing layers. Then fit a Böhler iron or a walking board (32-25B, wood with a piece of car tyre). Let the cast get completely dry before weight is placed on it.

Alternatively, a thin well-moulded layer of plaster, covered by a layer of fibre glass, will make a more long-lasting cast. Preferably, use fibreglass tape rather than sheet, because it lasts longer.

**CAUTION!**

- (1) *Do not mould the cast under pressure to obtain the required position, or you may cause ulcers and gangrene.*
- (2) Ask an assistant to hold the ankle at exactly 90° or slightly dorsiflexed (32-25E), until the plaster has set; *it must not be plantar-flexed or inverted or everted.*
- (3) *Do not press into the plaster with your fingers, because you may produce pressure points where more ulcers will develop.*
- (4) Remember that no pain is felt. A wrongly applied cast may cause ulcers! *So do not apply excessive pressure over a tight bandage.*

**If there are ulcers on both feet,** a wheel-chair may be necessary. If the patient has to crawl, provide 'hand sandals' to protect the hands. Make these with a piece of microcellular rubber, and give them a single strap. Incorporate a rocker bar in the plaster to take pressure off the ulcer site. If there are casts on both feet, double bars on walking boards will allow walking. Alternatively, make cushioned wooden rockers on a flat board and sandals to go over them.

Leave the cast on for 6wks. Remove it earlier if there are signs of infection (smell, discharge, pain). When you remove it, the shoe that you measured earlier should be ready. Make sure that there is a period of 'walking training' before resuming full activity. Apply a firm bandage, and start walking in a carefully graduated way. Check the foot for swelling or an increase of temperature. Rest it again if signs of inflammation return. Advise walking as little as possible, to take short steps, and to avoid uneven ground, sudden strains, and long walks.

**If the ulcer has not completely healed in one cast,** apply another.

**BONE INVOLVEMENT****INDICATIONS FOR REMOVING BONE.**

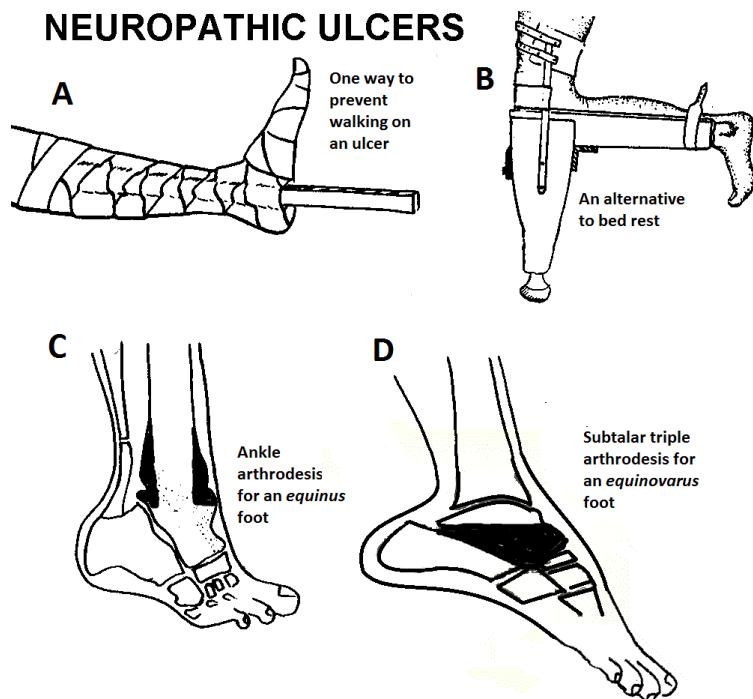
- (1) There is osteitis.
- (2) It is loose.
- (3) It is projecting into a septic cavity with no obvious blood supply around it.
- (4) It is projecting after an ulcer has healed, so that it forms a pressure point; if so cut it horizontally.
- (5) One metatarsal is obviously longer than the others, and the skin over it is ulcerating. Apart from the first metatarsal, which may usefully be longer, the others should all be on the same line across the foot, so that walking is possible without one sticking out prominently and taking extra stress.

**METHOD:**

Use appropriate antibiotics pre- and post-operatively. Apply a tourniquet (3.4), try to loosen the bone, and cut it off at the line of separation. If this line has not yet formed, nibble it at the point where you see the periosteum is adherent again.

**CAUTION!**

- (1) *Do not remove bone from the base of an ulcer unnecessarily, especially in the heel.*
- (2) Probing an ulcer will tell you if bone is exposed, but *not if it is dead.* Exposed bone may be healthy, but the soft tissues will take time to grow over it.
- (3) *Never strip periosteum unnecessarily, because this may kill the bone under it.*

**METHODS FOR NEUROPATHIC ULCERS**

**Fig. 32-26 METHODS FOR NEUROPATHIC ULCERS.**

A, one way to prevent walking on an ulcer while it heals is to bandage a wooden bar to the leg. This is only suitable for short periods. B, an alternative to bed rest is to provide a walking prosthesis like this. C, if all else fails, for an *equinus* foot, try to arrange an ankle arthrodesis: the malleolar parts of the fibula and tibia and parts of the talus are sawn off and used as bone grafts to fix to the talus internally. D, for an *equinovarus* foot, arrange a subtalar triple arthrodesis where a wedge of bone from the talus, calcaneus and navicular is removed to get the foot into dorsiflexion. A,B, after Brand, P. *Insensitive Feet, A Practical Handbook on Foot Problems in Leprosy*, Leprosy Mission International with the kind permission. C,D, after Fritsch, E. P. *Reconstructive surgery in leprosy*, Wright 1971

**DIFFICULTIES WITH NEUROPATHIC FEET  
FOOT DIFFICULTIES****If bed rest is impractical:**

- (1) Provide a splint and crutches, and avoid weight-bearing on the foot with the ulcer. The splint may be plaster (expensive and short-lasting), wood, plastic, wire (mesh fencing wire) but should last 6wks, or:
- (2) Attach a projecting bar to the foot (32-26A) and provide crutches.

**If a plaster cast for an ulcer is impractical, you can:**

- (1) Fit the kneeling leg prosthesis (32-26B), which is suitable for limited activity only.
- (2) Fit a 'healing shoe' which is less cumbersome than a cast, but also less effective.

It must have (32-22I):

- (a) a rigid sole with a central rocker,
- (b) an insole (ideally 'plastazote') moulded exactly to the shape of the foot,
- (c) an upper strapped round the foot and ankle, so that they cannot move in relation to the shoe.

**If the ulcer recurs**, check the way the patient cares for his feet. Does he inspect them and soak them daily and remove rough corn? Look at the shoes:

- (1) Is there increased pressure in some area which has caused necrosis?
- (2) Are the straps so loose that they allow movement of the foot inside the shoe, or so tight that they cut into skin?
- (3) Can the contour or fit of the shoes be improved?
- (4) Does the patient always wear the shoes?
- (5) How far does he walk without resting? Can he walk less, or walk with less pressure on the ulcer, or more slowly?

There are 2 possibilities:

- (1) You may be able to excise the ulcer, and all the scar tissue under it, and then graft it with split skin. This may provide a more suitable bed for the regrowth of subcutaneous tissue than the original scar tissue.
- (2) You may rarely be able to excise the scarred area, and close the gap you have made with monofilament sutures. This means an initial relieving incision on the dorsum or side of the foot, and packing the cavity till healing occurs from the base of the wound. Use honey or other suitable dressings (34.9).

**If the metatarsal heads protrude**, shave them off.

If the feet are well cared for and the right shoes are worn, the ulcer should not break down again. If it does, there is some underlying abnormality, such as:

- (1) Chronic osteomyelitis in of the bone under the ulcer. Remove sequestra surgically (7.5).
- (2) A protruding bone spur which needs excising.
- (3) A thick scar which splits under tension with walking.
- (4) Inadequate subcutaneous tissue over the metatarsal heads.
- (5) Malignant change in the ulcer (34.5).
- (6) Claw toes which repeatedly ulcerate.

**CAUTION!** When you treat ulcers avoid cutting into living bleeding tissue unless it is to:

- (1) Open an abscess.
- (2) Improve drainage from a deep sinus.
- (3) Remove necrotic tendon, muscle, or bone.
- (4) Remove a free lying sequestrum (7.5).
- (5) Remove bone that is so placed that healing and normal function are mechanically impossible.

**If there is an ulcer on the lateral border of the foot** (32-24E), it is likely to be associated with peroneal nerve paralysis (32.11). Treat it by bed rest and splints or casts. When it has healed a toe-raising strap attached to the area of the 5<sup>th</sup> metatarsal head may help to prevent recurrence.

**If you suspect infection under an ulcer in the middle of the lateral border**, surgically pare down the cuboid or the base of the 5<sup>th</sup> metatarsal, and removing any infected tissue. Make a dorsolateral incision, which leaves a sufficient bridge of tissue between the incision and the ulcer. Turn back the infected tissues by subperiosteal dissection, trim the bone, remove necrotic tissue, excise the ulcer with an elliptical incision on the sole.

When the wound is clean, try primary closure with monofilament to achieve healing of the plantar wound without a large scar which might ulcerate again. You can allow the dorsolateral wound to close by granulation if you cannot easily close this. *Do not let it close if the depth of the cavity is not clean.* A toe-raising spring (32-22J) may help to prevent recurrence.

**If a terminal phalanx becomes visible in an ulcer at the tip of a toe (or finger)**, nibble it away with a bone nibbler. If it is badly infected, disarticulate it. If necessary, use a fish mouth incision over the top and down the sides, which will leave the pulp intact.

**If you remove part or all of the middle or proximal phalanges**, approach them through incisions at the sides of a toe (or finger). If the remaining toe is stiff, awkward or painful, amputate it (35.7).

**If bone is exposed under a heel ulcer**, be very careful about removing it from the calcaneus: you can easily remove too much, and a foot without a heel can be a problem. Patients can however walk on very little calcaneus or even none, if you provide them with a rubber heel-pad. Try conservative management with special footwear and daily skin care. A normal calcaneus has a spur which projects forwards along the line of the plantar ligaments parallel to the ground; this is harmless.

#### EXCISION OF A CALCANEAL SPUR (OR OTHER BONY PROJECTION) (GRADE 2.1)

**If there is an abnormal residual bony spur** on the under surface of the calcaneus or elsewhere, associated with an ulcer, projects vertically downwards, remove it. Spurs may form under any prominent bone in a boat-shaped foot. Irregular bone may also develop because of a fracture or an infection. *Do not remove these bony projections through the ulcer*, because this will make the plantar scar bigger. Instead, paint the ulcer edge with gentian violet. Then make an incision round the back or lateral side of the heel (32-27B), so as to avoid the medial calcaneal vessels. Deepen the incision to the bone (32-27C), and lift the heel pad off the bone by clean sharp dissection. Continue the incision, so as to raise a flap of heel and plantar fascia, and mobilize the ulcer. Then excise and suture it as described above (32-27D). Trim the calcaneus with an osteotome to leave a flattened surface. *Do not remove bone unnecessarily*, or leave new sharp edges or corners to form new ulcers.

**If there is a short foot**, examine the patient carefully to see if the heel is taking its proper share of weight. *You can easily miss foot drop in a short foot.* Ask him to walk on his heels; if he cannot do so, some of the muscles are weak. Lengthening the Achilles tendon may help, even to the point of making the calf muscles useless, because this will make him walk mainly on the heel, and less on the front of the foot. If there is definite paralysis of the dorsiflexors, he will be better off with a tendon transfer (32.13). If this is not practical, fit him with a toe-raising spring (32-22J).

**If where there is muscle weakness, the tarsal bones disintegrate**, you may find this in any of 3 stages.

(a) 1<sup>st</sup> stage: the foot is hot, it may be swollen, but its shape is unchanged. Raise the foot to allow swelling to subside.

(b) 2<sup>nd</sup> stage: the foot is still hot with active bone disintegration; its shape becomes abnormal, and it may be hypermobile. Raise it in a splint for 3 days to reduce swelling. Then use the prone position (32-25E) and mould the foot into as functional a position as you can, accentuate its arch as much as possible, and apply a cast. Leave this on for 6-12 months, and then mobilize with care.

(c) 3<sup>rd</sup> stage: the foot is no longer hot, showing that the bone lesions are no longer active. If there are rough bones, which will be likely to cause ulcers, trim them. A high-risk shoe (32-22I) may keep the foot ulcer-free. An arthrodesis (32-26C,D) may then be needed, after which a walking cast for 6-9 months is necessary. Hopefully, the foot will revert to the 'moderate risk' class; if it does not, a special prosthetic shoe or brace will be necessary long term. Many of these patients can manage to live well in a simple sandal, with daily skin care.

**If there is an old fixed deformity which cannot be altered**, supply a special moulded high-risk shoe till you can arrange reconstructive surgery.

**If there is no practical way to establish a good arch**, at least try to get its bones healed and sclerosed. If the arch of the foot becomes completely flat, it should remain ulcer-free, but if the bottom of the foot becomes convex and boat-shaped, it will be more likely to ulcerate. If the talus and calcaneus are totally destroyed, perform an amputation (35.7).

**If clawed toes develop**, stage them, as ulcers are often associated, and treat as follows:

GRADE 1	GRADE 2	GRADE 3
Weak intrinsic muscles, mobile toes	Limited movements of toes	Fixed toes ± dislocation of mtp joints
No contractures	Moderate contractures	Severe contractures
Flexor tendon transfer	+ Excision metatarsal heads	+ ≥1 phalanx amputation, or transmetatarsal amputation

*N.B.* For seriously clawed toes, you may have to remove at least one phalanx, or the metatarsal head, or both to straighten them. If the remains of the toes will not bear weight, because they are so badly scarred, perform a transmetatarsal amputation (35-23).

**If squamous carcinoma develops in a long-standing (Marjolin's) ulcer**, the alternatives are local excision and amputation. You may be able to excise smaller lesions that do not involve bone, and are distal to the midfoot (34.5).

## ANKLE DIFFICULTIES

**If there is an irreducible dislocated ankle or a fixed ankle deformity**, a correction is necessary.

**If there is an equines or equinovarus foot**, walking may be satisfactory, but elaborate footwear is necessary to prevent ulcers recurring. If walking is difficult, and particularly if there is fixed plantar flexion or inversion, an ankle arthrodesis (32-26C,D) is necessary. Afterwards, an ordinary high moulded shoe, or a sandal of microcellular rubber, may be adequate to prevent ulcers.

**If the foot is pronated**, a simple canvas tennis shoe may be enough. If not, a surgical correction is necessary. Afterwards, an ordinary high moulded shoe (32-22I) or a sandal of microcellular rubber (32-22F) may be enough to prevent ulcers.

## SEPTIC DIFFICULTIES

**If there are signs of an acute infection with lymphadenitis**, treat with rest, cloxacillin or another suitable antibiotic, and if necessary, drainage. *There may not be a neuropathy*, and the foot may merely have a soft tissue infection.

**If heat and swelling rapidly return and persist**, there is active pathology, so apply a cast for 6 wks, repeat the radiograph and plan treatment accordingly. After this interval stress fractures and other bony lesions will have caused enough osteoporosis to be seen radiologically. If you are in doubt, or have no radiographs, suggest another trial of walking.

**If in a case of leprosy, heat and swelling return a 2<sup>nd</sup> time**, bone disintegration is highly likely; so reapply a well fitting walking cast for 6-12 months, depending on its site and severity.

**If there is septic arthritis in a toe ip joint**, excise it through a dorsal incision, remove the remains of its ligaments and cartilage, pack the cavity, and keep the toe straight at its ip and mtp joints: this will produce a fixed toe.

**If septic tenosynovitis complicates an ulcer,** draining the tendon sheath may assist healing. Drain it through an incision along the arch of the foot. Clean out all the infection, as far back as is necessary to find and remove the infected tendon stump. Close the skin with monofilament, so as to leave the smallest possible scar on the weight-bearing area. Leave both ends open, so that you can irrigate the lesion until it is clean. Allow it to heal by secondary intention.

**If a septic toe requires amputation,** use a racquet incision on the dorsum (35-24), leave the metatarsal head, and only resect the surface cartilage if there is septic arthritis of the mtp joint. Drain or pack the wound dorsally.

**If plantar ulceration results in osteitis of a metatarsal head,** you may need to excise it (32-27I). This will move the weight-bearing area proximally, so that more ulceration is likely. If you can save a toe in good position, it will help to protect the area of the new 'metatarsal head'. If you can save the distal part of the first toe, it will help to protect the second metatarsal head, which may otherwise soon ulcerate. Sometimes, you may have to remove several metatarsal heads. Do this through dorsal longitudinal incisions between them. If there are plantar ulcers over the metatarsal heads, excise them, and close the incisions in the sole with monofilament. Leave drains or packs in dorsally.

#### OPERATIONS ON THE FEET IN LEPROSY

Most leprosy ulcers do not need an operation, but there are some simple operations which you should be able to do. Try to correct clawed toes, because they predispose to ulcers at the tip of a toe, on the knuckle, and under the metatarsal head. Apart from the correction of clawed toes, most other tendon transfers are work for an expert. The only other possible exception is a *posterior tibialis* transfer for foot drop (32.13).

#### FOOT OPERATIONS FOR LEPROSY ULCERS

##### EXCISING AN ULCER OR SCAR ON THE SOLE

You may be able to close the gap you have made by primary closure. To do this, excise the ulcer with an elliptical incision, and close the wound with deep mattress sutures (4-8) of '0' monofilament to eliminate dead space. Keep the wound dry, and leave the sutures in for 2wks. If you can only close an ulcer under excessive tension, perform a Z-plasty (34-4). Loosely pack the dorsal incision, and leave it to granulate as described below. Make sure the bridge of skin, between the ulcer and the relieving incision, is adequate to maintain the circulation.

**CAUTION!** Only close clean surgical incisions by primary suture. Even some of these need drains to minimize haematoma formation. Remove the drains after 48hrs.

**If there is deep infection,** pack the wound and use honey or similar hygroscopic substance (34.9), till the wound is clean.

**If there is a deep ulcer with a sinus track,** outline this with gentian violet. Cut away all the violet-stained tissue, so that you remove all the infected areas.

**If there is osteitis,** excise or curette the sinus tracks and insert a pack.

#### EXCISING AN ULCER ON THE HEEL

**If osteitis is already draining through the centre of the heel,** curette and pack the lesion, without trying to excise the ulcer. Stop all weight-bearing until the ulcer is healed. provide a splint. When the infection is controlled, trim any rough bone. As soon as the osteitis is controlled, excise the ulcer scar and pack the lesion laterally till it is clean. *Do not allow walking on trimmed bone* for 6wks, or until the wound is fully healed, and the scabs have fallen off. Heel skin is specialized, so try to obtain primary closure. Make a 'fish mouth' relieving incision around the back or lateral margin of the heel (32-27B), then dissect to lift the heel pad off the calcaneus (32-27C), in order to be able to close the plantar defect.

#### SPECIAL OPERATIONS FOR LEPROSY

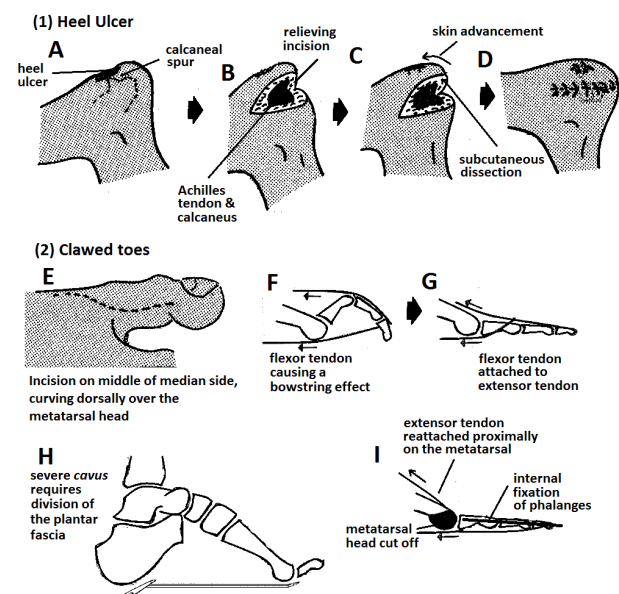


Fig. 32-27 SPECIAL LEPROSY OPERATIONS.

A, heel ulcer (with calcaneal spur shown). B, relieving incision in posterior heel skin taking care not to cut the Achilles tendon. C, dissection of the heel pad off the calcaneus to allow primary closure of the heel ulcer. D, finished result. E, incision in the middle of the medial side of a clawed toe curving dorsally towards the metatarsal head. F, the flexor tendon divided distally, and G, re-attached proximal to the pip joint onto the extensor tendon. H, if there is severe *cavus*, make a small incision over the attachment of the plantar fascia to the calcaneus and divide the tissue until you can flatten the foot. I, if the metatarsal head protrudes, and the clawed toes are immobile, remove the head and divide the extensor tendon and re-attach it proximally on the dorsum of the metatarsal. Take care not to damage the plantar skin if it is still viable. Fix the phalanges with a K wire for 6 weeks to keep them straight. You may transfer the flexor tendon as in G if it makes a bowstring. After Brand P. *Insensitive Feet, A Practical Handbook on Foot Problems in Leprosy*, Leprosy Mission International & F.G.H.I after Apley AG, Solomon S. *System of Orthopaedics & Fractures* Butterworth 6<sup>th</sup> ed 1982 p.315. E, kindly contributed by Grace Warren.



### TENDON TRANSFERS FOR CLAW TOES (GRADE 2.4)

This operation allows the toes to take more part in weight-bearing, and so protects the metatarsal heads. *It is not applicable where toe joints are fixed.*

#### INDICATIONS.

Mobile clawed toes.

#### METHOD.

Using a tourniquet, incise along the midline of the medial side of the middle and proximal phalanges of the toe whose tendon you want to transfer. Proximally, curve the incision dorsally to reach the dorsum of the foot at the distal end of the web (32-27E). Find the long flexor at the dip joint. Hold it in forceps, and cut it distally (32-27F). Cut the flexor sheath back to the middle of the proximal phalanx.

Lift the skin and soft tissue off the dorsum of the proximal phalanx and pip joint, and transfer the long flexor tendon so that it runs diagonally across the proximal phalanx, and reaches the long extensor tendon of that toe, and attach it there onto the long extensor tendon, proximal to the pip joint (32-27G). (Transferring the *flexor digitorum longus* at this level will keep it as a flexor of the mtp joint, but makes it an extensor of the pip & dip joints). Close the skin with monofilament. Splint the foot on a flat board for 6wks, and prevent walking.

**If there is severe *cavus*,** make an incision where the plantar fascia attaches the calcaneum, and divide the tissues at this point (the Steindler operation), so that you can get the foot flat. Close the incision with a few sutures. *Make sure the patient does not walk on the wound till it is well healed.*

### METATARSAL OSTEOTOMY, INTERNAL FIXATION & TENDON TRANSFER FOR CLAW TOES (GRADE 2.4)

#### INDICATIONS.

- (1) Stiff, clawed toes (especially >1)
- (2) Ulcers under the metatarsal heads.

Aim to reduce the scarred area, by shortening the metatarsals of one or all of the toes, so bringing the toes down to take some weight. Keep all incisions dorsal, and aim for a mobile pseudarthrosis, not an ankylosis. *Sepsis is not a contraindication*, if you leave the dorsal wound open and pack it, but try to get the operation site as clean as you can.

#### METHOD.

Over every stiff toe make a dorsal incision which is long enough for you to see the mtp joint, and 2cm of the metatarsal. Elevate the periosteum, and remove the metatarsal head with bone nibblers or cutters. *Take care to preserve all the viable plantar skin.* Smooth the remaining shaft with a small bone file or nibbler. You should now be able to straighten the toe; if it is still dorsiflexed, remove a little more metatarsal.

*Do not leave one metatarsal obviously longer than the others.* Excise any ulcers on the sole, as above, and close them when they are clean.

*Avoid damaging the proximal phalanges.*

or each toe, cut the branches of *extensor digitorum longus* and *brevi*s and re-attach the proximal cut end to the metatarsal. If the *flexor digitorum longus* tendons cause a bowstring effect, release them distally and anchor them over the proximal phalanges, as above.

Splint the toes straight by inserting a K wire through the distal toe pulp for 6wks.

If there is the slightest hint of infection, keep the wounds open and pack them daily till they are clean (34.9). *Make sure the patient does not walk on the wound till it is well healed.* After all the above procedures, try to prevent walking for at least 6wks. If absolutely necessary, use a walking cast, with the ankle in good dorsiflexion, and with sufficient plantar protection to stop trauma to the healing area. Leave the end of the granulating foot protruding for dressings.

**If there is marked osteoporosis,** apply a walking cast for 2-5 months to allow the damaged bones to recalcify, as they will do when infection is controlled. The bone may still look osteoporotic on a radiograph; but, provided walking resumes gradually, it should recalcify without breaking.

**If you are operating on the head of the 1<sup>st</sup> or 5<sup>th</sup> metatarsal,** do it in the same way. Make an incision on the medial or lateral side of the foot, but make sure there is enough width in the skin bridge to prevent it necrosing.

**If the soft tissue under the metatarsal heads has become so scarred that it constantly re-ulcerates,** remove all the metatarsal heads through dorsal incisions.

**If the foot has become shortened,** the toes may remain projecting, and make it difficult to fit a shoe, or they may be subject to excessive pressure. If so, amputate them (35-24).

**If the dip joints of the toes only are fixed, or they have repeated ulceration,** amputate them (35-24).

**If the foot is chronically scarred and ulcerated, and part of all the toes are lost, but there is good sole tissue proximally,** perform a transmetatarsal amputation (35-23).

CAUTION! *Foot operations leaving shorter stumps are prone to develop complications.*

**If the heel pad has some sensation and a good prosthetist is available,** consider a Syme's amputation (35-22): this is, however, too short and too small to be used for weight-bearing unless you can provide a good elephant boot.

### 32.13 *Tibialis Posterior* transfer for foot drop

A dropped foot, which a patient is constantly tripping over, is a great disability, but it is also a treatable one, whatever its cause:

(1) If there is a strong *tibialis posterior* and *gastrocnemius*, and a mobile ankle, you may be able to transfer the *tibialis posterior* tendon.

(2) If surgery is impractical, you can fit a toe-raising spring (32-22J), if necessary made with canvas or plastic straps, and using the rubber from an inner tube as the 'spring' or callipers (32-13), which will need careful fitting on an anaesthetic limb, if they are not to cause friction burns.

When the lateral popliteal nerve is paralysed, dorsiflexion of the ankle is impossible, so that walking is liable to injure the lateral side of the foot, the toes, and the ball of the foot. Severe ulcers and marked deformity may follow.

Transferring the *tibialis posterior* tendon to the dorsum of the foot will restore dorsiflexion of the ankle, and reduce the risk of ulcers. Remember that reconstructive surgery without physiotherapy is useless; train a physiotherapist yourself before embarking on this procedure.

*Tibialis posterior* and *gastrocnemius* are normally used together in walking. An important part of physiotherapy is education to separate these actions.

#### TIBIALIS POSTERIOR TRANSFER (GRADE 3.4)

*N.B.* This is different from the *tibialis anterior* transfer for relapsed club foot (32.10).

#### EXAMINATION.

Check the power of:

(1) The *tibialis posterior*. Test inversion of the foot against resistance (move it medially). The only other inverter is *tibialis anterior*, which is usually powerless or very weak in patients needing this transfer.

(2) The peroneal muscles. Test eversion of the foot, and feel the peroneal tendons contracting behind the lateral malleolus (if they are strong, you should not sacrifice them).

#### INDICATIONS.

(1) Foot drop from any cause, provided there is a strong *tibialis posterior* and *gastrocnemius*, and a mobile ankle.

(2) If there is leprosy *all* these conditions must apply:

(a) the leprosy must have been controlled, and there must have been no reaction for at least 6 months,

(b) the lateral popliteal nerve should have shown no sign of improving after 6 months of treatment and the use of a toe-raising spring,

(c) the power of the *tibialis posterior* must be 4 at least and preferably 4+ or 5 (32.1),

(d) the patient must have no ulcers or infections,

(e) preferably, he should be skin-smear -ve,

(f) you must be able passively to dorsiflex the ankle to 15° (with the knee flexed at 90°),

(g) the ankle must be suitably mobile, so test it like this:

(3) Flex the knee to 90°. If you cannot passively dorsiflex the ankle beyond 0°, tendon transfer alone is contraindicated.

(4) Straighten the knee. If you can passively dorsiflex the ankle to 15° (unusual), a tendon transfer alone is enough.

(5) If you cannot do this, perform an Achilles tendon lengthening at the same time.

**If the ankle is too stiff to dorsiflex without inverting,** you will not achieve a good gait. Try to refer for a wedge osteotomy, perhaps with a tendon transfer later.

#### TENDON TRANSFERS FOR THE TOES.

If a foot is not being dorsiflexed normally, its toe flexors shorten. If you correct the foot drop, the toes will remain abnormally flexed, unless they are corrected. So the clawed toes also need tendon transfers (32.12F,G), either at the same time as the *tibialis posterior* transfer, or later. If you fail to do this, walking may continue with the toe-nails turned under the toes, which will cause them to ulcerate.

RECORD THE PROGRESS OF THE FOOT preoperatively and again after removing the plaster cast, and at regular intervals afterwards. Record the angles of rest, active dorsiflexion, and active plantar flexion with the knee straight, and passive dorsiflexion with the knee at 90°.

#### SOME CRITICAL DETAILS

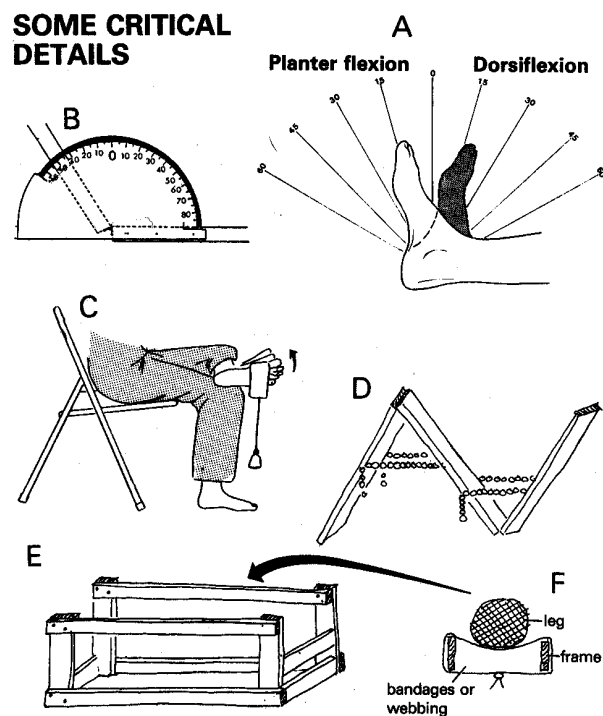


Fig. 32-28 SOME CRITICAL DETAILS.

A, measure the movement of the ankle like this. B, locally made goniometer. Hinge 2 boards together and nail a protractor to one edge. Mark the angles of dorsi- and plantar-flexion on it. C, exercises for *tibialis posterior*. D, locally made foot-drop-positioning frame made in three parts, hinged together, and adjusted by chains. E, frame for a leg rest (24x24x36cm). F, how the leg rests on webbing, cloth, or bandage stretched across the frame.

Kindly contributed by Grace Warren.

PREOPERATIVE PHYSIOTHERAPY is necessary to strengthen the *tibialis posterior*. Get the patient to sit with the affected foot resting on the other knee and to invert it without using the Achilles tendon (32-28C).

Hang a weight (starting with ½kg and increasing to 4kg, as the muscle strengthens) on the front of the foot, and ask him to lift this by inverting it. This exercise will help him to localize the action of the muscle that is to be transferred, so that it is easier for him to use afterwards.

#### PERIOPERATIVE ANTIBIOTICS.

An infected tendon transfer is a real disaster, so make absolutely sure the leg is thoroughly clean; use chloramphenicol and metronidazole (2.8) prophylactically.

#### EQUIPMENT AND TECHNIQUE.

Make a foot-drop-positioning frame (32-28D), from hardwood, hooks, hinges, screws, and two short chains. Ideally, you should use a 22 or 30cm curved Anderssen tunnel, but you can also use long Kocher's forceps. You will also need a leg rest, or cradle, to hold the leg about 20cm above the bed after surgery. Ask your carpenter to make a tubular metal or wooden frame with webbing across it (32-28E).

For a tendon use several small sutures rather than one large one, and make sure that no single suture bites >½ its thickness (which makes it liable to break later).

Rough tendon ends are harmless on the dorsum of the foot, but if a tendon needs to glide, as when you weave *peroneus brevis* to *tibialis posterior* above the ankle, use fine (6/0) nylon monofilament to close over and bury the ends of both tendon and the larger sutures, so as to prevent them sticking to surrounding structures.

#### CAUTION!

- (1) Clamp a tendon as close to its cut end as you can, and excise the crushed area, which should be as short as possible.
- (2) Watch for and avoid the main vessels. There is no need to tie off all the small ones.

#### PREPARATION.

Use the supine position, apply a tourniquet to the thigh (3.9), and sterilize the whole leg and foot below the knee. Clip a sterile towel round the thigh, so that you can lift the sterile leg without breaking sterility. A sandbag under the drapes will steady the leg, until you place it on the footboard.

In this operation, you detach the *tibialis posterior* from its insertion into the navicular, and divide its distal end into 2 slips. Thread these under the skin of the front of the leg and foot. Weave the medial slip into the distal end of the *tibialis anterior* tendon. Then weave the lateral slip into one of the following:

- (1) the distal end of the *peroneus tertius* tendon (only 75% of people have one; it is really the 5<sup>th</sup> tendon of extensor digitorum longus, and inserts into the medial part of the dorsal surface of the 5<sup>th</sup> metatarsal).
- (2) the distal end of the *peroneus brevis* tendon, if the *peroneus tertius* is absent, and the peroneal muscles are weak enough to be sacrificed.
- (3) a piece of tendon and use this as a free graft, if the peroneal muscles are not weak enough to sacrifice, or if the lateral slip of the *tibialis posterior* is too short to reach the lateral side of the foot.

**1<sup>ST</sup> INCISION.** Make a gently curved incision on the medial aspect of the leg, starting 2cm above the calcaneus and 1cm in front of the Achilles tendon, running parallel to the tendon for 5cm, and then curving up to reach the tibia about 14cm above the medial malleolus (32-29A). Cut the fat and deep fascia, and find the Achilles tendon. Open its sheath, and lengthen it (32-18). Suture it so that the ankle will dorsiflex to 15°-25° with the knee straight. Lift the tissues proximal to the medial malleolus, until you see the tendons, under the deep fascia. Slit this to find the *tibialis posterior* tendon which lies deeper than the *flexor digitorum longus*, (32-18D, 32-27A,F). Make sure you have got the right tendon by pulling on it and seeing what it does: *tibialis posterior* inverts the foot, and does not flex the toes.

**CAUTION!** Keep the exposed tendons moist by covering them with saline-soaked gauze.

**2<sup>ND</sup> INCISION.** Pull the *tibialis posterior* above the medial malleolus to find where it is inserted into the navicular. Make a 2-3cm incision along the plantar side of the tendon, from the navicular proximally (32-27C). Incise into the tendon sheath and raise the tendon with a blunt hook or curved forceps.

**CAUTION!** *Make sure you have got the right tendon.* It is the only one which is inserted into the navicular, and is usually thick and strong and the size of your little finger. Clamp the *tibialis posterior* tendon with Kocher's forceps, as far distally as you can easily reach it, on the medial aspect of the foot, and cut it at this point. (*Do not follow it and try to cut it where it inserts distally, among the arches of the foot*). Pull it up with its sheath into the 2<sup>nd</sup> incision, and free it from any adhesions, which would make it difficult to pull out of its sheath later. If there is a large sesamoid bone in it, remove this and reattach the Kocher's. *Don't pull it out of its sheath yet!*

**3<sup>RD</sup> INCISION.** Find the *tibialis anterior* on the dorsomedial aspect of the navicular (32-27A). It is the most medial of the tendons on the front of the ankle. Twist the foot into dorsiflexion and abduction to see it more clearly.

Make a J-shaped incision, with its long arm along the medial side of the *tibialis anterior* tendon, from the lower end of the tibia to the naviculo-cuneiform joint, and its short arm crossing the tendon laterally for 1cm. Reflect the flap at the level of the deep fascia, and try not to cut the dorsalis pedis artery. Find the *tibialis anterior* tendon (check that you are not pulling on the *extensor hallucis longus*), and open its sheath.

**4<sup>TH</sup> INCISION.** Make a ¼-circle curved incision, with its convexity towards the toes, extending from 2.5cm lateral to the distal end of the 3<sup>rd</sup> incision, and passing across the dorsum of the foot, to reach the base of the 5<sup>th</sup> metatarsal, but not extending over the bone itself (32-29B).

Use big scissors and the 'push and spread technique' (4-9) to raise all the superficial tissues off the deep fascia over the dorsum of the foot, so that you can see the toe extensors, the *peroneus brevis*, and the *peroneus tertius* (if there is one) inserting into the shaft of the 5<sup>th</sup> metatarsal.

Define and dissect out the *peroneus tertius* as far from its insertion as you can, above the extensor retinaculum. Cut its tendon free proximally, separate it from its muscle fibres, and leave it free, attached distally to its insertion.

**CAUTION!** The superficial fascia is thin here. *Be careful not to cut the extensor retinaculum*, which is the deep fascia at this point.

Use finger dissection, and blunt Kocher's, to tunnel up under the skin above the extensor retinaculum, raise the skin and superficial fascia to join the 3<sup>rd</sup> & 4<sup>th</sup> incisions, leaving a skin bridge. Keep in the midline initially, and then turn medially towards the proximal end of the 1<sup>st</sup> incision.

Starting about 7cm above the ankle, raise the skin from the deep structures. Complete a tunnel joining the 1<sup>st</sup>, 3<sup>rd</sup> & 4<sup>th</sup> incisions. Tunnel under the skin and preserve the long saphenous vein (32-27C). Make a pocket into which the muscle belly of the *tibialis posterior* will fit. If necessary, cut the deep fascia over the crest of the tibia, but avoid cutting the tibial periosteum (if you do it will promote adhesions later).

Above the medial malleolus put a finger under the *tibialis posterior* tendon, remove the Kocher's forceps from its distal end in the 2<sup>nd</sup> incision, and pull the tendon up into the 1<sup>st</sup> incision (32-29C).

Reclamp its distal end, and use the clamp to give you a good grip for traction, while your finger frees its muscle belly from the surrounding tissue at the back of the tibia.

**CAUTION!**

(1) Be careful to retract *flexor digitorum longus* posteriorly, so that *tibialis posterior* comes to lie anteriorly (32-29F), between the *flexor digitorum longus* and the tibia.

*Avoid tibialis posterior twisting round digitorum longus.*

(2) *Be careful not to damage the main vessels, the muscle fibres of the tibialis posterior, or the periosteum.*

Using finger dissection, a Langenbeck retractor and, if necessary, scissors, free the *tibialis posterior*, until it will lift up and roll easily round the edge of the tibia in an oblique direction towards the base of the 5<sup>th</sup> metatarsal (which it will usually reach), crossing the centre of the leg about 4cm above the ankle joint. Enlarge the tunnel if necessary.

When you have freed the tendon sufficiently to reach the dorsum of the foot, clamp its distal end with 2 Kocher's, and divide it between them. Pull the two slips apart into a 'Y' with 6cm arms. To prevent the slips separating any further, place a suture where they meet, and bury its knot inside the tendons when they lie together (32-29G).

**If the *tibialis posterior* will not reach the dorsum of the foot**, check that you have freed its belly sufficiently. If so, pass long Kocher's proximally, in the midline of the leg, from the 4<sup>th</sup> incision for about 10cm, and then deviate towards the proximal end of the 1<sup>st</sup> incision. Pick up both slips of the *tibialis posterior*, and pull them through onto the dorsum of the foot.

Pass the Kocher's from the 3<sup>rd</sup> to the 4<sup>th</sup> incisions. Pull one slip of tendon into the 3<sup>rd</sup> incision and leave the other one in the 4<sup>th</sup> incision. Keep a Kocher's on each slip.

Pass your finger along the *tibialis posterior* tendon to make sure it lies easily in its new bed, that it runs smoothly round the tibia, and that no fascia obstructs its direct pull.

Use everting monofilament sutures (4-8) to close the 1<sup>st</sup> & 2<sup>nd</sup> incisions, without closing the deep fascia.

Put the foot on the positioning splint, to hold the knee at 80°-90° of flexion, and the ankle at 20°-25° of dorsiflexion, with the foot everted. While you adjust the tension in the tendons, ask an assistant to hold the foot in this position, or tie it to the foot splint with sterile bandages.

**CAUTION!**

(1) *Do not let the foot invert.*

(2) Get the heel into the angle of the board.

Through the 3<sup>rd</sup> incision, place a Kocher's across c.¼ of the *tibialis anterior* tendon 2cm from its insertion. While your assistant holds the distal part of this tendon tense, use a #15 blade to make a small *longitudinal* incision in it (stab I), just distal to the Kocher's. Push a haemostat into stab I, enlarge it a little and pull the slip of *tibialis posterior* tendon through it. Make stab II at 90° to stab I ½cm distal to it, and then pull the tendon slip through that. Make stab III ½cm further distally again, and pass the tendon through that (32-29H) (if the tendon is not long enough, two stabs will do). *Do not suture this 'weave' yet.*

Turn to the 4<sup>th</sup> incision.

Take care:

(1) *Be sure to join the various tendons at just the correct length and tension*, to get the right degree of dorsiflexion and eversion of the foot (this is the position in which the lateral side of the foot is higher than the medial side). The foot must be tightly dorsiflexed when you put it into plaster. A special foot-drop-positioning splint is critical at this stage.

(2) If the transferred tendon weave gives way, your work is wasted, so be sure to keep the foot dorsiflexed until it has united firmly.

(3) Avoid subsequent toe drop by suturing the transferred *tibialis posterior* to the extensor tendons of the toes.

(4) *Do not anchor the tibialis posterior to a hole drilled in the foot in a case of leprosy.* This may work with other diseases, but in leprosy it will promote the disintegration of the tarsal bones.

THE 1<sup>ST</sup> METHOD is indicated if there is a *peroneus tertius* of suitable size. Holding the distal end of the *tibialis posterior* tight in Kocher's, weave the distal end of the *peroneus tertius* through it, in the same way that you wove the *tibialis posterior* through the *tibialis anterior*.

Make stab I in the *tibialis posterior* about level with the proximal end of the 5<sup>th</sup> metatarsal, just distal to the extensor retinaculum; make stabs II and III more proximally. When you have woven the 2 tendons, work them along one another, until there is no slack tendon. Then, holding both firm so that they are just in tension, with the foot on the positioning board and the ankle everted, join them with 6 small sutures, passing through a little of each tendon (32-29D).

## TIBIALIS POSTERIOR TRANSFER

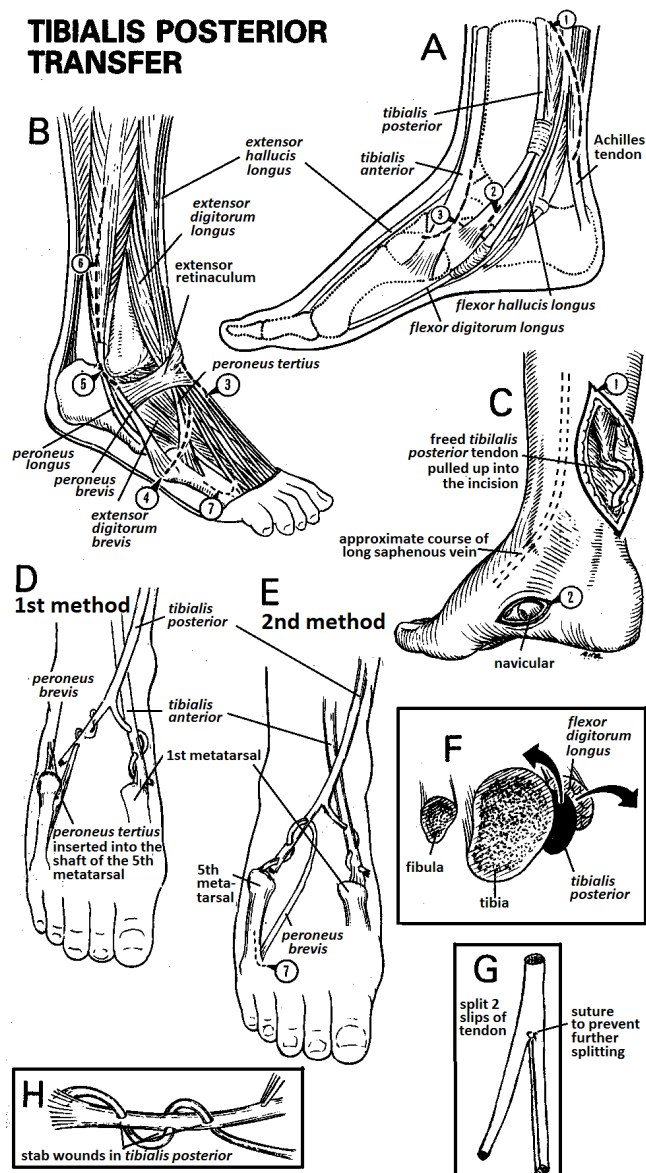


Fig. 32-29 **TIBIALIS POSTERIOR TENDON TRANSFER FOR FOOT DROP.** A, medial side of the foot with the 1<sup>st</sup> 3 incisions. B, incisions on the lateral side of the foot. C, pull up *tibialis posterior* into the 1<sup>st</sup> incision. D, 1<sup>st</sup> method, using *peroneus tertius*. E, 2<sup>nd</sup> method, using the full length of *peroneus brevis*. F, relationship between *tibialis posterior* & *flexor digitorum longus*. G, split and suture the tendon of *tibialis posterior*. H, weave the tendons.

Kindly contributed by Grace Warren.

**CAUTION!** As you suture the tendons, make sure they lie in the line of the pull of *tibialis posterior*, and are not raised away from the foot. If they are not in this line, they will become loose subsequently.

**If there is spare *tibialis posterior* tendon left over**, suture it to the *peroneus brevis*, or the extensor retinaculum, and tuck in any loose ends, so that they grow into the periosteum.

**If there is any spare *peroneus tertius* left over**, suture it so that it cannot attach itself above the ankle and limit movement.

Return to the 3<sup>rd</sup> incision. Move the woven tendons along one another until they lie snugly, and the tension in the medial slip is the same as that in the lateral one with the foot in the correct position on the splint. Suture the medial 'weave' in the same way.

**CAUTION!** Do not make the medial slip too tight, or the foot will invert.

Check the position of the toes. While your assistant holds them as straight as he can, use a few small sutures to join the slips of the *tibialis posterior* to the *extensor digitorum* and *extensor hallucis*, as they cross.

THE 2<sup>ND</sup> METHOD is indicated if there is no *peroneus tertius* tendon, or it is too small:

As the *peroneus brevis* is paralysed in most patients, use it. Proceed as above until you have woven the *tibialis posterior* and *anterior* together. *Peroneus brevis* is inserted into the base of the 5<sup>th</sup> metatarsal. Slip a blunt hook under it, and pull it, so that you can feel it under the lateral malleolus.

Make the 5<sup>th</sup> incision over the *peroneus brevis* tendon as it passes under the lateral malleolus. *Peroneus brevis* lies deep to *peroneus longus* under the lateral malleolus (32-27B), so you will have to hook out the deeper of the two tendons you find there. Pull it distally, and cut it off as far proximally as you can. This will leave the distal tendon as long as possible, without the need to make a 6<sup>th</sup> incision. Return to the 4<sup>th</sup> incision, you should be able to pull 8cm of *peroneus brevis* into it. Weave *peroneus brevis* into the lateral slip of *tibialis posterior* and suture them as above. Close the 5<sup>th</sup> incision.

If, rarely, the peroneal muscles are still functioning, do not sacrifice them, and take a free tendon graft from either: (1) a toe extensor. Weave and suture this free graft into the *peroneus brevis* as far distally as possible (to provide the best toe lift and eversion), and then into the lateral slip of the *tibialis posterior*, as described above, or: (2) the *plantaris* tendon from beside the Achilles tendon, if it is long enough.

With both methods, check that the position of the ankle is satisfactory by lifting the leg off the splint, keeping the knee well flexed, and checking the angle of the foot and ankle: it should be in 15°-20° of dorsiflexion and show no inversion. If it drops to 10° or inverts, undo some sutures and tighten them. Do not worry if it is high (20°-25°): it will stretch later.

Release the tourniquet, control bleeding by applying pressure for 5mins, and suturing any bleeding artery you can find, carefully keeping the foot in position on the splint, and then close the 3<sup>rd</sup> & 4<sup>th</sup> incisions, and apply the special cast.

**CAUTION!** Do not plantarflex the foot while you do this.

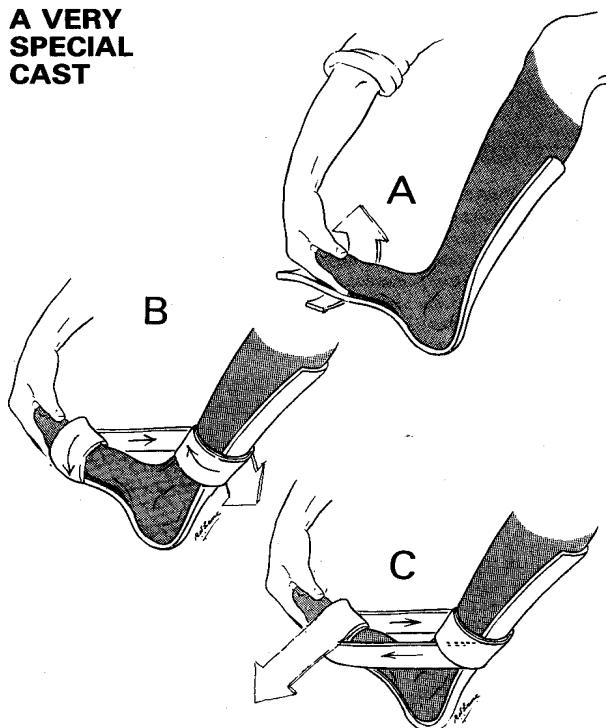


THE CAST must keep the foot dorsiflexed and everted, and leave the dorsum of the ankle free. For this it needs a backslab and two side struts or braces.

Ask your assistant to stand beside the patient, facing the foot of the table, to flex the patient's knee, and to flex and externally rotate the hip. The knee should rest on your assistant's abdomen. Your assistant's hand which is furthest from the patient should be flat on the sole of the foot (to avoid pressure areas), with its little finger over the head of the 5<sup>th</sup> metatarsal, its fingers straight, and with the ankle 20°-25° dorsiflexed and everted. The hand must stay in this position until the cast has set. Ask him to support the calf with the flat of the other hand, moving it as the cast is applied.

**CAUTION!** The patient cannot complain of pain because the foot is anaesthetic, so pad the heel well, or else pressure ulcers may ensue.

### A VERY SPECIAL CAST



**Fig. 32-30 A VERY SPECIAL CAST** for a patient who has had a *tibialis posterior* transfer. A, backslab applied with the foot dorsiflexed and everted. B, lateral strut of plaster. C, medial strut applied and the plaster being passed round the toes. Kindly contributed by Grace Warren.

With the foot in this position, firmly bandage on cotton wool, but not too tightly, with extra layers over the heel. Apply an 8-layer backslab from the tips of the toes to the mid upper calf (your assistant's hand will be between the backslab and the sole). Secure the slab with a 10cm bandage. Start at the big toe (32-30A), go across the sole medial to lateral, and pass 3 turns round the forefoot, just proximal to the toes. Then pass 2 turns round the lower leg (this will leave a strut of bandage at the lateral side of the ankle, and enable you to give the foot a good everting tilt as you do so: 32-30B). Then bring the bandage down the medial side of the ankle (to provide a medial strut) and run a turn or two round the forefoot. Continue until the bandage is finished.

Apply another 10cm bandage at the upper end of the backslab. Only now should your assistant remove his hand. Strengthen the side struts and the foot, *but leave the front of the ankle and the toes open*.

#### CAUTION!

- (1) *Make sure the toes are not dorsiflexed.*
- (2) *Do not leave finger depressions in the cast.*
- (3) *Do not pull the bandages tight.*

POSTOPERATIVELY, raise the foot preferably in a special prepared frame (32-28D), so that the foot is parallel to the femur, and the knee is bent. If necessary (unusual in leprosy), use morphine. Check the colour of the toes and the pulse hourly for 24hrs.

On Day 4 provide crutches, without weight-bearing.

**In the 4<sup>th</sup> wk.** (5<sup>th</sup> wk if physiotherapy supervision is limited), bivalve the cast down both sides, so that the struts are left attached to the posterior half of the cast (reinforced if necessary), which can be used as a protective resting splint during rehabilitation.

#### CAUTION!

Keep the foot dorsiflexed when you remove the sutures. If you do not, the flexors, aided by gravity, may pull away the healing tendons. Start exercises the day you remove the cast.

**5<sup>th</sup> wk.** (1<sup>st</sup> wk after removing the cast) Instruct the use of the transferred tendon in its new position. In supine position, with the hips flexed and externally rotated, and the knees flexed, with both feet in the frog position, so that the soles of the feet are almost touching each other, ask the patient to practice the inverting movements he did before surgery, the unoperated foot first.

When he does that satisfactorily, ask him to do it with both feet together, and with the eyes closed: the movement produced by the transfer is not what he is used to seeing. Hold the operated foot with your palm flat on the sole, so that it cannot plantarflex. When he can do this without looking, let him look; the first movement may be very slight. Then let him graduate to doing it with only one leg.

Concentrate on getting him to dorsiflex the foot without using the *gastrocnemius* muscle, while trying to get a long, slow pull on the foot. Slowly increase the range and strength of the exercises with the leg horizontal in bed. Once he can do them, let him sit and watch them. After about 5days, when he can move the transferred muscle easily and on command, sit him on the edge of the bed, and let him dangle his legs over it. Once he sits, he is lifting the foot against gravity, so he must not start doing this until he can isolate the transferred muscle and use it without *gastrocnemius*.

#### CAUTION!

- (1) These exercises are tiring. During the 1<sup>st</sup> wk, encourage him to do them many times a day for 5mins only, with 10mins rest periods with the foot back in its cast.
- (2) *Do not allow plantarflexion of the foot:* the strong *gastrocnemius* can easily pull the sutures out of the tendon transfer.

**6<sup>th</sup> wk.** If he can isolate the transfer, and has good movement, let him stand with crutches or in parallel bars. Instruct him like this: 'Put your operated foot on the ground behind your other foot. Lift up your toes (by contracting your transferred muscle), lift up your foot as if you are walking, and put it down heel first in front of your other foot. Lift it up and put it back again behind the other one'. Progress to walking carefully with crutches. Make sure that every step uses the transferred tendon, and that contraction is held until the foot reaches the ground again. Let him walk for periods of 10mins and rest for 10mins.

**7<sup>th</sup> wk.** While he walks with crutches, check that he uses the transferred tendon with each step. Practise on steps, slopes and stairs. When he is confident, graduate to walking without crutches.

When he is not doing physiotherapy, keep a bandage on the posterior half of the cast, until he learns to control the foot without trying to plantarflex it. He should be walking reasonably well at the end of the 7<sup>th</sup> wk, and be able to discard the cast by day. Continue the protective splint at night until the end of the 3<sup>rd</sup> month.

**8<sup>th</sup> wk.** When he is off crutches, he can start rising on tiptoe while supporting himself with his hands on a table. The tendon join will gradually stretch, and the muscles will adapt to the range of movement required of them: provided you did not damage the periosteum, and so promote the formation of adhesions above the ankle.

#### CAUTION!

- (1) *Do not try to force the foot into plantar flexion:* it will gradually come down as he walks.
- (2) He must not start plantar flexion too early, or he will lose the power of dorsiflexion.
- (3) Unless he learns to walk using the transfer with each step, he will not get a good gait; but even if he doesn't use it properly he should be much improved.

#### DIFFICULTIES WITH *TIBIALIS POSTERIOR* TENDON TRANSFER

The main difficulty is to persuade the patient to care for the feet for years to come.

**If the *tibialis posterior* tendon is short or is badly scarred,** so that its whole length cannot be used, transfer what tendon is available, and insert it into the *tibialis anterior* tendon more proximally. Then attach the *peroneus brevis* as in the 2<sup>nd</sup> method, taking it long so that it bypasses the scarred region.

**If the lateral slip of the *tibialis posterior* will not reach the lateral side of the foot without causing excessive eversion,** and the peroneal muscles are not functioning, use a longer piece of *peroneus brevis* than that described in the 2<sup>nd</sup> method. If necessary, there is 25cm of free tendon. *Do not make the 5<sup>th</sup> incision* but instead make a 6<sup>th</sup> incision 10cm long, starting 1cm behind the lateral malleolus and running up the leg in line with the fibula (32-29B).

Cut down until you see the deep fascia, cut this in the line of the tendon, and find *peroneus brevis* (usually deep to *peroneus longus*). Cut it out of the muscle (which will not be used), pull it back into the foot at the 4<sup>th</sup> incision, weave it into the lateral slip of the *tibialis posterior*, and repair the 6<sup>th</sup> incision.

**CAUTION!** Check the peroneal tendons behind the lateral malleolus, because *peroneus longus* and *brevis* are often attached together there. If necessary, cut the peroneal retinaculum behind, but not below, the lateral malleolus, so that you can pull the *peroneus brevis* down and out at the base of the 5<sup>th</sup> metatarsal without harming the tendon. Weave, adjust, and suture the *peroneus brevis* to the *tibialis posterior* as in the 2<sup>nd</sup> method.

Then tunnel its free end back under the skin and, through a small J-shaped 7<sup>th</sup> incision, suture it to the periosteum on the neck of the 5<sup>th</sup> metatarsal (32-29E). This will provide a better anterior lift if there is a very mobile foot.

**If pressure of the dressing causes sloughing and infection,** dress and graft the bare area.

**If the wound becomes infected,** the *tibialis posterior* tendon may adhere to other structures, or break. Splint the leg and apply a honey dressing (34.9). Rest it until you have controlled the infection, then slowly resume exercises.

**If the patient does not use the transferred tendon,** exclude infection and persist with physiotherapy.

**If the toes curl under the foot,** ulcers may form and the toes and even the foot may be lost. Keep exercising them to prevent stiffness, and correct them surgically (32.12).

**If the foot is slack on the lateral side, and tends to invert,** consider doing another operation to tighten the tendon, and perhaps bring *peroneus brevis* into the graft.

## 32.14 Painful hip or a limp in a child

### A. CONGENITAL HIP DISLOCATION (CDH)

Congenital dislocation of the hip causes no symptoms at birth, so it has to be diagnosed by screening all newborn babies. The danger is that it may cause premature osteoarthritis in later life. If however you can recognize a baby's dislocated hip at birth, reduce it, and hold it in place with a simple splint, you can usually prevent later complications. If it is not diagnosed at birth, the child may present with a limp (often very mild) when he starts to walk. The leg may then be shortened and the hip unstable. If however the dislocation is bilateral, you will not be able to diagnose shortening, and he may appear to walk normally, although careful observation should show a slight waddle. Baby girls are more likely to dislocate their hips than baby boys.

## DIAGNOSIS.

**In a baby** do Ortolani's test. The child must be relaxed, preferably after a feed. Flex the knees and hold so them so that your thumbs are along the medial sides of the thighs, and your fingers are over the trochanters (32-31A). Flex the hips to 90°. Starting from a position in which your thumbs are touching, abduct the hips smoothly and gently (32-31B). If a hip is dislocated or subluxated, you will feel the head of the femur slipping into the acetabulum as you approach full abduction (32-31C). You may hear a 'clunk', but this is not essential for the test to be +ve. *Restriction of abduction may indicate an irreducible dislocation.* If the test is +ve, you must not ignore the abnormality.

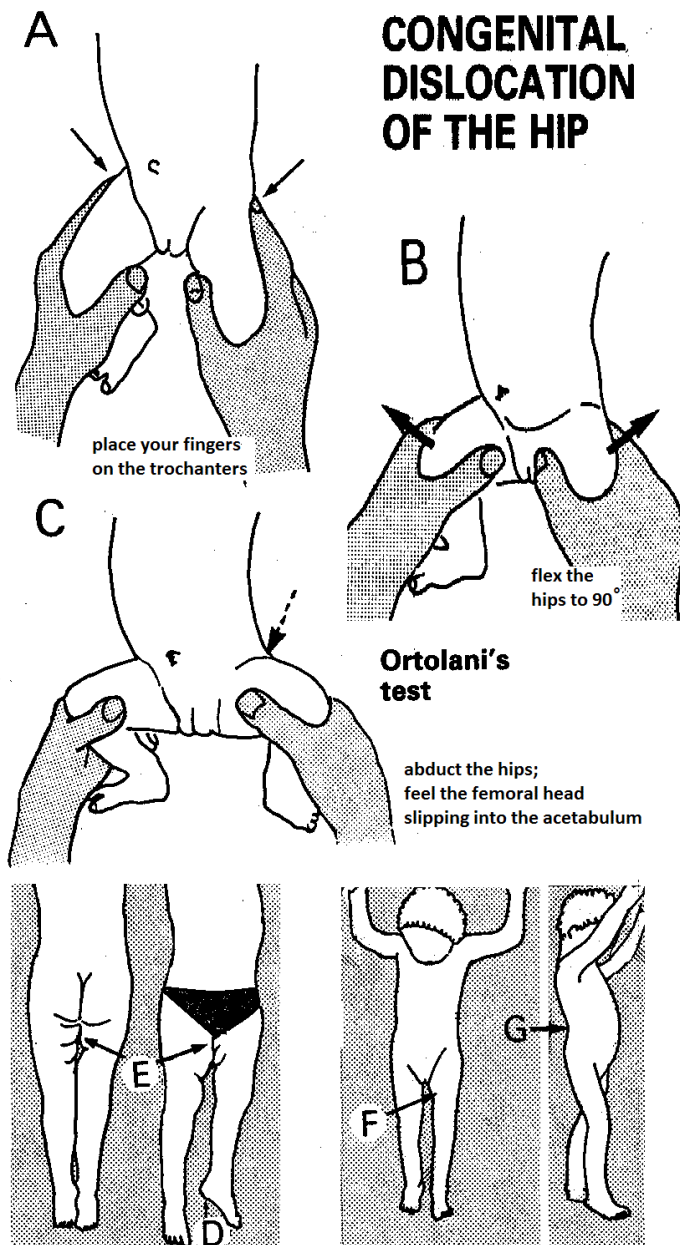


Fig. 32-31 CONGENITAL DISLOCATION OF THE HIP.

A,B,C, Ortolani's test. D, if the child is older, the leg may be slightly shorter, and the hip externally rotated. The skin folds of the thigh may be asymmetrical (E), but this sign is not very reliable. F, if both hips are involved the perineum is usually widened owing to displacement of the hips. G, if the child has been walking, lumbar lordosis may be increased. After McRae R, *Clinical Orthopaedic Examination*, Churchill Livingstone 1988, permission requested.

**If the child is older**, one leg may be slightly shorter, and the hip externally rotated (32-31D). The skin folds of the thigh may be asymmetrical (32-31E), but this sign is not very reliable. If both hips are involved the perineum is usually widened due to their displacement (32-31F). If walking has started, the lumbar lordosis may be increased (32-31G).

**DIFFERENTIAL DIAGNOSIS OF LATE WALKING** include cerebral impairment and neurological deficits. Confirm CDH radiologically (32-32).

## TREATMENT.

**For a neonate**, treat CDH with double nappies which will hold the hips in flexion and abduction. Examine again at 1wk. If the displaced hip has become stable, apply double nappies for a further 3wks, and examine again. If it is still stable, one nappy only is necessary.

**If instability persists**, the child needs a more substantial splint. Ideally use the von Rosen splint (32-33B). Alternatively, improvise a simple splint with a sheet of stiff polythene, padded round the edges, which passes between the abducted legs over the nappy. The edges of the sheet are held together at either side by 2 pieces of 'velcro' strapping. Apply the splint for 3months. Then examine the hip again and X-ray it. If the hip is still dislocated, the child may need a subtrochanteric (Salter) osteotomy.

*N.B. Over the age of 6yrs, reduction of a dislocated hip needs too much force and will damage it! Do not try to reduce bilateral dislocations after 4yrs because of the risk of asymmetry.*

## CONGENITAL HIP DISLOCATION RADIOGRAPHS

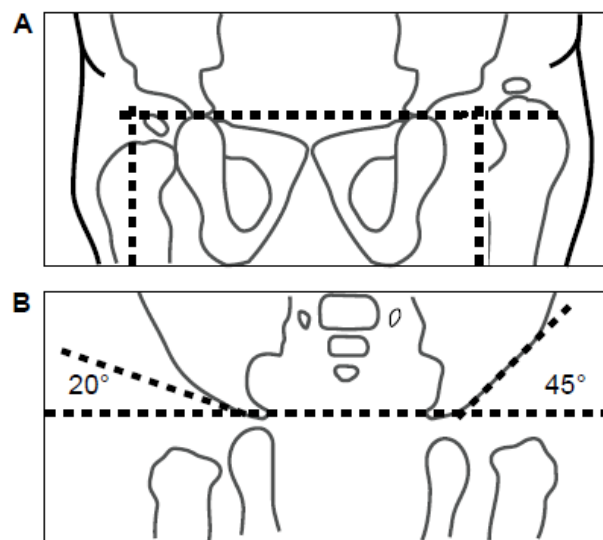


Fig. 32-32 RADIOLOGICAL APPEARANCES OF CDH.

A, draw horizontal (Perkin's) lines through the junction of sacrum, ilium & ischium and vertical lines down from the outer edges of the acetabula: the abnormal femoral head lies lateral to the vertical and above the horizontal line. B, where the acetabular roof is defective, the acetabular angle is increased. After Apley AG, Solomon L. *System of Orthopaedics and Fractures*. Butterworth, 1982, p.248 Fig.19.8

## SPLINTS FOR HIP DISLOCATION

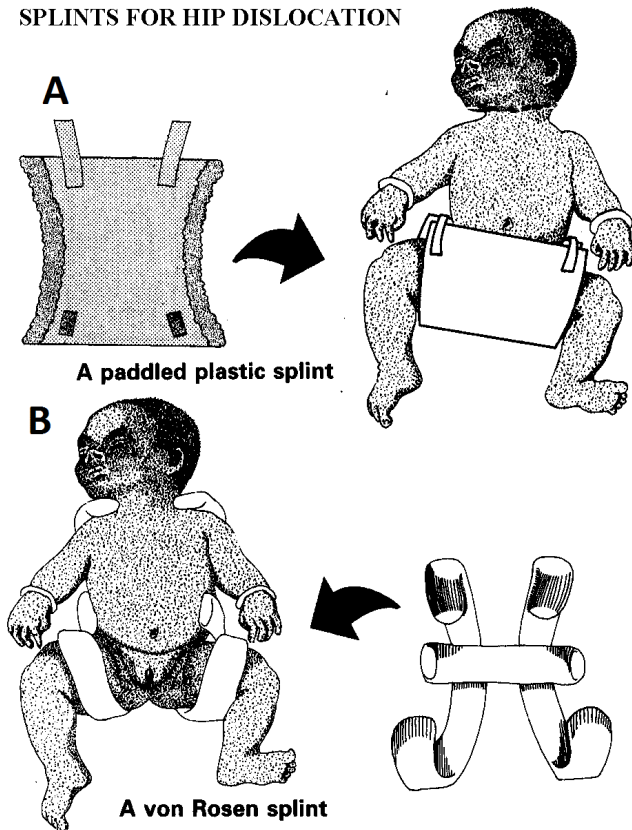


Fig. 32-33 A SPLINT FOR CDH.

A, a simple splint is a sheet of stiff polythene, padded round its edges, which passes between the child's legs over the nappy. B, ideally use the von Rosen splint made of washable malleable padded metal.

## DIFFICULTIES WITH CDH

If you diagnose CDH late (>3months), skilled surgery is needed and this will be difficult >8yrs. If a good range of movement is particularly important, as in societies where people squat, an unstable mobile hip may be preferable to a stiff one, whatever the risk of later arthritis.

If reduction is difficult or impossible, consider other causes of dislocation:

- (1) Partly treated septic or tuberculous arthritis.
- (2) ARTHROGRYPOSIS (a rare congenital anomaly, usually affecting all joints, producing contractures without mental deficit, demonstrated by:
  - (a) the absence of skin creases,
  - (b) generalized rigidity of the muscles often of all 4 limbs, causing shortening. Defects in at least one other organ are frequent.

If you recognize this condition, *do not attempt reduction*, which may be impossible.

If groin pain & vomiting persist, think of the rare Narath type of femoral hernia which is not visible clinically, but results in early bowel strangulation.

## B. PERTHES DISEASE (Osteochondritis)

Like congenital dislocation of the hip (CDH) and slipped epiphyses, Perthes disease causes only minor symptoms in childhood, but may cause severe osteoarthritis in later life. It is a very controversial disease.

A child with Perthes disease is aged 4-10yrs (occasionally 2-18yrs), and is usually male. If he presents early, he does so with intermittent episodes of pain in the front of the thigh, knee or groin, and a limp; in the early stages he is normal between these episodes. Sometimes there is no limp, but only some minimal abnormality of the gait, such as a tendency to walk with the leg turned inwards. Usually (but not always) all movements of the hip are mildly limited by discomfort rather than by pain, especially abduction and internal rotation. There may also be some fixed flexion. If movements are limited, the child usually also has spasm, particularly in the *adductor* and *psoas* muscles. The thigh and buttock may be wasted. He may be vaguely tender around the hip, but he is otherwise perfectly well. If presentation is late, after the disease has run its course, the only signs may be a slight loss of the normal range of abduction, extension, and medial rotation of the hip, or he may have no symptoms or signs. However, several present with permanent deformity.

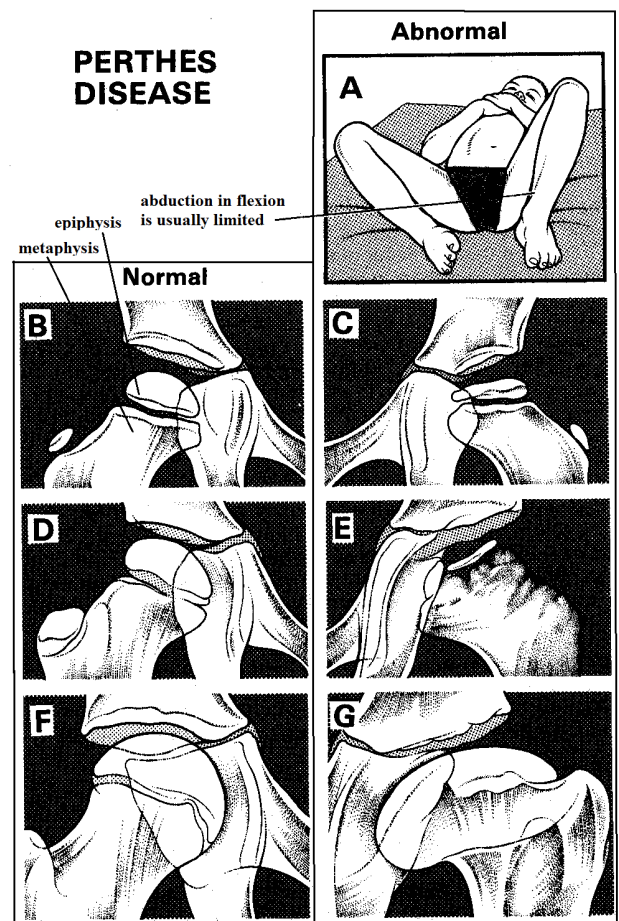


Fig. 32-34 PERTHES DISEASE.

This shows the progression of a patient in Catterall's Group IV. A, in Perthes disease there is always limitation of abduction. B, normal side. C, abnormal side showing the head of the femur is smaller and denser, and the joint space looks increased. D, normal growth. E, patchy fragmentation follows. F, continued normal growth, whilst G, the head becomes wide and flattened on the abnormal side. After Apley AG, Solomon L. *System of Orthopaedics and Fractures*. Butterworth, 1982 p.260 Fig.19.26 with kind permission.

Perthes disease is an avascular necrosis of all or part of the epiphysis of the head of the femur. Essentially, the disease passes through five stages over a period of 2-4yrs:

- (1) To begin with the radiographs are normal.
- (2) All or part of the head of the femur looks abnormally dense, which indicates reduced vascularity. The cartilage surrounding it does not die; instead, it continues to enlarge, and makes the joint space appear larger.
- (3) The epiphysis may fragment.
- (4) New blood vessels gradually grow in, and the epiphysis looks less dense.

The epiphysis and metaphysis may soften, so that the metaphysis bends and causes a mild *coxa vara* (the head and the neck of the femur are angled more medially from the shaft).

- (5) Eventually, the head returns to its normal density, but it remains flatter, and the neck remains wider than normal.

Avascular necrosis of the femoral head also occurs in later life because of steroid therapy, alcohol abuse and HIV disease.

A child is more likely to get osteoarthritis later in life, if the head of the femur flattens. The older he is, and the more misshapen the head, the worse the prognosis. But, even if it is seriously flattened, he will probably not get symptoms until he is middle aged. Unlike in slipped femoral epiphyses, the involvement of both hips is unusual in Perthes disease (15% of cases, mostly in younger children).

The hope of treatment is to prevent deformity, as long as the epiphysis and underlying metaphysis are soft, which is during the avascular phase and during revascularization. There are various possibilities, either alone or combined, none particularly satisfactory:

- (1) Prolonged traction (1-2yrs) produces little benefit, and is quite impractical.
- (2) Attempting to avoid weight-bearing by restricting a child's activity is difficult.
- (3) Weight-bearing callipers probably do not work and should be avoided.
- (4) Salter's Toronto splint is expensive and impractical.
- (5) *Surgery has never been proved to be better than non-operative management.*

#### TESTING FOR SPASM

**IN EXTENSION.** Lay the child supine, place your hands on the affected thigh, and roll it backwards and forwards (7-17). Compare both sides. If there is no spasm in extension, test it in flexion.

**IN FLEXION.** Flex the hip and knee to 90°. Rotate the leg inwards and outwards. Rotation is usually more limited than abduction or adduction.

**ABDUCTION IN FLEXION** is usually limited (32-34A).

**RADIOGRAPHS.** Take an AP and a lateral view. Abduct the hips, rotate the femurs inwards, and take an AP view to include both hips, so that you can compare them.

#### CLASSIFICATION AFTER CATTERALL:

	GROUP I	GROUP II	GROUP III	GROUP IV
<b>Height of head</b>	No loss	Mild loss	Obvious loss	No height
<b>Sequestration of head</b>	None	1/2 to 2/3	<1/4 normal bone only	Total
<b>Epiphysis</b>	Some lytic areas	Significant increased radiodensity	Marked increased density	Collapsed with mushroom-like protrusion
<b>Metaphysis</b>	Normal	Some radiolucency	Generalized changes	Destruction

#### Risk factors:

- (1) Lateral subluxation of the head leaving it partly uncovered.
- (2) A translucent area in the lateral third of the epiphysis.
- (3) Specks of calcium lateral to the epiphysis.
- (4) Severe radiolucency of the metaphysis. A fragmented upper femoral epiphysis which appears to be extruding from the acetabulum is a poor prognostic sign.

#### TREATMENT

*Do not intervene for Group I, or Group II & III if the child is <7yrs, unless risk factors are present when a femoral or pelvic osteotomy is needed to contain the femoral head in the acetabulum. Partial weight-bearing with elbow crutches and analgesics for 1yr is useful in the co-operative child: add active hip exercises, folic acid and aggressive antibiotic treatment for staphylococcus or salmonella infection.*

The prognosis in Group IV is bad and *forcing the femoral head into the acetabulum makes things worse.*

#### C. OTHER CAUSES

Hip disease in a child can present as: this may be so serious, that you should be on the look out for these 4 signs, which may be due to several diseases:

- (1) A painful hip.
- (2) A painful hip and a painful, but otherwise normal, knee, due to referred pain along the obturator nerve.
- (3) A painful knee with no pain in the hip.
- (4) A painless limp.

*Do not miss tuberculosis (32.3) and septic arthritis (7.16), because they need early treatment: septic arthritis urgently!*

*N.B. Do not forget that abdominal and spinal conditions can also cause pain in the hip.*

Remember also the possibility of disease near the hip e.g. iliac adenitis, pyomyositis (7.1), appendix abscess (6.16).

**Suggesting transient synovitis:** no radiographic changes, spontaneous resolution in a few weeks without further episodes. Some cases are viral, notably those due to the parvovirus, and several joints may be involved. There may be a history of mild trauma.



**Suggesting septic arthritis/osteomyelitis** (7.9,18): an acute onset, often a few hours. The hip is acutely painful, and is immobile in any direction, with general symptoms of acute infection. There are no bony changes for about 2wks. If a radiograph is good, you may see displacement of the fat shadow, or a widened joint space, indicating fluid in the hip joint. Partially treated cases are more difficult to distinguish clinically and by radiography.

**Suggesting sickle-cell disease:** onset 14-15yrs, especially in a boy, with crises of pain, especially on internal rotation and in the other hip (50% are bilateral) and other parts of the body also, due to infarction, with a +ve sickle-cell test.

**Suggesting rheumatic fever:** age 5-20yrs. Transient symptoms and the involvement of other joints.

**Suggesting tuberculosis** (32.3): any age, but common in childhood and adolescence. Bone erosion around the acetabulum (appearing to enlarge upwards), often with damage of the femoral head.

**Suggesting rheumatoid arthritis:** from childhood to 40yrs (at the onset). The involvement of several joints is usual, although mono-articular disease does occur.

**Suggesting reactive arthritis** (e.g. gonococcal or Reiter's syndrome): urethral discharge, conjunctivitis and/or anterior uveitis. A gonococcal arthritis is usually acute. Reiter's syndrome often follows a chlamydial infection, or *shigella*, *salmonella*, *campylobacter* or *yersinia* diarrhoea.

**Suggesting a slipped upper femoral epiphysis:** 12-18yrs. Usually a history of an acute onset, sometimes with a fall. Occurs typically in tall obese sexually immature children. Radiographs show a wide 'woolly' upper femoral growth plate and extrusion of the femoral head from the acetabulum on a lateral view.

#### CAUTION!

- (1) If you diagnose transient synovitis, follow up the child carefully: some children develop Perthes disease later.
- (2) Pain in the knee is often due to hip disease.

### A PAINFUL HIP IN A YOUNG CHILD IS INFLAMMATORY, UNTIL PROVED OTHERWISE

## 32.15 Stenosing tenosynovitis

This is a chronic benign condition, in which the tendons no longer run smoothly in their sheaths. The symptoms depend upon which tendon is involved.

If the patient complains of pain (and sometimes an abnormal prominence) over the radial styloid, which may be worse on extending and/or abducting the thumb, its abductor and short extensor tendons are constricted in their sheaths, as they pass over the groove in the end of the radius (this is de Quervain's disease). They are tender and you can usually feel a thickening in the tendon sheath.

Flexion and adduction of the thumb causes pain over the radial styloid.

If he complains of a 'trigger finger or thumb' so that, when he flexes one of the digits it locks, and he cannot extend it again, until he does so passively and forcefully, the flexor tendons are involved. The powerful flexors are able to pull the swollen part of the tendon proximal to the constriction, but the weaker extensors are unable to extend the finger again unaided.

#### TREATMENT

**If you see the disease early**, inject the thickened tendon sheath with 0.5ml lidocaine/hydrocortisone mixture using strict antiseptic precautions. Place the point of a very fine needle into the palpable swelling and inject between the tendon sheath, and the bone. You will see a wheal appearing on the proximal side of the tendon sheath.

**If injection is not successful** (50% of cases), apply a tourniquet and get fine instruments. Make a small transverse skin incision. Use a fine tenotomy knife to make a longitudinal incision in the sheath to release the tendon. Leave the sheath open, suture the skin only, and start active movements immediately. The result will be good.

#### CAUTION!

- (1) *Avoid the cutaneous branch of the radial nerve near the radial styloid and the digital nerves*, so look for them immediately you incise the skin.
- (2) *Do not try to make the tendon narrower or thinner.*
- (3) There may be several slips to the tendon, and thus several compartments in the sheath; make sure each is free. *Review the anatomy before you operate.*

## 32.16 Ganglions

A ganglion is a round cystic swelling that develops on the back of the wrist, or less commonly on the dorsum of the foot, usually in connection with a tendon sheath, or a joint capsule. Flex the wrist over the edge of a table; this will usually make the fluid in the cyst tense. You may be able to rupture the ganglion by pressing firmly with your thumb; the fluid is then absorbed.

**If this fails**, repeat it under general anaesthesia.

You may need to use a rubber mallet, or a similar object. The chances of recurrence are no greater than following surgery. Avoid operating because scar tissue will make it virtually impossible to rupture a ganglion easily.

Moreover, if you fail surgically to remove a ganglion completely, it is more likely to recur, and if you dissect too energetically, you may damage a tendon.

*Never try to aspirate a ganglion!*

If you have to explore for a ganglion, because you cannot rupture it, use a tourniquet, and remove some tendon sheath with the ganglion, trying if possible to keep the cyst of sticky synovial fluid inside the ganglion intact.

Sometimes, a 'ganglion' is actually a synovioma (34.15D), or even a tuberculous nodule! A synovioma gives a characteristic 'snowstorm' appearance on a radiograph.

### 32.17 The carpal tunnel syndrome

This is one of many nerve entrapment syndromes, which occur more often in women than in men and are often worse during pregnancy, and before menstruation. They are the result of pressure on a nerve, as it passes through a narrow tunnel. The median nerve passes through the carpal tunnel on the palmar side of the wrist.

It causes:

- (1) Pain, paraesthesiae and reduced sensation in the distribution of the median nerve (her thumb, the index and the middle finger, and the radial side of the ring finger).
- (2) Weakness and wasting of the muscles of the thenar eminence; the hypothenar muscles are spared.
- (3) Pain in the wrist, usually referred pain to the lower forearm, and sometimes even pain referred to the elbow and upper arm. The pain is worse at night, and she may get some relief by hanging it out of bed. Tapping over the flexor retinaculum (Tinel's sign) may bring on the symptoms.

A similar syndrome, known as *meralgia paraesthetica*, affects the lateral cutaneous nerve of the thigh where it passes medial to the anterior superior iliac spine, and so may be entrapped under the inguinal ligament.

#### NON-OPERATIVE TREATMENT.

- (1) Reduce the oedema with hydrochlorothiazide 25-50mg bd during pregnancy. *Do not operate while she is pregnant*, unless the symptoms are severe.
- (2) Encourage weight loss.
- (3) Inject the carpal tunnel with hydrocortisone suspension 2.5ml and lidocaine 2.5ml.

#### INDICATIONS FOR SURGERY.

- (1) Wasting of the muscles of the thenar eminence.
- (2) Failure of non-operative treatment.

#### METHOD. (GRADE 2.3)

Apply a tourniquet to produce a bloodless field (3.4).

Make an L-shaped incision over the creases on the front of the wrist (32-35). Incise longitudinally for 4cm in the thenar crease, and then transversely for 2cm in the wrist crease. Divide the flexor retinaculum in the line of the arm. Look for the median nerve, *but do not injure it!*

Opposite the proximal edge of the retinaculum you should see an incomplete annular depression, most marked anteriorly, which is the site of pressure. *Do not close the deep tissues.* Close the skin only with 3/0 mono-filament.

### THE CARPAL TUNNEL SYNDROME

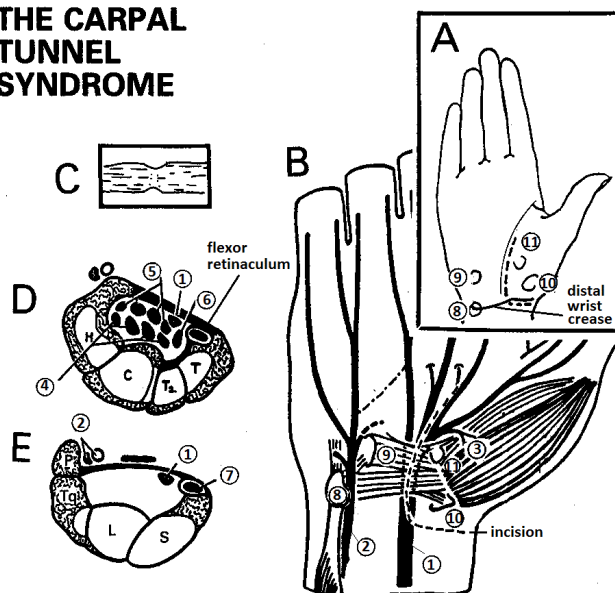


Fig. 32-35 CARPAL TUNNEL SYNDROME.

A, B, landmarks for the incision. C, median nerve with an annular constricting ring round it, caused by pressure from the edge of the flexor retinaculum. D, distal and E, proximal row of carpal bones and the carpal tunnel. H, hamate. C, capitate. T, trapezium. T<sub>2</sub>, trapezoid. L, lunate. S, scaphoid. Tq, triquetrum. P, pisiform.

(1) median nerve. (2) ulnar nerve and artery. (3) muscular branch of the median nerve. (4) flexor digitorum profundus tendons. (5) flexor digitorum superficialis tendons. (6) flexor pollicis longus. (7) flexor carpi radialis. (8) pisiform bone. (9) hook of the hamate. (10) scaphoid tuberosity. (11) trapezoid tuberosity. After Basmajian JV (ed) Grant's Method of Anatomy Williams and Wilkins, 9th ed 1975 Figs 32.17,20. Permission requested.

**POSTOPERATIVELY:** Apply a pressure dressing for 48hrs. Hang the arm up on a support, and watch the circulation in the hand hourly; if there is any problem with this, remove all dressings. Pain should normally be relieved immediately.

If not, *do not delay in reopening the wound!*

### 32.18 The hands in leprosy

A patient with leprosy can lose feeling in the hands suddenly during a lepra reaction, so that he complains of an immediate numbness, or so slowly that he hardly notices it. When this happens, neglected bruises, blisters, and cuts cause scars that progressively destroy the pulps of the fingers. Painless cigarette burns are a common presentation. To prevent this happening he must learn how not to injure himself. Persuade him that it is the injury to the hands which leads to wounds, and not the disease itself. If he fails to care for the fingers, and presents you with a severely disabled hand, there is little you can do, except to maintain such mobility as there is with physiotherapy. Patients are usually able to use their deformed hands quite well, and do not like having their fingers amputated.

Tendon transfers and arthrodeses are sometimes helpful, and you can make a Z-plasty to widen the web of the thumb, but these are not easy operations.

## HANDS AT RISK

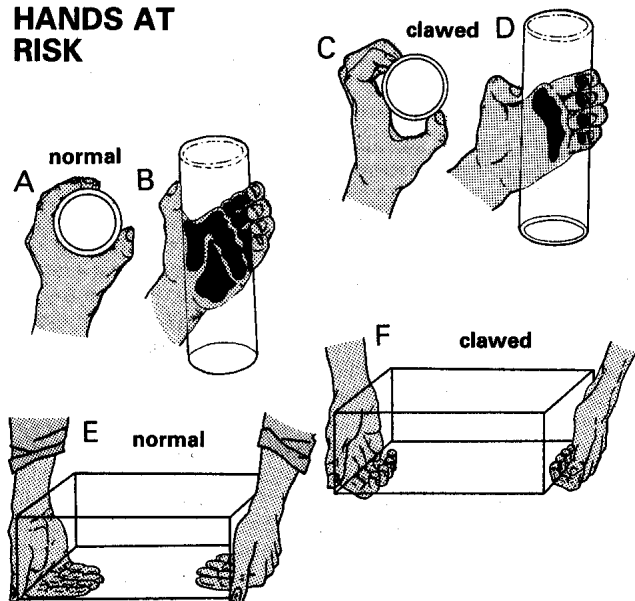


Fig. 32-36 HANDS AT RISK.

The area of skin in contact with the cylinder is black. A, and B, when a normal hand bears the weight of a block or a cylinder, most of its surface bears its weight. C,D, when a clawed hand does the same too much of its weight is borne by the finger tips. E,F, the same phenomenon when a patient lifts a box. This misuse of the finger tips is an important cause of finger absorption. From Brand PW, *Clinical Mechanics of the Hand*, Mosby 1985, with kind permission.

Protect the patient's hands during hard work, either by making sure he wears protective gloves, or by adapting the handles of the tools he uses. He is more likely to consent to wear gloves, than to use modified tools. If he smokes (persuade him not to) he must use a cigarette holder. Make sure that the insensitive hands are soaked and oiled in the same way as the feet (32.11).

**If the flexor surface of the finger cracks,** do not let it heal with a short scar which will be likely to reopen when it is stretched - splint it straight while it heals. Use plaster strengthened with a stiff longitudinal wire, or a short length of stiff plastic hose pipe, cut with a tongue which projects into the palm. Observe the finger carefully for blueness. Initially, remove splints at night, until you are sure they are not occluding the circulation.

**If the dorsum of the hand is scarred, so that the mcp joints become hyperextended,** severe disability will result. This can happen as the result of a lepra reaction, when a thick sheet of inflammatory tissue scars and perhaps ulcerates. Put the hand through a full range of movement daily during the reaction to keep it mobile. Later, a skilled surgical release may be possible.

**If there is one or more severely deformed fingers, such as a terminal phalanx bent to 90°,** consider amputation or, better, an arthrodesis with shortening of the bones to allow for the contracted tissue on the front of the joint.

**If the little finger is badly deformed,** remove it with half its metacarpal. Its absence will hardly be noticed.

**If paralysis is acute,** splint the hand in the position of function at night, and be sure it is moved by day. Ensure that all the joints of the hand are put through their full range daily, using the exercises (32-37D,E).

**If the ulnar nerve is acutely involved,** rest the arm in a sling with the elbow at 90°, and put the whole arm through its full range of motion at least once a day.

**If the lumbricals are involved,** there is danger of development of a claw hand, so teach the exercises described (32-37F,G).

**If the median nerve is involved,** the thumb web may need stretching. Do this by making a suitable mini-cast to wear at night.

**If paralysis is chronic and slowly progressive,** recovery is unlikely, so insist on exercises (32-37A): a paralysed hand is more useful if it is mobile rather than stiff, and is less likely to be damaged at work.

INFECTIONS are common. In leprosy patients they usually present late with abscesses (8.1), tenosynovitis (8.12), septic arthritis (8.15), osteomyelitis (8.16), and gangrenous fingers.

Watch for heat and swelling. Tenderness is often absent and fluctuation is too late to be useful. The first complaint may be painful glands in the axilla. The same principles apply as in normal hands (8.1), with one great difference: the pain which prevents a normal person from using the infected hand cannot protect an anaesthetic one. So make sure that a leprosy patient rests an infected hand, and apply a splint to make sure he does. Apply it in the position of safety with the mcp joints flexed, the ip joints almost fully extended, and the thumb abducted, as if holding a tennis ball.

**CAUTION! Rest is essential: antibiotics on their own are inadequate.**

**If infection starts as a macerated skin crease in a paralysed finger,** splint it with a posterior splint in just sufficient extension to open out the finger and expose it to the air. If a posterior splint is difficult, use a palmar one. If there is any discharge, add an antibiotic.

**If there is septic tenosynovitis,** it is likely to be the result of spread from a pulp infection. Splint the hand in the position of function. If drainage is inadequate, make a further opening in the middle palmar crease (8-4: incision 2).

**If you feel rough bone at the base of an ulcer or sinus in the hand and pus oozes from a joint,** this is osteomyelitis or septic arthritis.

**If you feel rough bone at the bottom of a sinus over the tip of the finger,** this is osteomyelitis of the terminal phalanx. If only part of a phalanx is dead, allow dead bone to separate spontaneously. Otherwise, you are likely to open the joint, causing loss of more finger length.

If most of a phalanx is dead, disarticulate the joint and remove the base.

If there is septic arthritis, aim stiffness in a useful position. Splint the hand and fingers as nearly as possible in the position of function (7.17), and use cloxacillin or chloramphenicol. Immobilize the infected joint for at least 4-6wks after the infection is controlled, and the ulcer healed, while putting all the other joints through their full range of movement daily. If splinting one finger is difficult, you may be justified in splinting it with one of its neighbours, depending on their condition. Curette dead bone and granulations, and pack the cavity with hypochlorite ('Eusol'), honey, ghee or sugar to encourage sequestra to discharge and granulations to fill the cavity. An ankylosis usually takes 12wks and a fibrous arthrodesis 6-8wks.

## HANDS AND FEET IN LEPROSY

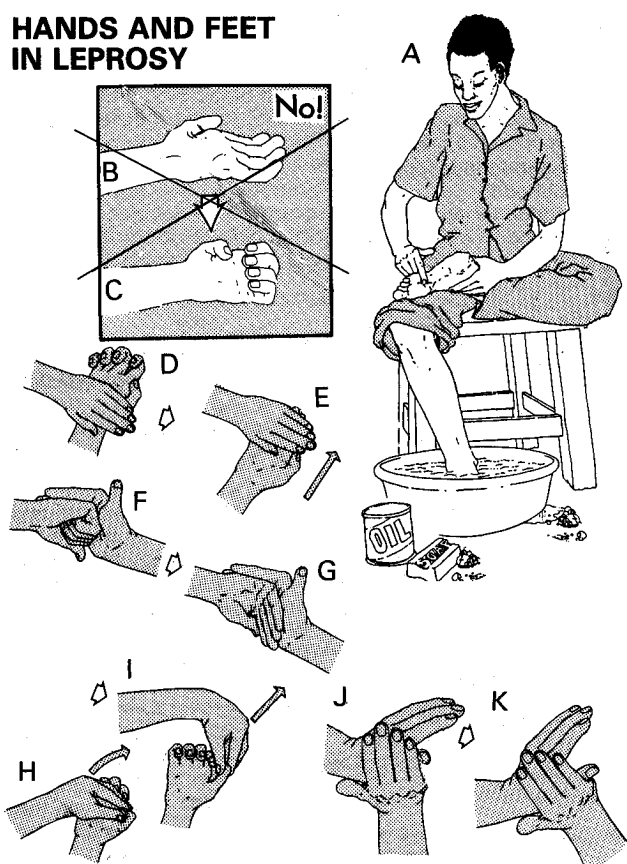


Fig. 32-37 HANDS AND FEET IN LEPROSY.

A, a patient inspecting his anaesthetic feet to find early wounds and 'hot spots'. He is soaking them, and is about to rub them with oil. The exercises shown here are for acute and chronic paralysis, and will prevent a hand like (B) from becoming a stiff claw hand (C) which physiotherapy cannot cure. Instruct the patient like this: D, "Rest the back of your hand on your thigh, or on a table padded by a cloth. E, Use your other hand to rub your fingers as straight as they will go, taking care not to crack any weak skin. F, Cup your knuckle joints in your other palm and keep them firmly bent. G, Then straighten the end two joints of your fingers, as firmly as you can. H, Use your other hand to straighten the end joint of your thumb, as straight as it will go. I, Pull gently and firmly, as if you were trying to lengthen your thumb, but do not pull it backwards. J, rest the little finger side of your hand on your thigh. Use your other hand to support the back of your thumb firmly (to keep its MCP joint flexed). K, then straighten the end joint of your thumb as firmly as you can."

After Watson JM, *Preventing Disability in Leprosy*, Leprosy Mission International, with kind permission.

If there is a grossly swollen hand, with pitting oedema of the dorsum, and obliteration of the concavity of the palm, there is probably a midpalmar space infection (8.9)

If the septic arthritis does not heal, excise the joint. Make a dorsal incision, remove the joint surfaces, and any dead tissues, and splint the joint in a position of function (7.17). Pack the cavity that remains, and allow it to heal by granulation. Keep the joint splinted in the position of function, and wait 12wks till the joints are no longer painful.

## 32.19 Ingrowing toe-nail

Ingrowing toe-nails are unusual in barefooted people. One of the hazards of a shoe is that it may press on the sides of the big toe over a long period, and make the side of the nail grow into the soft tissues and cause pain, inflammation, and the discharge of pus from the nail fold. Carefully cutting away the nail may relieve the symptoms, but if this fails, more radical surgery is indicated. If the toe-nail is not deformed, you can excise a wedge of soft tissue; but if it is deformed, a more comfortable toe will result if you remove the whole toe-nail, including its bed.

If the nail grows back in the same way, you can again remove a wedge, including a wedge of the nail bed. A tourniquet gives a bloodless field: you can achieve this with a rubber twisted around the base of the toe. Use a ring block with lidocaine. *Do not do this operation if there is peripheral vascular disease*; use prophylactic antibiotics with diabetics and advise elevation for 24hrs.

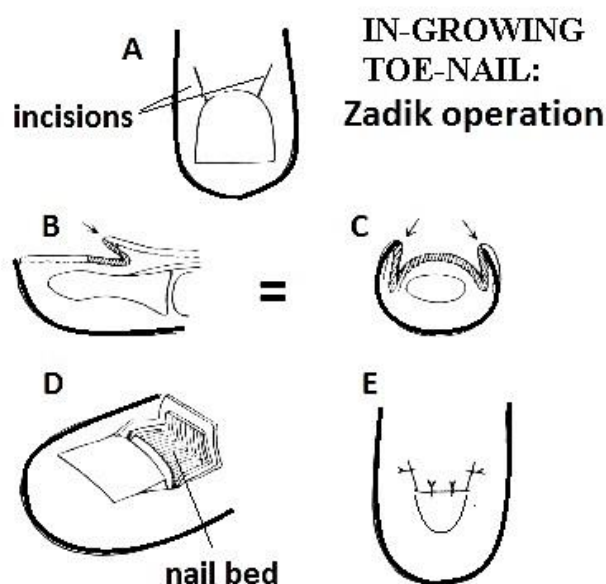


Fig. 32-38 INGROWING TOE-NAIL: ZADIK OPERATION.

A, Incisions. B, Lift the skin and dissecting proximally to the IP joint. C, Transverse view. D, Expose the nail bed. E, Remove the nail and nail bed and then close the wound.

After Kirk RM, Williamson RCN. *General Surgical Operations*. Churchill Livingstone Edinburgh 1987 p.535 Fig 30.38

**If the problem is bilateral**, perform wedge excisions on both sides or remove the whole nail initially by inserting an elevator underneath it and twisting it off.

**If there is infection**, cut a wedge of the in-growing nail off to drain pus. Make sure you extend the incision proximally if there is infection under the nail bed (paronychia). Then wait 6wks till all signs of sepsis have settled. When sepsis has settled, remove the entire germinal matrix (the growth plate) of the nail.

#### ZADIK OPERATION (GRADE 2.1)

Make sure the nail has been removed; use a tourniquet and ring-block. Make two 1cm incisions proximally from the corner of the nail to the transverse skin crease over the IP joint (32-38A). Lift up the skin as a flap proximally to expose the nail bed (32-38B,C): continue the dissection on the sides to expose all the germinal matrix (32-38D). Cut across the nail bed to remove the block as far back as the insertion of the extensor tendon on the phalanx. Close the wound with 3/0 monofilament sutures after removing any fragments of germinal matrix left behind (32-38E).

### 32.20 Malignant tumours of bone

Primary tumours of bone are unusual, and have a characteristic age incidence. There are: osteosarcomas, mostly in the 10-25yr age group, chondrosarcomas (15-50yrs), Ewing's tumours (5-25yrs) and giant cell tumours (15-50yrs). Adamantinomas occasionally occur in the jaw, usually the mandible (31.6), and chordomas mainly in the sacrum. Fibrosarcomas arising from the periosteum behave like fibrosarcomas of the soft tissues. Secondary deposits in bones and myelomas are much more common.

Fine needle aspiration cytology is useful for metastatic carcinoma, lymphoma, myeloma and osteosarcoma, but of no real value in benign tumours. Remember a malignant bone tumour may be well vascularised, so use a tourniquet and have blood cross-matched. *Try to avoid the disaster of a pathological fracture or excessive bleeding after a biopsy, or obtaining an unrepresentative sample.* Remember to supply full details as well as radiographic films to the pathologist.

#### A. OSTEOSARCOMA

About half of all primary bone sarcomas are osteosarcomas; they occur either in teenagers, or rarely as a complication of Paget's disease in men over 60yrs. They are aggressive tumours of osteoblasts, and either spread by local infiltration, or in the bloodstream to the lungs, often quite early.

An osteosarcoma usually presents as a painful swelling or pathological fracture of the metaphysis of the lower femur (40%), upper tibia (20%), upper humerus (10%), or pelvis (10%).

#### RADIOGRAPHS.

(1) Typically, there is an osteolytic lesion of the metaphysis, which expands the periosteum, and produces a triangle (Codman's triangle), of increased density where the tumour meets the normal shaft. You may see lines of 'sun ray' bone spicules.

(2) A few are small lesions with dense osteosclerosis round a lytic lesion with intramedullary 'fluff'.

#### DIFFERENTIAL DIAGNOSIS.

(1) Very important: early acute osteomyelitis; this causes much pain and shows no bone changes (7.2).

(2) Later, osteomyelitis produces a periosteal reaction.

(3) Chronic osteomyelitis causes dense sclerosis, often with sinuses, and usually involves an extensive area of the shaft.

Other differential diagnoses include:

(4) ordinary fractures (especially if they present late),

(5) stress fractures (fatigue fractures),

(6) simple bone cysts & exostoses,

(7) metastatic tumours, and other primary bone tumours.

**CAUTION!** *Osteosarcomas may cause fever.*

*Confirm the diagnosis by cytology or histology.*

**PROGNOSIS** is grim, and there are few long-term survivors. The tumour extends considerably beyond the area of the bone, which is involved clinically, or radiologically. 75% of presentations are with lung metastases, and these occur in 20% within 6 months if you perform an amputation alone. Chemotherapy is of limited value & very high cost.

**MANAGEMENT** consists of amputation and chemotherapy: if there are no metastases, amputate if this is practicable, and try to organize a régime of cisplatin & doxorubicin which may allow survival in 60%.

#### B. CHONDROSARCOMA

About 20% of primary bone tumours are chondrosarcomas; they occur in the pelvis (30%), the femur (the lower rather than the upper end, 20%), the ribs (10%), and the skull and facial bones (10%). Most arise *de novo*, but about 20% arise in patients with multiple chondromas, and <5% from patients with a pre-existing chondromas. They are less aggressive than osteosarcomas, and spread by local infiltration; bloodstream spread is late. The histological grading is useful in establishing the likely prognosis.

Presentation is with a bony swelling which is often slightly painful and tender. Pelvic masses are hidden by the overlying tissue, and present late.

**RADIOGRAPHS** show an area of translucency with trabeculae, multilocular areas of bone destruction, and scattered fluffy areas of calcification. There is usually a surrounding area of soft tissue swelling. Cortical destruction is late, and periosteal reaction is limited.



DIFFERENTIAL DIAGNOSIS includes:

- (1) subacute and chronic osteomyelitis,
- (2) chondromas (benign tumours of cartilage),
- (3) bone cysts, or fibrous dysplasia,
- (4) other bone tumours.

*Confirm the diagnosis by cytology or histology.*

**PROGNOSIS.** Without treatment 5% of patients survive 5yrs, and none 15yrs. Adequate surgery enables 50% of patients to survive 5yrs and 35% 15yrs.

**MANAGEMENT.** Amputate through the bone or joint proximal to the tumour. The recurrence rate after adequate excision is low. Early rib lesions have the best prognosis. If you suspect a rib lesion, resect it with at least 5cm of rib on either side, and preferably remove some of the neighbouring ribs. This requires GA and intubation, in case you open the pleura (9.1).

### C. GIANT CELL TUMOURS

These unusual tumours form about 5% of all primary bone tumours; most arise *de novo*, and a few in Paget's disease of bone. The common sites are the epiphyses around the knee (femur, tibia and fibula 50%) the lower radius (15%), the pelvis and sacrum (12%), and the maxilla (29.16). They consist of giant cells (like osteoclasts) and fibroblasts, and are graded histologically as I (low grade), II (intermediate) and III (relatively malignant). First they expand the cortex, and then they spread through it. Lymphatic spread is rare, and distant metastases unusual, but local recurrence after inadequate excision is common.

**RADIOGRAPHS.** Typically, there is an eccentric osteolytic lesion in the epiphysis which extends into the metaphysis in larger tumours, and has a 'soap bubble' appearance. There is usually little sclerosis of the cortex. A defect in it is a sign that the tumour has penetrated it. In small bones there are non-specific lytic lesions.

DIFFERENTIAL DIAGNOSIS is as for chondrosarcoma.

**PROGNOSIS** is good because metastases may never occur. After total excision 70% of patients survive 35yrs. After curettage the 5, 10, and 35yr survival rates are 45%, 40%, and 35% respectively.

**MANAGEMENT.** Total excision of the lesion and replacement with bone grafts is necessary.

### D. EWING'S TUMOUR

Ewing's tumour is rare. It consists of densely packed small round cells. It commonly arises in the diaphysis of a long bone; the femur (20%), the tibia (20%) the humerus (10%), and the pelvis (20%).

The patient presents with:

- (1) a moderately painful, tender, warm, bony swelling, mild fever, and a leucocytosis,
- (2) with a pathological fracture. There is a 30% chance that he already has widespread metastases in the other bones.

**RADIOGRAPHS** show a patchy osteoporosis, which is either 'moth eaten', or has defined lacunae. There is usually a periosteal reaction (typically an 'onion skin' appearance) in the intermediate stage. This is not present at first, and disappears as the tumour expands.

DIFFERENTIAL DIAGNOSIS:

- (1) Subacute and chronic osteomyelitis mimic Ewing's tumour closely.
  - (2) Metastatic neuroblastoma,
  - (3) Non-Hodgkin's lymphoma in bone,
  - (4) Fibrous dysplasia.
- Confirm the diagnosis by biopsy.

**PROGNOSIS.** Untreated, almost no patient survives 5yrs.

**MANAGEMENT.** Best results are achieved by surgery, chemo- and radiotherapy combined.

### E. MULTIPLE MYELOMA (MYELOMATOSIS)

This malignant tumour of plasma cells is more common than the primary tumours of bone, and causes widespread osteolytic lesions in any bone, particularly the vertebrae, pelvis, ribs, and skull. When extraosseous lesions occur, they are usually formed by tumour growing from a bone.

The patient, male or female, and is usually between 40 & 70yrs, presents with bone pain, especially in the back (75%), anaemia (50%), ill health, and loss of weight. He may also have anaemia, renal impairment, hypercalcaemia, and decreased resistance to infection. In practice, the diagnosis is difficult, because of the non-specific nature of the presenting symptoms.

**RADIOGRAPHS** may show well defined osteolytic lesions, usually without cortical thickening or sclerosis, but sclerotic lesions can occur, especially after treatment. Sometimes, there are no discrete bony lesions.

**SPECIAL TESTS.**

- (1) Bence-Jones protein is present in the urine of 50% of cases (this precipitates during heating, and dissolves again near boiling point).
- (2) Increased immunoglobulins in the blood (95%).
- (3) The alkaline phosphatase is nearly always normal, the prothrombin index is increased, and the ESR greatly so.
- (4) Bone marrow aspiration & biopsy confirm the diagnosis, and shows many abnormally large plasma cells, with poorly defined chromatin. Take a core specimen in addition to aspirating it, because tumour cells are usually in clumps.

DIFFERENTIAL DIAGNOSIS includes:

- (1) senile osteoporosis (especially when this produces kyphosis),
- (2) carcinomatosis of bone,
- (3) myelofibrosis.

**PROGNOSIS.** Untreated, most patients die in 6 months to 3yrs. Melphalan or cyclophosphamide with prednisone increase the average survival from 17-52 months.

## MANAGEMENT.

Treat anaemia by transfusion. Treat infection of the chest and urinary tract. Maintain good urine output by encouraging a high fluid intake. Decide if chemotherapy is possible, or worthwhile, in relation to other problems. You may also need to treat pathological fractures, paraplegia from spinal deposits, amyloidosis and hypercalcaemia.

**If there appears to be only one tumour (solitary myeloma)**, you will probably find other deposits, if you look hard enough. If there really is only one deposit, and it is affecting vital structures, remove it, if you can, and add chemotherapy. Otherwise, manage it like multiple myeloma.

## 32.21 Other orthopaedic problems

**If a child is born with an extra digit** (common and often bilateral), it usually consists of skin and subcutaneous tissue only. If so, tie cotton tightly round its base; it will soon necrose and fall off. If it is larger and contains bone, leave it for six months, when anaesthesia will be safer, and perform a formal amputation (35.4). For a true double thumb (with functioning joints in each half), perform a hemisection, leaving the most appropriate part. Remember to examine all 4 limbs for extra digits, and look out for kidney anomalies, often associated.

### AMNIOTIC BANDS

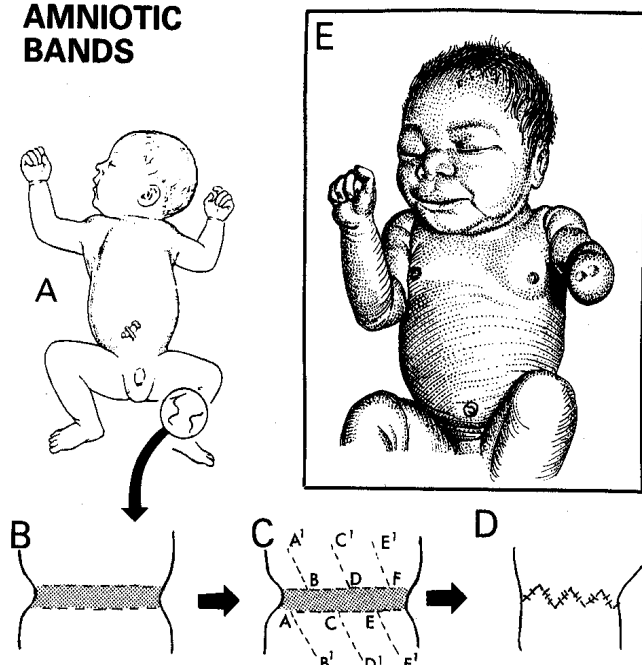


Fig. 32-39 AMNIOTIC BANDS sometimes amputate a limb in utero, as in the neonate E. If they merely cause a constriction (A), excise the constricted area (B), plan multiple small flaps (C) and perform a Z-plasty (D). Kindly contributed by Jim Thornton.

**If there are congenital constrictions of one or more limbs** (rare), they are probably due to compression by AMNIOTIC BANDS. These are like adhesions in the peritoneal cavity. A scar is formed which leads to amputation *in utero* (32-19E), or to circumferential constriction of a limb. The limb may become ischaemic, because the constricting tissue does not grow.

Apply a tourniquet <150mm Hg and for <30mins. Excise the lesion down to normal tissue (usually, only the skin and subcutaneous tissue are involved) (32-39B). Close the defect with multiple Z-plasties (34.2). Bring A to A' and B to B', etc. (32-39B,C,D).

*If you join the skin edges side to side, the constriction is more likely to recur.*

**If fingers are fused together** (SYNDACTYLY, fairly common), usually several fingers are involved. The hand may be quite functional especially as an infant. *Do not try to separate them with straight cuts through the webs*, because a severe flexion contracture will follow. At 2-3yrs of age, multiple Z-plasties, an inverted 'V' procedure for the web, and skin grafts for the defects are indicated. This is difficult surgery.

The importance of doing this depends on:

- (1) how many fingers are involved,
- (2) which fingers are involved,
- (3) the skill of the surgeon.

A web between the index and middle fingers is more serious than one between the ring and little fingers.

**If the toes are fused together**, leave them alone.

**If the legs are folded in  $\leq 50^\circ$  of hyperextension** (*genu recurvatum*), flex them to  $45^\circ$  and hold them there with plaster backslabs for 3wks. Normal growth without any disability will probably ensue. Occasionally, this is due to a true congenital contracture of the quadriceps which needs surgery.

## PROBLEMS IN OLDER PATIENTS

**If a young adult complains of severe hip pain without signs of fever or inflammation**, think of avascular necrosis of the femoral head, which occurs with HIV, steroid injections, alcohol and certain medications. Severe cases may benefit from a femoral osteotomy to avoid pressure of the upper end of the femur against the acetabulum. Otherwise, look on a radiograph for a flattened femoral head or bony protuberance of the acetabulum which prevent full hip abduction.

**If there is a bony outgrowth on the metaphysis**, which also has a marrow cavity and a normal bony structure, this is an EXOSTOSIS. There may be one, or many (diaphyseal aclasis). If possible, leave it until growing has stopped, unless it is in an awkward place, and is causing disability. Then chip it off with an osteotome. If you have to remove a prominence before growth has stopped, *take care not to damage the epiphyseal line*. Otherwise, a severe growth deformity may result.

**If a bone cyst develops**, usually in a child in the shaft of the humerus or femur, the possibilities include a benign bone cyst, fibrous dysplasia, benign osteoblastoma, non-osteogenic fibroma, enchondroma, Brodie's abscess (7-2A), and tuberculosis. If it is benign, it is probably a BENIGN BONE CYST, or an area of fibrous dysplasia. *Aim to avoid a pathological fracture.* The cyst may need to be opened, scraped out, and filled with a cancellous bone graft, if it does not resorb spontaneously.

**If the bone fractures across a small cyst**, it will probably heal spontaneously.

#### EPICONDYLITIS (TENNIS ELBOW)

This is a common condition in people who use the extensor muscles of their forearms vigorously, and not only in tennis players. It is caused by minute tears in the origin of the forearm extensor muscles. The patient complains of pain just distal to the lateral epicondyle of the humerus, without any history of trauma. The pain is worse when you press over the radio-humeral joint during pronation and supination. It lasts for months, or years, and may eventually disappear spontaneously. If it is debilitating, treat by injection of hydrocortisone suspension 2.5ml with an equal volume of 2% lidocaine into the tender area. One injection has an 80% chance of success, and a second one 2-3wks later another 10%. Take very careful aseptic precautions, and *do not use >3 injections*. If the disability is severe, a muscle slide on the extensor origin is necessary.