

35 Vascular surgery

35.1 Varicose veins

ANATOMY AND PHYSIOLOGY.

There are four categories of leg vein, and they all have valves which stop blood flowing downwards away from the heart.

(1) **Long and short saphenous veins** run superior to the deep fascia, and are usually deep to the fibrous layer of the superficial fascia (35-1). They have numerous valves, the most important of which is the femoral valve, in the long saphenous vein, just before it penetrates the deep fascia to join the femoral vein. The femoral valve prevents blood from the femoral vein flowing back into the saphenous vein.

(2) **Superficial collecting veins** are tributaries of the saphenous veins. They lie between the skin and the fibrous layer of the superficial fascia. These have valves, but they are poorly supported by connective tissue.

(3) **Deep veins** accompany the arteries, and run among the muscles deep inside the leg. These have important valves.

(4) **Perforating veins** pass through the deep fascia, joining the superficial collecting veins to the deep veins. Their valves direct blood into the leg. The most important of these perforating veins are just behind the medial border of the tibia.

Standing at rest, the superficial veins on the dorsum of the foot support a column of blood that reaches to the right heart. While the leg muscles are relaxed, this blood flows through the perforating veins, into the deep veins inside the leg. On walking, the contractions of the leg muscles squeeze the blood from the deep veins up towards the heart. This cycle of contraction and relaxation reduces the pressure in the superficial veins, and prevents varicosities.

However, if the valves of the deep perforating veins are incompetent, blood from inside the leg is pushed out at high pressure into the unsupported superficial collecting veins. This distends them, and makes them varicose. The increase in venous pressure makes capillary pressure increase, which results in tissue oedema, and leakage of fluid into the tissues, hence tissue oedema. This fluid is rich in albumin and so infection is a real risk, especially as the nutrition of overlying skin becomes impaired.

If the valves which guard the long and short saphenous veins are incompetent, the blood in the femoral and popliteal veins can flow downwards, into the saphenous veins, and make them varicose.

The aim of surgery is to stop blood flowing backwards through veins with incompetent valves.

Varicose veins are the result of failure of the valves in the venous system, which takes two forms:

(1) **Primary:** the valves of the saphenous system fail, while the deep veins of the legs remain normal; the symptoms are usually mild, and the legs rarely ulcerate.

(2) **Secondary (post-thrombotic):** the deep veins, or the communicating veins between the superficial and deep systems, have had their valves destroyed by thrombosis: ulceration is more common, and treatment more difficult.

Varicose veins are generally associated with Western life-styles; obesity and low-fibre diets play a rôle.

They are unsightly and cause aching and cramps, a scaly, itchy, varicose eczema, swelling of the legs, and ulceration; occasionally they bleed. Symptoms may bear little relationship to their size and extent. If they are primary, the swelling usually only involves the feet and ankles, and resolves completely overnight. If they are secondary, the lower legs may be swollen all the time.

Make sure the pain is due to the varicose veins (relieved on lying down, worse at the end of a day's standing), and not due to (invisible) ischaemia, arthritis of the hip or knee, a prolapsed intervertebral disc, or *meralgia paraesthetica* (32.17) which can be there at the same time as the (visible) varicose veins. Swelling of the legs may co-exist with varicose veins, but is usually due to another cause, *e.g.* heart failure or lymphoedema.

Very occasionally varicose veins are the result of an **arterio-venous fistula**: you should be able to hear a bruit and feel a thrill over the fistula. The veins may be enormous. Occlusion of the fistula by pressure will, however, make them disappear.

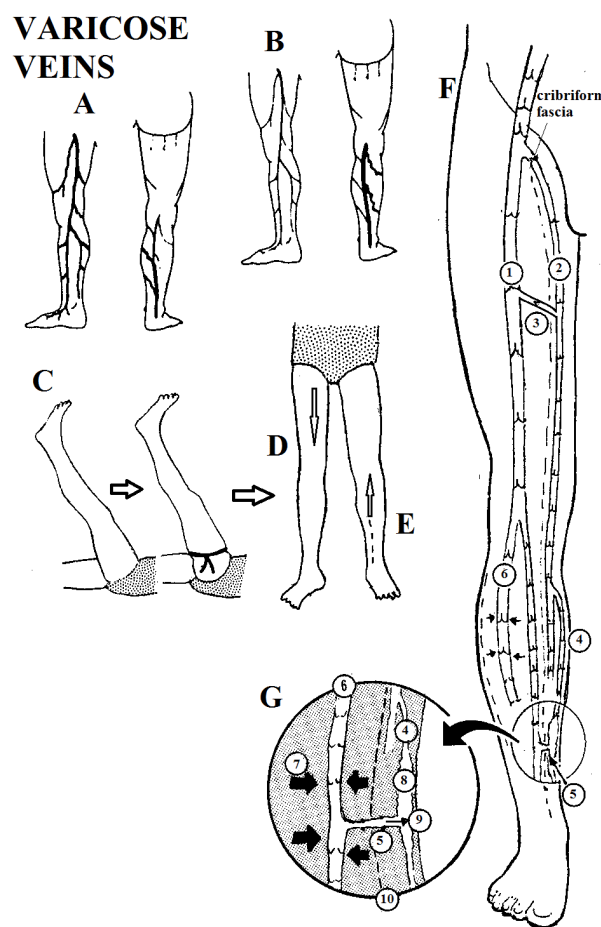


Fig. 35-1 VARICOSE VEINS: ANATOMY.

A, varicosities of the long saphenous system. B, varicosities of the short saphenous system. C, Trendelenburg test for the long saphenous vein: lay the patient supine and raise the leg. Apply a venous tourniquet just below the saphenous opening. Ask him to stand up and release the tourniquet. D, if the femoral valve is incompetent, the veins fill immediately from above. E, if it is normally competent, they fill slowly from below. F, anatomy of the veins of the leg; the long saphenous enters the femoral vein through the cribriform (deep) fascia. G, close-up view of a varicosity, and an incompetent perforating vein connecting it with the deep venous system.

(1) femoral vein. (2) long saphenous vein, passing through the cribriform fascia. (3) mid-thigh perforating vein. (4) superficial collecting vein. (5) perforating vein with its valves destroyed. (6) deep veins of the leg. (7) muscular forces compressing the deep veins. (8) varix in a superficial collecting vein. (9) blood forced through a perforating vein with an incompetent valve. (10) superficial fascia.

After Ellis H, Calne RY. *Lecture Notes on General Surgery*, Blackwell Science, 10th ed 2002 p.93 Fig 12.1, with kind permission.

**BE SURE THAT THE VALVES
OF THE DEEP VEINS ARE COMPETENT
BEFORE YOU TIE THE SUPERFICIAL VEINS**

VARIATIONS IN THE GROIN ANATOMY OF THE SAPHENOUS SYSTEM

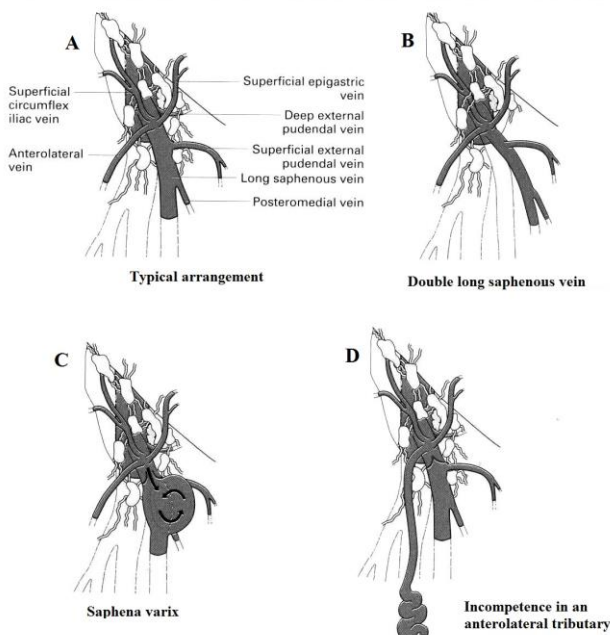


Fig. 35-2 VARICOSE VEINS: GROIN ANATOMY.

A, typical arrangement. B, double long saphenous vein. C, saphena varix. D, incompetence in an anterolateral tributary. After Morris, PJ, Malt RA. *Oxford Textbook of Surgery*, OUP, 1994 p.550 Figs 51a-c.

EXAMINATION. Examine the patient standing in a good light. Feel the veins. If he is obese, percuss the course of the saphenous veins. Examine the peripheral pulses. Feel for a thrill in the vein above as you tap it below, and listen for a bruit of a (rare) arteriovenous fistula.

If there is ulceration, thick induration, and marked hyperpigmentation, the valves of the deep veins are almost certainly incompetent, and the varicose veins are secondary. Otherwise they are probably primary. Perform the Trendelenberg test:

To test the competence of the perforating veins and the valves of the greater saphenous system, lay the patient supine, raise the leg, and massage the veins proximally to empty them. On the upper thigh apply a rubber tourniquet, tight enough to compress the veins. Then ask him to stand and move the forefoot up and down, so as to actuate the calf muscle pump. Inspect the varices for 30sec, and then remove the tourniquet (35-1C,D,E).

If the veins gradually fill from below on standing, and continue to fill gradually from below when the tourniquet is released, the valves in the veins of the legs are normal.

If the veins fill rapidly from below, the varices are being filled from the deep veins, and the valves of the perforating veins are incompetent.

If blood flows rapidly into the long saphenous vein from above, after removing the tourniquet, the long saphenous valve is incompetent.

If finger pressure on the upper part of a thigh varicosity controls blood flow, the anterolateral tributary is incompetent, by-passing the main long saphenous valve (35-2D).

To test the competence of the valves of the short saphenous vein, lie the patient flat and apply 2 tourniquets, one above the knee to occlude the long saphenous vein and another just below the popliteal fossa to occlude the short saphenous vein. Ask the patient to stand up, leave the upper tourniquet on, and remove the lower one. If the blood flows immediately into the short saphenous vein from above, the short saphenous valve is incompetent.

To find the sites of major incompetent perforating veins:

- (1) Look for visible and palpable 'blowouts' of subcutaneous veins.
- (2) Feel for circular gaps in the deep fascia below the visible or palpable 'blowouts'.
- (3) Repeat the tourniquet test at each level above a 'blowout', to see if this prevents the 'blowout' appearing.

SPECIAL TESTS. Doppler ultrasound is easy: pressure on the vein above causing a rush flow below indicates incompetence. *N.B. Do not perform a venogram with contrast:* you may cause the thrombosis you want to avoid!

DIAGNOSIS.

Suggesting primary varicose veins: usually start at 15-25yrs. No incompetence of the perforators shown by the test above. Incompetence demonstrated by back-flow on release of the upper thigh tourniquet (long saphenous), or just below the popliteal fossa (short saphenous).

Suggesting secondary varicose veins: obesity, multiple pregnancies, or a pelvic tumour; a history of venous thrombosis, an older age, less obvious veins partly hidden by eczema, fat necrosis, or ulceration.

NON-OPERATIVE TREATMENT INDICATIONS.

- (1) Minor symptoms.
- (2) Uncertainty whether symptoms are really due to varicose veins.
- (3) Untreated HIV disease.

METHOD.

Encourage weight loss if appropriate, frequent walking, avoiding prolonged standing and sitting, and raising the leg when seated. Try to fit graduated compression stockings from the distal metatarsals to thigh or calf (depending on whether long or short saphenous system is affected).

CAUTION! Make sure that the stockings are not too tight to give a tourniquet effect: however, *they are no use if too loose!* Ordinary elastic bandaging is not as good but better than nothing.

N.B. They are uncomfortable in hot climates though!

SCLEROTHERAPY OF VARICOSE VEINS

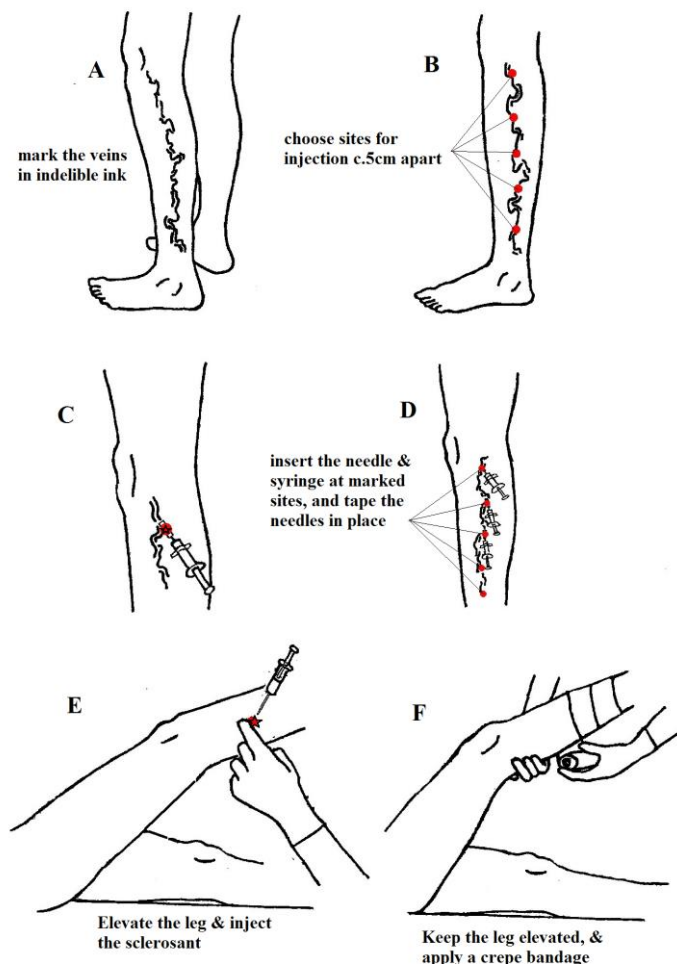


Fig. 35-3 SCLEROTHERAPY.

Method. A, mark the visible varicose veins. B, choose maximum 5 injection sites c. 5cm apart: mark these in a different colour ink. C, insert a needle and syringe and check that the needle is correctly in the vein by withdrawing a spot of blood, then tape needle and syringe to the skin. D, tape further needles and syringes to the skin. E, elevate the leg and inject the sclerosant, starting from the site nearest the foot and apply pressure. F, apply crepe bandage up to last injection site, and continue the injections.

Kindly contributed by George Poulton

SCLEROTHERAPY (GRADE 1.2)

INDICATIONS.

- (1) The cosmetic treatment of small primary varicose veins.
- (2) Incompetent perforating veins without an obvious incompetent major valve.
- (3) Varicose veins which persist or recur after stripping.

CONTRAINDICATIONS.

- (1) An incompetent major valve.
- (2) Large varicosities.
- (3) Gross obesity (it is difficult to maintain compression).
- (4) Deep venous thrombosis.

EQUIPMENT. 5 small syringes fitted with fine needles and filled with 0.5ml of 3% sodium tetradecyl sulphate, or 5% ethanolamine oleate. 2 different colour marking pens, strapping, gauze, crepe bandages and graduated compression stockings.

CAUTION! Anaphylaxis is rare but may occur, so have hydrocortisone & adrenaline to hand.

The veins must be almost empty when you inject, and be kept empty so that their walls adhere, so careful bandaging is critical. If you inject sclerosant into an artery, you may cause extensive gangrene, so do not inject around the ankle.

METHOD.

You need an assistant. Ask the patient to stand up, observe, palpate, and percuss the veins; mark them with a permanent marking pen. Then ask him to lie down, elevate the foot, and feel the course of the veins for gaps in the fascia (sites of incompetent communicating veins). Mark these with a pen of a different colour. Press with the tips of your fingers on as many of these gaps as you can, and, still pressing, ask him to stand. Remove your lowermost fingers first. If removing your finger from a gap in the fascia immediately causes the vein to fill, that gap is the site of an incompetent perforating vein. If it does not fill, there was no perforator in it. The sites where pressure controls the filling are the best sites for injection. Inject the lowest sites first.

Ask him to sit on a couch with the affected leg over the edge of the bed so that the vein fills, insert the mounted needle at the marked sites c. 5cm apart, and aspirate only as far as the transparent hub to be sure you are in the vein, and strap the syringes securely to the skin; then empty the vein by raising the leg above the horizontal. Isolate the segment to be injected by pressing with your fingers above and below it, and inject 0.5ml of sclerosant. Apply a pressure pad over the injection site to keep the vein empty, and apply a crepe bandage up to that site. Then move up to the next site, and repeat the process until all your chosen sites have been injected. *Do not inject >5 sites.* Leave a gap in the bandaging for knee flexion.

N.B. You might find butterfly needles easier.

Apply a graduated compression stocking over the bandage and immediately encourage walking for 1hr, and thereafter for 5km daily. Advise elevation of the legs as much as possible. Remove the bandages for a wash after 1wk. Then re-apply the bandages *od*, with the leg raised, for at least 3wks in order to maintain pressure without interruption. If the bandages become loose, reapply them. Further injections for missed or recurrent veins may be necessary: wait 3months before doing this.

If there is severe pain after the injections, take off the bandages with the leg elevated and look for skin necrosis or gangrene. Use analgesics and encourage walking if there are no untoward effects.

LONG SAPHENOUS VEIN LIGATION, STRIPPING & AVULSIONS FOR VARICOSITIES (GRADE 2.5)

Determine whether there is long sapheno-femoral or short sapheno-popliteal incompetence. Make sure the deep venous system is patent. Wait till after delivery if the patient is pregnant. If a patient is on oral contraceptives, she should stop them one month before operation.

EQUIPMENT. STRIPPER, for varicose veins, Nabatoff, in sterilizer case, complete with 3 metal olives, cable and handle. (Some strippers have olives that can be attached at either end)

LIGATION & STRIPPING OF VARICOSE VEINS

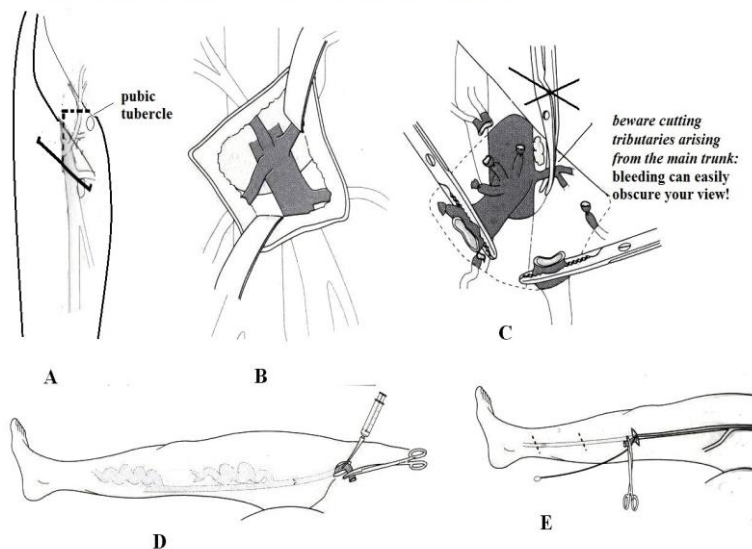


Fig. 35-4 VARICOSE VEINS: LIGATION & STRIPPING.

A, incision 2cm lateral and below pubic tubercle. B, expose the saphenous vein and tributaries (note the medial axis of the long saphenous vein compared to the femoral). C, divide the saphenous vein and tributaries. D, syringe test to prove incompetence. E, pass the stripper through the groin downwards. After Morris PJ, Malt RA. *Oxford Textbook of Surgery*. OUP 1994, p.551-2 Figs 51e(i,iii),f(iv,vii)g(ii),h(ii).

PREPARATION.

Scrub the groin thoroughly with betadine and make sure the legs are well washed beforehand. With the patient standing, mark the vein to be operated on, and all its tributaries and dilations, using a permanent marking pen. Also find and mark the perforating veins, using the finger-pressure method described above.

FOR THE LONG SAPHENOUS VEIN, lay the patient supine with a 30° head-down tilt with the feet apart. Support the heels on foam cushions.

Make a 5cm oblique incision 1-2cm below and parallel to the inguinal ligament, centred a finger-breadth medial to the pulsating femoral artery (35-4A). Deepen the incision, until you reach the superficial fascia. Proceed carefully using non-toothed dissecting forceps, spreading the fatty tissues gently with scissors to expose the saphenous vein (35-4B).

You may find the superficial external pudendal artery in the way, running over or under the long saphenous vein; make no hesitation in ligating and dividing it if it is in the way. You often come to tributary veins of the saphenous first before the vein itself. Tie and divide all these tributaries (35-4C). Then dissect out the groin end of the saphenous vein and demonstrate the sapheno-femoral junction as the vein dips down through the cribriform fascia (35-1F).

Tie the saphenous vein securely with two ligatures as close to its entry to the femoral vein as you can, making sure no further tributaries enter above your ligature. Clamp the saphenous vein a suitable distance from the femoral vein with haemostats and divide it.

N.B. There may be a *saphena varix*, a dilated saccule below the incompetent valve; you will need carefully to get above this to ligate the vein satisfactorily.

CAUTION! If you encounter much bleeding, do not clamp blindly with haemostats, or you may damage the femoral vein, or even the femoral artery. Instead, apply pressure, and raise the foot of the table. Get the suction ready. After 3mins pressure you can usually find the bleeding point and control it, either with a haemostat or a fine silk stitch.

Then mobilize more length of the saphenous vein down the leg; place an untied ligature round it and holding one edge of the vein carefully with dissecting forceps, release the haemostat. If there is too much bleeding from the open vein (because the patient was not put in head-down tilt), re-apply the haemostat further down the leg. Introduce a wide-bore cannula into the lumen of the vein, and inject 20ml of saline; no resistance should be found, and the varicosities should be shown to bulge (35-4D). If this is the case, introduce the stripper (one with a suitably-sized olive) into the vein and tie the ligature to prevent it falling out (35-4E).

N.B. Make sure you have put the stripper inside the saphenous vein and not the femoral!

Release the haemostat, if applied, and manipulate the stripper down the leg, by twisting and turning it. You may guide its passage by external manipulation as well. Try to get it to mid-calf position; *do not try to go as far as the ankle where nerves are close to the vein and may be damaged by avulsion*. Sometimes the stripper gets stuck because of the tortuosity of the varicose vein; in this case you can make a small incision over where the stripper has reached, dissect out the vein and manipulate it further by direct vision. You may have to open the vein between ligatures to do this successfully.

When the stripper has reached its destination, make a 2cm incision over the olive, dissect out the vein, pass looped ligatures underneath the vein at two sites, tie the lower ligature tight and divide the vein. Extract the olive from inside it, and tie the ligatures round the stripper and vein.

Now make 0.5cm long incisions through the skin over the various tributaries marked in indelible ink. Select prominent remaining varicosities, and by spreading forceps raise a loop of varicose vein by gentle blunt dissection. Follow it as carefully as you can in each direction and when you have exposed as much length of vein as you can, pull it out. Get your assistant to press on the site to stop the bleeding. There is usually no need to tie the vein unless it is large or perforates the deep fascia. Close the small skin incisions with one suture.

N.B. Do not go as far as the ankle with avulsions.

Now raise the leg high and slowly pull out the stripper attached to the vein out from the groin. Keep the leg high for a few minutes afterwards to reduce bleeding. Examine the groin wound for bleeding. Examine the avulsed vein for its length to make sure you have extracted it *in toto*; make sure the olive is still attached to the stripper. Close the remaining wounds, and bandage the leg firmly.

DIFFICULTIES WITH STRIPPING VARICOSE VEINS

If the varicosities do not bulge with the syringe test, incompetence may be in the anterolateral tributary (35-2D); dissect this out, and do the test again. Pass the stripper down this vein.

If the stripper does not pass below the knee, make an incision over the marked route of the varicose saphenous vein at a suitable point, and introduce another stripper in the same way from below, so that the 2 strippers meet. You can then try to manipulate the proximal stripper upwards, following withdrawal of the first one, or simply pull out each stripper in turn.

If the olive becomes detached, palpate where it has dislodged, and make a 3cm incision over it. Dissect down and remove it; bleeding may be troublesome, so have suction ready.

ANATOMICAL VARIATIONS OF THE SHORT SAPHENOUS

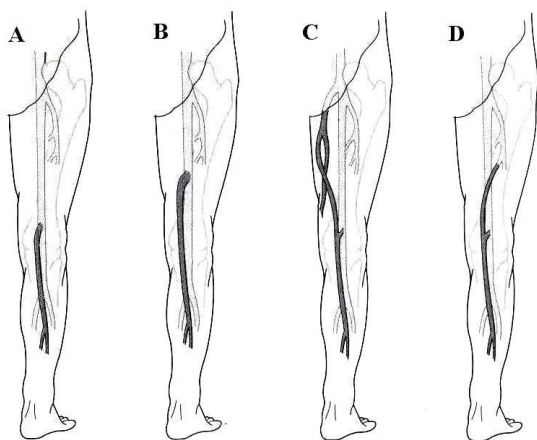


Fig. 35-5 ANATOMICAL VARIATIONS OF THE SHORT SAPHENOUS VEIN. A, normal level of the sapheno-popliteal junction. B, high level termination. C, upward extension to join the posteromedial tributary of the long saphenous vein. D, upward extension deep to the profunda femoris vein. After Morris PJ, Malt RA. *Oxford Textbook of Surgery*, OUP, 1994, p.553 Fig51j.

FOR THE SHORT SAPHENOUS VEIN, you need either spinal anaesthesia or GA and intubation. Use at least 2 assistants to turn the patient by a log roll and lay him prone with the feet apart, and the knees slightly flexed. Put pillows under the chest and pelvis, and make sure the neck is supported, and the abdomen can move freely. It is best to put the arms flexed above the head.

CAUTION! *If your team is not familiar with GA in the prone position, do not attempt it!*

Make a transverse incision across the middle of the popliteal fossa and deepen it through the deep fascia to expose the short saphenous vein (which lies deep to it). Dissect it out, ligating its tributaries, and trace the knee end down into the popliteal fossa, and doubly ligate it close to its communication with the popliteal vein.

CAUTION! The anatomy of the short sapheno-popliteal junction is notoriously variable (35-5). *Do not attempt to strip the short saphenous vein* as it is closely accompanied by the sural nerve, and avulsion may well result in anaesthesia of the lateral foot and calf. Also, there may be short *and* long saphenous incompetence! However, select prominent remaining *superficial* varicosities outside the deep fascia, dissect these out through 0.5cm incisions, and avulse them.

POSTOPERATIVELY, keep the legs elevated at 30° for 24hrs. Encourage walking as soon as possible for 1hr daily. Leave the pressure bandage applied at operation for 1wk, then remove the sutures. Advise wearing bandages for a further 2wks.

If varicose veins recur, try sclerotherapy if the varicosities are limited. Recurrence may occur when some tributaries of the saphenous vein or a double vein are not ligated; to re-explore the sapheno-femoral junction is quite hazardous because of scarring, though, and mapping of the veins by Doppler is usually necessary.

COMPLICATIONS OF VARICOSE VEINS

VARICOSE ULCERATION.

N.B. Most lower leg ulcers in the tropics are chronic tropical ulcers (34.9) and varicose ulcers due to incompetent perforators are less common. If the ulcer is not typically the result of varicose veins, consider alternative causes.

A varicose ulcer is usually on the lower $\frac{1}{3}$ of the leg, especially just behind and above the medial malleolus. It may be of any size and shape, its edges are usually brown and eczematous, and it has red granulations under the slough on its base. The patient is usually obese. Progressive fibrous atrophy of the subcutaneous tissues of the lower leg ('inverted bottle leg'), and liposclerosis precedes ulceration. There are gross varicose veins of many years' standing with incompetent deep perforating veins in 50% of cases.

TREATMENT.

Be prepared for a long haul! Insist on bed-rest and apply frequent sterile water soaks until the ulcer is clean and oedema has gone. Deslough the wound, and when clean, apply betadine or zinc oxide paste.

Only use antibiotics if there is associated cellulitis (6.22).

Do not use topical antibiotics.

Advise cleaning the ulcer once or twice daily, and sleeping with the foot of the bed raised.

When dressings are no longer cumbersome, apply graduated compression stockings from the base of the toes to the thighs. Recent ulcers (<3months) will often heal this way; but a graduated compression stocking should be worn for life, despite the discomfort in the heat.

If the ulcer will not heal or recurs, there is no history of deep vein thrombosis and you can be sure of the venous abnormality, check for malignant change (characterised by firm nodules) and take biopsies. Otherwise, treat the varicose veins by operation to reduce orthostatic venous pressure on the skin. Try honey, ghee, pawpaw or banana dressings (2.10). Then think of skin-grafting if the ulcer surface is granulating well (34.9).

HAEMORRHAGE

If varicose veins bleed, haemorrhage can be alarming. Elevate the leg and apply pressure to the bleeding vein. If bleeding persists or recurs, take the patient to theatre to expose and isolate the vein and ligate it formally.

SUPERFICIAL THROMBOPHLEBITIS

If an indurated line develops along the course of the vein, advise that it will usually be gone in a month. Use cloxacillin 500mg qid and ibuprofen 400mg tid for 1wk. There is almost no danger of pulmonary embolism.

35.2 Peripheral gangrene

Inadequate blood supply leads to gangrene of the peripheries; strictly speaking, gangrene implies digestion of dead tissue by anaerobic bacteria. This may occur as a primary process in gas gangrene due to *clostridia* (6.24), or more usually secondarily to ischaemia. If there is little subcutaneous fat, and no oedema, the skin becomes cold and waxy, haemoglobin diffuses out of the veins, discolouring the skin purple, and then black and ischaemia results in shrinking of the tissues (mummification or dry gangrene). There results a clear line of demarcation between viable and dead tissue, and the dead part sometimes simply falls off, leaving the stump to heal. At the junction between live and dead tissues, however, organisms do survive, as is the case with the more common scenario of fatty oedematous tissues, particularly found with diabetes mellitus. The result is a mass of infected, necrotic, smelly, partially destroyed tissue, known loosely as wet (or moist) gangrene.

Underlying causes are numerous, and can be:

(1) Sepsis with diabetes mellitus (causing a combination of vasculopathy, and neuropathy).

(2) Peripheral ischaemia due to arterial disease (usually because of cigarette smoking), HIV or syphilitic vasculitis, arterial emboli, vascular injury (including injection of barbiturate or sclerosant into an artery, 35.1), & vasospasm due to cold (*e.g.* in trench foot) or rarely an accessory cervical rib.

(3) Compartment syndrome due to burns, crush injury, snake bite especially with inappropriate tourniquet use, too tight Plaster of Paris, fibrous stricture (*e.g.* ainhum, auto-amputation of the 5th toe) or an acute venous thrombosis.

(4) Septicaemia resulting in simultaneous venous and arterial thrombosis, especially in neonates, HIV+ve patients, and the malnourished.

(5) Necrotizing fasciitis (6.23) or gas gangrene (6.24): these produce a toxic combination of (3) and (4).

EXAMINATION

The diagnosis of gangrene is usually obvious; unfortunately many patients present when gangrene is already established and all you can do is amputate. You therefore need to know where and how to do so.

Make sure ischaemia is established: you may still save toes, feet, fingers or arms if you release an eschar, decompress a compartment syndrome, or simply *slowly* warm up a cold periphery.

Make sure you document all the peripheral pulses (including thrills and bruits), examine for capillary return on the toes or fingers (should be <1sec) and for sensation, and check a random blood glucose and HIV screen (and also VDRL if available). Look for xanthelasmata at the inner canthus of the eyes, indicating hyperlipidaemia, as well as the tell-tale signs of nicotine-stained fingers.

Measure the ratio of the ankle to the brachial systolic pressure (significant occlusion exists if it is <0.85) but this may be unreliable if arteries are calcified as in diabetes or renal failure. If you have a Doppler ultrasound probe, this gives greater sensitivity than the finger and can give very useful objective information about flow rates. However, you may not be able to tell where the occlusion lies, and if there is a stenosis whether there is a more significant stenosis more proximally placed.

Similarly if you compare the p_aO₂ taken with a pulse oximeter at the big toe and the thumb, you can get an idea of the degree of relative hypoxia: this is significant if the ratio is <0.6; a reading of <20mm Hg in the lower leg demonstrates significant ischaemia.

VASCULAR RECONSTRUCTION

It is, sadly, often too late with many patients to consider this. However, with minor areas of gangrene or ischaemia, a patient will do better if you can arrange a successful revascularization of the limb and perform a minor amputation, rather than a major amputation *without any improvement in vascular supply*.

If you see a patient with claudication at <200m, or rest pain, try to refer him before gangrene sets in. You can relieve much pain (and peripheral inflow) with epidural analgesia.

35.3 Amputations in general

INTRODUCTION

Once you have cut off a limb there is no going back, so try to retain as much function as you can. The patient is unlikely to get an arm prosthesis, and it may be of little use even if he does get one. So aim instead for the longest possible stump of an arm. Every centimetre is useful; so is an elbow which he can use as a hook, and so is any kind of a wrist.

Bailey & Love's famous aphorism, on the indications for amputation, that if a limb or part of a limb is "dead, deadly or a dead loss", is as true as ever.

The leg must have a prosthesis which will bear his weight. There are a limited number of these, and the stumps for them are standardized. So always do one of the standard leg amputations. There are three technological grades of prosthesis; of these the third is not necessarily the worst. A patient might have:

- (1) A sophisticated modern prosthesis costing US\$300 or more.
- (2) A simpler modern prosthesis costing US\$30, such as one of those developed by BMVSS Jaipur foot (35-21A), which a mechanic can mend (www.jaipurfoot.org).
- (3) A traditional prosthesis, such as a pylon, a peg leg, (35-21B) or elephant boot.

Do not despise these; when well made they last longer than any of the others, and are better than a modern prosthesis for working in the fields. Remember that the patient may be used to sitting on the floor rather than on a chair, and so his prosthesis must take this into account. To this end, the Jaipur prosthesis is most suitable. It does not require any shoe: amputees can walk barefoot, or use a shoe. It is made of waterproof material, so that amputees can walk in wet and muddy fields. It permits enough foot dorsiflexion and other movements necessary to walk on uneven surfaces.

A leg prosthesis can:

- (1) have a cup to bear weight on the sides of the stump, in which case the scar should be at the end.
- (2) bear weight on the end of the stump, in which case the scar should be posterior.
- (3) have a modern total contact socket in which the position of the scar is unimportant. Limb fitting centres vary in their scope and preferences, so visit your local one and find out what they like. A good prosthetist can fit any well constructed stump with a prosthesis.

CONSERVE EVERY CENTIMETRE IN THE ARM; DO A STANDARD AMPUTATION IN THE LEG

In a perfect stump:

- (1) The scar is not exposed to pressure.
- (2) The skin slides easily over the bone.
- (3) The skin is not infolded.
- (4) There is no redundant soft tissue.
- (5) There is no protruding spur of bone.
- (6) The stump is painless.
- (7) The wound has healed by first intention.
- (8) The skin has good sensation.
- (9) The shape of most should be conical.

Deciding where to amputate can be difficult. The lower in the leg you amputate, the greater the chance that the patient will walk again afterwards. But there is also more chance that the tissue through which you cut will not be viable. So, feel the pulses carefully and take measurements to assess the degree of ischaemia (35.2): *do not perform a below-knee amputation if you cannot feel a popliteal pulse.* If the tissues have poor bleeding and the muscle is purple, abandon this amputation level and go higher up.

Consider a through-knee amputation in any frail and elderly patient unsuitable for a below-knee amputation. *Do not delay doing a below knee amputation for severe injuries;* otherwise you may well need to do an amputation higher up!

Make sure you have properly counselled the patient and obtained consent for amputation; *do not force him into this against his own judgement,* otherwise he will not co-operate and mobilize well post-operatively. An emergency amputation for sepsis or crushed limb may, however, save someone from the jaws of death!

Many patients (particularly labourers and even some surgeons) hardly miss an amputated finger, for example. If you decide to amputate, discuss the decision carefully with the patient. If he is going to take a long time to recover, tell him so. Discuss any alternatives, and if a difficult decision has to be made, let him share it. If he is involved in the decision, he is much more likely to be enthusiastic about subsequent rehabilitation.

Fish mouth flaps must be long enough to cover the soft tissues of the stump, but not be so long that their blood supply is inadequate and they necrose. If the flaps are equal, the scar will sit at the end of a stump. If they are unequal the scar will end up at the front or the back. Try to place the scar where it is not going to be pressed on. In the hand and the foot, place it dorsally. Higher up the arm the scar can be anywhere. In the leg, its site depends on the kind of prosthesis envisaged: end-bearing, side-bearing, or total contact. In the lower arm and leg, transverse scars are better than antero-posterior because they do not get drawn up between the two bones.

A 'dog-ear' at the corner of a wound usually resolves.

WHERE TO AMPUTATE

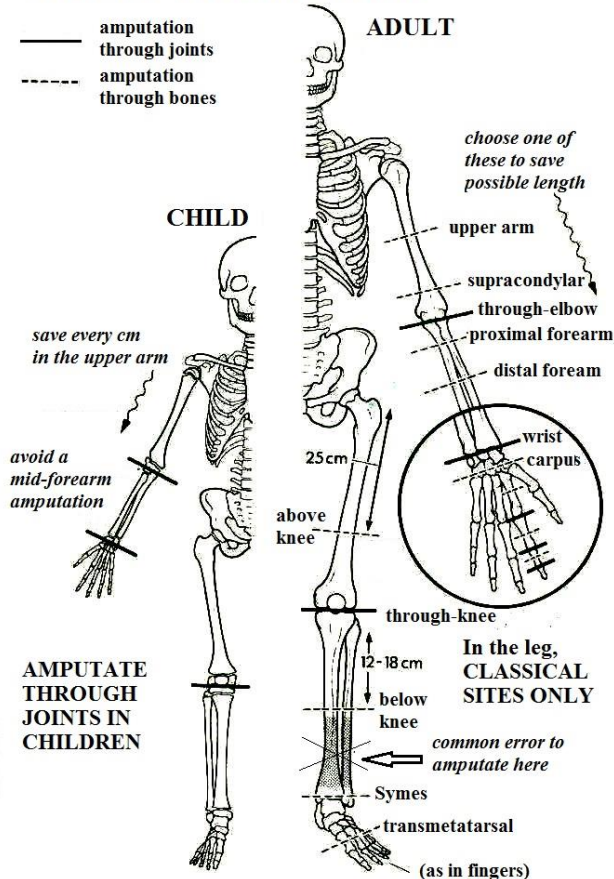


Fig. 35-6 AMPUTATION SITES.

In the arm save every centimetre in the child's upper arm, and at the joints so as not to affect growth; choose the longest feasible amputation in the adult arm; in the leg amputate at the classical sites only.

Delayed primary closure is always wise:

- (1) if the limb is already infected, or may soon be so.
- (2) if the blood supply of the stump is uncertain.
- (3) if there is much soft tissue injury, e.g. in battle injuries.

If you decide on delayed primary closure, cut the flaps long, to allow them to retract. Leave the muscle and fascia unsutured, bandage the skin flaps over dry gauze swabs, *do not put in any sutures*, and inspect the wound 3-5 days later. If the wound is not infected, close it. If it is infected, debride it and leave the flaps open for 1-2 wks, and close it only when it is clean.

The long posterior flap technique is the standard for the below-knee amputation (35-20A) in ischaemia.

The skew flap is also good, but more difficult (35-20C). In the leg, equal anterior & posterior, or lateral flaps are liable to fail.

Guillotine amputation is quick, and the flaps are less likely to necrose if the blood supply is poor. It is useful in emergency surgery for severe sepsis such as gas gangrene, gross sepsis in a diabetic or for a severely damaged limb.

This is important in fingers or toes, because if you do a formal operation and it becomes septic, you lose more length. After guillotine amputation, though, you often need to revise the amputation by fashioning a formal stump higher up, as simply grafting the wound, or just letting it heal naturally rarely give a good result. Also, a guillotine amputation may not differentiate between healthy and septic or irreparably damaged tissue. Therefore, you will lose more length with a guillotine amputation as you need to shorten the bone again to be able to cover it with muscle and skin. *So do not use it for legs and arms, except when in dire straits.*

Postoperative care. The leg stump must be prepared for the prosthesis, and you need to teach the patient how to use it. Firm bandaging will hasten change of the stump from a bulky cylinder to a narrow cone, and exercises will strengthen the remaining muscles. So, provide something to do with the stump. After a lower leg amputation, for example, learning to kick a large rubber ball about is very therapeutic. *Avoiding a flexion contracture of the knee is essential after a below-knee amputation.* If there is already a tendency to flexion, keep the knee in a backslab or cast until full mobilization.

Differences in children. Most of the same principles apply in a child. Disarticulate a joint if you can, especially at the knee, because this will preserve its epiphyses. Removing a limb by amputating through the shaft of a bone produces an effect which varies with the site. It can either cause excessive bony overgrowth with the need for revision amputations later, or a short stump.

AMPUTATION EQUIPMENT

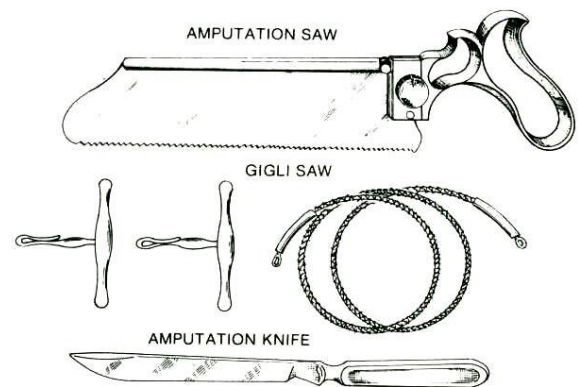


Fig. 35-7 EQUIPMENT FOR AMPUTATION.

If necessary, you can use any sterilizable saw or domestic knife.

SAW, amputation, with hinged back, 230mm, with spare blades. The back of the saw stiffens it during the early part of the cut, but can be hinged back later to let the saw pass through.

SAW, Gigli, with a pair of handles and 30cm blades. A Gigli bone saw is a piece of wire with sharp teeth on it which you pull to and fro between two handles. Use it to cut bone in awkward places.

KNIFE, amputation, Liston 180mm. If you do not have an amputation knife, sharpen a long kitchen knife and use that.

N.B. An electric saw is a luxury: keeping strict sterility is difficult.

INDICATIONS

Apart from gangrene, there are other indications for amputation:

- (1) An irretrievably damaged limb,
- (2) Chronic osteomyelitis,
- (3) Advanced soft tissue or bone malignancy,
- (4) A useless limb, such as affected by severe contractures or polio.

In these cases, you need not worry so much about ischaemia and can use a tourniquet, but *do not exsanguinate the limb with an Esmarch bandage (3-6L)* where there is sepsis or malignancy.

CAUTION!

For an amputation for malignancy, take a biopsy first.

Do not use a tourniquet (3.4) when you are amputating for ischaemia. Bleeding and contraction on cutting are useful signs that a muscle is alive. If it is dead you need to amputate higher up. *A tourniquet may also make critical ischaemia worse by encouraging thrombosis.* Release the tourniquet *before* you suture the muscles, so that you can tie any bleeding vessels before you cover them. For ischaemic limbs, try to use epidural anaesthesia, which causes vasodilation and improves peripheral blood flow.

FISH MOUTH FLAPS FOR AN AMPUTATION

Decide where you are going to saw the bone (the point of section) and plan the flaps in relation to that point. Place the angle of the fish mouth at the site of bone section. Mark the flaps out carefully with a permanent marker.

For equal flaps, make the length of each flap equal to $\frac{3}{4}$ of the diameter of the limb (35-8A).

For unequal flaps, make the longer flap equal to the diameter of the limb, and the shorter one equal to $\frac{1}{2}$ its diameter (35-8B).

N.B. As a general rule the combined length of both flaps should equal $1\frac{1}{2}$ times the diameter of the limb at the site of the bone section.

Cut through the skin down to the deep fascia, and reflect this up with the skin as part of the flap. The skin of the stump will need to slide over the deep fascia (35-8E), so keep them together. Minimize trauma to the flaps: handle them with stay sutures rather than with forceps, particularly with diabetics.

CAUTION!

- (1) Start by making fish mouth flaps long. You can always trim them if they are too long later, *but you cannot lengthen them if they are too short.*
- (2) Cut them round, *not pointed.*
- (3) If you are amputating a severely lacerated limb, try to preserve all viable skin.
- (4) *Make sure the scar is not at the end of the stump if that limb will carry the pressure of a prosthesis.*

THE GEOMETRY OF FISH MOUTH FLAPS

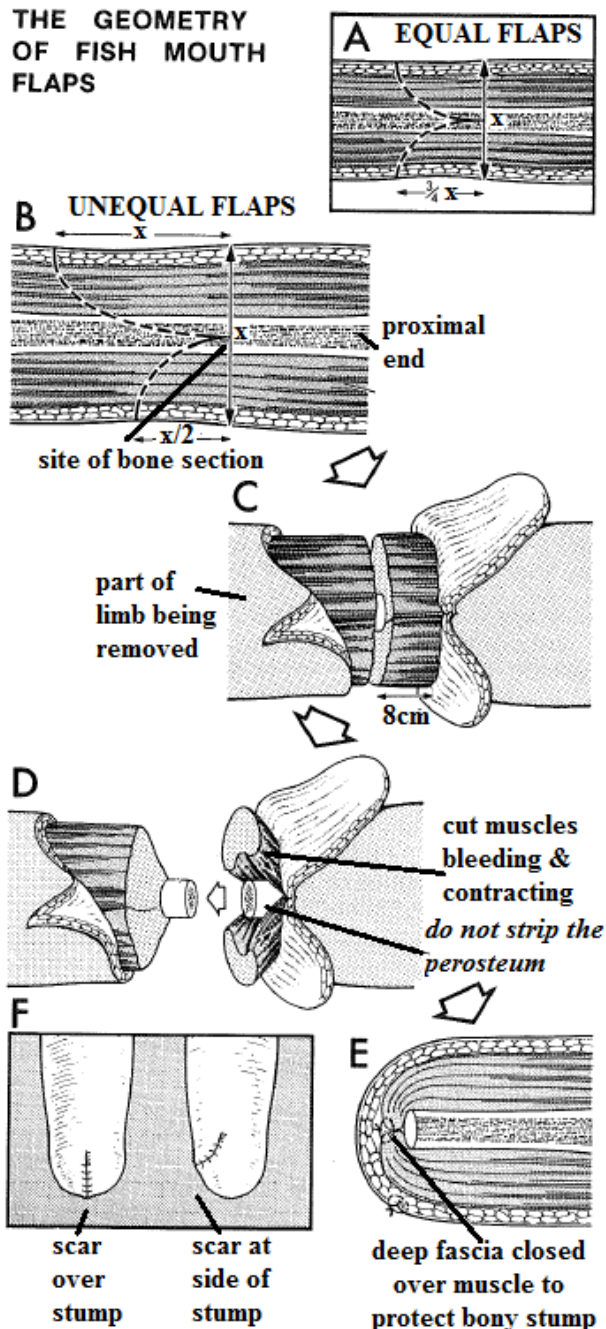


Fig. 35-8 FISH MOUTH FLAPS.

Together, the flaps should be $1\frac{1}{2}$ times the diameter of the limb. A, either make them as two equal flaps, each $\frac{3}{4}$ of the diameter of the limb, or B, make one flap equal to the whole diameter and the other flap equal to $\frac{1}{2}$ of it. C, reflect the skin with the deep fascia and cut the muscle 8cm distal to the bone section. D, reflect the periosteum only 1-2cm so you can see the bone clearly: *do not strip the periosteum off the bone.* E, the deep fascia closed over the bony stump, protecting it with muscle. F, position of scar depending on the type of flap you use.

Kindly contributed by Peter Bewes.

AMPUTATION

Cut the flaps as far distally as you can, so that you can refashion them later. Cut the skin down to the deep fascia all round the limb 2cm distal to the site of bone section. Let it retract. Then cut the muscle all round the limb down to the same site (35-10). Tie and cut all the large vessels you meet.

Cut all major nerves at least 2cm proximal to the end of the stump, to prevent an amputation neuroma causing 'phantom limb pain'. Saw through the bone. Dress the stump with vaseline gauze, betadine and plenty of dry gauze. Bandage it, and let it granulate.

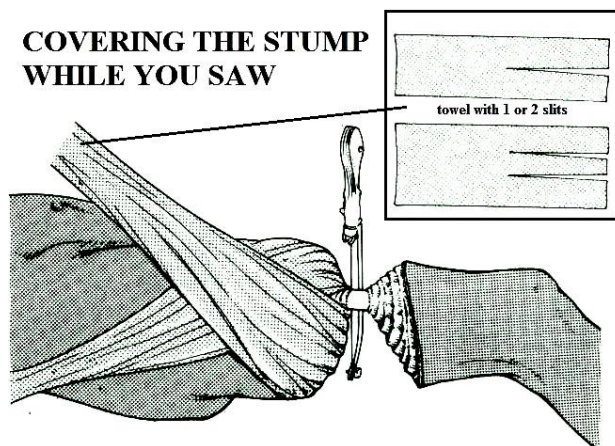


Fig. 35-9 HOW TO COVER THE STUMP WHILE YOU SAW.
The towel with 2 slits in it is for the forearm and lower leg. The central flap goes between the bones.

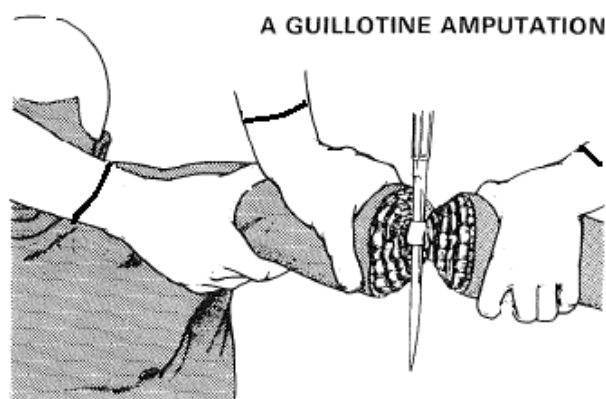


Fig. 35-10 A GUILLOTINE AMPUTATION.
This is quick and the flaps are less likely to necrose if the blood supply is poor, but a revision is almost always necessary later. Beware injury to your or your assistant's fingers from the knife! Use a saw for the bone!

CONTROLLING BLEEDING DURING AN AMPUTATION
Early in the operation, find the major arteries and veins. Tie them separately with double transfixion ligatures (3.2). Then cut the vessels between these ligatures. Later, after you have removed the limb, tie the remaining smaller vessels. *Do not use diathermy.*

If the cut ends of the muscles bleed furiously, apply packs for 5mins and a tourniquet. If the amputation is very high, you may have to expose the main artery higher up.

CAUTION!

- (1) If you do not use a tourniquet, try to find and tie the major vessels *before* you cut them.
- (2) *Do not use a clamp:* if it slips there will be massive bleeding.
- (3) Careful haemostasis of the stump is essential. If a clot forms, it is easily infected.

Suture the cut ends of the muscle securely together over the cut end of the bone, so that they cushion it, and are better able to move over the stump. Cut them long enough for this but do not leave so much muscle that the stump becomes bulbous.

CUTTING MUSCLES DURING AN AMPUTATION

Muscles always contract, after you have cut them. So cut them transversely about 8cm distal the site of bone section (35-8C). Leave them a little longer if you are using delayed primary closure, because they will have more time to shrink.

Use a long sharp amputation knife or kitchen knife to cut the muscles straight down to the bone. *Do not use a scalpel* which makes many small cuts, and leaves shreds of injured muscle.

If the muscles look unhealthy when you cut them, abandon the operation at that site, and amputate higher up. Healthy muscle is a nice bright red, and has a good capillary ooze. Ischaemic muscle is a dark bluish red, and bleeds little or not at all.

CUTTING NERVES DURING AN AMPUTATION

Do not tie nerves: a painful neuroma will result, especially in the fingers. Instead, gently pull each nerve into the wound, cut it cleanly with a knife, then let it retract above the amputation site. The sciatic nerve is accompanied by an artery which may bleed profusely, so tie the artery off carefully, separately from the nerve.

SAWING BONES DURING AN AMPUTATION

Clear the muscle from the site of section, and incise the periosteum all round it. Reflect this proximally only for 1-2cm with the muscles, so as to expose bare bone. Use a sharp saw with well-set teeth, or a Gigli wire saw (35-7). Steady it and draw it across the bone a few times to start with. When it has made a good groove in the bone, saw steadily. Ask an assistant to hold the limb to steady it, and maintain a steady smooth movement to prevent the saw locking in the bone and splitting it. Finally, remove any spikes with bone forceps, and bevel any protruding edges with a coarse rasp.

CAUTION!

- (1) *Do not reflect the periosteum proximally* (35-8D), because the bone under it will die, and a ring sequestrum will form.
- (2) *Do not damage the surrounding muscle with the saw.* Cut the muscle first, or retract it well out of the way with a towel wrapped round the limb (35-9), then saw.
- (3) Bone dust from the saw acts as a foreign body, so wash it away.

DEALING WITH FAT DURING AN AMPUTATION

If the limb is very fat, cautiously remove as much subcutaneous fat as is necessary. *Do not remove too much, especially near the edges of the flap,* or it may necrose. Learn to design flaps so that they come together accurately without dog ears; if they do form, leave them, they will soon disappear. *Do not excise them,* otherwise you may end up with a wound that is too tight to close!

CLOSING THE WOUND AFTER AN AMPUTATION

Release the tourniquet, if present, and control all bleeding before you suture the flap. Make sure haemostasis is meticulous. *Do not use diathermy.*

If oozing continues, insert a suction drain, or less satisfactorily, leave part of the wound open for drainage. *Avoid using an open drain*, as you risk introducing infection this way. *This may be disastrous in ischaemic tissues.*

If you are amputating for chronic or severe acute sepsis or for a traumatized limb with much foreign material *in situ*, leave the wound open, cover it with dry gauze and close it later.

Suture the skin and deep fascia separately. *Close the flaps without tension*, using interrupted monofilament 3/0 sutures without leaving gaping areas between them, and without tying them tight. Dress the stump firmly, *but not too tightly.*

Elevate the arm or hand. A plaster covering will make an above-knee stump more comfortable and its weight will tend to prevent hip flexion contracture.

Change the dressings only if they are smelly, or soaked. Remove sutures after 7 days for the hand & arm, and 14 days for the leg.

N.B. Delayed primary suture is safer if there is sepsis or whenever there is increased risk of sepsis.

CUT FLAPS LONG; REFLECT THE DEEP FASCIA WITH THE SKIN. DELAYED PRIMARY CLOSURE IS SAFER

POSTOPERATIVE CARE FOR AN AMPUTATION

Make sure the limb or finger is exercised from the 1st day. *Do not allow a knee flexion or hip flexion contracture to occur.* Mobilize the patient early; if you can fit a temporary prosthesis before a definitive one to allow exercises, do so. You will thereby avoid the development of pressure sores.

As soon as a lower limb stump has healed, bandage it. For the leg, suture two 15cm crepe bandages end-to-end. For the arm, use one 10cm bandage. Roll the bandage tightly, then wind it round the stump. Apply more tension to the end of the stump than to its base, or it will become bulbous. Reapply the bandage several times a day until the prosthesis is fitted.

Do not use adhesive strapping, or you may tear the skin off the stump.

DIFFICULTIES WITH AMPUTATIONS

If the stump bleeds some hours after the operation (reactionary haemorrhage), return to theatre, explore the wound, tie the vessels, leave the wound open and close it later when it is clean.

If the stump bleeds some days later (secondary haemorrhage), this is likely to be serious. Apply a tourniquet. Explore the wound to find the bleeding point(s).

If you cannot find them, wash the wound with hydrogen peroxide. In desperation, pack the wound with dry gauze, and remove it 48 hrs later.

If the stump becomes infected, open the wound, irrigate it and let pus drain. You may still be able to save the situation if there is no further ischaemia. *Always consider delayed primary suture if there is an increased risk of infection.*

If a persistent sinus develops in the stump, explore it; you may find a piece of necrotic tendon, or an area of osteomyelitis. Another possibility is a stitch sinus. If the offending suture might be securing a vessel, *do not remove it until you have tied the vessel higher up.* Explore the stump, remove all dead and dying tissue, and pack it ready for secondary closure.

If the flaps break down, you probably cut them too short or closed them too tight. Wait until granulation tissue is clean and ready and then apply a skin graft. The final quality of the skin over the stump will be worse than it would have been if the flaps had survived, and it may break down later. Alternatively, you may have to amputate higher up.

If a patch of gangrene forms in a flap, be careful, it may hide a larger area of necrosis underneath. You may be able to trim it away, or you may have to amputate again higher up, especially if the limb is ischaemic. If it is not ischaemic, you may be able to excise the gangrenous area, allow granulations to develop, and apply a split skin graft.

If there is spreading sepsis or gas gangrene, amputate higher up immediately, through the shoulder or hip if need be, and leave the wound open.

If a prosthesis cannot be fitted, you have probably designed the stump wrong. The reasons include:

- (1) bone adherent to the scar,
- (2) a spicule of bone sticking out through the skin,
- (3) a flexion contracture in a below knee or above knee amputation,
- (4) too short a stump.

Get advice from your rehab technician as to what is the best way forward.

If the stump is painful,

- (1) you may not have cut the nerves proximally enough, so that a neuroma has formed and stuck to the scar.
- (2) the bone may be too long in relation to the flap.
- (3) look for a haematoma or infection in the wound.

35.4 Arm & hand amputation

Save as much of the length of the arm as you can, because the patient will probably get no prosthesis. If possible, disarticulate the elbow. If you amputate higher up, a convenient place is 18-20cm below the acromion.

If you can leave a reasonable length of humerus, it can be used to hold things by gripping them against the chest. If you have to amputate very high up, even a very short stump will preserve the outline of the shoulder.

If you can provide a prosthesis, do not amputate through the lower 4cm of the humerus, because it will be difficult to fit. Remember that the brachial artery lies quite superficially, and is overlapped medially by the biceps.

Losing a hand is a serious deficit. Lessen it by trying to preserve as much of the length of the forearm as you can. An elbow with even a short length of forearm is better than none.

If possible, amputate through the metacarpus or wrist, rather than higher up. Ischaemia is an exception. The circulation in the distal forearm is easily compromised, so if the arm is ischaemic, an amputation higher up the forearm may be better than one lower down.

If you have to amputate through the wrist, it may later be possible to make an 'alligator mouth' out of the 2 forearm bones (Krukenberg's operation), so that there is something to grip with.

Antero-posterior flaps are better than lateral ones, because the scar cannot retract between the bones.

PREPARATION.

Abduct the arm to about 80° on an arm board. Place a block under the arm just proximal to the amputation site. Apply a tourniquet as high as you can. Note the time.

ABOVE ELBOW AMPUTATION (GRADE 2.5)

Start proximally at the site of bone section, and mark out equal anterior and posterior skin flaps. Make the length of each flap $\frac{3}{4}$ of the diameter of the arm at the site of section (35-11). Find, doubly ligate, and cut the brachial artery and vein just above the site of section.

Find, gently pull and cut the radial, medial & ulnar nerves so that their ends retract well above the stump. Cut the anterior muscles 1.5cm distal to the site of section.

Cut the *triceps* 4cm distal to the site of section or free its insertion from the olecranon. Preserve the *triceps* fascia and muscle as a long flap. Retract the periosteum 1-2cm to expose clean bone and saw it cleanly. Rasp the end of the humerus smooth. Bevel the *triceps* to make a thin flap, reflect it anteriorly over the end of the humerus, and suture it to the anterior muscle and fascia. Release the tourniquet, control bleeding and close the stump (35.3).

If there is any hope of an elbow prosthesis, reflect this flap proximally and cut the periosteum all round the humerus at least 4cm above the elbow joint to allow room for the elbow mechanisms of the prosthesis.

If there is no hope of an elbow prosthesis, leave as much bone as you can. Saw across the humerus at the level you choose, and rasp its end smooth. Trim the *triceps* tendon to make a long flap, carry it across the end of the bone, and suture it to the fascia over the anterior muscles.

SUPRACONDYLAR AMPUTATION OF THE UPPER ARM

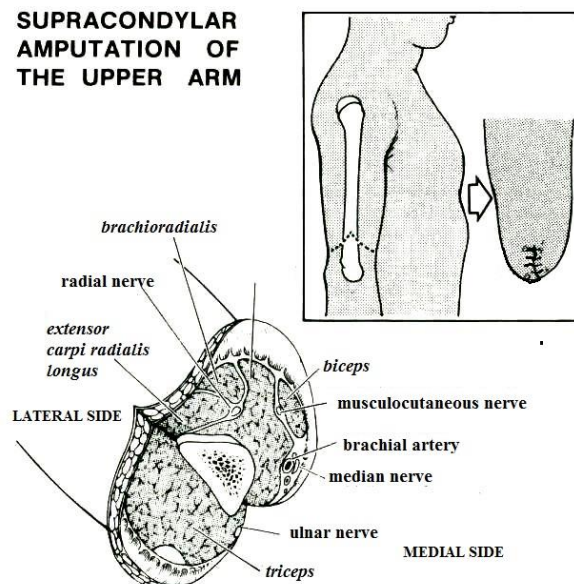


Fig. 35-11 UPPER ARM AMPUTATION.

If you leave a patient with a reasonable length of humerus, it can be used to hold things by gripping them against the chest.

After Rob and Smith with the kind permission of Graham Stack.

ELBOW DISARTICULATION (GRADE 2.5)

Make equal anterior and posterior skin flaps. Start at the level of the epicondyles and curve the posterior flap 2.5cm distal to the tip of the olecranon. Bring the anterior flap just distal to the insertion of the *biceps* tendon. Reflect the flaps to the level of the epicondyles.

Start on the medial side. Find and divide the bicipital aponeurosis. Free the origin of the flexor muscles from the medial epicondyle and reflect it distally to expose the neurovascular bundle on the medial side of the *biceps* tendon. Tie and cut the brachial artery just above the joint. Gently pull the median nerve and cut it proximally. Find the ulnar nerve in its groove behind the medial epicondyle and cut it proximally in the same way. Free the *biceps* tendon from the radius, and the *brachialis* tendon from the coronoid process of the ulna. Find the radial nerve in the groove between *brachialis* and *brachioradialis*, pull it, and cut it proximally. On the lateral side of the elbow, cut the extensor muscles 6.5cm distal to the joint, and reflect their origin proximally.

Cut the *triceps* tendon near the tip of the olecranon. Cut the capsule on the front of the joint, complete the disarticulation, and remove the forearm. Leave the articular surface of the humerus intact. Reflect the *triceps* tendon anteriorly and suture it to the tendons of the *brachialis* and *biceps*.

Make a thin flap from the extensor muscles, reflect it medially and suture it to the remains of the flexor muscles on the medial epicondyle. Suture the muscle mass to cover the bony prominences and exposed tendons at the end of the humerus. Put sutures through the periosteum when necessary. Release the tourniquet, control bleeding and close the stump as in 35.3.

AMPUTATING THROUGH THE FOREARM

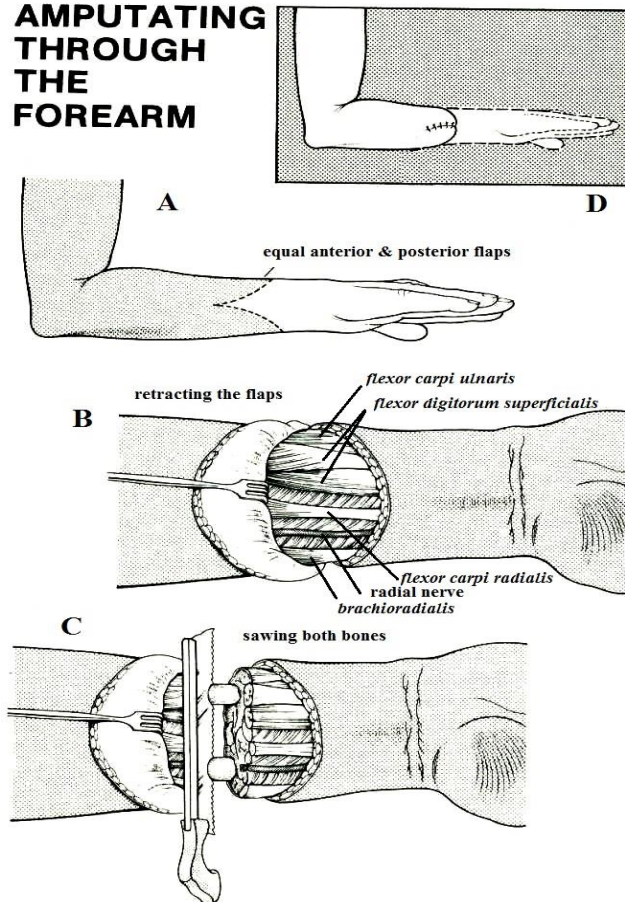


Fig. 35-12 FOREARM AMPUTATION.

Preserve as much length as you can. An elbow with even a short length of forearm is better than none. A, use equal flaps. B, reflect the flaps with the deep fascia. C, having divided the nerves and muscles, peel off the periosteum 1-2cm off the radius and ulna, and saw them cleanly through. D, final view.

After Rob C and Smith R, with the kind permission of Graham Stack.

BELOW ELBOW & DISTAL FOREARM AMPUTATIONS (GRADE 2.5)

Abduct the arm on an arm-board or side-table, and place it supine. *If you cut the flaps with the arm prone, they will later be twisted.* Try to preserve as much length as possible.

If there is enough good skin, make equal anterior and posterior flaps (35-12A), as long as $\frac{1}{2}$ the diameter of the forearm at the amputation site. If skin is scarce, make the best flaps you can.

Reflect the skin flaps with the deep fascia to the site of section (35-12B). Clamp, tie and cut the radial and ulnar arteries just above this site.

The radial and ulnar nerves run on the outside of their arteries, and the median nerve under *flexor digitorum profundus*; pull these nerves down gently, and cut them proximally.

Cut the muscles transversely distal to the site of section, so that they retract above it. Trim away all excess muscle. Saw the radius and ulna (35-12C) and smooth their cut edges. Suture the muscles closed over the bony stump. Release the tourniquet, control bleeding and close the stump (35.3).

DISARTICULATING THE WRIST

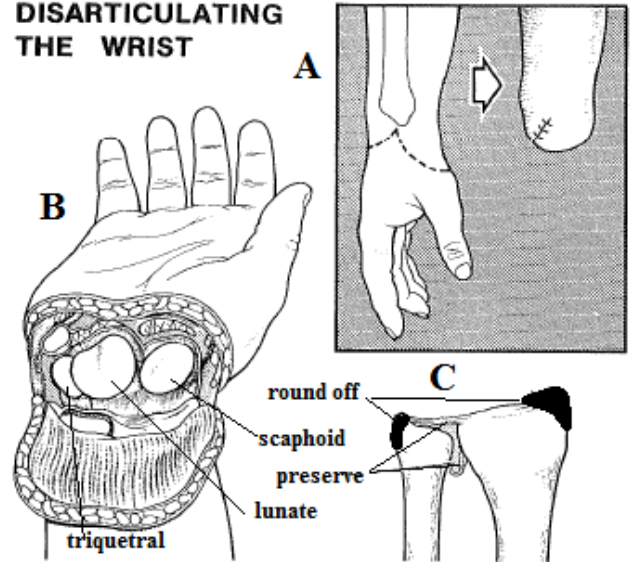


Fig. 35-13 DISARTICULATING THE WRIST.

A, make a long palmar and short dorsal flap. B, capsule of the wrist divided. C, round off the radial & distal styloids, and preserve the distal radio-ulnar joint and the triangular ligament.

After Campbell WD, Edmonson AS, Crenshaw AH, (eds) *Operative Orthopaedics*. CV Mosby 6th ed 1980 with kind permission

WRIST DISARTICULATION (GRADE 3.1)

Make a long palmar and a short dorsal flap. Start the incision 1.5cm distal to the radial styloid, extend it distally towards the base of the first metacarpal. Carry it across the palm, and then proximally to end 1.5cm distal to the ulnar styloid (35-13A,B). Make a short dorsal flap by joining the two ends of the palmar incision over the dorsum of the hand. Bring the dorsal flap distally level with the base of the middle metacarpal.

If skin is scarce, vary the design of the flaps. Reflect the flaps proximally with the underlying fascia to the wrist joint. Clamp, tie and cut the radial and ulnar arteries just proximal to the joint. Extend the incision proximally between *pronator teres* and *brachioradialis*, so that you can divide the median, ulnar, and radial nerves proximally. (If a neuroma forms here, it will be far from the scar.) Cut all tendons just proximal to the wrist and let them to retract into the forearm. Cut round the capsule of the wrist joint and remove the hand. Saw or nibble off the radial and ulnar styloids. Rasp the raw ends of the bones smooth and round. Release the tourniquet, control bleeding and close the stump (35.3).

CAUTION!

Do not injure the radio-ulnar joint or its triangular ligament. Damage to these will make rotation of the forearm difficult, and the joint will be painful.

TRANSCARPAL AMPUTATION (GRADE 3.1)

At this level, supination and pronation of the forearm, as well as flexion and extension of the wrist, are preserved and will improve overall function. Make a long palmar flap and a dorsal flap half as long. Reflect the flaps proximally to the site of bone section, and expose the soft tissues under them. Pull the finger flexor and extensor tendons distally, cut them, and allow them to retract into the forearm. Find the 4 wrist flexors and extensors (*flexor & extensor carpi radialis & ulnaris*), free their bony insertions and reflect them proximally to the site of bone section. Find the median and ulnar nerves and the fine filaments of the radial nerve. Pull them distally and cut them well proximal to the site of section. Clamp, tie and cut the radial and ulnar arteries proximal to the site of section. Cut the remaining soft tissues down to bone. Saw across the carpal bones, and rasp all rough edges smooth. Anchor the tendons of the wrist flexors and extensors to the remaining carpal bones in line with their normal insertions to preserve wrist function. Release the tourniquet, control bleeding and close the stump (35.3).

FINGER AMPUTATIONS IN GENERAL

Do not make the mistake of not amputating early enough or often enough. A stiff, painful, useless finger is often worse than no finger. If elaborate procedures are done to save it, not only is it likely to become stiff, but the neighbouring normal fingers are likely to become stiff too. *However, leave as much length in the thumb as possible, because length here is more important than motion.*

Most patients prefer a shorter finger covered with good skin than a longer one covered with poorer skin. Therefore, ask the patient if he uses his fingers for special skills. Ask how long he would prefer you leave the stump? *It is not easy to decide on the best.*

A flap from the volar surface of the finger is thus usually better than a graft. But, if making a flap means sacrificing too much length, a graft may be necessary. If possible, use full thickness skin, although a split skin graft does sometimes hypertrophy and stand up to pressure remarkably. The sides and back of a finger are less important, so that a split skin graft is good enough here.

When amputating through the middle phalanx, try to retain the middle of the shaft, because the *flexor digitorum superficialis* is inserted into it. If you amputate more proximally than this, the patient will have no strength in his finger, although it will help to stop things falling out of his palm. If you are in doubt as to where to amputate, choose the more distal site. You can revise the amputation later.

PROVIDE GOOD SKIN COVER OVER A FINGERTIP

AMPUTATING FINGERS

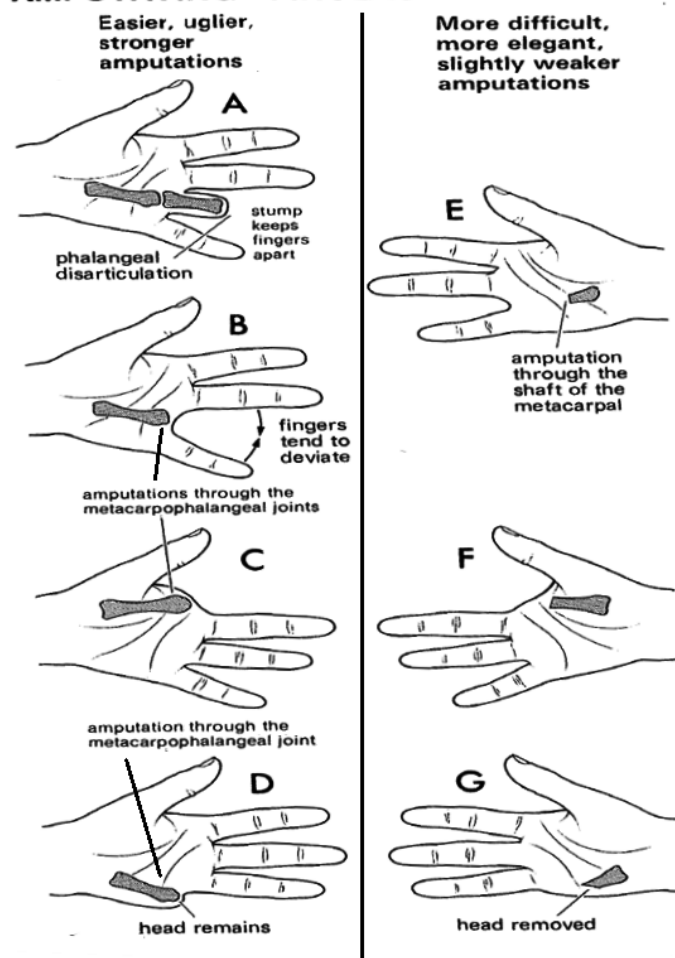


Fig. 35-14 FINGER AMPUTATIONS. The amputations on the left are easier, uglier, and stronger than those on the right. Amputating through a joint is easier than cutting through a metacarpal.

Partly after Farquharson EL. *Textbook of operative surgery* E&S Livingstone 1969 with kind permission

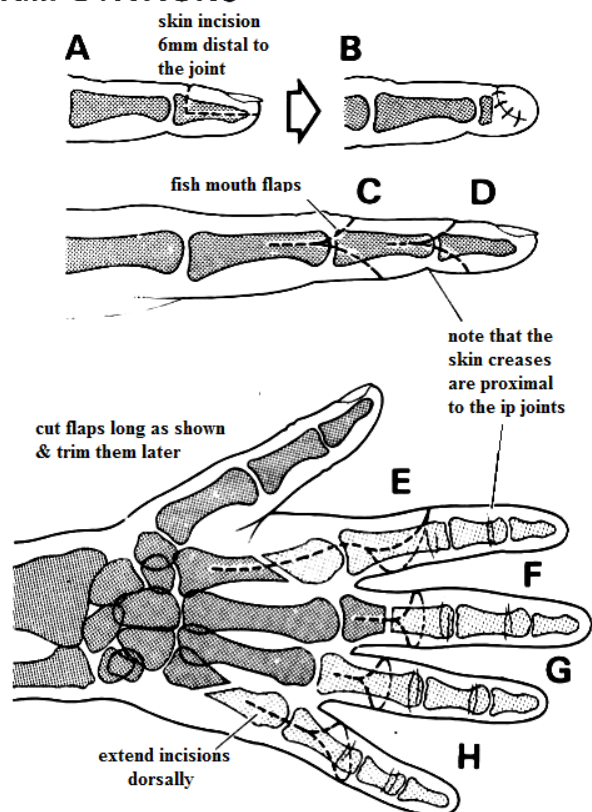
An amputation through the mcp joint that does not remove the metacarpal head and leaves a gap through which beans, rice or money can slip. It is usually said though that this (preferably leaving also a stump of phalanx) makes a stronger hand. It is certainly an easier operation but a more elegant solution is a ray amputation through the shaft of a metacarpal below its head (35-14).

This does narrow the palm, though, and reduces grip and pronation strength.

Retaining the stump of a phalanx (35-14A) further strengthens the hand by keeping the fingers apart and preventing them from deviating towards one another (35-14B). The stump will also help to stop small objects falling, through the hand.

Removing an index finger causes less disability than you might expect, and even a surgeon can operate quite satisfactorily without his index finger (35-14 F), provided the head of the metacarpal has been removed obliquely from the shaft. The middle finger soon learns to take over unless it is impeded by the index finger stump, which gets in the way. A finger missing from one edge of the hand (35-14F,G) is seldom a great disability, provided the head of the metacarpal is removed, so this is an elegant amputation. If great strength is not important, it is likely to be the best option.

INCISIONS FOR FINGER AMPUTATIONS



MCP DISARTICULATION

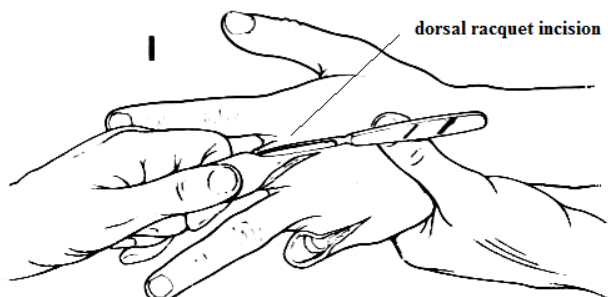


Fig. 35-15 INCISIONS FOR FINGER AMPUTATIONS. Cut the flaps long, you can always shorten them later if necessary. A, incision preserving the base of the distal phalanx. B, final result. C,D, flaps for amputations through ip joints. E, ray metacarpal amputation of the index finger. F, proximal phalangeal amputation of the middle finger. G, mcp disarticulation of the ring finger. H, ray metacarpal amputation of the little finger. I, mcp disarticulations. Partly after Farquharson EL. *Textbook of operative surgery* E&S Livingstone 1969 with kind permission.

The disadvantage of removing the metacarpal head is that it is a more difficult operation. If you are in doubt, leave the metacarpal head; you can always perform an amputation through the shaft later.

IF IN DOUBT, LEAVE THE METACARPAL HEAD

Use fish mouth flaps (35-15C,D). Plan them carefully in relation to the ends of the bones, and close them without tension, even if the finger has to be shorter. A shorter amputation with loose flaps is better than a longer one with tight shiny ones. Make the palmar flap a little longer than the dorsal one, because this will preserve the maximum amount of pulp tissue, which is very sensitive.

PLANNED FINGER AMPUTATIONS

CAUTION! With all amputations:

- (1) If in doubt, make all flaps a bit longer than you think you will need. You can always trim them later.
- (2) Ask yourself if the skin of the finger you are amputating could help to close a nearby wound.
- (3) *Don't suture the flexor and extensor tendons together over the bone.*
- (4) Find the digital nerves and separate them from the vessels. This will be easier if you use a tourniquet. The nerves lie palmar to the vessels. Divide the nerves cleanly 1cm proximal to the volar flap. *Don't include them in the ligature of a vessel.* If possible, bury them in muscle or fat. Neuromas are sure to develop, but if you do this they will be away from the scar and the finger tip.
- (5) When you amputate through a joint, trim down the condyles (where necessary), so as to avoid making a bulbous stump.

INDEX FINGER MCP DISARTICULATION (GRADE 2.5)

This operation preserves the head of the metacarpal. Flex the index finger and mark out the incision on its knuckle (35-15E,16A), so that the radial flap is larger and extends nearly half-way down the shaft of the proximal phalanx. It must be long enough to meet the web of the next finger without tension.

Deepen the incision dorsally until you can see the extensor tendon, then cut it and turn it distally. Separate the extensor expansion round the base of the proximal phalanx (35-16B). Cut the collateral ligaments. Cut the flexor tendons as far proximally as you can (35-16C). Cut the rest of the soft tissues, tie the vessels, shorten the digital nerves, and remove the finger. Reduce the bulk of the scar by trimming away the ligaments around the metacarpal head (35-16D), the volar plate, the collateral ligaments, and the flexor sheath.

N.B. When you cut flaps through the webs, use a complete web on one side and no web on the other side. *Don't use 2 half webs each side.*

INDEX FINGER MCP DISARTICULATION

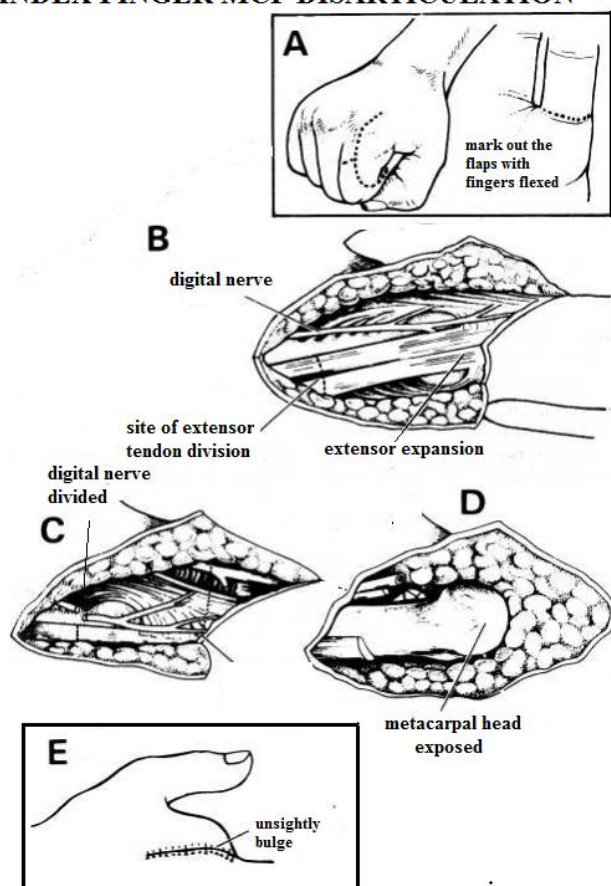


Fig. 35-16 INDEX FINGER MCP DISARTICULATION

A, mark out the incision with the fingers flexed. B, expose the extensor expansion and split it longitudinally. C, divide the digital nerves. D, expose the metacarpal head and remove the distal part of the finger. E, final result with the metacarpal bulge.

With the kind permission of Peter London.

INDEX FINGER METACARPAL RAY AMPUTATION (GRADE 3.1)

If an index finger stump will be in the way, make a dorsal racquet incision (35-17A). Keep the radial side of the flap long. You may need every millimetre. Preserve the subcutaneous tissue with the flap, and cut the extensor tendons (35-17B). Reflect the periosteum for 1cm with an elevator, and cut the metacarpal across at the junction of its proximal and middle $\frac{1}{3}$ (35-17C), then bevel it dorsally and radially. Separate the *interossei* and *lumbricals* from the shaft of the 2nd metacarpal. Deepen the palmar incision, and remove the flexor tendon sheath. Shorten the flexor tendons as deep in the palm as you can. Cut the vessels & nerves distal to the branches of the palmar skin. Turn the palmar flap medially, and close the skin without tension.

INDEX FINGER METACARPAL RAY AMPUTATION

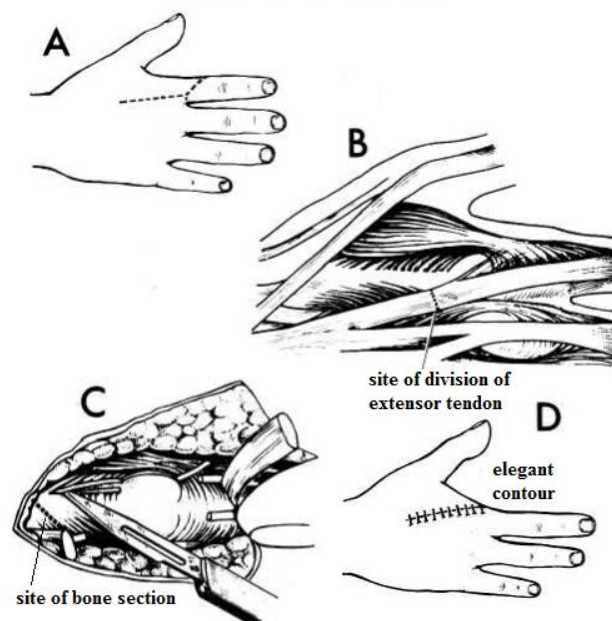


Fig. 35-17 INDEX FINGER METACARPAL RAY AMPUTATION

A, dorsal longitudinal incision with a circular incision at mid-proximal phalanx level, leaving the skin intentionally long. B, divide the extensor tendons. C, cut through the 2nd metacarpal at an angle. D, final result with a smooth thenar bridge.

With the kind permission of Peter London.

MIDDLE & RING FINGER METACARPAL RAY AMPUTATIONS (GRADE 3.1)

Leave the base of the metacarpal, and suture the deep transverse carpal ligaments on either side of the missing metacarpal. Failure to do this will result in a weak grip.

CAUTION!

Don't bandage the other fingers with the amputated one or they may become stiff.

Encourage moving them a day or two after the amputation. Use any convenient occupational therapy, such as rolling bandages, to make sure using the fingers starts soon postoperatively.

DON'T SUTURE A FINGER STUMP UNDER TENSION

LITTLE FINGER METACARPAL RAY AMPUTATION (GRADE 3.1)

If a little finger is stiff, and gets in the way, hindering hand function by catching on objects, make a dorsal racquet incision (35-15H); preserve the insertion of *extensor carpi ulnaris* on the base of the 5th metacarpal, and the hypothenar muscles. These provide important padding for the hand.

PROXIMAL PHALANX AMPUTATION (GRADE 2.3)

Try to amputate through the neck of a proximal phalanx. *If possible, preserve even a small stump of it.* This is easier than amputating through the mcp joint. Cut appropriate flaps (35-15F).

PIP FINGER DISARTICULATION (GRADE 2.3)

Do this as for a dip disarticulation below, but cut appropriate flaps (35-15C).

MIDDLE PHALANX AMPUTATION (GRADE 2.3)

Proceed as for the distal phalanx below, but amputate through the mid-shaft of the middle phalanx if possible, because this retains the attachment of the *flexor digitorum superficialis* tendon to its sides, and so function at the pip joint.

DIP FINGER DISARTICULATION (GRADE 2.3)

Incise the skin in the mid-lateral lines on either side of the neck of the middle phalanx. Join these 2 incisions to make a dorsal flap at the level of the joint, and a palmar flap 1cm distal to the flexor crease (35-15D). Dissect back the fibro-fatty tissue to find the digital vessels and nerves, the extensor expansion, and the flexor tendon in its sheath. If you cannot preserve tendon insertions, divide them and let them retract; *never suture the extensor to the flexor tendon over the bone stump* because of the 'quadriga effect' where the flexed amputated finger reaches the palm before the other fingers, and so weakens the grip of the hand.

Separate the nerves from the vessels, and divide the nerves proximal to the vessels. Tie the vessels without including the nerves. Complete the amputation by cutting the capsule and the collateral ligaments. Preserve the articular cartilage, which provides a 'shock pad' and close the wound.

DISTAL PHALANX AMPUTATION (GRADE 2.3)

If possible, preserve the base of the distal phalanx, because of the tendons which are inserted there. Also try to preserve as much pulp as possible. **If $<1/4$ of the nail remains**, a patient will be troubled later by the irregular hooked remnant, so excise the whole nail bed. **If you have to remove some of the pulp**, do not make a flap; place a non-stick dressing and allow the wound to heal on its own.

If you can preserve the pulp, flex the terminal joint and make a transverse incision across its dorsal surface 6mm distal to the joint (35-15A). Continue the incision as far as the sides of the phalanx, and deepen it down to the bone. Cut a long rectangular (*not pointed*) palmar flap almost to the tip of the finger. Dissect the flap off the front of the phalanx and reflect it forwards. Cut the phalanx with bone nibblers close to its base and smooth its edges. *Take care to remove bone chips and devitalized bone.* Trim protruding condyles and the anterior part of the phalanx to make a less bulbous stump; then fold the flap and close the wound (35-15B).

35.5 Above-knee (thigh) & through-knee amputation

Provided an above-knee amputation stump avoids the condyles of the femur, the longer it is the better, although at least 10cm length above the opposite knee is needed for fitting an artificial knee joint.

Be sure to exercise the stump immediately after the amputation, so as to strengthen:

- (1) the remaining adductor muscles, and prevent the prosthesis moving outwards on walking,
- (2) the extensors, because they will have to extend both the hip and the prosthesis which is to form the knee.

An amputee will also have to learn to balance with the hip instead of the foot muscles.

Study the anatomy of the leg carefully, so that you can find and tie the femoral artery under *sartorius* (35-18).

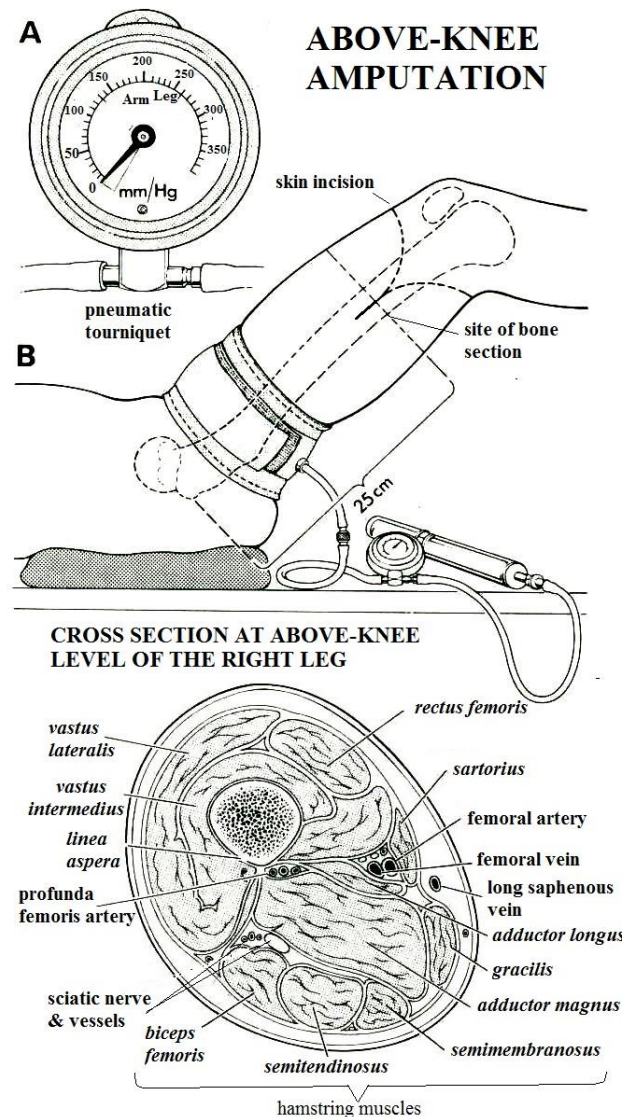


Fig. 35-18 ABOVE-KNEE AMPUTATION. Provided the stump avoids the condyles of the femur, the longer it is the better. *Do not use a tourniquet in the presence of ischaemia. Take care not to exceed correct inflation pressures & ischaemia time (3.4).*

DISARTICULATING THE KNEE:

- (1) is one of the easier amputations.
 - (2) preserves the distal femoral epiphysis of a child, and so allows the stump to grow.
 - (3) cuts little muscle and no bone, so it is quick, there is little bleeding, and infection is unlikely.
 - (4) allows the normal weight bearing end of the bone to carry the weight of the prosthesis.
 - (5) if performed with lateral flaps, is a good amputation for ischaemia.
- If you have a choice, disarticulating the knee is better than amputating above it. Good prostheses are now available for disarticulated knees and are easier to use than for above-knee amputations.

ABOVE-KNEE AMPUTATION (GRADE 3.1)

PREPARATION

Instill an enema before the operation to empty the rectum if it is full. Catheterize a female patient. Enclose the distal leg as far as the knee in a polythene bag, so as to isolate it from the field of operation. Preferably use spinal anaesthesia.

Place a sandbag under the buttock on the side to be operated on. Prepare the thigh. Raise the leg so that you can prepare the upper thigh and groin. Put a drape behind it and another one in front.

Plan to leave 25cm of the femur from the tip of the greater trochanter (35-18B). If possible, make equal anterior and posterior flaps. If there is insufficient viable skin on one side, make the other flap longer rather than amputating higher up.

Mark incisions for the anterior flap on the medial side of the thigh just proximal to the site of bone section. Curve it distally over the front of the thigh, to end on the lateral side opposite your starting point (35-18B). Mark the posterior flap in a similar way. The combined length of the two flaps should be $1\frac{1}{2}$ times the diameter of the thigh at the site of bone section. Cut the flaps.

Reflect the flaps to the site of section. Deepen the medial end of the anterior flap so as to expose the femoral artery in its canal under the *sartorius* muscle. Transfix, tie and divide the femoral artery and vein. Pull down the femoral nerve, cut it clean and allow it to retract.

Begin the incision in the *quadriceps* along the line of the anterior flap, and bevel it proximally to the site of section, so as to make a muscle flap not more than 1.5cm thick.

Ask your assistant to raise the leg while you cut across and bevel the posterior muscles distal to the site of section, in the same way as the anterior ones, so they retract. Trim away any excessively bulky muscle masses. Find, clamp, and tie the profunda femoris artery on the posterior aspect of the femur. Find the sciatic nerve under the hamstring muscles, separate it from its bed without tension, pull it down, cut it cleanly c.5cm proximal to the site of bone section. Tie the artery that accompanies the sciatic nerve, but *not the nerve itself*.

CAUTION! The collateral vessels which accompany the sciatic nerve can bleed profusely.

Elevate the periosteum all round the femur and saw it across immediately distal to this cut. Rasp away and make the end of the bone smooth. Slowly release the tourniquet (if used), and tie bleeding vessels as they appear. Suture the anterior muscle flap over the end of the bone. Suture its fascia to the posterior fascia of the thigh. Trim away any excess muscle or fascia. If you insert a drain, put it deep to this flap. Close the skin. Cover the stump with a crepe bandage and then apply a plaster cap. This will relieve pain, and its weight will help to prevent a flexion contracture developing.

DIFFICULTIES WITH ABOVE KNEE AMPUTATION

If a haematoma forms within the wound, open it up as much as necessary and evacuate the haematoma, otherwise it is very likely to become infected.

If the wound becomes septic, open it up and debride any dead tissue; you may need to re-fashion a stump higher up. This time, *use delayed primary closure*.

If bone protrudes through the stump, re-fashion it making sure the muscles are long enough to cover the bone end, and insist on exercises to prevent atrophy of the *quadriceps* muscle.

If the patient has to wait a long time for a prosthesis, pad the stump well, make a cast round it and fit it snugly into a sawn-off thinned-down crutch. Keep it in place with more plaster bandages. This will facilitate walking until the permanent prosthesis is ready. *If you don't do this, the quadriceps will atrophy and the patient may never walk again.*

If you have to amputate both legs above the knees, consider the possibility of getting short 'stumpy' prostheses for both legs. This may be preferable to a wheel chair, and they will be easier to balance with than prostheses of the standard length. The centre of gravity will however be closer to the ground, and two short sticks are needed. These 'stumpy' prostheses are much easier to make, because they do not have jointed knees, and need only be sockets with simple boots on. Keep them in place with cords over the shoulder.

AMPUTATING THROUGH THE KNEE (GRADE 3.1)

Cut a long, broad anterior flap, and a shorter posterior flap (35-19A). Mark these out with the knee flexed. Start the anterior flap on the medial side 1cm proximal to the knee joint line. Extend it 10cm below this, crossing the leg c.5cm below the tibial tuberosity and then curve it proximally to end at a point on to the lateral side of the knee opposite to where you started. Start the posterior flap at this point, and extend it so it crosses the back of the leg 5cm below the popliteal flexor crease. Then curve it proximally on the medial side to meet the starting point of the anterior flap.

CAUTION! Do not fashion an anterior flap if it might have an inadequate blood supply. If so, cut lateral and medial flaps, the latter 2cm longer than the former, beginning just above the tibial tuberosity. Get your assistant to hold the knee semi-flexed.

KNEE DISARTICULATION

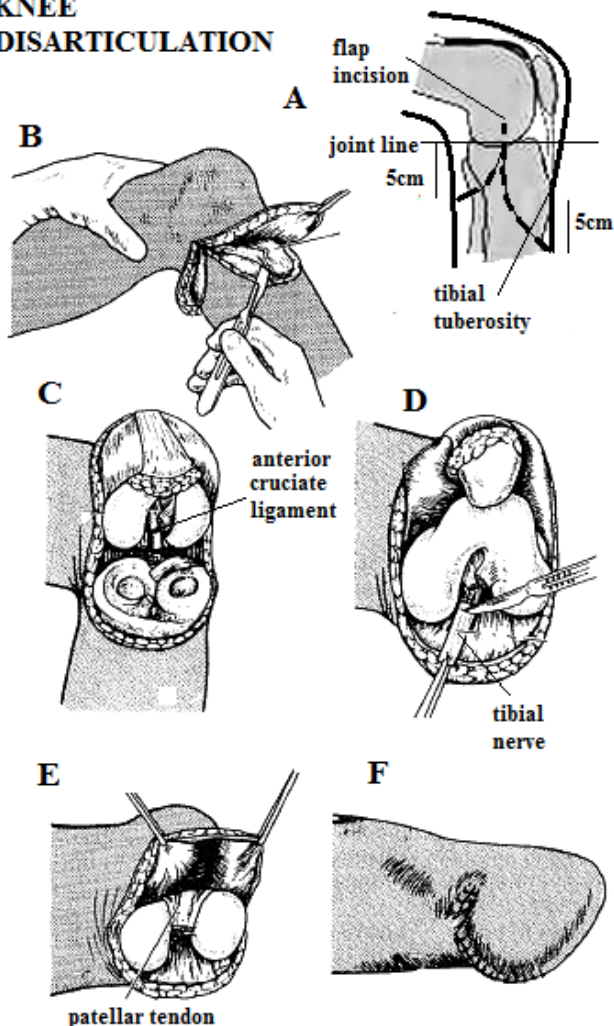


Fig. 35-19 KNEE DISARTICULATION.

A, mark out the flaps, with the knee flexed, starting 1cm above the joint line. If the blood supply for a long anterior flap is bad, make medial and lateral flaps. B, raise the flaps. C, cut the cruciate ligaments and the posterior joint capsule. D, cut the tibial nerve. E, suture the patellar tendon to the anterior cruciate ligaments. F, stump with posterior suture line.

After Campbell WD, Edmonson AS, Crenshaw AH, (eds) *Operative Orthopaedics*. CV Mosby 6th ed 1980 with kind permission.

Get your assistant to hold the knee half-flexed. Make the anterior incision down to bone, and the posterior to deep fascia. Lift the edge of the posterior flap and divide the medial hamstrings from the tibial tuberosity. This exposes the main trunk of the popliteal artery: doubly ligate this and divide it. Tie off the popliteal vein. Behind the artery, find the tibial nerve, draw it gently into the wound, and cut it clean (35-19D).

N.B. Divide the popliteal artery below its superior genicular branches which supply the soft tissues of the knee. These arise high in the popliteal fossa.

Reflect the anterior flap upwards with its underlying fascia to reveal the patellar tendon. Cut this at its insertion onto the tibial tuberosity. You can then lift up skin, fascia, patellar tendon, lower part of the capsule and the synovial membrane of the knee as a single flap proximally as far as the joint line.

Now expose and divide the *biceps femoris* tendon and the iliotibial tract on the lateral aspect of the knee. Find the common peroneal nerve deep to the *biceps femoris* tendon, cut it clean proximally so it retracts above the level of the amputation. Then reflect the short posterior flap and complete division of the capsule and ligaments of the knee round the whole circumference of the joint below the menisci. Detach the heads of *gastrocnemius* from the femoral condyles, and remove the lower leg.

CAUTION!

(1) The popliteal vessels lie very close to the posterior surface of the knee joint. If you have already tied them high up, they should not be in danger.

(2) There is no need to disturb the articular cartilage of the femur, or to remove the patella.

Draw the patellar tendon posteriorly through the intercondylar notch of the femur, and suture it to the anterior cruciate ligaments under some tension (35-19E). Suture the *sartorius* and the iliotibial tract to the fascial part of the extensor mechanism. Nibble or saw off the medial and lateral sides of the condyles. Remove the tourniquet (if present), control bleeding, drain and close the stump with the suture line lying posteriorly (35-19F).

GRITTI-STOKES AMPUTATION (GRADE 3.1)

To make a weight-bearing surface, saw off the end of the femur above the condyles, and saw the posterior surface of the patella off flat. Then bring the patellar tendon round so you can fix the undersurface of the patella to the bony stump of the femur.

35.6 Below-knee amputation

If a patient has a good prosthesis, he can walk, run, climb almost normally, even if he is a bilateral amputee. The best length of stump for a prosthesis is 12-18cm below the tibial tuberosity. The Jaipur type of prosthesis (35-21A) is cheap, versatile and readily available. For the traditional type of peg leg (35-21B) a shorter 10cm stump is needed. A stump of only 6cm slips too easily out of a prosthesis, so then a through-knee amputation would be better.

Do not amputate below the muscle area of the calf, because the tissue here has a poor blood supply.

Do not amputate below the knee if there is a fixed flexion deformity of the knee >30° from full extension or if the popliteal pulse is not palpable as the flap will depend on the profunda femoris artery.

BELOW-KNEE AMPUTATION

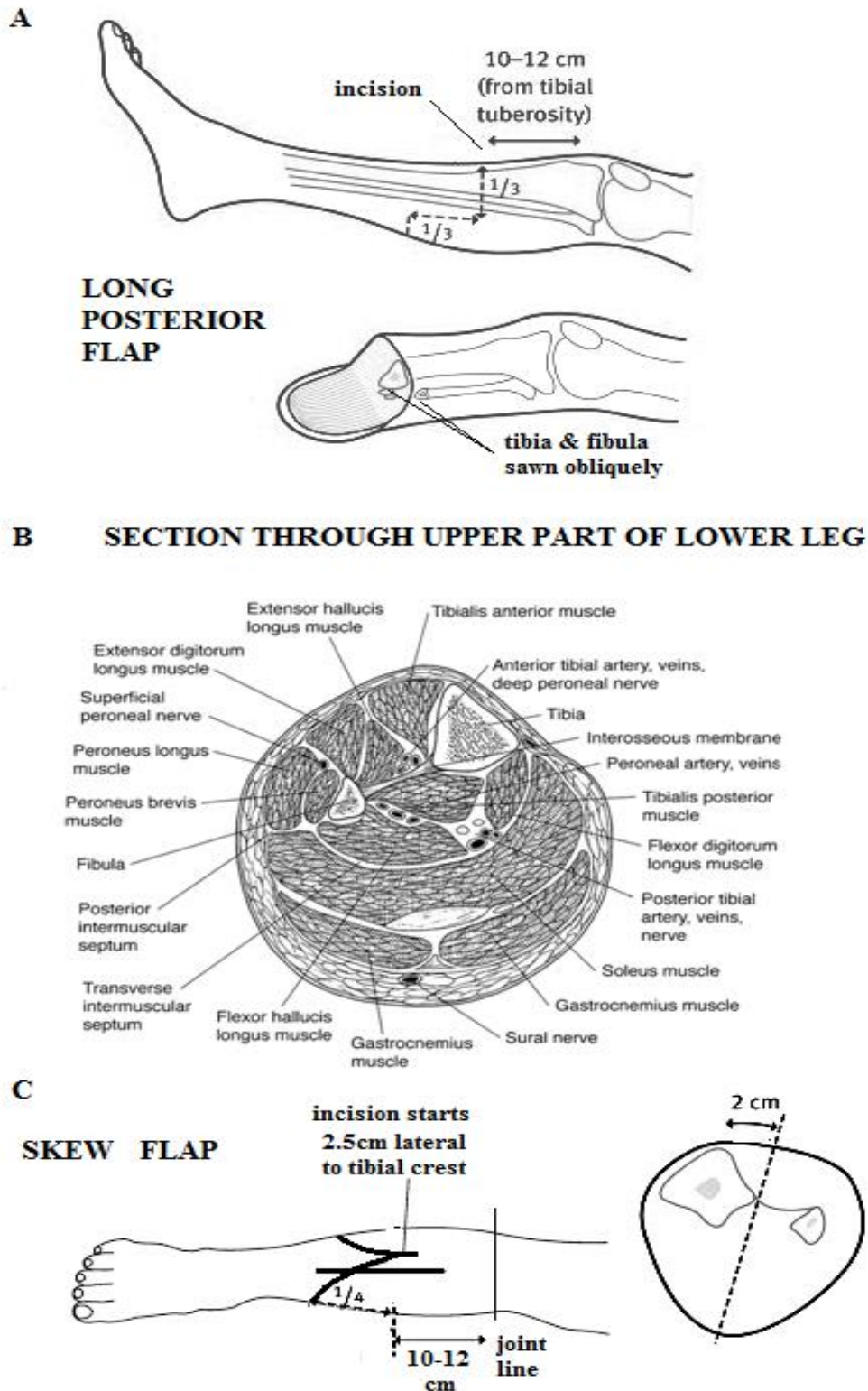


Fig. 35-20 AMPUTATING BELOW THE KNEE

A, incision using a long posterior flap. Mark the skin on either side of the tibia $\frac{1}{4}$ of the total circumference at a point 10-12 cm below the tibial tuberosity, and then mark down along the leg the same length. B, cross-section through the lower leg. C, skew flap showing apex of unequal fish-mouth incision placed 2 cm lateral to the tibial crest,

10-12 cm below the joint line, with a flap length $\frac{1}{4}$ the circumference of the leg. The result is a suture line at 15° tilt to the leg axis. A,C, After Marshall C, Stansby G. *Amputation and rehabilitation. Surgery* 2010;28(6):284-7. B, After Fraipont MJ, Adamson GJ. *Chronic exertional compartment syndrome. J Am Acad Orthop Surg* 2003; 11(4):268-76

BELOW-KNEE AMPUTATION (GRADE 3.2)

PREPARATION

Instill an enema before operation to empty the rectum if it is full. Catheterize a female patient. Enclose the foot in a polythene bag, so as to isolate it from the field of operation. Preferably use spinal anaesthesia.

Suspend the knee over an anaesthetic screen bar for ready access; if you cannot do this, place an inverted bowl under the lower leg. Prepare the skin right up to the groin, in case you need to convert to a through- or above-knee amputation (35.5). Make sure you have consent for this.

Mark the skin, ensuring a long posterior flap (35-20A). If you are not certain of the geometry of the flaps, cut them too long rather than too short. Measure the circumference of the leg 10-12cm below the tibial tuberosity, and divide this length into thirds. Start the skin incision anteriorly at this point and continue transversely round each side of the tibia $\frac{1}{3}$ of the way round; then continue down the leg the same length (usually 4cm below the anterior incision), and finally join both incisions posteriorly.

If a long posterior flap is not possible because of dubious skin vascularity, the skew flap is an alternative. It also moves the resultant scar away from the anterior crest of the tibia, on which a prosthesis socket rubs, and produces a more cylindrical stump, easier for fitting a prosthesis. In fact, the skew flap is actually a short posterolateral and a longer anteromedial flap based on a longitudinal leg axis tilted 15° laterally. Mark a fish-mouth incision, 2cm lateral to the subcutaneous crest of the tibia (35-20C) with the length of the flap $\frac{1}{4}$ the circumference of the leg.

If at this point you find ischaemic or infected tissues, proceed immediately to a through- or above-knee amputation.

Take the lateral incisions down to deep fascia, and the anterior incision straight down to the tibia and the interosseous membrane. The anterior tibial artery and vein lie on this membrane and need to be ligated. Cut the anterior tibial nerve clean. Strip the periosteum off the tibia for 2cm above the point of division and divide it obliquely with a saw, preferably Gigli's; then clear the fibula 2cm above the level of the tibial division, and divide it with a saw. *Do not use bone nibblers* as these tend to fragment the bone. Wash away bone dust, because this acts as a foreign body.

Hold the distal tibia forwards with a strong hook inside its medullary canal, and expose the posterior tibial and peroneal vessels lying under *tibialis posterior*; ligate and divide these and cut the posterior tibial nerve clean, allowing it to retract. Then slice obliquely through the calf muscles to reach the posterior skin incision; a large sharp amputation knife is best for this, giving a clean cut. Remove most of the *soleus* muscle as it plays no part in the vascularity of the myoplastic flap. This you can turn anteriorly and suture over the tibial stump.

Bevel the anterior corner of the tibia at 45° and smooth the edges with a rasp. Secure haemostasis and suture the deep fascia of the posterior flap to the tibial periosteum. It is important that there is absolutely *no tension* in this suture. Close the stump *again without tension*. *Do not cut off 'dog ears'*.

If there would be tension at this point, divide the tibia and fibula higher up; you may find you have to divide the vessels and nerves again higher up also.

DIFFICULTIES WITH A BELOW KNEE AMPUTATION

If a haematoma forms within the wound, open it up as much as necessary and evacuate the haematoma, otherwise it is very likely to become infected.

If the wound becomes septic, open it up and debride any dead tissue; you may need to re-fashion the stump if there is enough length. However, it usually means making a through- or above-knee amputation. This time, *use delayed primary closure*.

If bone protrudes through the stump, re-fashion it making sure the tibia is bevelled and the myoplastic flap is long enough to cover the bone end, and insist on exercises to prevent atrophy of the muscles.

If a fixed knee flexion contracture develops, make a through-knee amputation, or cut the stump even shorter and then fit a peg leg.

TYPES OF PROTHESES

moulded socket which covers the amputation stump & fits inside the prosthesis

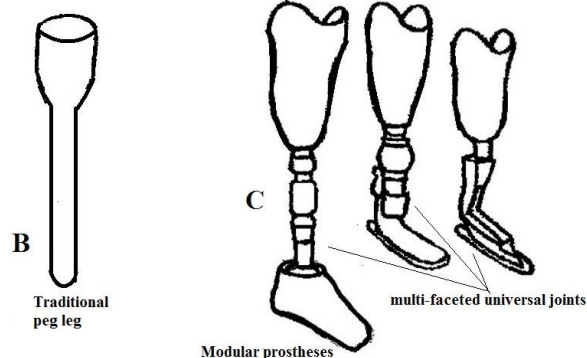
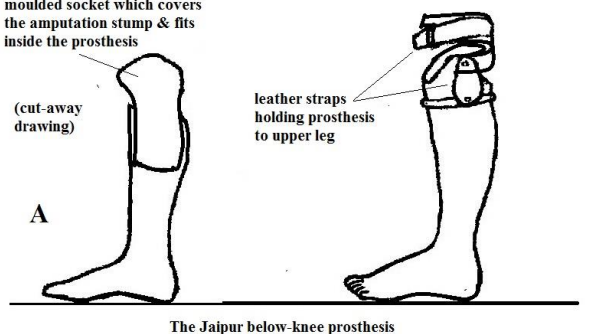


Fig. 35-21 TYPES OF PROTHESES.

A, The Jaipur foot. B, The peg leg. C, The modular jointed prosthesis. Kindly contributed by George Poulton.

35.7 Ankle & foot amputation

It is possible to disarticulate the ankle and adapt the stump so that it can be weight-bearing (the Syme's amputation). You need to remove all the bones of the foot and saw off the malleoli, so that the end of the tibia is flat. Then you remove a large full thickness heel flap subperiosteally from the calcaneum, and bring it forward to make a solid covering for the end of the tibia.

The patient can walk about his house on it without a prosthesis or crutches. He can also wear a simple and durable elephant boot. The distal tibial epiphysis is preserved, so it is good amputation for a child.

It is sometimes indicated in leprosy with very distal ulcers under the heads of the metatarsals.

This is an excellent amputation if it is well done, but it is also the most difficult of the amputations we describe. If you are not skilled, amputating below the knee would be wiser. However, if a Syme's amputation fails, a below- knee amputation is still possible. Its advantage is that if the front of the shoe is filled with cotton wool, a patient can walk reasonably well without a prosthesis.

A metatarsal amputation, however, is one of the less useful amputations; its main use is in crush injuries of the toes. *Do not use it for ischaemia.*

ANKLE DISARTICULATION (SYME'S AMPUTATION) (GRADE 3.4)

INDICATIONS

Lesions confined to the forefoot only, if you are fairly skilled.

CONTRAINDICATIONS

- (1) Arterial disease, unless this is strictly confined to the distal part of the foot. At least one of the posterior tibial or dorsalis pedis pulses should be palpable.
- (2) Infection. (Syme's amputation has a special posterior flap and is not suitable for delayed primary closure).

METHOD

Apply a tourniquet to the thigh (3.4), support the calf with a towel, and let the ankle protrude over the end of the table. Stand beyond the end of the table facing the foot. Mark out the flaps with a permanent marker. Hold the ankle at 90°.

Start the incision at the distal tip of the lateral malleolus. Bring it over the front of the ankle, level with the distal end of the tibia, to a point opposite to where you started, 2cm inferior to the tip of the medial malleolus. Then, bring the incision vertically under the sole of the foot to the tip of the medial malleolus.

Cut all structures down to the bone. Forcibly plantarflex the foot and cut all anterior structures down to the bone.

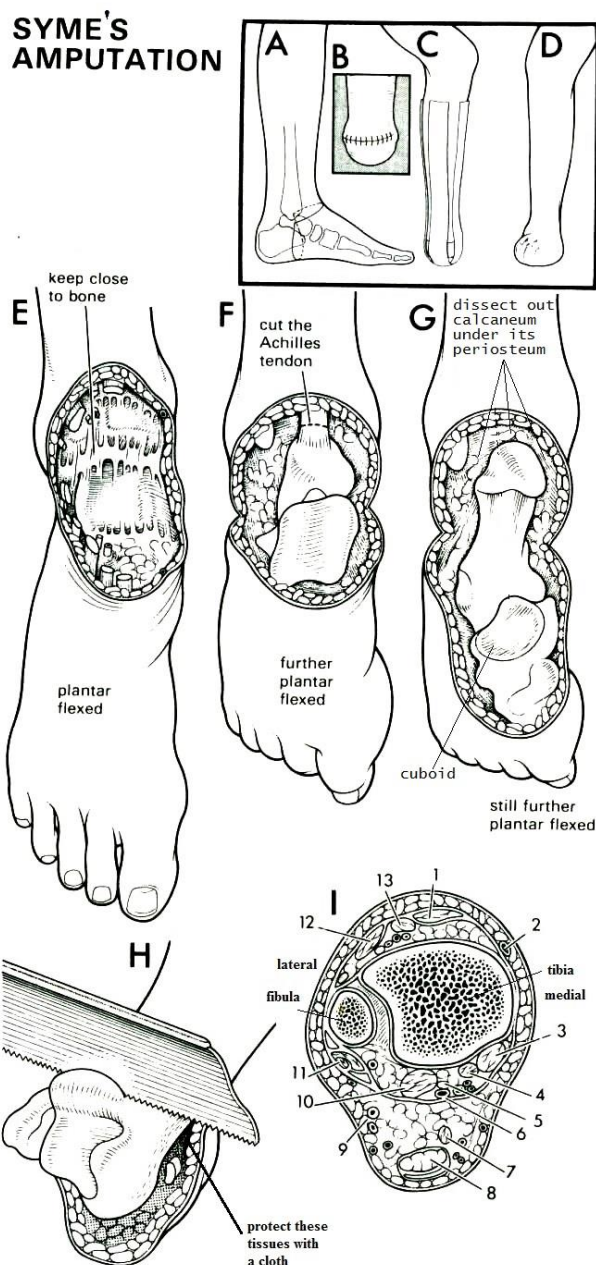


Fig. 35-22 SYME'S AMPUTATION.

A incision. B, completed stump immediately after suture. C, stump held in place with strapping postoperatively. D ultimate appearance of the stump. E, expose the ankle joint and cut its ligaments. F, further plantar flex the foot and cut its Achilles tendon. G, extreme flexion allows the calcaneum to be dissected out of its surrounding tissues subperiosteally. H, saw through the lower end of the tibia, protecting the soft tissues. I, cross section of the ankle joint with (1) *tibialis anterior* tendon, (2) *great saphenous vein*, (3) *tibialis posterior* tendon, (4) *flexor digitorum longus* tendon, (5) *tibial nerve*, (6) *posterior tibial artery and vein*, (7) *plantaris* tendon, (8) *Achilles tendon* and its overlying bursa, (9) *small saphenous vein*, (10) *flexor hallucis longus* tendon, (11) *peroneus longus and brevis* tendons, (12) *extensor digitorum* tendon, (13) and *extensor hallucis longus* tendon. After Campbell WD, Edmonson AS, Crenshaw AH, (eds) *Operative Orthopaedics*. CV Mosby 6th ed 1980 with kind permission.

Put a knife into the ankle joint between the medial malleolus and the talus and cut the deltoid ligament. Do the same on the lateral side and cut the calcaneo-fibular ligaments.

Put a bone hook posteriorly in the talus to plantarflex the foot even more. Using a new, sharp scalpel blade, dissect the tissues away from the medial and lateral sides of the talus and calcaneum, *keeping as close to the bone as you can*. Then cut the calcaneum out of the heel, leaving behind the periosteum and specialized fibrofatty tissue which is essential for weight-bearing. Work at it from all sides keeping very close to bone. *This is the most difficult and the most critical part of the operation.*

Pull the talus and calcaneum forward with a bone hook. Dissect posteriorly, and cut the posterior capsule of the ankle and the Achilles tendon. Using a step incision cut the Achilles tendon about 10cm proximal to the heel flap. This will prevent the heel stump displacing. *If you do not do this, the Achilles tendon tends to pull up the back of the stump.* Cut it high up, *or else you may injure the posterior tibial vessels.*

Then dissect subperiosteally round the ball of the heel, so as to free the calcaneum and reach the first incision on the sole. As you do so, steadily dislocate the foot downwards more and more, until you reach the distal end of the plantar skin flap and finally free it from the ankle.

CAUTION!

- (1) Keep within the periosteum very close to the bone: as you dissect the calcaneum out of the heel flap, or you will cut the posterior tibial and peroneal arteries which are very close to the back of the joint capsule. If necessary, remove the calcaneum piece by piece.
- (2) *Do not trim away any muscle or fat in the heel pad*, because it is needed for walking.
- (3) Keep close to the bone, and *do not button hole the heel flap*.

Remove the whole foot except for the heel flap. Dissect the heel flap from the malleoli, and reflect it posteriorly. Saw off the malleoli and the articular cartilage of the tibia in a single cut. Make sure that the ends of the tibia and fibula are accurately horizontal, so that weight-bearing squarely on the stump is possible.

CAUTION!

- (1) The cut surfaces of the bones must be parallel to the ground on standing.
- (2) If you are amputating a child's ankle, *do not destroy the distal tibial epiphysis.*

Round off and smooth all the sharp corners of the tibia and fibula. Pull on any tendons you can see, cut them and let them retract proximally into the leg. Tie and cut the posterior tibial artery and vein just proximal to the cut distal edge of the heel flap. Divide the posterior tibial nerve adjacent to the artery. Tie the anterior tibial artery in the anterior flap similarly. Release the tourniquet, and carefully control bleeding. Bring the heel flap forward to cover the ends of the bones.

CAUTION!

- (1) *Do not remove the dog-ears, however big:* they carry an important share of the blood supply of the flap and will disappear later.
- (2) Prevent the heel pad from tilting out of alignment with the tibia; *this is a real disaster!*

Apply two long U-shaped strips of strapping (35-22C). Put the 1st piece on starting below the knee posteriorly, bring it round the flap, and then anteriorly, so as to flex the flap over the stump. Apply the 2nd strip from one side to the other. Keep these strips in place for at least 3wks, and replace them as necessary. Check the strapping daily, to make sure that the heel pad is centred over the tibia. Adjust it if necessary. At 2wks, put on a well-moulded cast right round the stump. Avoid weight-bearing. At 6wks, take the mould for the prosthesis, and apply a weight-bearing cast. At 12wks get ready the definitive prosthesis or elephant boot.

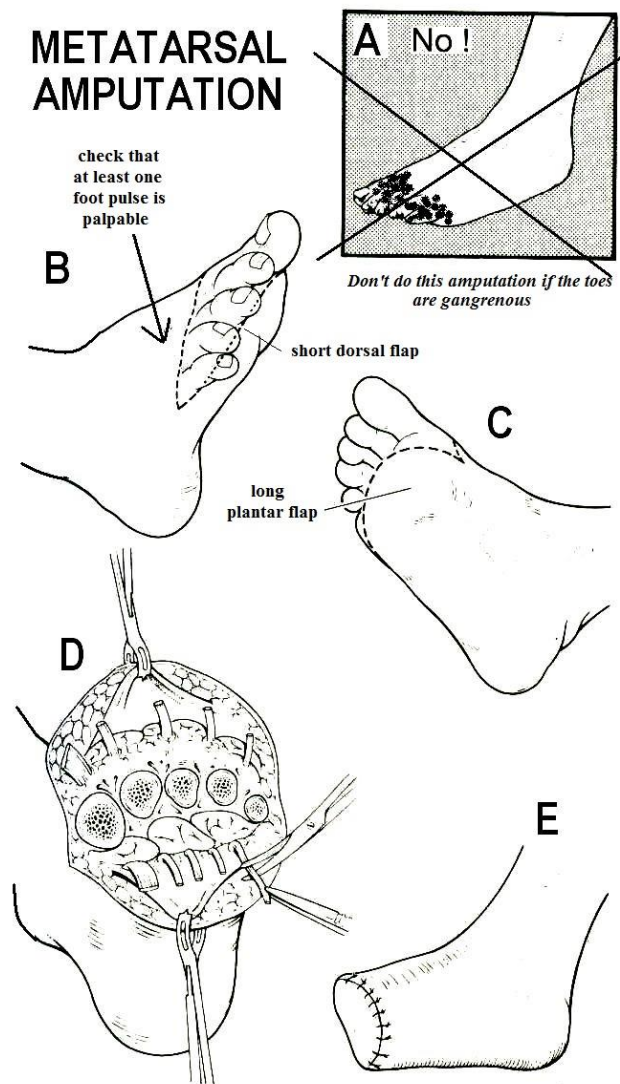


Fig. 35-23 LISFRANC'S AMPUTATION.

A, *not for gangrene!* B, short dorsal flap. C, long plantar flap. D, expose the metatarsals after division of flexor tendons. E, completed stump. After Rob & Smith with kind permission

TRANSMETATARSAL (LISFRANC'S) AMPUTATION (GRADE 2.4)

INDICATIONS

- (1) Crush injuries or contractures of the toes.
- (2) Occasionally, in leprosy when there are large and persistent ulcers due to osteitis.
- (3) Gross infections presenting late with osteitis.

CONTRAINDICATIONS.

Gangrene, particularly in a diabetic. Absent foot pulses.

METHOD.

Make a long plantar and a short dorsal flap (35-23). This will bring the suture line dorsally. Start the dorsal incision at the site of bone section on the anteromedial aspect of the foot. Curve it distally a little to reach the midpoint of the lateral side.

Take the plantar incision distally beyond the metatarsal heads 1cm proximal to the crease of the toes. The foot is thicker medially, so make the flap slightly longer on the medial than on the lateral side.

Cut the plantar flap to include the subcutaneous fat and a thin bevelled layer of the plantar muscles. Reflect the plantar flap proximally to the site of bone section and then use large bone cutters to divide the metatarsals. Try to preserve as much of them as you can.

If you cannot preserve the metatarsals, make a Syme's amputation, or amputate below the knee.)

Do not try to amputate through the tarsus, because the stump will tilt. If you can preserve the dorsiflexors, the result will be a reasonable stump; if you sacrifice them, the foot will remain in plantar flexion.

Find the nerves and cut them well proximally. Pull the plantarflexor tendons and cut them so that they retract into the stump of the foot. Release the tourniquet, control bleeding, and close the stump.

TOE AMPUTATIONS (GRADE 2.2)

INDICATIONS

- (1) Gangrene.
- (2) Osteomyelitis.
- (3) Gross deformity.

Remove all the toes if several are gangrenous or injured.

N.B. Try to preserve the hallux which gives 'lift off' when walking.

CONTRAINDICATIONS.

Absent foot pulses.

N.B. Avoid amputating single toes, especially the 2nd toe, if possible: adjacent toes tend then to become deformed.

METHOD.

Make a racquet incision for individual toes (35-24C), or a transverse incision across the proximal phalanges on the plantar surface and across the mtp joints on the dorsum so the scar finishes up dorsally if you are removing all the toes (35-24D).

TOE AMPUTATIONS

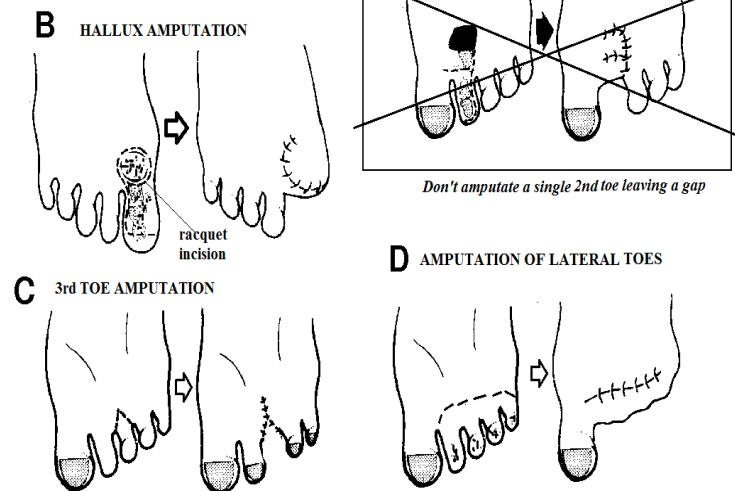


Fig. 35-24 TOE AMPUTATIONS.

A, avoid amputating the 2nd toe on its own. B, make a special curved racquet incision for the hallux. C, make a standard racquet incision for an individual (3rd-5th) toe. D, make a flap to close the wound on the dorsal surface if you are amputating all lateral 4 toes.

For the hallux, use a modified racquet incision, with the 'handle' over the distal 2cm of the 1st metatarsal, lateral to the extensor tendon, in order to preserve a skin flap long enough to cover the metatarsal head (35-24B). Divide both flexor and extensor tendons, and suture them together around the 1st metatarsal head to secure the sesamoid bones.

Cut down straight onto bone, and either divide the proximal phalanx just distal to the joint capsule, or carefully disarticulate the mtp joint. Make sure you smooth down any sharp osteophytes which may be protruding before you close the skin.

Release the tourniquet, control bleeding and close the stump.

35.8 Aneurysms

An aneurysm is a dilation of an artery; it can occur anywhere. The 'false' aneurysm of traumatic origin occurs when there is a laceration of the artery and blood leaks out into a confined space, clots and forms a false capsule. 'True' aneurysms can occur in large vessels (aorta or iliacs) but then require advanced vascular surgery; in smaller vessels, their treatment is not so complicated. The blood in an aneurysm does not flow smoothly, and so may clot; pieces of thrombus may detach and be carried further downstream as emboli.

Occasionally the aneurysmal sac may become infected secondarily, or it may originate from a septic embolus (the so-called 'mycotic' aneurysm). Its main danger is increase in size and rupture.

An aortic aneurysm >7cm diameter has a 20% risk of rupture within 1yr. This occasionally occurs into a vein, resulting in an arterio-venous fistula, or stomach or bowel, resulting in initially obscure intermittent usually minor rectal bleeding, and then later a sudden massive gastro-intestinal haemorrhage.

Remember: *aneurysms pulsate!* So, if you find a swelling which pulsates, *do not incise it thinking it is an abscess!* Check, if you can, by performing an ultrasound of the swelling (38.2D).

Weakening of the arterial wall also occurs with HIV disease, sickle cell disease, syphilis, salmonellosis and *staphylococci*. There are also rare fungal causes, and elastic tissue disorders such as Ehlers-Danlos and Marfan syndromes.

Surgery of aneurysms of the aorta or iliacs requires advanced surgery, so refer the patient if possible. For smaller vessels there are the following options:

In a limb, if the aneurysm is chronic, the collateral circulation will be adequate. Perform a Hunterian ligation: check that pulsation and flow distal to the aneurysm is present (preferably by ultrasound); then expose the artery feeding the aneurysm above and below it, and ligate it doubly on both sides. If the aneurysm sac is large or infected, it is best to open it and remove the contents.

If the aneurysm is acute, the collateral circulation will be inadequate. Excision with vein grafting is necessary. This is not as difficult as it may appear; if you are able to perform bowel anastomoses, you should be able to manage a vascular anastomosis with a fine non-absorbable running suture, with small spaces between bites.

N.B. Do not use haemostats to clamp vessels you wish to suture late: they will be irreparably damaged!

Remember:

- (1) use fine instruments (even eye equipment),
- (2) use rubber or cotton tape to isolate, retract or interrupt the flow in vessels,
- (3) use heparin to prevent blood which is not flowing from clotting: *use a maximum of 3,000 units into the vessel in an adult.*

SAPHENOUS VEIN GRAFT (GRADE 3.3)

Make a 10cm longitudinal groin incision, and carefully dissect out an adequate length of long saphenous vein. Tie its tributaries. Ligate above and below the site you wish to divide the vein.

Remove a segment of vein and reverse its direction (because of its valves); then hold its ends with bulldog clamps and fill it with heparinised saline. This will distend the vein to the correct size, and show up leaks from tributaries you have not ligated; put ties round these.

A SAPHENOUS VEIN GRAFT

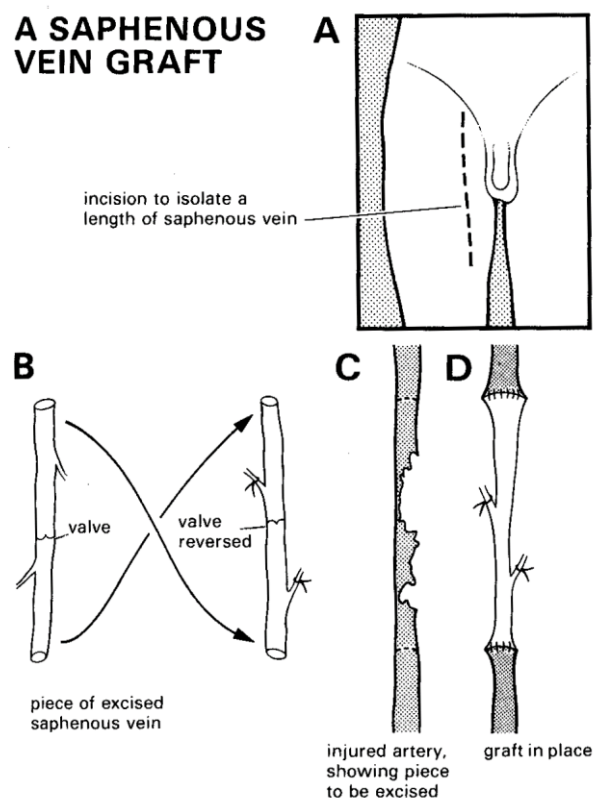


Fig. 35-25 SAPHENOUS VEIN GRAFT.

A, groin incision. B, reverse the vein orientation. C, arterial segment to be excised. D, vein graft sewn in place.

Kindly contributed by Peter Bewes.

Trim the ends of the vein, and leave it clamped with heparinised saline inside till you are ready to use it, under a warm pack.

Put a gauze or rubber drain behind the artery you wish to repair. Release the clamp on the artery to flush out any clots, and reclamp it. Place the vein graft (*with the valves reversed*, and the proximal clamp removed) adjacent to the proximal arterial segment. Put in two stay sutures bringing together the corners of both artery and vein. With one of these threads, make a continuous suture of the back layer till you reach the other stay suture; knot these together on the outside of the vessel. Then continue on the front layer. Now put two more stay sutures bringing together the corners of the vein graft and the distal arterial segment. Complete the anastomosis as before, making sure your knots are outside the vessel. Release the clamp to let the graft fill with blood before finally closing the last suture. Introduce some heparin into the distal arterial segment and then release the distal arterial clamp. Check for leaks; apply pressure and check again. *Do not be too hasty to insert another suture as this may cause a further leak!*

Check if you can palpate a distal pulse; if so, all is well. If not, check that the proximal pulse is palpable; if it is not, release the lower anastomosis slightly with a fine artery forceps to let out clot, and introduce some heparin. Otherwise instil heparin proximally.