

10 Pus in the abdomen

10.1 Abdominal sepsis: peritonitis

Abdominal sepsis is a common and life-threatening complication following severe infection, necrosis, perforation or injury of abdominal viscera. Not infrequently, abdominal sepsis occurs after medical intervention: a laparotomy, an endoscopic procedure, peritoneal dialysis, a radiological investigation.

In the majority of cases the mainstay of treatment is the expeditious removal of bacteria and dead tissue; early recognition of the condition is therefore imperative. Abdominal sepsis occurs in the form of either generalized or localized peritonitis. One form can evolve into the other.

The common sites for localized peritonitis are (10-6):

- (1) On the right side: subphrenic, subhepatic, ileocaecal (perityphlytic)
- (2) On the left side: subphrenic, perisigmoid
- (3) In the middle: intermesenteric, pelvic.

N.B. Localized accumulation of fluid in the peritoneum is usually referred to as an 'abscess'. This is a misnomer, because there is often no well-circumscribed wall containing the pus. Also, the nomenclature with regard to the anatomical sites of 'abscesses' is unsettled.

The area of the peritoneum is three times that of the skin, and is extremely porous to bacteria; thus septicaemia quickly ensues. So it is not surprising that the mortality from generalized peritonitis is at best 10%, even in good hospitals. Bacteria, both aerobic and anaerobic, can be released from the bowel when it perforates but also when it becomes inflamed or ischaemic. Bacteria can also come from an abscess, particularly the liver (15.10), or from the Fallopian tubes. When there is chemical contamination of the peritoneum from blood, stomach contents, bile, pancreatic juice, urine or cyst fluid, infection quickly follows. Traumatic or surgical intervention obviously allows a route for bacteria to contaminate the peritoneum; occasionally, especially in HIV+ve patients and cirrhotics, sepsis reaches the abdomen primarily from the bloodstream (primary peritonitis).

You can reduce the risk of death from peritonitis if you:

- (1) Operate early, before the patient becomes very ill,
- (2) Resuscitate adequately before operation, and
- (3) Take the necessary precautions to minimize contamination of the abdominal cavity, when you perform a laparotomy. So handle the tissues gently, anastomose the bowel carefully, pack away potentially infected areas, control bleeding meticulously, and use appropriate prophylactic *pre-operative* antibiotics (2.9).

Peritonitis develops through several stages, which need different treatment:

(1) Disease in an organ before the overlying peritoneum is affected. For example, there may be the symptoms of peptic ulceration, appendicitis, cholecystitis or typhoid fever, but no involvement of the peritoneum. At this stage, you should be able to treat the underlying disease and prevent peritonitis.

(2) Localized peritonitis. With proper treatment, localized peritonitis may resolve. A mass may form, but the toxic effects of sepsis will be absent.

(3) 'Abscess' formation around the organ responsible. Pus forms, but this is sealed off, not usually by a fibrous capsule from the rest of the abdominal cavity, but by loops of bowel and/or omentum which are stuck to one another by a fibrinous exudate. The mass is generally bigger than in stage 2 above, and is associated with toxic symptoms. It is still, if left untreated, likely to develop into spreading peritonitis (stage 4). Occasionally the abscess may be walled off entirely from the rest of the abdominal contents, or even be retroperitoneal (6.15). This abscess may however rupture and sepsis may then spread.

(4) Spreading peritonitis which may become generalized. Multiple collections of pus develop in the abdominal cavity, particularly in the pelvis and under the diaphragm. Later, all the abdominal organs become bathed in pus. If you operate and wash the pus out of the abdominal cavity, more collections may still form post-operatively.

Bowel which is surrounded by pus usually develops ileus (12.16): the bowel sounds become silent and the abdomen distends, as the bowel fills with gas and fluid. This fluid, and that which is lost into the abdominal cavity, depletes the circulating blood volume so the urine output falls and the pulse rate rises. As peritonitis advances, the peripheral circulation fails and shock results, but pain may diminish as ascites collects and dilutes the peritoneal irritation.

As always, but particularly with an acute abdomen, *a good history and a full examination are extremely important*: the commonest mistake is to leave out some of the essential parts of both. The history should suggest the diagnosis, and examination should merely confirm or refute it. Remember that your diagnostic success is proportional to the care you take getting the history, your keeping an open mind, and your thoroughness in your examination. When you decide to operate, *don't do so merely on the diagnosis of an 'acute abdomen'*, but on its most likely cause, with a list of possible alternatives, based on as much evidence as you can find. The early symptoms and signs will be more distinctive than the later signs, when generalized peritonitis has ensued. After the operation, if the diagnosis is a surprise, *think back to distinguish which features of the history were good clues*. However, *don't wait till you are certain of the diagnosis before you operate on a patient who needs surgery acutely!*

The common mistakes are:

- (1) Not to ask the right questions properly and methodically.
 - (2) Not to examine the patient carefully and systematically, admit him and monitor him carefully and *to look at him again* if you are not clear of the diagnosis, or to see if the condition has worsened.
 - (3) Not to make and record a diagnosis and a differential diagnosis, especially if you are handing over to a colleague.
 - (4) To forget that many medical conditions, especially pneumonia (by causing diaphragmatic pain), can mimic an acute abdomen.
 - (5) Not to consider other, non-surgical conditions.
 - (6) To forget that age and sex can profoundly influence the probability of a particular diagnosis.
 - (7) Not to make adequate allowance for the late case whose history is obscured, whose mind is clouded, and whose signs are altered.
 - (8) To forget the 'silent interval' between the immediate chemical peritonitis and the delayed onset of bacterial peritonitis (13.3).
 - (9) To forget that signs you expect may be obscured in advanced peritonitis, septic shock, diabetes, HIV disease, aged patients and with steroid therapy.
 - (10) Finally, worst of all, not to go and see a patient with a suspected abdominal emergency immediately.
- Base your diagnosis on as many items of information as possible. *The explanations given for a particular sign or symptom are suggestions only.*

HISTORY

Except in the very young, the very old, the demented, confused, psychotic and unconscious, PAIN is the cardinal symptom. Constitutional disturbances such as anorexia, nausea and vomiting, the inability to pass flatus in the presence of either constipation or diarrhoea and frequency of micturition are common. *In general, the patient with peritonitis is weak, thirsty, anorexic and nauseated.*

ONSET

(1) "How did your pain start?"

Waking at night	Probably serious
Start with an injury	Ruptured spleen
So severe that you collapsed or fainted	Perforated peptic ulcer Ruptured ectopic gestation Acute pancreatitis
Drinking much alcohol	Acute liver swelling Gastritis, pancreatitis

PAIN. Abdominal pain is usually the presenting symptom; its correct interpretation will lead you towards the cause. Expect it to have >1 component. *Severe pain lasting >6h is highly significant and demands you find out the cause!*

Look out for the *pattern* of pain:

- (i) A sharp continuous pain due to inflammation of the parietal peritoneum.
- (ii) An agonizing continuous pain due to ischaemia of the bowel.
- (iii) A colicky pain is due to obstruction of either bowel, biliary tree or urinary tract: it comes in waves and spasms and often makes the patient move about restlessly.

Colicky pain may come before the pain of peritonitis, but is *not* the pain of inflammation.

Pain may also be referred from the diseased area to the other parts of the body that are derived from the same spinal segment. For example, pain from the gallbladder may be referred to below the right scapula; pus or blood under the diaphragm may present with pain in the shoulder.

There can be pain of more than one kind. For example, when the lumen of the appendix is obstructed, there is central abdominal pain of type (iii), but as soon as the peritoneum over it becomes inflamed, there is pain of type (i) in the right iliac fossa. If the appendix becomes gangrenous, there is ischaemic pain of type (ii).

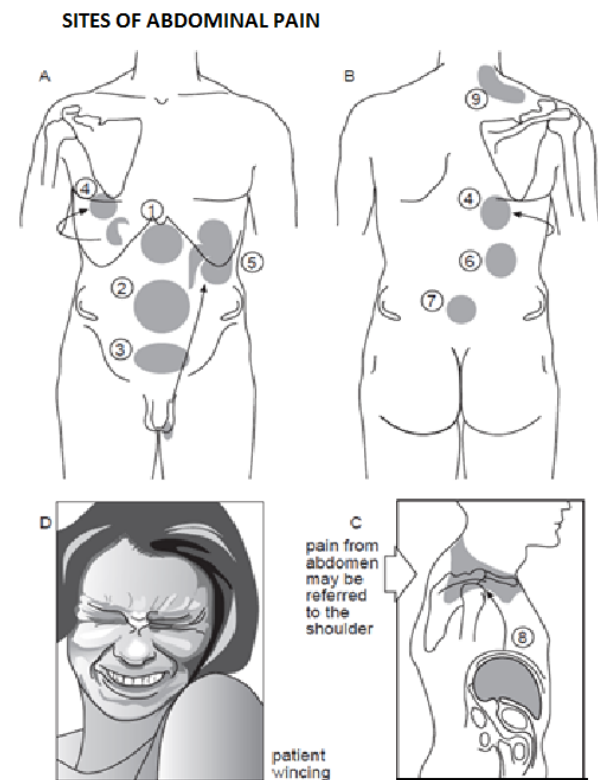


Fig. 10-1 THE SITES OF ABDOMINAL PAIN.
 A, (1) lesions in the stomach, duodenum, gallbladder, and pancreas cause pain in the epigastrium. (2) lesions from the duodenum down to the middle of the transverse colon cause pain in the middle of the abdomen. (3) lesions from distal transverse to sigmoid colon cause pain in the lower abdomen. (4) gallbladder pain is primarily epigastric or in the right hypochondrium, but may be referred under the angle of the right scapula. (5) ureteric colic is frequently referred to the testicle on the same side. B, (6) kidney and pancreatic pain may be referred to the back. (7) uterine and rectal pain may be referred to the sacral area. C, (8) diaphragmatic pain is frequently referred to the shoulder. D, when you examine the abdomen for tenderness, *always* look at the patient's face: wincing is a very reliable sign of peritoneal irritation. *After Silen S. Cope's Early Diagnosis of the Acute Abdomen. OUP, 15th ed, 1979, Figs. 2,3 with kind permission.*

(2) "Did the pain start suddenly?"

Suddenly	Rupture of duodenal ulcer or bowel Torsion of testicle, bowel or ovarian cyst Mesenteric vessel occlusion Rupture aortic aneurysm
----------	--

(3) "Where is the pain and where did it start?"

Epigastrium/umbilicus	Small bowel/appendix
Hypogastrium	Large bowel
All over abdomen	Perforated peptic ulcer Ruptured ectopic gestation Ruptured pyosalpinx
Loin & testicle (<i>retroperitoneal not causing peritonitis</i>)	Ureteric colic
Back	Ruptured aortic aneurysm Pancreatitis
Tip of the shoulder	Subphrenic/liver abscess Diaphragmatic pleurisy Ruptured spleen

(4) "What is it like?"

Throbbing/constant/burning	Inflammatory (e.g. appendicitis, salpingitis)
Burning/boring	(e.g. peptic ulcer, pancreatitis)
Intermittent with spasms	Colic

If it is colicky, how long do the spasms last, and is there complete relief between them?

(5) "Has it moved?"

Started in the umbilical region & moved to the right iliac fossa	Appendicitis
From the loin to the groin/testis on the same side	Ureteric colic

(6) "What makes your pain better?"

Lying absolutely still	Peritonitis
Walking bent forwards	Appendicitis, pancreatitis
Lying with knees flexed	Appendicitis, psoas abscess (<i>Inflammation in contact with the psoas muscle</i>)

(7) "What makes it worse?"

Coughing, sneezing, laughing, moving	Peritonitis
--------------------------------------	-------------

(8) "Does it hurt to pass urine?"

Dysuria	Urinary tract infection Pelvic abscess close to the bladder Inflamed appendix irritating the right ureter
---------	---

VOMITING

Vomiting in the form of a single initial vomit is usual in most kinds of acute abdomen, so is little help to make a specific diagnosis. However, a few special features will give you some clues, especially with intestinal obstruction (12.2).

(1) "Tell me about the vomiting."

Started with pain but now less	Perforated peptic ulcer*
Severe and persistent	Strangulated small bowel
At the height of the pain	Acute pancreatitis Bowel, biliary, ureteric colic Torsion testis/ovarian cyst

* N.B. persistent vomiting is rare in such patients

(2) "What is the association between the pain and the vomiting?"

Vomiting before the pain	Gastroenteritis
Vomiting sudden and soon after the pain	Strangulation or obstruction of proximal small bowel Cholecystitis
Vomiting c.4h after the pain	Distal small bowel obstruction Appendicitis Peptic ulcer
Pain but no vomiting	Salpingitis Tubo-ovarian abscess Haemoperitoneum Gastric volvulus Oesophageal perforation (<i>the cause is outside the bowel</i>) Large bowel obstruction

PREVIOUS HISTORY

(1) "Have you ever had pain like this before?"

Like the present but less severe	Intussusception Obstruction Appendicitis Torsion
When hungry relieved by food	Duodenal ulcer
Epigastric irregularly related to meals	Cholecystitis
Related to NSAID or steroid use	Gastritis Peptic ulcer

BOWELS

(1) "Have you noticed any change in your bowel habit?"

Usually regular, constipation for several days	Large bowel obstruction
Hypogastric pain & diarrhoea with mucus, then hypogastric tenderness & constipation	Pelvic abscess
Diarrhoea, colic, fever	Gastroenteritis
Bloody stools with mucus	Intussusception
Frequent bloody stools	Colitis
Worms	<i>Ascaris</i> obstruction

(2) "When did you last pass a motion, and what was it like?" Two or more stools may be passed after the onset of a complete small bowel obstruction. In complete low large bowel obstruction, no flatus or stools are passed.

MENSTRUAL PERIODS

(1) "When was your last period? Was it before or after the normal time? Was the loss more or less than usual? Has there been any slight loss since your last period?"

Last period late or scanty	Ectopic gestation
1-3 missed menstrual periods, followed by a small dark loss	Threatened miscarriage
Last period painful, dysmenorrhoea not usual	Salpingitis

CAUTION! Always ask the questions above with care. Asking "Are your periods normal?" is not enough.

OTHER SYMPTOMS

Poor appetite, weight loss, fever, general deterioration in health, change in girth	TB, HIV, malignancy
Severe illness with fever	Typhoid

Don't forget to ask about possible trauma. Vigorous massage of the abdomen may cause bowel injury!

GENERAL EXAMINATION FOR PERITONITIS

Abdominal tenderness, rebound tenderness and distension are the cardinal signs. There may be shortness of breath (which you may note simply by a difficulty in speaking), tachypnoea and cyanosis.

Tachycardia is common, as is sweating, whereby the extremities may be warm or cold. Fever is not always present, and infants as well as the aged may have hypothermia. There may be jaundice. Abdominal sepsis, almost invariably, if untreated, leads to septic shock.

(1) **The general condition** may be surprisingly normal especially early on in the disease. Later on, prostration and apprehension supervene. Look at the state of nutrition. If the patient is limp, lethargic, and slow to respond, suspect toxæmia, septicaemia, or shock. If he is restless, suspect cerebral hypoxia, due to hypovolaemia.

Look for a dry tongue and lack of skin turgor (dehydration), pale conjunctivæ (anaemia), mouth signs of HIV disease (5.6), and a sickly sweet breath smell (ketones). Look at the unpigmented skin for blotchy purplish discolouration (shock).

(2) **The face** may be characteristic in advanced disease.

Nose tip & earlobe and hands cold	Hypovolaemia Peripheral circulatory failure
Mildly grey	Perforated peptic ulcer Acute pancreatitis Strangulated bowel
Deathly pale with gasping respiration	Severe bleeding (e.g. ectopic gestation)
Gaze dull and face ashen	Severe toxæmia
Eyes sunken, tongue and lips dry, skin elasticity reduced	Dehydration Intestinal obstruction

(The Hippocratic facies is a combination of all of these; any one of these may deteriorate and look worse!)

(3) **The pulse** may be normal early on. An increase in the pulse rate is important in deciding if the abdominal condition is serious, especially with an abdominal injury. Tachycardia is usual in peritonitis, and early in strangulation of the bowel. The pulse of typhoid fever is no longer slow after the ileum has perforated.

(4) **The patient's attitude in bed** is characteristic: lying still and only changing position in bed with pain and difficulty, keeping the hips and knees flexed, fearing to cough, sneeze or move. If he is constantly moving around, straight one minute and doubled up the next, he has colic and *not* peritonitis.

(5) **The respiration** will show minimal movement of the abdomen; later there is shallow and grunting respiration, and in shock it is rapid and shallow. If, in a child, the rate is twice normal, and the *alae nasi* are flaring, pneumonia is likely. *Don't forget to listen to the chest.*

(6) **The temperature** is raised; if it is not, the inflammation is early or there is pure intestinal obstruction. Severe fever from the onset may occur in typhoid, basal pneumonia, or pyelonephritis.

THE ABDOMEN. Ask the patient to point to where the pain started, to where it is now, and to where it is worst.

(1) **Look at the abdomen.** Is its contour normal? Look for distension due to gas or fluid: test for shifting dullness. Initially in peritonitis the abdomen is tympanitic, later it will fill with ascitic fluid.

Does the abdomen move freely on breathing? Ask the patient to inhale and exhale fully and cough: inability to do this properly indicates peritoneal irritation. Peritonitis anywhere may splint all or part of the abdomen, and stops the normal movement that accompanies breathing.

Reduced movement in the lower abdomen suggests PID or appendicitis.

Visible peristalsis means there is obstruction not paralytic ileus, and so no peritonitis.

Expose the whole abdomen including genitalia and look at the groins: there may be an obstructed irreducible hernia.

Are there any old operation scars?

N.B. Don't miss the Pfannenstiel scar in an obese woman or the subumbilical laparoscopy scar!

(2) **Feel the abdomen.**

The great Hamilton Bailey (one of Britain's foremost surgical teachers, 2.10) used to examine the abdomen by kneeling by the patient's bedside: copy him!

First relax the abdomen by flexing the hips. If necessary, ask an assistant to support the flexed knees. If extending the hips causes abdominal pain, this is a reliable sign of peritonitis or psoas abscess. Tap the abdomen with your fingers: if this causes pain, you don't need to hurt the patient further by pressing harder!

Lay your hand flat on the abdomen, and keep your fingers fully extended as you feel for tenderness. Your hand must be warm, gentle, patient, and sensitive. You may win a child's confidence by examining him using his own hand or with your hand on top of the sheet, or secreted under the bedclothes, or even with him sitting on his mother's lap. Use light palpation first to test for muscle rigidity and spasm (guarding), and localize the tenderness. Then, if necessary use deep palpation.

Wincing (10-1D) on pressure of the abdomen is a very reliable sign of peritonitis and *you will miss it if you don't look at the patient's face!* If peritonitis is advanced, *there is no need to test for rebound tenderness*; it is cruel and unhelpful. If the abdomen is rigid like a board, this is proof of generalized peritonitis, especially that due to a perforated peptic ulcer. But if peritonitis is localized, rebound tenderness is a good indication as to which parts of the peritoneum are involved and which are not, but by itself, *it is not a very reliable sign.* Often light percussion is better.

Avoid the painful area, and start abdominal palpation as far from it as you can. (*Don't worry if the patient tells you it is the wrong place!*) Move towards it slowly. Find where the area of greatest tenderness is. It will be easier to find if there is no generalized guarding, and is a useful clue to the organ involved, e.g. the right iliac fossa (appendicitis), or the right hypochondrium (cholecystitis, liver abscess).

N.B. A doughy feel suggests chronic tuberculous peritonitis, especially if ascites is present.

CAUTION! A patient may show very little rigidity if:

- (i) He is HIV+ve and has a neuropathy, or is very old.
- (ii) The peritonitis is advanced and ascitic fluid dilutes the peritoneal irritation: *so as he gets more ill, the tenderness diminishes!*
- (iii) He is anyway very toxæmic and ill.
- (iv) She is a woman who is pregnant, or whose abdominal muscles are stretched after delivery.
- (v) He has been given narcotic analgesia, especially post-operatively, or is paraplegic with a sensory level at the 10th thoracic vertebra (T10) or above.
- (vi) He is taking steroid medication.
- (vii) He is diabetic.
- (viii) The perforation occurred about 6h before, so that the immediate rigidity has had time to go, and secondary bacterial peritonitis has not yet had time to develop.
- (ix) He is very fat and flabby, and the muscles are thin and weak.
- (x) Pathology is confined to the pelvis, retroperitoneum, or high under the diaphragm.

N.B. The cause of peritonitis does not relate to the intensity of the pain.

Look for superficial induration and tenderness in the abdominal wall (pyomyositis, necrotizing fasciitis).

(3) **Can you feel any masses?** In the right iliac fossa this may be a tuberculoma, an appendix mass, amoebiasis, a mass of *ascaris* worms, a lymphoma; in the right hypochondrium it may be an empyema of the gallbladder or a liver abscess; in the loin a pyonephrosis; in the pelvis a full bladder, adnexal mass or enlarged uterus. Faeces in the bowel is compressible, but may appear as a fairly solid mass. A tender mass adjacent to the midline (haematoma from rupture of the epigastric artery) will not disappear when the patient tenses the abdominal wall (Fothergill's sign).

N.B. In very severe pain, a moderate dose of opioid may:

- (i) reduce the pain,
- (ii) make for more comfort and improve getting a good history, and
- (iii) prevent immediate guarding of the abdomen whenever you touch it, so that the physical signs become more localized and the cause clearer.

(4) **Listen to the abdomen** for decreased or absent bowel sounds: you may need to wait for 3mins! High-pitched tinkling bowel sounds, coinciding with worsening of abdominal pain, are a sign of obstruction *not peritonitis*. 'Diminished' bowel sounds mean nothing specific!

(5) **The iliopsoas test** is only indicated if the patient is not very ill, and does not have generalized peritonitis. Get him

to lie on the opposite side to where the pain is, and extend the thigh on the affected side to its fullest extent. If this is painful, there is some inflammatory lesion near the psoas muscle (appendix abscess, iliac abscess, pyomyositis of the iliopsoas). *This test is not useful if the anterior abdominal wall is rigid.*

(6) **The obturator test.** If rotating the flexed thigh so as to stretch this muscle causes pain, there is pus or perhaps a haematocoele (in a woman) in contact with the surface of the *obturator internus*.

(7) **The thoracic percussion test.** Percuss gently with your fist over the lower chest wall. On the right, a sharp pain indicates an inflammation around the diaphragm or liver (often present in acute hepatitis); on the left, inflammation around the diaphragm, spleen, or stomach.

(8) **Percuss for liver dullness** in the right nipple line from the 5th rib to below the costal margin. If liver dullness is absent, there is probably free gas in the abdominal cavity.

(9) **Don't forget the hernial orifices.** Feel both femoral and inguinal openings, the umbilicus, and any old incisions.

THREE SIGNS

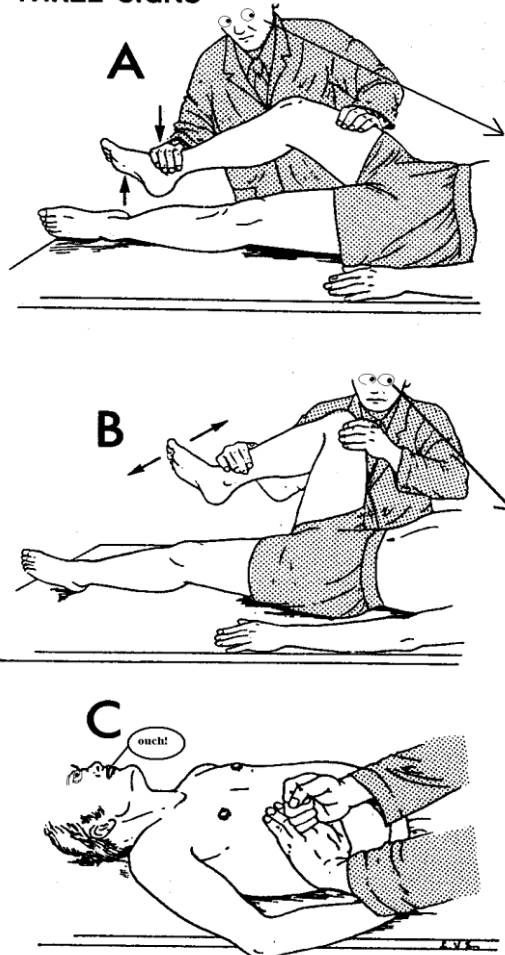


Fig. 10-2 THREE SIGNS.

A, iliopsoas test. Ask the patient to flex the hip against the resistance of your hand. If he feels pain, there is inflammation in relation to the psoas muscle. B, obturator test. Flex the hip to 90° and gently rotate it internally and externally. If this causes pain, there is inflammation in relation to the obturator muscle. C, fist percussion test. Percuss gently with your fist over the chest wall. On the right, a sharp pain indicates an inflammatory lesion of the diaphragm or liver; on the left, one of the diaphragm, spleen, or stomach. *Kindly contributed by Jack Lange.*

CAUTION!

- (i) An obstructed hernia is usually tense, tender, or painful but does not have to be so.
- (ii) It may be small, especially if it is a femoral hernia, <2cm diameter.
- (iii) The patient may be quite unaware of it.
- (iv) *Femoral hernias are very easy to miss in fat patients.*
- (v) *Don't overlook a small umbilical hernia lying deep in fat, or think a lump is not a hernia because the symptoms are not very acute.*
- (vi) Ask if the hernia has not been pushed back in recently: there may be obstruction from 'reduction en masse', i.e. without relief of strangulation.
- (vii) In a baby, it is not the bulging inguinal hernia which will strangulate, but the small slim one containing only a thin loop of the tiny bowel. It may only feel like slightly thickened cord and testicle, with reddening and oedema of the scrotal skin (18.5).

(10) **The pelvis** is just as important as the abdomen. You will find a vaginal examination often more useful than a rectal examination (except in a child). Do both. *Never forget to examine the rectum.* Lay the patient in the lateral position. Pass a well-lubricated finger as far up the anal canal as it will go. Feel for tenderness in all directions. Feel forwards, in a man for an enlarged prostate, a distended bladder, or enlarged seminal vesicles; and in a woman for swellings in the pouch of Douglas or displacements of the uterus. Feel upwards for a stricture, the apex of an intussusception, or the bulging of an abscess against the rectal wall. Feel laterally for the tenderness of an inflamed swollen appendix. Feel bimanually for a pelvic tumour or swelling, or for any fullness in the pouch of Douglas. Look if there is blood or mucus on your glove afterwards.

OTHER SYSTEMS

Don't forget to listen to the chest; there might be a basal pneumonia, pleural effusion or empyema. Examine the spine (spinal tuberculosis or a tumour can cause root pain felt in the abdomen). Feel for a stiff neck (meningitis can cause vomiting and abdominal pain). Look at the testes to exclude torsion.

SPECIAL TESTS

Get a full blood count: *N.B. in untreated HIV+ve patients, the white count may not be raised even in severe peritonitis.* Check the blood or urine for sugar, red cells and white cells. Check urea and electrolytes if there is dehydration or the urine output is poor, if you can, and the amylase if you suspect pancreatitis. If there is septicaemia, do blood cultures and check the clotting time. If the albumin is very low, this is a bad sign.

ULTRASOUND is possible at the bedside, and is the investigation of choice: it will show fluid accumulation and tissue necrosis, and usually allows immediate aspiration of pus, proving the diagnosis and providing a specimen for bacteriological examination.

Occasionally you can remove all the pus in an abscess by means of aspiration; this is more reliable, however, if you can position the tube for drainage and irrigation under ultrasound control.

You can also diagnose free fluid, recognize para-aortic lymphadenopathy, ectopic gestation, abdominal masses, and note any inflamed thickened structures, as well as an aneurysm. *However, beware of trying to diagnose appendicitis exclusively by ultrasound! Note, also, that an ultrasound will not easily show if an aneurysm has ruptured.*

RADIOGRAPHS must be good, because you are interested in the disposition and pattern of gas. Be selective, and look at the films yourself. *There is no point in ordering radiographs (except of the chest) if you have already made a diagnosis of peritonitis and have decided to operate.* An erect chest film is best to see gas under the left hemidiaphragm (and also to look at the condition of the lungs). It may also show a pleural effusion or empyema.

If the patient is too sick to sit up, you may see free gas under the abdominal wall in a lateral decubitus film of the abdomen.

Signs on abdominal films (erect and supine) are subtle:

- (1) Air in the small bowel: this is always abnormal except in a child <2yrs. You may see gas *both inside and outside* the bowel wall, though (Rigler's sign, which is a sign of bowel perforation), and air on the lateral border of the liver, outlining its edge clearly.
- (2) Displacement of the colon: a ruptured spleen may displace the shadow of the splenic flexure downwards and medially.
- (3) Obliteration of the psoas shadow: this can be caused by pyomyositis of the psoas, a psoas abscess from a tuberculous spine, a retroperitoneal abscess or by bleeding from an injured kidney.
- (4) Multiple small bowel fluid levels, identical in radiographic appearance to small bowel obstruction: occurs in longstanding paralytic ileus.
- (5) Urinary calculi: look for these along the lines joining the tips of the transverse processes of the vertebrae to the sacroiliac joints.
- (6) A faecolith in the area of the appendix, when there are good symptoms and signs of appendicitis, confirms the diagnosis.
- (7) Gas in the portal vein (you see the outline of the veins *peripherally* in the liver: from mesenteric ischaemia, portal pyaemia, or severe colitis (*this is a real danger sign*)).
- (8) Gas within the wall of the bowel or the gallbladder (this implies necrosis or ischaemia).

CAUTION! There may still be a perforation without gas under the diaphragm (especially early on), and in closed bowel obstruction with strangulation, there may be no fluid levels.

LAPAROSCOPY. If you cannot make a diagnosis, think of using a laparoscope (19.5) to help.

Don't rely on the findings unless you are very experienced with this technique. You may easily miss some relevant pathology. On the other hand, you may, having initiated an operation under GA, be persuaded unnecessarily to remove a normal appendix.

A. GENERALIZED PERITONITIS

DISEASES WHICH MAY PRESENT AS A SURGICAL ABDOMEN

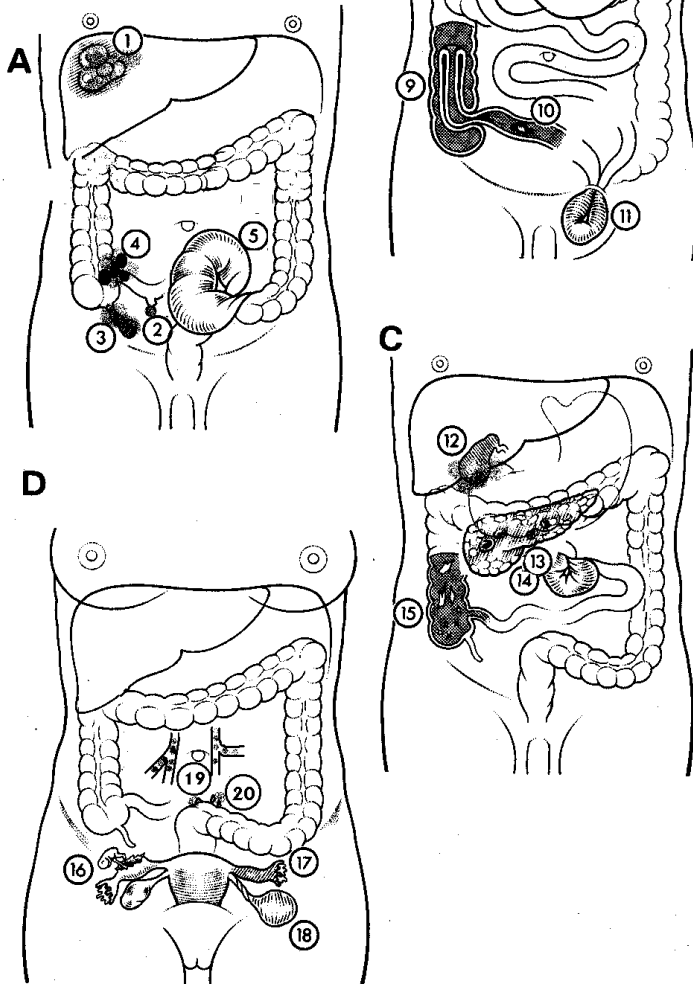


Fig. 10-3 DISEASES WHICH MAY CAUSE PERITONITIS.

A, (1) liver abscess. (2) perforation of Meckel's diverticulum. (3) appendicitis. (4) ileocaecal tuberculosis. (5) sigmoid volvulus. B, (6) perforated duodenal ulcer. (7) perforated gastric ulcer. (8) ruptured spleen. (9) intussusception. (10) perforation of terminal ileum (typhoid or HIV). (11) strangulated groin hernia. C, (12) empyema of gallbladder. (13) pancreatitis. (14) volvulus of the small bowel. (15) amoebic colitis. D, (16) rupture of an ectopic gestation. (17) PID. (18) torsion of an ovarian cyst. (19) mesenteric thrombosis. (20) diverticulitis.

DIAGNOSING PERITONITIS

How are you going to diagnose all the many causes of peritonitis, if the pattern of the symptoms they produce is so similar? Here is a checklist of the more important features of each to help you sort them out, in order of their frequency.

As is usual in medicine, a patient is more likely to have a rare presentation of a common disease, than a common presentation of a rare one. Be familiar with the pattern in your own area. "Common things are common, and most people get what most people get." If you think there is peritonitis, but are not sure, the list below may help you.

Don't be frightened by its length.

Concentrate on the *pattern* of symptoms and signs.

CLUES TO THE DIAGNOSIS OF PERITONITIS

(the diagnoses are listed in general order of frequency):

CENTRAL ABDOMINAL PAIN:

- Small bowel obstruction/strangulation (12.3)
- Appendicitis (14.1)
- Acute pancreatitis (15.13)
- Primary or tuberculous peritonitis (16.1)
- Colitis
- Necrotizing enterocolitis (14.4)
- Bleeding intestinal Kaposi sarcoma (5.6)

CENTRAL ABDOMINAL PAIN AND SHOCK:

- Ruptured ectopic gestation (20.6)
- Perforation of small bowel (14.3)
- Small bowel volvulus (12.8)
- Acute haemorrhagic pancreatitis (15.13)
- Mesenteric thrombosis (12.14)
- Dissecting/leaking aortic aneurysm (35.8)

CENTRAL ABDOMINAL PAIN AND SHOCK, AND RIGIDITY:

- Perforated peptic ulcer (13.3)
- Perforated small bowel (14.3)
- Perforated gall bladder (15.4)
- Ruptured oesophagus (30.7)

LOCALIZED PAIN AND TENDERNESS

(the causes depend on where these are found):

In the right hypochondrium:

- Leaking duodenal ulcer (13.3)
- Liver abscess (15.10)
- Acute cholecystitis (15.3)
- Empyema of gallbladder (15.4)
- Amoebiasis (14.5)

In the epigastrium:

- Leaking duodenal ulcer (13.3)
- Acute pancreatitis (15.13)

In the left hypochondrium:

- Splenic infarct of sickle cell disease (15.17)
- Ruptured spleen
- Leaking gastric ulcer (13.3)

In the right iliac fossa:

- Acute appendicitis (14.1)
- PID (23.1)
- Ascaris* mass (12.5)
- Ileocaecal TB (16.6)
- Chronic ectopic gestation (20.7)
- Torsion ovarian cyst (23.9) or testis (27.25)
- Amoebiasis* (14.5)
- Typhoid (14.3)
- Iliopsoas abscess (6.16)
- Angiostrongyliasis* and *oesophagostomiasis*
- Actinomyces*

In the hypogastrium:

- Septic uterus after delivery (22.14)
- Pelvic abscess (10.3)
- Cystitis (27.36)

In the left iliac fossa:

- PID (23.1)
- Intussusception and strangulation (12.7)
- Chronic ectopic gestation (20.7)
- Torsion ovarian cyst (23.9) or testis (27.25)
- Diverticulitis (14.2)

In both iliac fossae:

- Septic miscarriage (23.2)
- Puerperal sepsis (22.14)

In the abdominal wall:

- Pyomyositis (7.1)
- Necrotizing fasciitis (6.23)
- Haematoma

RENAL CONDITIONS can sometimes present as an acute abdomen.

Renal colic produces a sharp severe colicky pain spreading from the loin down to the groin, vomiting, a vague diffuse tenderness in the flank. Reflex intestinal ileus is not uncommon (27.13).

Pyonephrosis or retroperitoneal abscess produces a high fever, pain in the costovertebral angle, a tender enlarged loin mass, often with toxæmia (6.15).

SOME MEDICAL CONDITIONS MIMICKING AN ACUTE ABDOMEN

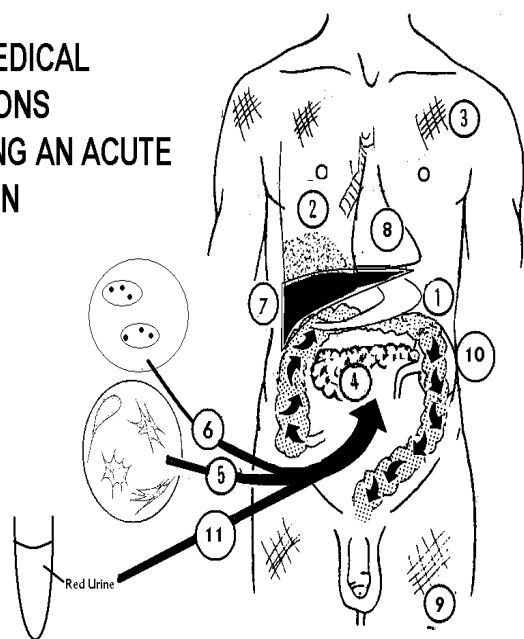


Fig. 10-4 SOME MEDICAL DISEASES MIMICKING AN ACUTE ABDOMEN.

(1) acute gastroenteritis and gastritis. (2) basal pneumonia and pleurisy. (3) viral myalgia. (4) diabetic precoma. (5) sickle cell crisis. (6) malaria. (7) chlamydial perihepatitis. (8) myocardial infarction. (9) brucellosis. (10) uraemia. (11) porphyria.

SOME MEDICAL DISEASES may mimic an acute abdomen. In most of them the fever is higher, the general symptoms worse, and the abdominal symptoms less evident than in the surgical acute abdomen. But *beware of peritonitis when the patient is so ill that the general signs predominate over local surgical signs.*

(1) **Acute gastroenteritis:** diarrhoea, vomiting and fever, colicky pains, minimal abdominal tenderness, hyperactive (but not obstructive) bowel sounds, fever early, perhaps with rigors.

(2) **Acute gastritis:** copious vomiting, severe epigastric pain doubling up the patient, usually associated with *helicobacter*, an alcoholic binge or dietary indiscretion. This is particularly common in the Caribbean after ingestion of *Ciguatela* fish.

(3) **Basal pneumonia and pleurisy:** early high fever, cough, rapid breathing, spasm of the upper abdominal muscles, and tenderness. Signs of consolidation on chest radiography, usually in the right lower lobe. Abdominal pain and rigidity may be very marked in a child, and involve the whole of the upper half of the abdomen, or the whole of one side.

(4) **Chlamydial perihepatitis** (Curtis-FitzHugh syndrome): pain in the right upper quadrant, and vaginal discharge.

(5) **HELLP syndrome** (haemolysis, leucocytosis and low platelets) in pre-term pregnancy, often associated with pre-eclampsia, may cause stretching of the liver capsule and so pain in the right hypochondrium.

(6) **Viral myalgia** (Bornholm disease): sudden onset with high fever, local or general abdominal and chest pain; marked superficial muscle tenderness and rigidity of variable intensity, quickly changing its position; tender intercostal muscles on one or both sides; lateral compression of the chest is painful; nausea but seldom vomiting, no chest signs. Often during an epidemic of 'flu'.
(7) **Diabetic precoma:** slow onset of abdominal pain and vomiting, dehydration, sugar and ketone bodies in the urine and breath.

(8) **Sickle cell crisis** caused by a hypoxic trigger factor (such as a chest infection): vomiting, central abdominal pain, guarding frequently, rigidity sometimes, sickle test +ve, with headache, a high fever, and pains in multiple sites, especially the limbs and back. Bowel sounds remain present.

(9) **Myocardial infarction:** sudden collapse with hypotension, sweating, chest and left arm pain especially in a smoker classically associated with ECG changes of ST depression.

(10) **Malaria** may cause diarrhoea, vomiting and abdominal pain; fever is usually present; look for splenomegaly.

(11) **Uraemia** may simulate ileus by causing abdominal distension and vomiting. The signs and the history are vague and variable.

(12) **Porphyria** is a hereditary condition found in specific areas (*e.g.* Ethiopia, Ghana, South Africa) often made worse by drinking alcohol, by anaesthetics (*e.g.* thiopentone) or sulphur drugs, where the urine goes red and sun-exposed skin blisters; abdominal pain is not associated with rigidity, but with emotional outbursts and polyneuropathy.

(13) **Brucellosis:** fever, headache, fatigue, bone and joint pains in herders of goats and sheep. Gastrointestinal symptoms are variable.

(14) **Polyserositis** is one of a number of rare familial conditions (typically found around the Mediterranean) which presents with fever and peritonitis. You may only diagnose this after you have done a laparotomy and found no obvious cause! The best treatment is with colchicines.

(15) **Angio-oedema** is an allergic reaction (usually with prodromal minor episodes of swelling of lips, ears or throat) which can cause intestinal oedema. If associated with

urticaria and itching, you can use adrenaline and salbutamol to reduce the oedema. *Beware! Surgery may precipitate an even worse reaction resulting in death by asphyxia.*

(16) **Snake bites**, particularly krait in India, may not cause local pain, but give rise to severe cramps before producing neurotoxic effects.

DIFFICULTIES DIAGNOSING PERITONITIS

If you are in any doubt about the diagnosis when you first see a patient, admit him. *Then come back repeatedly to re-examine him*, feel the abdomen and monitor him carefully, if necessary every hour. He will be easier to assess in the ward than in the outpatient or casualty department. You are also likely to get a more reliable reading of the pulse and temperature. This is especially important if you suspect strangulated bowel, appendicitis, or a peptic ulcer. The diagnostic use of a single opioid dose may be helpful: if he feels much better after one dose of opioid and no longer has any signs of peritoneal irritation, it is very unlikely that anything serious is going on. This is very useful if you think he might be hysterical. There is a small chance it is the Münchhausen syndrome (exhibited by a clever group of patients, including medical personnel, who persistently fake their symptoms).

Decide if he needs an operation, and if so, when? However, if he is no better, or in fact worse, peritonitis is likely. *If he deteriorates, operate. Don't leave a patient like this if you hand over to a colleague without giving a very clear picture of his condition.* This is where recording of your findings is most important. Often, when you have made the diagnosis, all you will know before you operate is that there is peritonitis, without knowing why. Try to establish how advanced it is from the history and the signs. A laparotomy is usually mandatory and even if you are in doubt, *most patients who are young will not suffer untowardly from a negative laparotomy, but they will die from neglected abdominal sepsis.*

BETTER A SCAR ON THE ABDOMEN THAN A SCAR ON YOUR CONSCIENCE

As you will see below, there are some special indications for non-operative treatment. However, if you are uncertain about these in a particular case, it is wiser to operate than not to do so. It is more important to decide when to operate and when not to operate, than the exact diagnosis.

"If in doubt, it is better to look and see than to wait and see."

But, *don't operate if the only symptom is pain and there are no abnormal signs, radiographs and lab results whatsoever.*

N.B. Don't delay operation on a pregnant woman with peritonitis because you fear for premature delivery. The need to act quickly is even more vital: if you delay, the toxæmia may well kill the baby, or even the mother!

INDICATIONS FOR OPERATION, *after adequate resuscitation*, are:

- (1) Diagnosis of peritonitis.
- (2) Diagnosis uncertain, and condition deteriorating after 4h of active management.
- (3) Diagnosis uncertain after a routine laparotomy, but signs suggestive of peritonitis or condition deteriorating.

INDICATIONS FOR DRAINAGE:

- (1) Localized collections of pus identified by ultrasound.
- (2) Pelvic abscess (10.3).

INDICATIONS FOR NON-OPERATIVE TREATMENT:

- (1) Acute pancreatitis (15.13).
- (2) Acute cholecystitis (15.2).
- (3) Abdominal mass with resolving peritoneal irritation.
- (4) A typhoid perforation of slow onset showing no signs of deterioration (14.3).
- (5) Necrotizing enterocolitis (14.4).
- (6) Medical conditions giving rise to abdominal pain.

N.B. Note that in these medical causes of an acute abdomen, there is rarely abdominal guarding present.

RESUSCITATION. The need for this varies:

If the pulse is rapid, there is postural hypotension and especially if the blood pressure is low, delay operation for a few hours (preferably $\leq 4h$) for proper resuscitation. Use Ringer's lactate or 0.9% saline IV (provide an adult 1L per day of illness). Be sure to correct potassium deficiency. If possible, measure the CVP and keep it at 6-8cm of water. Pass a nasogastric tube and *don't allow oral intake*. Monitor the urine output hourly and keep a fluid balance chart. Catheterize the bladder. Start gentamicin, chloramphenicol or a cephalosporin and metronidazole. (*Note gentamicin may prolong activity of relaxants, and is a hazard in renal impairment.*) Improve hypoxia by administering oxygen by a mask. Operate as soon as the pulse rate falls, the blood pressure rises, and the peripheral circulation improves. Resuscitation should not take $>6h$.

If the CVP remains low, continue rapid intravenous fluid infusion! *If signs of peripheral circulatory failure don't respond to generous resuscitation, death may occur despite all your efforts.* Dopamine and noradrenaline infusions need ICU care.

If there is confusion, severe hypotension, and hyperventilation, with a fast pulse, and warm pink extremities, or cold clammy ones, this is septic shock. The patient may be so sick that you should do the minimum just to save his life while you proceed with resuscitation and antibiotics. This is the so-called '**damage control laparotomy**'. If you can, drain the septic focus. Timing is important: the patient must be fit enough to withstand the operation, so overcome shock, and then do the simplest possible operation.

THE PERITONEAL CAVITY

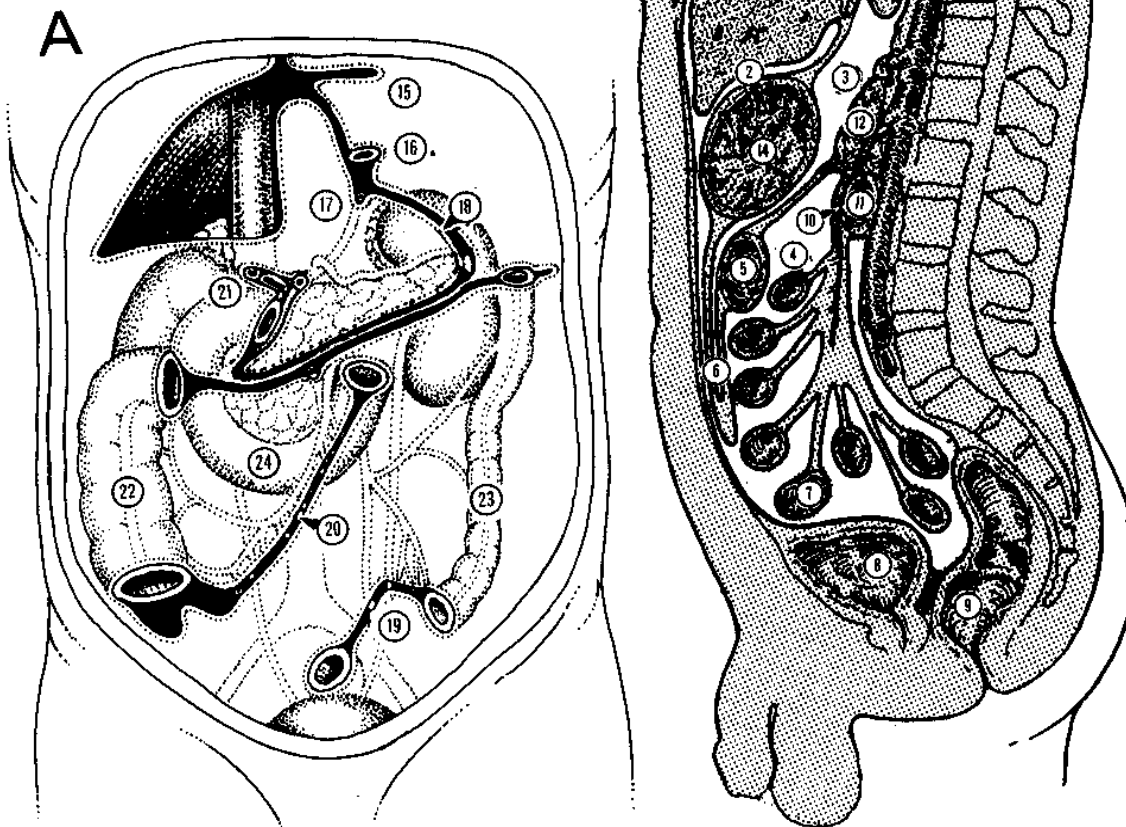


Fig. 10-5 THE ABDOMINAL CAVITY in generalized peritonitis fills with pus. **A**, posterior abdominal wall showing the lines of peritoneal reflection after removal of the liver, spleen, stomach, jejunum, ileum, and the transverse and sigmoid colon. Organs on the back of the abdominal wall are seen through the posterior parietal peritoneum. **B**, longitudinal section of the abdomen: (1) anterior superior subphrenic space. (2) subhepatic space. (3) lesser sac. (4) coils of jejunum. (5) transverse colon. (6) greater omentum. (7) coils of ileum. (8) bladder. (9) rectum. (10) mesenteric artery. (11) duodenum. (12) pancreas. (13) liver. (14) stomach. (15) left triangular ligament of the liver. (16) oesophagus. (17) upper recess of the omental bursa (lesser sac). (18) lienorenal ligament. (19) root of the sigmoid colon. (20) root of the mesentery. (21) cut edge of the lesser omentum. (22) ascending colon. (23) descending colon. (24) duodenum.

This may be just inserting drains into the flanks under LA, to allow pus to drain and give you the opportunity to wash out the abdomen. The condition may then improve sufficiently to perform a laparotomy much more safely later.

LAPAROTOMY FOR PERITONITIS (GRADE 3.2)

PREPARATION. This is very important: check everything is ready (11.1-2).

PHILOSOPHY. The primary objective of the operation is to remove all dead tissue (necrosis, pus, clots, fibrin, faeces etc), to clean the abdominal cavity and to prevent leakage and further accumulation of noxious materials. *Repair of intra-abdominal anatomy and of the abdominal wall are desirable but not the primary objectives of the emergency operation.*

INCISION

As soon as the patient is draped and anaesthetized, and the abdomen is relaxed, *palpate it*. A mass may appear under GA which was quite impalpable before! Make a midline incision or, particularly in children, a transverse incision. If there is already an incision, go through this if it gives you good enough access. It is usually best to cut out the previous scar.

ENTERING THE ABDOMEN

Aim quickly to discover what is wrong: *this may not be obvious*. Be careful and observant, learn to recognize what you see, and search thoroughly.

SMELL can tell you a lot. If a puff of gas greets you as you open the peritoneum, the bowel has probably perforated. In advanced sepsis, especially from the pelvis, a bad smell may be from gas-forming organisms.

If there is an abnormal smell, it may be:

- (1) acrid (perforated peptic or typhoid ulcer),
- (2) faeculent (ruptured large bowel),
- (3) characteristic of anaerobes (suppurative appendicitis),
- (4) putrid (gynaecological sepsis), or
- (5) urine (from an intraperitoneal rupture of the bladder).

LOOK FOR FLUID in the abdominal cavity, which may be:

- (1) **purulent fluid of various thickness**
(appendicitis, salpingitis, perforated peptic ulcer, primary peritonitis, mesenteric adenitis, including tuberculous, diverticulitis)
- (2) **foul, turbid brown fluid**
(peritonitis from appendicitis or sigmoid volvulus, ruptured ovarian cyst, ruptured liver abscess)
- (3) **blood**
(ectopic gestation, injured liver, spleen, or mesentery, ruptured ovarian lutein cyst)
- (4) **pale straw-coloured fluid**
(intestinal obstruction without strangulation, mesenteric adenitis, tuberculous ascites, cirrhosis)
- (5) **blood-stained**
(ischaemic bowel, torsion of ovarian cyst, streptococcal peritonitis, acute pancreatitis)
- (6) **bile-tinged**
(perforated stomach, duodenum or small bowel)
- (7) **frank bile**
(ruptured gallbladder, injured liver)
- (8) **watery, reddish-brown, offensive fluid**
(strangulation with incipient gangrene)
- (9) **clear colourless fluid**
(ruptured hydatid cyst)
- (10) **porridge-like material**
(ruptured dermoid cyst)
- (11) **sticky mucous fluid**
(ruptured ovarian cyst)
- (12) **urine**
(ruptured bladder, divided ureter)

If there is any exudate, send it for culture, if you can.

If the peritoneum is fiery red with flakes of fibrinous exudate, this is severe peritonitis. If these flakes are clear or nodular, they are probably due to tuberculosis. Firmer nodules are from metastatic carcinoma. Fatty flakes, which may look very much like tuberculosis, are from severe pancreatitis.

BREAK DOWN ADHESIONS with the greatest possible care. Break down light ones with your fingers. If they are dense, define them carefully, and cut them with scissors. If you are rough, you may drastically worsen the peritonitis by adding more organisms to the bacterial soup already present *and* you increase the chances of a faecal fistula, which may be a disaster.

If you do make a hole in the bowel, isolate and cover it with a swab, clamp the bowel either side of the hole with non-crushing bowel clamps, and carry on. *Don't waste time at this stage by repairing the perforation*: do this after you have freed all the bowel.

You may need to sacrifice an impossibly matted segment of bowel (11.3): this is better than causing a lot of bleeding trying to free it and using up a great deal of time with a sick patient on the operating table. When faced with bowel that is very stuck, approach it from a normal segment on both sides, and try to massage bowel content out of the affected segment and hold it empty between non-crushing bowel clamps. If then you do perforate it, you won't spill its contents.

Pack away the rest of the abdomen with swabs, so if you do spill content, you contaminate the peritoneal cavity as little as possible. Always lift up bowel from behind with your fingers, *never pull it!* If a loop is hopelessly stuck in the pelvis where you can't see it properly, you may be able to pinch it off and, whilst still holding the bowel wall tight in your fingers, deliver it out of the abdomen. This way, although you will certainly have to repair the perforation (11-5) or resect that piece, you will have avoided spilling bowel contents in an uncontrolled manner. Occasionally, you will be able to lift a whole clump of bowel out of the abdomen, and be able to work on it outside, whilst packing away the rest of the incision.

If thickened oedematous omentum is adherent to something, it points to the site of acute inflammation, strangulation (12.2), or abscess formation (14.1,2). *Take care you don't damage a viscus by pulling off the omentum*: this may actually be sealing off a perforation. Think carefully if it is best left alone; if necessary, cut away the omentum with the damaged viscus.

MINIMIZE THE RISK OF SEPSIS

- (1) If you have to open a hollow organ, or a septic collection, pack the abdominal cavity round it with moist swabs. If it is walled off from the rest of the abdominal cavity and this is unaffected by sepsis, just drain it and leave the remaining abdomen alone or you will spread infection into a clean peritoneal area.
- (2) Handle an inflammatory mass carefully: *don't let it burst and discharge pus everywhere*.
- (3) If an area does become contaminated, wash it out.
- (4) *Insert drains only when indicated* (4.9).

DECOMPRESS THE BOWEL (12.4) because this will:

- (1) give you a better view to see what you need to do next,
- (2) reduce the risk of rupturing the bowel if its wall is thin,
- (3) help you close the abdomen at the end of the operation, and reduce the risk of the *abdominal compartment syndrome* (11.10),
- (4) greatly reduce the risk of post-operative vomiting and aspiration,
- (5) reduce the risk of any bowel leaking by reducing the volume of fluid passing any anastomosis you make.

N.B. Generalized peritonitis, particularly of some days' duration, will always have distended loops of bowel present.

If the bowel is already open, suck its contents out through the perforation using either a Poole's or Savage sucker; or else, mobilize the bowel out of the abdominal cavity, and drain the contents into a bowl holding the open bowel end with Babcock's forceps.

This is messy, but as long as you take care to avoid spillage of contents into the abdominal cavity, it is extremely worthwhile.

If the bowel is not open, you can decompress its content either by (a) massaging contents proximally towards the stomach and suctioning via a wide-bore nasogastric tube, or (b) clamping an appropriate segment of bowel, making a small hole on the anti-mesenteric border of the bowel, and decompressing it through that, as above.

Do (a) if the bowel distension is relatively slight, you have good suction and an experienced anaesthetist who knows how to suction the mouth if there is spillage there.

Do (b) if there is serious bowel distension with thick bowel content, your suction machine is unreliable, the anaesthetist is inexperienced, or the patient is *a child with an uncuffed endotracheal tube*. You may hesitate to open bowel if it is not already opened. Do so, if otherwise closure of the abdomen would in any way be difficult: the advantages far outweigh the disadvantages!

EXAMINE THE ABDOMINAL CAVITY

If peritonitis is widespread, search systematically until you can find its cause. You should know where this might be from:

- (1) The history.
- (2) The nature of the exudate.
- (3) The place where pus and exudate are most intense.
- (4) The density of the adhesions; the densest ones may indicate the origin of the infection.

CAUTION!

- (1) Suck out all free pus before you start.
- (2) You must have good exposure.
- (3) If you find localized pus, try to minimize its spread around the peritoneum!
- (4) You face the dilemma described above: when to divide adhesions and when not to.

Inspect the abdominal cavity thoroughly, unless you are certain from the onset that sepsis is localized to one area. Inspection of the entire cavity may be difficult because of adhesions. All necrotic tissue must be removed; this may entail resection of bowel.

You need:

- (1) adequate exposure: make the incision big enough,
- (2) a good light focused in the right place: get assistance or use a head-light,
- (3) good retraction: you can't operate on your own,
- (4) a good view: position the patient in the best way, *e.g.* Trendelenburg for pelvic sepsis, and pack away the bowels (*but count the packs and don't forget them inside at the end of the operation!*).

MANAGING THE UNDERLYING CAUSE

First, you will have to find it, *and this may not be easy*. Let the smell and nature of the fluid guide you. Go first for your pre-operative diagnosis. Look for signs of inflammation (pus or adhesions), of perforation, or tumour.

If you are faced with something you are not sure how to handle, unscrub and refer to this text, or get an assistant to do so: *you don't need to pretend you know it all!* For this reason, keep this book *in theatre!*

Some places are difficult to see. If the source of sepsis is not obvious, look: in the lesser sac, under the liver, behind the duodenum (mobilize it using the Kocher manoeuvre, 13.5), and behind the colon (especially both flexures) and rectum. Play safe: the patient is desperately sick, and *you must not risk complications*. Remember '*damage control laparotomy*'. The decision how to proceed depends on the condition.

If the patient is still in shock, is hypothermic, acidotic or has signs of coagulopathy, terminate the operation in the most expeditious way. This may entail the sealing of all holes or intestinal ends by using, for instance, umbilical tapes and leaving the abdomen open. *Physiology takes precedence over anatomy*. The best place to correct physiology is the ICU. Try to finish emergency surgery within 45mins.

N.B. Don't remove the appendix 'prophylactically'.

LAVAGE

If there is generalized peritonitis, lavage the abdominal cavity.

If the peritonitis is localized, pack off the affected area and then lavage or mop out the infected space. Sometimes, you can safely wash out only the pelvis.

Tip in several litres of *warm (c.30°C)* fluid, slosh it around with your hand, and suck it out until the fluid which returns is clear. You may need 8-10L; usually 3-4L are enough. Wash out the upper abdomen, the sub-diaphragmatic and sub-hepatic spaces, the paracolic gutters, the infracolic area, between all the loops of bowel and the pelvis. *You don't need to use saline*: 10L of warm sterile water is preferable to 500ml of saline!

If there is much adherent septic fibrin on the bowel, liver, spleen and omentum, only peel away the parts that come away easily. Otherwise you may damage the viscera or bowel, simply in a vain attempt to make the abdomen look clean!

DRAINS. You cannot drain generalized peritonitis and multiple intra-abdominal collections, because the area to be drained is too large and the drains block anyway: so, wash out the pus vigorously. It may, however, be appropriate to drain a retroperitoneal collection, *e.g.* in the pelvis (vaginally in a female, or rectally in a male) using a Penrose drain (4.9).

Drains have limited use (11.8): if you do use them, insert a soft tube drain with several perforations cut in it on low suction, and irrigate it with liquid to keep it open.

Place the drain away from bowel and vessels, protecting these with omentum; bring it out away from a wound by the shortest route.

If the intra-abdominal tension remains high, *don't attempt to close the abdomen!*

Leave the abdomen open as a laparostomy (11.10) if:

- (1) you expect to have to look inside again within 48h, e.g. if you are uncertain about an anastomosis, or the vascularity of bowel, or if you had to leave a pack inside, or if you have limited your intervention because of severe metabolic disturbance (damage control),
- (2) there is gross faecal soiling or sepsis requiring repeated lavage,
- (3) there are multiple bowel fistulae,
- (4) there is severe haemorrhagic necrotizing pancreatitis,
- (5) there is more tissue necrosis which you were unable to remove,
- (6) you simply cannot close the abdomen without tension.

N.B. Your hands may smelly horribly after cleaning out a septic abdomen, even wearing 2 pairs of gloves: no amount of soap or perfume will remove the odour, but washing with coffee will!

CLOSURE. Confirm all the routine checks are done (1.8). Then, *not before*, close the abdomen with continuous through-and-through sutures of stout monofilament nylon, polydioxanone, poliglecaprone or steel deep to the skin (11.8). For skin, use subcuticular absorbable or nylon. *You should not have to pull the abdominal wall together with tight tension sutures!* Go back and decompress the bowel.

POST-OPERATIVE CARE AFTER LAPAROTOMY FOR PERITONITIS

N.B. The post-operative care is just as important as the operation itself!

Checklist:

- (1) **Nasogastric suction.** If there is generalized peritonitis, ileus is sure to follow; suction will reduce the distension, although it will not reduce its duration. You may suck out 2-6L fluid daily. Replace the fluid loss with IV 0.9% saline or Ringer's lactate in addition to the standard requirements.
- (2) **Intravenous fluids.** For maintenance an adult needs at least 3-4L in 24h: use 1-2L 0.9% saline, or Ringer's lactate, and 2L 5% dextrose in 24h.
- (3) **Bladder drainage.** You need to monitor the urine output (if possible 2hrly for the first 48h). Use a Paul's tubing (condom catheter) in a young male; remember catheterization is invasive and potentially hazardous.
- (4) **Fluid balance.** Keep an accurate fluid balance chart till the fluid balance is stable (at least for 48h, usually 3-6 days). The common error is to not infuse enough fluid and not chart the fluid input and output properly. If the initial fluid resuscitation was inadequate, there may still be a deficit to make up. Infuse sufficient IV fluids to keep the urine output >1ml/kg/hr.
- (5) **Potassium supplements.** *Don't forget these*, especially if there is a large volume of gastric aspirate. Start them when the post-operative diuresis begins.
- (6) **Blood.** If there was major blood loss during the operation (>2L), especially if previously anaemic and this loss was not replaced, check the Hb level; if it is <80g/L, transfuse 2 units of blood.
- (7) **Acidosis.** There are several ways you can correct this:

(i) Treat with 200ml of 8.4% sodium bicarbonate (200mmol), or with 500ml of 4.2% sodium bicarbonate (250mmol).

(ii) Treat with 11 1/6 molar lactate.

(iii) Infuse adequate IV fluids and let the kidneys correct the acidosis.

If the condition is poor, use (i) or (ii), and repeat daily.

(8) **Antibiotics.** If there was generalized peritonitis, continue the same antibiotics you used pre-operatively for 3-5 days. Look at the clinical response, rather than by the sensitivities reported by the laboratory. If there is no improvement after 2 days, consider re-laparotomy rather than changing the antibiotics.

(9) **Chest exercises.** Patients after laparotomy, especially for peritonitis, tend to have shallow respiration. To prevent pneumonia, provide adequate amounts of analgesics and encourage deep breathing exercises with physiotherapy. Serious cases need mechanical ventilation. As soon as you can, get the patient out of bed.

(10) **Mobilization.** Mobilize *early*, even from the 1st day post-op, to prevent thrombo-embolic and respiratory complications as well as bed sores (34.16).

OTHER MEASURES. Review the charts carefully each day for complications. Watch the temperature chart, the general state of alertness, the respiratory rate, the abdominal girth, the bowel sounds, the urine output and ask whether the patient passed flatus or stools. Start feeding early. Look if the wound is soiled or smelly.

POST-OPERATIVE COMPLICATIONS are many, and may occur after any laparotomy (11.9,15); so be especially aware of:

- (1) Abdominal sepsis (may lead to septic shock).
- (2) Wound infection.
- (3) Urinary infection.
- (4) Pneumonia.
- (5) Malnourishment.

If there is NO IMPROVEMENT, there may be residual sepsis and you should arrange another (**'second-look'**) laparotomy. Intra-abdominal sepsis is an extremely difficult diagnosis to make, particularly post-operatively, and you will often wish you had made it earlier. *Be very gentle* because the bowel will be friable and oedematous: *don't use sharp dissection*. Direct your attention to the source of the problem, rather than randomly extracting loops of bowel and dividing adhesions unnecessarily. Re-open a patient with severe generalized peritonitis *routinely* after 48h to:

- (1) lavage residual sepsis,
 - (2) detect any missed pathology,
 - (3) examine the viability of the bowel,
 - (4) check bowel anastomoses for patency,
 - (5) check for walled off abscesses in all far and deep corners of the abdominal cavity,
 - (6) prevent abdominal compartment syndrome (where the intra-abdominal pressure is >20mm Hg) (11.10).
- In very severe cases, particularly where fistulae are present**, and to decompress the abdominal compartment, leave the abdomen open as a *laparostomy* (11.10).

If sepsis persists, a 3rd or even 4th laparotomy is necessary, but with diminishing chance of success. Remember to change the antibiotics you are using after the 2nd re-laparotomy.

If there is NO IMPROVEMENT but no sign of fever, there may be HIV disease: test for this because you need to know how far you are likely to succeed in this case. Make sure you don't fail to treat tuberculosis.

If the ABDOMEN DISTENDS and the volume of the gastric aspirate remains high (maybe with vomiting), either the normal short period of ileus is continuing, or the bowel is obstructing (12.15).

If there is pain, a fever and a leucocytosis, suspect leakage of a bowel anastomosis, iatrogenic or spontaneous bowel perforation in HIV. This is much more likely than bleeding inside the abdomen. *Don't hesitate to re-open the abdomen for a second look.*

If serous fluid discharges from the wound, dehiscence is imminent. *Don't wait for a complete 'burst abdomen'*; return to theatre for closure of any residual defect with interrupted sutures.

If the abdominal wound becomes infected and breaks down (11.13), inspect it bd. If there is localized redness only, treat with antibiotics, but when a discharge or abscess develops, remove sutures, open the wound generously, wash it and *pack* it daily with diluted betadine.

If fever persists, there may be a post-operative wound, chest or urinary infection, deep vein thrombosis or there is further intra-abdominal sepsis.

If there is a mass which was not present previously, get an abdominal radiograph: it may be a retained swab! With HIV there may be a fever without any specific known cause.

If there is diarrhoea, especially with the passage of mucus, suspect a pelvic abscess (10.3). This may be due to an anastomotic leak.

If bowel content discharges from the wound or a drain, this is a fistula (11.15). If this is upper small bowel fluid (thin yellow), it may produce disastrous fluid and electrolyte losses and severe wasting.

Divert the effluent if possible, especially by suction. However, if the bowel is not obstructed distally to the fistula, and the output is <500ml/day, it should close spontaneously. Use low-pressure suction to keep the fistula wound dry, and make sure feeding continues and you correct potassium losses.

Unless you can drain a localized septic collection in the abdomen properly under ultrasound guidance, perform a laparotomy with all the same requirements as for generalized peritonitis.

If you find the collection walled off, or extra-peritoneal, drain it without contaminating the rest of the abdominal cavity. *Don't try to drain it blind from the outside or via the rectum or vagina.*

B. LOCALIZED PERITONITIS

Localized septic collections (these are rarely true abscesses) in the abdominal cavity can be the result of:

- (1) Generalized peritonitis: they are one of its major complications.
- (2) Some primary focus of infection, such as appendicitis or salpingitis.
- (3) An abdominal injury in which the bowel was perforated or devitalized.
- (4) Infection of a residual haematoma.
- (5) Leaving a foreign body (e.g. a swab or faecolith) behind.
- (6) Peritoneal dialysis.
- (7) Any laparotomy.

Fever has a characteristic spiky pattern (10-8). Prostration with anorexia, weight loss, and a leucocytosis are the norm, but may not be if there is HIV. If loops of the bowel pass through the abscess, they may become obstructed, acutely or subacutely (12.3).

ABSCESSSES IN THE PERITONEAL CAVITY

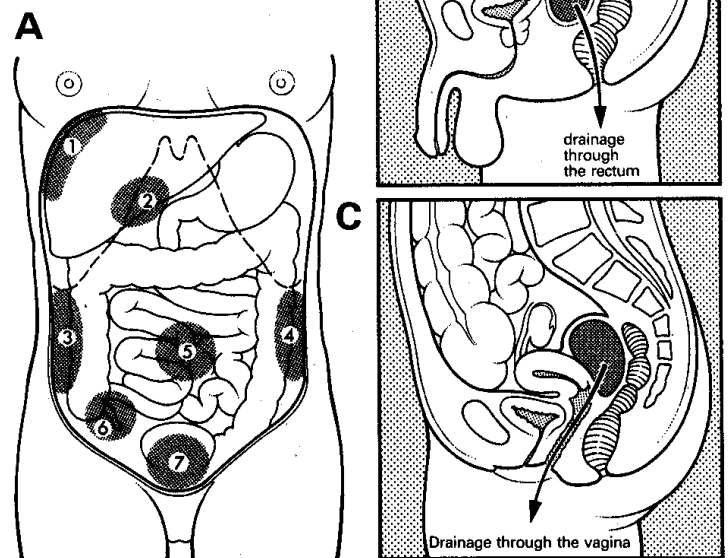


Fig. 10-6 SEPTIC COLLECTIONS IN THE ABDOMINAL CAVITY. A, common sites: (1) between the diaphragm and the liver. (2) under the liver. (3,4) in the right and left paracolic gutters. (5) among coils of the bowel. (6) around the appendix. (7) in the pelvis. B, pelvic abscess pointing into the rectum. C, pelvic abscess pointing into the vagina.

10.2 Subphrenic abscess

Pus under the diaphragm has usually spread there from somewhere else in the abdomen. A subphrenic abscess may be secondary to:

- (1) Peritonitis, either local or general, particularly following a perforated peptic (13.3) or a typhoid ulcer (14.3), or appendicitis (14.1), or PID (23.1) or infection following Caesarean section (21.13).
- (2) An injury which has ruptured a hollow viscus and contaminated the abdominal cavity.

- (3) A laparotomy during which the abdominal cavity was contaminated (10.1).
 (4) A ruptured liver abscess (15.10).

Suspect that there is a subphrenic abscess if there is a deterioration, or recovery followed by deterioration, 1-3wks after a laparotomy, with a low, slowly increasing, swinging fever, sweating, and tachycardia. This, and a leucocytosis (unless there is HIV disease), show that there is 'pus somewhere', which is causing anorexia, wasting, and ultimately cachexia. If there is no sign of a wound infection, a rectal examination is normal, and the abdomen is soft and relaxed, the pus is probably under the diaphragm.

The pus might be between the diaphragm and the liver, in the right or left subphrenic space, or under the liver in the right or left subhepatic space in the lesser sac. There may be pus in more than one of these spaces.

Ultrasound is easily the best tool to diagnose and drain such a collection of pus (38.2); if you can't do this, explore the abdomen on the suspicion that there might be a subphrenic abscess; the difficulty is knowing where to explore. If you fail to find pus, you will probably do no harm; missing a subphrenic abscess and doing nothing is far worse. If it is anterior, you can drain it by going under the costal margin anteriorly. If it is posterior, you can pass through the bed of the 12th rib posteriorly.

SIGNS AND SYMPTOMS

Thoracic signs are more useful than abdominal signs.

Ask or look for:

- (1) Cough.
- (2) Shoulder-tip pain on the affected side.
- (3) An increased respiratory rate, with shallow or grunting respiration.
- (4) Diminished or absent breath sounds.
- (5) Dullness to percussion.
- (6) Dull pain.
- (7) Hiccup (rare).
- (8) Tenderness over the 8th-11th ribs.

A subhepatic abscess may cause tenderness under the costal margin *anteriorly*. A subphrenic abscess, pyelonephritis, pyonephros or perinephric abscess can all cause similar tenderness *posteriorly*. If the patient is thin and the pus is superficial, you may feel a tender indurated mass under the costal margin in front (right subphrenic space), in the right flank (right subhepatic space), or posteriorly.

ULTRASOUND. A fluid collection is easily seen around the liver, which remains homogeneous in appearance (38.2b). You can use the ultrasound to guide you to drain the abscess.

CHEST RADIOGRAPHY will only be helpful to make the diagnosis if you can screen the diaphragms; you may find a pleural effusion, or collapse or consolidation at one lung base.

CAUTION!

- (1) The white count is usually raised but may be normal.
- (2) 10% of patients have no fever.
- (3) *Don't try to diagnose subphrenic abscesses blind by aspiration.* This is dangerous and misleading: do it with ultrasound guidance.

KIMANI (15yrs) was admitted with abdominal pain and vomiting of sudden onset, about 4h previously. He had shoulder-tip pain, but he also said he had pain when he put the tongue out, so it was first thought that he might be hysterical. He had no abdominal signs, so he was admitted for observation. The following day the abdomen started to distend, and aspiration of the abdominal cavity withdrew greenish fluid. A laparotomy was done, and an ulcer on the greater curve of the stomach was found and repaired. Initially he recovered well, but as he was about to go home 10 days later, he was not well, he ran a fever, he looked toxic, and there was tenderness and induration on the right side of the upper abdomen. He was suspected of having a subphrenic abscess, the abdomen was reopened through a midline incision, and a large quantity of foul-smelling pus was evacuated from under the right side of the liver, after which he eventually recovered.

LESSONS (1) If you are not certain that a patient is hysterical, it always pays to observe him. (2) Beware of the 'latent interval' 3-6h after a perforation, when there may be few abdominal signs. (3) Use the ultrasound if you have one to make the diagnosis. (4) You may be able to drain a subphrenic abscess through the original laparotomy incision, but the incisions described below may be better. (5) When a peptic ulcer causes general peritonitis, a thorough lavage of the abdominal cavity is as important as the repair.

DIFFERENTIAL DIAGNOSIS includes:

- (1) Liver abscess (15.10),
- (2) Empyema (9.1),
- (3) Pulmonary collapse (11.11).

MANAGEMENT OF SUBPHRENIC ABSCESSSES (GRADE 3.2)

WHICH APPROACH?

If you suspect a subphrenic abscess, and the general state does not improve, and the fever does not settle, prepare to drain the abscess. Try to do this with ultrasound guidance, if necessary on several occasions. Otherwise, especially if the pus is too thick, the collection does not resolve, or keeps recurring, explore the abscess! Avoid antibiotics which may mask the symptoms.

If there is a swelling, or oedema, or redness or tenderness just below the ribs or in the loin, make the incision there.

If the abscess follows appendicitis, a perforated duodenal ulcer, or cholecystitis, it will probably be on the right. If a high gastric ulcer has perforated, it is more likely to be on the left. If an ulcer in the posterior wall of the stomach has perforated, there will be pus in the lesser sac.

SUBPHRENIC ABSCESES

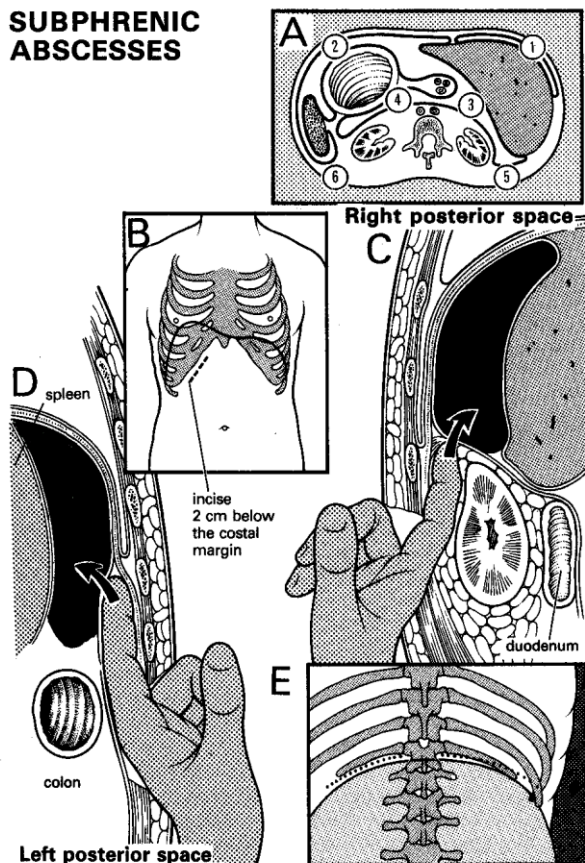


Fig 10-7 SUBPHRENIC ABSCESES.

A, spaces where pus can collect under the diaphragm: (1) right anterior subphrenic. (2) left anterior subphrenic. (3) right subhepatic. (4) left subhepatic (lesser sac). (5) right posterior subphrenic. (6) left posterior subphrenic. B, anterior approach: make a subcostal incision. C, explore the right posterior subphrenic abscess. D, explore the left posterior space. E, explore the posterior spaces through the ribs.

If you don't know which side it is on, there is about a 75% chance that it will be on the right, probably anterior. Approach it anteriorly, if possible through the old laparotomy wound, unless there are very clear signs that it is posterior. If one route fails, try another. You cannot readily reach the posterior surface of the liver through an anterior incision, or the anterior liver surface through a posterior incision, so use the anterior approach by preference, and the posterior approach only if you are certain pus is there, or you have found none anteriorly.

ANAESTHESIA. If GA is risky, block the lower 6 intercostal nerves. *Don't hesitate to explore the abscess* because the patient seems too weak for surgery!

ANTERIOR APPROACH. Preferably re-open the previous laparotomy incision; otherwise make a subcostal incision which is large enough to take your hand, a finger's breadth below and parallel to the right (usually) or the left costal margin. Cut from the middle of the rectus muscle laterally (10-7B). Cut the muscle fibres in the line of the incision. This way you can often drain the septic collection without entering the general abdominal cavity.

If you have entered through the previous incision, beware of adhesions, go carefully, and pack off the rest of the abdomen before you come to the abscess which you will find by noting tissues adherent to each other. Sweep your finger gently above the liver from one side to the other to explore the subphrenic space. If you don't find pus, sweep your finger laterally and explore below the liver. Break down any loculi, and send pus for culture. Insert a drain. If the liver is not adherent to the diaphragm, there may still be pus posteriorly, pushing the liver forwards.

CAUTION!

- (1) Try not to enter above the diaphragm. This is more likely to happen with an anterior approach. If you enter the pleura, lavage the thoracic cavity thoroughly, especially if you have spilled pus inside it, then close the diaphragm with a #1 suture and insert an underwater seal drain. If you have not yet found the pus, make sure the diaphragm is well closed before you approach the abscess.
- (2) Be sure that there is only one abscess.

If you damage the pleura accidentally, close it and insert an underwater seal drain.

SUBPHRENIC ABSCESS (posterior approach)

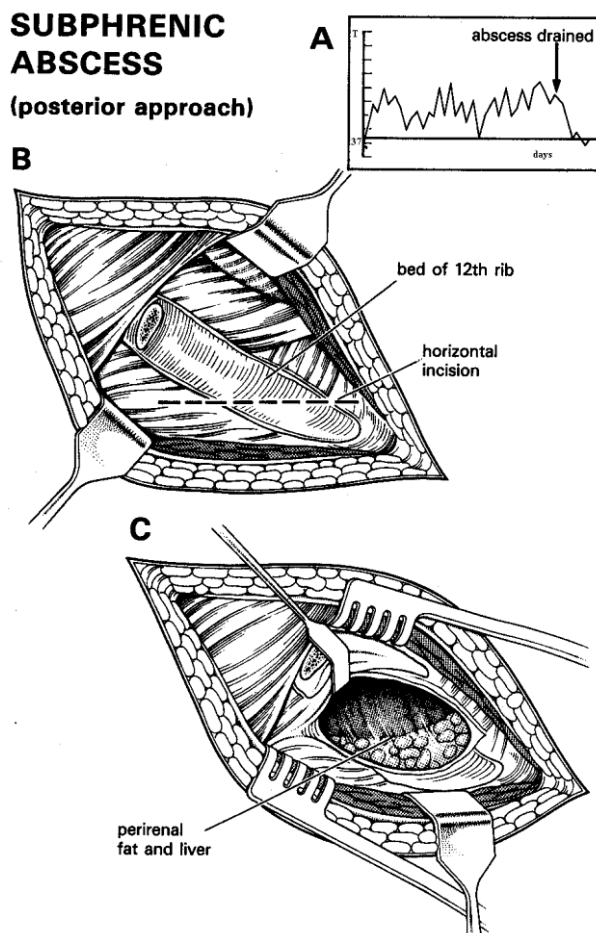


Fig. 10-8 POSTERIOR APPROACH TO A SUBPHRENIC ABSCESS. A, temperature chart: a hectic fever subsided after the abscess was drained. B, excise the 12th rib and make an incision in its bed. C, divide the bed of the 12th rib, showing the liver and the fat round the kidney. After Ochsner A, Graves AM. *Subphrenic Abscess: An Analysis of 3,372 Collected and Personal Cases.* Ann Surg. 1933;98(6):961-90.

POSTERIOR APPROACH. Lay the patient on his sound side with the lumbar region slightly elevated by breaking up the table or placing pillows under the opposite side. Make an incision which is big enough to take your hand over the 12th rib posteriorly (10-7E, 10-8). Remove the distal 2/3 of the 12th rib; divide it at its angle. Cut through the periosteum, reflect this from the whole circumference of the bone with Farabeuf's rougine, as for an empyema (9.1). Occasionally, you may need to tie the intercostal vessels.

CAUTION! Take great care not to damage the diaphragm. Incise the inner aspect of the periosteum horizontally. Push your finger upwards and forwards above the renal fascia to enter the abscess (10-7C,D).

If pus ruptures into a bronchus in a spasm of coughing, death from asphyxiation may result unless you institute urgent postural drainage (11.12). The pus is more likely to have spread from an amoebic liver abscess than from a subphrenic abscess.

If the subphrenic collection is recent after laparotomy, it may not have walled off, and be associated with other intra-abdominal collections. In this case, re-open the original laparotomy incision, aspirate all the abscess cavities, and lavage thoroughly with warm water. *Don't insert drains.* Plan a repeat laparotomy if the sepsis was severe.

10.3 Pelvic abscess

Pus in the pelvis is nearly as dangerous and difficult to manage as pus under the diaphragm. It is rarely completely walled off and so not strictly an 'abscess'. Infection in the pelvis usually arises following:

(a) **Infection of the female genital tract** (commonest) which can be any of the varieties of pelvic inflammatory disease (PID, 23.1). Those caused by anaerobes are particularly serious and likely to spread. The patient may be very ill; you may have difficulty finding pus, and knowing when and how to drain it. The danger is that pus may build up as a mass above the pelvis, and spread upwards into the abdominal cavity, perhaps fatally, instead of discharging spontaneously and harmlessly through the vagina or rectum. Drain this type of pelvic abscess early, and *don't 'wait and see'*.

(b) **Appendicitis** (14.1).

(c) **Caesarean section** (21.13) or **hysterectomy** (23.15).

(d) **Vaginal delivery** (22.14).

(e) **Generalized peritonitis** (10.1).

(f) **Diverticulitis.**

A septic pelvic collection can grow quite large without causing very obvious illness or signs. As the signs are subtle, it is worth becoming experienced in rectal or vaginal examination. One danger is that a pelvic abscess may obstruct the bowel (12.16). You can sometimes drain a man's pelvic collection rectally, and a woman's collection vaginally. This may be easier than performing a laparotomy. However, if coils of bowel lie between the pus and the posterior fornix, it will be more difficult to diagnose, and you will have to drain it abdominally. Sometimes, an abscess drains into the rectum spontaneously, but you will still need to drain it properly surgically.

SYMPTOMS AND SIGNS

Look for fever and the passage of frequent loose stools with mucus. There is often a history of tenesmus.

Feel for:

(1) A boggy, tender mass above a man's prostate filling the rectovesical pouch, or a soft bulging swelling in a woman's pouch of Douglas. Sometimes, the mass is almost visible at the vulva. You will not find fluctuation.

(2) Tenderness and occasionally an ill-defined mass suprapubically. If you suspect a pelvic abscess in a woman, put one finger into the rectum and another into the vagina. Normally, they should almost touch. If there is an abscess, you will feel it between your fingers.

DRAINING A SEPTIC PELVIC COLLECTION

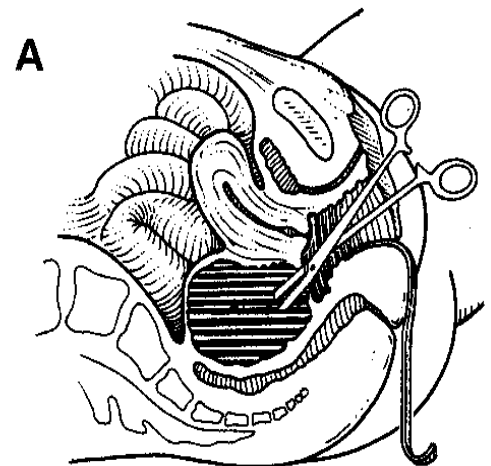
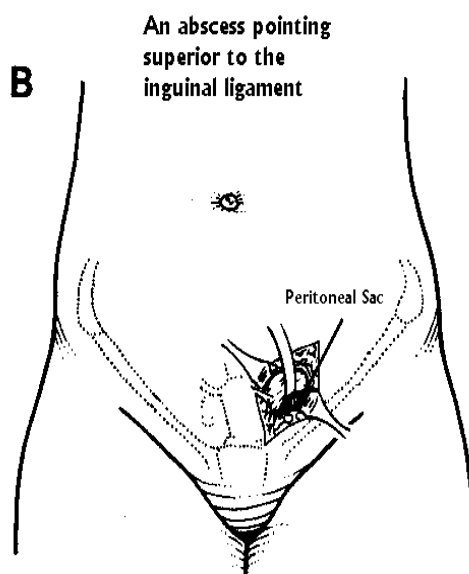


Fig. 10-9 DRAINING A SEPTIC PELVIC COLLECTION.

A, make sure the collection is pointing into the pouch of Douglas before you drain pus vaginally, or you may penetrate loops of bowel. B, drain a pelvic collection anteriorly by a Lanz or McBurney incision (11-1).

You can confuse a pelvic abscess bulging into the pouch of Douglas with:

- (1) A 'chronic' ectopic gestation (20.7).
- (2) An ovarian cyst (23.9). Some suspected cysts turn out to be post-inflammatory collections of fluid (post-inflammatory pelvic pseudocysts).

ULTRASOUND will most easily show a fluid collection in the pelvis (38-5), where it is, and how big it is: make sure the bladder is full before the examination! Always attempt drainage under ultrasound control, if possible.

VAGINAL DRAINAGE OF A PELVIC ABSCESS (POSTERIOR COLPOTOMY; CULDOCENTESIS) (GRADE 1.3)

INDICATIONS

- (1) A pelvic collection which extends into the pouch of Douglas or upwards suprapubically into the abdomen.
- (2) A pelvic collection which has ruptured in a patient too sick to undergo formal laparotomy.
- (3) A pelvic haematocoele ('chronic' ectopic gestation) extending into the pouch of Douglas (20-7).

PREPARATION

Use the lithotomy position and catheterize the bladder. Perform a vaginal examination to confirm the diagnosis. Clean the vagina with 1% chlorhexidine.

INCISION

Expose the vaginal wall of the posterior fornix (*which must be bulging*) with a short broad speculum. Ask an assistant to depress the vaginal wall with a Sims speculum, while you raise the posterior lip of the cervix with a vulsellum forceps.

Use ultrasound guidance if you can: push a long large needle on a 20ml syringe into the swelling in the midline and aspirate:

If you aspirate pus, this confirms a pelvic abscess, or **if you aspirate a pale yellow fluid**, you are probably draining a post-inflammatory pseudocyst. Make a 2-3cm transverse incision in the vaginal wall in the place where you found pus. Push in gently a blunt instrument; pus or fluid should flow. Enlarge the opening. Explore the abscess with your finger; feel for loculations in the abscess cavity and gently open them. Insert a large drain and suture it to the perineum or labia. Leave it in and continue antibiotics. Pus may discharge for up to 2wks.

If you aspirate blood which clots easily, you have punctured a blood vessel (which should not happen if the needle is in the midline.)

If you aspirate >2ml dark, free-flowing blood which does not clot even after 10mins, this is a haematocoele due to a chronic ectopic gestation (20.7): perform a laparotomy.

If you aspirate clear fluid, this may well be liquor (or a cyst in the pouch of Douglas) suggesting an acute ectopic gestation. Check whether the abdomen is full of ascites, suggesting TB or liver disease.

If you aspirate faeces, you have probably entered the colon, which may be stuck to the vagina. Withdraw the needle and repeat the aspiration in the midline. If a faecal fistula results, manage this conservatively (11.15).

CAUTION!

- (1) If pus is pointing laterally, drain it as close to the midline as you can, to avoid injuring the ureters (23.15).
- (2) *Don't push too deeply into the abscess with a haemostat*, or its roof may give way and spread the pus into the abdominal cavity; or you may damage a loop of bowel. Be safe, and gently insert your finger through an adequate incision. The effect should be spectacular, and marked improvement should result within 1-2 days.
- (3) *If you don't find pus, perform a laparotomy.*

If there is no improvement, there must be more pus somewhere. Repeat the ultrasound or perform a laparotomy.

RECTAL DRAINAGE OF A PELVIC ABSCESS (GRADE 1.5)

PREPARATION

Use the lithotomy position. While the abdomen is relaxed, palpate it gently. Then make a bimanual examination with one finger in the rectum, and your other hand on the abdomen. If you can ballot a fluid collection, using ultrasound guidance, needle it, taking a 1mm blunt needle attached to a syringe. Place the tip of your gloved right index finger over the place in the anterior wall of the rectum where you feel pus. Slide the point of the needle up alongside your finger, then push it through the wall of the rectum for about 2cm and aspirate.

If no pus comes out, inject a few ml of saline, and aspirate again. The needle may be blocked.

If you aspirate pus, drain it. Either push the tip of your index finger into it: pus will burst out. Or take a long curved haemostat, and with your index finger again acting as a guide, push its tip through the anterior wall of the rectum into the abscess. Enlarge the hole by opening and closing the jaws a few times.

CAUTION!

- (1) Make sure you find pus before trying to drain it.
- (2) The rectal wall may bleed seriously; if so, pack it with gauze.

SUPRAPUBIC DRAINAGE OF A PELVIC ABSCESS (GRADE 2.2)

This is sometimes needed in women (it is almost never necessary in men), particularly after an induced termination of pregnancy, or a Caesarean section when you can feel a mass suprapubically but not vaginally. Fortunately, you can usually drain an abscess from below, which is easier and safer. Rarely, if more pus collects after vaginal drainage, especially if there is distension, tenderness and induration behind and above the pubis, and if there is also severe toxemia, drain the pus suprapubically.

PREPARATION

Catheterize the bladder to make sure it is empty. Make a 10cm Pfannenstiel incision immediately above the pubis. Incise the *linea alba* and the peritoneum. Inspect the general abdominal cavity and pack off the upper abdomen with some large moist abdominal packs. Gently feel for the collection. Retract the bladder and bowel out of the way. Look for pus, for loops of bowel stuck down in the pelvis, and for oedematous or congested tissues. Insert a self-retaining retractor.

Use a 'swab on a stick' and gently mobilize adherent loops of bowel, until you have found the pus.

CAUTION!

- (1) *Don't use the Trendelenburg position to improve exposure*; this may spread the infection.
- (2) Keep manipulation to a minimum.
- (3) When you have found pus, do nothing more than is necessary to ensure adequate drainage. *Don't break down the outer walls of the abscess cavity*, but do break down any loculi inside. Distinguishing between them may be difficult.
- (4) *Don't remove a normal appendix.*

Culture the pus and insert a drain. Remove all the packs; suture the abdominal muscles securely, but *don't close the skin immediately* (11.8).

DIFFICULTIES WITH PELVIC ABSCESSSES

If there is colicky pain, vomiting, and abdominal distension, the small bowel is obstructed. Try to treat this non-operatively, with nasogastric suction and intravenous fluids (12.16). Draining the abscess will usually cure the obstruction. If it does not, you may have to relieve the obstruction operatively (12.4,6).

If you rupture the bowel whilst exposing the pelvic collection, control the spillage with soft bowel clamps and gently extract the remaining adherent bowel from the pelvis. Wash out the cavity with copious warm fluid. If the bowel perforation is small and the patient's condition is good, close it (11.3); otherwise bring out the proximal portion as an enterostomy.