

# 14 Bowel inflammation & perforation

## 14.1 Appendicitis

Appendicitis is becoming the commonest abdominal surgical emergency in most of the world, and one with widely variable symptoms. It becomes more common as people discard a high-fibre diet. It can occur at any age, but is rare in children <5yrs.

The disease starts as localized ischaemia of the appendix, probably due to an impacted faecolith; this then either resolves, or complicates with super-added infection, leading to gangrene or perforation. Occasionally the inflammation resolves leading to fibrosis. Sepsis may occasionally spread to the liver, giving rise to portal pyaemia with jaundice and rigors. If peritonitis does develop, the infection can either remain localized or become generalized. If it remains localized, it does so by forming an 'appendix mass' of adherent coils of bowel and omentum. This may then resolve, or suppurate. The distinction between a 'mass' which is not tender or is only minimally tender, and over which there is no guarding or rigidity, and an obviously tender 'abscess' is important, because an abscess needs draining, but a mass can be treated non-operatively.

An abscess may enlarge until it drains spontaneously to the surface, or into the bowel, or into the peritoneal cavity, where it causes generalized peritonitis. It may occasionally become very large but firmly walled off from the peritoneal cavity, giving an appearance like tuberculous ascites.

Appendicitis takes some time to develop, although this may be <6h: you can generally follow its course. Therefore try to work out if the symptoms have been present long enough or too long to fit the clinical picture because the development of an appendix mass or 'abscess' takes several days. Conversely, if symptoms have been present long, but the signs are not impressive, appendicitis is unlikely.

Central abdominal pain is usually the first symptom, and it may be severe enough to disturb sleep. Some hours later the pain moves to the right iliac fossa (or where the appendix is situated: this may be under the liver) and the patient may be able to localize it with one finger. The pain then increases gradually, and is constant. It is now *not* colicky, and is worse on moving, coughing, straining, walking or taking deep breaths (so irritating the parietal peritoneum). The patient moves with caution, and may find it easier to stoop forwards. Lying in bed, he is more comfortable with the right leg flexed. *He does not writhe around in bed.* In a more advanced case, he is almost always anorexic and nauseated. He usually vomits once or twice only, soon after the pain starts. At

this stage vomiting is never as severe as in cholecystitis, pancreatitis, or bowel obstruction.

Peritoneal inflammation is responsible for the most important sign of appendicitis: tenderness in the right iliac fossa. Significant rigidity is a sign that peritonitis is spreading.

(a) **Presentation** occurs at various stages:

(1) **When the infection is localizing as an appendix mass.** The history is likely to be that the symptoms began as above, then the patient began to feel better, the pain improved, and the appetite began to return. He now looks fairly well and has only a mild fever (37.5°C). The mass in the right iliac fossa is only mildly tender, with no guarding or rigidity.

(2) **When infection is still localized but has become an 'abscess'.** In this stage he is very unwell, anorexic and toxic; there is pain in the right iliac fossa, and a swinging temperature. The abscess may:

- (i) be only just palpable,
- (ii) be bulging, tender, and fluctuant,
- (iii) be in the pelvis, so that you cannot feel it abdominally,
- (iv) bulge into the rectum, or the vagina (unusual),
- (v) be palpable above the pubis,
- (vi) track along the right paracolic gutter to present in the right flank,
- (vii) stretch and obstruct loops of bowel.

(3) **Just after perforation,** when the pain of the distended appendix is suddenly relieved, with apparent relief of symptoms, before peritonitis has had time to spread.

(4) **When infection is spreading to cause generalized peritonitis.** There is now generalized abdominal pain, tenderness, guarding, and rigidity. If presentation is very late, there may also be dehydration, cachexia, oliguria, and hypotension with a silent, distended abdomen. All you will know is that there is peritonitis: appendicitis is merely one of its possible causes. If nothing is done at this stage, the patient may become moribund, when the signs of peritonitis may be less obvious.

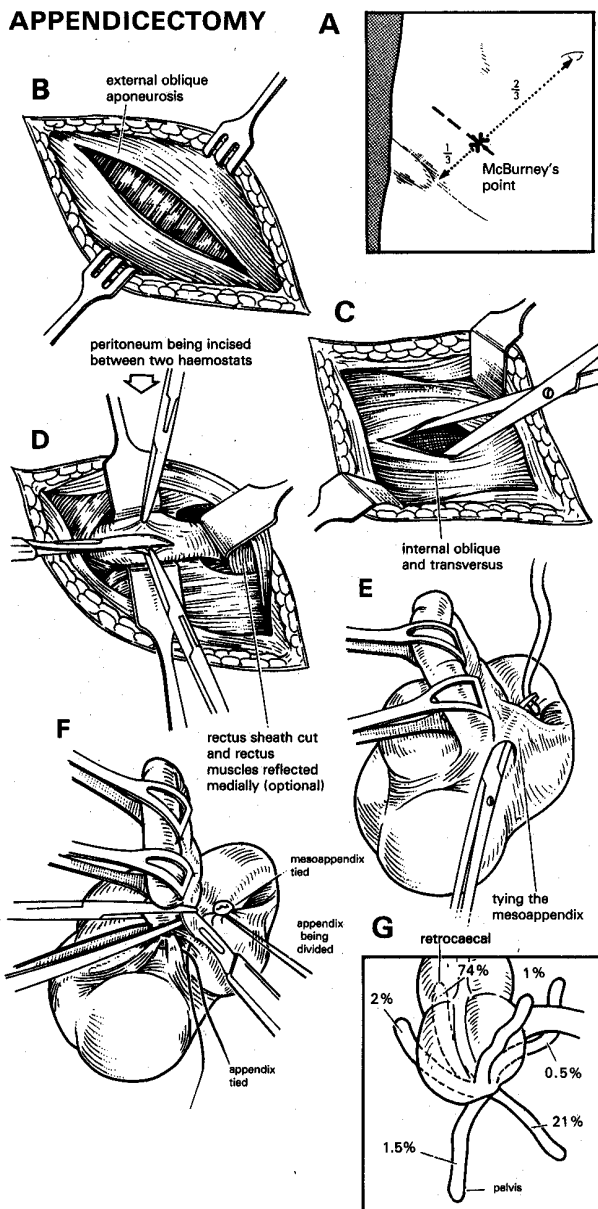
Try to recognize appendicitis early, before it is allowed to reach the stage of peritonitis or an abscess. The delay of even a few hours can be especially critical in a small child. Experience will teach you when to operate. Some of the alternative diagnoses require operation anyway, and some of those that might be harmed by operation, such as basal pneumonia, *ascaris* infestation, or gastroenteritis, should be easy to exclude. There are always some definite signs in a real case of appendicitis.

In spite of the long list of differential diagnoses that follows, the diagnosis is usually easy. But, remember that:

- (1) There may have been no central abdominal pain, so that pain first appears in the right iliac fossa.
- (2) There may be no tenderness in the right iliac fossa if the appendix is deep in the pelvis; *you may only find tenderness rectally:* so always do a rectal examination.

(3) The diagnosis is particularly difficult, but no less important, if the patient is very young, very old, fat or pregnant.

Occasionally you may see a patient with appendicitis with an appendix scar, or even with a history of having had an appendicectomy! He may have been misled, or the scar made for a different reason. A significant-sized stump may have been left behind, to become re-inflamed, or very rarely one of a duplicated appendix may have been missed. If the signs indicate surgery is required, *don't hesitate!*



**Fig. 14-1 REMOVING AN APPENDIX** through McBurney's incision (if the diagnosis is in doubt, a low midline incision is better). A, McBurney's point and the position of the incision. B, split the external oblique aponeurosis. C, split the internal oblique and transversus muscles. D, open the peritoneum between 2 haemostats. This drawing also shows how you can, if necessary, extend the incision medially by incising the anterior rectus sheath, and retracting the rectus muscle. E, pass a ligature through the mesoappendix. F, transfix the appendix base, and remove it. G, various positions where you may find the appendix: 74% behind the caecum, 22.5% in the pelvis. It is seldom anywhere else.

Partly after Maingot R, *Abdominal Operations*, HK Lewis 4<sup>th</sup> ed 1961 p.811 Figs. 2,3. with kind permission.

Removing an appendix is usually easy, but is sometimes very difficult:

- (1) The appendix may be difficult to find.
- (2) It may be difficult to deliver, if it is stuck deep in the wound and is obscured by bleeding.
- (3) The caecum may be fragile.
- (4) You may find totally different pathology.

Finally: if signs are equivocal, it is reasonable to administer gentamicin and metronidazole and review the situation periodically.

**(b) Early history.** Ask carefully how and where the symptoms began. How do the other symptoms fit into the story? Most importantly, at which point in the natural history of the disease does the patient find himself now? Remember that a retrocaecal or pelvic appendix may cause diarrhoea or frequency of micturition.

*N.B.* If vomiting or nausea preceded the onset of the pain, appendicitis is unlikely.

### (c) Examination

(1) **PULSE AND TEMPERATURE.** In the early stages the pulse is normal, and the temperature nearly so. If the pulse is raised, the appendix is probably phlegmonous. A steadily rising pulse is always serious. If there is rigor or high fever within 24h of the onset of symptoms, appendicitis is most unlikely.

(2) **INSPECTION.** Typically, the lower abdomen does not move with respiration.

(3) **TENDERNESS** on deep palpation in the right lower quadrant over McBurney's point (14-1A) is the single most useful sign. Ask the patient to inflate his lungs: if this causes pain in the right lower abdomen, it is a good sign of peritoneal irritation.

You must, however, examine the whole abdomen systematically with the flat of your hand. Examine the left hypochondrium first. Compare both sides, and the upper and lower quadrants on the right. *Don't dig your fingers into the right lower quadrant.*

**If the appendix is behind the caecum**, there may be tenderness in the flank. If it is in the pelvis, there may only be tenderness in the rectum, or above the pubis.

**If there is spreading peritonitis**, there will be tenderness over much of the abdomen.

**If you press gently in the right iliac fossa, and then quickly release your hand**, this may produce a sudden pain. *This is not so reliable if the patient is fat or pregnant.* This is rebound tenderness, and is a sign of early peritoneal irritation. *It is impossible to have guarding but no rebound tenderness!* A kinder way of eliciting this sign is to test for tenderness to light percussion. This is not so painful and is a better sign.

Try to feel a child's abdomen when he is asleep, or resting on the mother's lap. If he resents any attempt to examine the abdomen, there is probably something seriously wrong inside it. Examine him repeatedly at intervals of 1h, until you have enough evidence to justify a laparotomy.

(4) **GUARDING** is a sign of local peritonitis. Lay your hand flat on the abdomen, and gently flex your knuckle joints. If there is tightening over the right fossa, the sign is +ve, especially if the patient winces with pain. *Remember to look at his face, not your hand!* Tenderness is relieved by flexing the hip, but worsened by flexing the hip against resistance (10-2).

(5) **RIGIDITY** is a comparatively late sign, and shows that infection has reached the anterior abdominal wall. Generalized rigidity is a sign of generalized peritonitis (10.1). It is less marked in the obese, emaciated, very old, very young, or those with HIV disease. Advanced peritonitis becomes less tender as the volume of ascitic fluid increases.

(6) **AN APPENDIX MASS** may be palpable if the symptoms have lasted >2-3 days. With obesity, or a very low pain threshold, it will be difficult to feel. Distract the patient's attention while you palpate.

The mass is ill-defined and is probably an 'abscess' if:

- (i) it is tender,
- (ii) there is a high fever,
- (iii) there are features of intestinal obstruction.

Confirm the presence of pus by aspirating with a wide-bore needle.

*Don't assume a mass in the right iliac fossa is an appendix mass: it may be an adnexal mass, an intussusception, a mass of *ascaris* worms, an amoeboma, a caecal carcinoma, a lymphoma, an ileocaecal tuberculoma, an ileal phytobezoar, a bilharzioma, or due to *actinomyces* or *angiostrongyliasis*. Check the history!*

**(d) Rectal (or vaginal) examination:** *never forget this to feel for tenderness or a mass:* the inflamed appendix may be dangling in the pelvis. A rectal examination will often distinguish salpingitis, and a right-sided ectopic gestation. Slowly pass your half-flexed, well-lubricated index finger into the rectum (use your little finger in a child <10yrs). When it is completely inside, keep it still for a moment. Wait for the patient to relax, then gently press anteriorly, posteriorly, and on each side on the pelvic peritoneum with the tip of your finger.

**CAUTION!** *Don't let the patient confuse the discomfort of you putting your finger into the anus, with the pain of you pressing on the pelvic appendix.* Wait with your finger in the rectum until the initial discomfort has settled, then rotate and flex the tip of your finger and note the response.

#### (e) Special tests

A leucocytosis is a useful sign if present, but a normal white cell count may be present in advanced appendicitis with HIV disease. *Alone, without other signs, it is not enough to warrant exploration.*

**(f) Ultrasound** is helpful in detecting free fluid (38.2i), a mass or lymphadenopathy (38.2h), or the appendix swollen and non-compressible with a diameter >6mm, *but a diagnosis should not rely on an ultrasound report alone.*

#### (g) Differential diagnosis of appendicitis

This is a long list, but the most important possibilities are the first two, because surgery will make the patient worse:

**Suggesting an upper respiratory infection, a viral infection (mesenteric adenitis), or tonsillitis:** upper respiratory symptoms, tachypnoea and alar flaring, generalized muscle aches. All these can cause central abdominal pain in a child. Watch and examine repeatedly, especially the pulse, and if this does not settle, get a chest radiograph.

**Suggesting gastroenteritis:** diarrhoea, perhaps with vomiting. The pain will be colicky, the tenderness poorly localized, and there may be pus cells in the stool. Be sure to do a pelvic examination, if necessary several times, because a pelvic appendix abscess may be developing. Try to get an ultrasound scan (38.2).

**Suggesting amoebiasis:** a history of diarrhoea with blood and especially mucus: look for *amoebae* in the stools (14.5).

**Suggesting typhoid:** a history of fever, diarrhoea, and diffuse abdominal pain for c.3wks, suddenly becoming acute (14.3).

**Suggesting ileocaecal tuberculosis:** chronic pain which is sometimes colicky, with a general deterioration in health, especially with HIV disease (16.1).

**Suggesting a perforated peptic ulcer** (13.3): the pain, which is now in the right iliac fossa, *started suddenly* in the upper abdomen; there may be a history of chronic dyspepsia. Enquire for shoulder tip pain. Get an erect chest radiograph and look for gas under the diaphragm.

**Suggesting iliac adenitis** (6.16): a tender fluctuant mass in the lower quadrant, and a marked flexion contracture of the hip. Look for the primary source of the infection in the legs or perineum.

**Suggesting septic arthritis of the hip** (7.18): intense pain on any movement of the hip, which is kept flexed. Aspirate from the joint to detect pus.

**Suggesting a urinary infection:** frequency and pain on micturition, with central lower abdominal tenderness and little guarding. *These symptoms can also be caused by appendicitis, if the appendix lies against the bladder.* Examine the urine.

**Suggesting ureteric colic:** severe intermittent *colicky* pain radiating into the groin without fever. Test the urine for red cells: these are most often present if there is a stone in the ureter.

**Suggesting ‘caecal distension syndrome’:** a result of constipation where the ileocaecal valve is competent, allowing the caecum to swell uncomfortably. Look for constipated stool in the rectum. Although tenderness may be marked, there is no fever and no constitutional upset.

**Suggesting caecal carcinoma:** an elderly patient with chronic constipation and/or iron-deficiency anaemia. Look for a firm mass in the right iliac fossa.

**Suggesting diverticulitis:** an elderly patient with a Westernized diet, an irregular bowel habit and episodes of constipation.

*In women* there are several more possibilities:

**Suggesting PID (23.1):** pain on both sides of the lower abdomen for  $\geq 72$ h (rather than 12-36h, as is usual with appendicitis), a history of infertility, and previous pelvic infection. A tender fixed, or occasionally fluctuant, adnexial mass on the right side. A short history with advanced signs of pelvic peritonitis suggests that the mass (a tubo-ovarian abscess) may have ruptured. Examine the cervix for a purulent discharge (23.1). *PID may be impossible to distinguish from pelvic appendicitis.*

**Suggesting torsion of an ovarian cyst (23.9):** a brief history of acute pain localized to the suprapubic area. A mass palpable vaginally or bimanually. The temperature will not be high.

**Suggesting a right-sided ectopic gestation (20.6):** a history of a missed menstrual period, signs of hypovolaemia, signs on pelvic examination, and the aspiration of blood on paracentesis. If the ruptured ectopic gestation bleeds more slowly, diagnosis may be more difficult (20.7). Do a pregnancy test and get an ultrasound examination (38.3).

**Suggesting ovulatory bleeding:** the pain started in the middle of a menstrual cycle (*mittelschmerz*); mild abdominal tenderness without fever. It will settle in a few hours.

#### **(h) Management of appendicitis**

Treatment is usually straightforward.

- (1) In the early case, with appendicitis or localized peritonitis, remove the appendix.
- (2) Later, with a satisfactorily localizing condition (an appendix mass), and nothing suggesting peritonitis, an abscess or obstruction, treat non-operatively and observe (see below).
- (3) If the history has lasted  $>3$  days, with signs of an abscess which is enlarging, drain it.
- (4) If presentation is with general peritonitis, resuscitate and treat (10.1) with vigorous resuscitation and damage-limitation laparotomy if the condition is very poor.
- (5) If there is no toxaemia, it might be best not to operate in the middle of the night (especially if the numbers of nursing staff are low then) but treat with antibiotics and operate first thing in the morning.

#### **CAUTION!**

(1) Infection is less likely to localize at the extremes of life, so *don't be too conservative in the very young or very old.*

(2) In pregnancy, appendicitis does not localize: the danger to the foetus from untreated appendicitis is far greater than surgery, even in the first trimester. The appendix is pushed upwards by the gravid uterus, so tenderness may be high up. Hyperemesis may be confusing.

(3) *Don't try to remove an appendix if it is very adherent and you are afraid of damaging bowel.* Leave it, and insert a drain: it will probably resolve.

**(i) Laparoscopy.** If you cannot make a diagnosis, you might be tempted to use a laparoscope (19.5) to help. *Don't rely on the findings unless you are very experienced with this technique.* You may easily miss some relevant pathology. However, it may give you a definite indication to proceed surgically, but it already commits the patient to an operation!

#### **(j) Non-operative treatment for appendix mass**

##### **(1) Indications**

An appendix mass with no signs of infective spread. *This is not advisable in children  $<10$  yrs, because the omentum is too short to wall off the appendix, nor in the elderly.*

##### **(2) Method**

Monitor with the greatest care. Treat with metronidazole and gentamicin, and restrict oral intake. Rely on the patient's own assessment of himself, especially with such questions as “Is your pain still subsiding?”, “Can you move about more freely?”, and “Has your appetite improved?”. Monitor the temperature, the pulse, and the white blood count. Palpate the mass gently, and mark its outline on the abdominal wall daily with a felt pen. Allow fluids only by mouth when he starts to improve, then after a day or two, a light diet. Stop the gentamicin, and use metronidazole orally for 3 more days. Check that the mass continues to shrink and that improvement continues. Review in 1wk *but only remove the appendix if symptoms recur.*

##### **(3) Abandon non-operative treatment if:**

- (i) the pain gets worse, or the patient begins to feel generally worse
- (ii) the mass enlarges, or just does not shrink
- (iii) the abdominal tenderness increases and peritonitis develops
- (iv) signs of intestinal obstruction develop
- (v) the pulse rate increases and an abscess develops.

This is a very important sign. A slightly raised temperature is of less importance in the early stages, provided that the pulse is steady or falling. A persistently high or swinging temperature implies the presence of an abscess that needs drainage. Any or all of these things show that infection is spreading, so operate for an enlarging abscess, peritonitis, or obstruction.

*Remember the danger signs as 4Ps: pain, pulse, pyrexia, and palpable mass.*

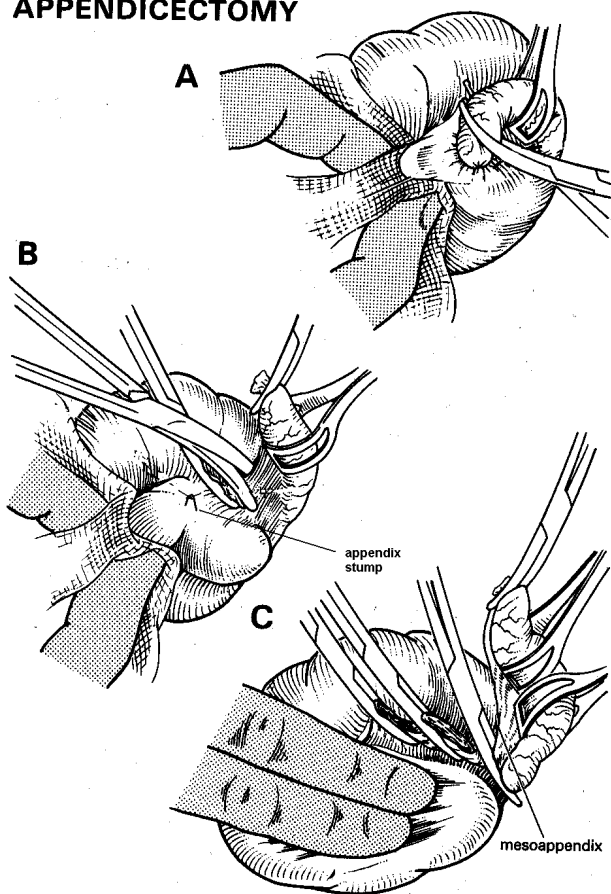
**CAUTION!** Non-operative treatment is only applicable with surveillance in hospital.

### (k) Operative treatment for appendicitis

#### (1) APPENDICECTOMY (GRADE 3.1)

This describes the operation where appendicitis is early, and inflammation is located to the right iliac fossa. Where this is *not* the case, and especially when you find a mass when the abdomen is relaxed under GA, or are not certain of the diagnosis, particularly in a woman, perform a formal laparotomy through a midline incision (10.1) because access is better and you can wash out the abdomen more satisfactorily: *this is crucial*.

#### RETROGRADE APPENDICECTOMY



**Fig. 14-2 RETROGRADE APPENDICECTOMY.**

A, free the proximal end of the appendix from the caecum and transfix it. B, divide it proximally and release it distally from the caecum. C, it is very nearly free. *N.B. This requires adequate exposure.*

Partly after Maingot R. *Abdominal Operations*, HK Lewis 4<sup>th</sup> ed 1961 p.816 Fig 7 with kind permission.

**PREPARATION.** Infuse Ringer's lactate or saline IV. Treat with oral or rectal metronidazole. Have suction ready. Make sure you have an assistant.

#### INCISION

Centre a 4-5cm slightly oblique skin incision at the point of maximum tenderness and resistance. This may be at McBurney's point ( $\frac{2}{3}$  the way from the umbilicus to the

anterior superior iliac spine), or it may not. (*For example, it is in the left iliac fossa in a case of situs inversus!*)

If you are not experienced, *don't try to operate through a keyhole incision*, and *don't site your incision too low* (to be hidden by a bikini!).

Remember, in a pregnant woman, the appendix is pushed much higher up, depending on gestational age.

Split the external oblique muscle aponeurosis in the line of its fibres, which is the same as that of the skin incision, over its whole length. Resist the temptation to extend the incision too far medially. Get an assistant to retract.

Hold the edges of the oblique aponeurosis aside with haemostats, and you will see the fleshy fibres of the internal oblique running transversely, and a little upwards. Insert a closed pair of blunt scissors between them and use the 'push and spread technique' (4-9) to separate them. Then extend the incision with your fingers. Replace these by retractors, to expose the *transversalis* fascia and peritoneum. Pick these up as a single layer and separate them in the same way. Open the peritoneum between haemostats (11-2), making sure you have not inadvertently picked up bowel.

#### EXPLORING THE ABDOMEN FOR ACUTE APPENDICITIS

Raise the edges of the peritoneum with retractors and look inside. Some exudate may escape. It does not indicate peritonitis, unless it is obviously purulent and foul-smelling. Suck it away using a Poole's sucker. If you cannot see the caecum, it is probably lateral to your incision, or is covered by small bowel. Search for it by sliding a finger into the paracolic gutter. If there is then much fluid coming out, suck it away. Try to feel for the appendix and lift it gently out if it is mobile; if not, retrace the appendix to its base and so locate the caecum. If you pull out small bowel, or sigmoid colon, replace it and try again: *don't keep pulling on small bowel hoping to get to the caecum!*

#### If you have difficulty finding the appendix:

(i) Look for the pink to grey-blue caecum first. It is often higher than you expect, and always lies laterally; it may unusually lie under the liver. The 3 *taeniae coli* of the caecum converge on the appendix, which lies normally on its posteromedial side. Follow the anterior *taenia* to its base. The tip of the appendix may lie under the caecum, or in the pelvis. With your index finger, feel for something worm-like, tense and rigid.

(ii) Retract the wound edges a bit more.

(iii) Extend the incision.

#### CAUTION!

(i) If there is localized peritonitis, take particular care not to spread the infection.

(ii) *Don't mistake the sigmoid or transverse colon for the caecum:* the transverse colon has greater omentum attached along its anterior surface.

(iii) Break down as few fibrinous adhesions as you can.

Put your finger under the anterior *taenia* and test the mobility of the caecum. If the tip of the caecum is free, it and the appendix should come to the surface easily. Hold the caecum with Babcock forceps and grasp it with a moist pack, and gently drag its lower end into the wound.

The appendix should follow. *Don't rupture it*, and use the minimum of force: you may be able to lift it out gently by finger dissection. Try to keep the appendix away from the wound edges.

**If omentum is folded round the appendix**, try not to separate it. Instead, tie it, and remove the adherent part with the appendix.

**If you need to extend a McBurney incision:**

- (i) extend the muscle splits; or
- (ii) cut across the muscles supero-laterally; or
- (iii) cut into the rectus sheath medially (14-1D), *taking great care not to cut the inferior epigastric artery*, which runs vertically on the deep surface of the rectus muscle.

**CAUTION!**

- (i) *Don't try to work through too small a hole.*
- (ii) If you cannot proceed satisfactorily, make a midline incision (*and learn from your mistake next time!*).

**If you have been able to deliver the caecum and appendix into the wound**, hold the appendix with a Babcock forceps round it away from the skin edges. Clip, ligate and divide the vessels in the mesoappendix. Pass an absorbable suture through the base of the appendix to transfix it (14-1F), and ligate it firmly. (*This avoids a ligature falling off.*)

**If the appendix has stuck in the pelvis, or behind the ileum, and is surrounded by a small abscess**, improve exposure by retraction, and by extending the wound downwards. Pack the area off with swabs, and cautiously free it by sharp or blunt dissection.

**CAUTION!**

- (i) If the mesoappendix is very inflamed, *don't apply artery forceps* but pass a ligature round it.
- (ii) Be patient and gentle when you try to remove a tense, unruptured, gangrenous appendix: if it is on the point of bursting, try to deliver it intact. (If it bursts, you will greatly increase the chances of infection.)

**If the appendix is stuck down behind the caecum or colon**, it may be held by fibrous tissue, making it impossible to free with your finger. Extend the incision upwards and laterally by an oblique cut through all layers of the abdominal wall to get better access. Now expose the caecum and, using scissors, carefully divide the peritoneal reflection on the lateral side of the caecum, using the 'push and spread' technique. Using a swab on a sponge-holding forceps, mobilize the caecum medially. Grasp it with a swab, and gently draw it up and out of the wound. Then, work your finger in the plane posteriorly. Tie off the base of the appendix first (14-2) and then remove the rest.

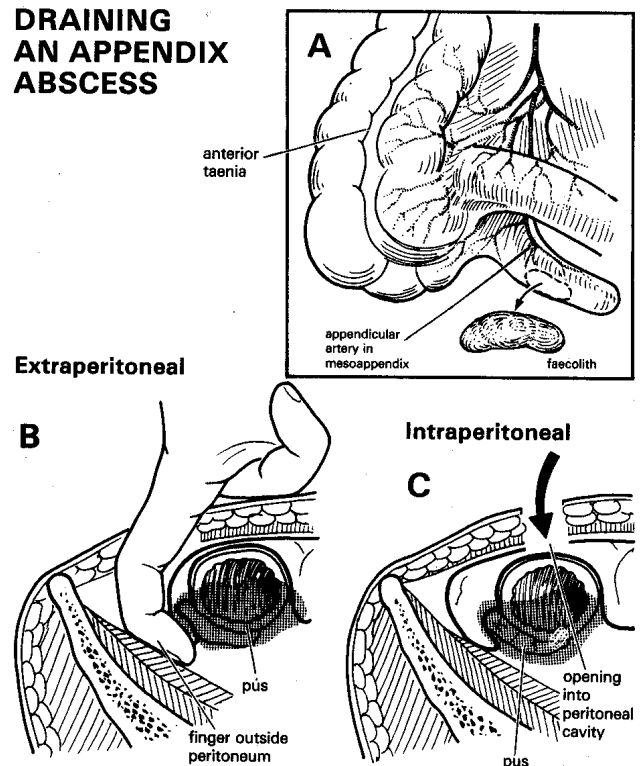
**If the appendix has perforated**, there is a 90% chance that there is a faecolith somewhere, either in the abdomen or the appendix. Faecoliths are calcified, and may show on a plain radiograph. Try to find and remove it: if you fail, insert a drain.

**LAVAGE.** Make sure you wash out the abdomen as thoroughly as you can with warm fluid; continue till the fluid aspirated is clear.

**CLOSURE.** Close the peritoneum with a running suture. It helps to keep straight forceps on the peritoneal edges and ask your assistant to hold them up: be careful you don't put a suture through bowel. If bowel keeps coming out through the wound, ask the anaesthetist for more relaxation. Bring the edges of the muscles together with a few stitches, if you have divided them. Close the external oblique with continuous absorbable, and the skin with subcuticular suture, or if you have removed a really dirty contaminated appendix, leave the wound open, and close it secondarily.

**DRAINS** are not usually indicated. They are much less important than sucking out and washing out the infected area at the time of surgery. It was thought that it would provide a tract for a fistula if one did form, but it actually may *be its cause*. If you had to leave the appendix (or part of it) behind or there was serious infection and abscess formation, and the patient is not improving, it is better to re-open the abdomen rather than rely on drains.

### DRAINING AN APPENDIX ABSCESS



**Fig. 14-3 DRAINING AN APPENDIX ABSCESS.**

**A**, anatomy of the appendix. If you cannot find the appendix, follow the anterior *taenia* of the caecum down to it. Sometimes, a faecolith forms in the appendix. If this escapes into the peritoneal cavity, it may be the cause of a persistent abscess. **B**, approach an abscess extraperitoneally. **C**, avoid the intraperitoneal approach, unless you happen to come across an appendix abscess unexpectedly during laparotomy.

## (2) DRAINING AN APPENDIX ABSCESS (GRADE 2.3)

INDICATIONS. A tender mass which is increasing in size with a history of appendicitis, or more rarely following appendicectomy 3-4 days previously, especially if there is increasing pain, pyrexia, and toxæmia.

THE EXTRAPERITONEAL APPROACH is best. If the abscess is dull to percussion, there is no bowel between it and the abdominal wall. It has probably stuck to the abdominal wall, so that you can easily drain it under LA. You may be able to do this satisfactorily by aspiration under ultrasound guidance; this is preferable to surgery but may mean more than one aspiration to empty the abscess.

Try to enter the abscess, *but not the peritoneal cavity*. Mark the point of maximum tenderness and fluctuation with a felt pen. Anaesthetize and incise the skin and muscles at this point. Try to enter the abscess as far laterally as you can. The muscles will be soggy and oedematous, but you can split them in the usual way, by pushing in a haemostat and opening it. Push a finger in laterally and backwards to make sure that the drainage track is big enough. Suck out pus, break down any loculi, and feel for and remove any faecoliths. Then push a large corrugated rubber drain well in. Suture this to the skin and shorten it gradually after the 3<sup>rd</sup> day. Remove it completely when it is no longer draining anything.

*CAUTION! Don't try to remove an appendix from the bottom of a large abscess cavity with much friable tissue that bleeds easily.* Drain the abscess and leave the appendix in place.

**If you cannot adequately drain the pus (or there is none present),** perform a formal laparotomy through a midline incision.

## (3) INTERVAL APPENDICECTOMY

If you have treated an appendix mass conservatively or an abscess by drainage, and left the appendix in, there is only occasionally a need for an interval appendicectomy. However, >80% of appendices in this situation fibrose or disappear by autolysis. Finding the appendix may actually be very difficult. It is probably not indicated in HIV disease. If symptoms of right lower abdominal pain recur, however, appendicectomy should be carried out. If initial histology showed tuberculosis or schistosomiasis in the appendix mass, and proper treatment was provided, interval appendicectomy is unnecessary.

***DON'T REMOVE THE APPENDIX AS AN INCIDENTAL STEP DURING ANOTHER OPERATION.***

***DON'T REMOVE A NORMAL APPENDIX.***

## (4) DIFFICULTIES AT APPENDICECTOMY

**If you find greenish fluid in the peritoneal cavity,** it has probably escaped through a perforated duodenal ulcer, and tracked down the right paracolic gutter. Make an upper midline incision and close the perforation (13.3).

**If the caecum is much thickened,** suspect amoebiasis, tuberculosis, or actinomycosis. Insert a drain and treat with metronidazole. Take a biopsy of adjacent tissue or lymph node.

**If you find an appendix mass or the appendix is inflamed,** but is so tied down by adhesions that it is difficult to remove safely, insert a drain and close the wound.

**If the base of the appendix is necrotic,** amputate it because you cannot tie it. This will leave a defect in the base of the caecum: if the margins are healthy, insert a purse-string suture around the edge of the defect and invert it. If the edges are unhealthy, and will not take a suture, make sure you have good enough exposure (if necessary, extend the incision) and remove more of the caecal base till you reach healthy tissue and close the bowel formally. Secure some omentum over the repair, insert a drain adjacent to it, close the muscles of the abdominal wall, but leave the skin open. The alternative, a formal laparotomy and an ileocaecal resection (12.7), is a formidable procedure and, unless you are experienced, may give you more problems.

**If the appendix is buried in a mass of adhesions and pockets of pus,** avoid spreading the infection. Enlarge the incision, lift its medial side forwards, isolate the mass with warm packs, suck out the pus, and remove the appendix if this is not too difficult. Otherwise, leave it, lavage the abdomen thoroughly and put in a drain.

**If you lose the appendix stump or appendicular artery,** enlarge the incision and withdraw the caecum into the wound once more to find the culprit. If this fails, open the abdomen formally by a midline incision.

**If you find a tumour in the caecum,** make a midline incision and perform a right hemicolectomy (12.11).

**If you find a tumour in the appendix tip,** it is likely to be a carcinoid. No further treatment is necessary apart from the appendicectomy, unless there are metastases in the liver.

**If you find a mucocoele of the appendix,** make a midline incision and perform an ileocaecal resection, together with a right oophorectomy (in a woman) and excision of any involved peritoneal surface.

**If the appendix looks normal,** look for other pathology:

(i) If there are enlarged mesenteric nodes, and a clear yellowish serous exudate, suspect mesenteric adenitis, and close. If the nodes are very large or numerous, take a biopsy from one for tuberculosis.

(ii) If you find a purulent exudate, suspect PID in a woman and other causes of peritonitis: make a midline incision.

(iii) If you can feel a tensely distended gallbladder when you pass your finger up through the incision, this may be due to cholecystitis or an obstructed gallbladder. *Don't be tempted to perform a cholecystectomy via a small incision in the right iliac fossa!*

(iv) If there is a tensely distended caecum, there is large bowel obstruction. Make a midline incision and feel for its cause (12.2).

(v) If there is blood in the abdominal cavity, the possibilities include ectopic pregnancy, a leaking ovarian follicle, pancreatitis, trauma, or necrotic bowel: make a midline incision.

(vi) If there is an inflamed Meckel's diverticulum about 1m from the ileocaecal junction, do a bowel resection to remove it. This will probably mean a midline incision.

*If you make a formal laparotomy incision, don't remove a normal appendix, but tell the patient the appendix remains in situ! Don't excise an uninflamed Meckel's diverticulum.*

#### (5) DIFFICULTIES FOLLOWING APPENDICECTOMY

**If shock develops some hours after the operation,** suspect that there is bleeding from the appendicular artery, or that you missed an ectopic gestation. Start resuscitation with IV Ringer's lactate or saline, cross-match blood and re-open the abdomen by a midline incision. Suck out the blood. Locate the caecum, find the artery and tie it, or deal with the ectopic gestation (20.6).

**If the abdomen distends, with vomiting and ileus,** suspect:

(i) Intestinal obstruction (12.15) due to an abscess or to kinking of the bowel. If necessary, drain the abscess, insert a nasogastric tube and manage conservatively (12.16).

(ii) Intussusception (12.7).

(iii) Gram-ve septicaemia and septic shock, with or without generalized peritonitis. If there is tenderness and guarding, re-open the abdomen by a long midline incision and drain the pus. If there is a faecal leak, exteriorize it as a caecostomy (11.6).

**If a faecal fistula develops,** it will probably heal spontaneously in 2-3wks, provided there is no distal obstruction (11.15). If it persists, suspect tuberculosis, amoebic colitis, actinomycosis, or a retained foreign body (a faecolith or retained swab). Check the HIV status. Exclude distal obstruction by doing a barium enema (38.1f).

**If the temperature rises in the 2<sup>nd</sup> week,** accompanied by malaise and local symptoms, there is probably pus somewhere.

(i) There may be a wound abscess.

(ii) There may be a subphrenic abscess (10.2), localized intra-abdominal collection, pelvic abscess (10.3) or a metastatic abscess in the liver (15.10). If there is a mucous rectal discharge or diarrhoea, suspect that there is pus in the recto-vesical pouch. Feel for a boggy inflammatory mass above the prostate, or in a woman's recto-vaginal pouch. Feel also for an inflammatory mass in the abdomen. Get an ultrasound scan (38.2l).

**If the wound continues to discharge,** there may be a non-absorbable suture left behind. Explore the wound and remove any foreign body. There may be a faecolith left behind. Explore the track, irrigate it and flush it out. There may be: (i) amoebiasis, (ii) tuberculosis, (iii) actinomycosis, or (iv) HIV disease.

**If the appendix has a tumour found on histology,** ileocaecal resection is only necessary if it was not completely removed or within 2cm of the resection margin.

**If the appendix shows tuberculosis** macroscopically or on histology, start anti-TB therapy and check the HIV status.

**If the appendix shows schistosoma eggs,** treat with Praziquantel 60mg/kg stat.

**If miscarriage follows surgery during pregnancy,** remember to ensure that the placenta is also delivered. Evacuation is rarely required.

**If a hernia develops in the right lower abdomen,** there is probably a small defect in the closure and you should repair this to avoid bowel strangulation (18.13).

## 14.2 Inflammatory bowel disease

Much inflammatory bowel disease you probably will have difficulty diagnosing; **Crohn's disease** affects the small and large bowel, causing strictures and fistulae, whilst **ulcerative colitis** affects the large bowel and may result in a toxic megacolon like in Chagas disease (12.13). Both may produce loose, blood-stained, mucus-filled stools. They are difficult to treat, needing steroids, sulfasalazine or azathioprine, and IV antibiotics, but fortunately are uncommon in the low- and middle-income countries. Differentiate such diseases from the treatable infective causes of dysentery; a biopsy may be all that you can manage, though you can treat the multiple complex perianal fistulae of Crohn's disease with setons (26.3). Avoid smoking, NSAIDs, opiates and anti-diarrhoeals.

Remember that **schistosomiasis**, **paracoccidiomycosis** and **radiation** >30Gray can also cause inflammatory bowel disease. Generally try to reserve these cases for an expert. Schistosomiasis of all types can cause, in the acute phase, a florid ulcerative enterocolitis with perforation, and with chronic infestation, granulomata, fibrotic strictures and polyps anywhere in the gastrointestinal tract, but especially in the colon. These may result in chronic stricture, intussusception, fistulae and rectal prolapse from persistent straining.

Infective causes are many; typhoid (14.3) is common in endemic areas. **Campylobacter jejuni** affects the caecum and causes lymphadenitis in the terminal ileal mesentery; **Yersinia enterocoli** affects the terminal ileum with similar lymphadenitis. You may be able to diagnose and differentiate these by ultrasound.

People eating Western diets for long periods often develop diverticular disease, where there are weak spots in the wall of the descending and sigmoid colon due to increased intraluminal pressure, usually on account of chronic constipation. These 'blow-outs' or *diverticula* may become inflamed, or stenosed, fistulate, perforate or bleed just like other causes of inflammatory bowel disease.

Ultrasound may help in the diagnosis: the bowel wall will be >4mm thick and if there is an abscess, you will see a poorly defined hypo-echogenic area adjacent.

**Diverticulitis** usually settles with eating restriction, and IV metronidazole and gentamicin or a broad-spectrum cephalosporin. If you are confident that an abscess has formed, you may be able to drain it under ultrasound guidance; but if pain gets worse with tenderness and fever, indicating localized peritonitis, perform a laparotomy.

**If the affected large bowel is inflamed but not perforated**, wash out the abdomen and leave a drain adjacent to the bowel.

**If there is severe large bowel inflammation or perforation with often an adjacent abscess cavity**, resect the affected segment, make a proximal end-colostomy and close the distal end (Hartmann's operation: 12.9), or fashion a mucous fistula if the distal segment is long enough. This may be difficult and bloody surgery, so have blood cross-matched, and proceed carefully. If you are unable to resect the affected bowel, make the proximal defunctioning colostomy as before, and leave in a drain. The inflammation will usually settle but may form an abscess which needs local drainage.

Diverticular disease occasionally affects the ascending colon, and is then more prone to complications. This is found commonly in Southeast Asia. If localized sepsis develops, wash out the abdomen as above; if this is severe, it is reasonable to perform a primary ileocolic resection.

*There is no indication to perform elective surgery for uncomplicated diverticular disease, nor probably for patients who have had several episodes of diverticulitis successfully treated conservatively. However, follow-up with colonoscopy or barium enema to exclude malignancy is wise.*

### 14.3 Typhoid and small bowel perforation

Although typhoid is common in many low- and middle-income countries, perforation seems to occur more commonly in some regions than in others. Where perforation is common (Madagascar, West Africa, particularly Sierra Leone and Ghana), it may be one of the commonest causes of peritonitis. Less often, typhoid can also cause serious intestinal bleeding, cholecystitis, pancreatitis or osteomyelitis.

Typhoid is more common in *Schistosoma* carriers, those with sickle cell disease, and achlorhydria. The disease is seasonal, and is most prevalent in the wet season. It is characterized by high fever (38.5-39.5°C), headache, confusion, bloody diarrhoea and abdominal tenderness. Bradycardia is only present in 1/3, splenomegaly in 1/3 and hepatomegaly in 1/4 of all patients.

A typhoid perforation is seldom dramatic, because loops of diseased bowel stick together, so that the bowel leak remains contained. It is usually difficult to tell exactly when it occurs, unlike the perforation of a peptic ulcer. Often, there may be no specific complaint. The signs will depend on:

- (1) how long ago the bowel perforated, and
- (2) how localized the peritonitis is.

Exactly the same scenario exists with spontaneous bowel perforation due to HIV or lymphoma (17.6), Crohn's disease, Behçet's disease or lupus (the latter common in Southeast Asia): the symptoms and signs are virtually identical, and the same advice holds true.

You will seldom miss a perforation if:

- (1) you examine the abdomen of any patient with typhoid fever and HIV-related abdominal pain twice a day: *perforations which occur in hospital are easily missed.*
- (2) you think of it in any case of acute abdominal pain, with signs of peritonitis, during a febrile illness especially with signs of depressed immunity.

**If there has been toxæmia and fever, with chronic abdominal pain for 2-3wks, and then sudden worsening of the pain**, a typhoid ulcer in the ileum has probably perforated. This usually happens in the 3<sup>rd</sup> week, but can occur in the 1<sup>st</sup> week, or during convalescence. The bowel is oedematous and friable, so surgery may be difficult.

**If a perforation presents insidiously, and appears to be localized**, you might like to opt for a conservative approach, but if the patient deteriorates, surgery will be that much more difficult. If you resuscitate aggressively and operate early, you can reduce the mortality to 3-10%.

*N.B. Salmonella typhi* is now resistant to both chloramphenicol and ampicillin in many areas. So adjust antibiotic treatment accordingly: quinolones are best. Ceftriaxone and ciprofloxacin are alternatives. When a typhoid ulcer perforates, many different bacteria are released into the abdominal cavity, including anaerobes. *S. typhi* is only one of them, and *not the most aggressive*.

Be sure that the staff of your outpatient department watch for typhoid perforations. There must be little delay between diagnosing a perforation and closing it. The prognosis will depend on timely intervention.

#### (a) Special tests

Blood culture is useful but the result will arrive after you have had to start treatment. The Widal test is only helpful if there is a fourfold rise in titre. The Diazo test (visible pinkish froth giving a +ve result) with urine is cheap and most reliable.

#### (b) Diagnosing perforation

Fever and headache at the onset of the illness are followed by vomiting, abdominal pain, and distension. Following perforation, tenderness usually starts in the right lower quadrant, spreads quickly, and eventually becomes generalized. There is usually guarding present, but seldom the board-like rigidity characteristic of a perforated peptic ulcer.

Percuss the lower ribs anteriorly; if there is gas between them and the liver, the percussion note will be resonant (due to the absence of the normal liver dullness).

The bowel sounds may be absent. Hypotension, oliguria, and bradycardia are terminal signs. If possible, culture the stools, if necessary more than once.

**CAUTION!** The bradycardia and leucopenia of typhoid may occasionally mask the tachycardia and leucocytosis of peritonitis.

If presentation is several days after perforation, the diagnosis will be difficult, because abdominal distension will overshadow other signs.

## TYPHOID FEVER

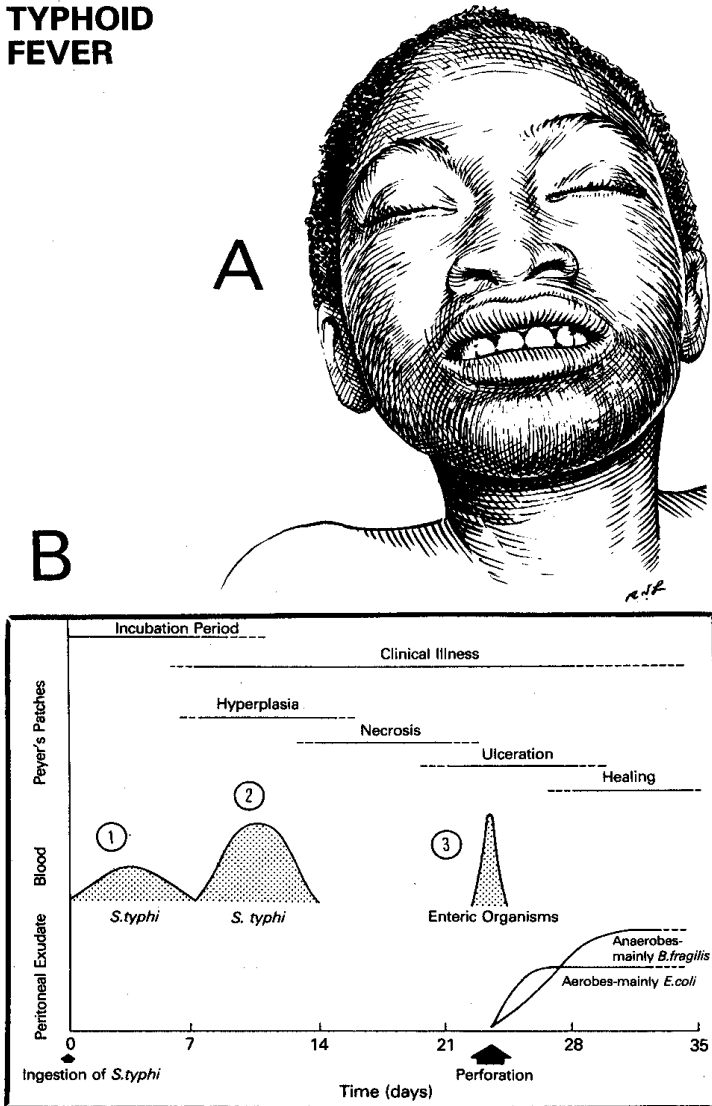


Fig. 14-4 TYPHOID FEVER.

A, characteristic appearance ('typhoid facies') of a patient with typhoid fever. B, bacteriology of intestinal perforation in typhoid fever. (1,2) Note the two phases of *S. typhi* bacteraemia, and (3), the third phase of bacteraemia, with organisms from the bowel, that follows perforation.

After Bitar R, Tarpley J. *Intestinal Perforation in typhoid fever. Rev Inf Diseases* 1985;7:257-271.

**RADIOGRAPHS.** Take an erect chest film, and look for gas under the diaphragm (50% +ve). If the patient is too weak to sit up, take a lateral decubitus film, and look for gas under the abdominal wall. *This is a very useful sign.* You may also see loops of the small bowel dilated with gas, usually without fluid levels.

(c) **Ultrasound.** Look for free fluid!

(d) **Differential diagnosis of bowel perforation** includes appendicitis (14.1), perforations from other causes, such as HIV disease (5.6), tuberculosis (16.6), ascariasis (12.5), schistosomiasis, paracoccidiomycosis, and necrotizing amoebic colitis (14.5).

Tumours of the bowel may also perforate: in the small bowel these are likely to be lymphoma or Kaposi sarcoma; in the large bowel, adenocarcinoma (12.11). Crohn's disease, ulcerative colitis, colonic diverticulitis, and radiation bowel disease are uncommon causes of inflammation and perforation outside the Western world. A perforated peptic ulcer (13.3) and other causes of a septic abdomen (10.1) such as small bowel obstruction from adhesions also of course give rise to peritonitis.

*N.B. Don't forget that unreported trauma may be a cause of bowel perforation, particularly in a child!*

**Suggesting appendicitis:** pain starting over the umbilicus and moving to the right iliac fossa; pain precedes fever.

**Suggesting HIV disease:** cachexia, lymphadenopathy, absent leucocytosis, and other signs of HIV disease (5.5).

**Suggesting tuberculosis:** a cough, cachexia, chest radiographic changes and lymphadenopathy.

**Suggesting ascariasis:** worms seen in the stool or on a radiograph.

**Suggesting schistosomiasis:** large numbers of ova in the stool in an endemic area.

**Suggesting paracoccidiomycosis:** lymphadenopathy, mucocutaneous lesions and chest radiographic changes in Central and South American agricultural workers.

**Suggesting necrotizing amoebic colitis:** a history of diarrhoea (especially with the passage of blood and mucus), followed by acute pain in the right lower quadrant, with guarding and a silent abdomen. Look for *trophozoites* in the stools.

**Suggesting a perforated peptic ulcer:** a sudden onset, and a history of ulcer symptoms.

(e) **Management.** Here are some guidelines:

**If there are signs of localized or generalized peritonitis,** perform a laparotomy.

**If the patient is moribund 36-48h after a perforation,** with a distended or board-like abdomen, a thready pulse, and very low blood pressure (septic shock), pour in large volumes of warmed Ringer's lactate or saline IV by 2 wide-bore cannulae. When the condition improves, perform a laparostomy (10.1) with copious lavage of the abdominal cavity in the first instance.

**If large volumes of melaena stools are passed (or occasionally frank blood),** transfuse blood to replace the loss. Bleeding will probably stop spontaneously. *Only operate if there is persistent or alarming bleeding.* Tranexamic acid 1g IV stat and then 10mg/kg/hr is effective in arresting massive bleeding, and worth starting

before rushing to a difficult laparotomy in an unstable patient. Dexamethasone 3mg/kg/day IV may reduce bleeding from inflammatory ulcers, usually in the distal ileum, but which may be difficult to find. If you do find one, perform an ileocaecal resection (12.7), or clamp the segment of bowel that is bleeding, and perform a 2<sup>nd</sup> look laparotomy after 24h. This is a critical situation.

**(f) Resuscitation** is critical. Be prepared to rehydrate vigorously. You may need to infuse >4L IV fluid. *Don't forget to add potassium lost (1-2mmol/kg/day)*. If the Hb is <70g/L, transfuse blood. Administer oxygen by mask. Monitor the urine output, and maintain the fluid balance. If possible, monitor the CVP. Add vitamin K 10mg od IM for 3-5 days.

**(g) Antibiotics.** Treat with IV chloramphenicol (up to 4g qds in very ill patients) with gentamicin 3mg/kg od; or ceftriaxone 1g od; or ciprofloxacin 500mg bd. Decrease the gentamicin dose if there is renal insufficiency. Add metronidazole 1g as loading dose, followed by 500mg tds.

**(h) Confusion.** Treat with phenobarbitone for a restless patient; avoid sedatives which depress respiration.

**(i) Nasogastric suction** will empty the gas from the stomach, and, hopefully, diminish the distension of the small bowel. Respiratory complications, particularly the aspiration of stomach contents, before, during, or after anaesthesia are an important cause of death.

**(j) Decompress a pneumoperitoneum** by needle aspiration in the right upper quadrant (below the liver) if breathing is severely compromised.

### **(k) Operative treatment**

#### LAPAROTOMY FOR PERFORATED SMALL BOWEL (GRADE 3.4)

**PREPARATION.** Make sure there is vigorous resuscitation already in process, there is a good urine output, there is a nasogastric tube inserted, and you have administered antibiotics.

#### **INCISION**

Make a midline incision, most of it below the umbilicus. As you incise the peritoneum, there will probably be a puff of gas, confirming that some hollow viscus has perforated. *Take care not to cause more perforations*, especially if the bowel is adherent. Aspirate the free fluid. Gently divide the adhesions. Expect to find:

- (1) Greenish ileal contents in the abdominal cavity.
- (2) In typhoid, the last 60cm of ileum inflamed and oedematous, and the adjacent structures somewhat less so. Also, often an inflamed gallbladder (15.3).
- (3) In late cases particularly, dilated loops of jejunum and proximal ileum.
- (4) Soft, soggy mesenteric lymph nodes.
- (5) Lots of purulent fluid.

Start at the ileocaecal junction, hold the bowel very gently with moist laparotomy pads, and work your way proximally until you reach healthy bowel, or the duodeno-jejunal junction. Look for one or more tiny perforations in

the ileum. The jejunum does not perforate in typhoid, but may with HIV. Typhoid perforations are usually on the antimesenteric border of the ileum, not far from the caecum.

*Note each perforation you find*, until you have found them all. There is usually only 1, and rarely >5. Divide any adhesions very gently by sharp or, if they are soft and thin, by blunt dissection.

**CAUTION!** *Handle the bowel with the greatest possible care:* it may come apart in your hands at any moment. If you drop the bowel, start the examination again at the caecum.

*Send any fluid for culture in a blood culture bottle.* When you get a result, alter the antibiotics accordingly.

**If a perforation is small (<1cm)**, freshen its edges if it is sloughy, by excising 1mm of mucosa all round its circumference, and close it transversely with 'all coats' sutures of continuous or interrupted 3/0 absorbable. *If you put them through only part of the bowel wall, they will cut out.* Invert these 'all coats' sutures with a continuous layer of non-absorbable Lembert seromuscular sutures (11-5E), and wrap some omentum around the closure.

**If there is a considerable amount of soiling, and the edges of the perforation are sloughy**, *trying to close perforated inflamed bowel will lead to disaster: it will leak!* You should resect the affected segment of bowel, and either make an end-to-end anastomosis (11-7), or bring both ends of bowel out as cutaneous stomas. (If you open the bowel, and it is very distended, make sure you empty it through the cut you have made, outside the abdominal cavity, into a kidney dish, after protecting the abdomen from contamination.) *Wait till the inflammatory process has settled before attempting to re-anastomose the bowel.*

**If there is a perforated Meckel's diverticulum**, resect the affected segment of bowel: because the inflammation is usually localized (in the area of ectopic gastric mucosa which is present in 50%), you can usually perform an anastomosis.

*N.B. Don't be tempted to remove a normal appendix.*

**If the perforation is jejunal**, pass a nasojejunal tube past the perforation for post-operative enteral feeding: if you use a fine tube, this is much more comfortable for the patient, and you can insert a nasogastric tube as well adjacent to it to empty the stomach in the immediate post-operative period. *(This can only be done for proximal small bowel perforations.)*

**If there is matted bowel with one or more perforations**, which you may not be able to see, and you fear that manipulating the friable bowel will cause worse problems, you can simply drain the area in the hope that a controlled fistula will result.

**If there are multiple perforations, or a large perforation, or a severely diseased discrete segment of bowel, or if there is alarming bleeding**, resect the diseased segment, and perform an end-to-end anastomosis (11-7). Exteriorize this, because it may well fall apart. An alternative is a mandatory second-look laparotomy (10.1).

If there is reasonable length of normal bowel proximal to the perforation, insert an ileostomy tube (or a Foley

catheter) through it. Fix it in place with a purse-string suture, correct fluid losses post-operatively, and then when the fistula track has matured (2-3wks), remove the tube and allow the fistula to close. (*You can only do this for distal small bowel perforations.*) Alternatively, make a formal proximal defunctioning ileostomy (11.6) to divert the intestinal contents. Do this where *presentation is late, with a localized collection of pus.*

**If there are nodes or peritoneal nodules present**, take a biopsy of a node or piece of mesentery for TB examination.

*Remember there will be much fluid loss, and excoriation of the skin will be difficult to prevent.*

**If peritonitis is localized**, perform a local toilet only, and avoid spreading infection to the rest of the abdominal cavity.

**If peritonitis is generalized**, wash out the entire abdominal cavity several times with several litres of warm fluid.

**CLOSE THE ABDOMEN** completely without drains. Leave the skin open, for secondary closure later (11.8). If sepsis is severe, leave the abdomen open as a laparostomy (11.10).

**POST-OPERATIVELY.** Chronic pre-existing illness and pre-operative metabolic abnormalities will still be imperfectly corrected. Manage as for other kinds of peritonitis. Monitor daily for the early detection of collections of intra-abdominal pus. Continue chloramphenicol (or better, quinolones) at ordinary, rather than high, doses for 2wks. This will help to combat typhoid, but not necessarily peritonitis. Add metronidazole. Fever usually subsides in 4-5 days.

#### (1) Difficulties with small bowel perforation

Be prepared for:

- (1) wound sepsis (11.13),
- (2) a burst abdomen (11.14),
- (3) intestinal obstruction (12.2),
- (4) intra-abdominal sepsis (10.1),
- (5) fistulae (very serious, 11.15),
- (6) anaemia and difficult nutrition and hospitalization,
- (7) respiratory complications (11.12) especially, and
- (8) an incisional hernia (18.13).

**If you don't find a perforation**, there may not be one, and the peritonitis may be primary (haematogenous), or from some other cause. It is doubtful if typhoid ever causes peritonitis without perforation, but primary peritonitis is common especially with HIV.

**If there is severe diarrhoea** about the 4<sup>th</sup> day, it will be very difficult to treat, and may be fatal. Replace the fluid loss energetically, and *don't forget to add potassium.*

**If there is renewed pain**, with post-operative deterioration, suspect that there is another perforation. Perform a re-laparotomy, leaving the abdomen open (11.10).

**If there is a sudden spike of fever** after about 5 days, when there should have been recovery from the typhoid, suspect wound infection (11.13), a subphrenic abscess (10.2), pelvic abscess (10.3), pneumonia, or an intestinal leak (11.15).

## 14.4 Necrotizing enterocolitis

(Pigbel, *Darmbrand*)

Like typhoid fever, necrotizing enterocolitis (pigbel or *darmbrand*) is much more common in the tropics, but is occasionally seen elsewhere. It is probably due to the  $\beta$ -toxins of *Clostridium perfringens* type C which multiply in the bowel following a large meal, classically a feast of pork (hence its New Guinea name 'pigbel'), especially where there is trypsin and chymotrypsin deficiency. This occurs with ingestion of sweet potato especially and threadworm infestation which inhibit trypsin secretion, and protein malnutrition where chymotrypsin levels may be undetectable. The result is a patchy necrosis of the small and/or large bowel.

This was at one time, before vaccination against  $\beta$ -toxin, the commonest condition requiring laparotomy in New Guinea. It also occurred in Germany in chronically starved people who were given a large meal, hence the term *darmbrand*, meaning 'burning bowel'. A virtually identical condition is seen in HIV patients, and occasionally after feeding through a jejunostomy (11.7). There may be associated mesenteric venous thrombosis (12.14).

**If bowel needs resecting**, the chances of death are c.50%. This condition in premature neonates is discussed in 33.2.

Presentation is usually in a child, or young adult, with:

- (1) Acute toxemia.
- (2) Severe colicky abdominal pain and vomiting.
- (3) Constipation with foul flatus, followed by bloody diarrhoea.
- (4) Continued vomiting often with blood, and abdominal distension.
- (5) An obscure abdominal illness, ending in a pelvic abscess that is the result of a perforation.
- (6) Rectal bleeding (26.4).

Typically, the abdomen distends with generalized tenderness, sometimes with a soft mass above the umbilicus. The patient is ill and may have a high fever. There may be erythema of the abdominal wall.

**(a) Radiographs.** An early sign is intramural gas seen in the bowel; later, a single dilated loop of bowel is highly suspicious; multiple fluid levels on an erect film, with gas in the large bowel down to the rectum, indicate peritonitis. Free gas under the diaphragm indicates a perforation of the bowel.

**(b) Special tests.** Leucocytosis (unlike the leucopenia of typhoid) is usual, unless there is HIV disease. An abdominal tap may reveal bloody peritoneal fluid.

(c) **Ultrasound.** Look for free fluid and gas in the portal vein!

(d) **Differential diagnosis**

**Suggesting intussusception** (12.7): the presence of a tender abdominal mass and bloody mucoid stools.

**Suggesting ischaemic colitis:** tests confirming sickle cell disease, or an elderly patient with aortic vascular disease.

**Suggesting ulcerative or Crohn's colitis** (14.2): a more chronic illness, especially in a wealthier patient.

**Suggesting amoebic colitis** (14.5): the presence of *Entamoeba histolytica* in the stools.

(e) **Non-operative treatment** may succeed.

Resuscitate aggressively. Pass a nasogastric tube and treat with large doses of penicillin (6MU IV stat, then 2MU IV qds) and metronidazole IV 1g tds. If the patient is too ill to undergo laparotomy, perform a percutaneous peritoneal lavage. Blood transfusion may be necessary.

*N.B.* The disease in infants is somewhat different (33.2).

(f) **Operative treatment**

**INDICATIONS**

- (1) Failure to improve, or deterioration on non-operative treatment.
- (2) Signs of peritonitis, and persistently large volumes of gastric aspirate.

**LAPAROTOMY FOR NECROTIZING ENTEROCOLITIS (GRADE 3.4)**

You may see the disease at any stage in its development. It usually only involves the small bowel, but it may involve the distal stomach, or the large bowel. Classically, several loops of the small bowel, from near the duodenal flexure onwards, are acutely inflamed, oedematous, and congested, often with localized necrotic areas mostly on the antimesenteric border, with a sharp line of demarcation between normal and diseased areas. There may be perforations, localized abscesses, and multiple adhesions causing partial obstruction. The necrotic areas are usually separate, but may occasionally extend from the distal stomach to the sigmoid colon. The mesenteric artery is patent, and you can feel pulsation down to the terminal arterioles at the margin of the affected bowel. The regional nodes are enlarged, and may be necrotic.

**Only if any bowel is non-viable** (11.3), resect it with an adequate margin of healthy bowel, so that the blood supply to the area of the anastomosis is adequate.

**If there is no sharp demarcation of healthy and affected bowel,** make a double-barrelled enterostomy (11.5). Wash out any infection liberally. If you have removed a considerable length of the small bowel, follow up carefully, and treat any small-bowel deficiency that

may develop with multivitamins, codeine phosphate, and cimetidine.

**If you decide to leave inflamed but not obviously necrotic bowel,** plan a routine second-look laparotomy in 48h, and resect any gangrenous bowel.

(g) **Prevention.** In endemic areas, war zones and famine regions, prevent necrotizing enterocolitis by vaccination with attenuated  $\beta$ -toxoid; this gives good immunity.

## 14.5 Amoebiasis: surgical aspects

Amoebiasis has some surgical complications, ranging from the very acute to the very chronic. They usually involve the bowel, but the liver (15.10), or occasionally the lungs, or even the skin can be involved. Amoebiasis is common, and no age is immune; amoebae may invade the bowel of babies. It is less often seen in women, but in pregnancy it can be fulminating.

*Entamoeba histolytica* normally lives harmlessly in the colon, but *trophozoites* occasionally invade its mucosa to cause shallow discrete circular or oval ulcers, with yellow sloughs in their bases, and sometimes red edges. These ulcers are most common in the caecum and ascending colon, the sigmoid colon, and the rectum. They cause diarrhoea, with or without blood, pus, and mucus.

The lesions in the bowel are usually quite superficial, but if immunity is low, amoebae may invade more deeply, especially in the HIV+ve, the pregnant, the diabetic, the alcoholic or recently severely injured patient. Invasive intestinal amoebiasis may cause massive mucosal necrosis of the colon, so that large pieces of it separate as casts, and are passed rectally. Alternatively, sloughing, gangrene and perforation result in an acute necrotizing amoebic colitis.

Bacterial infection may then spread as generalized peritonitis, or it may remain localized as a pericolic abscess which you can feel as a tender mass. Peritonitis may develop without actual perforation, or the bowel can perforate extra-peritoneally. As a result of this suppuration, bowel may obstruct, or develop an ileus. Occasionally, the colon bleeds severely, or distends massively as a toxic megacolon.

**If amoebiasis is more chronic,** there may be:

- (1) An amoeboma; this is a diffuse, oedematous, hyperplastic granulomatous swelling anywhere in the colon or rectum, which is often multiple, and may be palpable, and may obstruct the bowel (usually temporarily). Although an amoeboma may form anywhere, a mass in the caecum is more easily palpable. If you do feel a mass in a patient with amoebiasis, it is more likely to be a paracolic abscess than an amoeboma.
- (2) A fibrous post-amoebic stricture, which is one of the end results of an amoeboma. An amoeboma and a stricture are two stages in the same process, and there may be a lesion with some of the features of both. Both are common

in some areas (e.g. Durban, South Africa), and are the late, chronic complications of amoebic colitis; they occur years after the initial bloody diarrhoea, and are less serious than acute invasive amoebiasis.

The stricture usually involves the rectum (where you can feel it), the sigmoid, and the descending colon, in that order. All can cause diarrhoea and other abdominal symptoms, and obstruct the large bowel, usually incompletely.

#### (a) Treatment

Treat with metronidazole 800mg tds for 5 days and diloxanide furoate 500mg tds for 10 days. In severe disease, add doxycycline 100mg bd for 5 days.

#### (b) Invasive intestinal amoebiasis

If amoebae are invading the wall of the bowel, the danger is that it may perforate. If you can make the diagnosis before it has done so, metronidazole will probably be effective. Necrosis of the bowel wall in fulminant amoebic colitis is commoner in pregnancy, HIV disease, diabetes mellitus and the severely injured.

When the bowel has perforated, treatment is much more difficult. There are 3 forms of perforation:

- (1) An extraperitoneal ('sealed') perforation.
- (2) The perforation of an amoeboma, or an amoebic ulcer, into the abdominal cavity, in the absence of acute dysentery.
- (3) A similar perforation in the presence of acute dysentery (this is rare in patients on metronidazole).

Presentation is usually with an 'acute abdomen', but diagnosing that invasive amoebiasis is causing it is difficult pre-operatively.

Typically, there is abdominal pain, fever, diarrhoea, and pain in the right iliac fossa. Often, there is a history of diabetes, alcoholism, pregnancy, or trauma. On examination, you find a mass in the right iliac fossa, or rigidity masking its presence, and often a distended abdomen.

**If amoebiasis is endemic from where your patients come**, think of this as a likely diagnosis. It is better to start treatment on suspicion, than to miss a treatable disease. If possible, treat non-operatively. Avoid surgery if you can, because the colon will be friable and difficult to suture. Fortunately, surgery is usually unnecessary, because the perforation will probably have been localized by the diseased colon sticking to the surrounding small bowel and omentum.

**If there is generalized peritonitis** because the perforation has not sealed off, operation is mandatory even though the risks will be great.

At laparotomy you may find:

- (1) A large inflammatory mass in the region of the caecum. This is more likely to be a paracolic abscess than an amoeboma.
- (2) Greyish patches in the caecum.

(3) Multiple and often adjacent perforations, mostly in the caecum and sigmoid colon.

(4) Inflammatory lesions elsewhere in the large bowel.

(5) A hugely dilated megacolon.

(6) A single stricture usually in the anorectum or rectosigmoid.

SAROJ (45yrs) was admitted with a history of fever, bloody diarrhoea, abdominal pain, and a tender right suprapubic mass. Scrapings from typical amoebic ulcers in her rectum showed *trophozoites*. After only 2 days' treatment with metronidazole, she felt better, her diarrhoea improved, and her abdominal mass started to resolve.

MIRANDA (46yrs) had fever, diarrhoea, and vague abdominal pain for several weeks, worse during the last few days. She had a tender indurated mass in her right lower quadrant. At laparotomy, she had acute necrotizing colitis of her caecum, with multiple perforations, and much sloughing tissue. After a rigorous washout of the abdomen, an ileostomy, and tying off the distant colon, she recovered slowly.

LESSONS (1) Patients often respond to metronidazole rapidly. (2) When surgery is indicated, it is difficult.

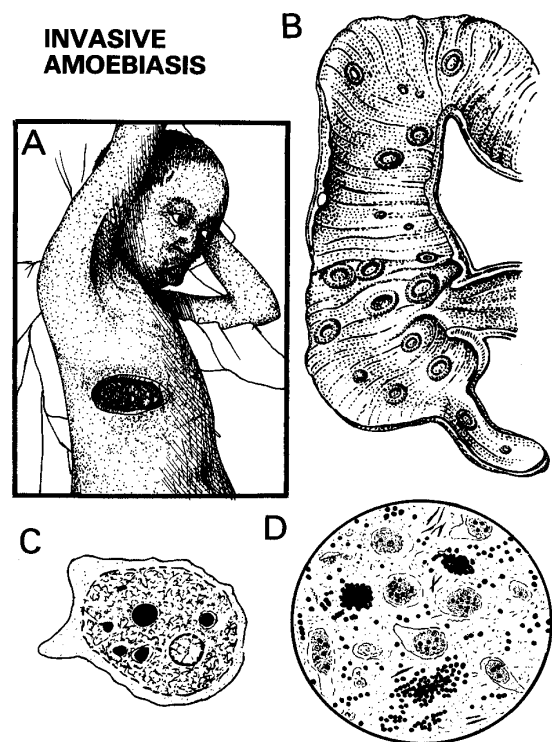


Fig. 14-5 INVASIVE AMOEBIASIS.

A, an amoeboma of the skin secondary to a liver abscess. B, the caecum and ascending colon with amoebic ulcers (seen in cross-section). C, *Entamoeba histolytica*. D, an amoebic stool with trophozoites, red cells and Charcot-Leyden crystals.

A, after Bowsman C, *Surgery & Clinical Pathology in the Tropics*, Livingstone 1960 with kind permission.

N.B. Avoid these mistakes:

- (1) Don't attempt a right hemicolectomy and ileocolic anastomosis, which is more difficult, and more dangerous.
- (2) Don't try to oversew a perforation: a necrotic colon will not hold sutures.
- (3) Don't attempt a primary anastomosis.

**If there is severe sepsis**, perform damage-limiting surgery. Repairing a perforation is impossible, because the whole colon is usually affected, very friable and adherent to other organs. But, if the bowel has perforated, you must

divert the faecal stream somehow and remove the source of sepsis. Resection and exteriorization is a bloody procedure which is heroic surgery, but it does relieve obstruction, and remove the focus of infection. Ileostomy is the better option initially, combined with drainage of the caecum by a tube; you may need, however, later to remove the affected bowel once there is some improvement in the general condition. Whatever you do, *the danger is that the caecum will burst and flood the peritoneum with faeces, so try to avoid this.*

### (c) Special tests

Examine warm stools for *trophozoites*, and look for amoebic ulcers with a sigmoidoscope. Take a scraping and examine it for amoebae. Take a biopsy of the adjacent mucosa and send it for histology. Look for the cysts of *E. histolytica* in the stools. Only some strains are invasive, but unfortunately it takes a sophisticated laboratory to tell which ones.

**CAUTION!** You will not always find amoebae, so *don't be misled by a negative finding*. If the patient is engaging in anal intercourse, check the sexual partner.

**(d) Ultrasound** may reveal dilated colon, or a mass in the right iliac fossa (an amoeboma).

**(e) Differential diagnosis** includes:

**Suggesting a typhoid perforation:** a 2wk history of fever and vague abdominal pain, which becomes acute when the bowel perforates; intestinal bleeding is uncommon.

**Suggesting ileocaecal tuberculosis:** often HIV+ve, usually (but not always) less sick than with amoebiasis. The mass in the right lower quadrant is not so large, or tender (unless it has perforated). The course of the disease is usually more chronic.

**Suggesting an appendix abscess:** pain which starts centrally and then moves to the right lower quadrant; no history of diarrhoea, especially no bloody diarrhoea; less toxic, and not so sick as with amoebiasis. The distinction is not important, because both need a laparotomy.

**Suggesting intestinal paracoccidiomycosis:** a male agricultural worker in Central/South America with lymphadenopathy and skin lesions, complaining of weight loss, anorexia, headache and fever. Sigmoidoscopic biopsies show granulomas which include *P. braziliensis*.

**Suggesting carcinoma of the caecum:** not so ill, or so toxic, often with rectal bleeding, which may be occult, presenting with anaemia. The mass is firm to hard, but not particularly tender. Subacute obstruction is more common.

**Suggesting ulcerative colitis:** the history is usually longer, in a wealthier and better-nourished patient with no *E. histolytica* found despite an extensive search. Previous response to steroids and sulfasalazine is typical.

### (f) Non-operative treatment for invasive amoebiasis

**INDICATIONS.** Manage non-operatively if you can, especially if there is:

- (1) An amoebic perforation of the large bowel, producing *localized* peritonitis, as indicated by a mass.
- (2) A critical illness with prolonged fever, diarrhoea, toxæmia, and peritonitis unfit for surgery.
- (3) Simple amoebic appendicitis.

### METHOD

Correct the dehydration, hypovolaemia, and oliguria, and especially the hypokalaemia. If there is much blood lost, replace it. Insert a nasogastric suction tube. Monitor the vital signs.

Chronic diarrhoea can cause severe potassium deficiency (resulting in confusion, weakness, hypotension, and ileus) which you can correct simply, and dramatically improve the 'toxic' state. Treat with IV metronidazole 800mg tds, (or 7.5mg/kg tds for a child) and chloramphenicol or gentamicin. Alternatively use metronidazole 1g rectally tds. Mark the outline of the mass on the skin, before you start treatment. Note how tender and indurated it is. Thereafter, examine it 8hrly. If it increases in size, becomes more tender, especially with guarding, perform a laparotomy.

### (g) Operative treatment for invasive amoebiasis

**LAPAROTOMY FOR INVASIVE AMOEBIASIS (GRADE 3.5)**

### INDICATIONS

- (1) Frank peritonitis.
- (2) Failure of non-operative treatment.

### PREPARATION

Resuscitate thoroughly, and follow all the steps described above for non-operative treatment: this is critical. Under GA when the muscles are relaxed, examine the abdomen again, and perform a careful sigmoidoscopy. This may confirm the diagnosis, and determine if the sigmoid colon is disease-free. *Take great care yourself not to cause a perforation!*

### EXPLORATION

Make a midline incision. Open the abdominal cavity, and examine it as for peritonitis (10.1). Gently feel for a mass. If there are greenish-grey, gangrenous patches on the soggy, soft caecum, your diagnosis of invasive amoebiasis was correct. It may fall apart and leak as you touch it. If the whole colon looks oedematous and inflamed, this may also be invasive amoebiasis, but in an earlier stage.

**If there is extensive caecal amoebiasis,** perform an ileostomy (11.6). This is easier and less dangerous than trying to manipulate the caecum to exteriorize it. Insert a drain to the right iliac fossa. If the caecum has perforated, aspirate the spilt faecal contents, pack off the rest of the abdominal contents, and insert a large Foley catheter through the perforation into the distal bowel.

**If the large bowel has ruptured extraperitoneally** (unusual), drain it *via* large tube drains through stab incisions in the flanks.

**If you find generalized peritonitis**, with no obvious local lesion, lavage the peritoneum thoroughly with warm water. Close the wound, and rely on metronidazole to effect a cure. *Don't try to break off adherent fibrin, which may have sealed off a colonic perforation.*

**If the whole colon shows necrotic patches**, which look as if they are about to perforate, perform an ileostomy. Plan a second-look laparotomy unless the condition dramatically improves.

**If distension is excessive**, a toxic megacolon has developed. The bowel is extremely friable and will come apart in your hands, with surprisingly little bleeding. Gently pack away the rest of the abdominal contents, and lift out the diseased colon. You will not be able to use clamps, so be prepared for some faecal spillage and minimize its effects.

Perform a proximal colostomy (or ileostomy) and bring out any distal disease-free portion as a mucous fistula, or close it off. It is probably best to leave the abdomen open (11.8), and close it later.

*CAUTION!* Remember to lavage the abdomen with plenty of warm water. Restore bowel continuity after recovery from the acute disease.

#### **(h) Difficulties with intestinal amoebiasis**

**If there is a mass in the large bowel**, *don't forget the possibility of an amoeboma*. This usually responds rapidly to metronidazole, sometimes in only a few days.

**If there is a stricture**, remember the possibility of post-amoebic fibrosis. You may need to dilate it with your finger, or through a sigmoidoscope. If you cannot do this, you may have to perform a proximal colostomy, or resect the stricture. Because amoebomas and post-amoebic strictures are so rare in some areas, the danger is that you may think that this is a carcinoma. If you are in any doubt, try metronidazole, and take a biopsy.

**If you find a regular, firm, sausage-shaped mass in the large bowel**, remember the possibility of intussusception (12.7). You may find that it has ulcerated, but the ulcers are unlikely to be amoebic.

**If there is severe bleeding from the colon**, this may be fatal, because at laparotomy it may look normal externally, so that you will not know where the blood is coming from. Perform a Peep test (26.4). Arrange a colonoscopy if you can. If the bleeding does not stop with IV tranexamic acid and/or installation of cold water, perform a colectomy of the affected segment.