

# 15 Gallbladder, pancreas, liver & spleen

## 15.1 Introduction

The gallbladder may be diseased due to stones, *ascaris* (15.6), infection *per se*, tumour or volvulus. The frequency of these diseases varies from region to region, but stones are more common in women than in men, and especially in obese, parous women >40yrs (*fat, fertile, female over forty*). Gallstones are found in c.80% of adults with sickle cell disease. Many patients are found at postmortem to have gallstones which have caused no symptoms. *Just because someone has gallstones, they may not be the cause of dyspepsia!* Stones or thick biliary sludge may however pass into the common bile duct and cause biliary colic, or obstructive (cholestatic) jaundice. Stones can promote infection of the gallbladder and cause acute or chronic cholecystitis, although this can arise *de novo* especially with HIV disease. Stones, especially in the form of gravel (sludge), can also promote infection in the biliary tree, especially in association with obstruction (cholangitis, 15.7), though this may also arise *de novo*; they can also obstruct drainage of the pancreas and cause pancreatitis. Rarely stones may fistulate into the small bowel and cause obstruction therein.

You can usually treat acute cholecystitis non-operatively (15.3), but if this fails, you can drain the gallbladder by doing a cholecystostomy. If you are experienced enough, you can treat chronic cholecystitis by removing the gallbladder (15.8). If obstructive jaundice is due to carcinoma of the head of the pancreas, you may be able to relieve the symptoms by bypassing the obstruction and performing a cholecystojejunostomy (15-5), but the situation is more complicated if the obstruction is due to gallstones, *ascaris*, *clonorchis sinensis* (Chinese liver fluke) or tumour obstructing the bile duct.

You can usually treat acute pancreatitis non-operatively (15.13), but a pancreatic abscess (15.15) and a large pancreatic pseudocyst (15.14) need drainage.

You will not be able to remove a pancreatic carcinoma, which may be very difficult to differentiate from chronic pancreatitis. Likewise you will not be able to remove tumours of the liver whether primary (hepatoma) or secondary except with sophisticated equipment, and only when presenting early. However, you will be able to treat hepatic tuberculosis. You may have to drain liver cysts, and may need to remove large hydatid cysts carefully (15.12). You may need to drain liver abscesses especially if they are large (15.10), and likewise splenic abscesses (15.18), which you can usually best deal with by splenectomy. This is also indicated for a number of diseases, other than for trauma (15.17). Splenic tuberculosis is usually only diagnosed after you have removed the spleen!

## 15.2 Biliary colic

Biliary colic is due to a stone or sludge impacting in the cystic duct. Very rarely it may be due to volvulus of the gallbladder. There is severe colicky epigastric pain which radiates to the right subcostal region and right scapula. The patient wants to bend herself double, she rolls around, and rarely keeps still. Intense pain comes in waves against a background of a dull ache, typically in attacks lasting about ½h, 1-3h after a fatty meal. Pain makes breathing difficult and may be accompanied by nausea and vomiting. Attacks occasionally last as long as 6h. If unrelieved >24h, cholecystitis develops. There may be tenderness in the hypochondrium or the right epigastrium, giving a +ve Murphy's sign (15.3).

ULTRASOUND is a simple, cheap and accurate way of finding stones in the gallbladder, whether or not there is jaundice: they cast an 'acoustic shadow' behind them (38-5). Occasionally you might find *ascaris* in a bile duct (15.6).

*N.B. RADIOGRAPHS. Most gallstones don't show up, so a plain film is unlikely to help.*

### DIFFERENTIAL DIAGNOSIS OF BILIARY COLIC

**Suggesting ureteric colic:** pain radiating towards the groin and genitalia. Blood in the urine on microscopy. Radio-opaque calcifications on abdominal radiographs along the line of the ureter.

**Suggesting right basal pneumonia:** cough, fever, and lung signs at the right base.

**Suggesting upper small bowel obstruction:** central colicky pain with profuse unrelieved vomiting.

NON-OPERATIVE TREATMENT OF BILIARY COLIC  
Treat with pethidine 50-100mg 3-hrly IV or IM, for 24-48h. Hyoscine 20mg may help.

Restrict to clear fluids only by mouth. If vomiting ensues, replace fluids IV.

Normally, pain will stop in 24-48h, and you can start feeding cautiously, avoiding oily or fatty foods.

**If symptoms persist >24h with tenderness in the right hypochondrium,** acute cholecystitis has developed.

## 15.3 Acute cholecystitis

Symptoms are often initially those of biliary colic (15.2), but they last >24h and pain becomes constant. There is a very good chance of recovery in 10 days, even without treatment. There is a 5% chance that

- (1) the infection will build up in the gallbladder to produce an empyema,
- (2) peritonitis will develop,
- (3) a fistula into bowel will occur from a perforation of the gallbladder.

Recurrent episodes of cholecystitis are likely in >50%.

In HIV disease, the gallbladder can be markedly inflamed *without the presence of stones* (acalculous cholecystitis). This is due to *cryptosporidia* or *cytomegalovirus* in 20%, and produces an ischaemia of the gallbladder wall. Infection may also be present with *salmonella*; in typhoid, organisms infect the gallbladder but cholecystitis is often masked by generalized peritonitis. Cholecystitis without stones may also be caused by brucellosis, dengue, leptospirosis and *campylobacter*.

Stones may be in the gallbladder but also in the bile duct and cause partial or complete obstruction with jaundice or cholangitis. Biliary debris at the sphincter of Oddi may result in pancreatitis.

Operate if:

- (1) there is cholangitis which is life-threatening,
- (2) the gallbladder forms a gradually enlarging acute inflammatory mass,
- (3) there are repeated attacks leading to chronic cholecystitis.

The acutely inflamed gallbladder is oedematous, and perhaps gangrenous, and often adherent to surrounding structures, *so don't try to remove it unless you are experienced*. Instead, drain it (cholecystostomy). This may be life-saving and is simple and safe, but it may not cure the disease permanently, so you may have to think of a cholecystectomy later.

*N.B. Never try to repair a perforation in an inflamed gallbladder.*

Repeated attacks of acute inflammation are usually less severe than a typical acute attack. Symptoms may subside without infection and leave the gallbladder shrunken and fibrosed. However, if a stone remains impacted in Hartmann's pouch (15.4, 15-3M), the gallbladder will distend with fluid (mucocoele of the gallbladder) and if this becomes infected, the subsequent distension with pus (empyema of the gallbladder) may cause it to burst.

## SIGNS

The patient is febrile, looks sick, and lies still. There is well-localized tenderness in the right upper quadrant. There may be exquisite tenderness (unlike biliary colic), with guarding and rigidity. Murphy's sign is usually +ve:

### MURPHY'S SIGN

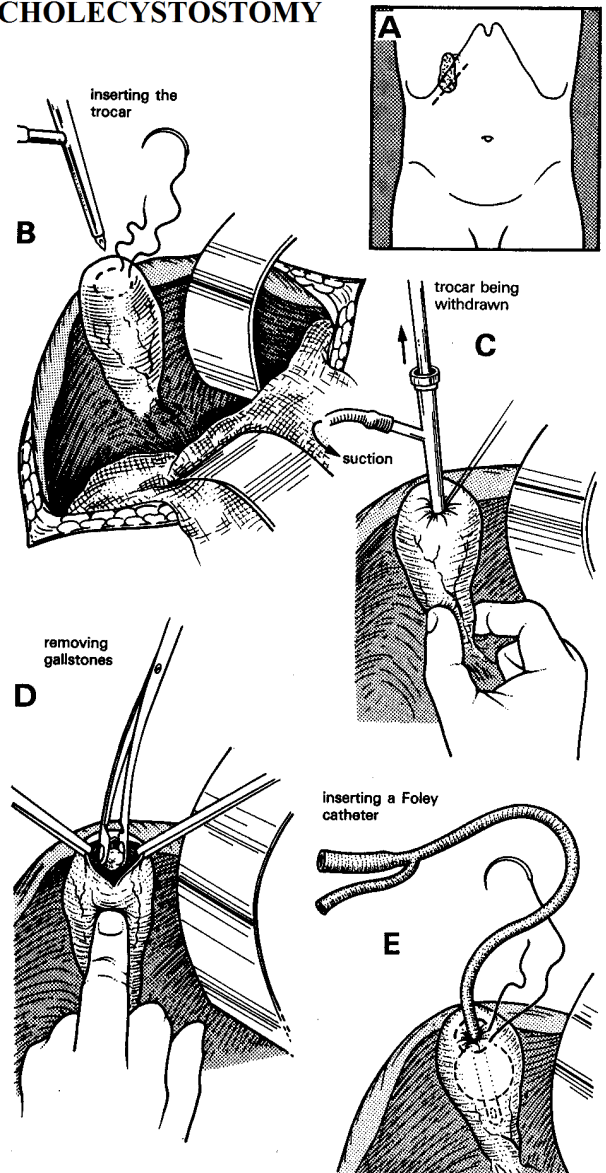
Put your hand under the ribs on the right side, and ask the patient to take a deep breath. If he feels pain as the gallbladder moves down on to your hand, the sign is +ve and indicates cholecystitis.

A well-localized mass sometimes forms a few days after the start of the attack, just below the right costal margin. Mild jaundice does not always mean that the common bile duct is obstructed by a stone. If there is jaundice, swinging fever, chills and rigors, however, suspect cholangitis.

**SPECIAL TESTS.** There is a leucocytosis, unless there is untreated HIV disease. The serum bilirubin and alkaline phosphatase will only be raised if there is obstruction of the biliary tree. The amylase and lipase are raised in pancreatitis.

**ULTRASOUND.** Gallstones readily show up with an 'acoustic shadow'. With experience you will be able to see if the common bile duct is dilated and if more stones are found inside the duct. The presence of stones may imply cholecystitis, *but does not prove it*. To confirm the diagnosis, you need to see a thickened gallbladder wall and/or fluid around the gallbladder (38.2c).

## CHOLECYSTOSTOMY



**Fig. 15-1 CHOLECYSTOSTOMY.**

**A, right subcostal (Kocher's) incision. B, insert a purse-string suture. C, aspirate the gallbladder. D, remove the stones. E, insert a Foley catheter.**

*Kindly contributed by Gerald Hankins.*

## DIFFERENTIAL DIAGNOSIS OF ACUTE CHOLECYSTITIS

**Suggesting liver abscess (15.10):** tender hepatomegaly with fever and previous diarrhoea and dry cough.

**Suggesting perforated peptic ulcer (13.3):** sudden onset of extreme constant pain, with previous dyspepsia.

**Suggesting acute pancreatitis (15.13):** pain radiating to the back, with alcohol abuse.

**Suggesting acute pyelonephritis:** pain in the flank associated with urinary frequency, haematuria and previous ureteric colic or *schistosomiasis*.

**Suggesting volvulus of the small bowel with strangulation** (12.8): initial colicky pain which then became constant, associated with abdominal distension, tenderness and guarding.

**Suggesting perihepatitis** (Curtis-Fitzhugh syndrome): previous episodes of PID, especially with HIV disease.

**Suggesting haemorrhage in a liver tumour:** tender knobby hepatomegaly with weight loss and anorexia.

#### NON-OPERATIVE TREATMENT FOR ACUTE CHOLECYSTITIS

Make sure of the diagnosis with ultrasound (38.2c) and repeated examination. Perform an OGD (13.2) if you can, to exclude reflux oesophagitis, gastritis or peptic ulceration as differential diagnoses.

Treat pain with enough opioid: *e.g.* pethidine (50-100mg 3hrly). Nasogastric suction is not essential, but it will keep the stomach empty and so relieve nausea and vomiting. Keep nil orally. Correct the initial fluid loss with IV saline.

Antibiotics are less necessary than you might expect, because the inflammation in the gallbladder is primarily chemical. However, they probably reduce complications: treat with chloramphenicol (or gentamicin), ampicillin, or doxycycline. Continue this treatment till the pain and pyrexia settle; then introduce oral fluids and after this allow a fat-free diet. Symptoms should start to improve after 24h, and disappear in 3wks. Advise a low-fat diet, and review after 2-3 months.

**If the patient is pregnant,** lean towards conservative treatment to allow the pregnancy to reach term or near-term if at all possible.

**If symptoms recur,** repeat the treatment for acute cholecystitis. When things have settled, think about an elective cholecystectomy, usually six weeks afterwards, if stones are definitely present. *Don't operate for acalculous cholecystitis* unless there is marked tenderness and you fear imminent perforation.

### 15.4 Empyema of the gallbladder

When cholecystitis gets worse, the gallbladder enlarges and becomes a tense inflammatory mass. This may occur if the cystic duct is obstructed with a gallstone, or secondary to carcinoma. The gallbladder fills with pus and so becomes an empyema; it then may perforate, resulting in septic biliary peritonitis which is frequently fatal.

The patient is sick, pyrexial, lies still and has a painful tender mass in the right hypochondrium below the liver. There may be a known history of gallstones, but usually *not* of jaundice.

**SPECIAL TESTS.** Leucocytosis progresses from earlier in the disease. Amylase is usually normal.

**ULTRASOUND.** The gallbladder is filled with turgid fluid, and often gallstones; its wall is thickened (38.2c). Aspiration may relieve some symptoms in a very sick patient, *but is not a lasting solution*.

#### CHOLECYSTOSTOMY (GRADE 3.3)

**INDICATIONS.** Drain the gallbladder if:

- (1) intense pain persists with swinging fever,
- (2) abdominal tenderness gets worse, the area of guarding extends, or the mass increases in size, both suggesting an empyema of the gallbladder,
- (3) there is cholangitis with a distended gallbladder (15.7),
- (4) the patient is too sick to undergo a cholecystectomy.

**ANAESTHETIC.** If the patient is very sick or very old, you can operate under LA, especially if the gallbladder is tense and easily palpable under the abdominal wall.

**PREPARATION.** Make sure your suction is working properly. Treat with gentamicin and metronidazole.

**INCISION.** Feel for the area of maximum tenderness, an ill-defined mass, or both (15-1A). Centre the incision over this area, and cut through all layers of the abdominal wall 2cm below and parallel to the line of the costal cartilages. You will probably find the gallbladder easily. If you don't find it, carefully separate the adherent omentum and transverse colon by pushing them away with your finger. Pack the rest of the abdominal contents away from the inflamed gallbladder. This will be easier if you tilt the table feet down. *Handle the gallbladder carefully; it easily ruptures and spills infected bile into the peritoneal cavity.*

If the structures below the right lobe of the liver are matted together in an oedematous haemorrhagic mass, so that the gallbladder is difficult to find, insert your hand over the upper surface of the liver, and draw your fingers down until you reach its edge. Then move your hand medially over the convex surface of the liver until you reach the falciform ligament, joining the liver to the diaphragm. At its lower edge is the *ligamentum teres*. About 5cm to the right of this, you should be able to feel the tense, turgid, elongated mass of the fiery-red, acutely inflamed, oedematous, and perhaps partly necrotic gallbladder.

Try to expose enough of the fundus of the gallbladder to allow you to drain it. Use your finger, or a 'swab on a stick' (4-9A), to 'peel' the omentum, the hepatic flexure of the colon, and the transverse mesocolon carefully out of the way. *Avoid sharp dissection.* If there is bleeding, control the haemorrhage with packs.

Put a purse-string suture on the gallbladder fundus (15-1B), incise it and aspirate the pus (15-1C). Then enlarge the opening and extract as many stones as you can (15-1D); if they are very adherent in Hartmann's pouch (15-3M), leave them, rather than perforating the gallbladder. *Don't attempt to explore the common bile duct.*

Place a wide-bore catheter, which you have inserted through a separate stab incision in the lateral abdominal wall, in the gallbladder, and close the opening around the catheter snugly with 2 purse-string sutures, one 5mm away from the other (15-1E). Secure the catheter drain and attach it to a drainage bag. Lavage the abdomen with warm water.

#### DIFFICULTIES WITH EMPYEMA OF THE GALLBLADDER

**If you cannot reach the inflamed gallbladder,** extend your incision across the midline as an inverted V.

**If you don't find a tense inflamed gallbladder** at operation, look for differential diagnoses and act appropriately.

**If the gallbladder is not that seriously inflamed,** and you are able to do so, perform a cholecystectomy (15.8).

**If you rupture the gallbladder at Hartmann's pouch** (15-3M) – a mucosal fold between the neck of the gallbladder and the cystic duct, sometimes caused by adhesions between them, where gallstones commonly get stuck (it may be present in both normal and pathological gallbladders) – try to remove any impacted stone (which should be freed up by your manipulations) and, if possible, put a ligature around the cystic duct remnant. Remove as much of the inflamed gallbladder as you can (if the posterior wall is very adherent to the liver, leave it) and insert a wide-bore drain through a separate stab incision in the abdominal wall.

**If the gallbladder is so tense and inflamed** that a suture causes it to leak profusely, apply suction and remove as much of the inflamed gallbladder as you can, as above.

**If the gallbladder has already perforated,** there is already effectively a cholecystostomy and friable tissues will make cholecystectomy too difficult. Aspirate septic fluid from the abdomen and pack away the bowels. Remove as much of the gallbladder wall as possible: you can leave the posterior wall adherent on the liver surface. Remove any debris and stones. Try to close the cystic duct with an absorbable suture if you can. Leave a drain brought out through a separate stab incision. Fold some omentum into the bed of the gallbladder.

POST-OPERATIVELY, expect bile to start draining in a day or two. Chart the daily amount of bile draining. Plan to remove the tube in 14 days. If the bile is still discharging after 2wks however, leave the catheter *in situ* for a month at least before removing it. If the bile loss is significant, replace fluid and electrolytes IV. You can try to return the bile to the intestines via a nasogastric tube if the patient will tolerate it. The fistula will slowly close unless a stone has been left in Hartmann's pouch (when a small mucous fistula will result, 15-3M).

*N.B. The cholecystectomy needed to cure this problem may be difficult indeed.*

## 15.5 Cholangitis

Ascending cholangitis describes infection in the bile duct, which, if untreated, may be followed by multiple abscesses in the liver, or by septicaemia. IV antibiotics are necessary, but if stones are the underlying cause, the common bile duct should be explored, and any stones removed. This is difficult and needs special instruments and on-table radiography. If it is impractical, and the stone is distal, you may still be able to decompress the common bile duct by inserting a T-tube (choledochostomy), or by opening the duodenum and opening the sphincter of Oddi wide, but this is difficult surgery.

A patient with cholangitis usually has a previous history of biliary colic and cholecystitis. Typically, an attack of colic is followed the next day by fluctuating jaundice, dark urine, pale stools, nausea and vomiting, fever and rigors. The liver may be tender, but the gallbladder is not palpable.

In HIV disease, cholangitis may occur intermittently without the presence of stones, mimicking primary sclerosing cholangitis. In East Asia, liver fluke infestation often causes cholangitis (15.7). In endemic areas, consider hydatid disease.

**SPECIAL TESTS.** Check if *ascaris* ova are in the stool: this does not necessarily mean that worms are the cause of cholangitis, but strongly suggests it (15.6).

**ULTRASOUND** (38.2) is very useful to confirm the presence of stones, cysts or *ascaris* and their number and position in a dilated common bile duct.

### CHOLEDOCHOSTOMY (GRADE 3.5)

#### PREPARATION

Treat with IV ampicillin, gentamicin and metronidazole, or substitute ampicillin and gentamicin with a cephalosporin, ciprofloxacin, or mezlocillin.

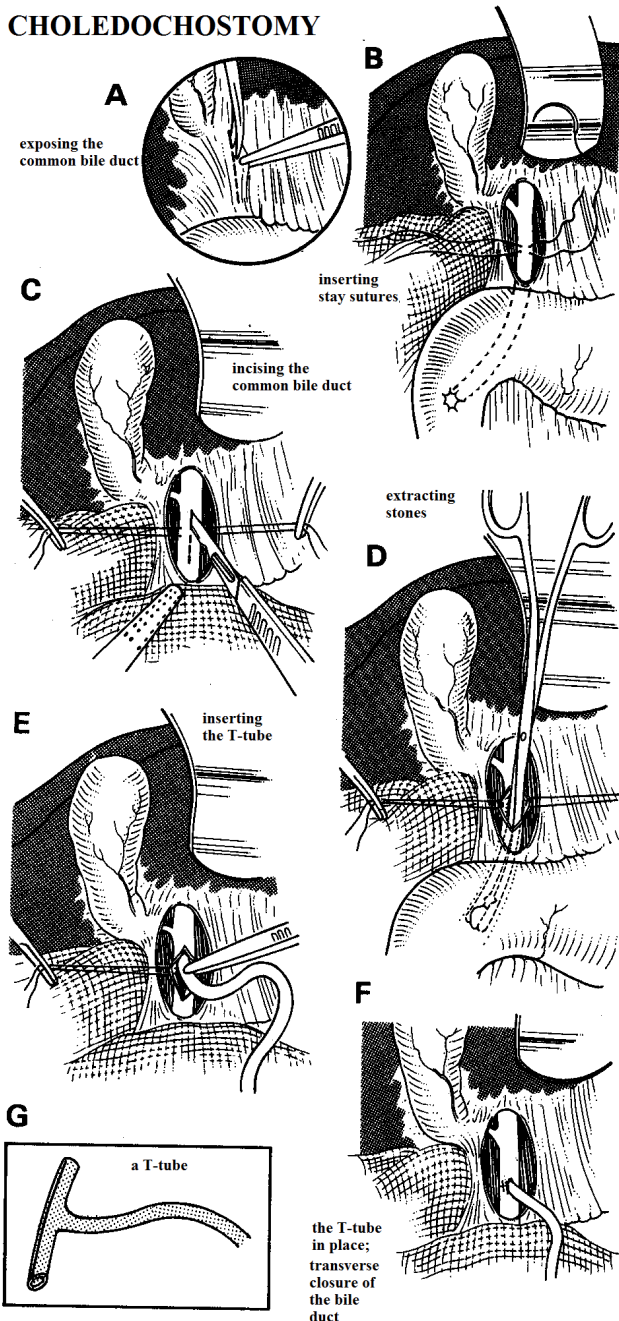
If he is septicaemic, resuscitate the patient with Ringer's lactate. Add vitamin K 10mg IM. Insert a nasogastric tube. *Don't delay.*

**INCISION.** Make an upper midline incision and follow the initial steps to find the gallbladder (15.3), then expose the subhepatic area, cystic duct, and common bile duct. (The midline incision is better for exposure of the common bile duct than a subcostal incision.)

Expose the biliary tree as in a cholecystectomy (15.8), but *without grasping the gallbladder*. Make sure you have found the bile ducts before proceeding further. Palpate them to be sure none of them pulsates! If in doubt, aspirate the common duct to make sure it contains bile and not blood. Then expose 2cm of the common bile duct, which will probably be significantly dilated (>5mm) (15-2A), and place two 3/0 stay sutures on its anterior surface about 4mm apart (15-2B). With the tip of the sucker close by, make a longitudinal incision between the stay sutures (15-2C). Suck out all the bile and exudate, and take a swab for culture and sensitivity.

Using Desjardin's stone forceps, gently remove any stones that you can easily see (15-2D). The curve on the forceps may help you: the stones are probably well down the common duct at its lower end, where it enters the duodenum. *Don't prolong this stage of the operation if it is difficult: you can do much harm.* If there is much 'sludge', wash out the common duct by irrigating it with plenty of saline using a plain rubber catheter and a 20ml syringe.

## CHOLEDOCHOSTOMY



**Fig. 15-2 CHOLEDOCHOSTOMY.**  
**A**, expose the common bile duct. **B**, insert stay sutures. **C**, incise the common bile duct. **D**, remove the stones. **E**, insert a Fogarty catheter. **F**, T-tube sewn in place. **G**, a T-tube.  
**EQUIPMENT.** FORCEPS, gallstone, Desjardin's. Use these long slender forceps for removing stones from the biliary system.  
 If you don't have Desjardin's stone forceps, a Fogarty balloon catheter pushed past the stone, inflated, and withdrawn is often as effective and less traumatic. You may possibly be able to use a tiny Foley catheter. Find 2 assistants in addition to the scrub sister.

Insert a T-tube (15-2E), and close the opening in the duct snugly round the drainage tube with a transverse absorbable 4/0 suture (15-2F). Bring the tube out through a stab incision, leaving some slack inside, in case it is pulled on. Anchor it securely to the skin with a non-absorbable suture.

(You can make your own T-tube by slitting the end of a piece of ordinary suction tubing, and cutting away  $\frac{1}{3}$  the circumference of the tubing.)

Close the abdominal wall carefully: the wound is likely to break down or become infected, so consider leaving the skin open (11.10, 11-20).

**POST-OPERATIVELY,** connect the T-tube to a bedside bottle, and allow it to drain freely until the jaundice and fever subside. Perform a tube cholangiogram 10-14 days post-operatively using 25% sodium diatrizoate ('*hypaque*') or similar aqueous contrast medium diluted 1:2 with 0.9% saline. *Make sure you don't inject any air with the contrast medium.* If you see no stones, and the medium flows nicely into the duodenum, clamp the tube. Provided that there is no pain, fever, or jaundice after 1wk, remove the tube.

**If the cholangiogram shows blockage of flow into the duodenum or any residual stones as filling defects,** try flushing the duct with 1L of warm saline suspended 1m above the patient, after treating with hyoscine 20mg IM. If this fails, check what pressure builds up. It should not be higher than 8-10cm of water. If after 24h no higher pressure develops, try clamping the tube. Remove it after 2wks if no discomfort develops. If pressure does build up in the tube, *don't remove it.* You may then be able to remove residual stones by dilating the T-tube tract and pulling them out with endoscopy forceps (the Burhenne technique), or they can be removed by an expert by passing a side-viewing fibre-optic endoscope into the duodenum and slitting the sphincter of Oddi, or by opening the duodenum at laparotomy.

## TRANSDUODENAL ODDI SPHINCTEROTOMY (GRADE 3.5)

**INDICATION.** When a stone is impacted at the distal end of the common bile duct; when antegrade extraction or lavage has failed to dislodge a stone.

**INCISION.** Expose the biliary tree as before; then mobilize the duodenum by the Kocher manoeuvre (13.5). Make a 4cm longitudinal incision in the lateral surface of the duodenum at the junction of first and second parts, and feel the papilla with your finger through the duodenotomy. If you can't find it, pass a bougie or catheter down through the common bile duct. Then insert a fistula probe into the papilla and open it upwards with a #11 blade (4-1) to free any impacted stones. When you see bile flowing freely, you know you have relieved the obstruction. Carefully spatulate the edges of the papilla open with absorbable 4/0 sutures. Be careful not to damage the pancreatic duct (usually visible at the 5 o'clock position). Close the duodenotomy transversely in 2 layers with long-lasting absorbable 2/0 sutures, and cover this with omentum if possible.

**If the bile duct has been opened,** place a T-tube as above.

## 15.6 Cholangitis caused by *ascaris*

*Ascaris* worms sometimes crawl up into the common bile duct and gallbladder, where they can cause biliary colic, acute cholecystitis, obstructive jaundice, cholangitis, and pancreatitis. This most often happens when a child has been given an antihelminthic. So, if a child has cholangitis, or if an adult does not fit the usual clinical picture for biliary disease, suspect ascariasis. Finding *ascaris* ova should arouse your suspicion, but *does not confirm the diagnosis*. Get an ultrasound scan. *Don't operate*, except on the indications below.

Nasogastric suction will empty the upper intestinal tract. Systemic antibiotics will help to control the cholangitis. Later, treat with levamisole 120mg stat, or piperazine 4g stat, or if there is multiple parasitic infestation, mebendazole 100mg od for 3 days, repeated after 15 days.

*N.B. Dead ascaris worms may still block the bile duct!*

**SPECIAL TESTS.** There is a microcytic hypochromic anaemia, a leucocytosis with >50% eosinophilia; bilirubin is raised in cholestatic obstruction and amylase in pancreatitis. *Ascaris lumbricoides* eggs can be found in the stool.

**ULTRASOUND** is best to determine if the *ascaris* worm is no longer in the bile duct (38.2c).

**INDICATIONS FOR SURGERY.** Deepening jaundice, spiking fever, chills and rigors which don't respond to antibiotics, nausea and vomiting, toxemia, dehydration, tachycardia, and perhaps hypotension; together with a leucocytosis. If there are these symptoms, explore and drain the bile ducts (choledochostomy, 15.5) after appropriate preparation. Remove any worms you find. Avoid a sphincterotomy as *ascaris* may then more easily crawl into the pancreatic duct subsequently.

## 15.7 Other causes of cholangitis

(1) In East Asia, liver flukes, *opisthorchis*, found in fish and snails, are extremely common. Many thousands of flukes can live for many years in the bile ducts causing inflammation. Resulting fibrosis leads to stricturing and dilation, secondary bacterial infection and stone development. Recurrent cholangitis can lead to biliary cirrhosis, liver failure, hepatorenal syndrome, portal hypertension or septicaemia, as well as pancreatitis. Recurrent inflammation may result in cholangiocarcinoma, and chronic infestation can lead to a *salmonella* carrier state if secondarily infected.

Presentation is usually at 20-40yrs (males more commonly), initially with non-specific malaise but then with a high swinging fever, chills and rigors, a gnawing right upper abdominal pain, and mild jaundice (Charcot's triad), usually with a history of previous attacks. The liver is tender and enlarged and the gallbladder may be palpable. The urine is dark, but the stools are seldom clay-coloured; complete obstruction of the common bile duct is rare.

(2) Around the Mediterranean, in East Asia and in Latin America, sheep liver flukes, *fasciola hepatica*, are found. These flukes are large and tend to remain in extra-hepatic bile ducts. The flukes may actually eat into the wall of the ducts, which leads to haemobilia, presenting as haematemesis and melaena, or more rarely perforate the duct, causing peritonitis. Inflammation leads to similar complications as with *opisthorchis*, but because the extra-hepatic ducts are preferentially involved, gallbladder distension and empyema are more common.

(3) Primary sclerosing cholangitis is an inflammatory condition affecting both intra- and extra-hepatic bile ducts, in men and women equally of 25-40yrs. Fatigue, weight loss, right upper abdominal pain, intermittent jaundice and itching are usual; an acute attack of cholangitis is rare. A similar picture can arise in HIV disease (5.6), with or without papillary stenosis. No medication has been found helpful.

(4) Rupture of a hepatic hydatid cyst into the bile ducts (15.12).

### SPECIAL TESTS

There is a leucocytosis (and eosinophilia with fluke infestation); the serum bilirubin and alkaline phosphatase are raised. If infection is severe and liver cells are involved, the transaminases are raised. Measure the serum amylase, because there is a 10% chance that there is also pancreatitis. You may find ova and dead flukes in the faeces and in duodenal aspirates.

### RADIOGRAPHS

A plain radiograph may show air in the biliary tract due to an incompetent sphincter of Oddi.

**ULTRASOUND** often shows dilation of intra-hepatic before extra-hepatic ducts, and may actually detect mobile flukes (38.2c).

### NON-OPERATIVE TREATMENT

If the disease is mild, take blood cultures and treat with antibiotics (cefradine or gentamicin, 2.8). Add vitamin K 10mg IM. Start intravenous fluids, restrict oral fluids and aspirate the stomach through a nasogastric tube. Praziquantel 25mg/kg tds for 2 days is the most effective treatment for *opisthorchis* but is ineffective against *fasciola*, for which bithionol 1g tds alternate days for 5 days is 100% effective.

### INDICATIONS FOR OPERATION

- (1) Failure of non-operative treatment.
- (2) A palpable, tender, enlarged gallbladder.
- (3) Septicaemia.

**LAPAROTOMY.** Aim to remove all biliary debris by washing out the extra- and intra-hepatic bile ducts with copious amounts of saline. Prepare the patient (15.5). Perform a choledochostomy (15.5), and insert a T-tube. In the presence of septicaemia and an enlarged gallbladder, perform a cholecystostomy (15.3). When acute symptoms have settled, treat any liver flukes.

## 15.8 Cholecystectomy (GRADE 3.3)

Removing the gallbladder is the standard method of treating chronic gallbladder disease, but it is not an operation for the occasional surgeon, so unless you are experienced, it is better to treat cholecystitis non-operatively (15.2,3). However, if symptoms and signs get worse, and you cannot refer the patient, and have sufficient experience, it is best to operate early on an acutely inflamed gallbladder than later when it becomes hopelessly stuck down.

If symptoms persist, consider the option of cholecystostomy (15.4) before deciding on cholecystectomy, which can be difficult and where the complications can be serious. The main dangers are bleeding and injuring the common bile or hepatic ducts. *Don't try to remove a fibrotic, contracted gallbladder.* Unfortunately, you will not be able to predict if the operation is going to be easy or difficult. So, be prepared to bail out: abandon the operation, or limit yourself to a cholecystostomy after all.

We describe 2 methods of removing the gallbladder: (i) the retrograde, in which you first dissect and tie its neck, and (ii) the antegrade, in which you start at the fundus.

The commonest cause of an injured bile duct or hepatic artery is an 'easy' operation done quickly. Another cause is anatomical variability (15-3).

### ELECTIVE CHOLECYSTECTOMY

#### INDICATIONS

- (1) Gallstones causing several attacks of cholecystitis.
- (2) A carrier of *salmonella typhi*.

#### CONTRAINDICATIONS

*N.B.* These are relative, but important:

- (1) Inexperience.
- (2) Uncertain diagnosis and failure to exclude other causes of dyspepsia.
- (3) Insufficient symptoms and signs which justify the operation.
- (4) Complicating factors, *e.g.* HIV disease or excessive obesity.
- (5) The need to bail out, or perform a cholecystostomy, if it is too dangerous to proceed.

**ANTIBIOTICS.** The main cause of death in gallbladder surgery is post-operative sepsis. Use a perioperative antibiotic (2.9) unless the case is a completely elective one.

#### PREPARATION

A self-retaining and a Deaver's retractor are almost essential. You will need two assistants as well as the scrub nurse. If you have facilities for radiography in theatre, make sure the patient lies on a suitable table so that radiographs can be taken of the upper abdomen. Check for sickle cell disease if this is common in your area.

**INCISION.** Make a right subcostal (Kocher's) or midline incision (11-1) extending up to the costal margin.

The Kocher's incision gives better access to the gallbladder itself, but the midline incision better access to the bile duct, and any other pathology that may be present.

### BILIARY ANATOMY

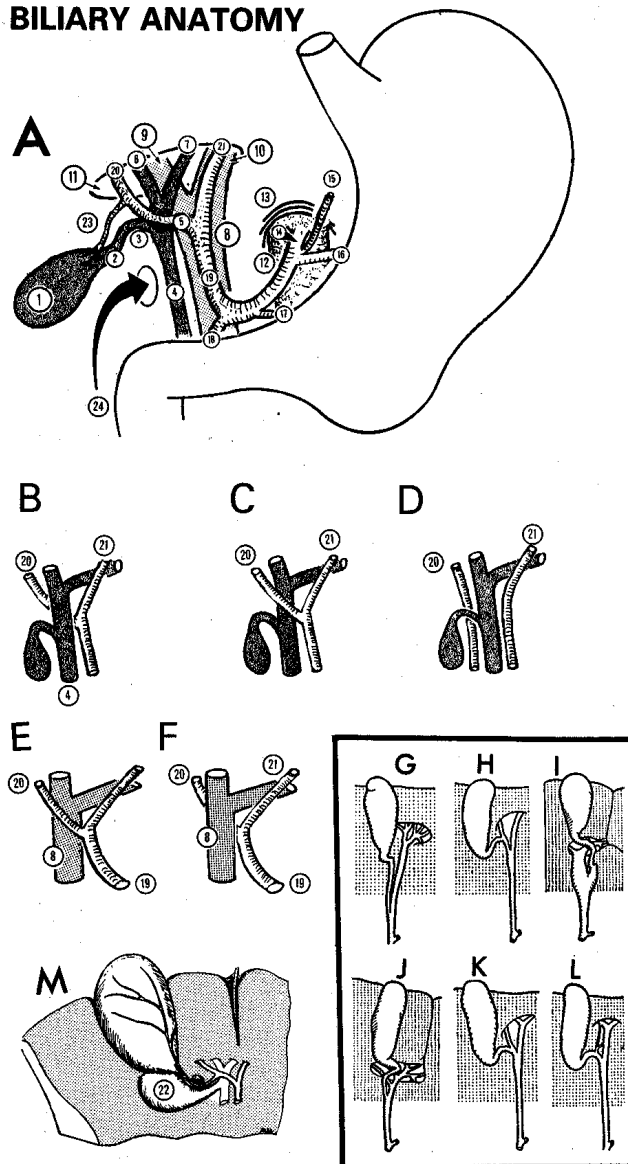


Fig. 15-3 ANATOMY OF THE BILIARY SYSTEM.

A, normal relationships of structures in this region. B-F, relations of the right hepatic artery. In B (and A), it runs posterior to the common hepatic duct (64%). In C, it runs anterior (24%), and in D, it arises from the superior mesenteric artery (9%). In E, it runs anterior to the portal vein (91%) and in F, posterior (9%).

G-L, variations in the bile passages (>50%). Note the accessory hepatic ducts in positions of surgical danger. M, a small pouch (Hartmann's pouch) may project from the right wall of the neck of a diseased gallbladder downwards and backwards towards the duodenum. When it is well marked, the cystic duct arises from its upper left wall and not from what appears to be the apex of the gallbladder.

(1) fundus of the gallbladder. (2) neck of the gallbladder. (3) cystic duct. (4) common bile duct. (5) common hepatic duct. (6) right hepatic duct. (7) left hepatic duct. (8) portal vein. (9) right branch of the portal vein. (10) left branch of the portal vein. (11) porta hepatis. (12) aorta. (13) some fibres of the diaphragm. (14) coeliac artery. (15) left gastric artery. (16) splenic artery. (17) right gastric artery. (18) gastroduodenal artery. (19) hepatic artery. (20) right hepatic artery. (21) left hepatic artery. (22) Hartmann's pouch. (23) cystic artery. (24) epiploic foramen (entrance to the lesser sac).

After Basmajian JV, *Grant's Method of Anatomy, Williams & Wilkins 9<sup>th</sup> ed 1975 with kind permission.*

Feel for the gallbladder. Feel for stones in the gallbladder and in the bile ducts. Feel both lobes of the liver to be sure they are smooth and normal. Examine the stomach and duodenum. Feel the pancreas.

**If the gallbladder seems far up under the rib cage,** run your hand over the right lobe of the liver, divide the falciform ligament across the dome of the liver, and draw it down. Put some large packs between the diaphragm and the liver – *don't forget to remove them afterwards!*

Insert a self-retaining retractor, and try to see the gallbladder. Get the anaesthetist to empty the stomach with a nasogastric tube. Use long tissue forceps to place large moist abdominal packs over the hepatic flexure of the colon, the duodenum, and the stomach. Ask your first assistant to draw these downwards and medially. You should now be able to see under the liver clearly.

Protect the liver with a pack, and ask your second assistant to retract it upwards and laterally with a large Deaver's retractor (15-4B). Look at the gallbladder. Divide any omental adhesions to the gallbladder, if present.

**If the gallbladder is acutely inflamed,** perform a cholecystostomy (15-1).

**If it is very small, shrunken, thick-walled, contains stones, and is firmly stuck to nearby structures,** leave it alone, or take out the stones and perform a cholecystostomy. Removing such a gallbladder will be very difficult.

**If it looks and feels reasonably normal,** apart from a few stones, and is attached by fine adhesions only, it should be safe to proceed.

**A. THE RETROGRADE ('DUCT FIRST') APPROACH**  
Use this if you can readily find the cystic duct, the common bile duct, and the hepatic artery, in the free edge of the lesser omentum. The epiploic foramen (of Winslow) lies behind it; you should be able to pass one or two fingers through it into the lesser sac.

Place a gallbladder clamp or sponge-holding forceps on Hartmann's pouch (15-4C). This is a widened area in the lower part of the patient's gallbladder, just before it tapers off into the cystic duct. Pull gently upwards on these forceps, so as to stretch the tissues and make dissection easier.

Incise Calot's triangle of peritoneum between Hartmann's pouch and the common hepatic duct. This will appear when you apply traction to the sponge-holding forceps on Hartmann's pouch. It is a most important step. Start by making a small nick in the peritoneum with a long pair of Metzenbaum scissors. Carefully insert the tips of the scissors, then, using the 'push and spread technique' (4-9) or a Lahey dissecting swab, open up enough of the patient's peritoneum to expose the deeper structures.

**CAUTION!** *Be careful not to cut any small blood vessels.* Bleeding will make the operation difficult. By spreading the blades of the scissors (*but not too far!*) before you cut, or using a Lahey dissecting swab, you should be able to separate peritoneum only.

Take a Lahey swab (15-4C, E), and gently push apart the peritoneum, so that you see the junction of the common bile duct, hepatic and cystic arteries. This is most important. *Don't proceed unless you are certain of the anatomy!*

**CAUTION!** There are some important anatomical variations:

(1) The common bile duct and the cystic duct may join high or low (15-3G-L). The cystic duct may be very short and the common bile duct is then dangerously tented by traction on the gallbladder.

(2) The right hepatic artery may pass behind the common hepatic duct (15-3A, B, more common) or in front of it (15-3C, less common).

(3) The cystic artery may be closely bound to the common hepatic duct.

(4) The cystic artery usually (64%) arises from the right hepatic artery. It may cross behind (usually) or in front of (unusually) the common hepatic and cystic ducts to reach the gallbladder. Sometimes, it arises from the common hepatic (27%) or the left hepatic artery (5%), or from other arteries in the region (rare).

Be sure of your landmarks before you start to divide anything. Use a Lahey swab and dissect by the 'push and spread' method and thereby find the junction of the patient's cystic and common bile ducts, as described above. Be sure to identify 2cm of the common duct, both proximal and distal to the junction. This will give you an idea of its course and direction. The common bile duct lies to the right of the structures going to the porta hepatis, and is a greenish colour: identifying it is one of the keys to safe gallbladder surgery.

**If the cystic artery runs posterior to the common hepatic and cystic ducts** (usual), take extra care. Using traction with your left hand on the gallbladder, follow the cystic artery onto the gallbladder. *Don't expect to feel any pulsation in such a small vessel.* If a strand of tissue runs to the gallbladder, assume it is the cystic artery, pass 2 mounted ties around it, and divide between them. Expect to find other branches and deal with them in the same way.

**If the cystic artery runs anterior to the common hepatic and cystic ducts** (unusual), define it by blunt dissection, and make sure that it is indeed going to the gallbladder.

**CAUTION!** *Don't tie the right hepatic artery by mistake.* If you are sure you have found the cystic artery, tie it doubly proximally and then close to the gallbladder with 2/0 silk (15-4D), and divide it leaving a short cuff of tissue, distal to the tie.

**If you have found the junction of the cystic and common bile ducts, and you are sure that what you presume is the cystic duct is going to the gallbladder, and nowhere else,** define it further, using blunt dissection (15-4E). This is the time to perform an operative cholangiogram if you can and you are still not sure. Using a long pair of Lahey forceps, gently open up the cleft between the cystic and common hepatic ducts. Pass a mounted tie of '0' absorbable suture through this cleft, and around the cystic duct, but not too close to the junction to cause a kink there. Tie it and for safety's sake, tie a 2<sup>nd</sup> suture around the cystic duct (15-4F).

## CHOLECYSTECTOMY

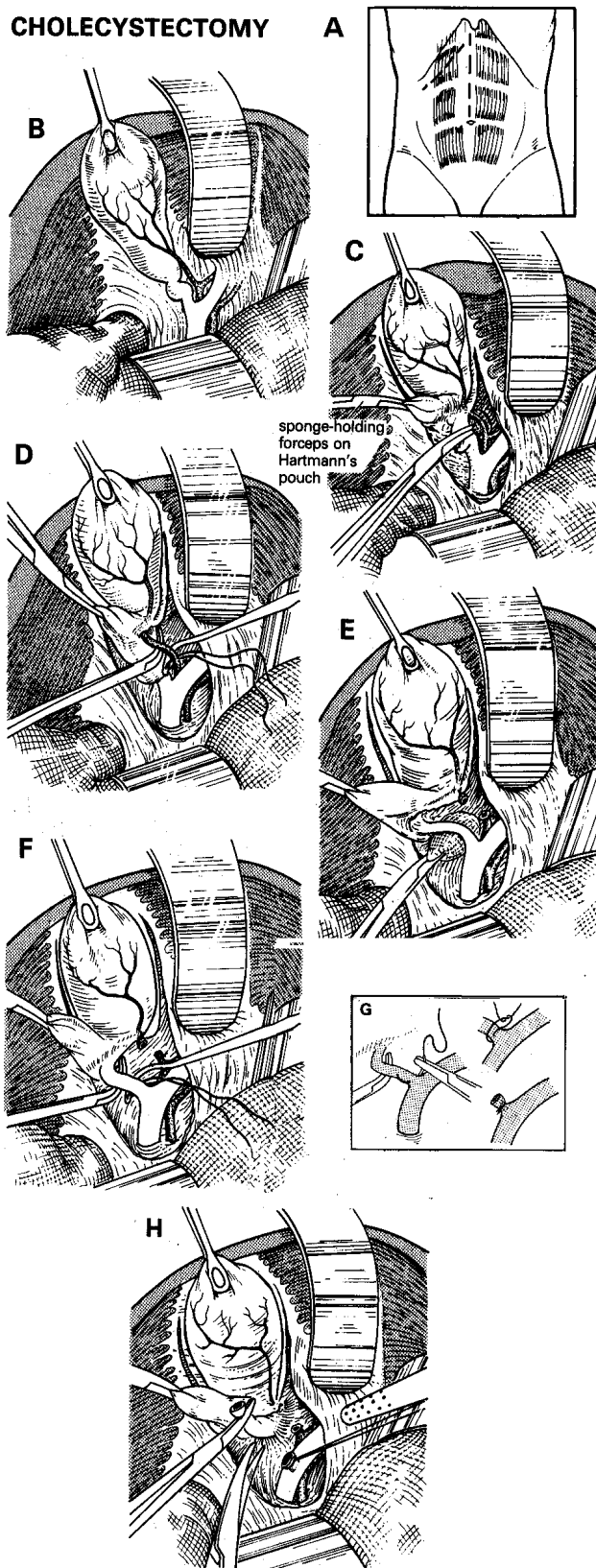


Fig. 15-4 REMOVING THE GALLBLADDER.

A, incisions. B, expose the gallbladder. C, expose the cystic duct. Note that the second forceps holds a Lahey swab. D, tie the cystic artery. E, free the cystic duct. F, tie the cystic duct. G, if the cystic duct is very large and thickened, transfix and tie it like this. H, separate the gallbladder from the liver. *N.B. if the liver bed bleeds, pack it.*

After Rob C. Smith R. *Operative Surgery*, Butterworth 2<sup>nd</sup> ed 1969, Vol4, p.404, with kind permission.

Place another Lahey clamp on the cystic duct, close to the gallbladder, above the ties. Cut the cystic duct just flush with the Lahey clamp, leaving enough tied cystic duct behind, so your ligature will not slip off. If the cystic duct is very large, transfix it (15-4G).

**CAUTION!** Only divide and tie structures that are passing to the gallbladder. *Don't leave too long a stump of cystic duct behind* as it may form a stone.

You should now be able to strip the gallbladder from its bed by pulling it gently upwards on the clamps. Cut any peritoneal bands that join it to the liver (15-4H), but tie off anything else: there may be a vessel or an anomalous bile duct inside a strand.

**If the bed of the gallbladder oozes**, press a warm pack into it. If small veins continue to bleed, cauterize them. It is unnecessary and dangerous to close the peritoneum over the bed of the gallbladder.

**CAUTION!** Check to make sure that the stump of the cystic duct is secure and that no bile is leaking.

**B. THE ANTEGRADE ('FUNDUS FIRST') APPROACH**  
Use this if you cannot readily find the cystic duct, common bile duct, and hepatic artery.

Place a gallbladder clamp or sponge-holding forceps on the fundus of the gallbladder, and divide the peritoneum between the fundus and the liver. You may need to tie any larger vessels that bleed. Mobilize the gallbladder in this way anteriorly and posteriorly, continuing till you reach the neck of the gallbladder. Locate the cystic duct and trace it to the junction with the common bile duct. Then continue as above.

**OPERATIVE CHOLANGIOGRAPHY (38.1)** is important if there has been a history of jaundice, if ultrasound shows dilated extra-hepatic bile ducts with or without showing a stone, and if a stone is palpable in the common bile duct.

**CLOSING THE WOUND.** Place a soft rubber drain through a stab wound down to the porta hepatis if tissues are inflamed or you are not certain that the cystic duct ligature will hold: *a controlled bile leak is better than an uncontrolled one!* Close the abdominal wound (11.8); do this in layers if you have used a Kocher incision.

### DIFFICULTIES REMOVING THE GALLBLADDER

**If you find an adherent inflammatory mass around the gallbladder**, withdraw and close the wound. Consider operating later, when the inflammation has subsided. Rarely is this a malignant mass, which is forever inoperable.

**If you palpate stones in the common bile duct, or find them on an operative cholangiogram**, perform a choledochostomy (15-2) and try to extract them with Desjardin's forceps, or perform a transduodenal Oddi sphincterotomy (15.5). Perform a post-extraction operative cholangiogram, if you can.

**If the cystic artery bleeds from the depths of the wound**, this can be alarming. *Don't clamp blindly.*

(1) Insert warm moist packs, apply pressure and wait 5mins by the clock. The spurting vessel will then be easier to find and control. Or,

(2) Put your index finger into the epiploic foramen and squeeze the structures (portal vein, bile ducts, and hepatic artery) in the free edge of the lesser omentum between your index finger and your thumb (the Pringle manoeuvre). This will control bleeding from the stump of the cystic artery. When you have suction and instruments ready, remove the packs and try to visualize the vessel, and clamp it. Transfix it carefully with 3/0 silk. *Don't use diathermy in the depths of the wound*, especially if you can't see properly! If exposure is poor, *enlarge your incision*.

**If you suspect you have injured the cystic duct early on**, make sure your suction is working properly and aspirate bile so you have a good view. If necessary, *enlarge your incision*. Get a cholangiogram if you cannot interpret the anatomy. If the cystic duct is incompletely divided, hold the part near the gallbladder in a Lahey clamp, and pass a mounted tie around it at the common bile duct end and complete the division of the cystic duct. If you injure it very near its union with the common bile duct, transfix it and carefully tie it, dividing it distally. *Make sure you haven't kinked or narrowed the common bile duct*.

**If you find that you have damaged the common bile duct**, you will have done so in one of three ways:

(1) By a ligature or by a clamp; undo the ligature or take off the clamp and inspect the damage. Perform a choledochostomy (15-2) higher up, and pass a T-tube limb inside through the damaged area.

(2) By partly dividing it; leave a T-tube threaded up and down the duct and proceed as for choledochostomy. Try to repair the hole in the bile duct using interrupted 4/0 absorbable sutures, taking care not to narrow it. Keep the T-tube in for 6wks, and then get a T-tube cholangiogram and remove it if there is free flow into the duodenum.

(3) By completely dividing it; try to drain the bile by passing a tube into the severed proximal end of the bile duct and secure it. You can leave this to drain externally into a bag. Or you can try to insert a T-tube into both ends of the severed duct, tie it so it doesn't slip out and manage the T-tube as before.

**If you cannot find the distal end of the bile duct**, however, insert the distal limb of the T-tube directly into the duodenum and secure it with a purse-string absorbable suture. (To make a permanent bypass, the definitive operation of choledochojejunostomy-en-Y using a Roux loop is a very demanding procedure.)

*N.B. Learn from your mistakes, seek to be able to forgive yourself, and carry on.*

#### DIFFICULTIES AFTER CHOLECYSTECTOMY

**If fresh blood discharges from the drain**, the pulse rises, the blood pressure falls, and there are signs of a haemoperitoneum, the cystic artery is probably bleeding. Re-open the abdomen, extend the incision, suck out all the blood and insert packs to control the haemorrhage. Then try to visualize the bleeding vessel, clamp it and tie it off.

**If bile comes from the drain, with fever, severe pain and a leucocytosis**, suspect that infected bile and exudate are pooling under the liver. Treat with gentamicin or a cephalosporin. Perform an ultrasound if you can to locate and quantify the amount of liquid. If there is no improvement, re-open the abdomen, extend the incision, suck out all the bile and inspect the cystic duct stump. If this is obviously leaking and you can hold it in a clamp, transfix it. Usually the whole area is grossly inflamed and you will not be able to identify structures easily; make sure the area is adequately drained.

**If the patient becomes jaundiced**, suspect the bile duct has been damaged or a stone has lodged in the distal bile duct. Try to confirm this by finding a dilated proximal biliary tree on ultrasound (38.2c). Unless you have access to sophisticated endoscopy, arrange a re-exploration which is difficult, and may mean a choledochojejunostomy-en-Y. If you cannot manage this, you can try to drain the proximal biliary system percutaneously through the liver under ultrasound guidance, or insert a T-tube (15.5) in the dilated part of the duct. Distal stones may pass on their own; a specialized endoscopist may be able to remove them from below.

### 15.9 Obstructive (cholestatic) jaundice

When jaundice is due to an obstruction in the flow of bile:

- (1) The stools are pale.
  - (2) The urine is dark, and contains little or no urobilinogen.
  - (3) The skin itches because of deposition of bile salts.
- These features are most marked in complete obstruction, as when carcinoma blocks the common duct. Pain and fever are usually absent. Stones typically cause an intermittent obstruction, and a less characteristic picture. If a stone impacts in Hartmann's pouch (15.4, 15-3M) or in the cystic duct, it causes pain but does not impede the flow of bile down the common duct, so jaundice is absent.

**If an older patient has a steadily deepening and usually painless obstructive jaundice**, and the gallbladder is palpably enlarged, some tumour is probably obstructing the common bile duct. It is unlikely that there are gallstones (Courvoisier's rule). This is probably incurable, but a cholecystojejunostomy to decompress the gallbladder, by diverting the bile into the jejunum, may make the patient's last days more bearable.

There are several causes, however, of obstructive jaundice:

- (1) A secondary tumour in the porta hepatis, usually from a primary in the stomach or gallbladder itself.
- (2) Carcinoma of the head of the pancreas.
- (3) Cholangiocarcinoma or other cholangiopathies (15.7).
- (4) Metastatic liver carcinoma.
- (5) Hepatoma (although this is a common disease, presentation as obstructive jaundice is unusual).
- (6) Drugs, e.g. antibiotics, contraceptives, chlorpromazine, cimetidine, oestradiol, imipramine and many others.

**In endemic areas**, other causes are liver flukes (15.7) and hydatid disease (15.12).

**In neonates**, look for a congenital abnormality (33.9).

**DIFFERENTIAL DIAGNOSIS.** First try to decide what kind of jaundice the patient has.

**Haemolytic jaundice.** The stools are dark. There is no bilirubin in the urine, but the urinary urobilinogen is increased. The blood shows increased levels of unconjugated prehepatic bilirubin (leading to high readings on the indirect van den Bergh test). The serum transaminases (GPT and GOT) are normal, and so is the alkaline phosphatase. There is a reticulocytosis. Look for evidence of a haemoglobinopathy, especially sickle cell disease, and malaria. Check for consumption of medicines, especially dapsone or sulphonamides. Check for a splenomegaly and insect or snake bites.

*N.B. Haemolysis may result in pigmented gallstones!*

**Obstructive jaundice.** The stools are pale (clay-coloured if obstruction is complete), and *show no improvement in colour in 10 days*. There is bilirubin in the urine, but little or no urobilinogen. There is a high conjugated (posthepatic) bilirubin level (giving high readings on the direct van den Bergh test). The alkaline phosphatase is very high. The transaminases are usually normal.

**Hepatocellular jaundice.** This is commonly viral hepatitis with an obstructive phase lasting 7-10 days, but sometimes much longer. At this stage the stools are pale. The urine contains bilirubin but little urobilinogen. The serum bilirubin is moderately increased (mostly conjugated). The alkaline phosphatase is usually only moderately increased, but if cholestasis is a prominent feature it can rise to levels seen in obstructive jaundice. The transaminases are increased. As the oedema of the cells settles, the stools become normal or even dark, the serum bilirubin falls, the urinary urobilinogen rises or reappears, and the transaminases fall gradually. The return of stool colour is the most important sign. This form of jaundice is not common >35yrs.

**CAUTION!** You may have difficulty distinguishing the obstructive phase of hepatocellular jaundice from surgical obstructive jaundice. Do all you can to make the distinction. A laparotomy for a stone may be life-saving, but GA (especially with halothane) and the trauma of surgery may cause hepatocellular jaundice to deteriorate, perhaps fatally.

**ULTRASOUND (38.2c)** is very useful. You need to show extra-hepatic bile duct dilation >7mm to make an operable diagnosis.

**Suggesting malignancy:**

(1) Relentlessly progressive, steadily deepening obstructive jaundice, weight loss.

(2) A palpable gallbladder which you can feel as an elongated, smooth, non-tender mass, normal in contour, and slightly mobile, which may extend to the umbilicus or even below it. If you can feel a distended gallbladder, it strongly suggests a malignant obstruction at the lower end of the common bile duct, but *its absence does not exclude this*. Aspiration of green bile implies free drainage from the common hepatic duct, but aspiration of 'white bile' (*i.e.* mucus) suggests occlusion of the cystic duct.

**Suggesting metastases in the liver or a hepatoma:** a large, hard, knobby liver. A bruit is often present with a hepatoma, ascites is common, and is often blood-stained.

**Suggesting a carcinoma of the stomach with metastases in the porta hepatis:** pain, anorexia, vomiting, an upper abdominal mass, and the visible peristalsis of pyloric stenosis. Anaemia is common.

**Suggesting carcinoma of the head of the pancreas:** vague epigastric pain, a palpable gallbladder and weight loss.

**Suggesting gallstones:** a long history of intermittent varying jaundice, severe intermittent colicky pain, fever, chills and rigors (suggesting cholangitis), little or no weight loss, flatulent dyspepsia. A leucocytosis suggests cholecystitis.

**Suggesting tuberculosis:** caseating nodes in the porta hepatis, with signs of glandular tuberculosis elsewhere.

**Suggesting stenosis of the bile ducts, either malignant or benign:** a tender, enlarged liver. A chronic history of repeated attacks of cholangitis. The gallbladder may or may not be palpable. Common where liver flukes are endemic.

**Suggesting carcinoma of the gallbladder:** an enlarged liver and a hard, irregular mass in the right hypochondrium, usually in a female.

**MANAGEMENT.** If there are gallstones, the patient needs a choledochostomy (15-2) unless you can remove the gallstones endoscopically. If there is malignant disease with obstruction at the lower end of the common bile duct, a cholecystojejunostomy may help unless you can refer the patient for endoscopic stenting.

**CHOLECYSTOJEJUNOSTOMY FOR OBSTRUCTIVE JAUNDICE (GRADE 3.3)**

**INDICATIONS.** In practice the presence of a smooth enlarged gallbladder is the only clear indication to operate. However, you may still achieve a good result in some cases where the gallbladder is not distended.

**CONTRAINDICATIONS.** Cachexia, debility, a hard irregular gallbladder mass, a hard craggy liver due to metastatic deposits, hepatoma, a large gastric tumour, ascites.

**PREPARATION.** Confirm suitability for operation by aspirating green bile from the gallbladder (if necessary under ultrasound control). Treat with vitamin K 10mg IM od at least 48h pre-operatively. This will reduce a tendency to bleed. Patients with jaundice are prone to acute renal failure if their glomerular filtration rate falls. So make sure hydration is adequate pre-operatively. Treat with dextrose IV to combat hypoglycaemia when starved pre-operatively.

## CHOLECYSTO- JEJUNOSTOMY

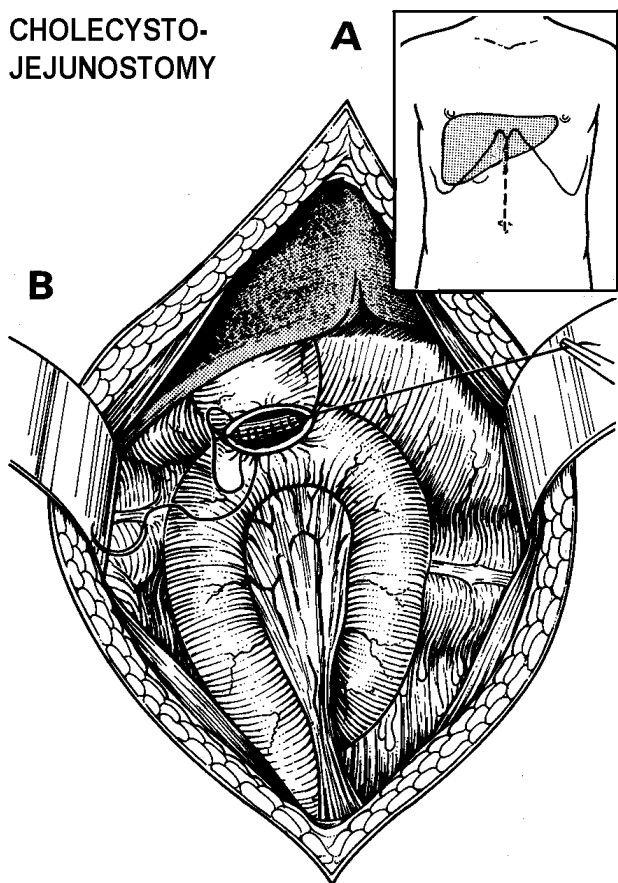


Fig. 15-5 CHOLECYSTOJEJUNOSTOMY.  
A, the incision. B, the first layer of the anastomosis.

**INCISION.** Open the abdomen through an upper midline incision. Expose the liver and subhepatic area (15.8). Good exposure is essential. Inspect and feel the upper abdominal viscera carefully. Is the gallbladder normal in size and appearance? If it is a hard, irregular mass which is fixed to the surrounding organs, it is probably malignant.

**If the gallbladder is inflamed, or contains many stones,** perform a cholecystostomy (15.3), unless the obstruction in the bile duct is proximal to the cystic duct junction. *Don't try to anastomose bowel to a thick-walled, inflamed, oedematous gallbladder.*

Feel the pancreas, especially its head. Lift the transverse colon upwards and forwards out of the wound with your left hand, while you feel the pancreas at the base of the transverse mesocolon. Its head lies to the right of the vertebral column at this level. A hard, knobby, craggy mass suggests a tumour. Also feel it from above. Stand on the left side of the table and feel with your right hand while you pull the hepatic flexure of the colon medially. Place your thumb anteriorly and your fingers posteriorly. Feel the head of the pancreas lying in the concavity of the duodenum. If necessary, mobilize the duodenum (15.5), so that you can feel the pancreas properly.

**CAUTION!** *Don't biopsy the pancreas.* Unless you use special methods like fine needle aspiration, you may cause pancreatitis and a fistula. However, if there are distant nodules, try to get tissue for histopathology.

Feel the porta hepatis and the structures lying in the free edge of the lesser omentum. Can you feel any craggy, fixed, indurated masses, suggesting primary carcinomas of the bile ducts or secondary deposits? Feel the stomach.

**If you find deposits suggestive of tuberculosis** (16.5), take a small biopsy of surrounding tissue.

### INDICATIONS FOR PROCEEDING FURTHER

*Decide what to do next only at this stage.*

**If there is an enlarged and distended but otherwise normal gallbladder,** showing that there is an obstruction in the common bile duct, proximal to or within the head of the pancreas, with no obstruction to the cystic duct, perform a bypass.

**If there is 'white bile' (mucus) on aspiration from the gallbladder,** the cystic duct is obstructed and a cholecystojejunostomy will be futile.

### METHOD

Pack off the distended gallbladder. Decompress it as at cholecystostomy (15-1). Remove the purse-string suture, and extend the opening with scissors to a length of 1.5cm. Apply Babcock clamps to the fundus of the gallbladder about 1cm from each end of the incision. Lift the transverse colon upwards and look for the ligament of Treitz. This is the point where the retroperitoneal 4<sup>th</sup> part of the duodenum emerges to become the jejunum, slightly to the left of the vertebral column, and distal to the attachment of the mesentery of the transverse colon.

Choose a loop of jejunum 30cm distal to the ligament of Treitz, and draw it up towards the open gallbladder. Apply one or two non-crushing bowel clamps across the jejunal loop. Apply two Babcock clamps 3cm apart on the antimesenteric border of the jejunum, to match those on the fundus of the gallbladder. Bring these clamps alongside one another, making sure that there is no tension on the jejunal loop. Aim to make a 1.5cm diameter stoma.

**CAUTION!** Make the anastomosis neatly and carefully: biliary peritonitis is a serious complication of a leak.

The end-to-side anastomosis is similar to that for a gastroenterostomy (13.7). Make the seromuscular outer layer of sutures of 3/0 on an atraumatic needle. Insert 5 sutures, which should ideally pick up only the seromuscular layer of the jejunum, but which will probably be of full thickness, in the wall of the gallbladder.

Place them about 2mm away from the cut edge of the incision, and on the bowel side about 2mm back from the antimesenteric border of the jejunum. Incise the jejunum 3mm back from the suture line. Trim away redundant mucosa with fine scissors. Apply Babcock forceps temporarily over any bleeding points. Insert a continuous 'all coats' posterior layer of 3/0 atraumatic absorbable sutures, starting at one end; then continue to close the anterior layer with the same suture. Finally, continue with the previous 3/0 to insert an anterior layer of seromuscular Lembert sutures. Cover the anastomosis with a layer of omentum, and suture this in place.

Be careful to close the abdominal wall soundly (11.8).

## DIFFICULTIES WITH CHOLECYSTOJEJUNOSTOMY

**If you do find gallstones**, make sure that the jaundice is not caused by stones distally in the bile duct. If it is, perform a choledochostomy (15-2), extract the stones, and if you are experienced, remove the gallbladder also. If the gallstones seem an incidental finding, the gallbladder is not inflamed and there is tumour distally, proceed with cholecystojejunostomy as above, but try to remove the gallstones from the gallbladder itself.

**If there is gastric outlet obstruction** (<10% of patients), shown by an enlarged stomach, and tumour obstructing the duodenum, perform a gastrojejunostomy (13.7) as well. To avoid bile refluxing into the stomach, you can make a third anastomosis, a jejunojejunostomy (part of the traditional 'triple bypass'), but this adds to the morbidity. Remember you are doing palliative surgery only. A Roux-en-Y (15.14) cholecystojejunostomy is probably a better combination with a gastrojejunostomy.

## 15.10 Liver abscess

### A. Amoebic liver abscess: extra-intestinal amoebiasis

When *Entamoeba histolytica* spreads outside the bowel, it usually involves the liver. Here it can cause an 'abscess' filled with liquid necrotic liver. To start with, this is yellow or yellow-green, later it becomes a syrupy dark reddish-yellow. The central area of necrosis is surrounded by zones of progressively less damaged tissue and amoebae. The term amoebic 'abscess' is a bad one, because there is no pus.

There is an 80% chance that the abscess is in the right lobe of the liver, where you will be able to detect it clinically, unless it is very deep. Collections in the liver are sometimes multiple.

Metronidazole usually treats an uncomplicated liver 'abscess' very effectively, but it occasionally (if >5cm diameter) needs aspiration, and rarely (if >10cm) drainage. The major risk is that it will suddenly rupture into the abdominal cavity, or through the diaphragm into the pleural or pericardial space, or even into the lung. Rupture into the abdominal cavity is a dramatic catastrophe, with collapse and peritonitis, like the perforation of a peptic ulcer. Although the contents of an abscess are sterile, they cause an acute inflammatory reaction in the peritoneum, whether this is acute or chronic.

*N.B.* Common mistakes are:

- (1) *Not to perform a sigmoidoscopy.*
- (2) *Not to recognize amoebic ulcers when you do see them.*
- (3) *Not to remember the existence of acute necrotizing amoebic colitis with perforation.*
- (4) *Not to use all the evidence you can to diagnose a liver abscess.*

## CLINICAL FEATURES

The patient is usually male (8:1 chance), <30yrs, and may be a child. In endemic areas (*e.g.* Kwazulu in South Africa; Pakistan; Mexico), amoebic 'abscesses' are not uncommon in babies, and also occur in the elderly.

The pain in the right upper quadrant, or the lower right chest, is constant or intermittent, not colicky, and does not radiate. It slowly gets worse, but is seldom severe.

Deep breathing and coughing often make the pain worse. Fever, anorexia, weakness, and loss of weight steadily progress. There is only a 30% chance of having had diarrhoea with blood and mucus during the previous year. Often, there is some associated disease, such as tuberculosis, HIV, malnutrition, or alcoholism.

The liver is tender, smooth, diffusely enlarged, and without an obvious lump. Palpation of the liver may cause much distress. Pressure over the lower 5 ribs in the right anterior axillary line is painful. Examine also for evidence of a pleural effusion.

**SPECIAL TESTS.** Leucocytosis and anaemia. Raised ESR. Check for hypoglycaemia and hyponatraemia. Look for amoebic ulcers with a sigmoidoscope. You are unlikely to find amoebae in the stools. Use new PCR tests which are very sensitive, if you can.

**CHEST RADIOGRAPHY.** Look for a pleural effusion, and elevation of the right dome of the diaphragm.

**ULTRASOUND** is by far the most reliable diagnostic tool. Look for a fluid-filled cavity in the liver (38.2b). Measure how near the abscess is to rupture: *<1cm liver tissue is dangerous!* You cannot differentiate an amoebic from a pyogenic liver abscess except by aspiration.

**DIFFERENTIAL DIAGNOSIS** includes:

- (1) hepatoma,
- (2) cholecystitis,
- (3) hydatid cyst,
- (4) pyogenic liver abscess,
- (5) perinephric abscess.

**Suggesting a hepatoma** (15.11): a hard nodular mass, liver less painful and less tender, no fever or low fever (fever only occurs with very rapidly growing tumours), a bruit, bloody ascites.

**Suggesting cholecystitis** (15.3), perhaps with spreading suppuration: pain and tenderness is localized to the gallbladder region, there may be a history of intolerance to greasy foods, and presence of jaundice, more commonly in a female.

**Suggesting a hydatid cyst** (15.12): the mass arises from one or other lobe, rather than enlarging it diffusely; it grows slowly and is largely asymptomatic; it is smooth, tense, and cystic; tenderness is minimal, there is no fever, and the general condition is good. All this may change rapidly if the cyst becomes infected.

**Suggesting a pyogenic liver abscess:** a short history; severely ill with a spiking fever.

**Suggesting a perinephric abscess (6.15):** the swelling is low down over the liver on the right; the distinction may be very difficult. Aspiration may establish the site.

#### MEDICAL TREATMENT FOR HEPATIC AMOEBIASIS

Metronidazole 800mg tds for 5 days, and then diloxanide furoate 500mg (children: 20mg/kg) tds for 10 days or chloroquine 600mg od for 5 days.

#### ASPIRATION FOR LIVER ABSCESS (GRADE 1.4) INDICATIONS

- (1) To confirm the diagnosis.
- (2) As a method of treatment if the abscess is >5cm diameter, or if the patient fails to improve with medication in 48h, or if the abscess is in the left lobe of the liver, as this may perforate into the pericardium.
- (3) If there is on ultrasound scan <1cm liver tissue between the abscess and the liver surface (38.2b).
- (4) If there is jaundice, suggesting involvement of the biliary system.

**METHOD.** Treat with metronidazole for 48h before aspirating. Check the prothrombin index if there is jaundice; and correct a clotting defect with vitamin K 10mg IM. Using LA and full aseptic precautions, preferably under ultrasound guidance, pass a wide-bore (>1mm) long needle on a 50ml syringe, or better, a wide-bore pigtail catheter through healthy skin, over the site of greatest swelling, or maximum tenderness.

If you obtain >250ml, introduce a multi-holed plastic catheter on a trocar in the same direction, attach a 3-way tap, and aspirate until the cavity is apparently empty. Irrigate through the tube daily. Continue until the cavity is empty and then remove the tube.

You have only a c.10% chance of finding amoebae in the fluid. They are more often found in the wall of the cavity.

#### OPEN DRAINAGE FOR LIVER ABSCESS

(GRADE 2.4)

##### INDICATIONS

(This is rarely necessary if you have used metronidazole and aspirated the abscess adequately.)

- (1) A deep-seated amoebic liver abscess which you have not been able to aspirate, and the patient is deteriorating on medical treatment.
- (2) Fluid too thick to aspirate.
- (3) Very large abscesses >10cm in diameter, which recur after repeated aspiration.
- (4) A large abscess in the left lobe which may perforate into the pericardium.
- (5) Abscesses causing marked elevation of the diaphragm.
- (6) Secondary infection of the abscess.
- (7) A suspicion of a pyogenic liver abscess or an infected hydatid cyst.

**DRAINAGE.** Make a subcostal incision, pack away the rest of the abdominal contents and insert an aspirating needle directly into the abscess cavity, to identify it. Push an artery forceps into it, open it and suck out the pus. Take some scrapings from the wall of the abscess, and examine a warm wet specimen for *trophozoites*.

If there is much discharge, insert a tube drain, and bring this out through a separate incision on the abdominal wall. The liver may recede from the abdominal wall as you drain it, and end up as a shrunken blob, in the right upper abdomen. Remove the drain in 6-7 days, to minimize the risk of secondary infection.

#### DIFFICULTIES WITH EXTRA-INTESTINAL AMOEBIASIS

**If there is a sudden pain like with a perforated peptic ulcer,** the abscess has probably ruptured into the abdominal cavity. Resuscitate with IV fluids and start IV metronidazole. As soon as the general state is satisfactory, perform a laparotomy.

Make a midline incision. Explore the liver as best you can, and look for the site of the rupture: a ragged area with chocolate-coloured fluid pouring from it. Suck out as much of this as you can. Mop up what you cannot aspirate. Irrigate all the crevices of the peritoneum with several litres of warm saline or water. Ensure a thorough lavage, and close the abdomen. Treat post-operatively as peritonitis (10.1).

**If there are tender ill-defined masses in the abdomen,** suspect that the abscess has leaked into the abdominal cavity. Start intensive medical treatment, and monitor the abdomen closely. Mark the outline of any mass, and check its size regularly. Perform a laparotomy if it gets bigger.

**If an abscess presents on the chest wall,** it will ultimately rupture through the skin, which may become infected with amoebae, and form a chronic ulcer (14-5A). Treat with metronidazole.

**If a severe cough and dyspnoea develop,** this may, or may not, mean that there is a pleural effusion. If the effusion is small, it will resolve as the liver abscess improves. If it is large, insert an underwater seal chest drain.

**If there is an ulcerating skin lesion** round a sinus from the liver, caecum, or anus, remember the possibility of CUTANEOUS AMOEBIASIS. Metronidazole cures cutaneous amoebiasis so fast that you can use it as a diagnostic test. In the perianal area, ulcerating skin lesions are usually non-specific. Untreated, the lesions spread fast; biopsies show up the *trophozoites*.

*N.B.* Tuberculosis, malignancy, and fungi are often commoner.

**If the patient coughs up dark reddish-yellow fluid,** the liver abscess has ruptured into a bronchus. Although this may drain the abscess, it may also fatally flood the bronchial tree. Get a chest radiograph and treat with IV metronidazole, aspirate the liver abscess, and use postural drainage for the lung (11-24).

**If the liver abscess discharges into the pericardium,** it usually does so from an abscess in the left lobe. Pericardial rupture is not uncommon in endemic areas, is often not recognized, and is usually fatal. Watch therefore for abscesses in the left liver lobe, and aspirate them. Try to aspirate the pericardium (9.2).

**If there is no adequate response (<5%)** to metronidazole alone, treat with chloroquine 600mg loading dose and 150mg bd for 21 days, and if necessary, dehydroemetine 65mg od IM for 10 days. This drug is cardiotoxic, so you cannot use it in heart failure.

**If an epileptic fit ensues**, there may be cerebral amoebiasis. If there are no focal neurological signs, treat with diuretics and steroids, as well as second-line therapy; if there are, suspect a brain abscess.

## B. Pyogenic liver abscess

A large pyogenic liver abscess is usually much less common than an amoebic 'abscess'. Organisms spread mostly from the biliary tract, or *via* the portal vein from the bowel (e.g. appendix abscess or intestinal salmonella carried with chronic *Schistosoma mansoni* infestation or HIV disease) or *via* the hepatic artery from a remote focus (e.g. pyomyositis). Multiple small abscesses can result from *staphylococcal* septicaemia or ascending cholangitis. Occasionally the abscess may arise from penetrating trauma, or infection in a hydatid cyst (15.12).

The history is usually shorter than with amoebiasis. Jaundice suggests infection from an obstructed bile duct. Although signs of a large abscess are like those of the amoebic variety, much more commonly there is a fever of unknown origin. Ultrasound is the easiest way of making the diagnosis, and aids in liver aspiration.

Until cultures are available, use broad-spectrum antibiotics: metronidazole, gentamicin, cloxacillin and ampicillin.

Try to aspirate the abscess completely; if you fail, proceed to open drainage (as above). Open a large abscess to prevent rupture into the abdominal cavity!

Test for sickle cell disease, *schistosomiasis* or melioidosis, if these are common in your area.

### 15.11 Hepatoma (Hepatocellular carcinoma)

Hepatoma is one of the world's common malignant tumours, mostly because it is so common in China, Southeast Asia, the Amazon region and Peru, and sub-Saharan Africa, where it is even more common than secondary tumours of the liver. In Africa, there is a 90% chance that a liver with a hepatoma is also cirrhotic, due to the strong association of hepatoma with hepatitis B, C and D infection, and with the *aflatoxin* produced by the *aspergillus* fungus growing in damp stored food. Prevalence of hepatitis B is also high in Greenland, Alaska and Northern Canada, and hepatitis C is a global problem.

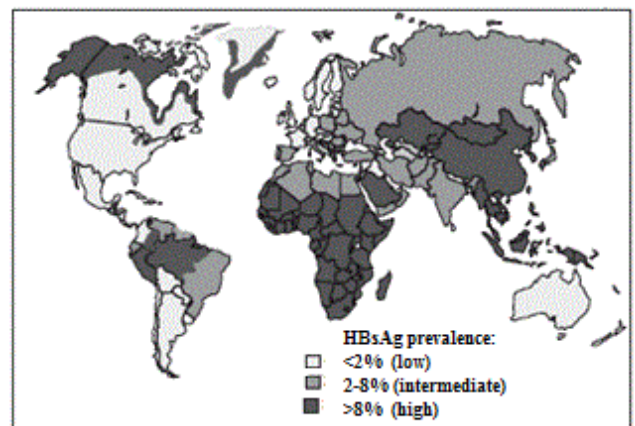
A hepatoma often arises simultaneously as multiple nodules in many parts of the liver. Sometimes, a huge mass deforms one lobe. The other primary liver tumour, cholangiocarcinoma, is a problem in Southeast Asia.

The patient is usually male (8:1), and 30-50yrs. He complains of pain, anorexia, weight loss, or a mass;

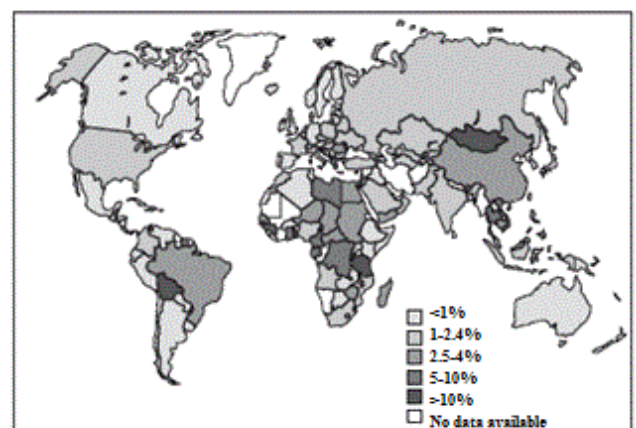
jaundice is a late sign. The pain is usually constant, and sharp or burning, and is in the upper abdomen, usually on the right. It is commonly made worse by food, which causes an inappropriate feeling of fullness after only a small meal. Typically, the pain is made much worse by alcohol, so much so that it may have caused abstinence.

Usually, presentation is late with a large, or even a huge, firm, irregular, tender liver. Quite a small tumour may cause prostration but normal activity may continue with a large tumour. There may be cachexia, but not always. Look for ascites and a large spleen. Look for collateral veins running vertically over the anterior costal margin, or parallel to the spinous processes. Listen over the tumour for a bruit or friction rub; this may be intermittent, so listen on several occasions.

#### GEOGRAPHIC DISTRIBUTION OF CHRONIC HBV



#### BROAD GLOBAL PREVALENCE OF HCV



**Fig. 15-6 HEPATITIS B, C AND HEPATOMA.**

The geographical distribution of the hepatitis B virus, based on incidence of Hb<sub>s</sub>Ag in blood samples, correlates with hepatoma incidence. Hepatitis C has a much broader spread in the world.

**If there is any room for doubt**, do all you can to confirm the diagnosis. Several diseases present as swellings of the upper abdomen. Try to distinguish those you can treat, such as liver abscesses, hydatid cysts, and tuberculosis, from those you can only palliate.

The best and most non-invasive tool by far is an ultrasound: do all you can to get such a machine and get acquainted with it (38.2b). If you have any hope of sending specimens for cytology, use this method. Otherwise you need to biopsy the liver to get histology. This can be dangerous, so use ultrasound guidance if you can. If you cannot get histology, aspiration with a fine needle may still be useful to detect pus or tuberculosis.

In children the primary liver malignancy is hepatoblastoma. Usually the child is severely anaemic. The liver may rupture with a minor injury. Chemotherapy is the only option.

**SPECIAL TESTS.** Serum  $\alpha$ -fetoprotein  $>500\mu\text{g/L}$  is present in 70-80% of cases. *Though this test is unlikely to be available locally, it may be easier to get a laboratory to do it rather than get histology on a potentially dangerous liver biopsy.* The bilirubin rises late, and is often not raised on presentation. If it is  $>40\mu\text{mol/L}$ , life expectancy is weeks only. The bilirubin and alkaline phosphatase levels rise parallel with one another. The transaminases are normal, unless there is also chronic active hepatitis. If there is ascites, aspirate a sample of the fluid and examine it. Blood-stained fluid supports the diagnosis of malignancy, not necessarily of the liver. Anaemia is seldom a marked feature.

*Don't forget to test the bleeding and clotting times.*

**RADIOGRAPHS.** Chest radiography usually shows that the right lobe of the diaphragm is raised. Metastases rarely show up but are present in 50% of patients postmortem.

**ULTRASOUND** is extremely useful and will show solitary or multiple lesions, or fluid cavities (38.2b). Use it to help guide a needle biopsy.

*NEEDLE, liver biopsy, Menghini, 1.6mm, normal Menghini point, with adjustable stop.*

*NEEDLE, liver biopsy, Vim-Silverman, adult size, 23mm x 88.5mm, with Franklin modification.*

## NEEDLE BIOPSY OF THE LIVER (GRADE 1.4) INDICATIONS

An enlarged liver when the diagnosis is unknown.

## CONTRAINDICATIONS

(1) *Don't do this if your histology service is dubious in quality, or if the results are unlikely to arrive for weeks!*

(2) Deep jaundice, severe anaemia, or any bleeding tendency, as shown by petechiae, ecchymoses, or haemorrhages.

(3) Hydatid disease, where needle biopsy may lead to fatal anaphylaxis or dissemination.

(4) *Don't attempt this if you cannot transfuse blood in an emergency. Correct coagulation problems first!*

**CAUTION!** Measure the bleeding time (normal  $<3\text{mins}$ ) and clotting time (normal  $<8\text{mins}$ ) before taking a biopsy and treat with vitamin K 10mg IM till the bleeding and clotting times are normal.

**ANAESTHESIA.** Use LA in an adult; a child may need ketamine.

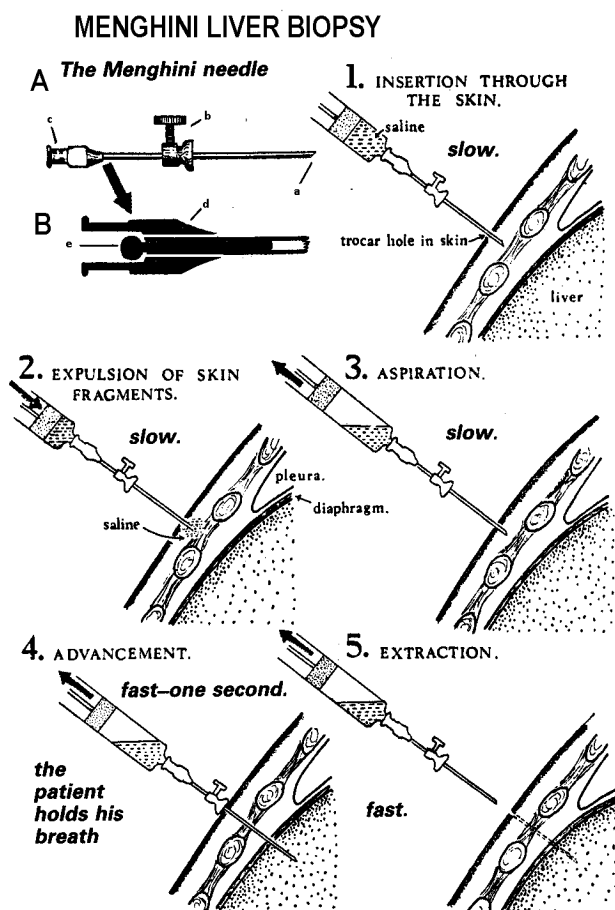


Fig. 15-7 MENGHINI LIVER BIOPSY.

**A, Menghini needle.** This has a sharp stout end (a), with an adjustable guard (b), and a Luer lock (c). **B, viewed in cross section,** the assembly has an obturator outside the needle, and a blocking pin, which slips loosely inside the needle and prevents the biopsy fragment from falling back and breaking up in the syringe. To take a biopsy using a Menghini needle: (1) insert it through the skin, (2) expel skin fragments, (3) aspirate, (4) advance the needle into the liver, with the patient holding his breath, and gently suck up tissue by holding the syringe steady, (5) extract the needle whilst gently maintaining suction. *After King M. Medical Care in Developing Countries, OUP 1967.*

### (A) MENGHINI NEEDLE

Fit the Menghini needle to a well-fitting 10ml syringe, set the guard at about 4cm, and draw up 3ml of sterile saline. Pass the needle point through the anaesthetized track through the intercostal space. Inject 2ml of saline to clear the needle point of any skin fragments.

**CAUTION!** Now, ask the patient to hold his breath in expiration. Start to aspirate, and while continuing to aspirate, rapidly push the needle into the liver perpendicular to the skin, then immediately pull it out again. Apply pressure to the site of the biopsy. Continue aspirating until you have placed the needle point under some saline in a glass dish. Discharge the saline remaining in the syringe. The biopsy specimen will appear. Rescue it and transfer it to formal saline. Clear the needle with the obturator.

### (B) VIM-SILVERMAN NEEDLE

Fit the inner obturator into the sheath. With firm but well-controlled pressure, push the needle through the abdominal wall while the patient holds his breath. You will feel the peritoneum 'give' as you go through it. *Don't push the needle in too far at this stage.* Ask the patient to take a deep breath. If the needle moves with respiration, its tip is already in the liver; if not, ask him to hold his breath again, and gently push it 3cm further in, or until it moves.

The needle has hollowed-out biopsy jaws, a sleeve which fits over them, and an obturator to discharge the specimen. The inner jaws grasp a core of tissue, after which you slide the sleeve over them to trap it. Surgeons vary in the needle they prefer. A Menghini needle is in a patient's liver for a shorter time, so it is safer. Its disadvantage is that it is less likely to withdraw a satisfactory specimen in a cirrhotic. This is important because cirrhosis is common in areas where hepatoma is common.

**CAUTION!** Don't manipulate the needle during regular breathing, or you may tear the liver.

Ask him to hold his breath, then remove the inner obturator and replace it with the biopsy jaws. Steady the needle with your left hand, and push the jaws with your right hand into the needle as far as they will go.

Ask him to hold his breath again. Hold the biopsy jaws firmly with your right hand, and slide the outer jaws 3cm further into the liver. This will wedge the jaws and the tissue firmly in the outer sheath. Rotate the needle once or twice, to break off any tissue which is attached at the tip, and then quickly withdraw it. Ask him to breathe again. You can do everything in a few seconds. *Long breath-holding is unnecessary.* Slide the sheath over the biopsy jaws and open them. Use a fine needle to remove the core of tissue from the jaws into formol saline.

**METHOD.** Before you use either needle for the first time, try it out by doing the biopsy on a mango (for example), and if possible, practise on a cadaver.

**CAUTION!** To avoid tearing the liver, tell the patient to hold his breath when you are pushing the needle in, pushing it in further, or pulling it out. There are also times when you will want him to breathe deeply to check the position of the needle. Before you start, make quite sure that he understands what is being done. If you are using LA, get him to practise holding his breath. This is important, because you must perform the puncture itself while he holds his breath at the end of expiration.

Lay the patient supine near to the right side of the bed, and place a firm pillow against the left side in the hollow of the bed. Place his right arm behind the head, and turn his face to the left.

Choose a point in the mid or anterior axillary line in the 8<sup>th</sup>, 9<sup>th</sup> or 10<sup>th</sup> intercostal spaces, or over the palpable mass that you want to biopsy. Clean the skin with iodine, and anaesthetize the chosen site with LA solution, down to the parietal peritoneum. Pierce the anaesthetized area with a scalpel (or with the special trocar).

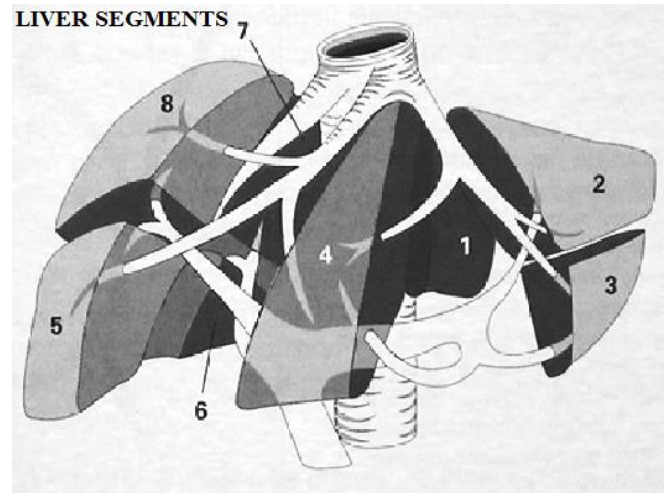
**If you have not succeeded,** try again in a different place. If you fail after several attempts, there is probably no solid tissue that can be biopsied. If the needle goes in without any resistance, attach a 20ml syringe to it and aspirate: you may withdraw pus of a liver abscess (15.10), or blood from a haemangioma, or clear fluid of a hydatid (15.12).

**POST-OPERATIVELY** (both methods), keep the patient supine for 12h. Monitor the pulse and blood pressure during this time, just in case there is bleeding into the peritoneal cavity. A hepatoma is very vascular, and occasionally bleeds when you biopsy it.

**DIFFERENTIAL DIAGNOSIS.** Try to exclude treatable diseases. Some of these are inflammatory, and so produce fever, but this also occurs in primary hepatoma (8%), so it is not a reliable guide.

**Suggesting secondary carcinoma of the liver:** a hard nodular liver, evidence for a primary tumour. In carcinoma of the stomach there may be a separate mass, dyspeptic symptoms, or symptoms of pyloric obstruction.

**Suggesting cholangiocarcinoma:** deep jaundice, no bruit, and a liver which is less big and irregular than with hepatoma.



**Fig. 15-8 LIVER SEGMENTS.**

Each side of the liver is divided into 2 sectors: paramedian and lateral. *N.B. The falciform ligament dividing the liver into traditional right and left lobes does NOT equate with the right and left vascular divisions.* Each of the 4 sectors is further divided superiorly and inferiorly, hence forming 8 segments. However, the left paramedian sector is not formally divided, though known often as segments 4A and 4B (or 9). The caudal lobe is its own segment (1). Thus a right hepatectomy consists of removing segments 5,6,7,8 and a left hepatectomy removes segments 2,3,4 whilst a left hepatic lobectomy removes only segments 2+3.

**Suggesting carcinoma of the head of the pancreas:** deepening jaundice, little or no pain, the absence of bile pigment in the stools, a gallbladder which is usually palpable, no bruit.

**Suggesting amoebic abscess:** fever, a smooth, diffusely enlarged, tender liver with no obvious lumps, no jaundice; tenderness, especially intercostal tenderness.

**Suggesting gallstones:** severe colicky pain, biliary dyspepsia, little or no weight loss.

**Suggesting hydatid disease, with cholangitis:** contact with dogs, a tense, almost painless, longstanding (years), smooth, rubbery mass, commonly in the right upper quadrant; little weight loss, general condition good.

**Suggesting a subphrenic abscess with downward displacement of the liver:** fever and an acute or subacute illness, cough and chest signs on the right side, shoulder tip pain on the right side.

**Suggesting tuberculosis of the liver:** a hard irregular liver, often with no fever, no jaundice, pain is not marked, especially in an immunocompromised patient. When there is no jaundice, you cannot distinguish hepatoma and secondary carcinoma from tuberculosis, except by needle biopsy, which is one reason why it is so useful.

**Suggesting intrahepatic stones:** fever, right upper quadrant pain, rarely jaundice in a patient in East Asia.

**PROGNOSIS.** Few patients survive >6 months.

**MANAGEMENT.** Cytokine inhibitors may palliate usefully, but they are enormously expensive. There is little you or anyone else can do for the patient, with the rare exception of a single tumour confined to one lobe which can be resected in specialist centres.

Try to promote hepatitis B vaccination in your area if hepatoma is common.

## 15.12 Hydatid disease

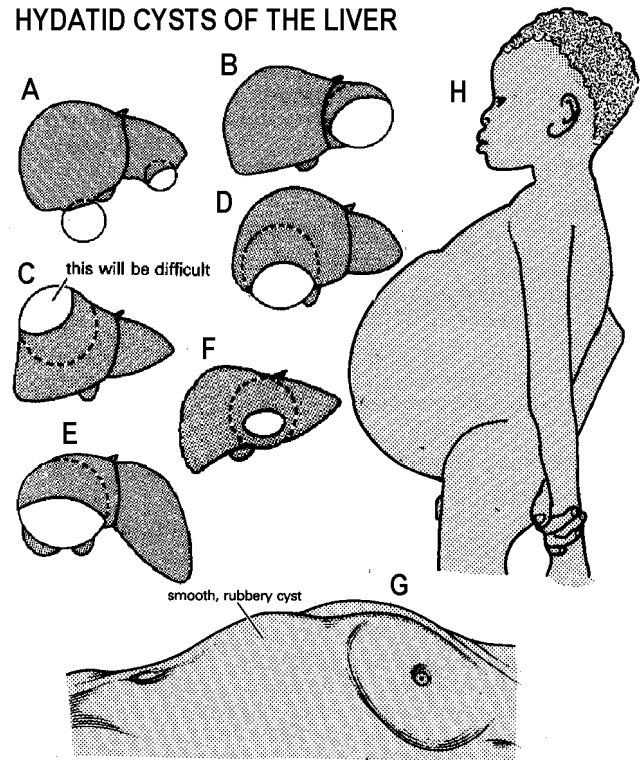
The *Echinococcus granulosus* tapeworms in their larval stages cause uni- or multi-locular or multiple hydatid cysts; in their adult forms they inhabit the gut of dogs, wolves, coyotes and foxes. Man is infested in the same way as sheep, horses, oxen and cattle, by ingesting ova from canine faeces (either by hand-to-mouth transfer or from contaminated drinking water). Hydatid disease is widespread in Turkey, Rio Grande do Sul in Brazil, as well as Australia, North Africa and Southern Africa; but also in Saudi Arabia, Siberia, Northern China, Japan and the Philippines. Turkana in north-west Kenya had the highest prevalence, but now only <4% of the population are infected. Programmes to control hydatid infection have been among the most successful measures of their kind.

**If hydatid disease is endemic in your area,** you may find hydatid cysts in the liver (80%), spleen (7%) or the other parts of the abdomen (14%), or occasionally in the lungs, brain, bones, or indeed almost anywhere. If there is a peripheral cyst, expect that there is at least one in the liver too.

The presentation is typically of a tense, almost painless, longstanding, smooth, rubbery, mobile cyst in the upper right quadrant, often of several years' duration, with little fever or malaise: it may be enormous, and may be multiple. A hydatid cyst usually contains several litres of clear highly antigenic fluid under pressure. Around it there is a thin, tough, fibrous ectocyst. Inside this, and separated from it often by an easy plane of cleavage, is a thick, yellowish, slimy, gelatinous endocyst, which the parasite forms, and which tends to split and curl up on itself when you cut it. Scolices, which are tiny, barely visible, white granules, and daughter cysts, like grapes or soap bubbles, float free in the fluid of the cyst.

*Echinococcus vogeli*, a parasite found in Central and South America, produces multiple cysts in the liver. Likewise, *Echinococcus multilocularis*, found in Central Asia, produces multiple cysts, but also inflammatory infiltrations that mimic tumour, and can spread to the lungs in 30%.

## HYDATID CYSTS OF THE LIVER



**Fig. 15-9 HYDATID CYSTS OF THE LIVER.**

A-F, some of the cysts you may find. C will need a thoraco-abdominal incision. G, a patient with a single cyst. H, abdominal distension due to multiple hydatid daughter cysts throughout the peritoneal cavity. After Pelissier G, Goïnard P, Peguilo J. *Le kyste hydatique*, Masson, Niort 1960.

A cyst in the liver may rupture into:

- (1) the bile ducts and cause cholangitis,
- (2) a serous cavity, where it may cause a hypersensitivity reaction, varying from urticaria to anaphylactic shock.

The diagnosis is difficult without ultrasound, and the disease may be so rare that you forget it as a possibility. There is hardly ever any hurry to operate, so investigate it as fully as you can.

Surgery is likely to be difficult, so treat it medically before you operate or aspirate. The method of puncture, aspiration, injection (of scolicide) and re-aspiration (PAIR) is safer than surgery in most cases. You may be able to do this under ultrasound control if you have had some experience.

**If you intend to remove a hydatid cyst surgically,** do so in the plane between the tissues of host and parasite: leave the ectocyst, and don't try to remove the entire cyst intact, unless you can do this easily, as in the ovary or spleen. Instead:

- (1) Gain access to the cyst, and pack it off, so that if any infective hydatid fluid does escape, it will not contaminate the peritoneal cavity; 1ml can contain thousands of scolices.
- (2) Aspirate some of the fluid, and inject a scolicide.

(3) After 10mins, aspirate as much remaining fluid as you can.

(4) Scoop out the endocyst and the daughter cysts.

(5) Close the cavity, so that it does not leave a sinus or a fistula.

In a child, the cyst will probably be monolocular, so that aspirating it will not be too difficult. But in an adult, it is likely to be multilocular, so that:

(1) the fluid will be difficult to aspirate, because the daughter cysts block the needle, and

(2) the scolices will be difficult to sterilize, because the scolicide cannot penetrate in to them.

*The great danger is that you will spill the fluid, which may:*

(1) allow daughter cysts to establish themselves in the peritoneal cavity, and

(2) cause anaphylactic shock. The recurrence rate is usually at least 25%.

**PREVENTION.** If yours is an endemic area, do all you can to educate the local population, especially about washing hands, eliminating stray dogs and regularly deworming their domestic dogs, not feeding them uncooked offal and burning refuse from slaughtered animals.

**SPECIAL TESTS.** An absolute eosinophilia is present in 30% of patients. *The Casoni test gives false -ve and +ve results in c.20% of cases, and is no longer used.* Other antibody tests, such as the ELISA test, may also give false negatives, particularly for bone and brain cysts.

**RADIOGRAPHS.** Take a chest film: there may also be cysts in the lungs. A cyst in the liver may raise the right lobe of the diaphragm. An old aborted cyst may leave a calcified shadow.

**ULTRASOUND** is the best way of detecting hydatid cysts (38.2b). A lamellated membrane, detachment of the membrane from the cyst wall, or the presence of daughter cysts confirms the diagnosis. You should be able to differentiate a hydatid from a simple liver cyst by its having a double wall.

**DIAGNOSTIC ASPIRATION.** *Don't try to do this, because this may make the cyst leak, and may be fatal.* Aspiration is part of treatment. *Don't try to tap a hydatid cyst merely to make it smaller.*

**If you are aspirating what you think is an abscess, and you aspirate clear fluid,** it is highly likely to be a hydatid cyst. Continue aspirating to dryness, before you remove the needle. Then inject a scolicide, wait, re-aspirate and then quickly withdraw the needle.

#### DIFFERENTIAL DIAGNOSIS

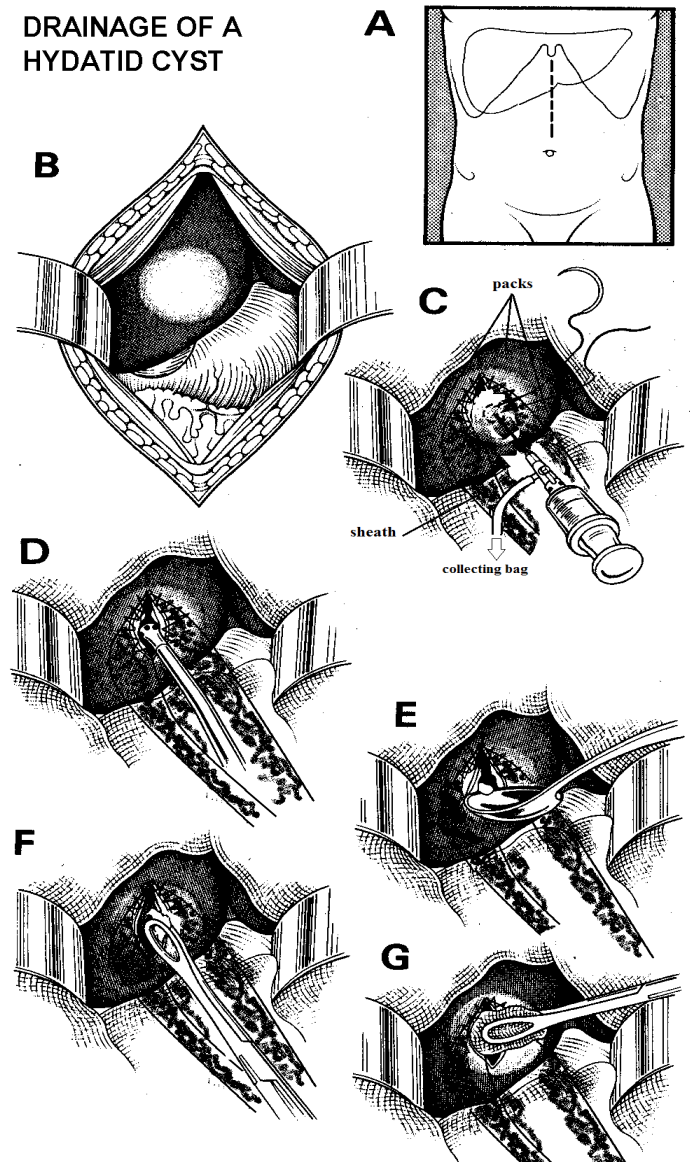
**Suggesting simple liver cyst:** smooth hepatomegaly, with single cyst wall on ultrasound.

**Suggesting liver abscess:** fever, tender smooth hepatomegaly, with short history of illness.

**Suggesting hepatoma:** irregular huge liver with ascites and weight loss; audible bruit.

**Suggesting secondary carcinoma of the liver:** hard knobby enlarged liver with weight loss.

#### DRAINAGE OF A HYDATID CYST



**Fig. 15-10 OPERATION FOR HYDATID CYST OF THE LIVER.**

A, high midline incision. B, expose the cyst. C, isolate the cyst with scolicide-soaked packs, and suture a tubular sheath to the pericyst. Work within this sheath to avoid spillage. Aspirate 50% of the fluid into a bag of scolicide. Leave the needle in place and inject 50-100ml scolicide till it becomes tense. Tie the purse string around the puncture site and wait for 10mins. Re-aspirate the cyst till it is flaccid. D, then incise the pericyst and suck out the rest of the fluid. E, remove the daughter cysts with a spoon. F, remove the endocyst completely with sponge forceps. G, swab out the cavity with scolicide.

*Partly after Rob C. Smith R. Operative surgery: Part 1: Abdomen, Rectum and Anus, Butterworth 2<sup>nd</sup> ed 1969 p.322 with kind permission.*

#### TREATMENT

Treat with praziquantel 15-25mg/kg bd for 7-14 days, pre-operatively. This kills the proto-scolices. Small cysts may disappear without surgical intervention. Albendazole in high doses (10mg/kg od for 28 days) damages the germinal membrane and so is complementary to praziquantel. You should therefore use both! Repeat the dose 4 times after a rest interval of 15 days. It is contraindicated in pregnancy. Mebendazole 600mg tds for 3wks is an alternative, but only effective in c.40%. Use cimetidine 400mg bd in addition.

## PERCUTANEOUS ASPIRATION, INJECTION AND RE-ASPIRATION (PAIR)

Treat medically first for a minimum of 3wks.

**If there is a single cyst <5cm diameter**, withdraw as much fluid as you can under ultrasound guidance through a wide-bore needle, and inject, preferably through a T-connection piece, an equivalent volume (or slightly more) of a scolicide (preferably chlorhexidine 0.04%, which is safer and more effective than other scolicides such as cetrimide, 70% alcohol, 1% povidone iodine, 0.5% silver nitrate, hydrogen peroxide or hypochlorite). Start slowly by injecting a small volume; if there is any pain, abandon the procedure. If not, continue, and re-aspirate after 1hr.

*CAUTION! Don't use formalin or hypertonic saline as scolicides.*

*Don't use PAIR if the cyst communicates with the biliary tree.* Remember that the liver moves with respiration and so even then a needle will not stay immobile.

## LAPAROTOMY FOR HYDATID CYSTS OF THE LIVER (GRADE 3.4)

### INDICATIONS

Large, symptomatic, subcapsular cysts in young patients; large especially peripheral viable cysts, prone to traumatic rupture.

*Don't attempt operation if the cyst is high on the right, under the diaphragm, or there are multiple, deep-seated cysts, or if there is a communication with the bile ducts because extensive mobilization of the liver will be necessary.*

**PREPARATION.** Kill the hydatids and make dissemination less likely by using praziquantel or albendazole.

Treat with hydrocortisone 100mg IM 12h before the operation, so as to minimize the danger of anaphylaxis when you open the cyst and reduce the risk of laryngeal spasm.

Have ready: An aspirator, or a large-bore syringe with a needle and 3-way tap; a long pair of sponge forceps, and a sterile kitchen spoon to scoop out the cyst; coloured packs which will let you see the brood capsules and scolices more easily (soak the packs in scolicide); 2 suckers, one for the trocar (if you use one), and another ready for any spills; a sterilized 6x15cm tubular polythene sheath; and a scolicide.

### INCISION

Make a midline incision unless the cyst is very peripheral. If necessary, extend this laterally in a J-shape, so that you have adequate exposure. Another way of getting better access is to stuff packs, soaked with scolicide, into the right subphrenic space, so as to push the liver down. If you know exactly where the cyst is, a subcostal incision may be even better.

The cysts present as smooth white swellings. Look and feel carefully to find how many there are. The rest of the liver is usually large, smooth, and distended.

Select a place where the cyst is close to the surface, and isolate it with carefully placed scolicide-soaked packs.

Suture a tubular polythene sheath 6x15cm with 3/0 silk to the pericyst without puncturing the cyst. Aspirate through the polythene sheath at least half the fluid with a 1.5mm needle (15-10C).

**If the needle blocks**, clear it by injecting a little scolicide. If needle aspiration does not work, use a trocar and cannula. If necessary, try introducing a multi-holed catheter through the cannula. This will however increase the risk of spillage. If many daughter cysts block the sucker, it is probably multilocular.

Collect the fluid in a bag containing an excess of scolicide. *Don't use an open dish as fluid may spill!* Keep a record of the volume you withdraw, as a guide to how much scolicide you will need to inject. Leave the needle in place and inject 50-100ml scolicide back into the cyst until it becomes tense. Then tie a purse-string suture snugly round the puncture site, and remove the needle. Wait for 10mins for the contents of the cyst to become sterile.

Re-aspirate the cyst till it becomes flaccid and open it through the part which presents most easily. Insert the tip of the sucker, and suck out the remaining fluid. Record-sized cysts have had over 40L! Using a kitchen spoon, remove all the daughter cysts, sediment and debris (15-10E). Then, using finger dissection, find the natural plane of cleavage between the ecto- and the endocyst.

To get adequate exposure, you may have to incise the cyst across the full width of its bulge, and deroof it. Remove the yellow laminated membrane of the endocyst completely, piece by piece, with sponge forceps (15-10F). There will be little bleeding.

### *CAUTION!*

- (1) Try not to rupture the daughter cysts as you remove them, because their contents are probably still infective.
- (2) *Don't try to remove the ectocyst*; it is tightly stuck to the liver, and will bleed.

Swab the inside of the cyst with packs soaked in scolicide, and explore it for secondary cavities. If you find any, repeat the process of aspiration and injection.

**If the cavity is small**, you may be able to bring its edges together with mattress sutures.

**If the cavity is large**, you can:

- (1) Suture any obvious small bile duct openings, and leave it alone, which is probably the wisest method.
  - (2) Fill it with ordinary 0.9% saline, and suture it.
  - (3) Saucerize it by excising the protruding portion. The difficulty with this is that the cut surfaces of the liver will bleed.
  - (4) Fill it with a graft of omentum. Dissect a strip of omentum on a vascular pedicle and stitch this into the cavity. The omentum will swell to fill the space and absorb the fluid from the cavity.
  - (5) Bring the walls of the cyst together with multiple absorbable sutures, so that the cavity is obliterated.
- Drain large cavities for about 10 days, especially if you have not been able to remove all the endocyst.

**CAUTION!**

(1) *Don't let the untreated cyst fluid spill*, or daughter cysts will form in the peritoneal cavity.

(2) If the needle hole leaks, insert a purse-string suture.

**If the cyst is a simple non-hydatid cyst**, you can simply deroof it and obliterate the cavity with omentum. Make sure you control bleeding from the cut cyst edge with a running suture or diathermy.

## DIFFICULTIES WITH HYDATID CYSTS

**If there are signs of peritonism with an anaphylactic response, shock, and dyspnoea**, the cyst has ruptured into the peritoneal cavity. Use hydrocortisone 0.5-1g IV, and adrenaline 1:1000 1ml SC.

**If the blood pressure falls alarmingly and there is no other reason for it**, the cause is probably an anaphylactic reaction. Treat as above. Alternatively the cyst may have eroded into a major vessel such as the inferior vena cava or portal vein: apply pressure with your fingers and get suction, bulldog clamps *etc* as for a vascular injury.

**If there is generalized abdominal swelling**, consider the possibility of HYDATIDOSIS OF THE PERITONEAL CAVITY. At operation you may find the peritoneal cavity distended with hydatid cysts, and remove bucketfuls of them. Try to remove as many of them as you can. Then flood it with liberal quantities of 0.04% chlorhexidine solution as a scolicide. Aspirate this and then irrigate it with saline to wash out the remaining scolicide. The surface of the bowel may be seeded with small white nodules. Make sure you start praziquantel and albendazole unless already started.

**If there is a cyst in the omentum**, try to remove it entire, with part of the omentum. If you cannot do this, aspirate and inject scolicide, as for the liver.

**If there is a cyst in the spleen**, perform a splenectomy (15.17).

**If there is a cyst in the kidney**, aspirate under ultrasound guidance, and introduce scolicide as above.

**If there is obstructive jaundice, perhaps with cholangitis**, aim to drain the common bile duct (15.7). Remove all hydatid sludge, debris, and daughter cysts from the duct, and irrigate it thoroughly. Drain the common bile duct with a T-tube.

**If a cyst is leaking into the peripheral bile ducts**, sterilize, evacuate, and drain the cyst. An external biliary fistula may develop, which may improve cholangitis which is likely to be present.

**If a fever develops post-operatively**, the cyst cavity is probably infected. Treat with gentamicin or chloramphenicol.

**If there are features of a liver abscess** – a swinging fever, anorexia, and increasing pain – suspect that a hydatid cyst has become infected. Open it, saucerize it, and drain it (15.10). Infection will have destroyed the hydatids.

**If there are recurrent cysts**, they will probably take about 3yrs to develop, be multiple, and be in the abdominal cavity. Distinguish recurrent cysts from the manifestation of an unsuspected second cyst. Start medical treatment.

**If there are cerebral cysts also**, use praziquantel in higher doses (60-90mg/kg bd for 30 days), together with dexamethasone 4mg qds.

**If a cyst is calcified and asymptomatic**, leave it alone.

**15.13 Pancreatitis**

Both acute and chronic pancreatitis are not uncommon; rarely a pancreatic pseudocyst (15.14) or abscess (15.15) develop as complications. If the patient does not recover 1wk after an acute episode, suspect such complications.

Pathologically, **acute** pancreatitis varies from oedema and congestion of the pancreas to its complete autodigestion, with necrosis, haemorrhage, and suppuration. Less severe forms may go on to form a tender, ill-defined mass in the epigastrium.

The main symptom is pain, which can vary from moderate epigastric discomfort to an excruciating, penetrating agony, which bores through to the back, and needs high doses of opioids to relieve it. There is tenderness in the epigastrium, perhaps with guarding. Vomiting, paralytic ileus and the outpouring of fluid into the retroperitoneum may result in severe fluid loss. If you see bruising around the umbilicus or in the flanks, this indicates intra-abdominal haemorrhage and means the pancreatitis is severe.

The underlying cause is usually:

- (1) alcohol abuse (especially spirits), or
- (2) gallstones (or 'sludge'), and occasionally,
- (3) *ascaris* worms,
- (4) liver flukes,
- (5) leptospirosis,
- (6) HIV disease (including treatment with ARV therapy),
- (7) mumps or *coxsackie* virus,
- (8) hypercalcaemia, hyperlipidaemia,
- (9) systemic lupus or cystic fibrosis,
- (10) trauma (including endoscopic instrumentation),
- (11) drugs such as sulphonamides, thiazides, oestrogens,
- (12) poisons such as organophosphates,
- (13) *tityus* scorpion envenomation (in Trinidad, Brazil and Venezuela),
- (14) typhoid (rarely).

You may diagnose pancreatitis clinically, or from laboratory tests, or only when (*in error*) you perform a laparotomy for an acute abdomen. Estimating the serum amylase is not difficult, and your laboratory should be able

to do it, because *you should avoid a laparotomy for pancreatitis at all costs!*

**Chronic** relapsing or recurrent pancreatitis is one of the causes of a severe chronic upper abdominal pain. It is quite common in alcoholics anywhere, and there is a calcific type found much in Kerala and Orissa in India, but also in Japan and sub-Saharan Africa; the pancreas calcifies and its endocrine function deteriorates. A longitudinal pancreaticojejunostomy is helpful if the pain is debilitating, but this is formidable surgery indeed. Chronic pancreatitis may also be due to tuberculosis (16.5).

## ACUTE PANCREATITIS

DIFFERENTIAL DIAGNOSIS includes:

- (1) gastritis,
- (2) perforated peptic ulcer (13.3),
- (3) acute cholecystitis (15.3),
- (4) rupture of a liver abscess (15.10),
- (5) strangulating upper small bowel obstruction (12.2).

**SPECIAL TESTS.** Serum amylase rises within hours of the start of the pain, and remains high for about 2 days. A level of >1,000 Somogyi units is almost diagnostic. A peritoneal tap in the right lower quadrant will confirm the diagnosis: the aspirate may be straw-coloured, or reddish-brown, but its amylase is always high.

In severe acute disease (Ranson's criteria):

- (1) the white count is >16000/mm<sup>3</sup>
- (2) the glucose is >10mM; after 48h,
- (3) the haematocrit drops >10%,
- (4) the urea rises >10mM,
- (5) the serum calcium drops <2mM,
- (6) the pO<sub>2</sub> drops <60 mm Hg with a metabolic acidosis.

Hyperglycaemia is common with chronic calcific pancreatitis.

(The Balthazar score gives the severity of the pancreatitis in terms of the degree of inflammation and necrosis seen, but this needs contrast-enhanced CT scanning.)

**RADIOGRAPHS** are not very helpful but may show pancreatic calcification, if there have been previous attacks; and a left pleural effusion, or distended loops of bowel from ileus.

**ULTRASOUND** demonstrates oedema, and fluid collections (or even necrosis) of the pancreas (38.2d). You may see gallstones, and especially 'sludge' in the common bile duct, or a completely different diagnosis!

## TREATMENT

**If pancreatitis is mild**, it will settle by a regime of restricting oral intake, with nasogastric drainage, analgesia and IV fluid replacement.

**If pancreatitis is severe**, replace fluid loss energetically with large volumes of 0.9% saline, Ringer's lactate, or a plasma expander. Correct electrolyte losses. Monitor the urinary output, the haematocrit, and if possible, the central

venous pressure. Monitor glucose; start an insulin sliding scale. The pain may be overwhelming: treat with large doses of opioids, supplemented by diazepam or promethazine. Administer oxygen by mask; consider mechanical ventilation. Prophylactic antibiotics, especially against *staph aureus*, are advisable. You may need blood transfusion later.

**If you are sure of the diagnosis**, *don't operate; but it is better to operate unnecessarily than not to operate on a case of strangulated bowel, for example.* The amylase level may rise with necrotic bowel. Severe cases may benefit from lavage with saline, *via* tubes which can be inserted in the flanks under LA (13.3), but attacks tend to recur. Formal open lavage is then better.

**If you do open the peritoneum**, you will know that there is pancreatitis when you see areas of whitish-red fat necrosis on the transverse mesocolon, or omentum, and the exudate described above. The pancreas feels swollen and oedematous, and may contain greenish-grey necrotic areas. The fat necrosis may be confused with TB, so take a biopsy. Drains by themselves don't help, but you may use them for continuous peritoneal lavage.

**If the abdomen is difficult to close**, leave it open as a laparostomy putting on a vacuum dressing (11.10, 11-20) or make fasciotomies in the rectus sheath.

## DIFFICULTIES WITH ACUTE PANCREATITIS

**If you find that there are also gallstones**, consider doing a cholecystectomy (15-4) later. *Don't be tempted to remove the gallbladder in the acute phase.*

**If, during the course of 2-3wks, septicaemia develops**, suspect that a pancreatic abscess (15.15) is developing, especially if there is haematemesis.

**If deterioration continues**, your only chance will be to refer to a centre where CT scanning is available: a pancreatic necrosectomy may be life-saving.

**If respiratory or renal failure develop**, usually in the first 48h (5-10% chance), death is likely. There is little you can do except treating with oxygen, plenty of IV fluids, and plasma expanders. Monitor the CVP, ventilate mechanically, add broad-spectrum antibiotics and nutritional support.

## 15.14 Pancreatic pseudocyst

A large watery pancreatic exudate sometimes collects in the lesser sac. This has no epithelial lining, hence the term 'pseudocyst'. It usually presents >3-4wks after an abdominal injury, or an attack of acute pancreatitis, with a mass in the abdomen and epigastric discomfort or pain. There may be toxæmia with fever and tachycardia, but the degree of sickness is much less than in acute pancreatitis, or a pancreatic abscess. The mass usually distends the abdomen: it may extend right across the epigastrium, and

reach down to the umbilicus or beyond it. It is not usually tender, but may be quite tense and not fluctuant if very large. Sometimes, there are symptoms of pancreatic insufficiency, with steatorrhoea.

You can drain the cyst into the stomach, jejunum, or percutaneously into a bag. The correct timing of these procedures is important because the cyst has to mature to hold sutures. It may not do so properly in HIV disease. Draining it is less urgent than draining a pancreatic abscess (15.15), and there is less chance of complications. External drainage usually results in leakage and skin excoriation, *and should be used only as a last resort*; cystogastrostomy is simple but cystojejunostomy is the definitive operation, and you should be able to manage this if you are confident with bowel anastomoses.

**SPECIAL TESTS.** The amylase level in the cyst fluid is grossly raised.

**ULTRASOUND** shows a large cyst easily, though you may have difficulty differentiating it from a liver cyst (38.2b,d).

**RADIOGRAPHS** are less useful: you can make the diagnosis by adding oral contrast: a lateral film of barium in the stomach will show a mass bulging into the contrast from behind. There is gross widening of the normal contour of the duodenum. You may see patches of calcification in the pancreas. Or, insert a nasogastric tube and inject 200ml of air into the stomach and take a lateral supine view of the abdomen. In a pancreatic pseudocyst the stomach is displaced forwards; in a liver abscess, backwards.

#### DRAINAGE FOR PANCREATIC PSEUDOCYST (GRADE 2.4)

##### TIMING

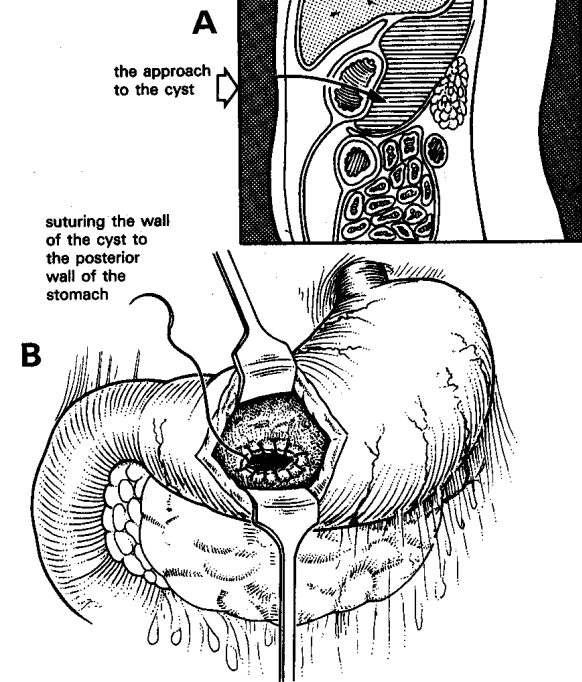
*Don't operate until >6wks after an attack of pancreatitis*, by which time the cyst wall will be mature enough to take sutures. Once a pancreatic pseudocyst is palpable, it rarely disappears spontaneously. Operate as soon as possible after 6wks; if you leave it too long, it may bleed, rupture, become infected, or destroy much of the pancreas.

**DIFFERENTIAL DIAGNOSIS** includes:

- (1) liver abscess (15.10),
- (2) hepatoma (15.11),
- (3) hydatid cyst (15.12),
- (4) renal cyst or hydronephrosis (27.14),
- (5) gastric outlet obstruction (13.7),
- (6) Burkitt's lymphoma (17.6),
- (7) abdominal tuberculosis (16.1),
- (8) aortic aneurysm (35.8).

Rarely, a pancreatic carcinoma can form a cyst.

## PANCREATIC PSEUDOCYST



**Fig. 15-11 PANCREATIC PSEUDOCYST.**

**A, approach to the cyst through the anterior and posterior walls of the stomach. B, suture the wall of the cyst to the posterior wall of the stomach to control bleeding.**

*After Maingot R, Abdominal Operations, HK Lewis 4<sup>th</sup> ed 1961 p.557 Fig. 26, permission requested.*

It may be necessary to drain the cyst earlier if it is about to rupture, if it causes persistent intractable vomiting, or has started to bleed.

You can drain the cyst percutaneously under LA; make sure you put two purse strings to hold the drain and invert the cyst around the drainage tube as for a gastrostomy (13.9). The problems are leakage and resulting skin excoriation. External drainage is a temporary measure if you are unable to perform a formal internal drainage procedure.

#### CYSTOGASTROSTOMY FOR PANCREATIC PSEUDOCYST (GRADE 3.2)

##### PREPARATION

In dehydration, anorexia, or toxæmia, administer IV fluids and high-calorie, high-protein enteral feeding for a few days pre-operatively. Insert a nasogastric tube the evening before the operation, and wash out the stomach thoroughly.

##### INCISION

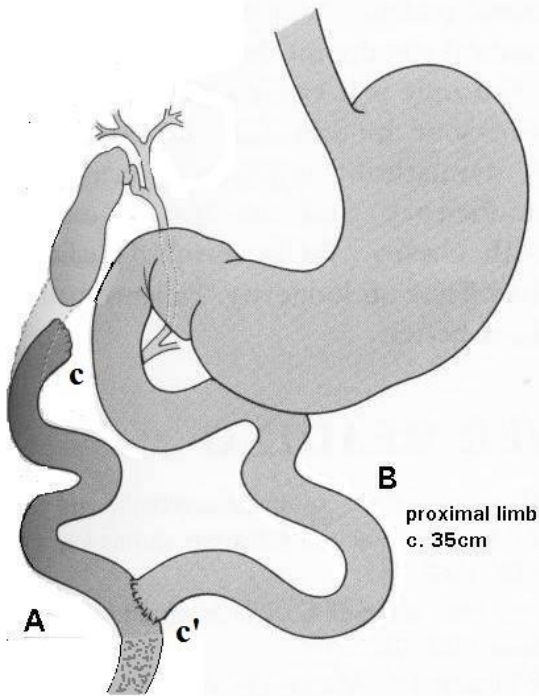
Make a midline incision. Choose an area on the anterior wall of the stomach that is overlying the cyst. Use a knife or diathermy to start a 4cm incision in the long axis of the stomach between 2 Babcock forceps. Enlarge it with scissors. Clamp any briskly bleeding vessels, and retract the edges of the incision, so that you can inspect the posterior wall of the stomach. Suck it empty.

After opening the stomach, aspirate through its posterior wall into the cyst. Expect to find a mildly opaque straw-coloured or murky brownish fluid. If so, insert a small haemostat through the hole in the stomach into the cyst, and open it so as to enlarge the opening to 3cm. Suck out the fluid: expect to aspirate up to 4L.

**CAUTION!** *Don't incise the cyst widely;* it may bleed severely.

**N.B.** *If you aspirate fresh blood,* the 'cyst' may be an aortic aneurysm: *stop!* Get an ultrasound scan (38.2e).

### ROUX LOOP



**Fig. 15-12 THE ORIGINAL ROUX LOOP.**

**A**, the distal afferent (Roux) loop, which you can use to drain the gallbladder, bile duct, pancreatic cyst, or stomach. **B**, the proximal efferent loop. The small bowel has been divided at **c**, and the proximal part anastomosed end-to-side at **c'**. Here the plan is to anastomose the Roux loop to the gallbladder.

If you have waited the 6wks for adhesions to form and the cyst wall to mature, there will be no need to suture the stomach wall to the cyst, as they will already be tightly stuck together. But control brisk bleeding from the stomach edge; so quickly oversee the opening all round with a continuous interlocking haemostatic suture of 2/0 non-absorbable. *Don't use absorbable suture,* because pancreatic juice digests it.

When you are sure the posterior opening in the stomach is no longer bleeding, close the anterior opening in two layers, the first a full-thickness haemostatic continuous layer of 3/0 absorbable sutures, and the second a seromuscular Lembert layer of continuous non-absorbable suture. Close the abdominal wall in the usual way.

### CYSTOJEJUNOSTOMY-EN-Y FOR PANCREATIC PSEUDOCYST (GRADE 3.5)

**INCISION.** This is the definitive operation. Proceed as above; after opening the cyst, lift up the proximal jejunum and look at its blood supply; select a point 30cm from the ligament of Treitz at which to divide the bowel so that the distal loop easily reaches the pseudocyst. Divide the bowel between non-crushing clamps. You will need to divide some of the vascular arcades in the mesentery to mobilize the distal bowel (the Roux loop) adequately. When you are satisfied there is no tension, make an end-to-side anastomosis of the loop to the opening in the pseudocyst. Then anastomose the proximal cut end of jejunum to the right side of the Roux loop some 20cm along its length with an end-to-side anastomosis, making sure the bowel lies comfortably. Close any mesenteric defects carefully avoiding damage to the fine mesenteric vessels.

### SIMPLE CYSTOJEJUNOSTOMY FOR PANCREATIC PSEUDOCYST (GRADE 3.4)

**INCISION.** This is a simpler, but less satisfactory, procedure. Make a midline incision. Open the lesser sac to get access to the pancreatic pseudocyst; check that its wall is thick enough to hold sutures. Then pack off the abdominal contents with large swabs, open the cyst by 2cm only and drain its contents. Bring a loop of proximal jejunum up to the cyst and make a side-to-side anastomosis (as for a gastrojejunostomy (13-16)).

**POST-OPERATIVELY,** restrict oral intake with nasogastric suction for 3-4 days, until flatus is passed; then start oral fluids, followed by a soft diet.

### 15.15 Pancreatic abscess

This is a dangerous complication of acute pancreatitis (15.13) or perforated duodenal ulcer. Occasionally it results from severe pancreatic injury. A collection of pus, necrotic tissue, and clot fills the lesser sac; it enlarges behind the peritoneum, it expands anteriorly to obliterate the lesser sac, and it pushes the stomach and transverse colon forwards. It may present with a catastrophic haematemesis.

If the abscess develops during the course of an attack of pancreatitis, the diagnosis is usually obvious, but it may be difficult otherwise. So if ever a severely sick patient has an ill-defined deep-seated epigastric mass, remember that there might perhaps be a pancreatic abscess.

**SPECIAL TESTS.** The urinary and serum amylase are usually high. Check the glucose.

**ULTRASOUND.** A fluid-filled cavity is seen adjacent to the pancreas, as a pancreatic pseudocyst (38.2d). *Aspiration is difficult and hazardous, so is not recommended.*

## LAPAROTOMY FOR PANCREATIC ABSCESS (GRADE 3.4)

**PREPARATION.** Resuscitate with adequate IV saline or Ringer's lactate. Correct hyperglycaemia with insulin. Administer oxygen, bicarbonate and calcium in seriously ill patients. Catheterize the bladder. Treat with gentamicin, ampicillin and metronidazole. Cross-match blood. Decompress the stomach with a nasogastric tube.

**EXPLORATION.** Make an upper midline incision from the xiphisternum to beyond the umbilicus. Open the abdominal cavity with care, because the mass, or the stomach or colon, may have stuck to the abdominal wall. You may find it difficult to know what you are seeing. Dissection is difficult and dangerous, because the tissues are so vascular and oedematous. Lift and free the abdominal wall from the organs under it, and insert a self-retaining retractor. Feel for the upper border of the abdominal mass. Try to find a place where you can incise it without injuring anything. This will usually be through the lesser omentum, or better, the transverse mesocolon to the left of the ligament of Treitz. When you have decided where to drain, seal the area from the rest of the peritoneum with large moist packs. Using a syringe and a large needle, aspirate the place where there seems to be the thinnest layer of tissue between the abscess and your finger. Take pus for culture. If you find pus under pressure, decompress the abscess with suction. Enlarge the abscess so that you can insert two fingers, but *don't try to dissect further*. Wash out any floating solid matter.

**CAUTION!** *Don't disturb the necrotic pancreatic tissue at the bottom of the abscess – it will bleed!*

Place 2 catheters in the abscess cavity, and bring them out through stab wounds. Bring one out anteriorly, and the other as far back as possible, in the most 'dependent' position. Use these to irrigate the abscess cavity continuously (about 2L in 24h). Make a feeding jejunostomy (11.7), because oral feeding will not be possible for 3wks, and you will probably be unable to feed parenterally. Feeding through a jejunostomy results in less secretion of gastric juice than feeding through a gastrostomy.

### POST-OPERATIVELY

Continue nasogastric suction, fluids, and antibiotics until the temperature is normal. Chart the daily drainage output. *Don't be in a hurry to remove the drains*, even if leaving them in does seem to increase the risk of a fistula. Allowing pus to collect again is a greater risk. If the wound is looking fairly clean, close it by secondary suture in 7-10 days.

**CAUTION!** *This is heroic surgery!* A pancreatic abscess carries a 30-50% mortality, and often reforms, even with adequate drainage. If so, be prepared to re-operate 3 or 4 times if necessary. However, if you don't operate, death is inevitable!

### DIFFICULTIES WITH PANCREATIC ABSCESS

**If pancreatic juice is still discharging after 2wks**, leave the catheters *in situ* for a month and then withdraw them slowly 5cm per day.

**If a pancreatic fistula develops**, collect the juice in a stoma bag with the orifice carefully cut to size to prevent skin excoriation. This can be mixed with jejunostomy feeds if malabsorption is a problem.

**If bleeding becomes severe**, try pinching the vessels in the free edge of the lesser omentum between your fingers and pack the pancreatic area. Leave the packs for 48h and remove them at a second laparotomy, when bleeding should be much less.

## 15.16 Pancreatic carcinoma

If the carcinoma is in the head of the pancreas (70%), it may obstruct the common bile duct, so that presentation is with painless progressive obstructive jaundice (15.9). If it is in the body of the pancreas (30%), presentation is with upper abdominal and back pain and general symptoms of malignancy. Spread to the lymphatics and surrounding structures is early, and 10% of patients develop ascites. Thrombophlebitis migrans (thrombophlebitis in any superficial vein appearing, resolving, and then appearing again elsewhere) may occur with any malignant tumour, but is particularly common with this one.

Radiotherapy, chemotherapy, and surgery are of little value, but differentiation with tuberculosis is important. Taking a biopsy of the pancreas itself may cause pancreatitis and worsen the condition, so try to get a piece of tissue from an adjacent node or piece of omentum. Sometimes carcinoma of the pancreas cannot be easily distinguished from chronic pancreatitis (15.13) or tuberculosis.

## 15.17 Surgery of the spleen

If you operate on the spleen, you often end up removing it. The indications for doing so (apart from trauma) must be good, because the spleen of a tropical patient is commonly large, and may be so firmly stuck to the diaphragm that:

- (1) exposing it is difficult.
- (2) bleeding is likely from the vascular adhesions that join it to the diaphragm.

**If there is portal hypertension**, the vena cava carries high pressure venous blood which escapes into the systemic circulation.

Remember the spleen protects against subsequent infection, especially *pneumococcal* pneumonia, malaria and dog and cat bites with *Capnocytophaga canimorsus* (a common commensal) which may rapidly be fatal. Infection is even more common if HIV is present.

## INDICATIONS (OTHER THAN FOR TRAUMA) FOR SPLENECTOMY

### (1) Spontaneous rupture

This is rare, but may occur typically in massive malarial (*not bilharzial*) splenomegaly; though it may be truly spontaneous, *e.g.* in mononucleosis, the patient may not remember any trauma because it was slight. It may occur after colonoscopy. Signs are of shock, left upper abdominal pain and abdominal distension, although initially there may be felt a *reduction* in abdominal girth as a large spleen bleeds.

### (2) Hypersplenism

A big spleen may be responsible for removing all the blood cell lines, resulting in anaemia, leucopenia and thrombocytopenia of varying severity, though the thrombocytopenia is commonest. The problem is that the same picture can be shown by HIV disease, which itself can give rise to splenomegaly. Thrombocytopenia is a serious hazard in surgery and so you need to have some experience before attempting a splenectomy without platelets available for transfusion. However, your hand may be forced if a patient continues to bleed elsewhere because of the thrombocytopenia, particularly if there is portal hypertension.

**If the underlying cause is HIV disease**, blood counts will improve with ARV therapy (5.8) without splenectomy. You should anyway be wary of removing a spleen when there is HIV disease because of the risks of infection; you may be able to make the distinction between hypersplenism and HIV-pancytopenia by looking at a bone marrow film: this is normal or *hyperplastic* in hypersplenism, but *hypoplastic* in HIV disease.

### (3) Chronic idiopathic thrombocytopenia

Here the low platelet count is *not* associated with an enlarged spleen but through destruction of platelets by antibodies. There are often 'megathrombocytes' in the peripheral blood film and raised numbers of megakaryocytes in the bone marrow.

It occurs more often in females than males (4:1); there is usually quite a good response to prednisolone, but eventually this option becomes undesirable in the chronic case.

However, splenectomy may not benefit 20% of cases. *Don't do it if systemic lupus erythematosus or rheumatoid arthritis is the cause of the chronic thrombocytopenia. Never do it for the acute thrombocytopenia, and especially not where thrombocytopenia is due to drug sensitivity (especially quinine).* If you have access to radiotherapy, this may be the safer option.

### (4) Haemolytic anaemias

There are several haemoglobinopathies, including sickle cell trait (*never sickle cell disease*) thalassaemia, and spherocytosis for which splenectomy may be beneficial, but their selection needs the advice of an expert.

### (5) Splenic torsion or wandering spleen

These are both very rare and arise when the spleen has an abnormally long pedicle and no adhesive attachments. You are unlikely to make the diagnosis before you operate. Torsion of the spleen tends to occur during pregnancy when it is confused with an ovarian tumour!

### (6) Hydatid cyst (15.12).

### (7) Malignancy

HIV-ve lymphoma, *Schistosomiasis*-related giant follicular lymphoma, chronic myeloid or lymphatic leukaemia, or fibrosarcoma affecting only the spleen, but you should get advice from an expert.

KASHY (20yrs) complained of a swelling in the right iliac fossa. Ordinarily, it was painless but during attacks of 'fever' it became painful and tender. At laparotomy, the whole spleen was found to be in the right iliac fossa, but the splenic vessels crossed the abdomen to their normal position. The 'wandering spleen' was removed easily.

LESSON Some rare conditions have easy solutions.

## CONTRAINDICATIONS TO SPLENECTOMY

(1) **Splenic abscess** (15.18) occurs occasionally. It starts acutely, it may become chronic, and it shows up radiologically as a fluid level in an irregular space. Ultrasound shows the spleen to be filled with dense fluid. The pus is sterile usually, but may be secondary to amoebiasis, brucellosis, salmonellosis, leptospirosis or candidiasis. There may be sickle cell disease, acute myeloid leukaemia or pancreatitis. Carefully pack away other abdominal viscera, and drain the abscess: don't try to remove the spleen.

### (2) Tropical splenomegaly syndrome

This is an immune response to recurrent attacks of malaria, and is responsible for nearly all large spleens in malarious areas. It responds to long courses of antimalarials. *Don't remove such spleens unless hypersplenism is a complication.*

### (3) Splenic tuberculosis (16.5)

Anti-TB therapy should make splenectomy superfluous; fibrosis during healing will shrink the spleen. HIV disease is particularly likely.

(4) **Leishmaniasis** (34.7). Medication should likewise make splenectomy unnecessary.

(5) **Acute diseases**, *viz.* leptospirosis, acute thrombocytopenia.

### (6) HIV disease (5.6)

Whilst not an absolute rule, the risk of infection increases, and so the indication must be really good. Institute ARV treatment first.

### CAUTION!

(1) *Don't operate lightly*; your only absolute indications for doing so are the first three.

(2) If the spleen is huge, think seriously about operating because it may need a thoraco-abdominal approach.

## SPLENECTOMY (GRADE 3.4)

### PREPARATION

Make sure you have a wide-bore cannula in place for fluid replacement; have blood cross-matched (but don't be in a hurry to raise the haemoglobin if this has been chronically low), and a nasogastric tube to decompress the stomach. Provided there is no allergy, always give prophylactic penicillin perioperatively. Place a sandbag or pillow behind the left thorax to rotate it to the right.

**INCISION.** Make a midline or left subcostal incision: this will give better direct access to the spleen, and you can extend this as a Chevron with a right subcostal incision. Alternatively for a very big malarial spleen, you can make a left thoraco-abdominal incision, because this allows you to see vascular diaphragmatic adhesions directly (11.1). Or you can turn the patient to the right, by propping up the left flank; this allows a huge spleen to 'fall out' of the abdomen more easily when mobilized.

Doing an elective splenectomy is different from an emergency splenectomy in that you can approach the spleen in a relaxed manner. Explore the abdomen, noting the condition of the liver and presence of any lymph nodes, as well as the mobility of the spleen. If it is adherent, and large, it is wisest to open the lesser sac and tie off first the splenic vessel artery and then the splenic vein before proceeding.

You can improve access by placing a pack behind the spleen if there are insignificant adhesions. Otherwise divide the peritoneal attachments. If bleeding is a problem at this stage, deliver the spleen, rotate it forwards to the right and tie a thick ligature right round the entire splenic pedicle. This is safer than trying to grasp it with a large clamp. As you do so, try not to damage the stomach, and try to cause the least possible damage to the pancreas. When you have controlled bleeding, proceed to tie the vessels individually.

Enter the lesser sac by opening a window in the greater omentum, and lift up the stomach off the pancreas by dividing the adhesions between them a short distance. Then feel for the splenic artery along the upper border of the pancreas. Incise the peritoneum over it, pass an angled haemostat underneath it and pass ligatures round it.

Carefully expose the splenic vein by dissecting away the fatty tissue in the pedicle. Then tie off the splenic artery, tie the vein and divide the splenic pedicle. For extra security, apply a second set of ligatures at the same point before the vessels divide. *Don't leave a long splenic vein stump which may thrombose!*

**CAUTION!** Make sure you pass the ligatures and tie them before dividing the vessels. If you use haemostats and the cut vessel drops off and is lost in a pool of blood, you may never find it again.

**If you haven't been able to draw the spleen forwards,** do so now, if necessary by dividing adhesions to the parietal peritoneum. Then divide the peritoneum lateral to the spleen (the lienorenal ligament); put your finger into the opening

and gently free the spleen. You can now bring it well outside the abdomen. Free the splenic flexure of the colon from the spleen and separate the tail of the pancreas from the splenic vessels. Free the spleen from its attachments to the greater curvature of the stomach by dividing the short gastric vessels individually in the gastrosplenic ligament.

**CAUTION!** *Don't include an area of stomach wall with your ligatures,* especially at the upper margin of the spleen.

Remove the spleen, keeping it in saline for possible autotransplantation (see below), and put a big dry pack in the splenic bed. Leave it there for 5mins; then remove it and look for any bleeding vessels and tie them off. If the operative site is not absolutely dry and you are uncertain about an injury to the tail of the pancreas, place a large drain in the splenic bed.

**SPLENIC IMPLANTATION.** *This is controversial and may not work.* Keep some slices of spleen, say 5x3x0.5cm, and implant them under the peritoneum in the side wall of the abdomen, or in the anterior abdominal wall. Or, place some 1cm cubes of spleen within a sandwich of omentum. They will usually take, and may reduce the severity of attacks of malaria and perhaps the danger of septicaemia, but will not fully protect against *pneumococci*.

The risk of adhesions is much less than the risk of life-threatening infections. You can check if the splenic slices are functional after 4wks if there are no Howell-Jolly bodies and no target cells in the peripheral blood film, and the platelet count is normal.

*Don't do this with splenectomy indications 4,5,6 or if there is already an accessory spleen.*

### SEGMENTAL SPLENECTOMY (GRADE 3.5)

Preserving a functional remnant of c.20-30% of the spleen avoids septic and immunological problems also; it can also be used in hypersplenism. You need to devascularize anatomical segments (especially middle and lower portions) of the spleen, by ligating branches of the splenic artery at the hilum.

Wait for 5mins to observe a line of demarcation, and cut it along this line in a V-shape whilst squeezing the proximal portion manually. A vascular clamp across the pedicle will reduce bleeding. Then sew over the remnant an omental patch, bringing the edges of the 'V' together. This is not easy surgery.

### DIFFICULTIES WITH SPLENECTOMY

**If you have damaged the stomach or the colon,** close the perforation in two layers with long-acting absorbable suture; make sure nasogastric suction is in place. Start gentamicin and metronidazole.

**If you have damaged the pancreas,** suture a piece of omentum over the damaged segment and leave a drain. Try to monitor amylase levels of fluid draining.

**If bleeding from the diaphragm persists,** insert one or two dry packs for 10mins by the clock; then come back and remove them to see if you can identify the bleeding vessels to tie them. If you still fail to control bleeding, leave packs

tightly *in situ*, close the abdomen, and return after 48h to remove them, by which time the bleeding will almost certainly have stopped.

**If shock suddenly develops post-operatively**, a ligature has probably come off. Re-open the abdomen immediately, with good suction available, to try to find the bleeding vessel, and tie it off.

**If the wound sloughs and there is a fluid discharge**, the tail of the pancreas or stomach may have been injured. Re-open the wound, and suture a piece of omentum over the damaged viscus; *don't try to ligate the pancreas or suture the gastric perforation* as sutures will probably cut out and cause more damage.

**If there is fever with no obvious cause**, and you have given penicillin, check for a subphrenic abscess (10.2).

**If there is rapidly developing haemolytic anaemia and fever**, suspect malaria or babesiosis, a tick-borne illness usually affecting domestic or wild animals, and get both thick and thin blood films. Use quinine 650mg orally tds and clindamycin 600mg orally tds for 5-10 days.

**If there is respiratory distress post-operatively**, think of a pneumothorax.

#### POST-OPERATIVE CARE AFTER SPLENECTOMY

Treat with penicillin or ampicillin prophylactically intra- and post-operatively for 2wks, and longer in children <2yrs. Follow protocols for *pneumococcus*, *haemophilus* and *meningococcus* vaccine if possible. *Insist on malaria, meningitis and tick-bite fever prophylaxis in endemic areas, including in the perioperative period.*

### 15.18 Splenic abscess

This starts acutely, though it may become chronic. It occurs in sickle cell disease, acute myeloid leukaemia, HIV+ve patients with candidiasis, and secondary to amoebiasis, brucellosis, salmonellosis, leptospirosis and occasionally as a result of acute pancreatitis or perforation from a gastric ulcer. The danger is rupture into the peritoneal or pleural cavity which may be accompanied by disastrous bleeding.

There is left upper abdominal pain, a dragging sensation in the abdomen, discomfort after meals, anorexia, and a palpable tender mass extending down from the left upper quadrant towards the right lower quadrant. This might be huge. There is usually anaemia and a low-grade fever. The mass may be tympanic because it usually is filled with gas, arising from oxygen liberated by red cells in the spleen, and carbon dioxide from tissue metabolism rather than gas-forming organisms.

**SPECIAL TESTS.** Leucocytosis and anaemia are usual, but the white count may not be raised with HIV disease. In Southeast Asia, check for melioidosis (6.10).

**CHEST RADIOGRAPH.** An erect film will show a gas bubble and fluid level below the left hemidiaphragm, pushing it upwards.

**ULTRASOUND.** Look for a fluid-filled cavity in the area of the spleen (38.2g). Much of the splenic tissue may be destroyed. Aspiration will confirm the diagnosis, but beware of causing severe haemorrhage or rupturing the colon. You may be able to aspirate a splenic abscess completely, and avoid surgery. Treat with antibiotics 48h beforehand and then follow a procedure as for a liver abscess (15.10).

#### LAPAROTOMY FOR SPLENIC ABSCESS (GRADE 3.1)

**INDICATIONS.** Essentially all splenic abscesses need surgery.

**PREPARATION.** Cross-match blood and start pre-operative penicillin and metronidazole.

**EXPLORATION.** Make a left subcostal incision or Chevron (inverted-V double subcostal) for very big abscesses. Pack away the rest of the abdominal contents. Drain the abscess and leave a large tube or catheter in the space, passed through a separate stab incision in the lateral abdominal wall. Lavage the abdomen with warm saline or water.

#### DIFFICULTIES WITH SPLENIC ABSCESS

**If access is difficult** and you have made a midline incision not expecting a splenic abscess, extend it as an inverted-L laterally with a left subcostal arm, as a left-sided Kocher incision (11-1).

**If serious bleeding from the spleen ensues**, pack the area and press firmly. Get assistance. Place a further pack (or two) above and behind the spleen to lift it forward, and perform a splenectomy (15.17). If you are experienced, this is the definitive operation rather than simple drainage.

**If you find a gastric perforation**, the tissues will be very friable. *Don't attempt to close the perforation with sutures*, but stuff a segment of omentum into the hole, and fix it there with absorbable sutures. Make sure you drain the stomach with a nasogastric tube. You are unlikely to be able to save the spleen because unravelling the inflamed tissues will damage it and result in considerable bleeding. Grasp the hilum of the spleen, place a pack or two behind it, and perform a splenectomy (15.17).