

# 21 The surgery of labour

## 21.1 Two different worlds of obstetrics

If labour does not proceed normally, intervention to help the woman may be necessary. How best you should do this, and what methods you should use, depend greatly on where she is. This has been beautifully described:

Obstetrically, there are now two worlds, with pockets of one world in the other, and every gradation between the two. In the advantaged industrial world Caesarean Section is now so safe that it has done much to change the whole pattern of obstetrics there. In that world obstetric services are good, and theatres and blood banks well organised. If a woman needs a Caesarean Section, it is done by a skilled obstetrician and an experienced anaesthetist. Antenatal care is available everywhere, transport is easy, and most women are sufficiently educated to understand why they should have a hospital delivery if they need one. Most of them only plan to have 2 or 3 children anyway, and are not frightened by the possibility that Caesarean Section might reduce their chances of having any more. Just because it is so safe, it is used electively for up to even 40% of women as a means of anticipating difficulty, rather than dealing with disaster. It is done so efficiently that seriously traumatic vaginal deliveries and perinatal deaths from birth injury have almost disappeared.

Most women in low- and middle-income countries are less fortunate. A really disadvantaged woman must have 6-7 children, in order to be sure that 3 or 4 will survive. If she has an obstructed labour in a distant village, she may arrive in your hospital after a long journey, dehydrated, ketotic, shocked, anaemic, or infected, or all of these things. If you have to perform a Caesarean Section, you may have to do it through infected tissues, so that it may be followed by peritonitis, which antibiotics may fail to control.

When she has recovered, she may remember only a frightening operation followed by a difficult puerperium, and deliberately not seek hospital care when she becomes pregnant again. If the foetus died, she may blame the hospital for the death, and decide to have the next one at home. Unfortunately, Caesarean Section seldom removes the factor which caused it, the narrow pelvis, which may have been the reason for the Caesarean Section, will still be present. But the scar in the uterus is now its weakest part, so that the chances of it rupturing are great.

*Lawson J. Embryotomy for obstructed labour. Tropical Doctor. 1974;4(4):188-91.*

How can you help a woman like this? She may have no antenatal care in the next pregnancy, and be unable to reach hospital for the next delivery. How can obstetrics be adapted to the needs, without being dominated by the practice of the industrial world?

*The answer is to make good use of the alternatives to Caesarean section, and one of the main purposes of this chapter is to describe them.*

Unfortunately, in many hospitals, the methods used to assist a woman who has prolonged or obstructed labour are unnecessarily limited. If an oxytocin infusion and a vacuum extractor fail – in some settings, not even those two life-saving options are employed to overcome non-progress in labour – Caesarean section is automatic, and no one thinks of other possibilities. If cephalopelvic disproportion (CPD) is mild, perform a symphysiotomy (21.7). If the foetus is dead, perform a destructive operation (21.8). At all counts it should be possible to learn how to manage a breech delivery (22.7) and other abnormal presentations without resorting to Caesarean section, except as a last resort.

One alternative which needs the hands of an expert obstetrician is the standard type of mid-cavity rotational forceps, such as Kielland's. *In the hands of anyone else, these forceps are so dangerous that the mother and her foetus will be safer if you use vacuum extraction, which you should learn anyway.* So you will find that the only forceps we describe here are Wrigley's outlet ('low') forceps. Perhaps the only acceptable use of the standard mid-cavity forceps by non-experts is their application to the aftercoming head during a breech delivery. For this purpose you can however usually use outlet forceps instead.

**The first priority**, when a woman is admitted in labour, is to examine her immediately, or to get the most experienced person available to do so. There should be a careful re-assessment  $\leq 4$ hrly thereafter and observations in between, accurately recorded on the partograph (21-2). *Unless this happens, the whole process of labour management breaks down.*

*N.B.* In some areas, traditional midwives may use herbs to induce labour, and this may result in inappropriately early and forceful contractions!

Your team will need guidelines to know when to call you. For the most part, they are the same as those for which a health centre refers a woman to hospital. Make it a point that no one should hesitate calling you early, rather than calling too late, even if this means you will get many calls at first.

When you start any operative delivery, make sure that the midwife who is assisting you knows how to resuscitate the baby, and has the equipment ready for doing this. In some hospitals, the results of not doing so are seen only too tragically, in the numbers of handicapped children who attend the paediatric clinics.

*Don't forget to relieve pain when you can, so make proper use of pethidine, ketamine and LA.*

## 21.2 Obstetric anaesthesia

Anaesthesia is often the most dangerous part of a difficult delivery. In many district hospitals you can avoid GA in obstetrics; consider also avoiding it for Caesarean section. When the patient is bleeding, or is already hypovolaemic, or very ill, you'll need to manage GA expertly. Unless you use ketamine, you'll need to intubate the patient. *Full GA is dangerous in the circumstances of many labour wards, and the operating theatre may take dangerously long to get ready.*

You can perform most Caesarean sections under subarachnoid (spinal) anaesthesia, provided you take the necessary precautions. You can also use ketamine and LA. For a vacuum extraction, use a pudendal block, with LA for the episiotomy if used, though it is not always necessary. For a destructive operation, other than a transverse lie, use a pudendal block combined with IV ketamine. For a transverse lie, use ketamine or spinal anaesthetic. For manual removal of the placenta, use ketamine.

Epidural anaesthesia is excellent, but may be impractical, except in specialized, well-staffed, well-maintained obstetric units where rigorous aseptic procedures are in place. You will need staff to monitor the patient carefully post-operatively.

### Pudendal block for an operative vaginal delivery

This is not 100% effective but may still be useful in certain situations. The danger of a needle-stick injury with a transvaginal or perineal pudendal block is high; you have to locate the ischial spines by palpation through the vagina canal on either side at 4 and 8 o'clock.

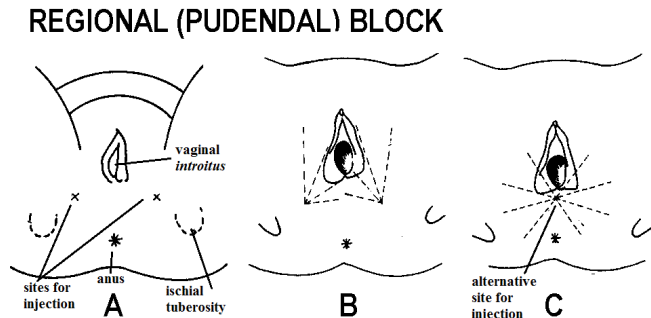


Fig. 21-1 REGIONAL BLOCK FOR AN OPERATIVE VAGINAL DELIVERY. A, position of injection sites for pudendal block through the perineal skin. B, direction of block from each side. C, or from a single central puncture site.

After Howie B. *High Risk Obstetrics* Macmillan 1986 Fig. 14-6,7 with kind permission.

Raise a skin wheal of LA halfway between the vaginal opening and the ischial tuberosities or centrally (21-1A,C). Use a 12cm x 1mm needle to reach the ischial spines. Inject 12.5ml of 0.5% lignocaine or 1% procaine (both with adrenaline) on each side. Supplement this with superficial infiltration for most operative vaginal deliveries. Withdraw the needle while you inject 25ml of solution in the directions shown. Use a total of 50ml. For an episiotomy and vacuum extraction, superficial infiltration alone may be enough.

#### CAUTION!

- (1) Premedicate with pethidine.
- (2) Distinguish the ischial spines from the ischial tuberosities.
- (3) *Always aspirate with the plunger before you inject.* If you withdraw blood, move the needle to avoid injecting the anaesthetic solution IV.
- (4) Allow the anaesthetic at least 3mins to act.

## 21.3 Delay in labour

Labour is seldom any problem if it goes at its proper pace. Most trouble starts when it is prolonged or the foetus cannot cope with the temporary lack of exchange caused by contractions interfering with the blood supply to the placenta. Even if the foetus can cope but reacts, for example, to cord or head compression by cardiac deceleration, it is difficult to be sure that no intervention is needed. Most unnecessary interventions have no serious consequences in rich countries but they may have deadly results in other circumstances, directly or a few years later.

(a) **The partograph** (21-2). In order to manage delay in labour, you must know as early as possible that it has occurred. To know this, you will need an effective method of monitoring labour. The most important part of this is plotting the dilation of the cervix in cm, and the descent of the head in fifths above the brim, against the duration of labour in h.

The purpose of the partograph is:

- (1) To prevent neglected obstructed labour and ruptured uterus (which cause 70% of maternal deaths in some areas) by enabling peripheral health workers to monitor labour, to detect deviations from the norm more effectively, and thus to refer women at the optimal moment, before it is too late. **This is the purpose of the 'alert line'.** Ideally, you should only use the partograph to monitor those women whose labour is expected to be normal; *women with obvious 'risk factors' should already have been prepared for assisted delivery.*
- (2) To monitor all women in labour in hospital, so that you know when to intervene. This is the purpose of the 'action line'. If the 'progress line' of a woman's cervical dilation moves to the right of the alert line, be extra-vigilant. **If the progress line reaches the action line, you must intervene, if you have not already done so.**

The partograph depends on the principles that:

- (1) The duration of the 1<sup>st</sup> stage of labour (though this is difficult to define as it may include false contractions) should not last longer than 8h, hence the thick vertical line at this point.

- (2) The latent phase ends and the active phase starts when the cervix is 4cm dilated (3cm was used in the past; it is best to stick to WHO guidelines if these are the rule nationally).
- (3) During the active phase of the 1<sup>st</sup> stage, the cervix should dilate quickly at  $\geq 1\text{cm/hr}$ .
- (4) A lag time of 4h is usually acceptable between the slowing of labour and the need to intervene; this is the distance between the alert and the action lines.

*N.B. This lag time of 4h is obviously too long if there is a scar on the uterus.*

The WHO partograph uses fixed alert and action lines and transfers the patient to the alert line as soon as she reaches 4cm, as has been done for one particular patient (21-3C).

Dilation of the cervix and its relation to the action line is only one of the factors measuring the progress of labour and the necessity to intervene. It and the descent of the foetal head are the 2 most useful and the most easily plotted. Other important factors are:

- (1) the presentation,
- (2) the moulding (foetal skull bone overlap) score (21.5),
- (3) the presence of foetal distress,
- (4) the woman's condition,
- (5) the duration and frequency of contractions.

Consider all these factors, and *don't be guided only by the dilation of the cervix* in relation to the action line and by the descent of the head, critical though these are. The position of the action line is to some extent arbitrary, and some obstetricians like the alert and action lines closer together.

In some circumstances there is a line halfway in between and parallel to the alert and action line. This is called the transfer line and is used, for example, in peripheral urban clinics to indicate the best time that the woman should be referred to a nearby hospital.

Intervention needs to be earlier in a multipara than in a primipara, so some partographs have 2 action lines, one at 3h for multipara and one at 4h for primipara.

Some hospital partographs leave out the action line altogether and take the alert line as the action line. The important point is that *the further the progress line is from the alert line, the greater should be your vigilance*, and usually the greater your need to intervene.

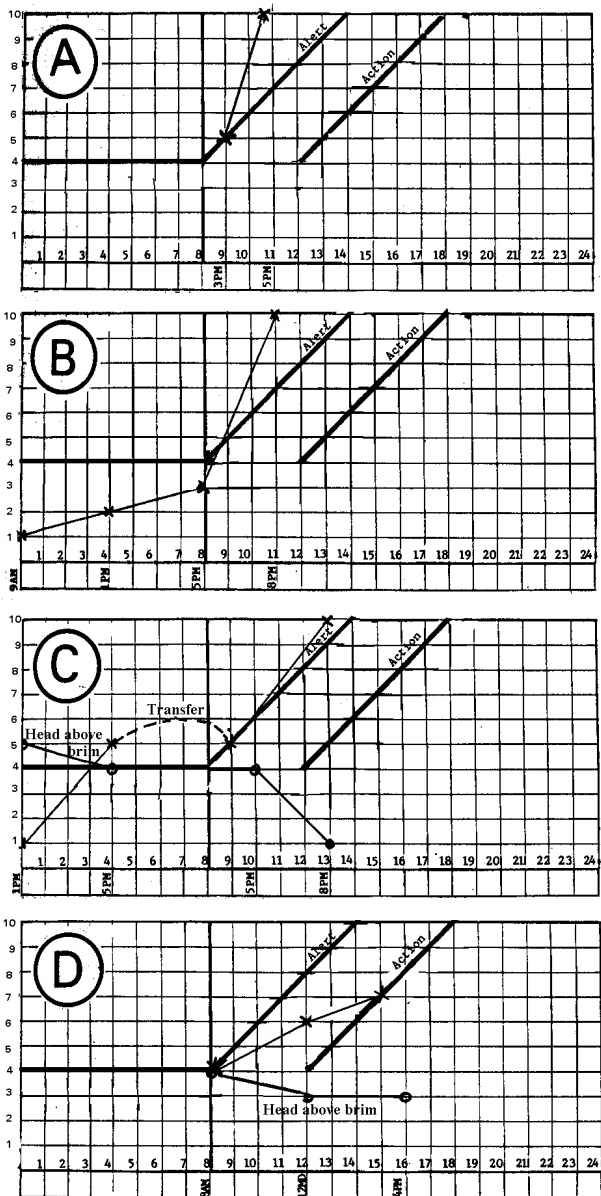
When the patient approaches the action line, assess all the factors listed above (and others) and decide what to do next, using the guidelines described for normal labour and for obstructed labour (21.4).

*N.B.* Some hospitals consider that the requirement for some intervention if there is no dilation  $\geq 1\text{cm/hr}$  is 'too active', and leads to an unnecessarily high Caesarean section rate, which is not suitable for populations with an average of perhaps 4-6 children, and when Caesarean section has to be done under less-than-ideal circumstances in small hospitals, so they give the alert line a flatter slope. This is justifiable at 4-7cm of cervical dilation, but  $>7\text{cm}$  4h delay is too long.

Partographs have proved so useful in reducing both maternal and perinatal mortality that not to introduce them might almost be considered criminal neglect. *If you don't already use them, you must! N.B. Partographs don't tell you about risk factors present before labour!*

### ARE YOU AND YOUR RURAL CLINICS USING PARTOGRAPHS?

SOME PARTOGRAPHS

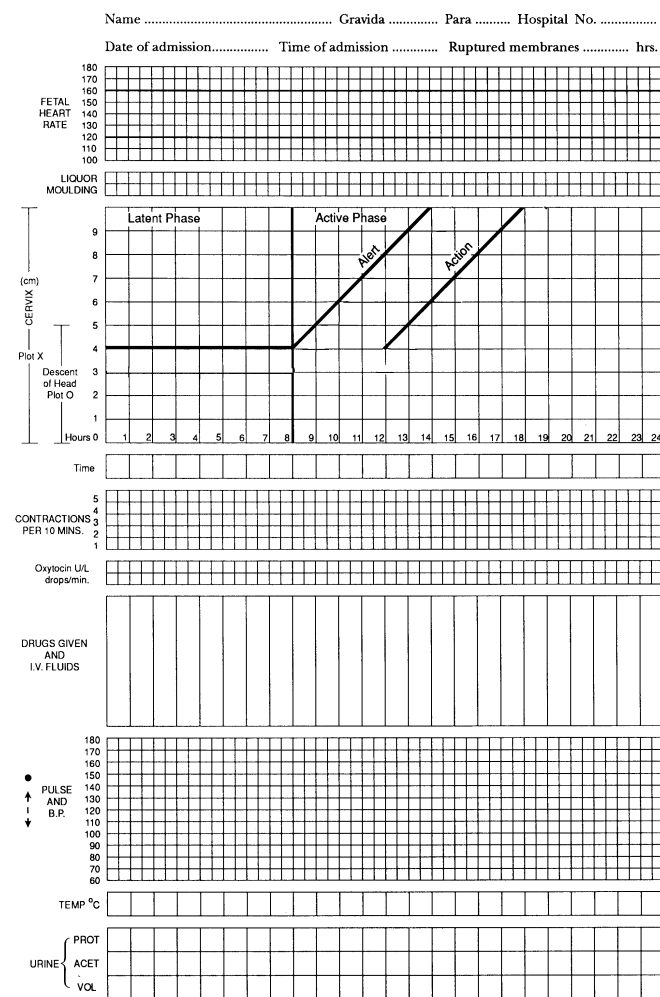


**Fig. 21-3 SOME PARTOGRAPHS.** If you don't have enough partographs for every woman, put a clean sheet of X-ray film over one of them, write on this with a marker pencil, and then wash the film clean for the next patient.

Woman A was admitted at 3pm 4cm dilated in the active phase of labour; the progress line remained to the left of the alert line and she delivered normally.

Woman B was admitted at 9am 1cm dilated; the latent phase lasted 8h and the active phase 3h. She quickly passed to the left of the alert line.

Woman C was admitted at 1pm 1cm dilated with the foetal head  $\frac{5}{5}$  above the pelvic brim. At the next vaginal examination (5pm) the head was  $\frac{4}{5}$  above the brim and she was 5cm dilated. She was therefore transferred to the 'alert line'; the cervix continued to dilate, the head descended, and she delivered normally.



**Fig. 21-2 THE PARTOGRAPH** is a very useful tool for managing labour. The vertical scale on the left measures cervical dilation in cm and the descent of the head in fifths above the pelvic brim. 'LIQUOR' represents rupture of the membranes and release of amniotic fluid.

Woman D was admitted to a health centre with the foetal head  $\frac{4}{5}$  above the brim and the cervix 4cm dilated, so she was put on the alert line. At 12 noon she was only 6cm dilated and had moved to the right of the alert line, so she was transferred to hospital. When she arrived at 4pm she was still only 7cm dilated and had reached the action line. The head was  $\frac{3}{5}$  above the brim, with a moulding score of 3 (21.5); it was not possible to put a finger between the head and the pelvic wall. So, following the indications outlined (21.4), she underwent a Caesarean section. If however she were a nullipara, the foetal heart action excellent and an anaesthetist available within 1h, a trial of oxytocin (for a maximum of 1h) might still prevent a Caesarean section. Alternatively a symphysiotomy (21.7) may allow a normal delivery.

#### THE CRITICAL AREA IN A PARTOGRAPH

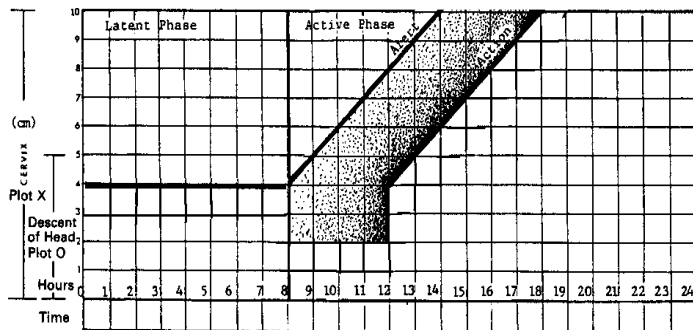


Fig. 21-4 THE CRITICAL AREA IN A PARTOGRAPH.

In a peripheral unit, if a woman's progress line reaches this area, she should be referred. In hospital, it is the area in which you should consider intervening; the darker the shading, the more important this is. *Don't let her cross the action line without careful reassessment!*

#### METHOD

Make sure this is not actually obstructed labour (21.4) by excluding:

- (1) severe moulding (21.5) and caput (soft scalp swelling, caused by the foetal head being pressed against the cervix),
- (2) foetal distress,
- (3) stretching of the lower segment, where the peritoneum becomes firmly attached to the anterior uterine wall (21.5),
- (4) bloody urine.

*N.B. DELAY IN THE LATENT PHASE* (primipara and multipara) is present if a patient who was 'admitted in labour' has not reached the active phase after 8h.

Distinguish 'false labour' from a truly prolonged latent phase.

Recognize false labour by:

- (1) membranes still being intact, and
- (2) the cervix of a nullipara remaining long and closed (or just admitting a fingertip), or the cervix of a multipara being not effaced, *i.e. thinned and shortened* (even though it may be 1-2cm dilated).

Explain that she is not in labour, and return her to the waiting shelter. If she insists that she feels painful contractions, administer pethidine 100mg IM, let her sleep, and then review her after 3h.

*N.B. If you artificially rupture the membranes and start an oxytocin infusion, you inevitably pass the point of no return and increase the chance of needing to perform a Caesarean section. This is only really indicated if you want to stimulate labour for example because of pre-eclampsia, gestational diabetes, or sickle cell disease.*

**If the latent phase is truly prolonged, the cervix is completely effaced, but remains undilated at c.2-3cm, or effaces and dilates very slowly, you have 2 choices:**

(1) Use sedation with pethidine 50-100mg IM, repeated if necessary, and allow mobilization.

(2) Administer very low dose misoprostol 20µg 3hrly (4ml of a 100µg ( $\frac{1}{2}$  tablet) dissolved in 20ml water) if there is an indication to induce but not strong enough to risk a Caesarean section by rupturing the membranes. Once labour starts, stop the misoprostol!

#### (b) Delay in the active phase in primipara

**If the progress line for a primipara approaches the action line, there may be simply a decrease in contractions, or obstructed labour.**

Perform a Caesarean section if there is:

- (1) gross cephalopelvic disproportion: head  $\frac{4}{5}$  above the brim and marked moulding,
- (2) a malpresentation, or
- (3) foetal distress.

**If there is no evidence of malpresentation or foetal distress, first correct dehydration and ketosis with an infusion of IV saline or Ringer's lactate, and provide adequate analgesia: either by a lumbar epidural block or use pethidine 100mg + promethazine 25mg IM.**

Then *in a primipara* where there is no foetal distress, nor scar in the uterus (also from myomectomy for example), stimulate the uterus with oxytocin and try to decide if the CPD is significant.

*N.B. Using oxytocin in women who have previously delivered is increasingly dangerous with each delivery. Meconium-stained liquor is in itself not a contraindication to the use of oxytocin but very good monitoring is mandatory. Often the first sign of impending uterine rupture, rare in primipara, is foetal distress. Women who have previously delivered vaginally are anyway less likely to have a decrease in contractions after real labour has started and oxytocin is less likely to be of benefit in this group.*

(Of course, you can use oxytocin to start labour in a multipara whose membranes have already ruptured but it should be stopped as soon as labour is established. *Note this is then induction, not augmentation, of labour.*)

Start an infusion of a solution of 5U oxytocin to 500ml of 5% dextrose at 10 drops/min, and increase the rate of the infusion by 10 drops/min at  $\frac{1}{2}$ hrly intervals, until there are contractions lasting 45-60secs at a frequency of 3-4 in 10mins. (This means the first increment will be 20drops/min, and 30mins later 30drops/min.) As soon as you witness good contractions, *don't increase the speed of the IV infusion anymore.* You may even decrease the drop rate if the foetal head is coming down and is well applied to the cervix.

**If good contractions (3-4 in 10mins lasting >40secs) don't clearly give rise to progress, and the membranes are ruptured, then there is an indication for a Caesarean section unless the cervix is nearly fully dilated.**

*N.B.* It is difficult to know what good contractions are, however. The frequency is easy to monitor, but the intra-uterine pressure is measurable only with a transducer in the uterus and even then, although low pressure is an indication for oxytocin, proper pressure does not mean the pressure is directed by coordinated contractions in the right direction. Consequently, estimate the length of contractions as an indicator of their strength: <20secs is weak, 20-40secs moderate, > 40secs is strong.

**If you are sure labour has started, the cervix is dilated  $\geq 4\text{cm}$  and the membranes are not already ruptured,** rupture them. *Remember the risks of prolonged rupture of membranes!* Monitor the mother's progress and the foetal condition carefully. Monitor the heart and watch for signs of foetal distress, especially a slowing of the foetal heart.

*N.B.* Meconium staining of the liquor is common, but is an unreliable sign.

**If you detect signs of foetal distress,** stop an oxytocin infusion if one is running.

*N.B.* Oxytocin itself can, of course, cause such strong, long, or frequent contractions that foetal distress ensues. Stopping the infusion and restarting it later at a lower rate might still result in the vaginal delivery of a healthy baby. On the other hand, some foetuses just cannot cope with inadequate contractions; if the contractions are optimized with oxytocin to cause further cervical dilation, the foetus is in danger. This is then definitely an indication for a Caesarean section, with poor descent of the head or even when almost full cervical dilation has been reached.

**If there is severe CPD,** which you can recognize by (1) inadequate cervical dilation and foetal descent, especially associated with foetal distress, (2) cervical dilation proceeding at <1cm/hr at the end of 4h, with no descent of the foetal head, or (3) the foetal head remaining high, with moulding, perform a Caesarean section.

*N.B.* Inadequate cervical dilation and foetal descent without foetal distress may suggest the option of a vacuum extraction (sometimes combined if necessary with a symphysiotomy, 21.7).

#### (c) Delay in the active phase in multipara

**If the progress line for a multipara approaches the action line,** this is serious, and you will need to assess the situation carefully. *Don't try to stimulate the uterus with oxytocin,* unless you are as sure as you can be that there is no CPD (21.6). This is difficult to be sure about, and if you are wrong, and there is CPD, the uterus may rupture. A good rule is: *no oxytocin for augmentation of labour in multipara unless you supervise it personally (not over the telephone) and certainly not for multipara >3, and for not longer than 2h!*

*N.B.* For a multipara whose membranes have ruptured, for example, it is acceptable to start labour carefully with oxytocin and reduce or stop the infusion as soon as labour is established. This applies also to a breech presentation.

**If you are sure labour has started (the cervix is >3cm) and the membranes have not already ruptured,** rupture them, *but take cautions regarding HIV exposure.* Labour goes faster

in multipara and prolonged exposure to vaginal HIV is less likely. Under close supervision, it is reasonable to start oxytocin at 4-6cm cervical dilation and if good contractions ensue, then to rupture the membranes.

**If you are in doubt,** observe for 2h more with adequate analgesia, and then reassess the patient. Feel the contractions yourself. She may progress to full dilation even when there is major CPD. You can only detect this by finding severe moulding and caput, with failure of the head to descend, and no progress or movement (>20secs in the 2<sup>nd</sup> stage, 21-5B,C).

*CAUTION!* Some women have 6 or 8 normal labours, and then need Caesarean section for CPD with their next pregnancy. *Don't forget to offer a sterilization with the Caesarean section in such a situation.*

#### (d) Difficulties with delay in labour

**If there is delay in the latent stage,** look carefully for hidden CPD. Provided there is a vertex presentation, it is always worth sedating the patient and waiting a little to see what happens.

*N.B.* CPD is almost impossible to diagnose when the membranes are intact and rupturing the membranes might be a good idea if the cervix is very ripe. Even if you are using oxytocin properly, its use with an unripe cervix will increase your Caesarean section rate.

**If there is foetal distress with an oxytocin infusion running,** *stop it;* turn the patient onto the left side, do a vaginal examination to exclude prolapse of the cord, and make sure she is adequately hydrated and administer oxygen. If the signs are not relieved, proceed to Caesarean section.

## 21.4 Obstructed labour

The exact point at which lack of progress (21.3) becomes **obstructed labour** is arguable. This is the failure of the presenting part to descend despite good uterine contractions. What really distinguishes prolonged labour from obstructed labour are the secondary signs and complications that follow: severe moulding (21.5), caput (21.3), intra-uterine infection, prolonged suffering, fear of death, pain between contractions, foetal distress, a stretched lower segment (21-5), bloody urine, fistulae and rupture of the uterus. Whereas delay in labour is common and often readily treatable, and is comparatively harmless, obstructed labour is none of these things. *It should never be neglected if care is adequate.* Arguably, obstruction is not uncommon (*e.g.* a failed properly executed vacuum extraction) *but obstructed labour should never be neglected.*

(a) **Recognized scenarios of obstructed labour** are, for example:

- (1) needing 3h to organize a Caesarean section after a failed vacuum extraction, without knowledge of how to perform a symphysiotomy (21.7); or
- (2) having waited for 2h with the mother actively pushing, without having attempted a probably easy vacuum extraction and needing 3h to organize a Caesarean section.

**(b) Causes of obstructed labour** may include:

- (1) An abnormality in the pelvis (a contracted pelvis): a true conjugate (antero-posterior diameter at the pelvic inlet) should be >9cm, and the diagonal conjugate (transverse diameter) 1.5-2cm larger.
- (2) An abnormality in the foetus (hydrocephalus, etc.).
- (3) An abnormality in the relationship between them, either:
  - (i) An abnormal lie or presentation (breech, brow, face, shoulder presentation, or prolapsed arm in a transverse lie),
  - (ii) An unfortunate coincidence of their relative sizes.

**Cephalopelvic disproportion** means the foetus may be too big for the mother, or *vice versa*.

- (4) A marginal CPD and/or soft tissue resistance combined with contractions which are not optimal, or poor pushing by the mother.
- (5) Rarer causes, such as stenosis of the vagina (particularly after FGM), locked twins, or a pelvic tumour, particularly fibroids or an ovarian cyst.

*N.B.* CPD is the most important cause (>65%), and an impacted transverse lie is the next most.

In well-nourished mothers (but not over-nourished) with an adequate pelvis, the occipito-posterior position is often involved in obstruction. This partly explains why the same woman often delivers the second, heavier, baby vaginally without problems.

In over-nourished women, the large size of the foetus and perhaps weaker contractions and fat in the pelvis are responsible for much obstruction.

Vitamin D deficiency seems to be involved in weak contractions. This is important for women whose diets are poor in vitamin D, and who cover themselves nearly completely when they venture outside. This is especially important if they live in climates with little sunshine and when they also have much pigment to block UV light.

**(c) Antenatal care screening** is mainly to detect women who are at risk from obstructed labour, although the sensitivity and specificity of this screening are quite limited.

The purpose of the partograph, however, is to detect it early in labour and it works (with cephalic presentations in single pregnancies) much better than screening.

In practice, when the presenting part stops moving through the birth canal, you may not be able to tell if this is because:

- (1) the uterine contractions are weak (uterine inertia), or
- (2) there is CPD.

Often in a primipara, there is a combination of inertia and CPD.

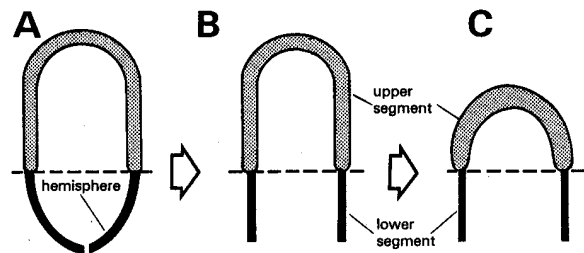
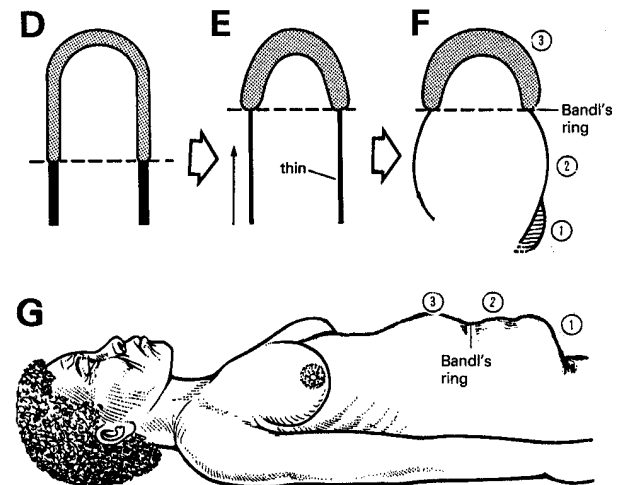
**(d) Preventing obstructed labour** depends on several factors:

- (1) Good nutrition starting in childhood and good health promoted by vaccinations, hygiene and mosquito nets so that women reach their genetically determined height and the pelvis its genetically determined size before the first delivery.
- (2) Avoiding teenage pregnancy where a girl has to deliver before the pelvis has reached its maximum size.
- (3) Universal antenatal care, so that obstructed labour can be anticipated from the history and any risk factors identified.
- (4) The monitoring of labour by skilled staff, so that a woman can be referred at the first sign of danger, before she obstructs.

Detailed preventive measures are:

- (a) screening for risk factors, especially short stature, and
- (b) the routine use of the partograph.

When adequate antenatal care is impossible, and where health centre and hospital beds are limited, the establishment of a 'mothers' waiting area or temporary village' is a useful alternative.

**OBSTRUCTED LABOUR****Normal labour****Obstructed labour**

**Fig. 21-5 OBSTRUCTED LABOUR.**

A,B,C, during a normal labour, the hemispherical lower segment is converted into a cylinder: it thins but does not elongate. During the 2<sup>nd</sup> stage, the uterus shortens itself by contraction of the upper segment. D,E, during an obstructed labour, the uterus cannot empty, so the thinned lower segment elongates. F, sometimes a palpable (Bandl's) ring forms between the upper and lower segments. G, from the side, you may sometimes see or feel three distinct abdominal swellings: (1) the bladder, (2) the lower segment, (3) the upper segment. Bandl's ring separates the lower and the upper segments.

*After Lawson JB, Stewart DB, Obstetrics and Gynaecology in the Tropics, Edward Arnold 1967 Fig 11.2. with kind permission.*

**(e) Neglected obstructed labour** is a major failure of obstetric care. Unfortunately, it still happens, even in some hospitals. It often depends on the prevalence of CPD in your area, and the quality of your antenatal and obstetric care. Alas, the poorest communities with the worst health services are usually those with the most CPD.

A warning sign that labour is going to obstruct is a prolonged 1<sup>st</sup> stage, but this may be normal or even short. The membranes rupture, and amniotic fluid (liquor) escapes. The uterus contracts and retracts, and forces the foetus into its lower segment, which gradually becomes overstretched.

Foetal escape is obstructed, so the lower segment moulds closely round and thins. The contractions of the uterus become hypertonic, and relaxation between them poor. The placenta is poorly perfused, there is foetal distress, and the foetus dies.

Obstructed labour has 3 main dangers:

- (1) Stuck between the foetal head and the pelvis, the vaginal, bladder, and rectal walls become squeezed, and eventually become necrotic, slough, and develop fistulae.
- (2) Often in a primipara, the contractions stop while the head is wedged in the pelvis, causing sepsis and/or fistulae.
- (3) In a multipara, the uterus keeps contracting till it ruptures or a (nearly) dead, severely moulded baby is delivered.

**A primipara** begins to have trouble when the cervix fails to dilate normally. An oxytocin infusion may speed up labour if the CPD is minimal or the lack of progress is caused by poor contractions, but cannot do so if CPD is gross. The result is that the labour usually obstructs before she is fully dilated, although she will usually reach full dilation eventually. The results, if the situation is not rapidly relieved, are dire:

- (1) Asphyxia and infection in the foetus ensue, owing to prolonged uterine contractions reducing the placental blood flow.
- (2) The foetal head is damaged, so that brain injury may result.
- (3) Pressure necrosis and sloughing of the vaginal wall occur. As this slough separates, a fistula develops anteriorly between the vagina and the bladder (21.18), or posteriorly between the vagina and the rectum (21.19). The fistula may involve the proximal half of the urethra and/or the neck of the bladder, up to its ureteric orifices, or involve the rectal sphincter mechanism.

MPHO MOKETE (14yrs, para 0, gravida 1) became pregnant after her 1<sup>st</sup> period. She hid the pregnancy from her parents, and so received no antenatal care. She arrived at hospital exhausted, anxious, and febrile, with a fast pulse. Her contractions were strong and painful, with little relaxation between them. The head of the foetus, showing signs of foetal distress, was high, and overlapped the brim of the pelvis. The liquor had drained, so that the uterus was moulded around the foetus.

The vulva and cervix were oedematous, and although the foetal head could be felt just inside the cervix, this was not because it had descended, but because it was severely elongated. Abdominal examination showed that most of it was still above the pelvic brim. The vagina was dry and 'hot', and the cervix not fully dilated.

The bladder was distended. Catheterizing it was difficult, and the foetal head had to be dislodged by putting two fingers into the vagina and pushing it up. The bladder was drawn up so high that the catheter had to be passed a long way before any urine flowed; when it did so, it was blood-stained. The foetus was alive, and the foetal head was 4/5 above the brim, so neither symphysiotomy nor vacuum delivery were suitable. She was therefore resuscitated with IV fluids, treated with antibiotics, and delivered by Caesarean section. The baby survived with a neurological handicap, but the wound became infected, and she developed a pelvic abscess, which was drained. She was in hospital a month, and was lucky not to develop a fistula.

LESSONS (1) The decision to perform a Caesarean section was correct. (2) She was only 14, and so the pelvis will continue to grow. (3) She is at risk of a ruptured uterus in future, so she must deliver in hospital.

Later, as the ring of necrosis in the vagina heals and contracts, it stenoses. If the mother does not die, she delivers an injured, severely moulded dead baby.

She is also at risk from septicaemia, peritonitis, peritoneal abscess, atonic postpartum haemorrhage (22.11), and foot drop from the pressure of the foetal head on the pelvic nerves. Even if the fistula can be repaired, she may be infertile, and the vagina may be so stenosed that sexual intercourse is difficult. There are of course also serious psychological consequences.

If the fistula is successfully repaired, and she becomes pregnant again, she must have a Caesarean section to prevent the repair breaking down. If the fistula is not repaired (in which case she is less likely to become pregnant), stenosis of the vagina is likely to prevent vaginal delivery.

**A multipara** may show the same failure to dilate as a primipara, or the cervix may dilate normally to begin with, and then slow during the active phase, only to dilate finally if she is left untreated. Meanwhile, the presenting part fails to descend.

MAPULESA (35yrs, para 8, gravida 10) arrived at hospital just before the uterus ruptured. She too was anxious, distressed, and febrile. The cervix however was fully dilated. The lower segment had continued to retract and thin, so that the junction between the upper and lower segments had risen in the uterus as far as the umbilicus. She had a 'three-tumour abdomen' when viewed from the side: an oedematous distended bladder, a distended, tender lower segment, and a tonically contracted upper segment. A (Bandl's) ring could be felt through the abdominal wall between the upper and lower segments (21-5G). The round ligaments (21-18) stood out on either side of the ballooned lower segment, like the guy ropes of a tent. A brow presentation was felt on vaginal examination. She was resuscitated with IV fluids, and had a Caesarean section. At operation the uterus was found to have ruptured into the abdominal cavity. The foetus was alive, but was asphyxiated, and died within 1h. The uterus was repaired, the tubes ligated, and she recovered uneventfully.

LESSONS (1) Even a patient who has had many normal deliveries may get an obstructed labour from a malpresentation, malposition, or just because babies tend to become larger with higher parity and males are also on average larger and have larger heads than females. (2) A partograph would have given earlier warning of the impending obstruction. (3) Tubal ligation was essential.

**(f) Rupture of the uterus** is the critical event, in a patient like this. It usually starts in the thin lower segment, and extends downwards on one side into the vagina, as well as upwards towards the fundus. Several things can then happen:

- (1) The presenting part may remain jammed in the pelvis.
- (2) The foetus may be expelled through the rupture into the peritoneal cavity.
- (3) Bleeding from the ruptured uterus may be seen in the vagina.
- (4) Occasionally, the bladder also ruptures, especially if it is stuck to the scar of a previous lower-segment Caesarean section.

Before rupture, the signs that it is imminent are:

- (1) Failure of labour to progress. Lack of progress should therefore alert you to the possibility that rupture might be imminent.
- (2) Bandl's ring.
- (3) A distended bladder which is difficult to catheterize.
- (4) Frequent strong uterine contractions, with little or no pause between them.
- (5) Persistent pain between contractions in a restless, anxious patient.

After rupture, a woman may have little or no pain. Typically, contractions were strong, but then suddenly stopped, and were replaced by a lesser continuous pain, or no pain at all. She may be alert and even talkative, or quite obviously collapsed in severe hypovolaemic shock, with cold, sweaty skin, and a weak or absent radial pulse. She might survive only 10mins or 72h. You feel no uterine contractions, but you can usually feel the foetus through the abdominal wall lying free in the abdomen. Often the presenting part, when examined vaginally, has disappeared and cervical dilation has decreased (21.17).

*A multipara who is not steadily progressing in the 2<sup>nd</sup> stage (when the cervix has dilated fully) and has started to push but has not delivered after 60mins is in great danger.*

*N.B.* Most fistulae occurring after uterine rupture are complications of the surgery, not the labour.

## 21.5 Managing obstructed labour

**If a woman with obstructed labour is admitted from home**, she may have been in labour for days, and tried many home remedies. Her stomach is likely to be full, and she can inhale its contents only too easily if she vomits. She is thus a major anaesthetic risk. There are several ways in which you can deliver her foetus, but *you should never use mid-cavity or rotational forceps, such as Kielland's* (21.1).

Vaginal delivery is often possible, but try to predict when it is going to be difficult, so that you can avoid a 'failed vacuum', and perform a symphysiotomy (21.7) or a Caesarean section (21.9) from the start, especially when there is foetal distress. However, judging whether vaginal delivery will be successful by clinical vaginal examination can never be perfect. If you are prepared to perform vacuum extraction combined, in case of failure, with a symphysiotomy, you will be able to avoid around 25 subsequent Caesarean sections if your judgement is only wrong in 10% of cases. *This statistic is only invalid if you perform a tubal ligation at the same time as the Caesarean section.* The side-effects of one symphysiotomy are different but certainly *not* more dangerous than the side-effects of one Caesarean section, and the side-effects of 25 Caesarean sections are naturally overwhelmingly more serious and frequent than those of one symphysiotomy.

*N.B.* Of course a symphysiotomy is nearly absolutely contraindicated if the foetus has died.

*An assisted vaginal delivery* (apart from shoulder dystocia which needs a combined vaginal and abdominal approach) *is absolutely contraindicated if the uterus has already ruptured:* perform a laparotomy. Often, you will not know whether the uterus has ruptured, nor whether it will rupture in the next 30mins: so perform *all* vaginal procedures for the relief of neglected obstructed labour in the operating theatre, with equipment and staff available instantly for a laparotomy.

Caesarean section has a limited role in the management of obstructed labour, *especially if neglected*, and is likely to be a serious risk, *so don't undertake it lightly*. It is mainly indicated when the foetus is alive and the mother is in reasonable condition. However, make sure that the foetal heartbeat is still present just before you start the incision!

A destructive operation (21.8) is indicated when the foetus is dead, the cervix is fully dilated or nearly so, the presenting part is fixed in the pelvis, and the uterus has not ruptured, and is in no danger of doing so. If you are in any doubt, perform a mini-laparotomy as above. Occasionally, when a destructive operation for foetal death would be difficult, because the foetal head is mobile and  $\geq 3/5$  above the pelvic brim, you might have to resort to a hysterotomy (21.5).

### (a) Symptoms

A woman in obstructed labour is in great pain, anxiety, and distress. In the bustle of treating her, *don't forget to comfort and reassure her.*

If the foetus is already dead, inform her. *If you don't, she may blame you for its death*, and not come to hospital when she is pregnant next time.

### (b) Diagnosis

Suspect obstructed labour or neglected obstructed labour if you find:

- (1) No cervical dilation despite what appear to be good contractions.
- (2) Increasing moulding (21.5) and caput (21.3), but without descent of the foetal head.
- (3) Anxiety and restlessness.
- (4) Hypertonic uterine contractions, with poor relaxation in between.
- (5) A stretched lower segment with a Bandl's ring.
- (6) Bloody urine.
- (7) Unexpectedly easy dislodgement of the presenting part followed by a gush of vaginal bleeding: then abandon vaginal delivery and open the abdomen.
- (8) Variable or poor application of the cervix to the head.
- (9) Offensive discharge or fever.
- (10) A vesico- or recto-vaginal fistula (usually found 2-3 days after delivery).

*N.B.* Now determine if the uterus is ruptured.

**If you are in doubt about uterine rupture**, make a mini-laparotomy to check the uterus: if it is intact, proceed to a vaginal delivery while the incision is covered with sterile towels, then recheck the uterus and perhaps, when indicated and desired, tie the tubes.

This is far less risky as an operation than a Caesarean section, because the contaminated fluids in the uterus don't enter the peritoneal cavity and don't soil the uterine and abdominal wall incisions.

Otherwise, with ultrasound guidance, you can try aspiration with a long needle lateral to the uterus to reveal meconium-stained fluid (more common than bright red blood). This confirms the diagnosis of rupture.

*N.B.* *Ultrasound, on its own, is unreliable unless the rupture is obvious.*

### (c) Differential diagnosis

There is, in the main, a prolonged latent phase. If the patient was made to push during the latent phase, she may be distressed and dehydrated, and the vulva and cervix may be oedematous.

The cervix will however not be dilated, or only slightly so, the membranes are likely to be intact, and there will be no Bandl's ring. Reassurance, observation, analgesics, sedatives and IV fluid replacement may be all that is needed.

#### (d) Emergency care

Hypovolaemic and/or septic shock are very common. Resuscitation must be rapid, because delivery is urgent. Admit the patient directly to whatever high-risk area you have, usually the labour ward or the theatre, and resuscitate her there. This will allow you to operate as soon as she is in an optimal condition.

Correct the dehydration, the electrolyte deficit, and the acidosis with warmed Ringer's lactate; there is usually no need to use bicarbonate. She may rarely need blood, preferably red cells only. *If the haematocrit is raised as a result of dehydration, a transfusion, even of safe blood, may be harmful:* her primary need is IV fluids.

Administer IV chloramphenicol, benzylpenicillin and rectal metronidazole. If, in spite of adequate resuscitation, shock persists, try a titrated infusion of dopamine. This will cause peripheral dilation, so correct it immediately with more IV fluids. *Don't however waste time with sophisticated methods if your team is not familiar with them;* proceed simultaneously with delivery.

**(e) Monitoring.** Record the pulse and blood pressure every 5mins. Monitor the urine output hourly.

**If the presenting part stops descending,** the cervix usually stops dilating, although this may not be so in multipara. On the partograph, the progress line will have crossed the action line.

#### (f) Management

(1) Assess the height of the foetal head. *Don't assess this by vaginal examination only.* There will be much caput (21.3), and this will mislead you. It's the descent of the skull that matters, not the descent of the foetal scalp swelling!

(2) Calculate the foetal moulding score:

0	Bones still separate
1	Bones touching
2	Bones overlapping, but separate when you press with a finger
3	Bones overlapping but not separable

Feel where the foetal parietal and occipital bones touch one another. Overlapping at both the sagittal and the lambdoid (between the parietal and the occipital bones) sutures is more serious than at the lambdoid suture alone. An easy way to document moulding is to add the moulding between the parietal bones (PP) and the moulding between the occipital and one parietal bone (OP). So if PP 2+ and OP+, total moulding is 3+.

(3) Watch for foetal distress. Count the foetal heart rate for 30secs, before, during and after a contraction. Foetal distress is shown by a rate of <120 or >160/min or slowing which persists *after* a contraction (slowing during it is normal).

#### CAUTION!

(1) *Don't use an oxytocin infusion if there are signs of obstruction.* On the correct indications (see later), you can use it for delay.

(2) *Don't use Kielland's forceps, or try internal version.*

(3) *Never attempt an operative vaginal delivery if the uterus has already ruptured.*

*N.B.* You may not know if the uterus has ruptured, so do all vaginal procedures for the relief of obstructed labour in the

theatre, with a set of laparotomy instruments ready for instant use. Alternatively, perform a mini-laparotomy.

(4) Choose an appropriate method of delivery:

**(g) Episiotomy.** This is sometimes all that a primipara needs, especially if the foetal vertex is in an occipito-posterior position. Putting her into the lithotomy position may make delivery easier. *Beware of 'routine' use: the cut may become bigger, be painful, get infected and cause excessive blood loss.*

#### (h) Vacuum extraction (21.6)

##### INDICATIONS

(1) A live foetus with <<sup>2</sup>/<sub>5</sub> of the foetal head above the brim: the more moulding there is, the lower the head should be for a successful vacuum extraction.

(2) An occipito-transverse or occipito-posterior position, without CPD, or with only mild CPD.

(3) Definite CPD combined with a symphysiotomy (21.7).

(4) For an unconscious patient, *e.g.* with eclampsia, perhaps combined with fundal pressure to make up for the lack of straining.

##### CONTRAINDICATIONS

(1) A live baby with ><sup>2</sup>/<sub>5</sub> of the foetal head above the brim.

(2) Severe moulding.

(3) Definite CPD *unless combined with a symphysiotomy.*

#### CAUTION!

(1) Delivery with a vacuum extractor or outlet forceps should never be a difficult operation. If foetal asphyxia is already present, it should merely be a 'lift-out'.

(2) Use a systematic technique of pulling.

*Don't be afraid to use an old machine which works even if you don't have a modern Kiwi device!*

**If it has taken >3h for the cervix to dilate from 7-10cm on the partograph, or the fundal height is >40cm,** suggesting a large baby, perform the vacuum extraction in the operating theatre, and prepare for symphysiotomy or Caesarean section.

**(i) Fundal pressure** may save the day in such situations as: foetal distress, or an exhausted mother where her straining is just not forceful enough to deliver, and where a little bit of extra force will deliver the baby. Or else, even without foetal distress, when there is no working vacuum extractor present and transport to a suitable venue with better facilities will take too much time, or there is the risk of delivery in an unsuitable vehicle (or oxcart) during transport. Even in a sophisticated hospital, when a vacuum extraction is almost successful but that little extra force needed pulls off the cup, fundal pressure may solve the problem.

#### (j) Symphysiotomy (21.7)

##### INDICATIONS

A live foetus, of fundal height <40cm (2.5-4kg), in a cephalic presentation, with these scores:

Head above the brim	Total foetal moulding score (PP+OP)
≤ <sup>2</sup> / <sub>5</sub>	<6 if the head is on the pelvic floor
≤ <sup>3</sup> / <sub>5</sub>	≤3

**(k) Destructive operations (21.8)**

INDICATIONS. Make sure that *all* these conditions are met:

- (1) Foetal death or severe foetal malformation incompatible with life.
- (2) An impacted foetal head with  $\leq 2/5$  above the pelvic brim, or a transverse lie.
- (3) Cervical dilation at least 7cm, and preferably full.
- (4) *No uterine rupture, nor imminent danger thereof.*

**CAUTION!** A multipara who has been in labour for a long time will have a lower segment which will be very thin. If it is also tender and distended, it is certainly *very* thin and on the point of rupture.

*Don't push an instrument against the foetal head without somebody supporting the fundus;* otherwise your pushing might rupture the uterus if the head dislodges upwards.

*N.B. When the lower segment is paper-thin, any destructive operation will rupture the uterus,* unless you are simply decompressing a hydrocephalic head with a needle.

**(l) Caesarean section (21.10)**

INDICATIONS

- (1) A live foetus whose head is too high for vacuum extraction or symphysiotomy.
- (2) A dead foetus  $< 2/5$  above the pelvic brim, whose head cannot be pushed down into the pelvis to perform a destructive operation safely.

CONTRAINDICATIONS

- (1) A head which is deeply engaged in the pelvis ( $\leq 2/5$  above the brim).
- (2) A dead foetus which can be delivered by a destructive operation.

Here we are mostly concerned with a vertex presentation and a few curiosities. See elsewhere for a breech presentation (22.7), a transverse lie, and a brow or a face presentation (22.8).

**VERTEX CEPHALIC PRESENTATION**

**If uterine rupture is suspected but uncertain,** perform a mini-laparotomy for inspection (see above).

**If the foetus is alive and the cervix is not fully dilated,** perform a Caesarean section.

**If the foetus is alive and the cervix is fully dilated,** management depends on:

- (1) the height of the foetal head,
- (2) the degree of moulding,
- (3) signs of foetal distress,
- (4) the risks associated with needing further Caesarean sections,
- (5) the estimated size of the foetus.

**If the foetal head is:**

$0/5$  above the brim, with minimal moulding, apply the vacuum extractor and see, in the course of delivery, whether an episiotomy is needed or not.

$1/5$  above the brim, with a total moulding score (PP+OP) 0-1 and foetal distress, perform a trial of vacuum extraction in the operating theatre, with everything ready for symphysiotomy.

$1/5$  above the brim, with a total moulding score 2-3 and foetal distress, combine vacuum extraction with a symphysiotomy, or perform a Caesarean section.

$2/5$  above the brim, with a total moulding score of 0-2, maybe 3, perform a trial of vacuum extraction in the operating theatre, with everything ready for symphysiotomy or Caesarean section.

$2/5$  above the brim, with a total moulding score of 4 or possibly 5 and foetal distress, perform a trial of vacuum extraction in the operating theatre, with everything ready for symphysiotomy or Caesarean section.

$3/5$  above the brim, with a total moulding score of 0-2, perform a trial of vacuum extraction. If necessary and if the pelvis is big enough (you can get your finger between the head and the symphysis), perform a symphysiotomy.

$3/5$  above the brim, with a total moulding score of  $>2$ , perform a Caesarean section, unless you can get a finger between the head and the pelvic wall, indicating that a symphysiotomy might be possible.

**If the foetus is dead, with an impacted head  $\leq 2/5$  above the pelvic brim and the cervix is  $\geq 7$ cm dilated,** perform a destructive craniotomy, provided you can get a finger between the foetal head and the pelvis.

**If the foetus is dead and its head is mobile or  $\geq 3/5$  above the brim,** get an assistant to push the head into the pelvis as you perform a destructive craniotomy. If this fails, and the foetus is mobile enough in the uterus, see if you can insert a balloon catheter into the foetal rectum and apply traction for a breech delivery (22.7). Only as a last resort, perform a hysterotomy.

**MENTO-POSTERIOR PRESENTATION**

**If the foetus is alive and the cervix is fully dilated,** perform a Caesarean section.

**If the foetus is dead and the cervix is fully dilated,** perform a destructive craniotomy.

**(m) A congenital vaginal septum** (rare) seldom causes trouble, because it is usually quite thin, pushes to one side, and may never even be diagnosed during labour. If it does cause trouble, but is thin, you may be able to divide it. If it is thick, perform a Caesarean section, and excise it later making sure the patient is not pregnant.

**(n) A vaginal stricture** (quite common) caused by scar tissue from a previous delivery, or of uncertain cause, feels quite different from a cervix. If it is thin, incise it latero-posteriorly on both sides (at the 4 and 8 o'clock positions), and let vaginal delivery proceed, and afterwards suture the incisions if they bleed significantly. If it is wide and fibrous, perform a Caesarean section.

**(o) An ovarian tumour or a fibroid obstructing labour** (21-6). Perform a Caesarean section. If there is an ovarian cyst or tumour, you can remove it at the same time as the Caesarean section. If there is a fibroid, leave it unless it has a thin pedicle, and remove it subsequently if necessary.

*N.B. Never try to remove a non-pedunculated fibroid at Caesarean section,* as it will bleed copiously.

**(p) Post-operatively after a difficult vaginal delivery**

An over-stretched infected uterus will often not contract properly after delivery. So there is an indication for active management of placental delivery (the 3<sup>rd</sup> stage), as well as rubbing the uterus and the continuous use of IV oxytocin after the placenta is delivered.

Keep the patient in hospital for 3-4 days (7-10 days for a symphysiotomy). Observe her carefully. Before she goes home, make sure that she understands what operation she has had, and why it was done. This will be important when she becomes pregnant again.

**(q) Obstetric paralysis**

**If there is a history of neglected obstructed labour,** examine her early in the puerperium for signs of peripheral nerve injury. She may fail to complain about sensory changes and weakness, so you will have to look for them. They are present in obstetric paralysis, and may vary from mild footdrop to extensive paralysis of her legs, including her gluteal and quadriceps muscles. If you are not careful, she may develop contractures. So put her joints through their full range of passive movements regularly, and encourage her relatives to do the same. If she has a foot drop, use a posterior plaster splint to keep her ankle fully dorsiflexed at night (32.11). During the day, typical high basketball shoes make walking much easier. She is almost certain to recover, but this may take 2yrs.

**If despite infusion of large amounts of fluids, only <400ml urine is passed in 24h,** she is in renal failure. Put her on an accurate fluid balance. This is serious, but potentially curable. Early treatment will improve her prognosis, so watch for it. Try furosemide 40-320mg IV. If this fails, try dopamine if obtainable. Start with 2-5µg/kg/min. Increase in steps till an effect has been attained; this is usually at <20µg/kg/min.

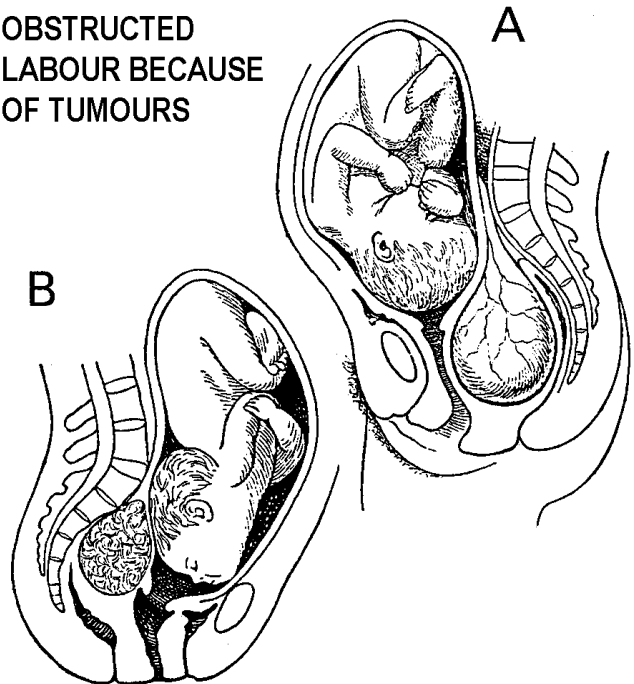
**If labour was obstructed with cephalic presentation for a long time** (active labour for ≥6h), insert a catheter for 14 days: it might just prevent a fistula. If one does develop, keep the catheter *in situ* for at least 6wks.

**N.B. The neonate has a greater chance of brain damage in a difficult delivery.** This may be caused by:

- (1) Direct trauma from the procedure itself.
- (2) Lack of oxygen.
- (3) Poor foetal blood flow.

Watch carefully for signs of twitching, irritability, or fever.

## OBSTRUCTED LABOUR BECAUSE OF TUMOURS



**Fig. 21-6 TWO TUMOURS OBSTRUCTING LABOUR.**

**A, an ovarian cyst. B, a cervical fibroid.** If a patient has an ovarian cyst or tumour, you can remove it at Caesarean section. If she has a fibroid, leave it unless it has a thin pedicle and remove it later if necessary.

After Young J. *A Textbook of Gynaecology A&C Black 5<sup>th</sup> ed 1939 Figs 125,168.*

**(r) Oxytocin**

Oxytocin is an invaluable drug for making the uterus contract:

- (1) To induce labour.
- (2) To accelerate labour.
- (3) To stop bleeding after abortion or delivery.

*Always have a secret cache of this drug so that you never run out.*

The main dangers are that:

- (1) *The uterus may rupture if you administer too much too fast to a multipara late in labour.* The sensitivity of the uterus to oxytocin varies greatly. Early in pregnancy it is comparatively insensitive; it becomes much more sensitive later, especially in a multipara. So in a pregnant patient always use an IV infusion, starting with a small dose. If you don't get the effect you want, use more in incremental doses. After delivery, or during an abortion, this rule does not apply, and you can safely use a bolus injection IV or IM.

- (2) *The supply of oxygen and nutrients to the foetus via the placenta will be inadequate if uterine contractions take too long or are too frequent.* The foetus might not cope, even if there is a normal placenta. If, however, there is already marginal placental function, e.g. in the presence of high blood pressure and/or growth retardation, the effect on the foetus may be catastrophic.

Remember: *oxytocin might kill a foetus if you don't monitor its use properly. Even normal contractions may be too much for the foetus if placental function is very poor!*

(3) *You can add too much fluid* at the same time when infusing oxytocin IV, especially when you use oxytocin to induce labour early in pregnancy, when you may need high doses. So, when you use escalating doses, avoid the danger of water intoxication by using 0.9% saline or Ringer's lactate, *not 5% dextrose*.

The primigravid uterus is sufficiently insensitive for oxytocin to be safe enough for midwives to give routinely to accelerate labour. *But, using oxytocin to accelerate labour in multipara can be dangerous*, so only use it if you are experienced, and *don't let your midwifery team use it unsupervised*.

*In Africa, the head is often high through much of the 1<sup>st</sup> stage*. Speeding its descent with oxytocin is dangerous for the inexperienced. If labour in a multipara is slow, and her previous deliveries were normal, she will probably deliver the present foetus eventually, provided he has a cephalic presentation. So it is likely to be safer to leave her, after examining carefully to exclude a brow presentation, than risk rupturing the uterus by using oxytocin unnecessarily.

Oxytocin is used otherwise in many situations: evacuation of incomplete or delayed miscarriage (20.2), and retained miscarriage (20.4), inducing labour (22.2), breech presentation (22.7), multiple pregnancy (22.10), and post-partum haemorrhage (22.11).

*Always use the 'protocol on the wall'*

#### AVOID OXYTOCIN IN A MULTIPARA

### 21.6 Vacuum extraction (Ventouse) (GRADE 1.3)

*You will find a vacuum extractor invaluable, so if you are not already using one, you must!* A properly functioning one will save many mothers and babies. It has many advantages in the confined space of the commonly small pelvis of many women seen in many low-income communities.

Unlike forceps, the vacuum cup takes up no extra space beside the head in the birth canal, and it is difficult to injure the mother seriously. The foetal head can rotate spontaneously at the optimum level, and if it is not flexed enough, vacuum extraction will often flex it. *Most importantly, a vacuum extractor is less likely to damage the foetal brain than forceps*. The indications for its use in a hospital are somewhat broader than those in a health centre.

*N.B.* Make it a habit to clean and grease your (manual) vacuum apparatus weekly. Machines which don't function at the critical moment might kill babies and even mothers.

If somebody offers donations to your hospital, ask for extra cups (preferably the model Bird type, including one posterior cup) and tubing so that you have a few autoclaved packs ready, particularly over a long weekend. Invest in the best quality: *there are very poor-quality sets on the market*. Before you start applying the cup to the head, try it on your gloved hand first to see if there are any leaks.

#### INDICATIONS

- (1) Delay in the 2<sup>nd</sup> stage of >1h in a primigravida, and 30mins in a multigravida, especially delay caused by malrotation of the occiput.
- (2) To reduce maternal effort if a woman has cardiac failure, gestational hypertension, or exhaustion.
- (3) To minimize the strain on a scarred uterus.

(4) Relative CPD due to deflexion and malrotation of the head.

*N.B.* *If there is absolute CPD, don't use a vacuum extractor*; it will be ineffective and potentially dangerous unless you combine it with a symphysiotomy (21.7).

(5) A need for haste because of foetal distress without or with only mild CPD.

(6) In an unconscious patient, *e.g.* with eclampsia, with near (8cm) or full cervical dilation and a moderate-sized foetus.

(7) Failure to progress, or exhaustion in a 2<sup>nd</sup> twin with a cephalic presentation, when the cervix is closing down even if the membranes have been ruptured and an oxytocin infusion is in progress. The height of the head does not matter in this situation, provided you can get the cup on the occiput. (*This is not easy because the head is often high and the flabby cervix and the cord of the 1<sup>st</sup> foetus tend to find their way into the cup.*)

(8) Prolapse of the cord in a multipara.

(9) In combination with a symphysiotomy in order to control the delivery better and keep the head away from the temporarily poorly supported urethra.

#### CONTRAINDICATIONS

(1) Prematurity <36wks, because of the risk of intracerebral haemorrhage.

(2) A brow or face presentation.

(3) CPD, unless you combine vacuum extraction with symphysiotomy (21.7).

(4) Foetal death.

*CAUTION! Don't apply a vacuum extractor before full or nearly full (8cm) cervical dilation* because it is usually dangerous: the only exceptions are (5), (6) and (7) above. *Don't use it for delay late in the 1<sup>st</sup> stage* (21.3). (If this does not respond to oxytocin, it is likely to be due to CPD.)

**If (a) it has taken >3h to dilate from 7-10cm on the partograph,**

**or (b) the fundal height is >40cm** (suggesting a large baby), expect difficulty. Perform the vacuum extraction in theatre, and prepare for Caesarean section.

#### REQUIREMENTS

(1) A cephalic presentation.

(2) The foetal head must be  $\leq 1/5$  above the pelvic brim.

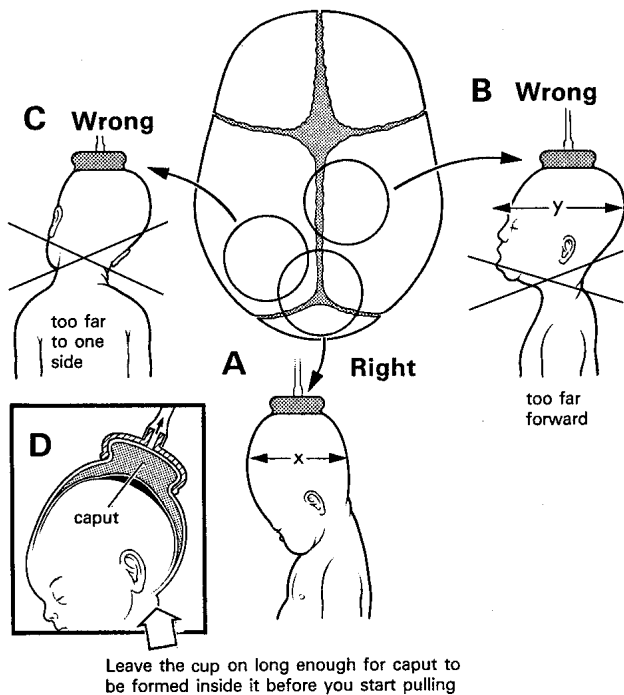
*N.B.* Always determine the position of the head in relation to the pelvic brim, and *not to the ischial spines*; if the pelvis is shallow and there is much caput, you may be able to feel it below the spines before it is engaged.

(3) The head must descend, or at least move somewhat, with contractions and bearing-down efforts.

(4) You should preferably know where the occiput is, because traction will be more effective if you can put the cup there. This is often not that easy and sometimes you are forced to put the cup at the lowest point. An ultrasound might help, if you are not sure, to locate the back of the occiput (21-7).

**If a bimanual examination indicates that the head is wedged solidly in the pelvis, and you are unable to rock it up and down at all**, then a vacuum alone is unlikely to be successful. If there is severe moulding >4, you will need to add a symphysiotomy at least. However, seeing the foetal head in the *introitus* especially between contractions is a good reason for optimism.

## WHERE TO PUT THE CUP



**Fig. 21-7 WHERE TO PUT THE VACUUM EXTRACTOR CUP.** You will find a vacuum extractor invaluable. Attach the cup as nearly as you can over the posterior fontanelle or just a little in front of it.

### METHOD

Cooperation from a woman who is fully conscious is desirable, but not essential. Good uterine contractions, which mean 3-4 every 10mins lasting >40secs, are the norm, but not essential (as in the case of an unconscious patient). With an uncooperative patient, use ketamine.

*N.B. An oxytocin infusion in the absence of good contractions may cause foetal distress.*

Use 3 pulls, the first to dislodge the foetal head from its arrested position, the second to bring the head to the pelvic floor, and the third to deliver the foetus, or at least make the vertex visible at the *introitus*. Pull during contractions combined with maximum straining and keep traction maintained in between to prevent the head from retreating between contractions/pushing efforts.

*N.B. There are situations where you use vacuum extraction to prevent strenuous pushing, e.g. when there is a scar on the uterus, maternal cardiac abnormality, hypertension or fear of maternal cerebral haemorrhage.*

Sometimes you know that pulling a little harder could deliver the baby, but you also know that the cup will then come off. If you think that is the case, it is quite legitimate to get an assistant to push on the fundus. Contraindications for this fundal pressure are a scar in the uterus and perhaps an extremely enlarged spleen.

It might be advisable to insert the local anaesthetic for a symphysiotomy (21.7) before the vacuum extraction, in case it fails.

## 21.7 Symphysiotomy (Pelvic release)

Cutting the symphysis allows the two halves of the pelvis to separate 2-3cm. This increases its diameter by 0.6-0.8cm, which is enough to overcome mild or moderate CPD, and so avoid Caesarean section. After delivery, its circumference remains wider by about 1.5cm, and its diameter by about 0.5cm, so that the next deliveries may well be normal. Symphysiotomy is thus particularly valuable if the mother expects a large family. Moreover, having a scar on the uterus is hazardous if the next delivery is not guaranteed to happen in a well-equipped and -staffed hospital.

*This is an invaluable operation which needs to be reinstated and given its proper place in obstetric practice in poorly resourced centres. The reasons are clear:*

- (1) Unlike Caesarean section, especially with unskilled anaesthesia, it is never fatal, and seldom produces complications, particularly serious ones.
- (2) It does not leave a woman with a scar in the uterus which may rupture if she does not deliver in hospital when she is pregnant the next time.
- (3) It may save her life if she delivers in a health centre and cannot be speedily referred.
- (4) Retrospective studies show quite clearly that symphysiotomies are less dangerous for the women involved and very probably the baby also.

We encourage you to investigate this, since, like the destructive operations, it is one of the few practical procedures which might really alleviate maternal mortality from obstructed labour.

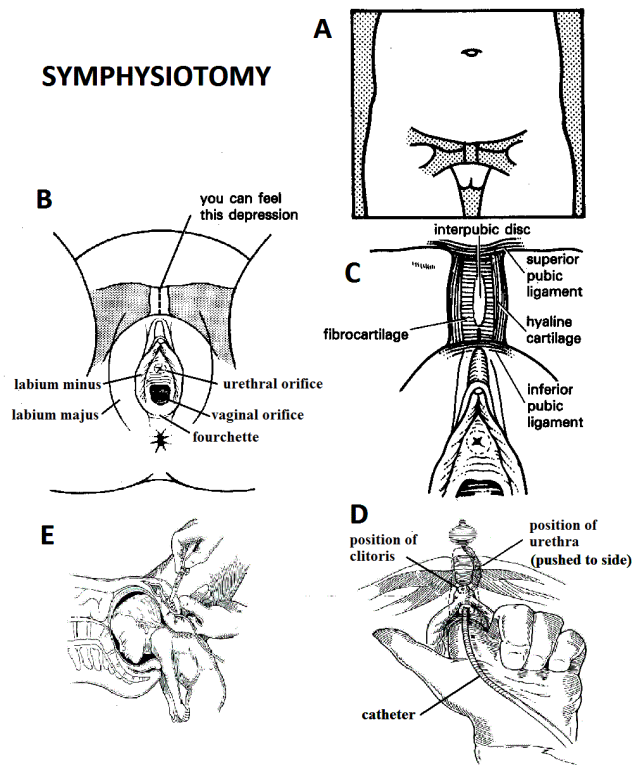
Symphysiotomy has fallen into disrepute in rich countries of the world, where CPD is uncommon, where trends are set and where most textbooks are written, because gynaecologists stopped performing the operation. There it is rarely used and then mainly for shoulder dystocia. But, in countries where CPD is common, symphysiotomy is excellent when used properly (as is the case for any procedure) for obstructed labour.

There is no doubt that, if CPD is marked, a woman needs a Caesarean section. The skill you need is to recognize when this is mandatory. You will not need to make a symphysiotomy very often, but there are hospitals in Nigeria where it is performed more often than a Caesarean section and the patients prefer a symphysiotomy if given a choice. You will find that deciding when to perform one needs more judgement than deciding when to perform a Caesarean section. If a symphysiotomy fails, you can still perform a Caesarean section: but you should look upon this as an error of judgement, and try to do better next time.

In many countries there is resistance from the medical/gynaecological/midwifery/political establishment to symphysiotomies. If you have to prove your point, it is therefore better to start with a very solid indication, *viz.* a woman who is feverish, has been in obstructed labour for hours, and has a live foetus whose head is low. In these circumstances, a Caesarean section is very dangerous and might be impossible to organize within the 30mins before the foetus dies.

On the other hand, with the stuck aftercoming head in a breech presentation, a shoulder dystocia or a failed vacuum extraction, it will take only 15mins to execute your first symphysiotomy slowly and methodically. If all goes well, that might be a watershed for introducing the value of this procedure.

If you have sufficient helpers, ask your staff to prepare for a Caesarean section, but get on with the symphysiotomy in the meantime!



**Fig. 21-8 SYMPHYSIOTOMY.** A, position of the symphysis on the anterior abdominal wall. B, position of the symphysis in relation to the clitoris. C, structures to cut. D, incision in relation to the urethra pushed laterally, and the bladder. E, situation in shoulder dystocia.

After Pust RE, Hirschler RA, Lennox CE. *Emergency Symphysiotomy for trapped head*, *Tropical Doctor* 1992;22(2):71-75.

## SYMPHYSIOTOMY (GRADE 2.1)

### INDICATIONS

Mild or moderate CPD associated with any of these problems, most of which are interrelated:

(1) A failed trial of vacuum extraction even after applying fundal pressure. This is the most common indication. It is difficult to be sure that vacuum extraction won't work without having a try! A difficult vacuum extraction may succeed, but only after prolonged traction and the risk of damaging the baby. Symphysiotomy will make delivery easier and safer. At the strategic moment, preferably before there are any signs of foetal distress, it is ideal. If the indications are right, it is better than Caesarean section, and it avoids a difficult vaginal delivery.

(2) Neglected obstructed labour with a live foetus. If the foetal head is deeply jammed into the pelvis, perhaps with caput visible at the vulva, symphysiotomy will be safer. If you try to perform a Caesarean section, the foetal head will be difficult to deliver, and cause a laceration of the lower segment into the large vessels or deep in the cervix or even into the bladder.

Moreover, there will often be an infection at this stage and by opening the uterus, infected material can contaminate the operative field including the peritoneal cavity. The wound in the uterus and the abdominal wall is likely to become infected. An infected uterine incision is likely to result in a weak scar.

(3) A woman living in an isolated location, who comes late to hospital, and who is likely again to present late with the next delivery, and especially whose foetal outcome is likely to be poor. She may subsequently be tempted to deliver at home with fatal consequences, about which you will hear nothing. If she has a symphysiotomy, her pelvis will be somewhat larger and there will be no uterine scar.

(4) Mild or moderate CPD with a live foetus, particularly in a primigravida, when the foetal head is  $1/5$  or  $2/5$  above the brim, and is too tightly held for vacuum or low forceps alone.

(5) To deliver the arrested aftercoming head of a breech presentation (if you are quick!) or a shoulder dystocia.

*N.B. Never do this as your 1<sup>st</sup> ever symphysiotomy.*

(6) Extreme anaemia when there is no blood available or the patient is a Jehovah's Witness who refuses transfusion.

(7) When there is a long lag time between taking the decision to perform a Caesarean section and actually doing it, especially if this delay might kill mother and/or child. Moreover, the longer the waiting list is for Caesarean sections, the more likely it is that somebody else will die who is even later in the queue.

(8) In a health centre, where a symphysiotomy is an emergency delivery method, thus securing a live baby, when referral is impossible.

### CONTRAINDICATIONS

(1) Severe CPD.

(2) Malpresentations, with the exception of the aftercoming head of a breech (22.7).

(3) Foetal death; if there is minor CPD and a symphysiotomy would be feasible, a craniotomy will likewise be possible; if there is no CPD, a symphysiotomy is unnecessary. Only in very exceptional circumstances would a symphysiotomy be an option with CPD and foetal death: when a woman is highly likely to have CPD in the next pregnancy and she is very unlikely then to deliver in hospital next time. A larger pelvis after the symphysiotomy for a dead baby could help with the next delivery.

(4) A complete family when the patient would like a sterilization. The chances are that there will be fewer combined obstetrical problems now and in the future if a tubal ligation is performed together with a Caesarean section.

(5) Abnormalities of the maternal pelvis or legs.

(6) A large foetus >4kg as estimated by the fundal height being >40cm (who is too big to deliver by symphysiotomy), or <2.5kg (who does not need one).

(7) A foetal head which remains  $>3/5$  above the pelvic brim after rupture of the membranes, e.g. in hydrocephalus (22.6).

*Relative contraindications are:*

(8) Severe obesity,

(9) Previous symphysiotomy, or

(10) Previous VVF repair.

If you have the opportunity, see what happens to a cohort of women who delivered by Caesarean section and who could have had a symphysiotomy instead. Record the complications, not only those around the index delivery

but also from subsequent deliveries, say over the next 10yrs. Such a study in your region will probably show that many women who had a Caesarean section, but could have had a symphysiotomy for failed vacuum extraction, or for failure to progress or foetal distress in the 2<sup>nd</sup> stage, die of complications of a subsequent delivery or become infertile because of post-operative peritonitis. There will then be evidence to challenge inappropriate use of Caesarean section in your region.

#### METHOD

Check the cervical dilation, the descent and position of the foetal head. At this point, decide if symphysiotomy is indicated or not. (Symphysiotomy is normally done at full dilation, but you can do it when there is still a 1 or 2cm ring of cervix.)

**If the foetal head is  $\frac{1}{5}$  above the pelvic brim,** a symphysiotomy is unnecessary, unless combined with a failed vacuum extraction.

**If the foetal head is  $\geq\frac{2}{5}$  above the pelvic brim,** symphysiotomy may be indicated.

**If the foetal head is  $\geq\frac{3}{5}$  above the pelvic brim,** try to insert a finger vaginally between the foetal head and the pelvis. *If your finger passes too easily, symphysiotomy is unnecessary.* If it passes with difficulty, symphysiotomy is indicated. If it does not pass at all, CPD is too great, so proceed to Caesarean section.

Listen to the foetal heart to make sure that the foetus is alive. Place the patient in the lithotomy position.

**CAUTION!** Find 2 assistants and ask them to support each of the legs, so that the abduction angle between the two upper legs is at maximum 90° (each upper leg 45° angle with the horizontal). This must be their only job; they must do nothing else. If they allow the legs to flop apart, the fibres of the sacroiliac joint may rupture, and the patient will have much post-operative pain, and maybe pelvic instability. You will value these assistants anyway, even if you have reliable lithotomy poles, to prevent too much abduction.

Palpate the bony margins of the symphysis pubis. Infiltrate the skin and subcutaneous tissue over the symphysis and the 'joint' between the pubic bones with 12-15ml of 1% lignocaine with adrenaline. Infiltrate also the area for an episiotomy with the remaining LA in your syringe. Although normally a vacuum extraction does not automatically mean an episiotomy, it does with a symphysiotomy. By controlling the descent of the head and keeping it away from the urethra, you will prevent a tear.

Clean the skin and vulva well with betadine or chlorhexidine. Insert a stiff urinary catheter. You may need to push the foetal head a little to pass the catheter. Apply the vacuum extractor. Place the index finger (*don't use two fingers, because the urethra tends to slip between them*) of your non-dominant hand in the vagina, to displace the catheter in the urethra away from the midline, and place behind the cartilaginous groove between the pelvic bones, *so you can feel the scalpel move!*

**CAUTION!** You *must* displace the urethra, or you may cut it. This could be a major disaster!

Use a large blade, preferably a solid knife, so that the blade does not come off or break. Make a 2-3cm incision in the skin and subcutaneous tissue 1cm below the upper edge of the symphysis pubis exactly in the midline. Then hold the knife vertical, and find the exact position of the 'joint'. (This you should have located when you injected LA.)

Push the point of the still vertically held blade about 1cm deep in the space between the pubic bones (in the mid-point

between the superior and inferior margins) with the cutting edge of the knife facing downwards. In order to avoid damaging the vagina or urethra (which you are pushing to the side with the index finger of your non-dominant hand), stop cutting downwards, but swing the blade towards you, so that you are now cutting upwards (away from the vagina). The fibres of the upper part of the 'joint' will then act as a fulcrum for the blunt part of the end of the blade. The sharp part of the blade will cut the fibres of the lower part of the 'joint'; you will feel them giving way as they part under tension.

*N.B. If you feel the scalpel against bone, re-position it!*

The skin is usually so flexible in this area that the skin incision will only be enlarged a little because of this manoeuvre. Once you have cut the fibres of the lower part of the 'joint', *taking care never to go beyond the arcuate ligament* (which arches across the inferior aspect of the symphysis), withdraw the knife, hold it again vertical and rotate it in such a way that the belly of the blade is now facing upwards. Re-insert the knife through the stab wound and now swing the blade away from you, thereby cutting the fibres near the superior margin of the 'joint'. When the 'joint' is almost divided, it will begin to open, sometimes audibly: 2cm is ideal, it should never open >4cm. Often, though, you will not have cut enough fibres and will have to divide some more. The best way to do this, keeping your non-dominant finger in the vagina pushing the urethra away from the midline, is to insert the blade again under the skin in the 'joint' but keeping it nearly horizontal, and push the belly of the blade (*not the point though*) against the tense fibres. *Don't make a sawing motion*, but you can move the handle up and down somewhat in a 20° rocking action against pressure of your finger in the vagina. Gentle pressure usually suffices.

If you cut 90% of the fibres, that is enough; *don't be persuaded to cut more in the superior part of the 'joint'* because it is more difficult to dislodge the proximal urethra and bladder base in this area. Alternatively, when nearly through the fibres, use the top of your thumb through the wound as a wedge to force open the 'joint' so that the knife stays far away from the vagina. (This works well, although your thumb will be somewhat tender for a few days!)

*N.B.* Sometimes the 'joint' is not completely vertical and you have to hold the blade aiming somewhat out of the midline (therefore not completely vertically down). *Be careful not to exert too much rotating force on the handle (clockwise or anticlockwise)* because you could wrench the blade out of the handle or break it. However, it is usually easy to retrieve a large blade.

*N.B.* Often the 'joint' opens suddenly and the head comes down very fast and it is a struggle to apply the vacuum and perform an episiotomy. *So it is better to apply the vacuum before the symphysiotomy. You may well need to perform an episiotomy as well.*

You will find anyway that most of your symphysiotomies will be done after a failed vacuum. It is very difficult to be sure, where there is an indication for symphysiotomy, that an extraction will fail. It is better to perform the episiotomy as late as possible because there might be significant loss of blood with greater chance of HIV exposure.

**CAUTION!**

- (1) *Always keep the urethra to one side with your non-dominant hand.*
- (2) *Don't cut above the symphysis pubis*, because the uterus or bladder may be protruding there.
- (3) *Don't cut below the symphysis pubis*, in case you damage the clitoris.
- (4) *Never perform a symphysiotomy without an episiotomy.*
- (5) *Make sure the legs of the patient are held firmly in position and strapped together before moving her from the delivery bed.*

If you have operated on the right indications, the mother will deliver easily, usually after bearing down with 1-2 contractions.

**CAUTION!** *Don't apply delivery forceps after symphysiotomy*; they may stretch the sacroiliac joint too much or damage the initially poorly supported urethra.

**If the incision continues to bleed**, suture the subcutaneous tissue and skin with 1-2 vertical mattress sutures. Lie the patient on her side, and press on the wound for 5mins.

Leave a self-retaining catheter in place for as long as the patient is immobile because lifting the buttocks on a bedpan will be painful. Normally after 2 days when she is able to sit on the side of the bed, remove the catheter, provided the urine is not blood-stained. The usual cause of this is obstructed labour or a balloon blown up still partly in the urethra because the foetal head prevented it being passed all the way in the bladder.

**If the indication was for prolonged obstructed labour (>6h)**, the patient is at risk of developing a fistula; so leave the catheter *in situ* for 10 days to try to prevent this from developing or to help a tiny fistula close completely.

Apply a stretch bandage around the knees for 2 days. Allow walking with the help of a chair, frame or trolley as soon as the legs can move independently without pain (usually 72h). Some patients can do this easily, others, especially the heavier ones, fail to walk until the 5<sup>th</sup>-7<sup>th</sup> day. Remove sutures on the 7<sup>th</sup> day. Most patients walk well, and are fit for discharge, on the 10<sup>th</sup> day. *There is no need to bind the pelvis*: the symphysis will heal leaving the pelvis larger than it was before.

**Difficulties with symphysiotomy**

**If spontaneous delivery does not occur**, pull with the vacuum extractor. Use oxytocin with the birth of the anterior shoulder or very soon after, because an infected, exhausted uterus tends to contract poorly, so there is then a risk of PPH.

**If the wound shows signs of local infection**, use ampicillin or chloramphenicol, which are not passed through breast milk as are tetracycline or sulphonamides.

**If there is post-operative fever**, suspect urinary or puerperal infection because of prolonged labour, or both.

**If urine does not pass** when the catheter is removed on the 3<sup>rd</sup> day, replace it and try again on the 5<sup>th</sup> day.

**If there is incontinence of urine**, it may be:

- (1) stress incontinence which happens often in the first weeks after operation but will usually recover spontaneously within 3 months, or
- (2) evidence of a fistula. In this case, keep the catheter *in situ*: it might close or at least the hole might become smaller. However, check that there is not in fact a large fistula kept open by the catheter balloon!

**If, later, the patient develops chronic pain and discharge**, she has chronic pubic osteitis. This is rare, and treatment is difficult; use NSAIDs, and rarely antibiotics. It probably only occurs when the incision involves bone, so keep strictly to the midline in the fibrocartilage of the joint.

**If the patient has difficulty walking with an uneven gait**, this may well be because her hips were not held firmly, and the sacral ligaments were stretched or disrupted. A corset is rarely required, but active physiotherapy is necessary.

**If you injure the urethra**, see 21.18.

**21.8 Destructive operations**

For an obstructed labour with a dead baby, a destructive operation is usually better than a Caesarean section. These operations are sometimes said to be old-fashioned, and to have no place in modern obstetrics. Old-fashioned and unpleasant perhaps, but they have some useful features:

- (1) They need few instruments and only simple anaesthesia, so that they can be done in a health centre where a woman is first seen. If she cannot be referred, they may save her life. If referral is difficult, they avoid the risks and delays of a long journey.
- (2) They leave the mother with an intact uterus, which will be less likely to rupture if she has a home delivery the next time.
- (3) If there is already infection present, they are less likely than Caesarean section to spread the infection into the peritoneum.
- (4) Hospital stay is shorter.

The case for destructive operations is strongest in communities where a woman is married very young. She may not be fully grown when she first becomes pregnant, so that the pelvis is small and the first labour obstructs. The pelvis will continue to enlarge until she is 19yrs, so, if she delivers vaginally with the first pregnancy, the later deliveries may be possible vaginally without the risks of scarring the uterus.

Besides their distasteful messiness, the main problems with these operations are:

- (1) overlooking uterine rupture
- (2) damage to the vagina from instruments or ragged foetal parts.

We insist that as long as there are fistulae resulting from neglected obstructed labour, symphysiotomy and destructive operations are *not* obsolete. If your maternity staff are not familiar with these procedures, explain their indication and benefit carefully.

There are several types of destructive procedures, each with its own indication:

- (1) Craniotomy,
- (2) Decapitation,
- (3) Cleidotomy (cutting the clavicles),
- (4) Thoraco-abdominal evisceration (or embryotomy).

A transverse lie requires decapitation, and often evisceration also, which is more difficult than craniotomy; but even so, it is often wiser than Caesarean section, which is particularly dangerous for an infected neglected transverse lie.

#### INTRA-UTERINE FOETAL CRANIOTOMY (GRADE 2.3)

##### INDICATIONS

(1) For a cephalic presentation, all the following conditions must hold:

- (a) Foetal death.
- (b)  $\leq \frac{2}{5}$  ( $\frac{3}{5}$  if you are experienced) of the foetal head must be above the pelvic brim. The foetal head must be impacted.
- (c)  $\geq 7$ cm cervical dilation, preferably full.
- (d) *No uterine rupture, present or imminent.*

*N.B.* If a multigravida has been in labour for a long time, the lower segment will be very thin, and if it is tender and distended, it is *extremely* thin. Any destructive operation, except pushing a needle into a hydrocephalic head, will rupture the uterus.

(2) For a breech presentation (22.7) when a normal or hydrocephalic aftercoming head has 'stuck'.

**PREPARATION.** Always perform a destructive operation in the theatre with a laparotomy set ready for immediate use. You need this, either immediately instead of a destructive operation if you find that the indications are unsuitable, or immediately afterwards if you discover that the uterus has ruptured.

Confirm foetal death. Set up an IV infusion, take blood for cross-matching, and administer pethidine 50mg and diazepam 10mg IV with chloramphenicol 1g, benzylpenicillin 5MU.

Use the lithotomy position, and clean and drape the vulva and perineum.

Infiltrate the perineum with 0.5% or 1% lignocaine.

Catheterize the bladder. Ask your assistant to hold 1 or 2 Sims' specula in the vagina so that you can see the foetal head well.

**CAUTION!** Ask another assistant, standing on a footstool if necessary, to steady the foetal head by fundal pressure so that the foetus is not pushed upwards when you operate on the head.

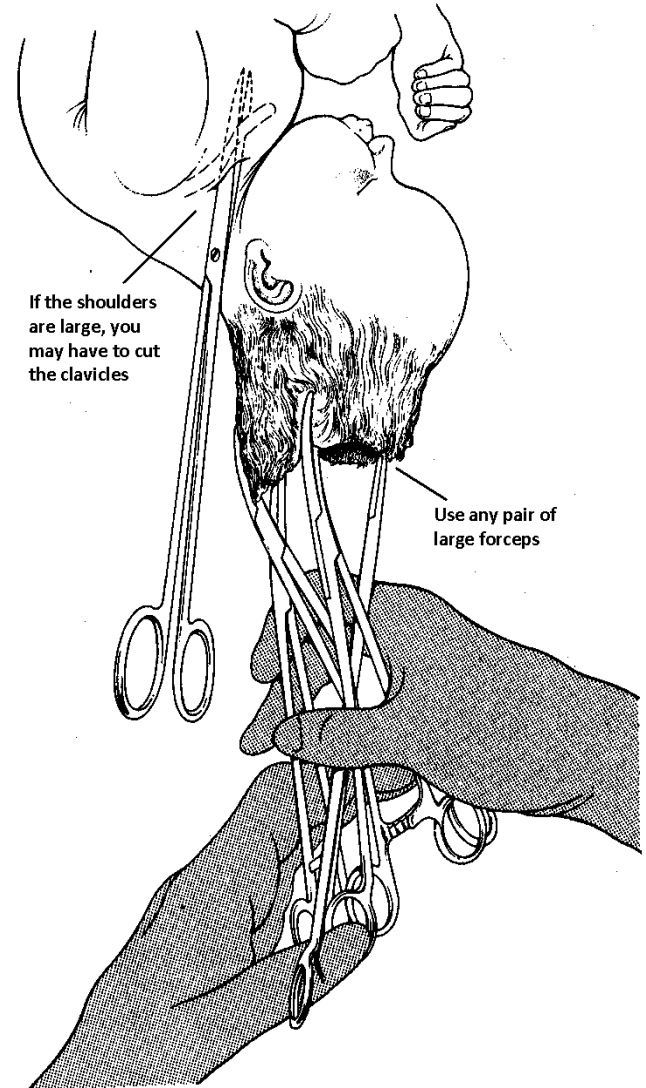
##### METHOD

*N.B.* For a hydrocephalic head, you only need a large bore cannula to drain off the fluid for the head to collapse. (You can do this through the mother's abdominal wall if guided by ultrasound, if the presentation is not cephalic.)

Put your fingers through the cervix to rest against the foetal skull. Check that the foetal head is wedged in the pelvis, or stabilized by your assistant.

Push a closed pair of strong pointed forceps (*e.g.* Kocher's) or, better, Simpson's perforator into the skull through the cranium.

## FETAL CRANIOTOMY



**Fig. 21-9 CRANIOTOMY AND CLEIDOTOMY.**

For an obstructed labour with a dead baby, a destructive operation is usually better than a Caesarean section or symphysiotomy.

*Kindly contributed by John Lawson.*

For a face presentation, perforate the foetal hard palate or the foetal orbit.

Ensure that the tip of the instrument is at the centre of the foetal skull. You may have to withdraw it a little to be sure of this.

*Stabilize the instrument well so that it does not slip off the skull and damage the mother.* When you are 5-10cm inside the skull, open the instrument and rotate it 360° to break down the septa.

Remove the instrument while still partly opened to enlarge the hole. Brain tissue will flow out from the perforation; the foetal skull will now collapse.

Remove any loose pieces of sharp bone. Attach 3 or 4 strong forceps to the foetal scalp and the remains of the foetal skull. Pull on them and try to bring the foetal posterior fontanelle under the symphysis. If sharp edges of bone stick out, protect the vagina with a Sims' speculum.

Wait until there is a contraction. Hold the 3 pairs of forceps together, and pull and twist. The collapsed foetal head should now deliver. Sometimes descent does not go very fast; instead of struggling impatiently and panicking, it is better to connect a strong traction rope to the handles of the instruments and connect that to a weight of 2-3kg over the foot end of the bed and observe for 20mins. The foetal body will follow. If a piece of the foetal skull pulls off, reattach the forceps taking a deeper bite of skull closer to its base. Make an episiotomy if indicated and deliver the remains of the foetal head.

**CAUTION!**

- (1) *Don't include folds of the vaginal wall or cervix.*
- (2) Use a good light and a large Sims' speculum, to make sure you grasp only the foetal skull.

**If delivering the foetal shoulders is difficult**, put a hand behind the foetus and try turning it through 90° or 180°. Then try delivering the foetal shoulders again.

**If you cannot bring down the foetal shoulders by turning**, bring down the foetal arms one by one. Put a hand behind the foetus in the vagina and feel for the foetal posterior arm. Gently pull it down. *Don't worry if the arm breaks, but don't damage the vagina.*

Then turn the foetus through 180° and deliver the other arm in the same way. Delivery should now be easy. Alternatively, cut the foetal clavicles (cleidotomy, 21-9).

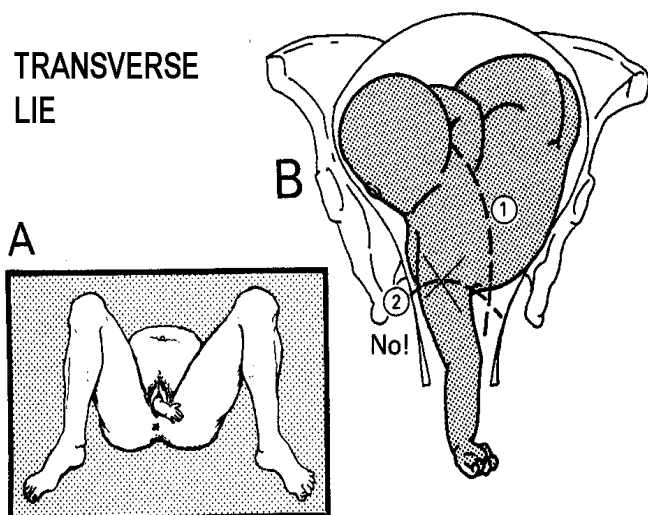


Fig. 21-10 A TRANSVERSE LIE.

A, if a community health worker meets this, advise her to refer the patient to you urgently! B, a shoulder presentation with a prolapsed arm. (1) The incision for decapitation, for a dead foetus, leaving the head attached to an arm. (2) *Don't try to remove an arm, leave it attached to the head or the body, to help you to bring these down.*

A, after Werner D. *Where there is no Doctor*. Hesperian Foundation 1978; B, after Howie B. *High Risk Obstetrics*, Macmillan, 1986 with kind permission.

## INTRA-UTERINE FOETAL DECAPITATION (GRADE 2.5)

### INDICATIONS

For a transverse lie, all the following conditions must hold:

- (1) Foetal death.
- (2) A transverse lie.
- (3) Cervical dilation  $\geq 8$ cm.
- (4) *No uterine rupture, present or imminent.*

PREPARATION. As for craniotomy above.

### METHOD

Put one hand into the vagina and support the fundus with the other. Measure the cervical dilation. Examine the condition of the lower segment; explore it as far as you can without using force. Assess the exact position of the foetus. Which of the foetal arms have prolapsed? Where exactly are the foetal head and neck, chest, abdomen, and back? Can you reach the foetal neck easily?

**CAUTION!**

- (1) *Don't try an internal version without doing an evisceration first: you will rupture the uterus.*
- (2) *Don't attempt decapitation, or evisceration, through the vagina if the foetus is still high in the birth canal; you will not be able to protect the vaginal wall and cervix adequately.*

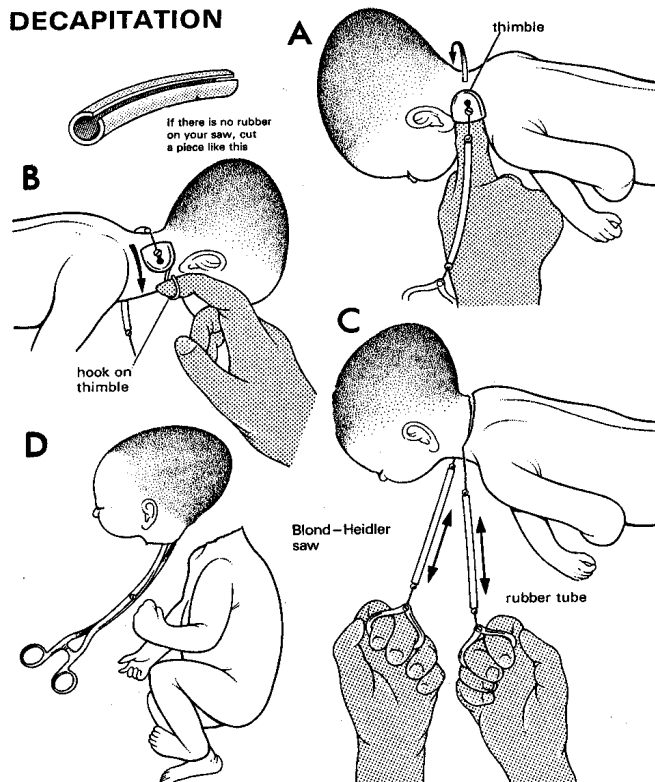
Bring a foetal arm down or pull on a prolapsed arm with one hand, and apply a weight connected to the arm; if you can bring the foetus down even a little, the operation will be much easier and if it is a premature foetus, this will often achieve spontaneous delivery! It also prevents the foetus being pushed upwards by your hand in the uterus, prevents the distended lower uterine segment being stretched, and brings the foetal neck lower, which you can now feel with your other hand. Feel how large it is, and how easy it is to put a finger around it. If the foetus is small and macerated, you can usually cut the foetal neck with strong scissors.

If it is larger, use the Blond-Heidler or Gigli saw (or equivalent, 21-11C). If you do have to use a saw, fix the thimble (21-11A) to it and put this on your right index finger (21-11A). Pass the thimble over the foetal neck, and down the other side (21-11B). If this is difficult, because there is little room between the foetal neck, head, and chest, try putting the saw over the foetal neck and under the arm. (21-10B: this has the advantage of making delivery of the head easier, simply by pulling on the arm.) Or improvise a smaller thimble by fixing something else, such as a piece of wire, to the end of the saw. Remove the thimble, and fix handles to each end of the saw, and cover the saw with rubber sleeves (21-11C). Keep the handles close together, so that the vagina is not injured. Protect it with the speculum. Cut the foetal neck with a few firm strokes (21-11D).

**CAUTION!** Hold the handles close together, otherwise you might lacerate the uterus or vagina.

**To deliver the foetal body**, pull on the foetal prolapsed arm, protecting the vagina from any jagged pieces of bone in the foetal neck.

## DECAPITATION



**Fig. 21-11 DECAPITATION FOR A DEAD FOETUS** will leave a woman with an intact uterus, which will be less likely to rupture if she delivers at home next time. Cut through the foetal neck with a Blond-Heidler saw. A, push the thimble round the foetal neck. B, pull the loop of the thimble down the other side of the foetal neck. C, saw through it. D, remove the foetal head with forceps. Pieces of rubber tube cover the outer  $\frac{1}{3}$  of each end of the saw.

*Kindly contributed by John Lawson.*

**To deliver the foetal head,** put a hand in the vagina, and turn the foetal head so that the neck points downwards. Grasp the stump of the foetal neck with large forceps, and put a finger in the foetal mouth. Then deliver the foetal head, as if it were the aftercoming head of a breech. This will prevent the stump from injuring the birth canal. If the foetal head is very large, you may need to perform a craniotomy. If you delivered the foetal head first, deliver the foetal body by pulling on the other arm. *Don't try version:* the cut foetal neck might lacerate the uterus.

**If you are using scissors,** hook one or two fingers round the foetal neck and pull it down. Ask an assistant to protect the vaginal wall with 2 specula. Gently pull the foetal arm. When you do this, you will feel the foetal neck. Try to see what you are cutting with each cut, because you could otherwise easily cut the uterus or bladder. Cut the foetal neck a little at a time, then deliver the foetus as before.

**CAUTION!** *Don't cut if you cannot see the foetal neck.* After each cut, pull on it. It will come a little further down with each cut until you have cut right through.

## INTRA-UTERINE FOETAL EVISCERATION (GRADE 2.5)

### INDICATIONS

For a transverse lie when the foetal neck is difficult to reach, but the foetal body is well down, or after decapitation if this fails to effect delivery.

**PREPARATION.** As for craniotomy above.

### METHOD

Ask your assistant to pull on the foetal prolapsed arm, and find the foetal axilla. Protect the vaginal wall with 2 specula. Grasp the foetal abdominal wall with strong long forceps, and with strong scissors make a large opening in the foetal abdomen. Put one or two fingers into the opening and remove all the internal organs. Make sure you remove the liver, heart, and lungs. If necessary, perforate the foetal diaphragm with the scissors. Now reassess the situation, and try whichever of these manoeuvres seems best:

- (1) Put two fingers behind the foetal pelvis and hook the foetal breech down.
  - (2) Inflate the balloon of a Foley catheter placed in the foetal pelvis with 50-60ml and apply traction (as in a breech presentation, 22.7).
  - (3) Grasp a leg or foot and bring that down.
  - (4) Try to bring the foetal neck down for decapitation by pulling on the foetal arm.
  - (5) Divide both clavicles (cleidotomy) to reduce the width of the shoulders of a large dead baby. Use long scissors to make a small cut in the skin of the foetal neck. Through this, guided by the fingers of your other hand, feel inside the foetal skin, until you can divide a clavicle between the tips of the opened blades of the scissors. The ends of the foetal clavicle will then overlap and narrow the foetal shoulders. *Be sure it is the foetal clavicle and not the spine of the foetal scapula that you are cutting.*
- Or, finally,
- (6) Separate the foetal prolapsed arm at the shoulder. Push the embryotomy scissors (19.2) through the foetal axilla and divide the internal structures from inside the foetal skin, while keeping your other hand between the foetal body and the uterus, as a constant guide. Finally, divide the foetal skin and superficial tissues under direct vision, and deliver the foetus in 2 halves.

### DIFFICULTY WITH DESTRUCTIVE OPERATIONS

**If you have difficulty delivering the foetus,** try to visualize carefully the foetal lie and identify its anatomy. Ultrasound may help. Remember, there is usually no rush to perform this procedure.

### POST-OPERATIVELY AFTER A DESTRUCTIVE OPERATION

Remove the placenta manually, and immediately feel for tears of the uterus and lower segment. Administer oxytocin IV as the foetus is delivered. Check the uterus by feeling inside it to make sure it has not ruptured. If it has, perform a laparotomy and repair it (21.17). Check the cervix, vagina, and vulva for tears, and repair them (21.15).

**If the uterus is not well contracted**, set up an IV oxytocin infusion with 5-20U in 500ml. Continue the saline infusion for 24h as well as perioperative antibiotics.

Monitor for:

- (1) Postpartum haemorrhage in the first 24h.
- (2) Acute urinary retention in the first 24h.
- (3) Infection of the genital tract after 24h.
- (4) Infection of the urinary tract at 7-10 days.
- (5) A fistula (21.18).

**If the foetal head has been impacted in the pelvis for many days**, leave a urinary catheter *in situ* for 14 days. This will help to prevent a fistula. However, obstructed labour with a transverse lie does *not* cause pressure necrosis of the vagina.

*CAUTION!* After any destructive operation, be sure your assistant wraps up the foetus immediately on delivery. Try wrapping it in such a way that the mother can still see the face if she wishes, without exposing the debris of the operation. This will help her in the grieving process more than simply disposing of the dead foetus. In some cultures, the family may wish to bury the foetus with all due ceremony. *Be careful that you respect such traditions.*

#### **AVOID CAESAREAN SECTION WHEN THE FOETUS HAS DIED**

### **21.9 Which kind of Caesarean section?**

Caesarean section is the commonest emergency procedure after episiotomy and evacuation of retained products of conception carried out in a district hospital. If you are inexperienced, it will also be the one which you will be most frightened of doing. In unskilled hands, it is often fatal, as a result of:

- (1) anaesthetic-related problems such as obstruction of the upper airways and the inhalation of gastric contents, spinal shock or ventilatory paralysis and overdose,
- (2) haemorrhage, often related to inexperience or technical problems after earlier operations,
- (3) sepsis.

There are several methods of uterotomy (opening the uterus):

**(a) Lower segment**, through a transverse incision (21.10). This has long been the standard operation because:

- (1) a scar here ruptures 10 times less often than the scar from a classical incision,
- (2) when it does rupture, it does so less dangerously,
- (3) the incision in the uterus heals better,
- (4) the danger of spreading infection is reduced,
- (5) the placenta is less often directly underneath the uterine incision,
- (6) the bowel is less likely to stick to the scar in the uterus,
- (7) there are fewer post-operative complications.

There are still some problems, though:

- (1) A lower segment operation needs more skill.
- (2) It is still dangerous if there is intra-uterine infection, although less so than the classical incision.
- (3) You may injure the bladder.

(4) Bleeding from the ends of the incision is more difficult to control, especially if there are lateral extension tears, as may happen if the lower segment is thin and distended, or the foetus is in an awkward position, as in a transverse lie. These tears may bleed severely, and in trying to control bleeding you may tie or cut the ureters.

(5) You may find it difficult to extract a distorted presenting part through a lower segment incision, and tear the uterus as you do. This tear will be dangerous, and the only way to avoid such, is to extend it. If you can do this curving the incision upwards at the edges, well and good; otherwise you may have to resort to a T incision, which does not heal well, and is a very bad incision to have to make. So only make the standard transverse incision if it is safe.

(6) The risk of spontaneous rupture is low, but not insignificant, at 1%.

Because of these dangers, we describe 5 other methods:

**(b) Transverse classical**, through a transverse incision low in the upper segment. This is occasionally needed if there is:

- (1) a transverse lie,
- (2) a contraction (Bandl's) ring,
- (3) a very vascular lower segment, with many thick veins,
- (4) a placenta praevia (20.11),
- (5) a poorly developed lower segment especially if it is a premature delivery, or
- (6) a uterus which is a mass of fibroids in its lower part.

**(c) Midline classical**, through a vertical incision in the upper segment (21.12). This is really only rarely indicated if:

- (1) the lower ½ of the upper segment is very vascular, or inaccessible as a result of adhesions from previous surgery,
- (2) a previous classical incision has healed poorly,
- (3) you will proceed to hysterectomy anyway,
- (4) in the rare case of postmortem delivery.

*N.B. You should combine a classical incision with a tubal ligation unless there is a very good reason not to, because uterine rupture may occur spontaneously in pregnancy and occurs in up to 10% of all cases.*

**(d) De Lee (Kronig or Cornell)**, through a vertical incision, ⅔ in the lower segment, and ⅓ in the upper. Use this if:

- (1) a lateral tear is likely, as can happen if the lower segment is very thin,
- (2) the foetus is in an abnormal position, *e.g.* transverse lie, especially if the foetal back is presenting.

*N.B. It is often difficult to know where the lower segment ends and the upper segment starts, so a de Lee may actually become a midline classical incision. Risk of spontaneous rupture is up to 5%.*

**(e) With hysterectomy**. Indicated occasionally for:

- (1) rupture of the uterus (21.17),
- (2) severe bruising of the lower segment,
- (3) laceration of the uterine artery,
- (4) established uterine infection,
- (5) severe placenta accreta after previous Caesarean sections,
- (6) early *proven* cervical carcinoma

*(N.B. You can easily confuse this macroscopically with cervical schistosomiasis or TB.)*

**(f) Extraperitoneal**, by excluding the peritoneal cavity from passage of the foetus. This greatly reduces the impact of infection as septic fluids are prevented from entering the peritoneal cavity.

## 21.10 Lower segment Caesarean section

A quick, effective, and anatomically correct approach is the Joel-Cohen abdominal wall incision (11.2) for a Caesarean section. This is especially justified if it is combined with a tubal ligation. Adhesions behind a lower abdominal incision, likely especially after infection or keloid formation, may be very difficult. Occasionally, a lower midline incision is safer if future circumstances are uncertain, but the Joel-Cohen incision is still preferable in most instances, even if there has been a previous midline incision. It is easier to learn and perform, quicker, causes much less bleeding, heals stronger, risks less infection, and is more versatile.

### (a) Pre-operative counselling

Always think of discussing with the patient the advisability of performing a simultaneous tubal ligation. Indications are:

- (1) >1 previous Caesarean section.
- (2) Parity >2.
- (3) >30yrs of age.
- (4) Hypertension, diabetes, sickle cell disease, or heart disease.
- (5) Advanced or untreated HIV infection.
- (6) Previous classical incision.

It is always a good idea, especially in resource-poor countries, to discuss, preferably halfway during pregnancy, whether a parous pregnant woman would like a tubal ligation in case she needs a Caesarean section. She then has time to think about it and discuss it with the relevant persons, and is not rushed into making a decision in an emergency. *A pre-printed questionnaire on her antenatal record will help remind staff and also make it routine.* This is important as patients must not feel the question is specifically directed at them, but that it is the routine to ask.

**(b) Antibiotics** halve the incidence of wound infection after Caesarean section: use prophylactic pre-operative benzylpenicillin, chloramphenicol IV and metronidazole PR stat as soon as you make the decision to perform surgery.

If you wait till the cord is clamped, it is too late to help prevent foetal sepsis.

**If you have difficulty catheterizing the bladder before operating**, raise the foetal head with your hands. If you fail to pass a catheter on the first occasion, try again after the patient is anaesthetized, when pushing up the foetal head will be easier. If you have to operate with a full bladder, *be very careful as you open the peritoneum.* Open it as far cranially as you can, and empty the bladder with a long needle *via* the abdomen.

Clip the hair where you intend to make the incision. (*Avoid shaving, which increases the risk of infection.*) Prepare the skin of the lower abdomen (21-12B), drape the abdomen with 4 plain towels, and cover these with a towel with a slit (21-12C).

**EQUIPMENT.** Make sure you have, if possible, at least 2 Caesar laparotomy sets (4.12) ready on stand-by at all times. Have sutures and oxytocin ready also.

**(c) Anaesthesia.** You can use GA, spinal anaesthesia, ketamine or LA, or a combination. *Don't let the lack of an anaesthetist inhibit you in performing an emergency Caesarean section.*

### (d) Method (GRADE 3.1)

**POSITION.** Stand on the right side of the patient if you are right-handed (on the left if left-handed). Prevent the supine hypotensive syndrome (pressure on the vena cava) by tilting her about 5° to the left. Do this either by tilting the table, or by putting a pillow or sandbag under the right buttock. Find some way of preventing her slipping off the table. A moderate head-down (Trendelenburg) position, after the spinal anaesthetic is fixed at the correct level, will give you better access to the lower segment. It will make delivering the foetal head easier if there is a vertex presentation. It will also be an additional safeguard against vomiting.

### INCISION

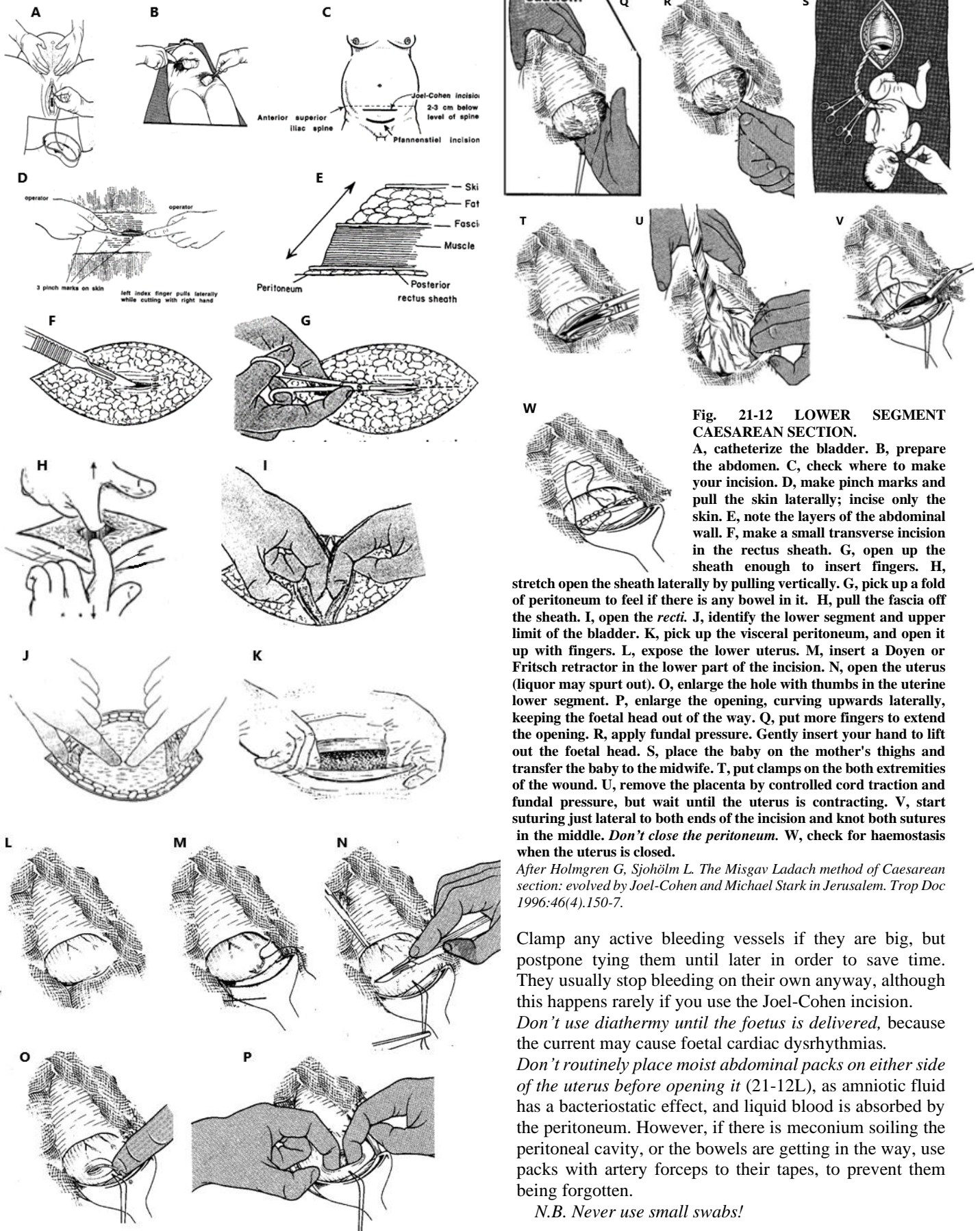
Pinch 3 marks in the skin crease c.3cm below the level of the anterior superior iliac spines, at both ends of your planned incision and in the midline (21-12D). Stretch the skin sideways to enable you to make a straight incision *through the superficial skin layer only (not the subcutaneous tissue).* At the centre of this incision, deepen a 2-3cm cut down to the rectus sheath (21-12F), because there are no large blood vessels here.

Now make a small transverse incision in the middle portion of the *rectus* sheath and gently separate the fascia from the sheath under it upwards and downwards (21-12H); this exposes the *rectus* muscle and makes an oval opening. Then hook 3 fingers of each hand through the midline that separates the *recti* muscles, so you get right beneath the muscle, and pull firmly laterally (21-12I). (You may even find yourself lifting a light patient slightly off the bed!) This will tuck any blood vessels in the fat out of the way.

At this point, the peritoneum is attached to the *transversalis fascia*. Stretch this layer laterally till you make a small hole in its middle, and then open it by stretching it vertically with both index fingers to just above the reflection of the bladder (21-12J). *Don't use a blade:* there is then less danger to bladder and bowel!

**CAUTION!** If the patient has had a previous operation, including a previous Caesarean section (21.14), omentum or bowel may be adherent to the abdominal wall and *can be easily damaged.* If you cut the bowel by mistake, clamp it and close it later (11-5). If there have been several previous Caesarean sections, the anatomy will be much distorted by adhesions.

## LOWER SEGMENT CAESAREAN SECTION



**Fig. 21-12 LOWER SEGMENT CAESAREAN SECTION.**

A, catheterize the bladder. B, prepare the abdomen. C, check where to make your incision. D, make pinch marks and pull the skin laterally; incise only the skin. E, note the layers of the abdominal wall. F, make a small transverse incision in the rectus sheath. G, open up the sheath enough to insert fingers. H,

stretch open the sheath laterally by pulling vertically. G, pick up a fold of peritoneum to feel if there is any bowel in it. H, pull the fascia off the sheath. I, open the *recti*. J, identify the lower segment and upper limit of the bladder. K, pick up the visceral peritoneum, and open it up with fingers. L, expose the lower uterus. M, insert a Doyen or Fritsch retractor in the lower part of the incision. N, open the uterus (liquor may spurt out). O, enlarge the hole with thumbs in the uterine lower segment. P, enlarge the opening, curving upwards laterally, keeping the foetal head out of the way. Q, put more fingers to extend the opening. R, apply fundal pressure. Gently insert your hand to lift out the foetal head. S, place the baby on the mother's thighs and transfer the baby to the midwife. T, put clamps on the both extremities of the wound. U, remove the placenta by controlled cord traction and fundal pressure, but wait until the uterus is contracting. V, start suturing just lateral to both ends of the incision and knot both sutures in the middle. *Don't close the peritoneum.* W, check for haemostasis when the uterus is closed.

*After Holmgren G, Sjöholm L. The Misgav Ladach method of Caesarean section: evolved by Joel-Cohen and Michael Stark in Jerusalem. Trop Doc 1996;46(4):150-7.*

Clamp any active bleeding vessels if they are big, but postpone tying them until later in order to save time. They usually stop bleeding on their own anyway, although this happens rarely if you use the Joel-Cohen incision.

*Don't use diathermy until the foetus is delivered,* because the current may cause foetal cardiac dysrhythmias.

*Don't routinely place moist abdominal packs on either side of the uterus before opening it (21-12L),* as amniotic fluid has a bacteriostatic effect, and liquid blood is absorbed by the peritoneum. However, if there is meconium soiling the peritoneal cavity, or the bowels are getting in the way, use packs with artery forceps to their tapes, to prevent them being forgotten.

*N.B. Never use small swabs!*

You may find it helpful to place a stay suture held with a haemostat, into the lower segment (21-12L), either in the middle or at the edges, *but don't do this if you are in a hurry!*

**If the foetal head is impacted in the pelvis** and needs to be disimpacted from below, ask yourself if a symphysiotomy (21.7) would not have been better, and remember this next time! Ask an assistant, with sterile gloves, to put his hand into the vagina, and to disimpact the foetal head. *He should do this before you incise the uterus.* If he waits until after you have incised it, the foetal shoulders may prolapse into the wound, and make delivery difficult. Unfortunately, it is difficult to predict that the head needs disimpaction, until after you have opened the uterus. If the disimpaction fails, perform a symphysiotomy (21.7) nonetheless.

Push the bladder downwards with your index finger or a swab. Pick up the loose peritoneum of the vesico-uterine pouch with dissecting forceps (21-12J). Make a 1cm transverse cut just below the point where the loose peritoneum becomes firmly attached to the anterior uterine wall. This is the abdominal marking of the lower segment. *Don't make this opening too low, or you may not give enough room to extract the foetal head.* Open this laterally with fingers, and push the visceral peritoneum down off the bladder. Feel and observe the uterus to find how it is rotated, and identify the presenting part. It is usually rotated to the right, so that the left round ligament is usually more anterior and closer to the midline than the right. If the uterus is markedly rotated, turn it towards the midline. *If you don't allow for rotation, you may cut the left uterine artery,* because your incision will be too far to the left.

Insert a Doyen or Fritsch retractor over the bladder, to protect it for the rest of the operation.

Cut a small opening in the lower uterine segment to introduce your index finger. The membranes may bulge out or break at this point. Stretch the uterine opening laterally (21-12I) with your thumbs usually slightly more to the right than the left (as the uterus is normally rotated a little to the right, as above). For a large head, curve the incision slightly upwards with scissors, keeping the foetal head away with your fingers. The not-so-neat edges of the arteries cut by fingers bleed less and the extent of the opening is easy to control.

*N.B. If you avoid using a knife, you cannot in this way cut into the foetus and transfer HIV, HBV, or HCV.*

As you reach the edges of the uterus, aim your fingers in a more cephalic direction, so that the 'smile' opening in the peritoneum is c.10cm long, curved (21-12J) with its ends curving gently upwards directed to the attachments of the round ligaments. This should be  $\leq 2$ cm below the peritoneal reflection, and at least  $\geq 2$ cm above the detached bladder.

*N.B. Don't make your transverse opening too low in the lower segment.* Place it where normally the empty bladder reflects (*not where a bladder pulled up by adhesions reflects*) or 1-2cm higher.

#### CAUTION!

(1) *Take great care to avoid injuring the bladder, especially if this is pulled up high and is oedematous.*

(2) *Don't denude the lower segment of peritoneum for  $>5$ cm: if the cervix is effaced and dilated, you may enter the vagina by mistake.*

**If the patient has had previous Caesarean sections, and the uterus is very fibrotic,** you may have to extend the incision with scissors, curving it upwards laterally.

#### CAUTION!

(1) The lower segment varies considerably in thickness. It is thick before labour and becomes thinner during labour, so *be careful not to cut the foetus!* This will not happen if you open the uterine wall with your fingers.

(2) *Don't make the opening too small,* or the uterus will tear as you remove the foetal head.

(3) If you decide to enlarge the opening, curve it upwards at its ends in a U-shape, so as to avoid the uterine vessels. Also, when you suture it, you will be less likely to suture the ureters.

**If there is a scar in the lower segment from a previous Caesarean section,** make a shallow cut along it, where you want to open the rest of the uterus.

**If you can feel the foetal vertex through the uterine wall,** the placenta is probably lying in the fundus or posteriorly, so you can expect a delivery without difficulty.

**If you tear the placenta as you open the uterus,** try to detach it, and deliver the foetus around it. *Only tear through the placenta if you have to.* There can be severe bleeding from a lacerated placenta, so clamp the umbilical cord quickly (21.11).

**If the ends of the opening in the lower segment bleed severely,** before the foetus has been delivered, quickly proceed with delivery, and then control bleeding as described below.

**If there are large veins over the lower segment,** place your uterine incision towards or in the upper segment, or place clamps across the veins and incise the uterus precisely and carefully between the clamps, and deliver the foetus rapidly. The veins will probably stop bleeding soon after. If necessary, ligate the veins.

#### DELIVERING THE BABY

Remove the retractor. Put 2 fingers (only) into the uterus under the baby's head to decompress a vacuum, and make it easier for the foetal head to rise in the incision. Get your assistant to push downwards on the fundus of the uterus. Then put your hand outside the lower flap of the incision, and lift the foetal head up (21-12Q).

**If the incision is not long enough to deliver the foetus without a lateral tear,** extend its ends upwards and laterally with your fingers, so as to make a U-shaped flap.

Now ask your assistant (or the anaesthetist by groping under the drapes) to press on the fundus to assist delivery. This may mean pressing firmly, but carefully and without hurrying.

It may be necessary also to pull up the upper margin of the uterine opening to make delivery of the baby easier.

**CAUTION!** *Don't try to aspirate the nose especially with a big Yankauer sucker:* it may push maternal blood into the nose and/or traumatize the nasal passages.

#### ERGOMETRINE OR OXYTOCIN

*If there is hypertension, or eclampsia, or you are operating under LA, avoid ergometrine, and administer 5U oxytocin IV or IM.* Ergometrine occasionally makes a conscious patient sick, and may raise the blood pressure. Because you are manipulating the uterus and can easily make sure it is empty (leaving placenta behind is embarrassing), the uterus is usually well contracted during closure. But after that, you will often not notice relaxation because bleeding will not be overt. An oxytocin infusion at the end of the operation and the first post-operative hours can save lives.

**If there is placenta praevia,** clamp the cord quickly, because blood loss from the injured sinuses of the placenta may be significant. Otherwise delayed cord clamping, placing the baby below table level and milking the cord all serve to increase the Hb level of a neonate, especially if pre-term.

#### CONTROLLING BLEEDING

Now deliver the uterus by lifting the fundus out of the abdomen; it is easier then to see what you are doing.

#### REMOVING THE PLACENTA

When the uterus is contracting firmly, remove the placenta by a combination of controlled cord traction and fundal pressure (21-12U). If necessary, help it to contract by massaging the fundus from inside the abdomen. Pull gently on the cord, and press the uterus back with your left hand. This should deliver the placenta easily.

**If there is a placenta praevia grown into a previous Caesarean section scar,** there is serious danger of serious blood loss at this stage.

If you cannot remove the placenta manually (the practical definition of placenta accreta), then you may be forced to proceed to hysterectomy. While deciding or organizing blood, apply a tourniquet round the cervix (22.11).

When the placenta is delivered:

(1) Inspect the uterine cavity to make sure it is empty. Remove pieces of membrane.

(2) Make sure that the placenta is complete.

**CAUTION!** *Don't probe the cervix to improve drainage: keep out of the contaminated vagina!*

#### CLOSING THE UTERUS

**If you are a quick operator,** apply one Green-Armytage clamp (or sponge-holding forceps) at one angle of the uterine opening (21-12V), and start suturing at the opposite end.

**If you are a slow operator,** apply several Green-Armytage clamps (or sponge-holders) all round the cut edges of the uterus, particularly at the angles. *Make sure they don't grasp the posterior wall of the empty uterus, as it lies on the promontory of the sacrum.* You can easily do this by mistake if bleeding has been brisk. The difficulty in applying many clamps is that they will get in your way.

*Don't pull on the clamps during suturing* as this will result in an asymmetric closure.

Close in one layer using #1 long-acting absorbable sutures on a large round-bodied Mayo's needle. *Don't use non-absorbable sutures, particularly not on the inner wall.* Ask your assistant to hold the lower edge of the uterus forwards, while you suture from the angles inwards (21-12T). Start the 1<sup>st</sup> sutures just beyond the lateral extremity of the wound. Knot with good tension and protect the point of your needle with the needle holder; then start with a different suture and needle holder just beyond the other lateral extremity, make a similar knot and work towards the first suture, and tie this 2<sup>nd</sup> suture to the 1<sup>st</sup> in the middle of the uterine opening (21-12U). In this way, you secure the angles first. You will, if you use 90cm sutures, have at least enough material left to tie the tubes (if desired), and close the rectus sheath.

*Unless the sutures are tight, they will not stop the bleeding.*

#### CAUTION!

(1) Start suturing just lateral to the wound extremity with an adequate bite through the whole uterine wall.

(2) *Don't suture the lower edge above the upper one,* because this may advance the bladder up the uterus.

(3) *Don't include the bladder in your sutures.* If you find, at the end of your closure, that you have included it, you will probably be wise to leave a catheter in for a few days, rather than removing the sutures and starting again, which can cause severe bleeding.

(4) *Don't suture too deeply with a large needle at the angles of incision;* you may obstruct the ureters.

(5) *Don't suture the front and back walls of the uterus together.* So, before the first layer of sutures is completed, put 2 fingers into the uterine cavity, to make sure that its walls are free. If necessary, release the sutures and start again.

(6) *Don't suture the bowel to the back of the broad ligament.* Suture only the uterus, and not too deeply downwards towards the vault of the vagina. If you are in any doubt, put your fingers down behind the uterus before you start to close the lateral extremities of the opening so that the peritoneum stays out of your suture.

When the uterus is no longer bleeding, close the peritoneum of the vesico-uterine pouch with continuous sutures of non-absorbable (21-12V). *Again, avoid including the bladder with the lower edge of the peritoneum.*

#### COMPLETING THE REPAIR

Look carefully at your completed repair. If there is still bleeding, put in some more 'figure of 8' sutures at the bleeding points. *Don't close the peritoneum until you have controlled all bleeding,* but minimal oozing is allowed.

**If you find an ovarian cyst >5cm diameter,** perforate it, unless it is very large (23.9).

**Now is the time to tie the tubes** (19.4). The Fallopian tubes in pregnancy are swollen; *don't use rings or Filshie clips on them:* they tend to slip off or break and are costly!

## CLOSING THE ABDOMEN

Clean all blood and debris from the peritoneal cavity, and especially from the paracolic gutters. They will be much cleaner if you have previously inserted abdominal packs beside the uterus (21-12K). Wash out the abdominal cavity with copious warm water if there was soiling present. Replace the uterus if you have exteriorized it. Place the greater omentum over the uterus: it will usually reach the bladder. *Don't close the peritoneum.* Close the anterior rectus sheath and bury the knots. *Don't put sutures in the fat layer.* *Don't insert a drain.* Leave the skin wound open if there is much sepsis.

### (e) Bonding

As soon as the mother has delivered, after any necessary resuscitation, give her the baby to hold. This close early contact is important in developing the bond between them. If she has had a GA, place the baby in a cot beside her, so she can see her child when she wakes up.

### (f) Post-operative care after Caesarean section

Estimate the blood loss: it will probably be more than you think, but if the membranes were intact, some of the liquid will be liquor. The average loss is 1L. Unless you have expert staff, check the vital signs yourself. Check and chart the pulse, temperature, and respiration  $\frac{1}{2}$ hrly, until she is awake, and then, when the condition is satisfactory, hourly for 12-24h. Continue an IV infusion for 24h; start oral fluids as soon as she is fully awake. *Don't forget analgesia.* It is wise to administer oxytocin 20U in 1L IV over 6h post-operatively to ensure good contraction of the uterus. It is worthwhile making a postpartum vaginal examination: you will instantly diagnose a urinary leak, if present.

**If bleeding was excessive**, make sure there are 2 cannulae *in situ* and IV saline or Ringer's lactate fluid replacement is flowing nicely. Review the patient yourself in 1h. You will be surprised how often a patient who left the theatre in reasonable condition is now collapsed.

**CAUTION!** Look for signs of infection:

- (1) Fever.
- (2) A large, soft, tender uterus.
- (3) Tender thickening in the lateral fornices.

**If the membranes were ruptured for >24h before the operation**, or there are other reasons for suspecting infection, continue antibiotics for 3 days.

*N.B. Don't use antibiotics routinely post-op.*

**If vomiting ensues with abdominal distension**, insert a nasogastric tube.

**CAUTION!** Before the patient goes home, make sure that she and her relatives know that future deliveries must occur in hospital: *this is ESSENTIAL!* When next pregnant, she must attend regularly for antenatal care. Give her a card which explains why Caesarean section was done, or add these details to the baby's birth card.

**If there was obstructed labour and the urine is blood-stained**, leave a catheter in the bladder for 10 days.

## 21.11 Difficulties with Caesarean section

Many difficulties attend Caesarean section, and many disasters can follow it, so the list below is long. *Torrential bleeding when you cut through a placenta praevia can kill a woman quickly. Disasters with the urinary tract are usually the result of very poor technique.* Fortunately, most of the other problems are rare. Some of the many difficulties are only seen in poor-resource settings, where inexperienced operators find themselves working under difficult circumstances.

### (a) Difficulties with the incision

**If a patient has had a previous Caesarean section**, dense adhesions may have formed between the uterus and the abdominal wall.

*Don't excise a keloid scar:* the keloid will probably get bigger. Just go through the middle of it. Excise redundant skin if you intend simultaneously to repair an incisional hernia (18.13). If the sides of the abdominal wall might prove difficult to line up accurately, mark a transverse line before your incision and align the points later.

Open the parietal peritoneum beyond the end of the previous scar. If you find a plane of loose connective tissue, free it with a finger. Cut fibrous bands. If dissecting the adhesions is very difficult (unusual), give up and make an upper segment incision.

**CAUTION!**

- (1) Stay close to the uterus to avoid the bladder.
- (2) If you find it helpful, open the uterus between stay sutures.

**If the patient has had a previous classical Caesarean section**, you would probably be wiser to perform a lower segment operation this time.

**If the bladder has stuck to the lower segment**, separate them with a finger, incise the peritoneum on the uterus about 2cm above the bladder. Lift the lower edge in forceps to stretch the adhesions between the bladder and the uterus. Cut them close to the uterus, keeping the points of the scissors directed at it. If this is difficult, give up and make an incision c.3cm above the area where the bladder and the uterus have stuck together.

**If the incision in the uterus tears** as you extract the foetal head, there will probably be a vertical tear in the corner which will run down behind the bladder, often with heavy bleeding. If you are alone with the scrub nurse, ask for an extra assistant. Exteriorize the uterus by drawing it out of the abdomen. Identify the edges of the incision and the tear. Mobilize the bladder further downwards if necessary.

**If you cannot define the extent of the tear**, carefully open the broad ligament by cutting the round ligament (21-18). This will let you feel the ureter, so that you can avoid it before you apply any clamps. Now apply Green-Armytage forceps to the edges of the tear, and draw its angle into view. Apply direct pressure with a dry pack, find the bleeding vessels, and tie them. Use interrupted sutures in the area of the tear. These will be easier to unpick if you find you have caught the bladder or the ureter by mistake.

*CAUTION! After repairing a tear, check visually that the ureter has not been caught in a stitch by mistake. If you have a doubt, inject dye into the ureter to see if it leaks.*

**If these measures fail**, the only way to control bleeding may be to tie both the uterine arteries, just after they have entered or branched into the uterus or cervix.

**If you are unable to repair the uterus**, perform a subtotal hysterectomy (21.17).

### **(b) Difficulties with particular presentations**

**If there is obstructed labour with a cephalic presentation**, enter the abdomen just below the umbilicus so as to avoid the bladder. If catheterization before the operation was impossible, empty the bladder now with a needle and syringe. Much of the swelling will be oedema, which will not go away. Mobilize the bladder free from the lower segment as usual. If necessary, get an assistant now to push the foetal head up from below through the vagina, before you open the uterus. Otherwise, the foetal shoulder may prolapse into the incision and make delivery more difficult. Make a transverse incision in the lower segment. Choose its level carefully. If it is too high, delivery will be difficult; if it is too low, you may have technical difficulties closing the vagina or you may even incise the vagina.

**If delivering the head is difficult**, don't panic. Everyone finds this a problem, especially when the uterus is tight around it. Take time to push the uterine wall back from around the head, by inserting 2 fingers all round. If you still have difficulty, enlarge the wound curving upwards laterally in a U-shape.

*CAUTION!*

(1) *Don't lever the head out with your whole hand*, because this can cause vertical downward tears in the lower segment.  
(2) If the liquor was purulent or infected, clean the abdomen carefully, and wash out the pelvis with warm saline. Administer antibiotics for at least 5 days.

**If there is a breech presentation**, feel for a leg or, better, both legs, and deliver the foetus breech-first as if you were delivering the head. Then deliver the head slowly, or you may damage it.

If, by mistake, you take hold of an arm, replace it. Then feel for a leg; recognize it by feeling for the heel.

If an arm comes out and will not go back, you are in trouble: you may have to make an inverted 'T' incision to get the foetus out.

When necessary, deliver the head (22.7) by a modified Mauriceau-Smellie-Veit manoeuvre, and the arms by pressure on the upper arms which you feel by palpating the back, or by a modified Løvset manoeuvre.

**If there is a transverse lie**, the choice of incision is important (21.9).

(1) **If the mother is in early labour, and the lower segment is poorly developed**, with most of the baby in the upper segment, make a transverse incision in the upper segment and deliver the foetus by breech extraction (22.7).

(2) **If early labour has begun, the lower segment is well developed, and the membranes are still intact**, make a transverse incision in the lower segment, and deliver the foetus by breech extraction.

(3) **If labour is obstructed, and most of the foetus is in the overdistended lower segment**, simple delivery through a transverse incision in the lower segment will cause large tears. So, if the foetus is alive, make a vertical incision in the lower segment, and extend the incision into the upper segment until it is big enough to effect delivery.

(4) **If the foetus is dead**, try to avoid opening the uterus. Only make a transverse incision in the lower segment as a last resort and decapitate or eviscerate the dead foetus in order to deliver it in any convenient way (21.8).

*CAUTION! Don't try to deliver a dead impacted foetus intact*, because this will tear the lower segment severely. *Don't make a classical or inverted 'T' incision for a dead foetus.*

### **(c) Difficulties with the placenta**

**If you anticipate placenta praevia**, expect difficulty, and get help if you can. You can usually use the ordinary transverse lower segment incision. *This is, however, contraindicated if:*

(1) there is a poorly developed lower segment, which would not allow a transverse incision of adequate length.

(2) there is a very vascular lower segment with large veins on it: this might be a placenta accreta.

(3) the presenting part is high, and the foetus is lying transversely, indicating that the placenta praevia is probably central. If so, mobilize the utero-vesical fold, as for a lower segment operation. Make a low vertical midline or a transverse incision in the upper segment.

#### **If you find placenta in the incision:**

(1) Peel it away from the uterine wall and enter the uterus from above it.

(2) When the edge of the placenta is too far away to allow this, push your finger through it quickly, and deliver the foetus without delay through the hole that you have just made. If you meet the cord, clamp it before you deliver the foetus, but *don't waste time looking for it*: you can clamp it immediately afterwards. Remember that a baby can easily bleed from an injured placenta. The mother can also bleed, so if you see a large bleeding vessel in the placental bed, control it with a figure-of-8 suture.

*Beware of a placenta praevia after a previous Caesarean section*: it might very well be a placenta accreta, increta or percreta. If you can't get the placenta off the uterine wall in this situation, you have confirmed the diagnosis and should proceed directly to a hysterectomy.

*N.B.* If, beforehand, a referral is possible to specialists where there is a reliable blood bank, that would be best.

**If there is post-operative bleeding** (not uncommon with the common type of placenta praevia), it is probably arising from the lower segment at the site of the attachment of the placenta. Administer oxytocin, and if necessary transfuse blood. In desperation, pack the uterus (22.11) using a condom in the uterus, attached to an infusion to fill it as a balloon.

**(d) Secondary PPH**

**If there is severe vaginal bleeding 8-14 days after delivery**, the operation site is infected (common after an obstructed labour with sloughing of the tissues) or a piece of placenta was left behind, under perioperative antibiotic cover. Take the patient back to theatre, and examine her under GA. Put a gloved finger into the uterus through the external os and feel for a piece of retained placenta, and for the inner wall of the uterine scar. If this feels weak, or has broken down, re-open the abdominal incision. You may find, especially in the presence of HIV infection, a soft necrotic bleeding uterus, with blood and spreading infection in the peritoneal cavity. What was the scar may now be an infected hole in the uterus. Under such circumstances, perform a subtotal hysterectomy (21.17). *If you don't attempt this, she will die.* Expect to find that the parametrium is acutely infected and swollen, so that it feels like cheese. In this situation, treat the patient for septic shock with much IV fluids and broad-spectrum antibiotics.

**(e) Difficulties with the urinary tract**

**If you notice that you have opened the bladder**, which is not often detected during the operation, identify the hole carefully, hold its edges with Allis forceps, mobilize the surrounding tissues if necessary, and bring its edges together with continuous inverting sutures of 2/0 or 3/0 long-acting absorbable. Drain the bladder continuously with an indwelling catheter for 14 days.

**If you have injured the ureter** at operation, first check that the other ureter is intact. Either, repair the damage if you can with 4/0 interrupted long-acting absorbable. Or, insert a fine T-shaped tube into the ureter, bringing out the 'leg of the T' to the abdominal wall, and close the abdomen. Later, refer the patient for expert help. *Don't fashion an external ureterostomy*, as this will stenose.

**If there is anuria:**

(1) This may be the result of severe hypotension while the patient was in obstructed labour (not uncommon) or the result of pre-eclampsia. Hydrate the patient well and add IV furosemide 40mg.

(2) Both ureters may have been tied or damaged. This you will find out usually the day after the operation. Perform an ultrasound to look for hydronephrosis. If you think you have tied one ureter or both, re-open the abdomen. For each side, check if the ureters are patent by injecting blue dye proximally. If no dye comes out in a urinary catheter, remove the uterine sutures one by one. Then close the uterus again. Otherwise refer the patient for reconstruction; if you cannot, except after considerable delay, fashion bilateral temporary nephrostomies (27.14).

**If there is a severe dull pain in one loin post-operatively**, you may have tied one of the ureters. Proceed as above. Otherwise refer the patient as before.

*N.B.* Sometimes, when the ureter is damaged, neither the patient nor you are aware of it: the kidney merely stops functioning.

**If urine discharges from the vagina after 2-5 days**, there might be:

(1) Overflow incontinence. Check if the bladder is distended. This can happen if there is bladder atony due to stretching of the detrusor muscle fibres. Keep in an indwelling (*not a condom*) catheter for 4wks. Expect complete recovery.

(2) Bladder or urethral stress incontinence. Ask the patient to cough: you will see urine spurting out of the urethra. If it is disabling, refer her for a colpo-suspension.

(3) A fistula. Pass a Foley catheter and perform a dye-test by instilling methylene blue in the bladder.

*N.B. Not all urinary leakage postpartum is due to a fistula!*

**If the test is +ve**, the dye comes out from the anterior vaginal wall (juxta-urethral, 21-20A or mid-vaginal VVF, 21-20C) or the cervix (juxta- or intra-cervical VVF, 21-20E,F). The first is due to pressure from the foetal head during prolonged obstructed labour. The last is the result of cutting the bladder or stitching the bladder together with the lower uterine segment during the Caesarean section.

*Don't prescribe antibiotics* (they are of no use) *and don't send the patient away for evaluation in 3 months' time!*

Contrary to general belief, a great deal can be and should be done immediately by very simple measures under any conditions, however deprived of resources, by whoever is involved in postpartum care. The principle is to decompress the bladder totally for a sufficiently long time to give it the opportunity to heal spontaneously as the fresh wound edges lie against each other. The earlier you do this, the better the chance. Some 25-30% of fistulae will heal spontaneously in this way and larger fistulae will reduce to half the size.

It is still worthwhile trying with fistula presenting up to 3 months postpartum. Open drainage of the catheter into a pot or a plastic bowl is often better than closed drainage into a urine bag, which is often carried on the head or shoulder! Therefore it is good to fix an IV giving set to the catheter to allow the patient free mobility.

There should be free drainage at all times: instruct the patient to take care not to block the catheter or to lie upon it when she sleeps.

In all cases keep a sufficiently large (Ch18) indwelling catheter *in situ* for at least 4-6wks, filling its balloon with a *maximum* of 10ml water. Encourage the patient to drink at least 5L fluids daily in order to produce a minimum of 4L urine/day: the urine should be completely colourless and odourless like clear water. If she does not drink enough and the catheter gets blocked, flush it or change it for another.

*Don't allow it to get blocked or infected!*

Early on, sitz baths bd are useful, to prevent leaking urine irritating the skin. Remove any necrotic tissue from the vagina.

Support the patient with haematinics, and a high-protein diet. Insist on immediate mobilization: *it is a catastrophe to develop contractures and bedsores because of a fistula.*

For the first few days the patient should stay in the hospital under close supervision to monitor her and to instruct her properly in catheter care and drinking. Then when her general condition is satisfactory she can be treated as an outpatient. She should come every week to report on the leak and to be instructed again to drink as much as 5L/day.

After removal of the catheter, instruct the patient to continue drinking and to pass urine frequently. She has to refrain from sexual intercourse for 4-6 months. She must attend antenatal care at subsequent pregnancies and deliver in a hospital at all subsequent deliveries.

**If after 6wks of catheterization, the urine still leaks all the time** (*i.e. not dry at night*), and upon vaginal examination the fistula is too big or the balloon is inside the fistula, remove the catheter and try to refer the patient to a hospital where fistula repair is done regularly: *the first attempt gives the best result*. If referral is impossible, you may be justified to attempt repair of simple fistulae (21.18).

**If the dye test is -ve**, there might be a leak from a uretero-vaginal fistula. To confirm this, do the 3-swab test: put 3 pieces of cotton wool in the vagina, instil methylene blue through the catheter and let the patient walk around for 20mins. After that, remove the cotton swabs one by one.

(1) If the first swab is blue, there is urethral incompetence or a urethro-vaginal fistula.

(2) If the middle gauze is blue, there is a vesico-vaginal fistula.

(3) If the last gauze is blue, there is a vesico-cervical or vesico-uterine fistula.

(4) If the last gauze is wet but not blue, there is a ureteric fistula. This type of fistula is probably caused by damage to the ureter at Caesarean section or hysterectomy by:

(a) clamping it in error, not recognizing this, and leaving the clamp on for more than a few minutes, or

(b) including the ureter in a suture whilst closing the uterine opening. An IVU will tell you which side is involved.

The kidney on the affected side will show some degree of hydronephrosis. The left side is almost twice as often damaged as the right side. There may or may not be pain in the loin. A uretero-vaginal fistula has a better prognosis and is less urgent than tied ureters, because it means that the kidneys will not stop functioning. Try to refer for elective repair: the ureter may need re-implanting into the bladder, or repair end to end. To maintain good kidney function, refer without delay.

**If there is a contraction (Bandl's) ring** in the lower segment, or between the lower and the upper segments, deal with it like this: If the foetus is entirely above the ring, make a transverse incision entirely above it. If it is round the neck, make a vertical incision across it.

**If there are uterine fibroids**, leave them unless they are pedunculated and removal is very easy. In this case, make a V-shaped incision, *not a straight transection*, so that closing the uterine surface is possible without tension. Otherwise, leave them: they may settle and atrophy. Removing a fibroid at delivery, from within the wall of the uterus, causes severe bleeding.

**If there are ovarian cysts or tumours**, remove them if they are >5cm diameter. Ovarian cystectomy is possible, but removing the ovary and tube will be quicker and safer. Smaller functional luteal cysts will have usually disappeared spontaneously by the end of pregnancy.

**If there are dense adhesions**, you will have to separate them sufficiently to get good access to the uterus. *Don't try to remove them from around the tubes and ovaries*; they will ooze and form again.

## 21.12 Alternative methods of Caesarean section

### (a) Transverse classical in the upper segment

Check that the uterus is wide enough. Incise the peritoneum over the lower part of its upper segment with a scalpel. Mobilize it away from the incision with scissors, and incise the uterus transversely in the midline. Enlarge the incision to the right and left, by stretching it with your fingers (it is usually too thick to be cut with scissors), and deliver the baby by breech extraction.

### (b) Midline classical in the upper segment

The midline classical Caesarean section is seldom done by experienced obstetricians. Because rupture of the uterus is such a danger with subsequent pregnancies, perhaps as early as 28wks, you must close the uterus with particular care, and do all you can to persuade the patient to consent to a simultaneous tubal ligation. Many steps are similar to those for a lower segment operation. However, the uterus is much thicker in the upper than in the lower segment, so you will have difficulty opening it using your fingers only. Make a 12cm vertical midline incision: *check carefully that the uterus is not rotated*, before cutting!

#### MIDLINE CLASSICAL CAESAREAN SECTION

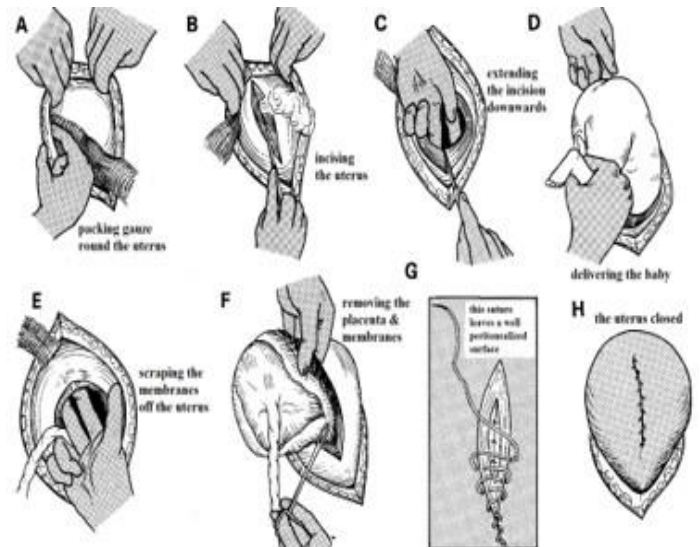


Fig. 21-13 MIDLINE CLASSICAL CAESAREAN SECTION.

A, packing gauze round the uterus. B, incising the uterus. C, extending the incision downwards. D, delivering the baby. E, emptying the uterus. F, removing the placenta and membranes. G, an anchor stitch has been inserted, and the wound is being closed by an inverting suture, which pierces each wound edge from within outwards. H, this buries the peritoneal surface of the wound, and minimizes the formation of adhesions.

After Bonney V. *Gynaecological Surgery*. Baillière, 1971 Figs 331-7 with kind permission.

### (c) De Lee (Kronig/Cornell) vertical

#### In $\frac{2}{3}$ of the lower and $\frac{1}{3}$ of the upper segment

To make a de Lee incision, incise the visceral peritoneum transversely, as described below but high on the lower segment. Mobilize the peritoneum and the bladder well down. Find the midline of the uterus. Insert a small transverse suture where the bottom end of your incision is going to be, to prevent it extending downwards behind the bladder. Make a longitudinal incision, two-thirds of it in the lower segment, and one-third in the upper segment.

Later, repair a de Lee incision with two layers of continuous #1 or #2 absorbable. *Don't catch the full thickness of the uterine wall in the first layer:* it is often too thick. Make sure you include the uterine fascia in the second layer, or it will continue to bleed. Repair the peritoneum and pull it up high, so that the top of the incision is covered, preferably with a locking suture (4-8G).

If you have made a long cut in the upper segment, tie the tubes on the same indications as in a classical Caesarean section.

### MODIFIED EXTRAPERITONEAL CAESAREAN SECTION

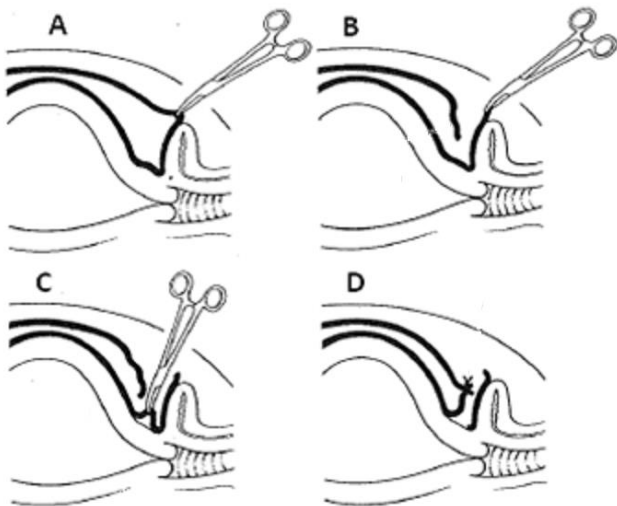


Fig. 21-14 MODIFIED EXTRAPERITONEAL CAESAREAN SECTION. A, holding the parietal peritoneum, B, separating it from the rectus muscle, and cutting it transversely. C, picking up the utero-vesical fold. D, suturing this to the parietal peritoneum to leave a passage for the foetus to pass through.

### (d) Modified extraperitoneal

This method has undergone a renaissance, being recommended not so much where antibiotics are absent, but where infection is rife. The idea is that the foetus, on its way out of the uterus, does not pass through and so does not contaminate the peritoneal cavity (21-14).

Separate the parietal peritoneum from the rectus muscle down to the level of the dome of the bladder, and cut it open transversely to its lateral limits. Similarly cut open transversely the utero-vesical fold.

Then suture the superior leaves of the parietal peritoneum and of the utero-vesical fold together, thus sealing off the peritoneal cavity from the lower uterine segment, before you actually open this. *Don't exteriorize the uterus!*

## 21.13 Infection following Caesarean section

Peritonitis (10.1) may follow any obstructed labour, or an infected Caesarean section, and is common after rupture of the uterus. Death is a real risk when:

- (1) labour is abnormally long: the longer, the greater the risk,
- (2) the foetus is dead,
- (3) membranes rupture early and liquor becomes infected,
- (4) HIV infection is present,
- (5) sterile procedures are poor.

Use pre-operative antibiotics and proper sterile practice to try to prevent sepsis (2.7).

Infection may take the following forms:

- (1) Wound infection (11.13) may discharge through the scar into the cavity of the uterus. Infection may resolve, or you may need to drain pus suprapubically. If fever recurs with signs of more pus collecting, do another drainage operation.
- (2) Pelvic abscess (10.3), which will need draining suprapubically or *via* a gridiron incision.
- (3) Peritonitis (10.1): You will probably find that the uterus is totally disrupted, so it is hopeless to try to repair it. A subtotal hysterectomy (21.17) will usually be enough, commonly with the removal of both adnexa, but retain one if you can.
- (4) Subphrenic abscess (10.10), which is a common late complication, and is likely to kill the patient if you don't drain it; as may multiple abscesses between loops of the bowel (10.3).
- (5) Secondary postpartum haemorrhage (22.11,12) may occur with a retained segment of placenta, needing evacuation, or an infected uterine scar, which will mean a hysterectomy (21.17).
- (6) Burst abdomen (11.14) occurs especially after several Caesarean sections, and needs repair.
- (7) Infertility (19.3) is a late complication of infection.
- (8) Bowel obstruction and low-grade peritonitis will occur if packs or swabs have been left behind in the abdomen.

## 21.14 Elective Caesarean section, 'trial of scar', or Caesarean section early in labour?

If a woman has had one Caesarean section, the alternatives for the next pregnancy are:

- (1) an elective Caesarean section, before labour ensues.
- (2) a Caesarean section in early labour.
- (3) an attempt at vaginal delivery (a 'trial of scar' (TOS), or 'vaginal birth after Caesar' (VBAC)).

A lower segment Caesarean section is sometimes done for such conditions as foetal distress, placenta praevia, or the prolapse of the cord or an arm, which are unlikely to happen again in a later pregnancy. When a woman like this becomes pregnant again, there is every reason to expect that the labour will be normal, except for the scar that she now has in the uterus. This will almost always give some warning before it ruptures, so, with good supervision, you can safely let her have further attempts at delivering vaginally.

She can have as many trials (TOS or VBAC) as she likes, provided the previous one was successful, but she must have only had 1 previous Caesarean section. Sometimes, however, after several TOS there is only a very thin membrane, the peritoneum, separating the uterine and the abdominal cavity. A subsequent TOS is more likely to end in disaster in this case.

**If a woman has had  $\geq 2$  Caesarean sections, you should nearly always repeat the Caesarean section.**

*N.B.* It is a good idea with any multipara to discuss during the antenatal period whether, if she needs a Caesarean section in any case, she would also like a sterilization. Note on her medical card that it has been discussed and what the result of the discussion was. This is even more important where women have one scar from a Caesarean section.

### **TWO CAESARS OR MORE ALWAYS A CAESAR AGAIN**

When you try a trial of scar, admit the patient to hospital and monitor her closely. If the scar shows signs of rupturing, perform a Caesarean section immediately. These warning signs only last 1-2h before the uterus ruptures, *so you must monitor her with the greatest care.*

**If CPD was the reason for the Caesarean section,** it reduces the chances of a successful trial of scar in the current pregnancy, but *does not exclude it*, because: (1) the pelvis continues to grow up to the age of 19yrs, (2) uterine action is often poor in the under-16s.

### **NO TRIAL OF SCAR IF THE PREVIOUS CAESAREAN SECTION WAS CLASSICAL MIDLINE!**

You can assume that no progress after 6cm cervical dilation in the 2<sup>nd</sup> stage of labour after a Caesarean section, with a vertex presentation and good (oxytocin-induced) contractions, means CPD. Caesarean section for foetal distress in developing countries is most often related to CPD.

### **ONE VERTICAL SCAR, ALWAYS ANOTHER**

Good care during a trial of scar means that monitoring must be reliable, and you must be able to perform a Caesarean section within 1h, even if it is 3am at night.

If the organization and discipline of your hospital are not such that it can provide care of this quality, elective Caesarean section will give the mother a better chance of saving her foetus, as well as her own uterus, and perhaps her life.

*If it takes several hours to find a driver, to fetch you, and to prepare the theatre, a trial of scar will be dangerous. Ideally, uterine rupture should never occur during a trial of scar.*

Even when conditions are not ideal, a trial of scar may be justified, because the immediate and future risks of a further Caesarean section can be considerable. If a woman knows that she cannot have a trial of scar in hospital, she may try to have a dangerous trial by herself at home. A woman will

usually understand if you say, "We will give you a trial, and if you have any difficulty, we will perform another Caesarean section."

Ask the clinics to refer all women who have had a previous Caesarean section, and who are sure of their dates, at 34wks, so that you can assess. If a trial of scar is not indicated, plan an elective Caesarean section at 38wks, or in early labour, if a woman is not sure of her dates.

Elective Caesarean sections are a way to avoid a trial of scar, but they are not the complete answer: you may perform a Caesarean section too early because the dates may be uncertain, but even if they are certain, they need to be confirmed by early ultrasound, and risk prematurity. Furthermore, you may become unpopular, so find out what the local women think.

The best indication that a uterine scar is going to rupture is a tachycardia, or foetal distress. Make observations  $\frac{1}{2}$ hrly. If the foetal pulse rises  $>160$ /min, or drops persistently  $<100$ /min, or there is pain *between* contractions, the scar is probably rupturing, so proceed to Caesarean section. Other signs are described below.

HARBANS KAUR (38yrs, gravida 4, para 3) was admitted at 9am on a Saturday, for a trial of scar, having had one previous Caesarean section with the first pregnancy. She was 7cm dilated and had good contractions. At noon she was fully dilated and the foetal head was  $\frac{3}{5}$  above the brim. During the next  $\frac{1}{2}$ h it remained there. The doctor on duty was called for another emergency Caesarean section, so the intern was advised to attempt vacuum extraction. He failed, but in doing so, he included the cervix under the cup, and tore it. At 3pm she developed pain, shock, and abdominal tenderness, and the foetal heartbeat disappeared. She was rushed to the theatre. The uterus had ruptured, and the tear had extended into the bladder. The superintendent was called. He found that the ureter had been caught in a hastily applied suture. The following day she was found to be leaking urine vaginally.

LESSONS These are many; they include: (1) In multiparas the second stage should not last longer than 20 minutes. (2) A vacuum extractor was applied when the head was  $\frac{3}{5}$  above the brim. It should be only  $\frac{1}{5}$  above or less (except for a trial of vacuum or symphysiotomy). (3) When you apply the cup of a vacuum extractor, you should make sure that you don't include the cervix. (4) When a trial of scar is done, it must be possible to perform an immediate Caesarean section if the trial fails.

### **WARNING SIGNS MAY ONLY LAST 1-2H BEFORE RUPTURE**

#### **TRIAL OF SCAR INDICATIONS**

- (1) A woman who has had only one previous lower segment Caesarean section, and the indication for it is absent in the current pregnancy.
- (2) A scar from a myomectomy (provided the uterine cavity was not opened during the operation), hysterotomy (21.5), or uterine perforation during a D&C.

*N.B.* A request for tubal ligation may induce you to perform an elective Caesarean section. On its own, it is not a reason to avoid vaginal delivery, because this followed by tubal ligation will still be safer for the patient whether she arrives in labour or not.

#### **CONDITIONS**

- (1) Only  $\leq 1$  previous Caesarean section.
- (2) In hospital.

- (3) Caesarean section must be available within 1h any time of the day or night.
- (4) Estimated foetal weight <4kg.
- (5) A vertex presentation in the occipito-anterior position.

#### CONTRAINDICATIONS

- (1)  $\geq 2$  previous lower segment Caesarean sections.
- (2) 1 previous classical midline Caesarean section.
- (3) Any degree of CPD, or suspected CPD in this pregnancy.
- (4) An occipito-posterior presentation.
- (5) Any other form of malpresentation (except perhaps a breech, if you are experienced) or obstetric complication.
- (6) Foetal or maternal distress.

**METHOD.** Assess all pregnant women with a uterine scar in the antenatal clinic at 36wks. Take a careful history. Assess the pelvis clinically and assess the size of the foetus by measuring the height of the fundus; if it is >40cm, don't do a trial of scar. A previous successful vaginal delivery at term is a good omen.

Ask the patient to avoid heavy work during the last month of pregnancy, or to come in for rest. If possible, admit her to a waiting area at 36wks for rest and observation. When labour starts, restrict oral intake to fluids only. *Don't as a rule induce labour.* Unless your blood bank can be relied upon to have blood available within 1h, have it cross-matched, and ready to use if necessary. Record the pulse and the foetal heart rate carefully.

You may sometimes be able to feel the scar in the lower segment at vaginal examination. This will be easier if you are using epidural anaesthesia. If it bulges or feels weak, perform a Caesarean section immediately: you may be able to assess weakness of the scar on ultrasound. The tenderness of a scar is difficult to assess in labour, and is not on its own an indication for Caesarean section. Assist delivery with vacuum extraction, if necessary.

#### **Abandon the trial if:**

- (1) The alert line is crossed on the partograph!
- (2) The foetal pulse rises to 160.
- (3) There is pain between contractions.
- (4) Pain is generalized.
- (5) There is unexplained vaginal bleeding or haematuria, *though this may be caused by the balloon of a Foley catheter being inflated in the urethra when the foetal head is low.*
- (6) Uterine contractions cease.
- (7) There is rectal or vaginal tenesmus.
- (8) Restlessness ensues.
- (9) Palpation of the uterine scar causes the patient to hit you on the hand!

Stay with the patient during labour so that you can examine the lower uterine segment vaginally immediately after delivery of the placenta, so as to be sure that it has not ruptured. This is uncomfortable, but does not need anaesthesia if you do it just after the placenta is delivered. *Don't delay because vaginal examination is an insufficient indication for a GA!* If you find a rupture, which may present as postpartum haemorrhage, *don't delay but proceed to laparotomy* (21.17).

## 21.15 Birth canal injuries

### (a) 1<sup>st</sup> and 2<sup>nd</sup> degree perineal lacerations

The objective of your repair is to achieve haemostasis and to approximate any disrupted tissues to assist natural healing. Good anatomical alignment is essential. You need good lighting properly to identify the structures involved.

Ensure that your patient has adequate analgesia and is as comfortable as possible throughout the initial assessment (*i.e.* the systematic examination of the perineum, vagina and rectum) and also the subsequent operational procedure. For minor injuries LA might be sufficient, but if the patient is uncomfortable or distressed, a GA or spinal anaesthesia may be more appropriate.

#### METHOD

Insert a large swab or tampon made from sterile compresses tied together with a thick thread into the upper fornix of the vagina to absorb any bleeding. Leave the 'pull string' visible at the vulva to prevent you forgetting it when the procedure is over.

It is important to reach the upper edge of any wound. Put a stay suture at upper end, leaving the thread long. Place another suture c.1cm above the apex of the tear to avoid bleeding from retracted blood vessels.

Close the vaginal laceration from inside to out up till the hymenal margins, using a continuous (spiral) suture. *Leave no cavity underneath the vaginal wall* because this can produce a painful haematoma, which may become infected. *Take care at the same time not to suture too deeply to avoid injury to the rectum.* Perform a rectal examination after the procedure to ensure that no suture material is inserted into the rectal mucosa. Use the hymenal margin on both sides as a landmark for correct vaginal re-adaptation.

Repair the *bulbocavernosus* and *transverse perineal* muscle layers with 2-3 absorbable single sutures, and the perineal skin with rapidly absorbable continuous or interrupted sutures.

**If there are multiple vaginal lacerations with friable tissue,** insert a vaginal tampon and remove it after 24h; leave a catheter in the bladder while the pack is *in situ*.

### (b) A 3<sup>rd</sup> degree tear (GRADE 1.3)

You can nearly always avoid 3<sup>rd</sup> degree (anal sphincter) tears by controlled pushing of the fourchette (21-8B) from both sides to the midline with your fingers if a tear is imminent. An episiotomy does not altogether prevent a 3<sup>rd</sup> degree tear. It is not proven but likely that massage and stretching of the perineum before the largest diameter of the head is delivered might help in preventing large tears. These large tears follow instrumental more often than simple vaginal deliveries. If a vacuum extraction is performed for foetal distress, marginal CPD or exhaustion, *it does not mean an episiotomy is also always needed* (a narrow pelvis can co-exist with a wide vulva).

# REPAIRING A THIRD DEGREE TEAR

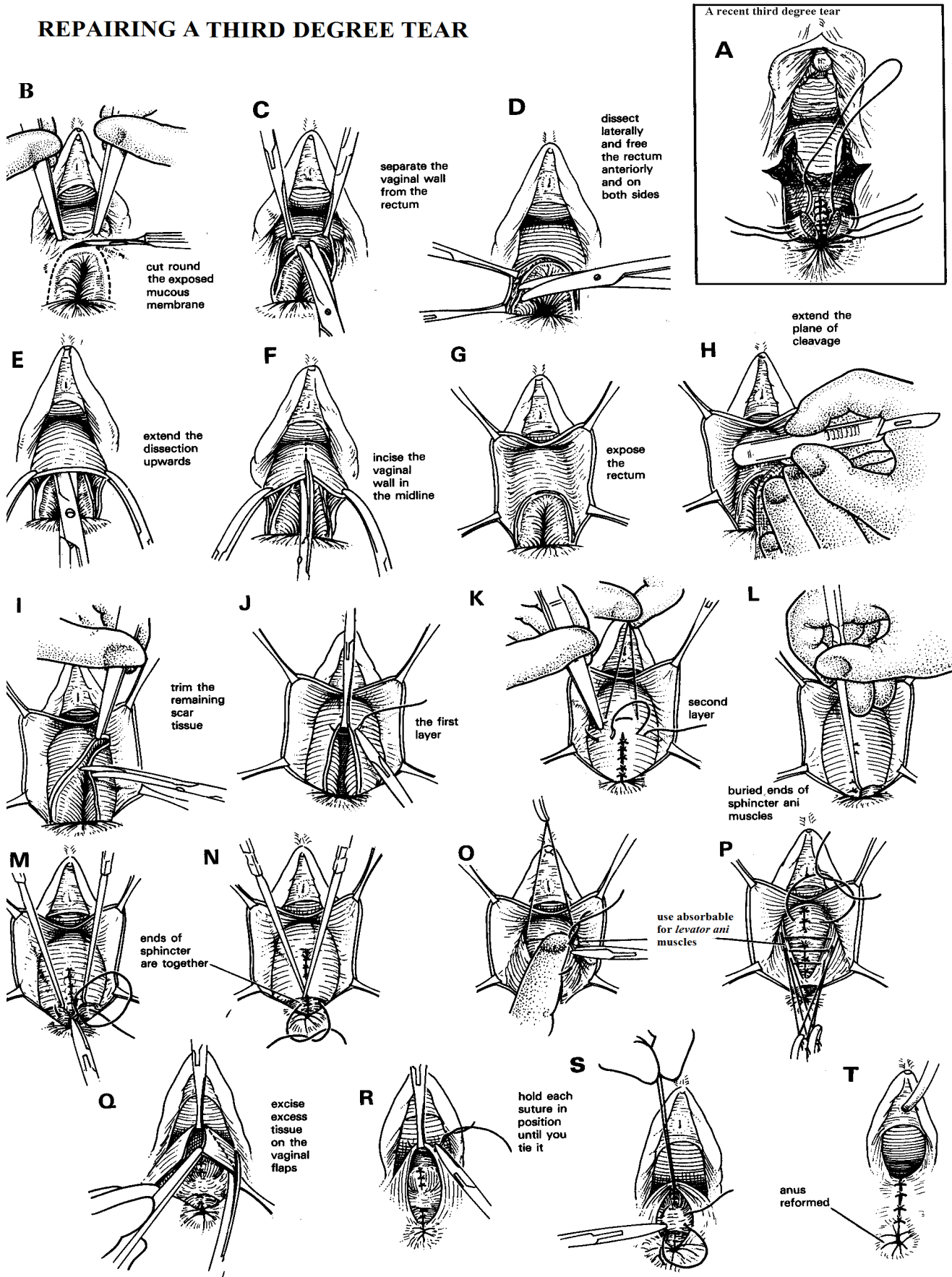


Fig. 21-15 REPAIRING A 3<sup>rd</sup> DEGREE TEAR. A, a recent tear. B-T, an old one. After Parsons L, Ulfelder H Atlas of Gynaecological Surgery WB Saunders 2<sup>nd</sup> ed 1968 p.259,261 with kind permission.

On the other hand, a fast delivery through the soft tissues of the vulva gives the tissues less time to stretch and, although a vacuum cup does not increase the diameter of the foetal head, a large tear becomes somewhat more likely, often because you are impatient or worried about the wellbeing of the foetus.

*Don't blame the midwife.* She will be upset anyway, and will be tempted to conceal such a tear if you are harsh. A common mistake is to support the perineum too vigorously, so as to force the head against the pubis, and tear the tissues. It is best to repair 2<sup>nd</sup> (perineal muscle) or 3<sup>rd</sup> degree tears within 24h of delivery, provided they are suitably clean, or delaying till they are so. The problem is that, if you wait, the tissues may become very distorted and stenosed (21.16).

With a recent 3<sup>rd</sup> degree tear:

- (1) Start by suturing the edges of the patient's rectum together.
- (2) Cover these sutures with a layer of fascia.
- (3) Suture the anal sphincter with 2-3 interrupted sutures.
- (4) Close the vaginal and perineal skin. If a tear is old, first incise and reflect the skin which has grown over it.

Repair this as soon as possible in theatre; you usually will need GA or spinal anaesthesia. *Don't consider this a trivial operation.*

The best chance of success is the 1<sup>st</sup> attempt. If you fail, the patient is condemned, at best, to some episodes of faecal incontinence.

#### METHOD

Use the lithotomy position, with the buttocks hanging well over the edge of the table. Shine a good light on the wound. Clean it and the skin round it thoroughly. Put a large gauze pack with a tape attached to it into the vagina. This will keep the tear free from blood, but *be careful that you don't obscure occult uterine bleeding.* Get a competent assistant to retract the vaginal wall while you survey the tear.

**If the tear goes high up the rectum and vagina,** you must repair these in separate layers, first dissecting them free from one another. More distally, the perineal body makes a clear separation between the two. Suture the rectal serosa with interrupted or continuous sutures on a round-bodied curved needle, starting at the apex of the tear from outside inwards, so that the knots end up on the outside of the rectum.

**If the rectal tear is very extensive,** pick up the pre-rectal fascia with a second row of sutures, reinforcing the first layer. To close the *external sphincter ani*, look for the torn ends of this muscle at the left and right postero-lateral positions (4 & 8 o'clock), which may be deeply retracted and rolled up laterally. Search for these with hooks or baby Babcock forceps (*artery forceps will damage the muscle and tear it*). Pull on the ends of the muscle on both sides, and get your assistant to hold the forceps approximated.

Place your index finger in the rectal lumen: you should feel firm contraction over it. *If you do not, you will need to look again for the retracted end of the sphincter muscle.* Then insert 3 deep long-acting absorbable sutures through the muscle *and surrounding fascia* (if you pick up muscle alone, the sutures will cut out), making sure you exclude the forceps. *Don't tie the sutures until you have removed the forceps* (21-15A); try to approximate the 2 blocks of tissue accurately and tie them together without tension.

*Check that you have not made the rectum too narrow.* You should be able to insert 1 finger comfortably.

To close the vaginal skin, use a single layer of continuous absorbable sutures.

To close the *levator ani* muscles (25-15P), take deep bites with the needle each side, so as to take a good hold of the muscles and the fascia covering both their surfaces. These thick sheets of muscle and fascia lie deep on each side of the rectum. Begin at the anal end and approximate them (21-15P). Suture the anal skin with a few interrupted intracuticular absorbable sutures, doing the same with the perineal skin.

*CAUTION! Don't close the skin and vaginal wall too tight; leave room for drainage, in case there is infection or oozing.*

POST-OPERATIVELY, encourage sitz baths twice daily, mobilization and provide some laxatives. *Don't use an enema:* rough use may destroy your handiwork!

If the tear is very soiled with faeces, delay surgical repair. In untreated HIV+ve patients especially, make sure you have emptied the rectum beforehand with laxatives and enemas, and have administered gentamycin and metronidazole for 3-5 days. In severe cases, establish a defunctioning colostomy first (11.5).

**If the cervix is torn,** it may have a single tear, large enough to need suturing, or numerous small tears. Bleeding from small tears is most easily controlled by packing (22.11). A large laceration will need repair (22-11).

*N.B.* Bleeding is more likely to be arising from a poorly contracted uterus, which needs oxytocin.

**If there is a haematoma of the vulva,** incise it at its lowest point, and evacuate the clot. Insert a drain, and suture this in position. If it bleeds severely, pack the cavity for 24h. These haematomas are usually unilateral, cause great pain, and occasionally retention of urine.

**If the clitoris is torn,** it may bleed severely. Put in a figure-of-8 non-absorbable suture.

## 21.16 Old 3<sup>rd</sup> degree tears

Delay in anatomical repair of a 3<sup>rd</sup> degree tear will result in scarring, distortion and stenosis. Make sure any woman with a deep perineal wound gets sitz baths at least bid. *Don't be tempted to rush in to repair before you can identify all the structures.* This may mean considerable, difficult, intricate dissection, and it will mean a good understanding of the normal anatomy. Sometimes patients have minimal symptoms; remember >20% of patients still have some incontinence after a successful repair. Operate if your means for effective referral are very limited. If there is a minor tear in the *levator ani*, the patient may only have mild incontinence with loose stools: *don't make a tolerable situation worse!* Consider that this region is always primarily infected. Reconstruction is hazardous in untreated HIV+ve patients. Make sure the rectum is cleaned out with laxatives and enemas 2-3 days pre-operatively.

### REPAIR OF AN OLD 3<sup>RD</sup> DEGREE TEAR (GRADE 2.4)

#### METHOD

Position the patient as before (21.15). Cut round the exposed mucous membrane for the full thickness of the vaginal skin. Apply tissue forceps, and use scissors to separate the vaginal wall from the rectum gently (21-15C). While you exert gentle tension on the vaginal wall, dissect laterally and free the rectum anteriorly and on both sides (21-15D). Apply clamps to the cut edges of the vaginal skin, and hold them downwards. Extend the dissection upwards in the plane of cleavage between the rectum and the vagina, holding your scissors against the posterior vaginal wall (21-15E).

Incise the vaginal wall in the midline (21-15F), to expose the rectum (21-15G). Hold the rectum medially, and use the handle of your scalpel to extend the plane of cleavage between the vaginal flap and the rectal wall (21-15H).

If you are able to mobilize the rectum, you will be able to close it without tension. Trim the remaining scar tissue from the edge of the rectal mucosa (21-15I). Hold the upper edge of the torn rectum in tissue forceps, and invert its mucosa with a row of fine atraumatic long-acting absorbable sutures (21-15J). Continue these until you reach the muco-cutaneous margin of the anal opening, so as to refashion a normal anus. Reinforce and bury the 1<sup>st</sup> layer of sutures with a 2<sup>nd</sup> layer (21-15K). This will reduce the size of the rectum, but only temporarily.

Search for the retracted ends of the *sphincter ani* muscles, which you will find buried in dimples at either side of the anus. This is essential, because *if you only freshen up the margins, you will not achieve continence.* Use hooks (21-15L), or baby Babcock forceps. Bring the hooks together to see if you have secured the sphincter (21-15M,N) and approximate them with at least 3 long-acting absorbable sutures.

Close the *levator ani* muscles with long-acting absorbable (21-15O,P) starting distally. Excise any excess tissue on the flaps of the vagina (21-15Q), *taking care not to remove too much.* Bring the raw edges of the vaginal wall together with interrupted absorbable sutures (21-15R,S).

Hold each one until the next is in position, and then cut it. When you have closed the vagina, close the perineal skin.

The last 2-3 sutures should complete the formation of the anus, so that anal skin folds (*rugae*, 21-15T) radiate from it like the spokes of a wheel. If they don't, you have not done the operation as you should.

Manage the patient post-operatively as above (21.15).

## 21.17 Uterine rupture

The uterus can rupture before or during delivery, especially

- (1) in multipara,
- (2) after previous Caesarean section, especially with a vertical incision, and
- (3) when oxytocin is used, or
- (4) when version has been performed.

In only c.2/3 of cases do you make the diagnosis before delivery. In the rest you make it afterwards, usually after some difficult obstetric manoeuvre, such as a retained placenta (22.11), a destructive operation (21.8), or after a trial of scar (21.14). Here we are mostly concerned with rupture of the uterus before delivery, as a complication of obstructed labour.

**If a woman, particularly a multipara, arrives late in obstructed labour, or you don't make this diagnosis,** the uterus is likely to rupture. *This is a great obstetric disaster.* If primary care is really poor in your district, 50% of the women referred to you may need an operative delivery, and of these 5% may end up with a uterine rupture.

The usual story (21.11) is that a woman is brought from a rural setting in obstructed labour, having waited a long time for transport to hospital. She is often sufficiently clear-headed to be able to tell you that she had strong frequent pains which stopped suddenly.

When the uterus ruptures, it may do so intra-peritoneally (complete rupture), or extra-peritoneally (incomplete rupture, less common) when the foetus remains out of direct contact with the intestines.

**If the membranes have ruptured some time before delivery,** the contents of the uterus will become infected, and the uterine muscle bruised and in poor condition for repair.

*N.B. Never try to deliver a woman with a ruptured uterus vaginally.* Your aim is to:

- (1) Resuscitate the patient and operate soon.
- (2) Remove the baby and the placenta.
- (3) Control bleeding.
- (4) Repair or remove the uterus on the indications given below. Unless the rupture is extensive, and the tissues are particularly bruised and oedematous, repairing the uterus is likely to be easier than removing it, because distortion of the anatomy makes hysterectomy difficult. But even repair is not easy, because the edges of the tear will be ragged and not easy to bring together.

Hysterectomy takes longer than repair, and causes more bleeding. A subtotal, which leaves the cervix and perhaps part of the lower segment, is easier than a total hysterectomy; it causes less bleeding, and there is less danger to the ureters. If you have to remove the uterus, try to leave at least one ovary behind.

The secret of success is to exert continued compression on the uterus (22.12), to place a tourniquet around the cervix or base of the uterus (22.11), and to identify important structures and landmarks before you start to cut or suture them.

### EVIDENCE SUSPICIOUS OF A RUPTURED UTERUS

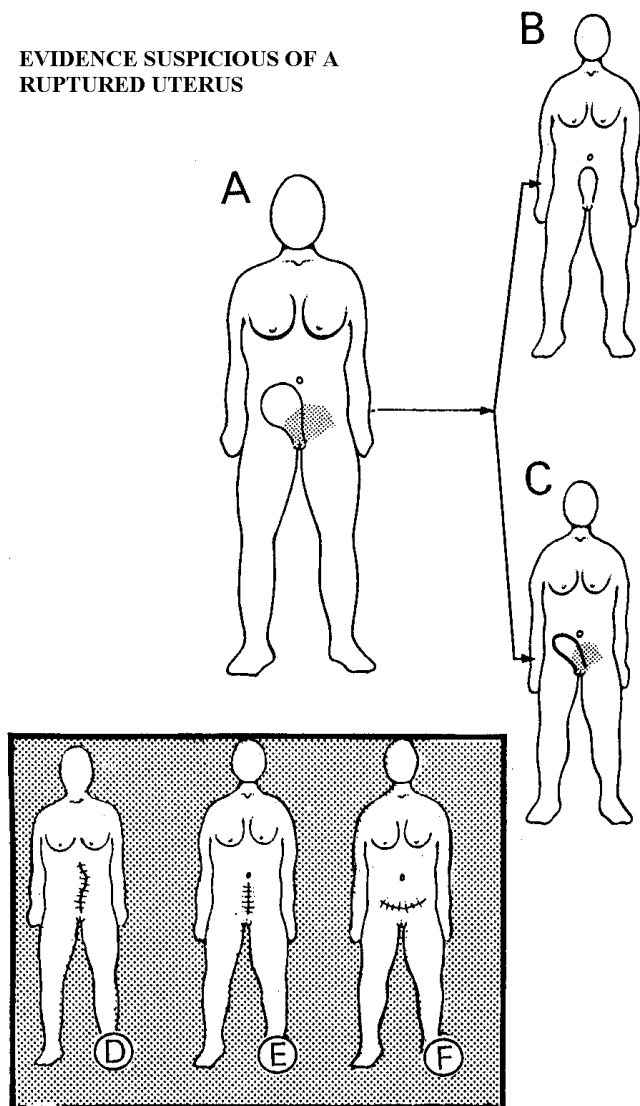


Fig. 21-16 EVIDENCE SUSPICIOUS OF UTERINE RUPTURE.

If a postpartum patient has a mass connected to the uterus (A), which does not disappear on catheterizing the bladder (B), but persists (C), it is probably a haematoma of the broad ligament due to rupture of the uterus. If a previous Caesarean section has left scar D, suspect strongly that it was the midline classical type. Scar E might be either. F is almost certainly a lower segment scar.

After Nasah BT, Drouin P. Review of 70 cases of ruptured uterus in Cameroun. *Tropical Doctor* 1978;8(3):127-31 with kind permission.

Speed is critical. Most time is lost getting the patient to theatre and in getting it ready, so make sure that it is *always* ready. If you are not familiar with the anatomy, study 21-18, 23-20, 21! Be aware of impending rupture when labour is obstructed, especially in multipara, and try to prevent it by rapid intervention.

### UTERINE RUPTURE

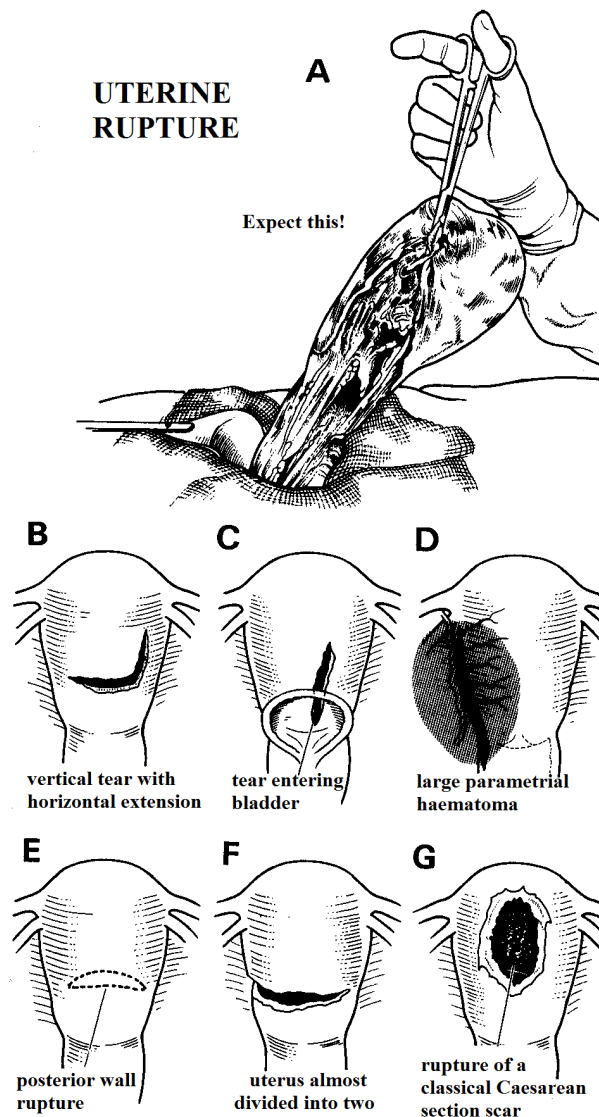


Fig. 21-17 UTERINE RUPTURE.

A, may look like this. B, a tear in the anterior wall with a vertical extension at one end. C, a tear involving the bladder. D, a tear in the lateral wall opening into the broad ligament. E, a transverse tear in the posterior wall. F, a tear which almost detaches the uterus. G, a tear from a classical vertical Caesarean section.

#### (a) Signs of impending rupture:

- (1) The Bandl's ring between the upper and lower segments rises towards the umbilicus.
- (2) The lower segment becomes stretched and painful to touch, even between contractions, which increase in strength and duration.
- (3) The patient becomes anxious and restless with a tachycardia  $>100$  and irregular respiration.

#### (b) Signs of actual rupture:

- (1) Uterine contractions stop suddenly and are replaced commonly by no pain, less pain, or else, more rarely, by severe continuous pain.
- (2) Shock and pallor without immediate response to blood transfusion (especially if the placenta is retained).
- (3) Vaginal bleeding, usually quite severe, but not necessarily so.

*N.B.* If the presenting part is jammed in the pelvis, no blood can escape from the vagina. Perform an immediate ultrasound to see if the patient has a haemoperitoneum, or aspirate at the sides of the uterus.

(4) A tender uterus to palpation (it may feel soft, or be permanently tense), especially vaginally. Later, the entire abdomen may be tender.

(5) The foetus is usually abnormally difficult to feel, but may be abnormally easy to palpate! Sometimes, the shape of the uterus changes, and you may be able to feel the foetus outside it (usually the limbs are close under the abdominal wall, a certain sign of rupture).

(6) The foetal head which was previously low in the pelvis, has now risen higher and may now no longer be palpable vaginally.

(7) Blood-stained urine.

(8) An absent foetal heartbeat usually, unless the rupture is early and small.

(9) Rarely, the appearance of the placenta at the vulva before delivery.

(10) Rarely, prolapse of loops of bowel into the vagina.

*N.B.* Shock or severe vaginal bleeding may dominate the picture. The patient is usually lucid, and may even be talkative, which may delude you into thinking she is less critical than she really is. Dramatic symptoms of rupture are uncommon *but death within a very short time is not.*

#### (c) Differential diagnosis

**Suggesting placental abruption:** the cervix is closed or nearly so.

*N.B.* Beware making this diagnosis in a patient with a previous Caesarean section scar. The cervix may still be closed in rupture of a vertical Caesarean scar, or a corneal ectopic gestation.

**Suggesting septicaemia:** purulent discharge or other signs of infection, which may be subtle in the presence of HIV.

**Suggesting severe dehydration:** reduced skin elasticity, extreme thirst, dry mouth, no urine output.

#### (d) Management

Resuscitate the patient vigorously in theatre or the labour ward. Instil at least 1L normal saline or Ringer's lactate before anaesthesia starts. *Don't delay*; adequate resuscitation is impossible if bleeding continues internally. Continue the resuscitation while you operate.

Start 2 IV infusions: one for saline or Ringer's lactate run fast, and the other for blood. Prepare for an emergency laparotomy (11.1). Administer IV antibiotics.

Use the lithotomy position. Wash the abdomen, and introduce a urinary catheter: this will prevent you mistakenly opening a high full bladder.

**If there is obstructed labour, and you are still not sure if there is uterine rupture or not,** perform a vaginal examination. The presenting part may have disengaged, so that your hand passes through the rupture into the abdominal cavity, allowing you to feel the inner surface of the abdominal wall. You may find that the presenting part is unexpectedly easy to dislodge from the vagina, and there is then a gush of blood flowing out.

**If the presenting part is not easy to dislodge,** try pushing it up a little vaginally. If this fails, stop for fear of damaging the urethra. Pass your fingers anterior to the presenting part, into the uterus, and feel for a rupture. If there is one, you will feel the inner surface of the abdominal wall. If you are convinced there is no rupture, proceed to vaginal delivery if the foetus has died (21.8).

**If the patient is sufficiently conscious to understand,** explain that you would like to tie the tubes. If she is not fit enough to understand, speak to the relatives. It is seldom necessary to tie tubes without permission. As a general rule, no woman who has had a ruptured uterus should ever become pregnant again. The only exception is an extraperitoneal (partial) rupture through a lower segment scar.

*CAUTION! Don't try to deliver the foetus before starting resuscitation, and beware of using any relaxational anaesthetic* because this will remove the tamponade effect of the abdominal wall muscles, increase shock, and perhaps extend the uterine tear.

#### EXPLORATION

Make a low midline incision (11.2), and insert a self-retaining retractor. You may find a lot of bleeding, and an obvious uterine rupture with, commonly, a dead foetus. The placenta may be lying free in the abdomen, but if it is still attached to the uterus, the foetus may still, albeit rarely, be alive, even if lying free in the abdominal cavity. A detached placenta means foetal death, wherever it is.

**If the foetus is lying free in the peritoneal cavity,** uterine rupture is complete. Extract the foetus and check if it is still alive.

**If the foetus is in the broad ligament,** divide it and extract the foetus.

**If the foetus is still in the uterus,** as with a posterior rupture, deliver it through a transverse incision in the lower segment, as for a standard Caesarean section.

At delivery, administer oxytocin. Suck out blood, meconium and liquor from the abdomen. Lower the head of the table and pack off the bowels. Deliver the empty uterus into the wound and inspect it, especially its posterior wall: there may be another tear. Find the edges of the tear along its whole length. Divide the round ligament (21-18) if this makes the tear easier to see. The rupture may:

- (1) be in the anterior wall of the uterus, often with a vertical extension at one end, making it L-shaped (21-17B).
- (2) extend into the bladder (21-17C).
- (3) extend longitudinally, along the lateral wall of the lower segment, from the fundus to the vagina, opening up the broad ligament and involving a uterine artery (21-17D), especially on the left.
- (4) extend, rarely, transversely across the posterior wall of the uterus (21-17E).
- (5) detach the uterus almost completely (21-17F).
- (6) keep to the upper segment through the scar of an old classical vertical Caesarean section (21-17G).
- (7) have torn one of the uterine pedicles right across.

Feel for the placenta and detach it from the uterus with your fingers. Try to get a tourniquet (a taut Foley catheter is the most readily available) around the base of the uterus, close to the cervix (22.11). Control bleeding from the uterus with #2 long-acting absorbable. Or, clamp the edges of the tear with several pairs of Green-Armytage forceps. Control bleeding from the broad ligament temporarily with pressure from a pack. If there is an extensive haematoma tracking up from the torn vessels on one side towards the kidney, evacuate the haematoma and ligate the vessels.

#### REPAIR OF A RUPTURED UTERUS (GRADE 3.1)

##### INDICATIONS

- (1) A rupture which is not too large.
- (2) A rupture with clean edges which are easy to see and are not too oedematous.
- (3) Little or no infection.
- (4) Relative inexperience.

##### CONTRAINDICATIONS

- (1) Extensive or multiple tears.
- (2) Edges which are very bruised and oedematous and not easy to define, especially a posterior rupture, or rupture extending down into the vagina.
- (3) Gross uterine infection.
- (4) Uncontrollable haemorrhage.

In these circumstances, a hysterectomy is preferable.

Start by defining the position of the uterine pedicles, the ovarian pedicles, and the round ligaments (21-18).

**If the tear extends into the cervix or lower segment**, reflect the bladder as for a lower segment Caesarean section. *Avoid the ureters*. Ask your assistant to pull the uterus forwards and to the opposite side. Lift the tube and ovary, to make the infundibulo-pelvic ligament, which carries the ovarian vessels, taut. Put your thumb and index finger on either side of this ligament, and slide them down.

Feel for the ureter as a hard round cord near the pelvic brim. From there trace it down to the injured area (23-20). Remove all clot. If there is a little bleeding, disregard it. If there is much, apply haemostats or transfixion sutures.

##### CAUTION!

- (1) Be sure to keep the bladder well away from the edges of the tear.
- (2) *Don't excise any tissue unless it is obviously dead.*

Start at the apex of the rupture; if convenient, hold it with a stay suture. Suture it as for Caesarean section, using 2 layers of continuous long-acting absorbable in a large (#2 or #3) half-circle round-bodied needle. You can suture a vertical tear going down to the cervix from below upwards, but sometimes the other way round is easier. Traction on the suture will help to bring the lower end into view. Don't worry if the inner layer has to be placed inside the uterus. Make the second layer an inverting continuous suture. If necessary, use extra sutures to close off the corners, or repair the vagina, usually anteriorly.

**If the rupture is lateral and has extended into the broad ligament**, open its peritoneal roof, and ligate the bleeding vessels. Control any oozing not stopped by compression with under-running sutures. *Avoid the ureter*. With one finger inside the broad ligament and another behind it, feel for the ureter; if necessary, pass a cloth tape under it to keep it out of the way. Start at the apex of the rupture and work downwards. Exert traction on the running suture to expose the depths of the tear. Stop before you reach the lower edge, so as to leave room for a drain from the broad ligament into the vagina. If there is much oozing, pack the broad ligament with a gauze bandage, bring it out of the vagina, and close the visceral peritoneum over it. Remove the pack 12h later.

*N.B. Don't forget to perform a tubal ligation (unless you have repaired a lower segment rupture, and the patient wishes for more children).*

#### PARTIAL HYSTERECTOMY FOR A RUPTURED UTERUS (GRADE 3.4)

Hysterectomy may be surprisingly easy when the tear is extensive and transverse, and the uterus almost completely detached.

##### INDICATIONS

- (1) Complicated rupture of the uterus.
- (2) Postpartum haemorrhage, which is not responding to treatment, and when a B-Lynch suture (22-13) or tying uterine arteries has failed to control bleeding.

##### METHOD

This is modified somewhat from elective hysterectomy (23.15). Having delivered the uterus from the abdomen, maintain traction on it with one hand, or insert a traction suture. Start by identifying: (1) the uterus and round ligaments, (2) the tubes and ovaries on both sides, (3) the infundibulo-pelvic ligaments (21-18), (4) the avascular area in each of the broad ligaments, (5) the lower segment, (6) the rectum, and especially (7) the ureters (23-21). You will find this difficult, because of the size of the uterus, and the disturbance to the normal anatomy caused by bruising and oedema, both near the tear and far from it.

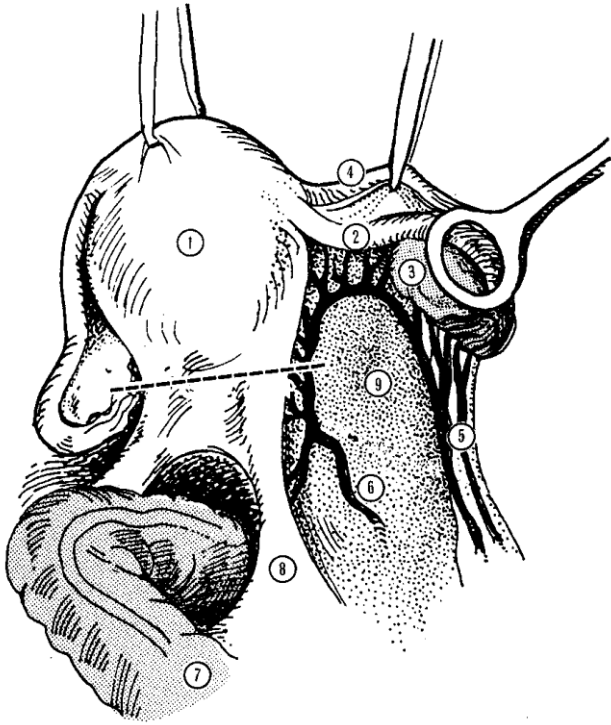
Deflect the bladder, and trace the ureters over the whole length of the operative field (23-22G). Find where they are in relation to the tear, in the distal part of their course. Find the tear and clamp the obvious bleeding points. Pull the uterus to the left, and divide the right round ligament between clamps about 2cm from it. This will open the anterior peritoneal leaf of the broad ligament. Enlarge this opening down towards the bladder. Lift the right tube and ovary with one hand, and push a finger of your other hand from behind through the avascular area in the broad ligament.

**CAUTION!** Leave the ovary and tube in place on one or both sides.

On the side on which you will remove the ovary, clamp the infundibulo-pelvic ligament between two artery forceps and divide it. On the other side, to retain the tube and ovary, clamp and divide the tube and the ovarian ligament near the uterus. If they are very thick and avascular, you may have to clamp and divide them in 2 steps.

Transfix the pedicles of the round ligaments and infundibulo-pelvic ligaments with #2 multifilament or absorbable.

## ANATOMY FOR HYSTERECTOMY



**Fig. 21-18 ANATOMY FOR EMERGENCY HYSTERECTOMY.** Posterior view of the unruptured uterus. It is tilted to the left and the adnexa (ovary and tube) have been lifted up to show them more clearly. (1) the body of the uterus. (2) the right Fallopian tube. (3) the ovary. (4) the round ligament. (5) the ovarian vessels running in the infundibulo-pelvic ligament which is being stretched. (6) the uterine vessels. (7) the rectum. (8) the sacrouterine ligament. (9) the avascular area in the broad ligament.

*Kindly contributed by Frits Driessen.*

Using the clamps that you have already applied, pull the uterus well up in the midline, and cut the peritoneum between the uterus and the bladder. Extend the incision laterally to meet the incisions you have made in the anterior leaves of the broad ligaments.

Push the bladder off the lower segment for 2-3cm with a swab on a holder. *Pushing it further down can cause bleeding.* If the rupture is anterior, put its edge on the stretch before you separate off the bladder.

Now expose the back of the lower segment by pulling the uterus forwards over the symphysis pubis. Divide the peritoneum over the back of the lower segment at the same level as you did anteriorly. Extend the incisions laterally to join the openings in the broad ligament. Push the lower peritoneum off the lower segment with a swab on a holder; or, if this is difficult, cut it loose with scissors.

On either side of the uterus there will now be a bundle of loose connective tissue containing the uterine vessels. If you need to see them more clearly, strip down the peritoneum off the broad ligaments. Pull the uterus to the right and clamp the uterine vessels with strong Kocher forceps, just above the level where the bladder is still attached to the lower segment.

**CAUTION!** Make sure the points of the forceps are close to the uterus or even a little in its wall.

Place a 2<sup>nd</sup> clamp inside the 1<sup>st</sup>, and cut the uterine vessels between them. Tie and transfix the pedicle. Use a double transfixion ligature because of its width, and then do the same thing on the other side.

Excise the uterus through its lower segment, just above the level of the cut uterine vessels. Have artery forceps ready to pick up the cut edge of the lower segment, before it disappears in the depth of the pelvis. Clamp any bleeding vessels.

**If the tear extends across the lower segment,** it will probably serve as the line of demarcation to remove the uterus. Examine the edge and remove any very oedematous and bruised tissue, again first checking the position of the ureters.

**If there is a downward tear in the cervix,** repair this now, after making sure that the bladder and ureters are well out of the way. Alternatively, perform a total hysterectomy, and remove the cervix.

Suture the anterior and posterior walls of the lower segment with figure-of-8 sutures, being sure to include the angles on each side, because these bleed. If there are signs of infection, leave the centre open so that you can insert a drain; otherwise close it. The pelvis should now be nearly dry. Tie any remaining bleeding vessels.

**If the broad ligaments are oozing,** apply compression and perhaps, if oozing persists, place a drain near them and bring it out through the vagina.

Close the pelvic peritoneum with a continuous suture. Start on the left at the pedicle of the infundibulo-pelvic ligament, and suture the anterior edge of the peritoneum to the posterior edge, placing all vascular pedicles under it. Let the remaining ovary and tube hang freely in the pelvis.

Clean and wash the peritoneum with at least 2L warm water. Close the abdominal wall (11.8).

### (e) Difficulties with rupture of the uterus

**If the bladder is torn,** its wall near the opening is usually stuck to the lower segment, and needs mobilizing before you can repair it. You may find that the bladder is so torn that it lies flat like a handkerchief.

Use Allis forceps or Babcock clamps to stretch the wall of the bladder and the lower segment. Suck away the blood. Separate the bladder from the lower segment with a 'swab on a stick', or with scissors. Gently dissect it off the lower segment, taking care not to make the tear any bigger. Free the bladder wall round the opening for 1-2cm.

Close the opening in the bladder with 2 layers of 2/0 continuous long-acting absorbable. Put the first layer through the full thickness of the bladder wall, but just submucosal if possible. If this is difficult, include the mucosa. Use the 2<sup>nd</sup> layer to invert the 1<sup>st</sup> one. Insert an indwelling catheter and maintain open drainage for 10-14 days.

Unfortunately, complete closure of the bladder is often impossible; its edges are usually thin and necrotic, so that a fistula often follows. In this case, re-insert the catheter and wait 3 months.

**If complete closure of the torn bladder is impossible**, because there is much pressure necrosis, or the opening extends far down into the urethra, you may have to close the bladder over a wide-bore suprapubic tube. If a vesico-uterine fistula develops, arrange for its repair later.

**If you think that you have caught the ureter in a suture**, unpick it; usually there is no permanent harm.

*It is better to be safe than sorry!* A dye test (21.11) may help. Otherwise a nephrostomy will bail you out.

**If there is anaemia after delivery with a boggy pelvic swelling and deviation of the uterus**, there is probably a PELVIC HAEMATOMA. This is really a rupture of the uterus which has bled into the broad ligament instead of into the peritoneal cavity (21-16A,C). If the patient presents <24h after delivery, perform a laparotomy and explore and repair the tear.

## 21.18 Vesico-vaginal fistula (VVF)

Fistulae are usually the result of:

- (1) obstructed labour in a young primigravida (21.4).
- (2) unskilled Caesarean section.
- (3) rupture of the uterus into the bladder, especially through the scar of a previous Caesarean section.
- (4) traumatic vaginal delivery (especially with Kielland's forceps).
- (5) vaginal trauma (by assault or FGM).

### MECHANISM OF VESICO-VAGINAL FISTULA FORMATION

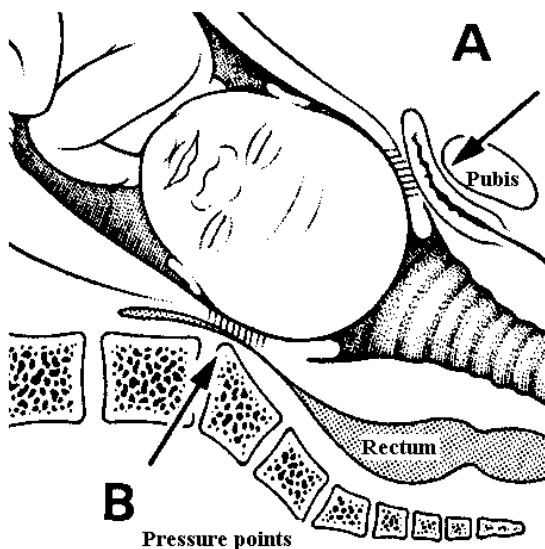


Fig. 21-19. THE MECHANISM OF FISTULA FORMATION DUE TO OBSTRUCTED LABOUR. A, pressure against the pubis causing necrosis of the vagina and posterior bladder wall. B, pressure against the sacrum causing necrosis of the vaginal and anterior rectal wall.

Fistulae result as the unrelieved obstructed foetal head impacts against the back of the pubis, especially in very young girls (<16yrs). The head cannot move further, resulting in pressure necrosis of the vaginal and adjacent bladder wall (21-19A). If the pressure of the head is exerted posteriorly (21-19B), the result may be a recto-vaginal fistula (RVF, 21.19).

A vesico-vaginal fistula (VVF) means uncontrollable urinary incontinence for the young woman, usually stillbirth, and often also infertility subsequently. After the catastrophe of losing her baby in childbirth, the young mother is often thrown out of the home because she cannot have sexual intercourse, is incontinent and smelly. She is rarely able to find a job, becomes depressed, lies curled up in the corner of a house where she can find lodging, develops contractures and pressure sores, and dies neglected.

There are estimated to be 3 million untreated VVF patients in Africa alone. In Ethiopia there are just under 10,000 new cases per year, and the Fistula Hospital in that country has gained a well-deserved worldwide reputation for the treatment of such fistulae. If you can get training there (or at another special centre), you will not regret it, but don't think that all VVF must be handled at a specialist centre: there are too many fistula victims for this to be feasible.

They have a reputation of being impossibly difficult to repair, but this is not so for at least 25% of cases. Certainly, though, your best chance of success is in the first attempt; so, don't perform this operation unless you are reasonably experienced, or have gone to a special training centre, preferably several times in between increasing your own experience. The important thing is to be able to recognize which is the easier fistula, and which the complicated. You are advised to leave the latter, and the second or subsequent repairs, to experts.

Even then, experts who tackle every type of case will only achieve 75% success, meaning total continence (*i.e.* absence of stress incontinence, which is often severe). Anyone who claims a 100% success rate either has not done many, has selected easier cases, or has not done a proper follow-up.

*N.B.* A *gracilis* flap is easy to learn and can help out in many difficulties: try to get an expert to show you how to do this!

Fistula surgery for easier cases does *not* need special instruments or equipment; good post-operative nursing care is, however, very important but *not* complicated and you can achieve success even when you have not done such surgery previously.

These cases are immensely rewarding, because you can transform the life of a young woman from existence as an outcast; indeed one of the most senior VVF surgeons in Addis Ababa started off as an outcast VVF patient!

#### (a) Site of the fistula

The area where pressure necrosis occurs will be where the fistula results. Most commonly this is the urethro-vesical junction, but other sites can occur together or individually: juxta-urethral, mid-vaginal, juxta-cervical and intra-cervical.

## SITES OF VESICO-VAGINAL FISTULAE

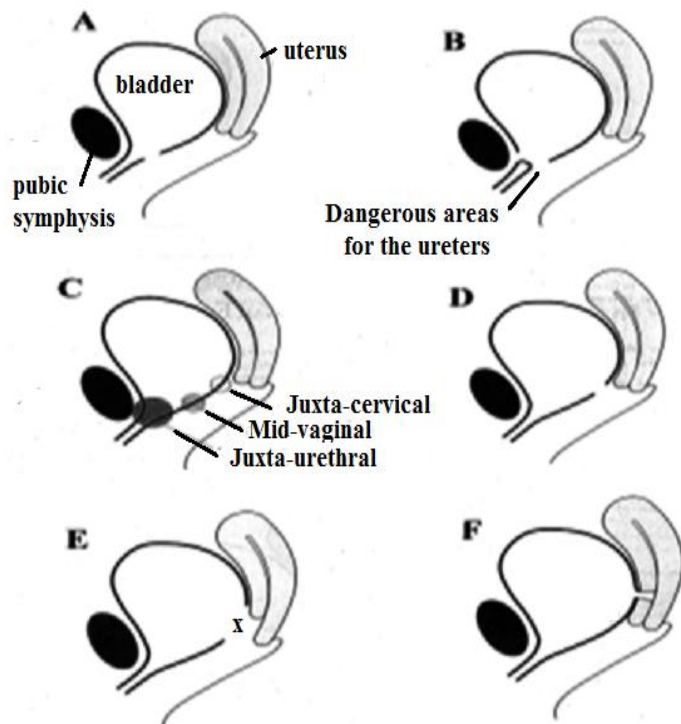


Fig. 21-20 SITES OF VESICO-VAGINAL FISTULAE.

A, simple juxta-urethral. B, extensive juxta-urethral with a gap between (stenosed) urethra and bladder. C, mid-vaginal. D, simple juxta-cervical. E, complex juxta-cervical involving the anterior cervix. F, intra-cervical. (x) is the site of the ureteric orifice.

After Hancock B, *First Steps in Vesico-Vaginal Fistula Repair*, RSM, London 2005, Figs 2-7 p.4-6.

The first is the most common: if ischaemia is mild, a small hole is produced (21-20A); if ischaemia is prolonged, the defect may be circumferential and result in separation of the urethra, which becomes closed off, from the bladder itself (21-20B). The mid-vaginal fistulae are less common but easy to repair, unless they extend to the cervix (21-20C). The juxta-cervical fistula (21-20D) usually follows a vertical tear in the lower segment at Caesarean section (21.10): the defect may include the anterior cervix, and encroach onto the ureteric orifice (21-20E). The intra-cervical fistula may be due to prolonged pushing against an incompletely dilated cervix, or due to iatrogenic injury at Caesarean section (21-20F).

### (b) Features of the fistula

Apart from their position, take note of their **size**: tiny (admitting only a probe) to large (>3cm, usually involving most of the anterior vaginal wall and the complete vesico-urethral junction). Occasionally the fistula may be truly extensive, extending to the anterior bladder wall, and exposing the bare bone of the back of the pubis. The ureters may even be draining freely outside the bladder!

Take note of the amount of **scar tissue**: if you find extensive scarring, leave the case to an experienced surgeon.

Note the remaining **length of the urethra**: the shorter it is and the more scar tissue that needs to be removed, the bigger the risk of stress incontinence.

### (c) Prophylaxis

**At Caesarean section**, take care to dissect the bladder well down off the lower segment prior to incising the uterus.

If the head is deeply impacted in the pelvis, get an assistant to push from below, rather than inserting your hand between the foetal head and the lower segment.

**After Caesarean section**, take care when suturing lower segment tears, and always ask yourself if you have not inadvertently picked up the bladder.

Leave a urinary catheter *in situ* for at least 10 days after a Caesarean section performed for prolonged obstructed labour.

**At follow-up**, if urine is leaking, leave a Ch18 urinary catheter *in situ* for 4-6wks, making sure you inflate the balloon only with a maximum of 10ml, and the balloon is not inflated in the urethra. Let the urine drain freely. Recommend sitz baths to wash the perineum, a high-protein diet with haematinics, copious drinking of fluids to 5L/day, good mobilization, and abstinence from sexual intercourse for 3 months.

### (d) History

(1) **Age and parity** (some patients still achieve pregnancy after developing a fistula after a Caesarean section).

(2) **Incontinence**. Check if the patient is wet all the time: if she is dry at night, a fistula is unlikely. Ask about faecal as well as urinary incontinence. They may be separate or combined.

(3) **Amenorrhoea**. Ask about menstruation: it often stops after traumatic childbirth, but may suggest a hysterectomy about which the patient was never informed.

(4) **Delivery**. Ask if labour was prolonged, delivery difficult and traumatic. Ask if it was at home, in a clinic or at hospital. Note whether a Caesarean section was performed, and if so, how many times.

(5) **Previous surgery**. Ask sympathetically if previous attempts at repair have been made: remember patients may try to hide this, fearing they may be turned away.

(6) **Neurological deficit**. Look especially for a foot drop, even if partially recovered.

### (e) Examination

(1) **General**. Note malnutrition, state of hydration (many patients drink little in order to reduce their wetness), anaemia and the psychological state.

(2) **Dermatitis and pressure sores** (34.16). Look for an obvious urinary leak and signs of dermatitis (discoloured darkened or reddened skin around the perineum) and examine pressure points. If you cannot see any wetness, ask the patient to drink plenty of water and re-examine her after 1h. Get the patient to cough if you still cannot visualize any wetness.

(3) **Urethral orifice**. Is it destroyed or stenosed?

(4) **Vagina**. Perform a gentle digital examination and then, if necessary, with a Sims' speculum. You may find it easier in theatre in the lithotomy position with a good light, but you *don't need a GA*. Is the vagina stenosed?

The lateral or posterior surfaces may feel fibrous, or the whole vagina narrowed. Is there a palpable defect anteriorly? If so, where is it in relation to the urethra and cervix? Are the margins of the fistula soft and supple, or firm, or even fixed to the pubic bone? Can you identify the cervix? Does it feel normal? Is the vagina shortened?

(5) **Ureter.** If you suspect ureteric damage after Caesarean section, ask the patient to empty her bladder and then insert a dry swab high in the vagina. Get her to drink water, walk about and then 30mins later, remove the swab, looking for wetness.

(6) **Ano-rectum.** Examine for anal sphincter function: this is often impaired after delivery. Look for evidence of urine flowing out of the anus.

#### (f) Dye test

Use *dilute* methylene blue or gentian violet: too concentrated dye will colour everything, making interpretation impossible. Introduce a urinary catheter and inflate the balloon. Place 3 moist swabs well up in the vagina; then insert 50ml slowly into the catheter. Remove the swabs gently one by one. A fistula is confirmed if the 2<sup>nd</sup> or 3<sup>rd</sup> but not the 1<sup>st</sup> swab is discoloured with dye.

**If you don't see any swab stained blue**, repeat the test with 200ml after leaving the dye 20mins in the bladder. If this 2<sup>nd</sup> test is -ve, suspect a uretero-vaginal fistula (see above). If the 3<sup>rd</sup> gauze is wet but not blue, suspect a ureteric fistula (21.11).

**If, after you have removed the catheter, leaving the dye inside, the colour dribbles out**, especially on coughing, this indicates stress incontinence, which you should treat with pelvic floor exercises, or 12wks of continuous catheter draining if there is an atonic bladder with overflow after delivery.

#### (g) Selection of cases

Select a straightforward case for your first attempts at repair; you will get a good reputation through success, so *don't attempt any difficult cases until you have considerable experience*. You will do your patients and your reputation no good by attempting difficult cases and failing. *Don't waste time with futile investigations and treatment*: if you cannot treat a patient, refer her early.

#### (h) Contraindications

##### *Don't attempt:*

- (1) Complex fistulae, including those you have difficulty visualizing, and recto-vaginal fistulae, except in special circumstances (21.19).
- (2) Cases where the urethra is completely detached.
- (3) Cases where there is considerable scarring.
- (4) Surgery in grossly malnourished, anaemic or untreated HIV+ve patients.
- (5) A case where you are uncertain how to proceed.

#### (i) Preparation

Explain clearly what the patient is to expect, especially the length of time she will be in hospital and how long she may need a urinary catheter, and how long she may need to abstain from sexual intercourse.

Make sure the patient is well hydrated from the moment you take the decision to operate. She should be drinking 6-8L/day before operation. Make sure she gets a high-protein diet, iron and folate. Stop fluids only 4h before anaesthesia. *You should see urine dripping when she stands with legs apart.*

*There is no indication for pre-operative antibiotics.*

Make sure the rectum is empty by getting the patient to go to the toilet just before theatre, or administering an enema the evening before.

*N.B. It is no good doing this just before theatre because the perineum will be contaminated.*

#### EQUIPMENT

No special equipment is necessary: you will need a self-retaining weighted Auvard speculum, good-quality dissecting scissors, toothed dissecting forceps, Allis tissue forceps, artery forceps, a metal catheter, a small probe, towel clips and a #15 blade.

Sharply curved Thorek scissors, a sharp Deschamps aneurysm needle and long vaginal instruments are a great help.

Long-acting absorbable sutures are ideal: *don't use non-absorbable*. Half-circle 25mm round-bodied needles are best, though J-shaped needles are very useful in more difficult cases.

You will need an operating table which tilts and has shoulder rests for more complex cases. A headlight is very useful; if this is missing, turn the table to face the bright sunshine!

#### (j) Method of VVF repair (GRADE 3.3)

Place the patient, with the buttocks well over the end of the table, in the exaggerated lithotomy position with legs flexed and slightly abducted. Make sure *your* position is comfortable, that your seat is not too high or the operating table too low.

Suture the labia to the thighs, and cover the anus with a swab (21-21A), or insert a temporary purse-string suture to close it if faecal leakage is troublesome.

Record the size and position of the fistula. Estimate the distance from the external urethral orifice to the distal fistula margin (ideally 3-4cm), and that from the proximal fistula margin to the cervix (ideally >4cm) (21-21B). The nearer the fistula is to the cervix, the greater is the danger to the ureters.

Only operate juxta-cervical fistulae in multiparous women where you can easily pull the cervix downwards.

Pass artery forceps or a metal catheter through the urethra, holding it to point forwards to expose the fistula clearly (21-21C). Check if the urethra is detached from the bladder: in this case, leave it for an expert.

Administer gentamicin 160mg IV plus metronidazole 500mg if there has been faecal contamination. Check with ultrasound if there are stones within the bladder, and estimate the size.

Infiltrate the tissues between the vagina and bladder with dilute (1:200,000) adrenaline solution (21-21D).

Whilst steadying the anterior vaginal wall with the forceps passed through the urethral orifice, lift up the mucosa over the urethra with an Allis forceps and incise in the posterior margin of the fistula through the vagina (21-21E).

## VESICO-VAGINAL FISTULA

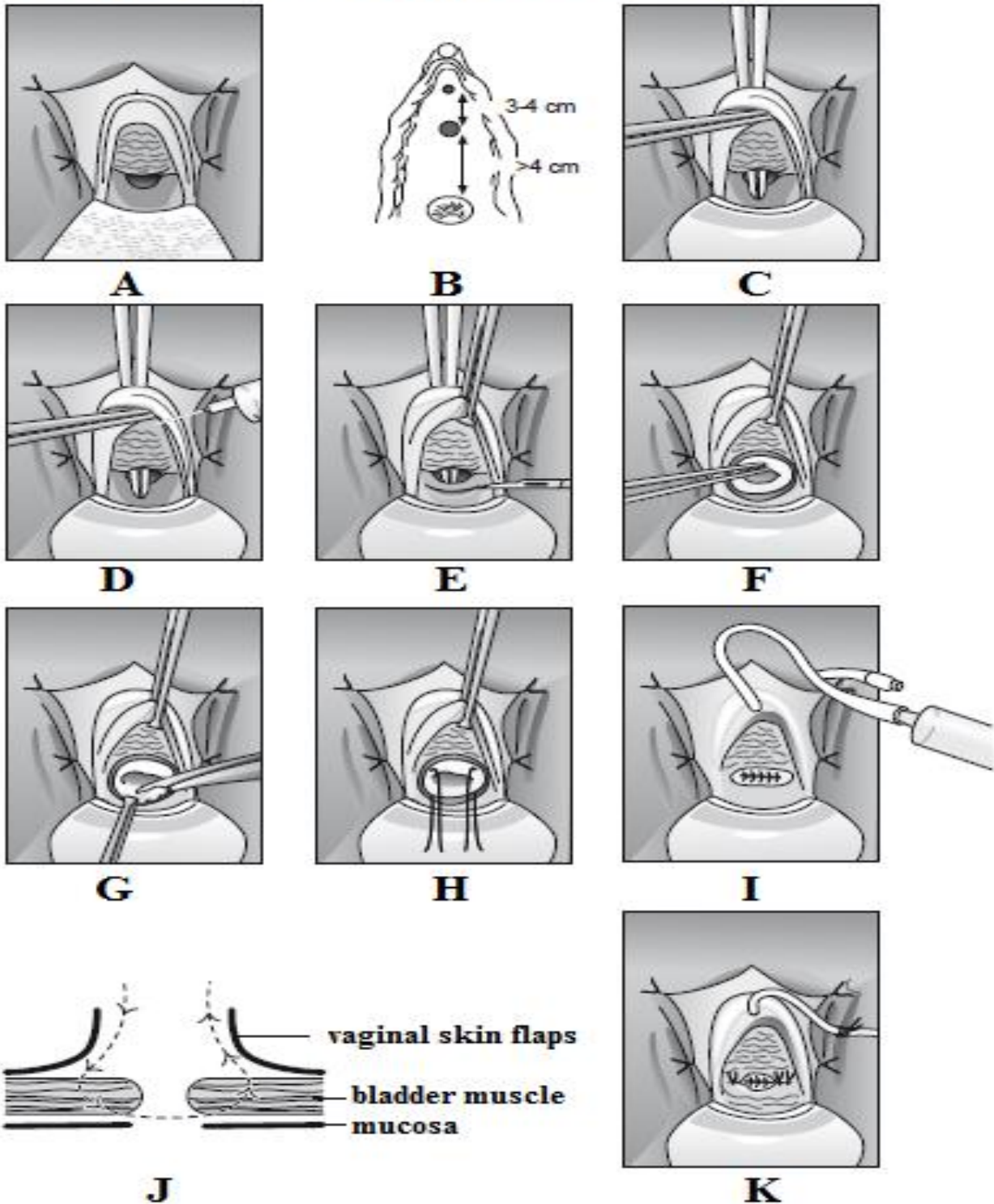


Fig. 21-21 SIMPLE VESICO-VAGINAL FISTULA REPAIR.

A, suture the labia to the thighs and cover the anus. B, record the size of the fistula and its distance from the external urethral orifice and cervix. C, insert artery forceps through the urethral orifice to expose the fistula. D, infiltrate around the fistula orifice with 1:200,000 adrenaline solution. E, steady the anterior vaginal wall with the forceps passed through the urethra and lift up the mucosa around the urethra with Allis forceps. Identify the correct plane between vagina and bladder, and mobilize the posterior margin, keeping at least 1cm from the fistula orifice. F, remove the artery forceps inside the urethra. Start the anterior dissection with a small incision vertically, and continue laterally.

G, trim away any vaginal mucosa and scar tissue at the fistula margin. H, insert 2 corner sutures through the freshened margins of the fistula. I, complete the closure with 3-4 sutures, c.4mm apart, taking big bites of the full thickness of the bladder muscle, excluding the mucosa. Then insert a catheter in the urethra and introduce 50ml of dilute methylene blue dye. J, if there is no leak, close the vagina with interrupted everting mattress sutures. K, then fix the catheter to the labium, and pack the vagina with a betadimized swab.

After Hancock B, *First Steps in Vesico-Vaginal Fistula Repair*, RSM, London 2005, Figs 31,32,33a,c-h,k,o,q,t. p.25-28.

Identify the correct plane between vagina and bladder and continue to dissect round to the sides so that you mobilize at least 1cm beyond the fistula hole (21-21F). Start the anterior dissection with a little extension vertically towards the urethra and complete it right round; then tie the right and left antero-lateral flaps to the labia to improve the exposure of the fistula. *Don't use diathermy.* Trim away with scissors any vaginal mucosa and scar tissue (this should be minimal) at the fistula margin (21-21G).

Now you have freshened up and exposed the margins of the fistula, you can start closure from the corners (21-21H). Insert 2 sutures and complete the repair with interrupted big bites taking in the full thickness of the bladder muscle, but not the bladder mucosa (21-21I,J). Remove the forceps in the urethra and insert a catheter, and perform a dye test (21-21K) with 50ml of dilute solution. Press over the abdomen or ask the patient to cough to see if there is any discolouration. If there is a leak through the suture line, inset another one or two sutures, and re-test. Exclude the presence of a 2<sup>nd</sup>, unsuspected, fistula higher up.

Finally, close the vagina with interrupted everting mattress sutures, and fix the catheter *in situ* with a suture to the labium. Place a betadinized pack gently in the vagina.

#### **(k) Difficulties with simple VVF repair**

**If exposure is poor**, perform an episiotomy, on both sides, if necessary (and remember to repair them at the end of the operation).

**If there is necrotic sloughy tissue**, debride this adequately and review the situation when all the tissues are clean and fresh. This is likely, however, to become a complex fistula.

**If the urethra is stenosed**, try to dilate it with sounds. Remember you will need more generous exposure of the fistula, and need to excise scar tissue. You may find the stenosis recurs and needs regular dilation, so keep a careful follow-up.

**If you find bladder stones**, unless the stone is small, or comes out easily through the fistula, abandon the VVF repair, and proceed to cystolithotomy (27.16). Schedule the VVF repair at least 2wks later.

**If you suspect the ureter to be damaged**, you are likely to be dealing with a juxta-cervical fistula, which is a matter for an expert.

**If your operation is taking >1h**, you are either tackling too complex a fistula, or there is some difficulty with your technique. Consult this manual and get help.

#### **(l) Post-operative care**

You may have performed marvellous surgery, only for it to be ruined by poor nursing care; so make sure, before you embark on VVF repairs, that you involve all your nursing staff and explain what is needed and why. Keep a simple record of patients on their beds: *measuring urine output is unnecessary.*

**(1) The aim is that the patient is drinking freely, draining urine freely and free to mobilize without being wet.** *The catheter must never block:* if this happens, urine will emerge alongside the tube or even leak through your well-sutured repair and re-create the fistula. The problem about drainage bags is that they can fill up (quickly if the patient is drinking well) and fall on the floor, or cause traction on the catheter when the patient turns in bed, or overfill and cause back-pressure, or twist and become blocked. The easiest solution is connecting the catheter to a straight plastic tube that drains freely into a basin or bucket: this has the advantage that you can readily see if urine is dripping freely from the tube.

**If the catheter blocks**, *i.e. you no longer see urine dripping from the tube, and the patient is wet or has a full bladder*, act immediately: untwist the catheter, unkink the tubing (or replace it, if it is full of debris), gently irrigate the catheter with a bladder syringe. If this does not make urine flow, replace the catheter.

*Urine will not flow if the patient is not drinking!* So make sure she drinks 5L/day, because concentrated urine flows poorly and is susceptible to becoming infected. The urine should be almost colourless.

**If the patient is wet**, exclude a blocked catheter. Check if urine is leaking alongside the tube during bladder irrigation: this may suggest urethral dysfunction. Perform a dye test to check your repair or look for a second (missed) fistula.

**(2) Wash the perineum twice daily**, especially where the catheter emerges from the urethra.

**(3) Remove the vaginal pack** after 48h.

**(4) Mobilize the patient**, carrying a bucket to drain her urine.

**(5) Remove the catheter** after 12-14 days after you have confirmed that a dye test shows no leak. Encourage the patient to pass urine every 2h and then increase the interval gradually as bladder tone recovers. *Don't clamp and unclamp the catheter:* this all too frequently leads to disaster!

**(6) Before discharge:** wait 48h after removing the catheter. Check if the patient is dry; if not, perform a dye test. If it is +ve, all is not lost, though an early leak suggests a worse prognosis. Keep the catheter *in situ* a further 4wks if more urine drains through the catheter than the vagina. Monitor to see if the leak is reducing. Lying in the prone position allows the catheter tip to rest free from the fistula.

**(7) General advice.** Insist on abstinence from sexual intercourse for 3 months. Advise on tubal ligation or contraceptives. Further delivery must be by Caesarean section. Recommend a high fluid intake to prevent infection and development of urinary stones. Persuade patients to come for regular follow-up so you can check whether a late leak or urethral stenosis develops, or stress incontinence persists, and you can do an audit of your activity. In these latter cases, try to get help from an expert.

### 21.19 Recto-vaginal fistula (RVF)

Fistulae between the rectum and the vagina (RVF) are less common than those between the bladder and the vagina (VVF). If there is a large VVF, there may also be an RVF, also when there is pressure exerted posteriorly (21-19B) on account of unrelieved obstructed labour. An RVF may occur, rarely, without a VVF.

The diagnosis is obvious: faeces start to leak through the vagina.

Sometimes, especially in babies but also in adults, an RVF may occur spontaneously due to HIV disease (26.2). It may also occur as a result of syphilis, lymphogranuloma venereum and other venereal diseases; and also due to carcinoma, itself HIV-related.

To distinguish an RVF from a 3<sup>rd</sup> degree vaginal tear, clean away the faeces, and look at the perineum. If the site of the fistula is not obvious on inspection, digital palpation or proctoscopy, proceed to sigmoidoscopy. You might need to use ketamine to do this, remembering to position the patient *before* administering the drug. Note the position of the fistula, the degree of inflammation present, and its size.

Repair of an RVF is *not for the beginner*. Chances of success are better early rather than late, providing the initial inflammation has settled, and they are significantly improved if you can divert the faecal stream beforehand.

This will mean performing a defunctioning loop colostomy (11.6), which the patient may not tolerate well, and may think more debilitating than the RVF itself: so be cautious before inflicting this on a patient and make sure you explain carefully what it entails. It is only really worthwhile if you have arranged RVF repair beforehand, and you can fashion the colostomy as a staged procedure.

It is possible to treat low fistulae successfully with a seton (26.3), but be prepared for it to take a long time till healing results.