

## 24 The breast

### 24.1 Introduction

There are two kinds of inflammatory lesion in the breast:

- (1) Acute abscesses, which mostly occur during lactation, but may be a sign of HIV disease in a non-lactating woman, and occasionally occur during pregnancy (6.13).
- (2) A varied group of subacute or chronic infections, including tuberculosis, which you need to distinguish from tumours of the breast.

### 24.2 Breast lumps

Most breast diseases make the breast lumpy. Sorting out these lumps can be difficult. The important decision is whether or not a patient has a carcinoma.

Consider all lumps in the breast as malignant unless you are *sure* they are benign. No woman should be left with a lump in the breast if she can have it removed by aspirating a cyst or by excision. After the menopause, lumps in the breast are more likely to be malignant.

A normal breast is slightly and uniformly nodular, especially before the menopause; this nodularity is maximal before menses. At the menopause the nodularity becomes less, and more fat is deposited.

The classical signs of malignancy are:

- (1) fixation of the lump to the skin or to *pectoralis major* muscle,
- (2) enlarged nodes in the axilla,
- (3) 'peau d'orange' (24-1),
- (4) disease of the nipple (resembling eczema, unrelated to Paget's disease of bone).

#### FUNGATING BREAST TUMOURS

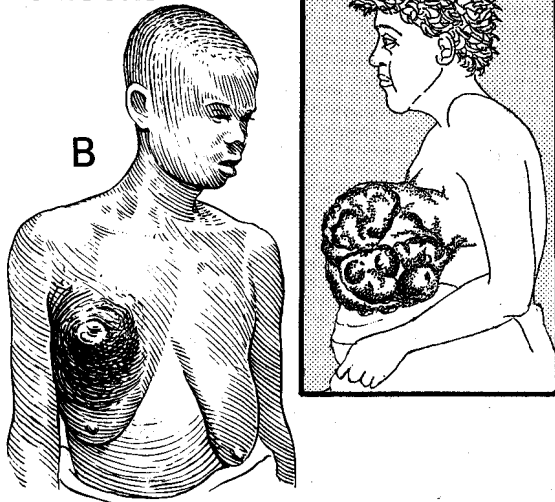


Fig. 24-1 TWO FUNGATING TUMOURS OF THE BREAST. Unfortunately, many patients may present late when their tumours are already fungating like this. A, phylloides tumour (uncommon: see below). B, fungating carcinoma (very common); note the 'peau d'orange' appearance of the breast skin, resembling an orange peel, and the malignant ulcer.

The absence of these signs does NOT exclude carcinoma. Their presence increases the chances of it, but they are not confirmatory, because they can also be caused by tuberculosis or fat necrosis.

(a) **History.** How long have the symptoms been present? Is there any pain? Is it associated with menses? If there is pain, is it in one breast or both? Is there any discharge from the nipple? Is it watery, bloody, or like thin pus?

(b) **Inspection.** Ask for permission, and if you are male, ensure you have a chaperone present, *i.e.* a person who acts as a witness during any intimate examination. First examine the patient sitting up undressed to the waist, then lying down. Examine both breasts, starting with the normal breast, regional lymph nodes, chest, liver, and the skeleton.

(1) The nipples for position, retraction, and cracking.

(2) The areolae for pigmentation, swelling of Montgomery's tubercles (the external orifices of the areolar glands), a rash or eczema ('Paget's disease').

(3) The skin for prominent veins, sinuses, ulcers, and 'peau d'orange' (orange-peel skin), which is thickening due to lymphoedema under the skin.

(c) **Palpation**

(1) Each of the 4 quadrants, then the subareolar area.

(2) For lumps, note their size and site, and whether they are discrete and well-defined, single or multiple; also their consistency, warmth, tenderness, mobility, and surface.

(3) For tethering to the skin, or to *pectoralis major*. Test for this by asking the patient to place her open hand on her waist, and then ask her to press downwards to tense this muscle, while you try to move the lump.

(4) With your finger and thumb behind each nipple, and look for any discharge.

(5) The axillary nodes: medial (pectoral), lateral, anterior and posterior. Note their number and size, and if they are fixed to the skin, or to deep structures. Although the number is actually not so relevant, the presence of a metastasis in the sentinel node is, *i.e.* the first 'guard' node where lymph spreads.

**If you are not sure if there is a lump or not**, examine it again 2 or 6wks later, at the opposite phase of the menstrual cycle. Write down your findings clearly on the 1<sup>st</sup> occasion!

(d) **Diagnosing cysts in the breast**

**If a lump is deep and spherical in all directions**, it is probably a cyst; it may or may not be fluctuant, and is usually benign. Distinguish cysts from solid lumps by aspiration with a wide-bore needle, or using ultrasound.

(1) **Fibrocystic disease** (or fibroadenosis) is the commonest cause, especially between 25-50yrs, and makes both breasts abnormally granular, usually with premenstrual pain and some tenderness. One or more of these granular areas may be sufficiently obvious to be palpable as a cyst, and there may be a clear discharge from the nipple; rarely, this is blood-stained.

(2) **Breast abscess** may present by finding pus on aspiration, especially in HIV disease, when there is not much inflammatory response: this still needs drainage (6.13).

Other, rarer causes are:

(3) **Galactocele**: a residual milk-containing cyst, the contents of which may solidify.

(4) **Intracystic papilliferous carcinoma**: aspiration yields blood-stained fluid, and does not make the cyst disappear entirely.

(5) **Carcinoma of the breast with colloid degeneration**: aspiration yields only a little thick fluid, and does not make the cyst disappear.

(6) **Cystadenoma phylloides**: a rapidly growing benign giant fibroadenoma, which becomes partly necrotic and fluctuant. The skin over it may ulcerate, but is not infiltrated.

(7) **Hydatid cyst** (15.12): a possibility in endemic areas: look for cysts elsewhere, especially in the liver.

#### (e) Diagnosing solid lumps in the breast

Careful palpation will give you a good idea of the nature of a lump, but even experts are misled. These are the classic features:

(1) An '**antibioma**' is the result of treating an abscess with antibiotics, and not draining it. The lump is usually tender, but not always so. It is indurated but smooth; aspiration may produce pus. There may be tender axillary nodes and even '*peau d'orange*'.

(2) A **fibroadenoma** (common) is a smooth, well-defined, usually painless firm lump 2-5cm in diameter (but which may be much larger) that moves freely in the breast (a 'breast mouse'). There may be several fibroadenomas in one or both breasts (24-2). From its firmness such a lump could still be a carcinoma; mobility is the important sign, so is lobulation. Be careful to distinguish a fibroadenoma, which is an isolated lump, from an area of nodularity due to fibroadenosis, which is a different disease, featuring pain and nodularity increasing before and during menstruation. The patient is almost always 15-45yrs, and usually 18-30yrs.

(3) A **giant fibroadenoma** (uncommon) presents as a large breast filled with a large, deeply lying, firm, smooth, lumpy mass (24-6). If it is untreated, it may fungate (24-1) or develop into a sarcoma.

(4) A **neurofibroma** (rare) feels hard, like a fibroadenoma, but may be soft, and may be one of many similar tumours elsewhere (neurofibromatosis).

(5) A **lipoma** (uncommon) feels like breast tissue, but has an indistinct outline separating it from the surrounding normal breast.

**If there is a serous, dark or blood-stained nipple discharge**, it may herald the presence of an intraduct papilloma, adenoma

or carcinoma. If a lump is palpable, it is more likely to be a carcinoma. The prognosis after local resection is usually good.

(6) An **organizing haematoma** or **fat necrosis** may occur after trauma as fairly discrete, mildly tender lumps.

(7) **Tuberculosis** is less often seen in the breast than in the axillary lymph nodes (17.4) but you should suspect it if there are signs of HIV disease; it closely resembles carcinoma. Suspect tuberculosis if there is a sinus and the swelling and '*peau d'orange*' are generalized. The mass is painless, and may be attached to the skin or the muscles of the chest wall. The nipple may be retracted. Look for signs of tuberculosis elsewhere. The breast itself may be swollen due to enlargement of axillary nodes, and may not be the seat of the primary pathology.

(8) A **carcinoma** (usually squamous) may be ductal or lobular (both common). It is a hard, painless, fixed mass often with tethering of the skin or attachment to *pectoralis major*, overlying localized '*peau d'orange*' and fungation of tumour through the skin.

(9) **Mastitis carcinomatosa** (rare) is a highly malignant form of carcinoma seen during pregnancy. It is more generalized, and more like inflammation, or Burkitt's lymphoma, than the hard, fixed mass of a typical carcinoma.

(10) **Burkitt's lymphoma** (17.6) is rare, usually bilateral, occurring at 14-25yrs. It may simulate mastitis carcinomatosa, but is not particularly associated with pregnancy. The skin is stretched, and may ulcerate; there are usually other tumours elsewhere.

#### (f) Managing cysts in the breast

First exclude a hydatid cyst (if that is at all likely), by looking for hydatid cysts (15.12) elsewhere.

Aspirate the cyst with a wide-bore needle as completely as you can.

**If the fluid you aspirate is blood-stained**, explore and excise the lump.

**If a lump remains after you have aspirated the cyst**, excise the lump completely.

**If the fluid is clear and the lump disappears**, as is usual in fibrocystic disease (the commonest cause), no further treatment is necessary. Do a regular follow-up. If the cyst appears again, or other cysts appear, aspirate again. If at any time lumps don't disappear, remove them as above.

#### (g) Managing solid lumps in the breast

Consider any lump as potentially malignant, until you are sure it is benign.

**If it is an obvious fibroadenoma**, shell it out completely unless it is <1cm in diameter, when you can review it at 3-monthly intervals (24-5).

## THE PATHOLOGY OF A FIBROADENOMA

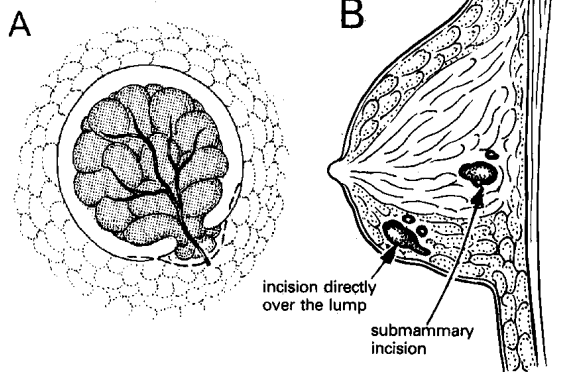


Fig. 24-2 PATHOLOGY OF A FIBROADENOMA.

A, tumour is attached to the capsule by a stalk carrying its blood supply. Sometimes the tumour extends into the capsule near the stalk. B, remove a superficial fibroadenoma by incising directly over it. If it is deeper, a submammary incision may be best.

After Rob C. Smith R. *Operative Surgery Vol 1, Butterworth 2<sup>nd</sup> ed 1981 with kind permission.*

**If you are not sure but think it is benign**, remove it completely together with a 2cm margin of tissue around the lump and send it for histology. *Don't try to perform a trucut biopsy on a small lump, especially if it is mobile*; you may well miss it or just biopsy unrepresentative tissue!

**If there is a lump and a discharge from the nipple**, it is likely to be a duct papilloma, adenoma or carcinoma. Excise the duct involved (24-7), as well as the lump with a 2cm margin.

**If you suspect tuberculosis**, get an aspirate for AAFB (or PCR) from the breast and axillary nodes. Otherwise do an open biopsy; it is better to do this on the nodes because the breast may not heal well. Then treat (5.7) for TB; there is no need for mastectomy.

**If you suspect malignancy**, try to get a diagnosis first to plan your treatment. Fine needle aspiration cytology is the best method but needs careful immediate expert examination of the slides. It is almost essential if you suspect Burkitt's lymphoma. Do cytology on axillary nodes: if you find breast cells, you have proved metastases. Or, do a trucut biopsy if the lump is big enough and you can hold it firmly in the hand (24-3). Otherwise, excise the lump fully with a 2cm margin of normal tissue *and remember to orientate it properly for the pathologist, by marking it with indelible inks or coloured threads*. If this is not feasible, take a small incision biopsy. If the result is carcinoma, proceed as in 24.4.

**If there is a fungating mass**, perform a 'toilet' mastectomy (24.5); it is cruel on the patient to waste time getting a histology result when it will not affect the management.

**(h) Special tests.** Ultrasound is useful to distinguish between cystic and solid lesions, and between discrete lumps and lumpy breasts. It is unnecessary for an easily palpable lump which you can aspirate.

## TRUCUT BREAST BIOPSY

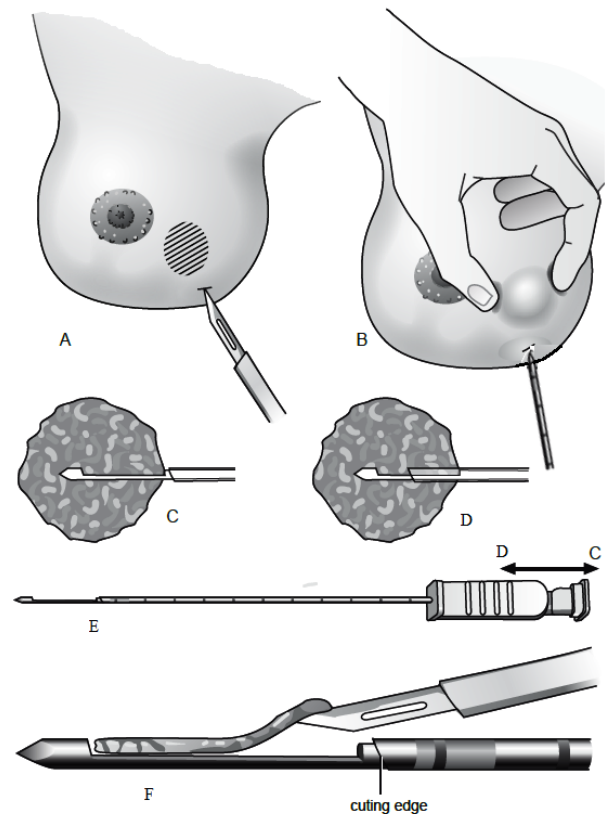


Fig. 24-3 TRUCUT BIOPSY OF THE BREAST (GRADE 1.2).

A, using LA, make a small cut with a blade. B, introduce the closed biopsy needle into the lesion, with an assistant steadying the lump. C, open the trucut biopsy device. D, close the trucut device by pushing the handle, and withdraw the needle. E, positions of trucut needle open and closed. F, examine the specimen obtained to see if there is adequate tissue sampled.

Mammography needs special equipment where the breast is squeezed between two plates and X-rayed; it is sometimes painful and may miss some carcinomas.

Try to screen women with a strong family history of breast cancer before the age of 40yrs, or contralateral breast cancer, especially of the lobular type.

## EXCISION OF A BREAST LUMP (GRADE 2.3)

**ANAESTHESIA.** LA is only really feasible if the lump is very small and superficial. Regional anaesthesia using intercostal nerve blocks works well (but a pneumothorax may occasionally result); otherwise use ketamine or GA.

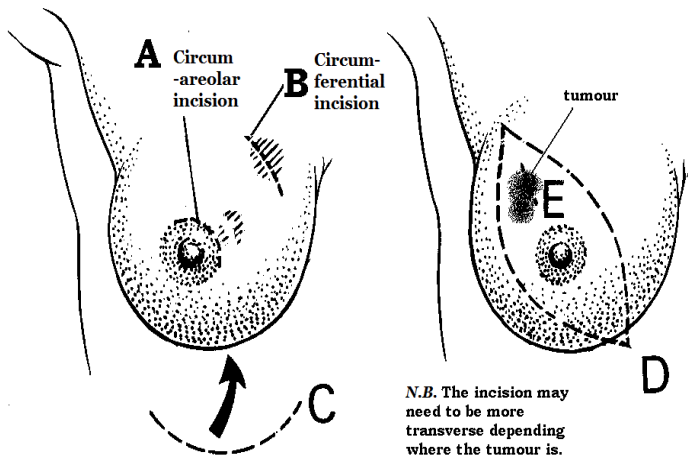
**INCISION.** If you are removing a benign lump from a woman, try not to disfigure the breast or compromise future lactation. Use a circumareolar (24-4A), circumferential (24-4B) (less satisfactory), or submammary incision (24-4C).

*N.B. Avoid a radial incision.*

*N.B. With all incisions, use a sharp knife.*

**If you suspect malignancy**, excise the lump with a margin of at least 2cm of normal breast, and orientate the specimen carefully for the pathologist.

## INCISIONS FOR LUMPS IN THE BREAST



**Fig. 24-4 INCISIONS FOR REMOVING LUMPS FROM THE BREAST.** A, if the lump is within 5-8cm of the nipple, make a circumareolar incision, not longer than  $\frac{2}{3}$  the circumference of the areola. B, if the lump is further away, make a curved circumferential incision over it, parallel to the areola. C, if the lump is deep in the breast, you may be able to use a submammary incision. D, slant a mastectomy incision as transversely as possible towards the axilla. E, if your histology services are good enough to justify taking a biopsy, make a radial incision within the area of a possible later mastectomy, so that you can excise the scar.

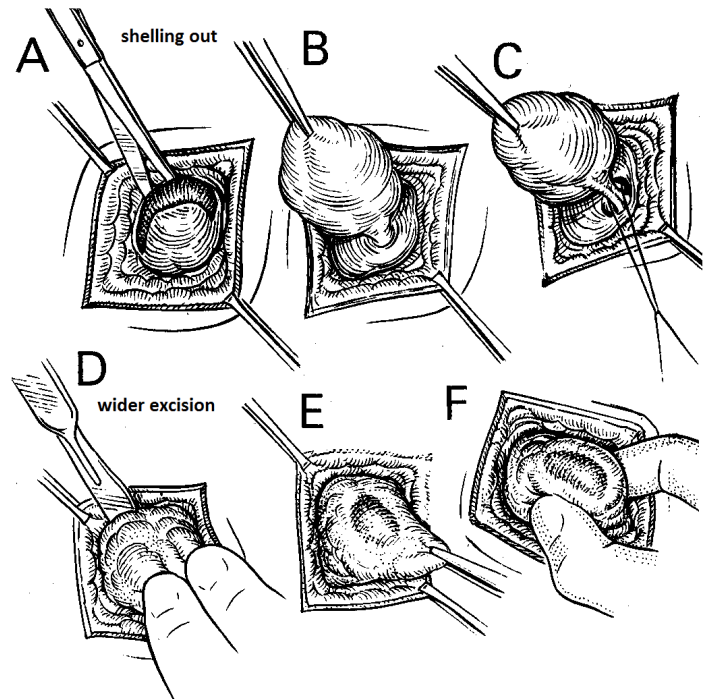
**By a circumareolar incision (24-4A)**, remove a lump up to 5cm from the nipple. Gently dissect radially through the breast from the areola, in line with the ducts. You can cut  $\frac{2}{3}$  round the circumference of the areola without compromising its blood supply.

**By a circumferential incision over it (24-4B)**, remove any lump if an inframammary incision is too far away. This produces an obvious scar, but will be much more aesthetic than a radial scar.

**By a submammary incision (24-4C)**, approaching the lump from the underside, remove deep inferiorly placed lumps: this will be less easy than the circumareolar or circumferential incisions. Cut round the infra-lateral quadrant of the breast: in light-skinned women this follows a pigmented line. Hold the breast up while you make your incision in this line, and free the breast from the pectoral fascia. Continue to hold the breast up. Incise the posterior surface of the breast, until you have exposed the lump. Grasp it with forceps, and then free it from its bed with a scalpel or curved scissors.

Bleeding is not usually much of a problem. If it is difficult to control immediately, pack the wound with swabs, apply pressure for 5-10mins, remove the swabs, and then either transfix and tie the bleeding vessels, or control them with diathermy.

## CLOSE & WIDER EXCISION OF A BREAST LUMP



**Fig. 24-5 CLOSE AND WIDER EXCISION OF A BREAST LUMP.** A-C, remove a benign lesion through a small incision with minimal disturbance to the surrounding tissue. D-F, WIDER EXCISION for the removal of a suspicious lump: expose the lesion, *but don't cut into it*, and remove the lump with a small part of the surrounding breast. After Rob C, Smith R. *Operative Surgery Vol 1, Butterworth 2<sup>nd</sup> ed 1981 with kind permission.*

Close the cavity with interrupted sutures of absorbable suture on a half-circle needle. If the cavity is too large to be completely obliterated by sutures, and bleeding is troublesome, insert a Penrose drain.

Close the skin with 3/0 or 4/0 subcuticular monofilament. Post-operatively, apply a tight binder, which is uncomfortable, or better, a pressure dressing of adhesive strapping.

### (i) Difficulties with tumours of the breast

**If there is a giant fibroadenoma (24-6)**, simple removal may not be possible, and you may have to remove it piecemeal with the risk of seeding cells resulting in recurrent fibroadenomas. Avoid a mastectomy unless the tumour is fungating. If it only occupies part of the breast, you may be able to shell it out. If you preserve normal breast tissue where you can, the breast may surprisingly return to its normal shape afterwards.

## 24.3 Other benign breast conditions

### (a) Managing a discharge from the nipple

This can be:

- (1) The normal action of breasts in pregnancy. Colostrum can be discharged from the 16<sup>th</sup> week of pregnancy, and even earlier in multipara.
  - (2) The normal, usually milky discharge after lactation stops. This may however still persist for months and occasionally years, especially if lactation is prolonged.
  - (3) The clear, or less often blood-stained, discharge due to an intraduct papilloma, adenoma or carcinoma.
- Or rarely,
- (4) The discharge associated with fibroadenosis.
  - (5) The discharge associated with periductal mastitis.

Discharge is more serious if it comes from one duct rather than from many, if it is bloody, or if it is associated with a lump. At the start of the examination, *don't palpate the breast in the normal way*, because this may squeeze out any secretion which has accumulated, and you want to see exactly where it is coming from.

Instead, with the patient supine, gently wipe the nipple clean. Then, press with one finger 3cm distal to the areola, and move it towards the nipple. Start at the 10 o'clock position and move progressively all round the breast to the 12 o'clock position. If there is any discharge, wipe it away and note its position. Then examine the breast in the usual way.

### EXCISING A GIANT FIBROADENOMA

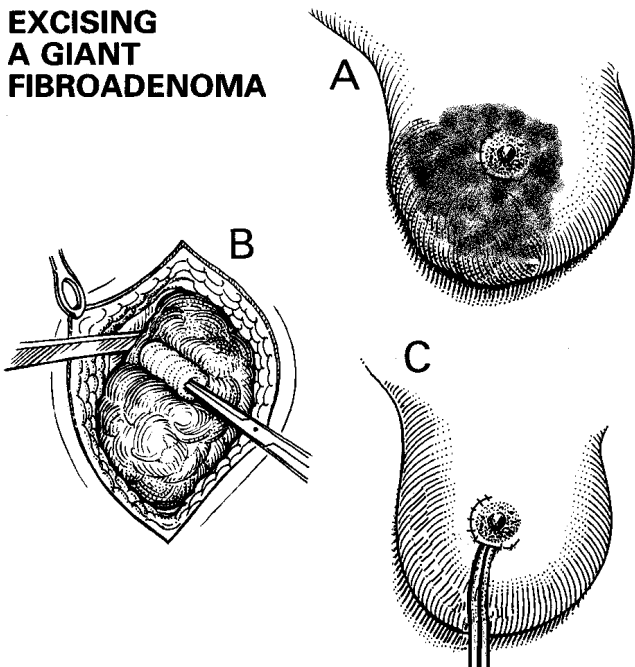


Fig. 24-6 EXCISING A GIANT FIBROADENOMA.

A, make a circumareolar (or for a very large mass, a circumferential) incision. B, shelling out the tumour. C, leaving a drain in place. *N.B.* Very rarely, only if there is gross pressure ulceration, you may need to perform a simple mastectomy.

After Rob C, Smith R. *Operative Surgery Vol 1, Butterworth 2<sup>nd</sup> ed 1981 with kind permission.*

In a pregnant woman, if the fluid is clear and comes from many ducts in both breasts, reassure her.

If both breasts continue to discharge milky fluid from many ducts, this is galactorrhoea, which may be due to medications (sedatives and anti-depressants), or rarely a pituitary tumour raising prolactin levels. Jasmine is effective if you cannot get bromocriptine.

If there is a recurrent discharge from several points on the nipple, watery or viscid, green, white, black or occasionally bloody, suspect duct ectasia and/or periductal (plasma cell) mastitis, which is common in smokers. It can also present as a hard, tender swelling with redness of the overlying skin, which you can confuse with an acute breast abscess, or a rapidly growing carcinoma.

If there is fibrocystic disease, the retention cysts it causes may occasionally cause a discharge from one breast, seldom both. Aspirate the cyst if there is one. If it does not disappear, or if the fluid is blood-stained, perform an excision biopsy.

If there is a watery, or bloody, or dark discharge from one duct, usually without a lump, this is probably due to an intraduct papilloma or adenoma. If there is a lump, it is more likely to be a carcinoma; even so, the prognosis is usually good. Excise the lump with the duct (see below).

### AN INTRADUCT PAPILOMA

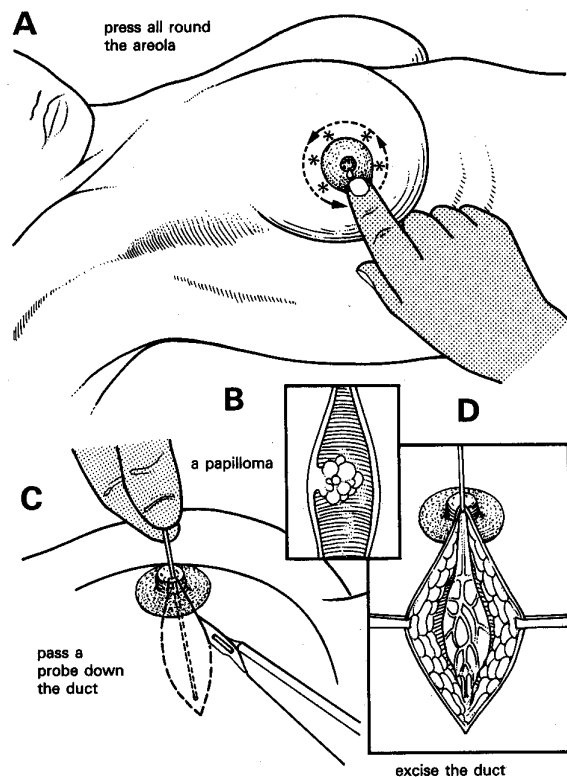


Fig. 24-7 BREAST MICRODOCHECTOMY.

A, carefully palpate all round the breast to find out which segment the discharge is coming from. B, lesion in the wall of a duct which might equally well be a duct adenoma or a carcinoma. C-D, pass a fine probe down the duct, and excise it with some of the surrounding tissue.

**(b) Breast microdochectomy (GRADE 2.3)**

Aim to excise a single duct system with its surrounding tissue. Try to make sure that neither the patient, nor anyone else, squeezes the breast during the 2-3 days before you do so. Under GA, find the orifice of the affected duct by squeezing the secretion out of it. You may be able to feel the lesion under the areola (24.2). Pass a fine probe or a hypodermic needle with a blunt end along the duct (24-7C). Ask your assistant to hold this, while you excise an oval of skin and breast tissue with the duct and the lesion. Make sure that you excise the probe with a margin of at least 2cm of macroscopically normal tissue horizontally and vertically all round the duct, except at the nipple (24-7D). Suture the deeper layers with plain absorbable suture to obliterate the dead space. Close the skin with 3/0 monofilament. There is no need for a drain. If haemostasis is not good, apply a pressure dressing. Send the specimen for histology. Remove sutures at 7 days.

At review, if it is a papilloma (75% chance), nothing further is needed. If there is an *in situ* carcinoma (15%), do a careful follow-up for at least 6 months.

The operation itself should be sufficient, but if there is an invasive carcinoma and the tumour is >2cm diameter, perform a mastectomy unless radiotherapy is available.

**(c) Managing a sinus or fistula in the breast**

A sinus or fistula may discharge milk, or a non-specific fluid. A milk fistula can follow a breast abscess, trauma, tuberculosis, a cancer of the breast, or occasionally the presence of a foreign body, or fungal infection.

**If there is a milk fistula, and the patient is or should be breastfeeding**, try to improve or re-establish breastfeeding soon. The fistula will probably heal. If it does not, it will probably do so when breastfeeding ceases at the normal time.

**CAUTION!** A milk fistula is not an indication to stop breastfeeding. Rather, it is an indication to re-establish breastfeeding soon, if lactation has stopped.

**(d) Nipple diseases**

(1) **Paget's disease of the nipple**, a localized eczema, is unilateral and, though rare, a sure sign that there is an underlying intraduct carcinoma. Biopsy the nipple skin and if you find 'Paget' cells, perform a mastectomy.

(2) **Chronic eczema** (uncommon) is bilateral. Clean the nipples frequently with soap and water. Apply zinc and salicylic acid paste (Lassar's) 1%, or hydrocortisone ointment 1%. Make sure you follow up the patient and exclude Paget's disease!

**A painless ulcer on the nipple** may be a syphilitic chancre if there is a history of nursing an infected child or kissing by an infected individual; check the RPR or VDRL and treat with penicillin.

(*N.B.* The mother of a syphilitic infant does not get re-infected by her own child.)

**(e) Difficulties with other breast diseases**

**If there is evidence of acute inflammation** – a recent history, throbbing pain, and tenderness – *don't wait for fluctuation*. Treat as for a breast abscess (6.13). Acute infection may be difficult to differentiate from mastitis carcinomatosa (24.2).

**If both breasts are enlarged**, with pitting oedema, suspect some generalized disease, such as cirrhosis, nephrotic syndrome, or heart failure.

**If there are small fibrotic axillary nodes**, not the typical enlarged matted tuberculous nodes, and no signs of tuberculosis elsewhere, there may be chronic non-specific infection following repeated infection of the hand and arm, usually from wounds, or filariasis (34.14).

**If the nipple is chronically ulcerated**, suspect that this is associated with an underlying duct carcinoma, unless there is a clear history of trauma. Get a biopsy to exclude rare causes such as syphilis and tuberculosis.

**If there is one swollen breast with pitting oedema and no palpable mass**, this may be:

(1) Primary TB of the breast, or

(2) Secondary to chronic axillary lymphadenitis. The affected breast is larger than the opposite one, is not tender or only slightly so, and almost always shows '*peau d'orange*'. The axillary nodes (usually the lateral pectoral group) are commonly matted together, and may be attached to underlying structures and the skin. In TB, there may also be a discharging sinus. Look for signs of TB elsewhere, especially enlarged nodes in the other axilla, groins, and abdomen. Get a chest radiograph, and do an ESR. This manifestation of TB affecting the breast via the axillary nodes is more common than primary TB of the breast.

In endemic areas, think of filariasis (34.14).

**If both breasts enlarge prematurely**, associated with menstruation, there is precocious puberty. Look for an ovarian tumour, or an intracranial lesion, which may disturb the gonadotrophin releasing mechanism.

**If one breast is very much larger than the other during puberty**, but is otherwise normal, this is probably congenital GIANT HYPERPLASIA, and may affect both breasts. Later, the breasts usually become the same size but may enlarge again in the 3<sup>rd</sup> decade, especially following pregnancy. *Don't remove breast tissue in a child for a biopsy* because you will destroy the normal development of the breasts.

**If both breasts enlarge hugely in an adult**, this may cause backache; very large breasts can be made smaller by reduction mammoplasty but this is difficult plastic surgery.

**If extra breasts develop**, they may develop anywhere along the nipple line from the axilla, along the chest wall down to the thigh. Rarely, these breasts are functional. You should be able to excise them easily.

If there is a soft fatty lump in a lady >70yrs, which feels as if it might be a lipoma, suspect that it is in fact a carcinoma, which can be as soft as a lipoma at this age.

## 24.4 Breast carcinoma

Carcinoma of the breast is common and can occur at any age >20yrs, but is most common from 50-70yrs, particularly in nullipara and in women who started childbearing late; it is also common in the sisters of patients with the disease, and to a lesser extent in their daughters. It appears to arrive earlier in HIV disease, and may act more aggressively. It may be a consequence of the use of hormone replacement therapy which used to be advocated to prevent menopausal osteoporosis.

Carcinoma of the breast may also occur in males, *but is not related to gynaecomastia* (24.6).

Breast tumours arise commonly from the duct system or less commonly from the lobule. When confined and not invading the basement membrane, they are described as *in situ* carcinoma, and therefore potentially curable by surgical excision. Most invasive ductal carcinomas have no specific features, but medullary, tubular, mucinous, papillary and cribriform have better prognosis, whilst signet ring, clear cell and inflammatory types have worse prognosis. **Mastitis carcinomatosa** is of this last type. Lobular carcinomas are often bilateral but have better prognosis than invasive ductal carcinomas, unless they are of the pleomorphic type.

Sarcomas are rare and arise from fibrous stromal tissue. They occur in young girls <20yrs as **phylloides** tumours (24.2). These may be well circumscribed but tend to recur if a margin of excision is not included with the tumour, and rarely metastasize.

**Lymphomas** (rare) also occur, especially Burkitt's lymphoma (17.6).

Breast carcinomas form no capsule; they invade locally through the lymphatics, and spread widely through the bloodstream. The prognosis is related to:

- (1) the stage at which treatment starts,
- (2) the histological tumour type, and
- (3) less significantly, the treatment.

The stage at which the diagnosis is made is critical, so persuade your staff to include breast palpation in every general clinical examination. A 1cm lump represents 30 doublings; growth however occurs in spurts and dormant periods are frequent but irregular. Occasionally you may detect a carcinoma as a suspicious lesion on a mammogram or ultrasound when it is still not palpable.

Carcinoma of the breast may present as a painless lump in the breast (80%), as enlargement of a breast, as ulceration, or as a discharge from the nipple which is usually but not always blood-stained.

Treatment is mainly surgical but as in any other part of the body, surgery can only cure if it remains localized and has not

spread elsewhere. If radiotherapy is available, it is the preferred treatment for affected axillary nodes. Anti-oestrogens improve survival and chemotherapy can result in remission. Many patients present late with foul, stinking ulcers. Metronidazole often helps here to remove the odour, and a 'toilet' mastectomy, if it is possible (the growth may be fixed to the deep structures and make it not worthwhile), relieves suffering, and may make the last months more bearable.

### (a) Staging and prognosis

The Manchester system of staging describes:

**Stage I:** growth is confined to the breast, skin involvement smaller than tumour

**Stage II:** growth is confined to the breast, palpable mobile axillary nodes

**Stage III:** skin involvement larger than the tumour, or tumour fixed to underlying fascia

**Stage IV:** distant metastases, fixed axillary nodes, palpable supraclavicular nodes, satellite nodules.

The TNM classification describes tumour size, nodal involvement and distant metastases:

**T0:** no tumour,

**T1:** tumour <2cm diameter,

**T2:** tumour 2-5cm,

**T3:** tumour >5cm,

**T4:** tumour fixed,

**N0:** no nodes,

**N1:** mobile axillary nodes,

**N2:** fixed axillary nodes,

**N3:** supraclavicular nodes,

**M0:** no distant metastases,

**M1:** distant metastases.

The systems overlap as follows:

	T0	T1	T2	T3	T4
N0	Stage I				
N1	Stage II				
N2	Stage IIIA				
N3	Stage IIIB				
M1	Stage IV				

5-year survival should be >65% for stage I and 60% for stage II, but dropping to 15% for stage III and <5% for stage IV.

On microscopic examination the axillary nodes are involved in 10% of patients in Stage I, although they may not be obvious for 20yrs. Tumours in the lateral half of the breast have a better prognosis. If the tumour is Stage I in the lateral half of the breast, there is a 90% chance of cure surgically. If it is in the medial half of the breast (less common), the prognosis is worse, because it is more likely to spread to the internal mammary nodes.

Inadequate local removal of tumour will result in local recurrence; wide excision of a tumour >2cm diameter without radiotherapy will result in a 30% chance of local recurrence. However, the more radical operations (the standard Patey's, removing *pectoralis minor*, or Halsted's, removing *pectoralis major*) don't confer any survival benefit by virtue of their more guaranteed clearance of tumour.

## (b) Management

### (1) Stage I

Excise the lump with 2cm of normal tissue around it (24-5D-F) and send it for histology. If the result confirms a carcinoma <2cm diameter, do a follow-up every 6 months for a year, and yearly thereafter. If the carcinoma is >2cm diameter, or the excision margin is <2cm, perform a mastectomy.

You can try to map *sentinel nodes* especially in the axilla if you inject 0.5-2ml of blue dye around the lump, and then 10-15mins later explore the axilla (17.3). You may be able to increase your detection of axillary nodes by ultrasound. If you then remove *sentinel nodes* which have taken up the blue dye, as well as obviously palpable nodes, you will get a better definition of the spread of the disease, and be able to advise better about further treatment options.

*N.B. Nipple-sparing mastectomy may be feasible in a younger woman, with a view to later insertion of a prosthetic implant (i.e. silicone): think about this if you can arrange to get it done.*

### (2) Stage II

Perform a mastectomy and remove as many obviously involved nodes as you can. This 'axillary sampling' is controversial, but axillary clearance is difficult and may result in damage to the axillary vein and nerves, and may not give any better result. If available, administer radiotherapy if axillary nodes are involved.

**If the patient cannot contemplate removal of the breast**, you could do a wide excision of the lump but this should include axillary node excision and radiotherapy if the nodes are involved. So it may not actually be the best option if radiotherapy is not available; also the risk of local recurrence is higher, and if the breast is small, a wide excision might not lead to a better oncological result.

Treat with tamoxifen 20mg od if nodes are involved, for 5yrs. Administer chemotherapy (cyclophosphamide 100mg/m<sup>2</sup> od for 14 days, and methotrexate 30mg/m<sup>2</sup> plus either 5-fluorouracil 500mg/m<sup>2</sup> IV on days 1 and 8, or doxorubicin 60mg/m<sup>2</sup> every 3wks for 6 cycles) if the patient is <40yrs old and HIV-ve.

Alternatively, as good an effect can often be achieved by bilateral oophorectomy.

### (3) Stage IIIA

Perform a more extensive mastectomy to clear tumour with a 2cm margin and remove as many involved nodes as you find. Occasionally the tumour becomes fixed to the chest wall without significant lymph node spread; if you can remove all of the tumour the first time round, you may give her long disease-free survival, otherwise local recurrence is inevitable.

Advise radiotherapy to the chest wall and axilla if possible, and tamoxifen 20mg od up to 5yrs.

Alternatively, advise bilateral oophorectomy.

### (4) Stage IIIB

Perform a mastectomy *only* if you think you can clear tumour with a 2cm margin (unlikely) or if there is fungating tumour eroding through the skin (a 'toilet' mastectomy). You probably will not be able to close the defect except with a skin graft; unless the tumour mass is very infected, it's best to do this at the time of the mastectomy rather than delaying.

*Interference with fixed axillary nodes may damage nerves and blood vessels and is unlikely to be helpful.*

**If the tumour is firmly fixed to the chest wall**, only very extensive surgery is likely to be successful. Radiotherapy is probably palliative at this stage, but tamoxifen 20mg od may help, and if you can administer chemotherapy it may benefit, but you probably will have more deserving cases for your valuable resources.

Alternatively, advise bilateral oophorectomy.

### (5) Stage IV

No surgery is likely to be helpful here. Treat with tamoxifen 20mg od: occasionally it can produce dramatic results. Radiotherapy to bone metastases may remove constant pain, and bilateral oophorectomy in pre-menopausal women results in remission in c.20%.

## (c) Difficulties with carcinoma of the breast

**If you suspect Burkitt's lymphoma of the breast**, take a needle biopsy, stain a slide preparation, and interpret it yourself (17-1). Or, less satisfactorily, send a biopsy. If you are not confident that you can interpret a slide preparation, do both; excise the lump, make a slide from it, and send the biopsy for histology. If the tumour is large and ulcerating, excise it, and skin-graft the exposed *pectoralis major* as for Stage IIIB tumours. If Burkitt's lymphoma is likely and histology reporting slow, start chemotherapy immediately (17.6).

**If you find breast carcinoma in a pregnant woman**, it may not necessarily be mastitis carcinomatosa (24.2). Treatment of the breast carcinoma takes precedence, however, over the pregnancy.

**If no cytology or histology is available**, *don't delay treatment inappropriately to seek confirmation*, but always consider TB as an alternative diagnosis.

The patient may not return, the report may be lost, and there will be too long an interval between the biopsy and the definitive operation. The biopsy scar may interfere with your proposed mastectomy incision.

**If there is a suspicious impalpable lesion found on mammography or ultrasound**, and you have no way yourself of localizing the lesion, repeat the ultrasound scan if you can, move the affected breast quadrant and make sure you get a histology report. If the lesion is malignant and >2cm, it is best to proceed to mastectomy.

## 24.5 Modified simple mastectomy

In this operation you always remove the nipple (24-4D).

### PREPARATION

Check the side to be operated upon is correct when the patient is still awake and can confirm the side; mark it with indelible ink.

Cross-match blood if the breast is large, you are inexperienced or your diathermy is faulty.

Position the lady supine with the arm on the affected side abducted to 120° and carefully place sterile towels underneath the axilla. It helps to flex her elbow and place her hand under the head.

### ANAESTHESIA

You can use intercostal nerve blocks instead of GA.

**METHOD (GRADE 3.1).** Infiltrate with 1:400,000 adrenaline subcutaneously to reduce bleeding. Make an incision as transversely as possible including the areola and 5cm around the tumour. Ask your assistant to stretch the skin as you cut. Excise a teardrop-shaped ellipse of skin (24-8A). Make it wide enough to let you dissect the breast adequately, and yet not so wide as to make closure difficult. Control bleeding by asking your assistant to press firmly with gauze as you cut.

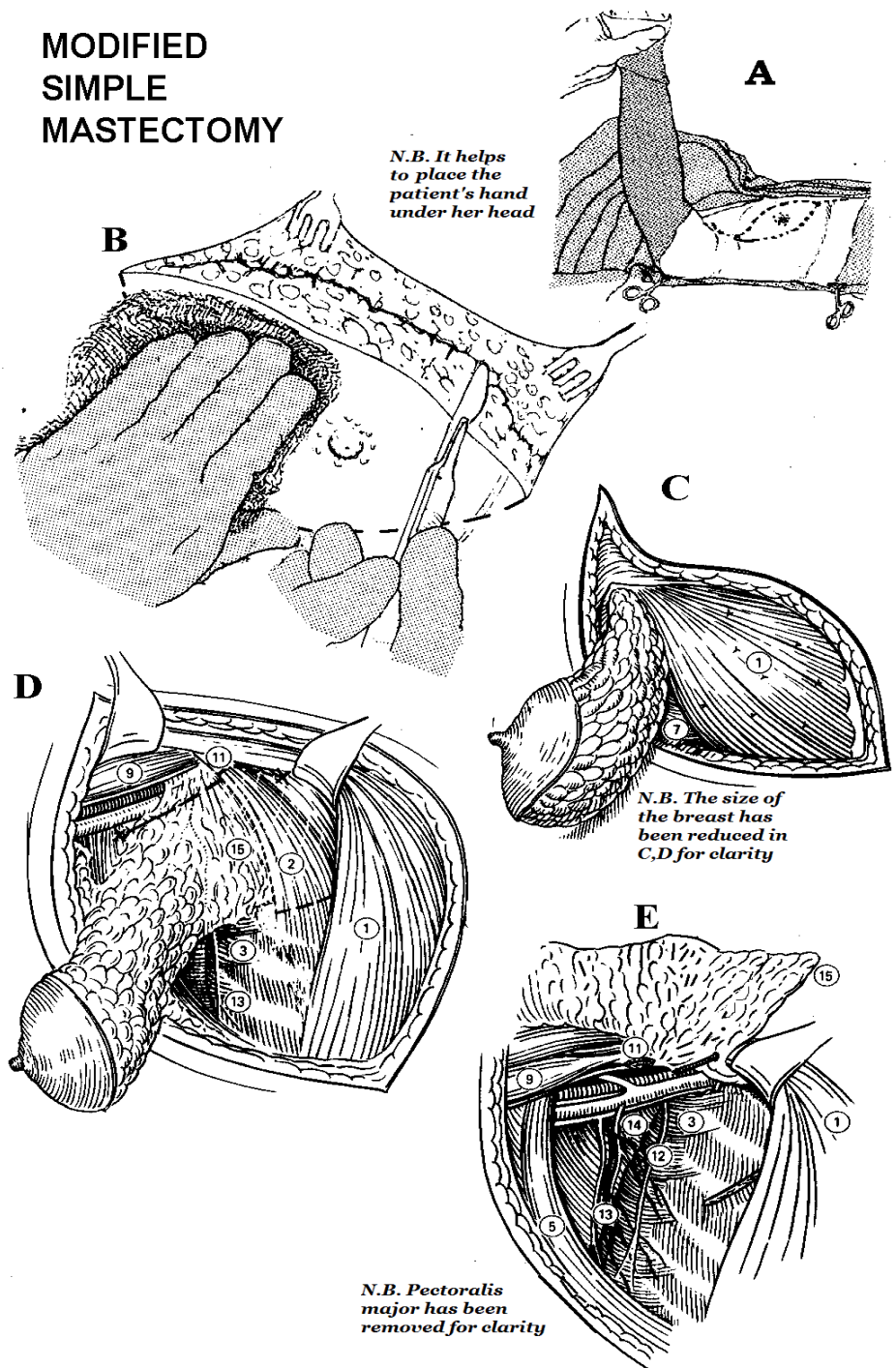
Dissect back the superior (24-8B) and inferior flaps, in the plane between the subcutaneous fat (usually 1-2cm thick) and the breast fat. Hold the skin flaps underneath the skin surface in Allis forceps, and control bleeding of the flaps with haemostats or diathermy.

Continue the dissection to the periphery of the breast, where you will meet the *pectoralis major* muscle on the chest wall. Do this for upper and lower flaps in turn; when the flaps are raised fully, dissect the breast off *pectoralis major* (24-8C: usually using a knife), clamping bleeding points as you proceed, leaving the axillary tail attached. Laterally, dissect the breast off the *pectoralis minor* which will lead you to the fascia overlying the axillary vessels.

### CAUTION!

(1) Don't make the skin flaps too thin, or open up tissue planes more than is necessary. The flaps should be  $\geq 1$ cm thick. Move the Allis forceps lower on the flaps as you proceed.

## MODIFIED SIMPLE MASTECTOMY



**Fig. 24-8 MODIFIED SIMPLE MASTECTOMY.**

A, make a transverse-oblique teardrop-shaped incision on the breast with its apex from its superolateral to its inferomedial margin, centred over the tumour mass and including the nipple. B, dissect upper and lower skin flaps. C, continue dissection to the edge of the breast, and dissect it off *pectoralis major*. D, dissect it further off *pectoralis minor*, leaving its axillary tail intact. E, clear the axillary nodes (if necessary). You don't remove the *pectoralis minor*. (Numbers as in 24-9)

After Rob C. Smith R. *Operative Surgery Vol 1, Butterworth 2<sup>nd</sup> ed 1981 with kind permission.*

- (2) *Don't remove the pectoral fascia, or muscle, unless the tumour is sticking to it.*  
 (3) Make the flaps of even thickness.

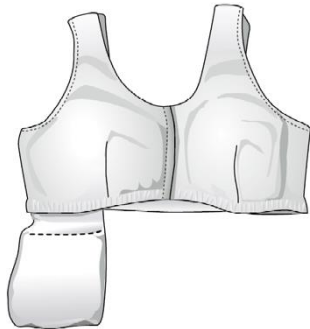Then enter the axilla. The axillary tail only extends a short way into the axilla, but you should be able to look at the axillary nodes. Carefully separate the axillary skin from its underlying fat, and try to remove any lymph nodes *en bloc* with the breast. This is easiest if you identify the axillary vein, and tease the axillary contents with small 'Lahey' swabs (3-3).

*Take care not to damage the long thoracic nerve and the nerve to serratus anterior (24-8E, 24-9B).*

Now control bleeding points by diathermy or ligatures. Irrigate the wound with warm water before you close it. Remove any redundant skin, so that the edges of the incision come together cleanly. If you cannot close the wound completely, cover the bare area with a split skin graft. Insert a suction drain inferolateral to the incision, placing the drain puncture wounds as inconspicuously as possible.

Close the wound with 2/0 absorbable and 3/0 subcuticular monofilament skin sutures. A useful device is a pocket sewn to the bra to carry the suction bottle (24-10).

#### POCKET ON BRA FOR SUCTION BOTTLE



**Fig. 24-10 A pocket sewn to the bra to carry the suction bottle.**  
 After Bradbury C, Parvaiz, MA, Sircar T. *Ann Roy Coll Surg Engl* 2014;96(3):241 with kind permission.

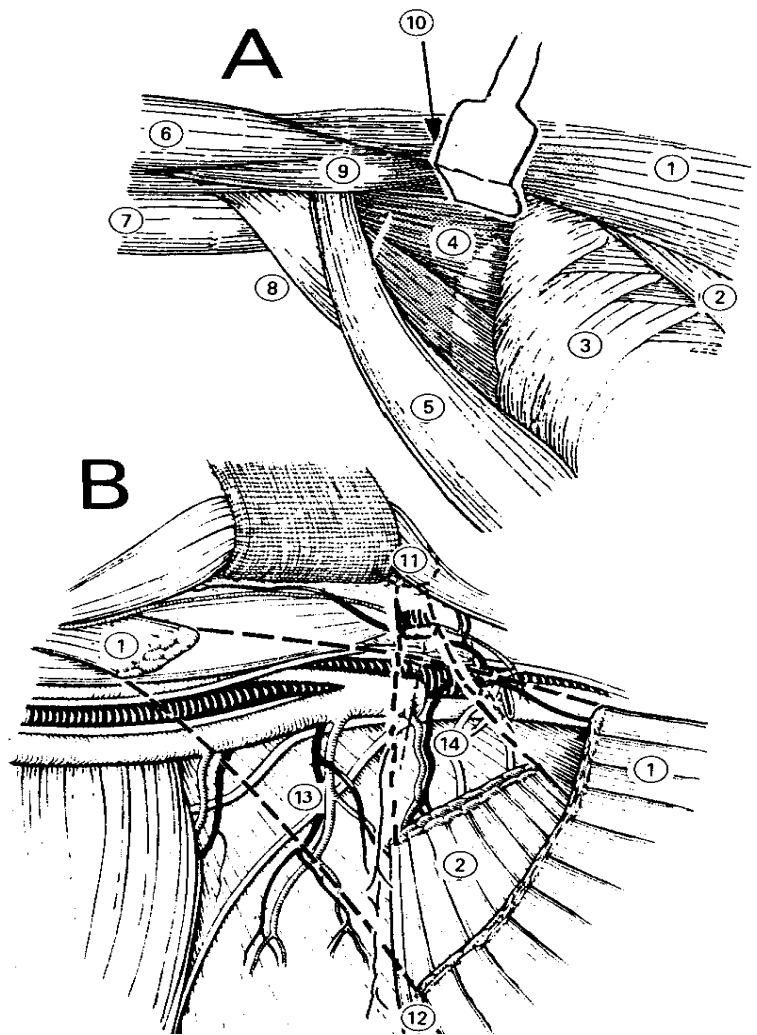
POST-OPERATIVELY, cover the wound with layers of gauze and cotton wool, and hold them firmly in place with adhesive strapping. Apply a pressure dressing for 3-4 days. Remove the drain when no more blood or serous fluid comes out, usually at 3-7 days. Remove the sutures after 7-10 days, the alternate ones first. Encourage active movement of the arm and shoulder.

#### DIFFICULTIES WITH MODIFIED SIMPLE MASTECTOMY

**If you accidentally buttonhole the skin flap during dissection,** use the hole for a drain.

**If you damage the axillary vein,** *don't panic!* Press firmly, arrange suction and extra light, and call for assistance. *Don't apply haemostats.* You can use bulldog clips if you have them. When you can identify the hole in the vein, try to close it with a round-bodied 4/0 or 5/0 continuous monofilament suture.

## ANATOMY OF THE AXILLA



**Fig. 24-9 ANATOMY OF THE AXILLA.**

**A,** empty axilla showing its muscles, as if its contents were absent. **B,** *pectoralis major* shown partially cut away to reveal the structures under it. (In reality it is retained.)

- (1) *pectoralis major*. (2) *pectoralis minor*. (3) *serratus anterior*. (4) *subscapularis*. (5) *latissimus dorsi*. (6) *biceps*. (7) *triceps*. (8) *teres major*. (9) *coracobrachialis*. (10) axillary space. (11) coracoid process. (12) long thoracic nerve (of Bell). (13) nerve to *latissimus dorsi*. (14) lateral pectoral nerve.

After Rob C, Smith R *Operative Surgery Vol 1, Butterworth 2<sup>nd</sup> ed 1981* with kind permission.

**If the tumour is fixed to the *pectoralis major* or *minor*,** remove the affected muscle with the breast. If you dissect along the clavicle, *be careful not to damage the vessels deep to the muscle.* Remember that this is probably palliative surgery, so *don't attempt anything too heroic.*

**If a solid mass forms in the scar** after you have performed a mastectomy for carcinoma, excise it with a 2cm margin, and send it for histology: it is probably a recurrence.

**If the patient is unable to pull the shoulder down post-op,** you have damaged the nerve to *latissimus dorsi*. If there is also much pain as well, explore the wound to see if you have tied a ligature round the nerve: if so, carefully untie it.

**If the shoulder becomes stiff,** you have omitted exercises post-operatively. Start them now!

## 24.6 Gynaecomastia

**If a male <20yrs has a firm tender discoid swelling deep to the nipple just larger than the areola**, and concentric with it, this is physiological. It occurs as a normal variant in infants, in boys near puberty, and in young men. In infants it is nearly always bilateral, and is sometimes complicated by mastitis. In young men it may be uni- or bilateral. Reassure all these patients.

**If one of or both an adult man's breasts enlarge**, this is gynaecomastia. Look for disease of the liver and testes. Distinguish this from breast carcinoma.

Ask about alcohol consumption and marijuana use. Check for leprosy, and enquire about treatment with medicines such as cimetidine, ketoconazole, diazepam, spironolactone, efavirenz, diethylstilbestrol or others. Check also for adrenal or pituitary disease. Often, however, no cause can be found. It may be due to poor waste water management with accumulation of bisphenols (from plastic) which have an oestrogen effect.

*N.B. Beware, however, the enlargement of breasts that comes about with simple obesity! However, true gynaecomastia cannot be treated by liposuction as the enlarged tissue is not due to fat!*

### DIFFERENTIAL DIAGNOSIS

**Carcinoma of the male breast** is harder and often irregular in shape with early skin tethering and fixity to the chest wall. Excise it, together with some of the skin and the muscle underneath it. Because there is so little fatty tissue, the tumour infiltrates the skin and deeper tissues at an earlier stage, and the prognosis is worse. Orchidectomy (27.26) usually produces a temporary remission.

### SUBCUTANEOUS MASTECTOMY FOR GYNAECOMASTIA (GRADE 2.5)

#### INDICATION

Social embarrassment with significantly enlarged breasts.

*N.B. It is difficult to make both sides look exactly the same post-operatively!*

#### METHOD

Make an inferior circumferential incision in the periphery of the enlarged breast. Dissect off a skin flap containing the nipple making sure it is not too thin, and avoiding buttonholing the skin. Continue towards the nipple and dissect out all the breast tissue down to *pectoralis major*. *Don't remove all the fat*, otherwise there will be a depression under the scar. Make sure haemostasis is good; if you are not certain, insert a suction drain.

If the breast is very large, you may need to preserve the nipple with a tissue flap, using skin and subcutaneous tissue from the inferior part of the breast.