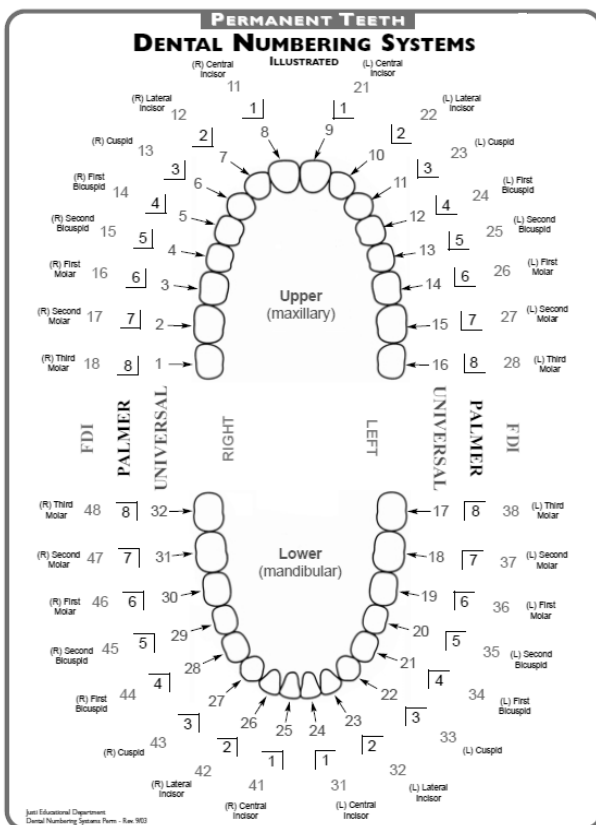


31 Dental & oral surgery

31.1 Introduction

Various dental problems may lead to serious illness; where there is no dentist, periodontologist, or oral surgeon, you may need to intervene yourself. Dental abscesses are described elsewhere (6.9). *Don't forget that a hospital can play a key role in dental health and education;* improved oral hygiene is one of the main ways to combat caries and periodontal disease, and to keep the community's teeth from falling out. When treatment is needed, make sure dental auxiliaries are trained and available for the community to provide care at an affordable cost. Try to get the WHO Basic Package of Oral Care.

DENTAL NUMBERING SYSTEMS (PERMANENT TEETH)



TOOTH NOMENCLATURE. Primary (baby) teeth are numbered in the Universal system as A-T (in the same order as the adult system), in the International (FDI) system as 51-55, 61-65, 71-75, 81-85 according to the quadrant starting top right clockwise, and in the Zsigmondy (Palmer) system as $\overline{5} | \overline{7} | \overline{6} | \overline{8}$ A-E accordingly.

If you are not sure, it is best to describe the teeth as incisor (x2), cuspid or canine (x1), bicuspid or premolar (x2), and molar (x3).

Tooth nomenclature is complicated. The 'Universal' system (used in the USA) uses successive numbers starting at 1 with the tooth furthest back on the top right, continuing to the top left, and then from the bottom left to right. The International (FDI) system divides the mouth into 4 quadrants (1:top right, 2:top left, 3:bottom left, 4:bottom right). The Zsigmondy (Palmer) system uses a cross to designate in which quadrant the tooth lies, so $\overline{11}$ is the 1st upper tooth to the left of the midline.

N.B. The difficulty inserting the sign before the tooth number has made this system unpopular.

(a) Anaesthesia for operations round the mouth

As so often, much of what you can do will be limited by your anaesthetic skills, or those of your assistant. You can however do much with dental, lingual, mandibular, maxillary or pterygopalatine blocks. Be familiar with the anatomy of the jaw. *Don't infiltrate LA fast, especially over the upper incisors:* the small space available distends quickly and will produce more pain if filled quickly than the pain from the bad tooth!

You can also do many procedures under ketamine; it is likely to be safer than an inexperienced GA, especially for babies and children under 2yrs, who would need intubation. Bleeding and the risk of inhalation are the biggest risks from oral surgery under GA; *so always have a swab on dissecting forceps, and a sucker, with a catheter at its tip, instantly ready.*

(b) Cleaning the mouth before surgery

The mouth harbours millions of organisms, including anaerobes. Make sure the patient brushes his teeth before surgery. *Do it yourself (again) in theatre before operating on his mouth as a precaution!*

SOME DENTAL INSTRUMENTS

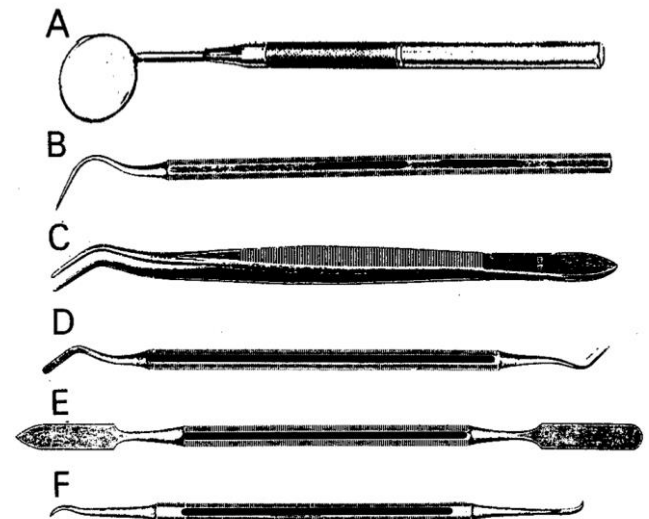


Fig. 31-1 SOME DENTAL INSTRUMENTS (shown from the side). A, mirror. B, probe. C, forceps. D, 'plastic instrument' for putting filling into a tooth. E, spatula (with end-on view). F, Cumine scaler for plaque removal (with end-on view). *From the Ash instrument catalogue.*

EQUIPMENT needed

CHAIR, operating dental.

A dental chair is expensive. If you don't have one, you may be able to adapt a strong chair and fit it with a rest to support the patient's head when it is pushed firmly backwards, especially when you extract upper teeth.

DENTAL MIRROR, serrated handle with #4 size plane head (31-1A).

DENTAL PROBE, single-ended (31-1B).

DENTAL DRESSING TWEEZERS (31-1C).

'PLASTIC INSTRUMENT' (31-1D).

This is for inserting filling material into a cavity.

SPATULA, metal, for mixing fillings (31-1E).

SCALER, dental, Cumine (31-1F).

DENTAL MATERIALS, clove oil for dental use. Zinc oxide powder. When mixed together on a glass slab with the spatula listed above, these make an effective analgesic and a mildly antiseptic dressing for a dental cavity.

SUCTION MACHINE. This is essential, to prevent aspiration of liquids, pus or blood.

31.2 Gum disease

The gums of healthy teeth cover their necks and those of adjacent teeth (31-3G). If gums are diseased by periodontitis, they recede and expose the necks of the teeth (31-3H,I), which ultimately become loose and fall out. Besides causing sore, bleeding gums, periodontal disease causes more lost teeth in many communities even than caries. It may be caused by *actinomycosis*.

Periodontal disease is the result of a vicious circle. Food tends to accumulate between a tooth and its gum, and causes the gum to slowly recede. This makes the pocket larger, so that food accumulates even more easily. In more severe cases the diseased gums swell, bleed easily (gingivitis), and discharge pus (pyorrhoea), often with severe foetor (31-2). Gingivitis is common in early pregnancy (<12wks), and scurvy (vitamin C deficiency), and may result in severe necrotizing ulceration with HIV disease.

Ingestion of food increases mouth acidity, which attacks the enamel lining of the teeth. Saliva exists to buffer and wash away acid, but if there is excessive sucrose and little fluoride, an exopolymer of extracellular polysaccharide matrices in a viscous hydrated phase builds up as a very sticky biofilm. This is known as plaque, under which the tooth continues to disintegrate.

The prevention of gum disease, and most of its treatment, is improved oral hygiene: better tooth-brushing (31-3D,E), increase of fibre and reduction of sugar content in the diet, and when necessary, scaling to remove hardened plaque that has accumulated in the crevices (31-3J).

You may not find yourself scaling many teeth, but there must be someone in your hospital who could do this, and you should be able to teach how to do it properly.

DETAILS OF HEALTHY & DISEASED TEETH

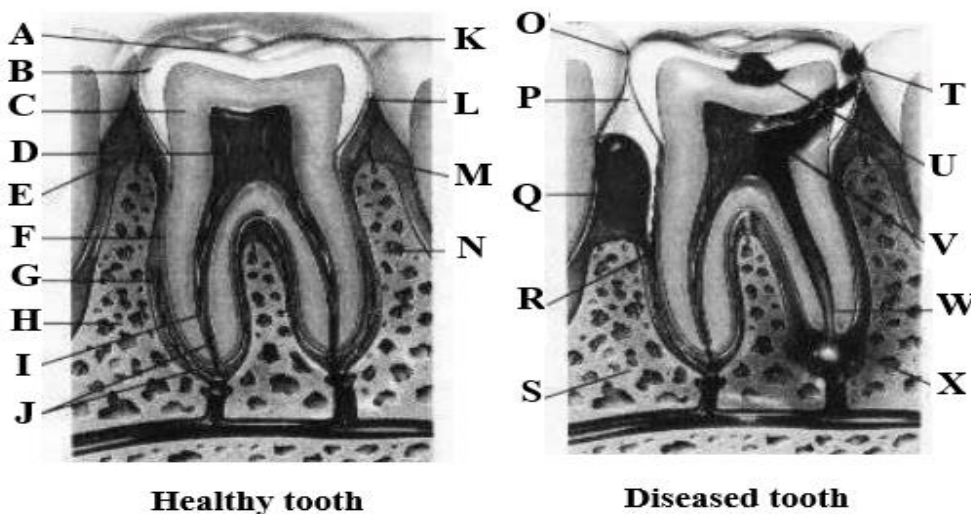


Fig. 31-2 DETAILS OF TEETH.

Healthy tooth; internal structures: (A) fissure. (B) enamel. (C) dentine. (D) pulp. (E) gum (gingiva). (F) cementum. (G) periodontal fibres. (H) alveolar bone. (I) root canal. (J) blood and nerve supply at root apex. **External features:** (K) white, shiny enamel (a crown is fixed onto this). (L) no space between tooth and gum. (M) firm, pale gums. (N) bone supporting tooth.

Diseased tooth; stages of periodontal disease: (O) plaque (bacteria) forms and infects gum. (P) gum recedes and forms a pocket for food and bacteria to collect. (Q) gum becomes inflamed (gingivitis), bleeding often. (R) periodontal fibres destroyed; abscess develops. (S) bone destroyed (periodontitis) and tooth becomes loose and may fall out. **Stages of dental decay:** (T) bacteria in plaque convert sugar to acid. (U) acid destroys enamel (caries). (V) decay spreads to dentine, which becomes sensitive to heat and cold, and infection spreads to pulp cavity. (W) pulp infection spreads down root canal. (X) peri-apical root canal abscess develops.

After Ahmed MAM, Abdel-Latif, MMM in *Textbook of Tropical Surgery*, ed Kamel R, Lumley J, Westminster 2004 p.320 Fig 82.1.

(a) Preventive dentistry

(1) **CLEANING TEETH.** Explain that this should always start with the toothbrush (or toothstick, 31-3B,C) on the gums, moving it up over the lower teeth, and down over the upper ones, at least 10 times, for at least 2mins. This is not easy behind the lower front teeth, and needs much practice. After this, it is important to rinse out the mouth. If there is no toothpaste, you can use common salt, or nothing: brushing is more important than paste.

Don't discourage the use of sticks or sugar cane!

(2) SCALING TEETH INDICATIONS

Use the spoon end of a scaler (31-3F) to remove deep hardened plaque (31-3J). This starts just below the gum. Removal may be difficult, because the plaque may stick so firmly to the teeth that scraping it off can cause mild pain and bleeding.

Use the point of the scaler to remove plaque from between the teeth. Rinse the mouth out thoroughly, and then demonstrate how to clean the teeth properly.

CAUTION! The most important part of treatment is demonstrating how to clean teeth effectively and regularly. Advise use of dental floss and avoidance of sticky sugary foods, including most fizzy drinks.

DENTAL HYGIENE

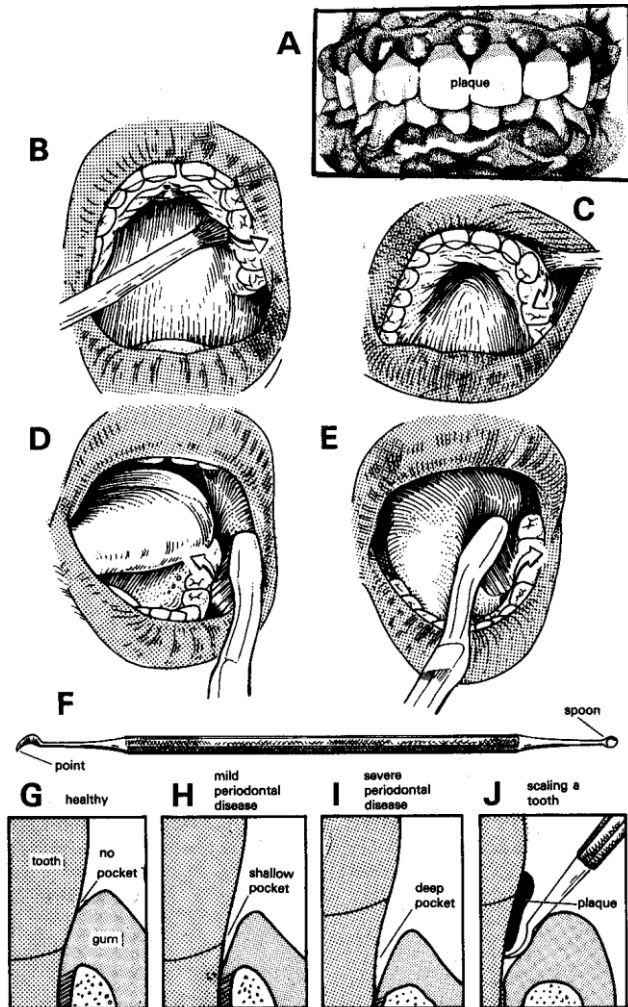


Fig. 31-3 PREVENTIVE DENTISTRY.

A, plaque around the lower front teeth. B-C, use of a toothstick on the upper teeth. D-E, use of a toothbrush on the lower teeth. Use the brush vertically from the gums up and over the teeth, and not horizontally along them. F, dental scaler. Sections of a tooth and gum: G, healthy gum. H, early periodontal disease. I, severe periodontal disease. J, remove plaque with a scaler.

After Halestrap DJ, *Simple dental care for rural hospitals*, Med Missionary Assoc, London, 4th ed 1975 p.198 7-11 with kind permission.

(b) Gingivitis

If this is severe, apply a strong topical antiseptic such as chromic acid 5% od, and treat with oral metronidazole. Measure the depth of the gum pockets with a special blunt probe which you can introduce under the gingiva alongside the tooth. If the pockets are <5mm, scaling may be all that is necessary, but if they are deeper than this, gingivectomy is necessary. If this is impractical, consider extraction.

(c) Caries

If you can save the tooth, scrape out the carious portion, and fill the cavity with fluoride-impregnated plastic filling: this is part of the WHO Atraumatic Restorative Technique.

31.3 Extracting teeth

You should be able to extract teeth, either for severe toothache due to irritation of the dental pulp or abscess

formation or, less often, for periodontal disease. This makes teeth so loose that they often fall out on their own. Try to remove the tooth with all its roots, and without damaging anything else in the mouth.

The secret of success is to force the beaks of the forceps over the visible crown of the tooth, and under the gums, between the periodontal membrane and the alveolar bone, so as to grip its roots firmly. Then, while still grasping the tooth firmly, gently rock it or rotate it depending on the kind of tooth you are removing (31-6D,E). This will break down the periodontal membrane, and widen its socket. *The common idea of 'pulling teeth' is false*; the important movement is the early one of pushing the beaks of the forceps into the jaw around the root of the tooth.

Each forceps has handles, a hinge and a pair of blades. Forceps for the upper jaw are straight, or slightly curved; those for the lower jaw have blades at right angles to their handles.

Ideally, forceps should avoid the crown, and fit the whole surface of the neck and root of a tooth. The blades must be sharp, so that they can easily slide between a tooth and its gum. If necessary, sharpen them on the outside of their tips.

If a tooth has one root, you can loosen it by twisting it (31-6D). The teeth which have one root are: the upper incisors and canines, and the lower incisors, canines, and premolars. All other teeth have more than one root, so you cannot twist them. Instead, you have to rock them (31-6E). You will need two forceps for upper molars: one for the right and another for the left. Upper molar forceps are curved, so as to avoid the lower lip. The buccal blade with a beak on it is designed to grip the two outer roots, and the palatal blade is designed to grip the one inner root. One pair of lower molar forceps is enough. You can, however, remove *any* tooth with lower premolar forceps (31-4).

EQUIPMENT needed

FORCEPS, dental, set of six: (a) upper anteriors. (b) upper right molars. (c) upper left molars. (d) upper premolars and roots. (e) lower molars. (f) lower anteriors and roots.

Alternatively, **FORCEPS, dental, universal, set of 2, upper universal, and lower universal.** Dental forceps are expensive, so you may have to manage with these 2 universal forceps, but they are not so easy to use.

ELEVATORS, dental, (a) upper jaw, straight inclined plane, Coupland, (b)&(c) lower jaw, Cryer's set of 2. Coupland's elevator is a small gouge on a metal handle (31-8A,B). You will need it to remove roots; if you don't have one, you may be able to use the narrow blades of anterior forceps.

TWEEZERS.

PROP, dental. You may find this useful to keep the mouth open while you extract teeth.

DENTAL DRILL. If you are fortunate to have this, acquaint yourself with its proper use. You can attach ordinary IV tubing to it with small elastic bands in order to supply continuous water irrigation to cool the tooth and the drill bit: this is much cheaper than expensive pumps.

(a) Indications

- (1) A painful, severely carious tooth.
- (2) A periapical abscess (31-2X).
- (3) A periodontal abscess.
- (4) Severe periodontal disease.

TYPES OF TEETH AND FORCEPS

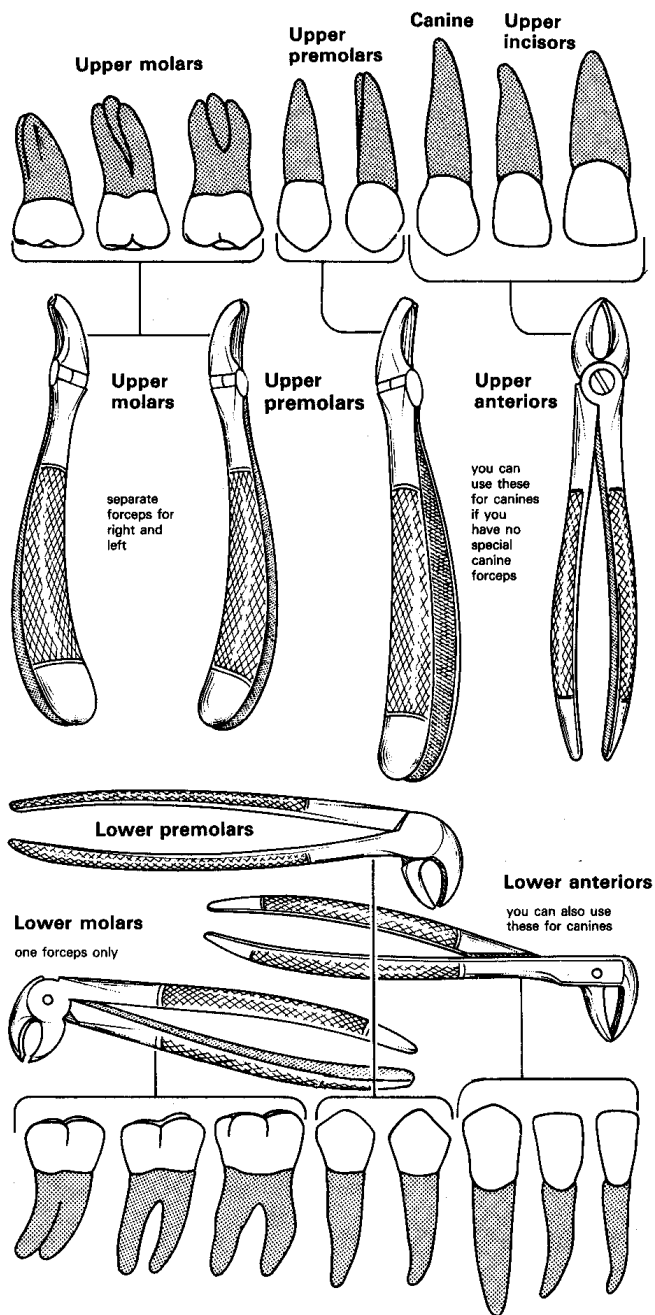


Fig. 31-4 TEETH AND FORCEPS.

Forceps for the upper teeth are straight, and those for the lower teeth are cranked. There are separate forceps for the upper molars, right and left; all other forceps can be used on either side. The beak of a pair of molar forceps is always on the outside, where it fits between the two buccal roots.

Kindly contributed by Hanif Butt.

(b) Relative contraindications

These may give you problems:

- (1) Buried, impacted (31.4), or displaced teeth.
- (2) Teeth which have no visible crown.
- (3) Teeth in very dense bone.
- (4) An uncorrected bleeding disorder.

If there is severe periodontal disease and the teeth are firm, but have swollen gums round them, leave them until other remedies have failed; you may still be able to save them. But if one or more of the teeth are loose in their

sockets, and the gums are red and swollen, and bleed easily on light pressure, remove such teeth.

If a small hole in the tooth seems to be responsible for the pain, clean out the cavity. Use a mixing spatula on a glass surface to make a paste of zinc oxide powder and oil of cloves. Dry the hole with cotton wool. Pack the mixture into the cavity with a plastic hand instrument (31-1D). You can easily remove this paste later.

(c) Children's teeth

Under 12yrs, be very careful when you remove a deciduous (primary, or 'milk') tooth, lest you remove or damage the permanent tooth underneath.

(d) Medical history. Don't forget this!

Use antibiotic prophylaxis if the patient has a prosthetic heart valve.

(e) Which tooth?

If there is toothache, it is usually clear which tooth is responsible. Occasionally, however, when pain is referred, it is not clear even which jaw is affected. So, don't necessarily remove the tooth which appears to be at fault. The offending tooth may:

- (1) have a large hole in it. (If you cannot immediately see any carious areas, use a dental mirror to look on the adjacent surfaces of the teeth.)
- (2) be broken, black, or brown.
- (3) look grey under its enamel.
- (4) be loose with severe periodontal disease around it.
- (5) be tender on gentle tapping.

Tap each tooth in turn with the handle of a dental mirror. The most sensitive one is likely to be the cause of the toothache.

N.B. Toothache may come from an infected maxillary sinus, or the temporo-mandibular joint!

(f) Radiographs

If a tooth is displaced or impacted (31.4), get a radiograph.

(g) **Antibiotics.** If there is an apical abscess (6.9), use cloxacillin for 24h beforehand, and continue for 3 days afterwards.

(h) **Anaesthesia.** Use LA. Make sure that a tooth is properly anaesthetized, by pushing a blunt probe into the gingival crevice (sulcus) on its outer (buccal, facial, labial) and inner (palatal, lingual) surfaces. If there is pressure but not pain, anaesthesia is adequate; otherwise inject more LA.

(i) **Position.** Keep the patient seated so that his head is level with your chest as you stand. Position him and yourself correctly (31-5B, 31-6B).

(j) Extraction of a lower tooth (GRADE 1.2)

Use right-angled forceps and press downwards.

If you are extracting a lower front tooth or a lower left molar or premolar, sit the patient upright in the chair, and low enough for the mouth to be level with your elbow. If he is too tall, stand on something. Grip the tooth socket

between the index and middle fingers of your left hand, and put your thumb under the mandible (31-5A).

If you are extracting a lower right premolar or molar tooth, stand behind the patient (31-5B).

If you are left-handed, stand behind the patient whilst extracting all lower left premolar and molar teeth. For all others, stand in front, but on the left side.

EXTRACTING LOWER JAW TEETH

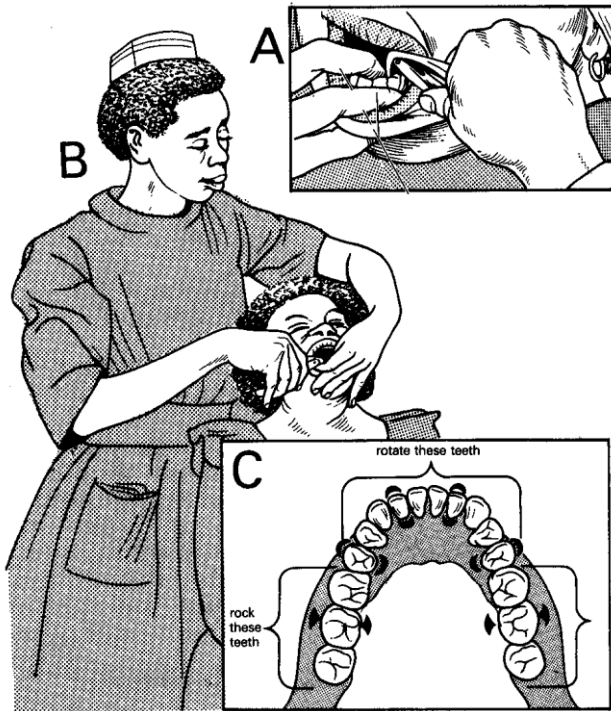


Fig. 31-5 EXTRACTING A LOWER RIGHT TOOTH.
A, support the jaw with one finger inside and one outside. B, stand behind the patient. If you cannot get high enough, stand on a step or something stable. C, rotate the incisors and rock the molars. After *Common oral diseases*, WHO, Fig. 2.9.3. with kind permission of Martin Hobdell.

The beaks of lower molar forceps are both pointed to fit between the 2 flattened roots. Use small rotating movements combined with a sideways movement between the tongue and the cheek. Use constant downward pressure, and support the jaw in your other hand.

To extract a lower incisor tooth, stand in front, push the beaks of the forceps down round the root, and apply a gentle backwards and forwards movement.

To extract a lower canine, which has a more rounded root, use gentle rotating movements (31-6D).

To extract lower left premolars, turn the head towards you and use gentle rotating movements.

To extract lower right premolars, move to the right, or even stand behind the right shoulder.

To extract a lower right molar, stand behind the right shoulder, and use a side-to-side rocking action (31-6E).

If you have difficulty extracting the lower 3rd molar, this may be because its roots are deformed, and need to be dissected out with bone chisels (31.4).

(k) Extraction of an upper tooth (GRADE 1.2)

Tilt the head backwards. If your chair does not have a head rest, support the patient's head against a wall, or ask your assistant to support it. Stand upright and to the right in front of the patient. For all upper teeth, put the finger and thumb of your left hand on either side of the gums.

CAUTION!

- (1) Make sure that the long axis of the tooth forceps blades is in the long axis of the tooth.
- (2) *Don't grasp the tooth and the gum together.*
- (3) Carious teeth are brittle and will break if you put too much sideways pressure on them: *don't use the forceps as a 'nut cracker'.*
- (4) *Don't start extracting movements when you have only grasped the crown of the tooth.*
- (5) When you rock a tooth, feel if it is responding to reasonable pressure; if it does not respond and seems very firmly fixed, abandon the attempt.

To extract an upper incisor, or canine, which have a single conical root, rotate the tooth at the same time as you press it firmly in the direction of its apex (31-6D). Finally, tilt it outwards.

To extract an upper premolar, which has delicate roots (the 1st premolar often has 2), be as gentle as you can. Make small side-to-side and rotating movements while you push upwards with considerable force. When the tooth is loose, pull it downwards.

To extract an upper molar, which has 3 roots, 2 on the outer side, and a single large one on the inside next to the palate (the roots of the 3rd molar are sometimes fused together), choose the correct molar forceps (right or left), so that the pointed blade slips down outside the crown between the roots on the outer side.

Press upwards firmly until the beaks are beside the roots, while you make slight side-to-side rocking movements to loosen it (31-6E).

Finally, increase these movements, and exert pressure in an outward direction, until you can draw the tooth out of its socket into the cheek.

CAUTION! Make sure you support the socket firmly between your finger and thumb, because you can easily break off part of it, especially when you extract a 3rd molar, and break the maxillary tuberosity posteriorly.

EXTRACTING UPPER JAW TEETH

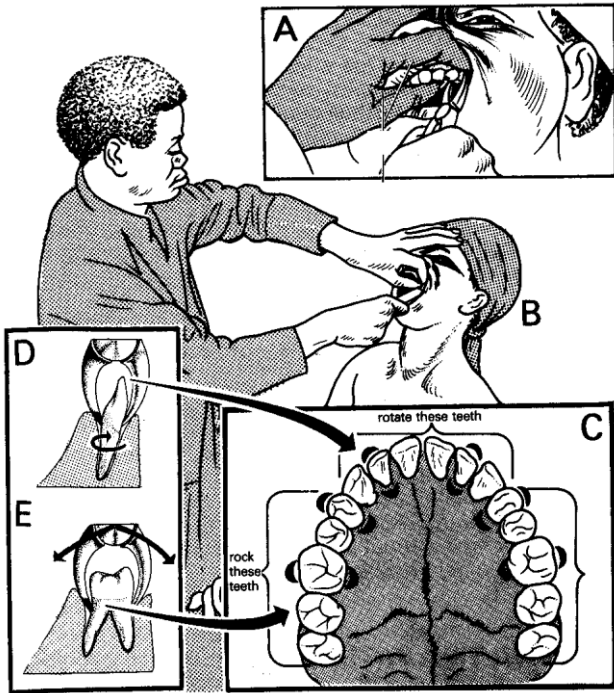


Fig. 31-6 EXTRACTING TEETH FROM THE UPPER JAW. A, support the gums between the finger and thumb of your left hand. B, tilt the head backwards and support it against a wall, or ask an assistant to support it. Note the excellent position of the operator in this figure. C, the teeth to rotate (those with single roots), and the teeth to rock (those with >1 root). D, rotate a tooth with a single root. E, rock a tooth with >1 root. After *Common oral diseases*, WHO, Fig. 2.9.2, with the kind permission of Martin Hobdell.

(l) Post-operatively after tooth extraction

Rinse out the mouth *once only*. Remove loose bits of bone and tissue. Push the inner and outer sides of the empty socket together. Place a tight ball of gauze over the socket, and tell the patient to bite on this for 15mins; make sure he presses on the gauze. Ask him not to spit or wash out the mouth again for 24h; it may wash away the clot, which should be filling the empty socket. The following morning, start rinsing out the mouth with water, using a small spoonful of salt to a cup of water. Tell him not to touch the socket, or play with it with his tongue.

CAUTION!

If you have extracted a tooth for an abscess, commence antibiotic treatment if the swelling does not rapidly improve. Examine the tips of the roots you have removed to make sure they are complete.

N.B. If the empty socket does not bleed after you have removed the tooth, use a dental probe to scratch around inside it until it does bleed. A socket which does not bleed is more likely to become infected ('dry socket').

(m) Difficulties during tooth extraction

If there is a constant oozing during the operation, swab, suck, and apply packs. If necessary, press a dry pack over the wound for 2mins *timed by the clock*.

If the tooth is immovable, and fails to yield when you apply reasonable force with forceps or an elevator (31-8), it probably needs dissection.

If the enamel crown or root breaks, examine it carefully to see how much you have left behind. What you should do depends on how much is left. If it is only a root apex, <5mm in its greatest dimension, leave it. In a healthy patient, the retained apex of a living tooth is unlikely to cause trouble. If the root is >5mm, try to extract the fragment of the broken root with a Coupland's inclined plane elevator (31-8B). Wiggle the elevator between the root and its socket. Otherwise, wedge a blunted 26G needle or wire, braided if available, firmly into the exposed root canal of the tooth fragment, and pull on this to extract it. Alternatively use a large burr to grind out the socket (broken root included) so that no tooth fragment remains.

CAUTION!

- (1) Hold the elevator with your index finger near its tip to stop it slipping.
- (2) The upper premolar and molar roots are very close to the maxillary sinus, so you can easily push a root into it.

If the socket breaks as you remove the tooth, examine the bone. Remove any bony fragment which has lost >½ its periosteal attachment. Grip it with haemostatic forceps, and dissect off the soft tissues.

If you displace a tooth into the sinus or if, while you are extracting an upper molar, you feel supporting bone move with the tooth, the MAXILLARY TUBEROSITY IS FRACTURED, and you have, technically, opened the sinus. If only a small piece of tuberosity has broken off, remove it. If a larger piece has broken, this will need a mucoperiosteal flap made to cover the gap. Warn that if the same teeth are extracted on the other side, the same thing may happen again.

If, when you remove the upper molar, you suspect you have produced a fistula, ask the patient to grip his nose and to try to blow air through it. This will raise the pressure in the maxillary sinus, make blood in the socket bubble, and deflect a wisp of gauze you hold over the socket. The fistula needs to be closed with a flap. *Don't allow rinsing of the mouth until you can arrange repair of the defect, and don't put any instrument through the fistula*: you may infect the sinus.

If you have produced a fistula, and this presents within 24h, close it immediately, by incising the periosteum and advancing a buccal mucoperiosteal flap over the defect (31-8E), and suture it in place. Post-operatively, use cloxacillin and inhalations of tincture of benzoin.

If a fistula presents after 24h, the edges of the wound will probably be infected, so *don't suture it*. Advise oral intake of a sloppy diet. Allow the area to heal, excise the fistulous tract, and close the fistula with a buccal flap. You can remove most teeth or roots from the sinus through the original defect enlarged if necessary.

If you lose a tooth while you are extracting it, immediately bring the head forwards, and ask the patient to cough it out. If you don't find it, X-ray the socket *and* the chest.

If it has been inhaled, try to remove it by bronchoscopy (29.14) as soon as possible, before a lung abscess develops.

If you break or dislocate the mandible, you will need to fix it internally and reduce it.

If you injure the tongue, and the wound is small, it needs no treatment except mouth washes. If it is larger, pull it forwards, inject some lidocaine with adrenaline and repair it with absorbable sutures.

If there is an extra tooth, it is usually conical, and may present almost anywhere on the jaw, and even in a nostril. Removing it may call for skill and ingenuity. If necessary, use a dental elevator to clear away the soft tissues of the gum before you apply forceps.

HAEMOSTASIS FOR A BLEEDING SOCKET

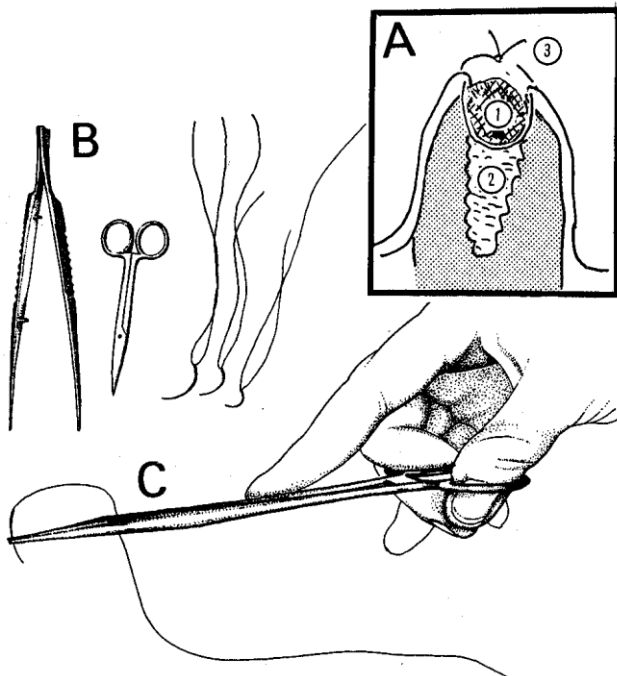


Fig. 31-7 SUTURING A BLEEDING SOCKET. A, ball of haemostatic gauze (1), soaked in adrenaline and plugging a clot-filled socket (2), which is closed by sutures (3). B, C, equipment needed; hold the needle at an angle.

B, from *Common oral diseases*, WHO, with the kind permission of Martin Hobdell.

(n) Bleeding after tooth extraction

Bleeding during the first few hours is likely to be reactionary haemorrhage. Later bleeding is the result of infection (secondary haemorrhage, 3.5).

If there is continued haemorrhage, tell the patient to bite on a rolled gauze, soaked with a 1mg ampoule of adrenaline, in the socket for a further 30mins. Make sure the pad really does press onto the socket this time. (If the socket is infected, use hydrogen peroxide.)

If there is persistent haemorrhage, suture the gums. Use a half-circle cutting needle and 3/0 black waxed non-absorbable suture. Pass 3 such sutures through the gum one side of the tooth socket, and out on the other side.

Place a plug of haemostatic gauze over the bleeding socket (31-7A), and tie this in position. If you don't have haemostatic gauze, use cotton wool; *but be sure to remove the pack after 48h*. Alternatively, bring the edges of the gum together by chipping away bone from the crests of the socket. This will put the gum under tension, and make it less likely to bleed. *Be careful not to suture foreign material under the gingiva!*

CAUTION! Don't be content with inadequate suturing; it will only cause more problems later.

(o) Infection after tooth extraction

Diagnose infection when there is:

(1) **Pain and bleeding.** Irrigate the socket, remove clot and food debris, pack it with haemostatic gauze, and suture this in place. Place a firm gauze pack on top and ask the patient to bite on this. Use metronidazole. *Don't allow rinsing of the mouth*, which may restart the bleeding; instead, clean it with wet gauze.

(2) **An acutely painful empty socket, without any clot in it.** This is a **DRY SOCKET**. It is a local osteitis of condensed bone. The danger is that osteomyelitis may follow. Irrigate it with warm water and remove any food and degenerating blood clot. Under LA, scratch around inside the dry socket to make it bleed. Try to excise any sharp bone spurs. If it bleeds and a clot forms, it will probably heal. A dry socket is very painful, so make sure you provide adequate analgesia.

(3) **Fever and a very painful socket, a mandible which is exquisitely tender, and perhaps numbness of the lips** (owing to involvement of the mental nerve). This is acute **OSTEOMYELITIS** (7.15).

(p) Broken roots after tooth extraction

If a root breaks off, leave a small piece (<1/3 of a root) in place. Remove a larger piece. Try to do this with the narrow blades of a pair of anterior forceps, or by passing Coupland's inclined plane elevator between the root and its socket (31-8A). Push the elevator towards the bottom of the socket, while you press it firmly and rotate it a little each way. As you do so, hold it with your thumb near its tip to prevent it doing any unnecessary damage (31-8B). It should act like a wedge and move the root out of the socket. You can also use this elevator for loosening very firm teeth.

If you fail to remove a root, use a large surgical pneumatic burr to drill vertically into the root, thus destroying it, but not drilling surrounding bone. This avoids the risk of thermal osteonecrosis, and requires no flaps. The mucosa will grow over the defect. Furthermore the patient can then have an implant inserted.

CAUTION! Don't try to remove a fractured maxillary root by passing instruments up the socket. You may enter the sinus and produce a fistula (31-8D). This is much more likely to occur with molars and premolars than with incisors and canines.

DIFFICULTIES WITH ROOTS

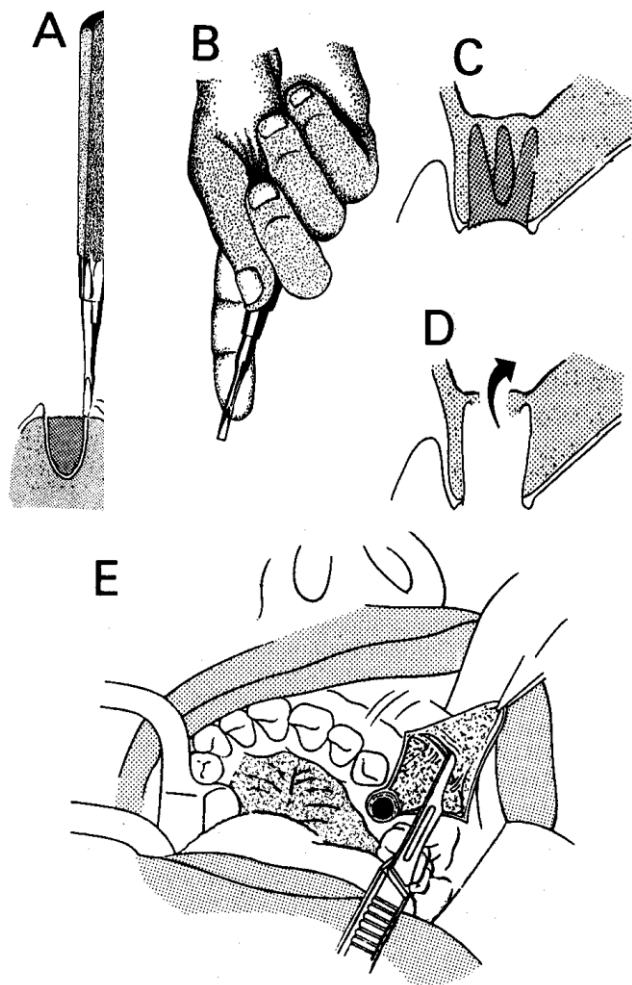


Fig. 31-8 DIFFICULTIES WITH ROOTS.

A, Coupland's inclined plane dental elevator. B, how to hold this with your finger close to the end, to act as a guard. C, roots of a patient's upper teeth are close to the maxillary sinus. D, be careful *not* to cause a fistula into the maxillary sinus. E, make a relieving incision through the periosteum (only) on the undersurface of a mucoperiosteal flap, and move this across to close an oro-antral fistula.

A-D, kindly contributed by DJ Halestrap. E, after Dudley HAF (ed) Hamilton Bailey's *Emergency Surgery*, Wright, 11th ed, 1977. p.182 Fig. 16.45 with kind permission.

(q) Other difficulties with carious teeth

If there is a small discharging granuloma with underlying induration, on the lower face, jaw, or chin, or inside the mouth on the surfaces of a dental socket, it is probably a DENTAL SINUS. An abscess around an infected residual root has caused osteomyelitis in the bone under it, and pus has tracked through the soft tissues to discharge on the gums or on the surface of the face.

Radiographs show a carious tooth, or a residual root, opposite the sinus. Using GA or ketamine, remove the root with a dental elevator and forceps. Curette away the granulation tissue on the face. Advise oral intake of a sloppy diet. The discharge should stop in 48h, and the granuloma should not recur. Treat with cloxacillin for 6wks.

DENTAL SINUSES

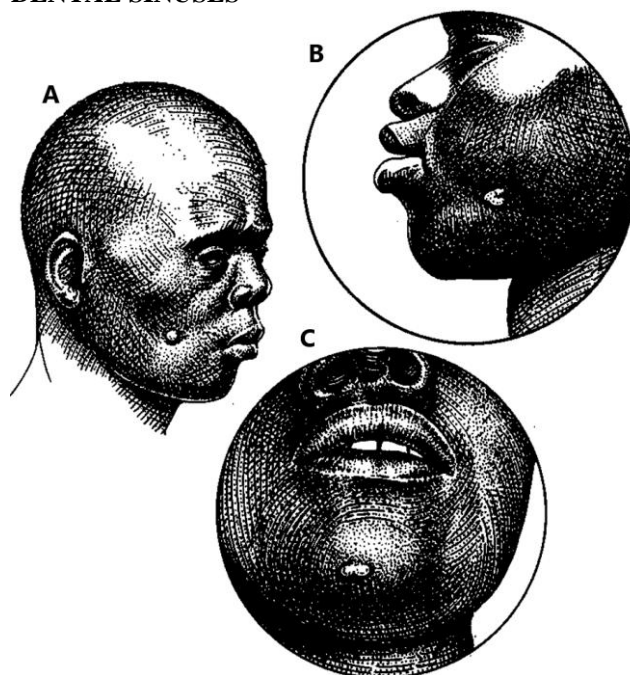


Fig. 31-9 THREE DENTAL SINUSES.

These are caused by a chronically infected residual dental root which has caused an abscess in the bone around it. This erupts A, on the gums, or, B, less often, on the surface of the cheek, or C, the chin.

After Bowesman C. *Surgery and Clinical Pathology in the Tropics*, Livingstone 1960, permission requested.

31.4 Impacted 3rd molar ('wisdom' tooth)

A lower 3rd molar sometimes fails to erupt because it faces forwards, or lies horizontally impacted against the second molar. A pocket or flap of gum (operculum) may overhang it, so that food is trapped and inflammation results. The patient, usually a young adult, complains of pain, which may be referred to the ear, and sometimes has trismus (lockjaw). Secondary infection may follow.

Gently syringe the space between the crown of the patient's unerupted tooth, and the flap of gum over it, with warm water. Then insert a pledget of cotton wool soaked in oil of cloves under the flap. Use metronidazole for infection, and ask him to use hot antiseptic mouth washes. The infection may settle down.

If infection does not settle, you may be able to incise the gum round the edge of the apex of the tooth, so that food no longer impacts around it.

If a 3rd molar is pressing on the gum flap, and making the condition worse, control infection and trismus with mouth washes, syringing, and antibiotics. If this fails, introduce an inferior alveolar and lingual nerve block.

If the 2nd molar is carious, remove it to leave space for the 3rd.

If the 2nd molar is normal, and the impacted 3rd molar is at a nearly normal angle, use bone forceps or dental forceps to nibble away the jaw behind it.

If the 3rd molar is completely horizontal, split it with a chisel, and then extract it in 2 parts, with any convenient forceps.

AN IMPACTED 3RD MOLAR

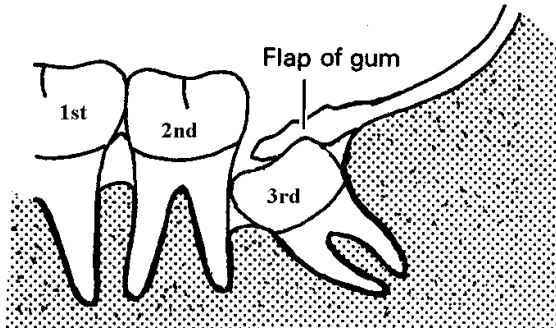


Fig. 31-10 IMPACTED WISDOM TOOTH.
This 3rd molar is lying obliquely in the jaw and is covered by a flap of gum. Food may be trapped and inflammation results.
Kindly contributed by James Gardiner.

31.5 Cancrum oris

(Gangrenous stomatitis, Noma)

Cancrum oris is not uncommon. It is a gangrenous process of the mouth which starts suddenly, rapidly involves the adjacent tissues of the face, quickly becomes well demarcated, and then spreads no further. It most often affects one or both sides of the jaw, and occasionally the front of the face (mouth, lips, nose, and chin). Mixed organisms including *Fusiformis* and *Borrelia* are mostly responsible, but it is not contagious. It is a necrotizing fasciitis, and may be associated with simultaneous extra-oral gangrenous lesions of the limbs, perineum, neck, chest, scalp, or ear, etc, especially in the presence of HIV disease.

Although cancrum oris can occur at any age, it is most common in poor malnourished children from 1-5yrs whose general health has been further weakened by some infectious disease or depressed immunity. It was endemic in Nazi concentration camps during World War II.

The lesion starts inside the mouth, in association with acute ulcerative gingivitis, and then spreads to the lips and cheeks. The earliest stage, which you rarely see, is a painful red or purplish-red spot, or indurated papule, on the alveolar margin, most often in the premolar or molar region. This lesion rapidly forms an ulcer, which exposes the underlying alveolar bone. You can stage the extent of the disease by how much of the face is affected – grade 1 (<¼), 2 (¼-½), 3 (½-¾), 4 (>¾) – and describe the part affected: N(nose), O(outer cheek), I(inner cheek), T(trismus), U(upper lip), L(lower lip).

At this stage, there is a sore mouth, a swollen, tender, painful lip or cheek, profuse salivation, and an extremely foul smell, with purulent discharge from the mouth or nose. Within the next 2-3 days, a bluish-black area of discoloration appears externally on the lips or cheek. The gangrenous area is cone-shaped, so that much more tissue is destroyed inside the mouth than the external wound might indicate. After separation of the slough, the exposed bone and teeth rapidly sequestrate.

Quite extensive superficial lesions can heal surprisingly well. But destruction of the deeper tissues, teeth and skeleton can produce such appalling disfigurement that expert plastic reconstruction will be necessary. This may have to include: correction of gross mutilation, 'dental anarchy', trismus (particularly difficult) and a salivary leak. You can however treat the acute stage. Untreated cancrum oris is almost always quickly fatal, owing to associated illness (e.g. measles, typhoid, diarrhoea, pneumonia) or a complication, such as septicaemia or aspiration pneumonia and malnutrition. Secondary haemorrhage is most unusual.

CANCNUM ORIS

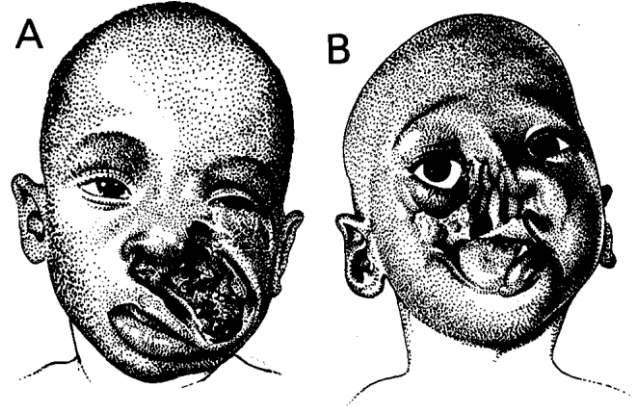


Fig. 31-11 CANCRUM ORIS.
A, cancrum oris in the acute stage, showing well-demarcated gangrene of the upper lip and adjacent cheek. B, typical example of the gross facial mutilation that follows.
After Tempest MN, *Cancrum Oris*, *Tropical Doctor* 1971;1(4):164-9 with kind permission of the editor.

Early treatment of cancrum oris

Start emergency treatment *immediately*, and aim to build up the child's immunity. Correct protein energy malnutrition and electrolyte losses, by normal feeding if possible. If the mouth is too sore, start nasogastric feeding. Correct the anaemia using folic acid, iron, vitamin C and B complex, particularly B3 and niacin, and blood transfusion if necessary. Treat with penicillin in large doses and metronidazole. Repeatedly irrigate the lesion. Debride septic surfaces; use hydrogen peroxide. Pack cavities with gauze pads soaked in hypochlorite ('Eusol'), saline, or BIPP. Change these dressings often, and keep them moist by adding more solution to the outer layers. Chewing raw pineapple, or slices of orange, will help to clean the mouth. *Avoid petroleum jelly gauze* (which acts like a foreign body), *especially when it has been impregnated with antibiotics.*

In a fit child, cut away any separating dead tissue, and remove any loose teeth or sequestra (dead bone). When quite large sequestra are ready to separate, you may be able to remove them under ketamine.

In an unfit child, allow the dead tissues to separate spontaneously. Sequestra occasionally drop out. More often, they have to be removed after 3-4wks, when the child's condition has improved enough for surgery to be safe. Check for intestinal worms and schistosomiasis.

CAUTION! There is no place for radical surgery at this stage, except to control bleeding (rare).

Try to organize reconstruction at 3-6 months, before marked trismus develops. This will allow the scars to mature, the local tissues to become supple and soft, and the child's health to improve. Meanwhile, maintain good nutrition and oral hygiene.

These children have major psychological difficulties of adjustment; do all you can to help them.

31.6 Jaw swellings

Lesions which make the jaws swell, apart from trauma, are:

- (1) Infection: an alveolar abscess (6.9), a dental sinus, actinomycosis and osteomyelitis (7.14).
- (2) Various types of dental cyst.
- (3) Tumours: Burkitt's lymphoma (17.6), ameloblastoma, carcinoma, salivary tumours (17.7), and giant cell tumours (31-13D).
- (4) A complex group of fibro-osseous lesions.

Actinomycosis classically follows oral surgery, or may complicate poor dental hygiene; infection arising from *Actinomyces israelii* spreads across tissue planes and results in a woody hard swelling around the mandible, resulting in sinuses discharging yellow 'sulphur-like' granules.

N.B. These are not sulphur at all, just yellow in colour; they stain blue under microscopy.

Osteomyelitis results, and infection may spread to the base of the skull, giving rise to cranial nerve lesions. There is no lymphadenopathy early on as the bacillus is too large to pass in the lymphatics; lymphadenopathy implies secondary infection.

You should drain pus, excise fistulae and remove necrotic tissue; however, the definitive treatment is till acute infection has settled and then oral penicillin for 2-6 months. In case of penicillin allergy, you can use erythromycin or doxycycline.

A dentigerous cyst forms round the apex of a chronically infected, and usually non-vital, tooth, commonly in an older patient. Chronic infection causes the epithelial remnants in the periodontal membrane to grow and become cystic. Dental cysts are usually quite small, and are commonly symptomless. Occasionally, they grow large enough to expand the alveolus in which they arise. In the maxilla they may extend into the sinus or the nasal fossae. It expands the lateral aspect of the jaw while the stronger medial side resists deformation. The tooth which forms the cyst usually fails to erupt, and you can see that it is missing from its normal place in the mouth. If this tooth is normally placed, opening the cyst may allow it to erupt. Often, it is so misplaced that it cannot erupt, and needs enucleation. The fluid it contains is usually clear, but may contain cholesterol crystals. The lesion may be hard, tense, or fluctuant. If the bone over a cyst is thin, it may crackle like an eggshell when you press it. Radiographs show a clearly defined, well-corticated, unilocular radiolucency, unless the cyst is infected, which causes it to lose its cortex.

An odontogenic keratocyst (rare, developmental) is filled with keratinized epithelial squames. These make the contents creamy, so that it looks like pus, and can only be distinguished from pus microscopically. *Don't confuse this cyst with an abscess*; there are no signs of infection. Radiographs show a well-corticated uni- or multi-loculated radiolucency. These cysts are particularly likely to recur after they have been removed (20-60%), so need radical surgery.

Developmental cysts (rare) are not associated with teeth. The commonest one is a nasopalatine cyst, which develops from epithelial remnants in the nasopalatine canal, immediately behind the upper front teeth. If it is causing problems, it should be enucleated. If this is impractical, you may have to open it out, taking care not to injure the incisor teeth and their supplying vessels.

Treatment of jawbone cysts

Simple methods are to:

- (1) Marsupialize a cyst, by removing the mucosa over it, together with the immediately underlying bony wall and lining, washing it out, and then suturing the lining of its floor to the surrounding mucoperiosteum. This relieves tension, stops further expansion, allows drainage, and lets the space the cyst occupied slowly fill up from the bottom.
- (2) Lay a cyst open.
- (3) Decompress a dentigerous cyst, by opening it, and allowing the tooth in it to erupt.

Dentigerous cysts

(1) EXAMINATION

Stand exactly in front of the patient and inspect the face carefully for asymmetry, especially of the mouth, nostril, and the level of the inner canthi (corners of the eye). Feel the mass carefully. Most dental cysts which arise from an apical infection are small (<1cm), most dentigerous cysts are quite large (3-8cm). Examine and count the teeth.

If a tooth is missing (and has not fallen out), it may be hidden in a dentigerous cyst.

If one tooth in a line of permanent teeth is much smaller than the others, it might be a persistent milk tooth, with the missing permanent one hidden in a dentigerous cyst. Aspirate and examine the fluid from the swelling with a wide-bore needle. If you withdraw clear yellow fluid, it is a cyst. If you withdraw a substance that looks like pus, it is either true pus from an infection, or a mixture of keratinous squames from an odontogenic keratocyst. Microscopy will tell you which of these it is. Look for dental sinuses (31-9) on the gums or face.

(2) RADIOGRAPHS

Take films in 2 planes. Compare the density of the sinus shadows on either side. A cyst is an area of radiolucency surrounded by a radio-opaque line. If there is a tooth in the cyst it is dentigerous, otherwise it is probably dental.

MARSUPIALIZING A CYST

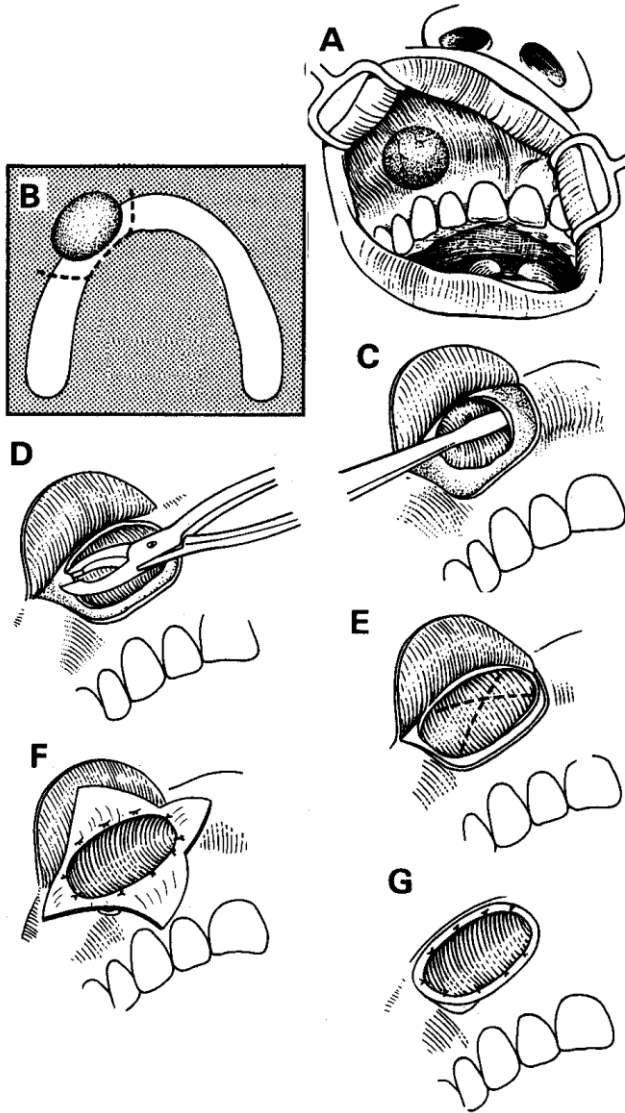


Fig. 31-12 MARSUPIALIZING A CYST.

A, a cyst on the gum. B, reflect the area of the mucoperiosteal flap. C, remove the bony roof of the cyst. D, trim the bone from the edges of the cyst. E, prepare to incise the lining of the cyst. F, open the cyst. G, marsupialization complete.

Adapted from Howe GL, *Minor Oral Surgery*, Wright 2nd ed 1971 p.194 with kind permission.

CAUTION!

- (i) Be careful to distinguish a cyst in the maxilla from a normal part of the maxillary sinus: this can be difficult.
- (ii) The signs that indicate that the lesion is not a simple dental cyst but a more aggressive lesion are:

(a) A multilocular ('honeycomb') radiolucency, indicating an ameloblastoma, an odontogenic keratocyst, or a giant cell tumour.

(b) A loss of cortex, indicating an aggressive lesion, particularly a carcinoma. If a benign cyst is infected, it may also lose its cortex.

(3) MANAGEMENT

If a dentigerous cyst is small and symptomless, leave it.

If it is small but is causing symptoms, remove the tooth and curette the cyst.

If a dentigerous cyst is large, and especially if it is in the upper jaw (unusual), remove the tooth. The danger is that you may produce a fistula between the mouth and the nose or the maxillary sinus. This usually needs surgical closure.

If the dentigerous cyst is <1.5cm diameter, marsupialize it, especially if it is in the lower jaw.

(4) MARSUPIALIZING A CYST (GRADE 2.4) INDICATIONS

- (i) An easier alternative to enucleation for a larger dental cyst.
- (ii) A small dentigerous cyst.
- (iii) An elderly patient, in whom there is a risk of pathological fracture.

ANAESTHESIA. Use a combination of LA and regional blocks. You may prefer to add ketamine. Thoroughly clean the mouth first.

INCISION

You can approach all cysts from inside the mouth, unless you need also to resect the jaw.

Approach the cyst from the side of the jaw on which the swelling is greatest. If it is equal on both sides, approach it from the buccal side. Reflect a large mucoperiosteal flap (31-12B). Remove bone over the same site (31-12D). Remove the superficial part of the lining (31-12E), so as to expose the cavity widely, and render the deeper part of its lining continuous with the oral mucosa. Wash out the cyst, and examine its lining for signs of neoplastic changes. If there is more than a little tissue in it, suspect that it might be an ameloblastoma. Send any material you remove for histology.

If you are marsupializing a dentigerous cyst, be sure to remove all the epithelium, or it may grow again. To do this, remove all the soft tissues on the outside of the bony cyst wall. Remove the tooth at the same time. Leave it open to granulate.

If a dentigerous cyst is related to a permanent tooth, the tooth is likely to be non-viable. It might be saved by root canal treatment, but you will probably have to remove it. If it is related to a deciduous tooth (unusual), remove the tooth.

If the bone is much expanded and the bony wall of the cyst is thin, consider compressing it to reduce its size.

Pack the cavity, and remove the pack at 48h or earlier. Continue with thorough mouthwashes until it has healed. Insist on washing out the mouth after meals.

CAUTION!

Be sure to make a wide opening. If it is too small, it will close, and the cyst will recur.

(5) LAYING OPEN A CYST INDICATIONS

An infected or 'messy' cyst, with a lining which you cannot completely remove, or a flap which you have to sacrifice.

METHOD

Remove the tooth associated with a dental cyst, unless it can be root-treated. Open the cyst, remove as much of its lining as you can, and then pack it with BIPP-impregnated gauze. Reduce the bulk of this over 4wks, to allow the cavity to granulate slowly from its base.

(6) ENUCLEATING A CYST

More advanced methods include enucleating a cyst by reflecting a periosteal flap, opening it, removing all its lining, and then replacing the flap. This is more difficult than the preceding methods. GA with tracheal intubation is essential.

Approach a cyst in the upper jaw through the outer aspect of the socket. Approach a cyst in the lower jaw through an incision 1cm below the lower border of the mandible, or inside the mouth, through the labial side of the socket. Infiltrate the tissues with adrenaline in saline (3.1).

Clear the bony covering of the cyst, fracture its eggshell surface, and remove a piece of bone from its most prominent part. Nibble away more bone, and push the cyst off the bony wall of the cavity in which it lies. If it is a dentigerous cyst, its lining will be held round the tooth it contains.

BENIGN TUMOURS OF THE MOUTH

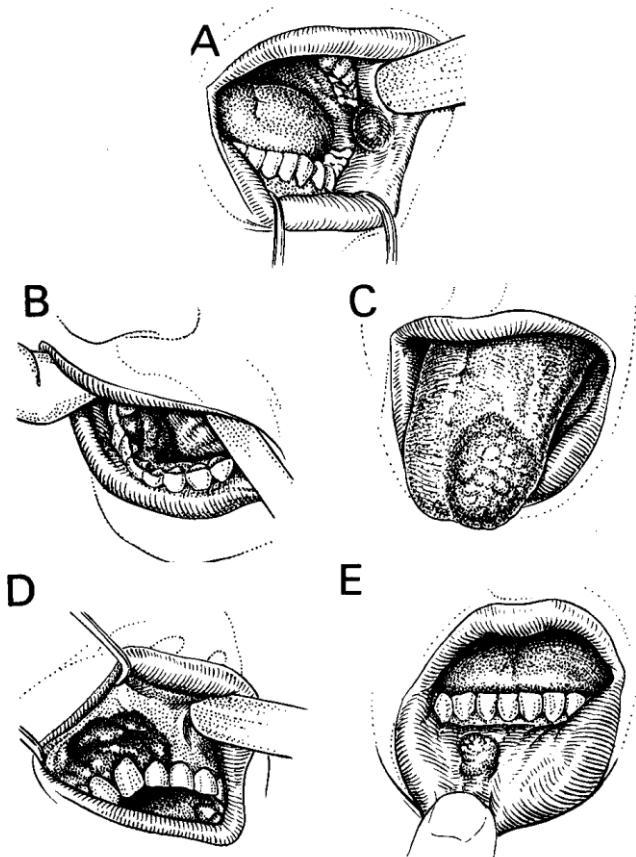


Fig. 31-13 BENIGN TUMOURS OF THE ORAL CAVITY. A, a fibroma. B, a pregnancy epulis (a benign gingival growth, 31.9). C, a haemangioma of the tongue. D, a giant cell tumour. E, a hard papilloma (31.9).

Adapted from drawings by Frank Netter, with the kind permission of CIBA-GEIGY Ltd, Basle, Switzerland.

You need an expert to excise a piece of jaw with a tumour. This may be:

(1) A **giant cell tumour** which is only locally invasive, but may grow very large if it is not treated (37-4).

(2) An **ameloblastoma** (adamantinoma), which arises inside the jaw from the enamel organ of a tooth, and slowly destroys the surrounding bone. It may be solid or cystic, it is locally invasive like a basal cell carcinoma, and does not metastasize.

You are unlikely to miss an ameloblastoma if you remember that: (a) the radiolucent lesions it produces are commonly multilocular (the cysts described above are mostly unilocular), (b) the solid tissue from around any 'cyst' should be sent for histology, which is the only certain way of making the diagnosis (the cysts described above are filled with liquid). An ameloblastoma requires radical removal.

(3) An **odontogenic keratocyst**, an **ossifying fibroma**, a **carcinoma**, or a **fibrosarcoma**.

31.7 Cleft lip and palate

(a) Cleft lip

This may be variable in extent, and is often associated with cleft of the tooth socket or palate. It is usually unilateral, but may be bilateral. Defects of the midline or oblique facial clefts are more complicated and of different embryology.

The Millard rotation advancement repair is the most popular; you should only attempt correction if the baby is in good nutritional state, and preferably >9 months old.

Make sure you have a fine marking pen and indelible ink or dye. *Don't attempt this operation if your experience is limited and your supply of fine sutures limited: getting a good cosmetic result on a re-do is very difficult.*

MILLARD CLEFT LIP REPAIR (GRADE 2.5)

Mark the points 2 to 4 on the child (31-14A), and infiltrate with lidocaine/adrenaline solution (3.1).

Incise through full thickness of the lip at points 4f and 5g so their thicknesses are equal, and along the dotted lines 4h and 5e, these also being equal. Make a curved extension 4a and an equal curve laterally dc under the *ala nasae*.

Preserve a small 'C' flap so that cd'e5 fits into 4'ab4. This allows for closure of the nostril. Close the flaps with buried knots using 4/0 absorbable suture so that points 45 and fg align. Suture the skin with 5/0 nylon, and paint the wounds with chloramphenicol ointment qds. If you leave one length long, you can use this as a stay suture for easy retraction whilst you complete the remaining sutures.

Restrain the child from tampering with the wound by splinting the elbows at 45° flexion; make sure he is fed a sloppy diet with a spoon and uses mouthwash after eating. Remove the sutures after 4 days, preferably under ketamine.

If there is a **bilateral cleft lip**, repair the more severe side first, and then a month or two later do the other side. If the philtrum protrudes anteriorly, you can strap it back for a few months before surgery; protruding teeth will need to be removed because they will get in the way. (It is possible to repair a bilateral cleft lip in one sitting, but this is for the expert.)

MILLARD CLEFT LIP REPAIR

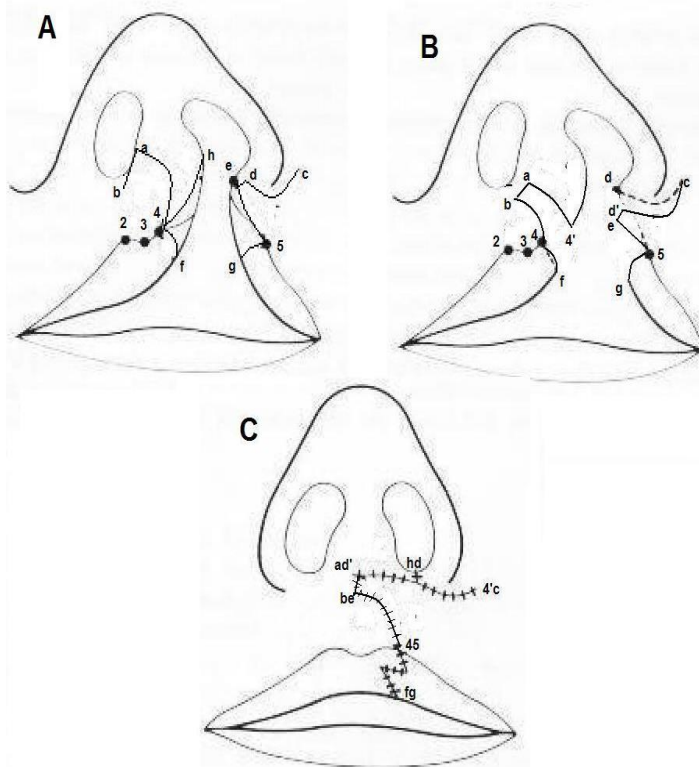


Fig. 31-14 MILLARD CLEFT LIP REPAIR.

A, 3 is the centre of the lip (Cupid's bow); 2 is the peak of Cupid's bow on the normal side; 4 is the projected point equivalent to the point 2 on the affected side, so that $23=34$; 5 is the start of the mucosal thickening of the cleft side, so that $5g=4f$; h is the medial extremity of the open nasal sill on the cleft side, and e the lateral extremity. The lip vermilion does not usually reach these points. B, intra-operative view: divide the upturned cleft lip across $4f$ and $5g$ such that these are equal. Cut $4h$ so $4h=5e$; cut a curved extension $4a$ where a is the medial border of the nasal sill on the unaffected side; this effectively removes the abnormal lip tissue (and makes the defect look bigger and worse!). Cut a C flap to allow plastic nostril closure: cut $cd=a4$. Extend an incision along the nasal sill $ab=de$ to make the C flap fit nicely. C, end-result: points fg , 45 , be , ad' , hd , and $4'c$ are all joined together. The Z-plasty closing the upper lip is optional: omit it if you are unfamiliar with it or you don't have very fine instruments.

After Kirk RM, Williamson RCN. *General Surgical Operations Churchill Livingstone 2nd ed 1987 p.563 Fig 31.26.*

(b) Cleft palate

If milk comes from a baby's nose as he sucks, suspect that there is a cleft palate. This is often, but not always, associated with a cleft lip. It may be unilateral or bilateral. Cleft palates are much more difficult to repair than cleft lips. You should not operate before c.12-18 months, before the child tries to speak, and when he should be fit enough for a major operation, if he has been adequately fed. Breastfeeding is a major problem, except for minor clefts of the soft palate only, which need no treatment.

Try a cup and spoon. Alternatively make a feeding spout to fit a standard feeding bottle (31-15). If this fails, he will have to be fed through a nasogastric tube, until he is stronger, when cup and spoon feeding may be possible. A special plate, supported by 2 wire arms on the cheek, can be constructed in the first few days of life, to bridge the gap in the cleft palate.

SPATULATE FEEDING SPOUT

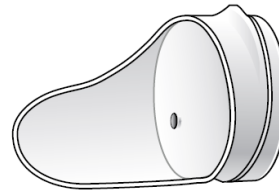


Fig. 31-15 SPATULATE FEEDING SPOUT.

Attach this to a feeding bottle and squeeze it to deliver a bolus into the spout.

After Jones PG, Woodward AA. *Clinical Paediatric Surgery, Blackwell 3rd ed 1986 p.210 Fig 24.4.*

Good dental care is essential. These children are prone to recurrent ear, nose and throat infections, and particularly get 'glue ears' (29.2,4).

Experts can do the surgery in theatres with basic facilities: if a programme for cleft repairs can be set up in your district, this is the best chance for your patients.

31.8 Oral tumours

Carcinoma of the mouth accounts for c.30% of malignant tumours in India. It is a disease of the poor, of both sexes, and is caused by:

- (1) Chewing *paan* (betel leaf) with tobacco and slaked lime. *Paan masala* (spiced betel nut) chewing is popular in India, and results in oral submucous fibrosis: this is pre-malignant and ultimately results in cancer.
- (2) Reverse or 'chutta' smoking.
- (3) Smoking cheap 'bidis' (rolled tobacco leaves).
- (4) Poor oral hygiene, especially associated with vitamin A deficiency, and low iron levels.

The patient, who is usually elderly, presents with:

- (1) An area of dry, blanched leathery mucosa subsequently becoming thick or indurated,
- (2) Inability to open the mouth (trismus), whistle and blow out the cheeks.
- (3) A painless mass.
- (4) An ulcer.
- (5) A sore throat or dysphagia (late).

Because the disease is painless, poor patients are usually unaware of the danger and present late. Yet the mouth is easily accessible, so teach health workers to examine the mouths of their patients always.

Carcinoma can occur anywhere on the lips, or inside the mouth. It most commonly involves the buccal mucosa, but it may involve any part of the tongue, the floor of the mouth, the alveolus, or the hard palate. It commonly occurs in the gingivobuccal groove, where betel leaf is kept to chew later.

There are several kinds of tumour:

- (1) Squamous cell carcinomas (90%). A few of these are slow-growing, cauliflower-like 'verrucous carcinomas' with a good prognosis.
- (2) Adenocarcinomas arising from ectopic salivary glands (5%).
- (3) Kaposi sarcoma, associated with HIV disease: these are typically purplish raised lesions.
- (4) Other sarcomas (rare). Most tumours spread to the lymph nodes on the same side, and bloodstream spread is rare. The prognosis depends on the extent of the local disease, and whether or not there is cervical metastasis.
- (5) Melanoma; most black-pigmented spots though are benign.

Precancerous lesions occur as:

- (1) leucoplakia (white patches: dyskeratosis),
- (2) erythroplakia (leucoplakia interspersed with reddish spots),
- (3) submucous fibrosis,
- (4) chronic dental ulcers.

Surgery and/or radiotherapy gives excellent results in early cases. In late cases radiotherapy reduces bleeding, discharge, and smell, and is useful palliation. If the buccal mucosa is involved, radiation is enough, but if bone is involved, resection of the jaw is also necessary.

MALIGNANT MOUTH TUMOURS

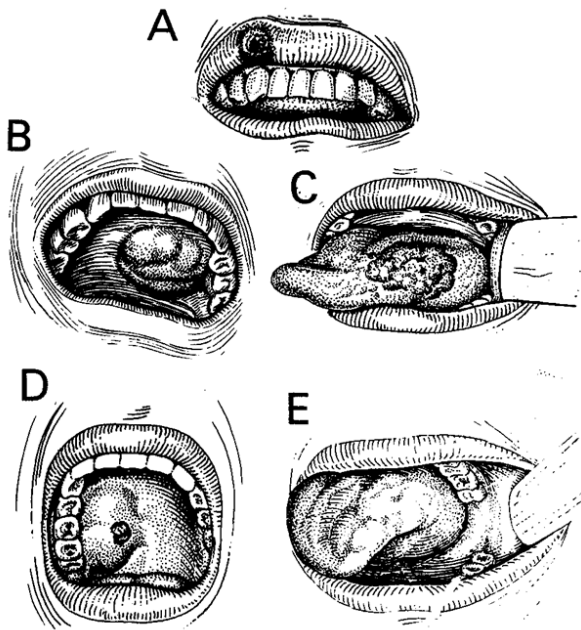


Fig. 31-16 MALIGNANT TUMOURS OF THE MOUTH.

A, early carcinoma of the lip. B, mixed tumour of the palate. C, carcinoma of the side of the tongue. D, carcinoma of the palate starting to ulcerate. E, leucoplakia of the tongue (this is precancerous). Adapted from drawings by Frank Netter, with the kind permission of CIBA-GEIGY Ltd, Basle, Switzerland.

(a) **Examination.** Any ulcer or lump in the mouth which does not respond to treatment in 2wks, you should suspect as being malignant and biopsy it. Feel for enlarged nodes in the neck.

(b) **Special tests.** Confirm the diagnosis with a punch or incision biopsy. X-ray the mandible, or maxilla, to detect local infiltration, and the chest for distant spread.

(c) **Management.** You can only satisfactorily treat these patients in the earliest stages.

If there is a lesion <1cm on the lips or tongue, excise it with a margin of at least 1cm. All other patients need chemotherapy, followed by radiotherapy and/or surgery. Verrucous carcinoma is best treated by surgery only, because radiotherapy causes it to become a rapidly growing anaplastic lesion.

If there is cancer of the mouth, and you can feel nodes in the neck on presentation, consider your options carefully. Patients with a potentially curable lesion with mobile nodes and no distant metastases may have a 25% chance of cure with skilled surgery. If nodes appear months or years after the primary has been treated, *and are still mobile*, radical dissection has a 30-50% chance of cure. Node biopsy may be useful. The nodes may be enlarged by infection. If in doubt, try antibiotics for a few days, and see if they become smaller. Adequate surgical excision may mean using an extensive delto-pectoral or forehead rotation flap. CHEMOTHERAPY is not curative, but there is a 20% response rate to x2wkly IV methotrexate at 40mg/m², with little further benefit from multi-dose regimes or more expensive drugs.

31.9 Other dental and oral problems

The range of possible oral pathology is large; some of the more important lesions are tumours.

(a) Mouth ulcers

If a patient has a recent, shallow, painful ulcer in the mouth, it is likely to be an APTHOUS ULCER, or a recurrent HERPETIC ULCER (both very common). The distinction between them is not important, since there is little you can do about either of them, and they will resolve spontaneously. Advise mouth washes, and try folic acid 5mg weekly, both as prevention and treatment. These ulcers are common in people taking the anti-malarial prophylaxis, proguanil.

If there is irregular ulceration of the gums, cheek or the floor of the mouth, suspect that this is a CARCINOMA (uncommon), especially if it has a raised edge. Send tissue for histology and arrange deep radiotherapy, or radical surgery.

Mucocutaneous leishmaniasis (34.7) is endemic in Bolivia, Brazil and Peru, and is transmitted by the sandfly from other infected humans, dogs or rodents. Itchy papules arise at the mucocutaneous junction of the lips and nose, and ulcerate. With spread by lymph and blood, tissue destruction may become extensive, requiring plastic reconstruction.

Paracoccidiomycosis (blastomycosis) is frequent in parts of Central and South America, particularly Brazil. It occurs between the ages of 20-40yrs. The fungus is inhaled from vegetables or the soil, and implanted through breaks in the skin or mucosa, resulting in haemorrhagic papules which soon ulcerate. Regional lymphadenopathy is common, and the intestines may also be involved. Use ketoconazole 200-600mg od if you can make a diagnosis early. The problem with the disease is gradual destruction of the mouth and nose, requiring plastic reconstruction as for cancrum oris (31.5).

(b) Lumps arising from the alveolus

If there is a firm lump on the gum, it is probably a FIBROUS EPULIS (common, especially in pregnancy). Very few of these lesions are fast-growing, and if a lump is soft, bluish, and grows rapidly, it may be a sarcoma (very unusual). Excise it and send it for histology. If it is very extensive, try to refer to an expert periodontologist (if you can find one!) or a maxillofacial surgeon. It may be one of a wide range of obscure, rare, fibro-osseous lesions.

If there is a soft swelling on the gum, between two teeth, or on the palate, and associated with chronic infection, it is probably a PYOGENIC GRANULOMA. It is related to HIV disease, when it is often very vascular, and may simulate a malignancy. Pyogenic granulomas are common inside the mouth, and can also occur on the tongue. *Don't try to excise this during pregnancy.* Otherwise, excise it using infiltration with adrenaline, and provided the infection is eradicated, it will not return. Send any material you obtain for histology. Make sure there is no underlying osteomyelitis (7.14).

If a child has a loose tooth with a swelling of the jaw, suspect that this is BURKITT'S LYMPHOMA (17.6) if it is common in your area. Typically, the teeth are displaced.

(c) Lumps arising elsewhere in the mouth

If there is a pedunculated swelling on the cheek (or tongue), it is probably a FIBRO-EPITHELIAL POLYP or a fibroma (31-13A). This is commonly associated with repetitive irritating trauma, particularly that from an ill-fitting denture. Excise it and it will not recur, provided the trauma is removed.

If there is a papilloma (wart) inside the mouth (31-13E), it may be viral (verruca vulgaris or condylomata associated with HIV disease), and there may be similar lesions on the hands and genitalia. If necessary, excise the oral lesion.

If there is an expanding tumour of the mandible, with a radiograph showing large loculi and a honeycomb appearance, suspect that this is an AMELOBLASTOMA (31.6).

(d) Cysts of the mouth

If there is a bluish, translucent, raised vesicle 0.2-2cm diameter, it is probably a MUCOUS RETENTION CYST

(31-17C). These cysts may arise from the mucous glands anywhere inside the mouth, including the tongue, but are most common inside the lower lips. They may arise in a few days, persist for months, periodically discharge their contents, and then recur. Try to excise the lesion; if you merely incise it, it is likely to recur.

If a child has a circumscribed, fluctuant, often bluish swelling of the alveolar ridge, over the site of an erupting tooth, it is probably an eruption cyst. This is common, usually symptomless, and bursts spontaneously to allow the tooth underneath to erupt. If it does not, under ketamine, grasp it with toothed forceps, and excise it. A little dark blood will escape, and the underlying tooth will erupt within the next few months.

If there is a slowly enlarging painless unilateral swelling on the roof of the mouth with normal mucosa over it, it is probably a RANULA (31-17A). This is a particular form of retention cyst, arising from the inferior aspect of the tongue, and caused by blockage of the submandibular duct. If you remove it entirely by careful dissection, it will not recur. If this is difficult, deroof it; it may, but will probably not, recur.

It may also be a SUBLINGUAL DERMOID CYST (31-17B), which is a rare developmental cyst in the line of fusion of the 1st branchial arches. The epithelium lining it is thicker than that of a ranula. Although it arises in the midline, it usually displaces the tongue to one side. Dissect it out cleanly, and take care not to injure the submandibular duct.

CYSTS OF THE MOUTH

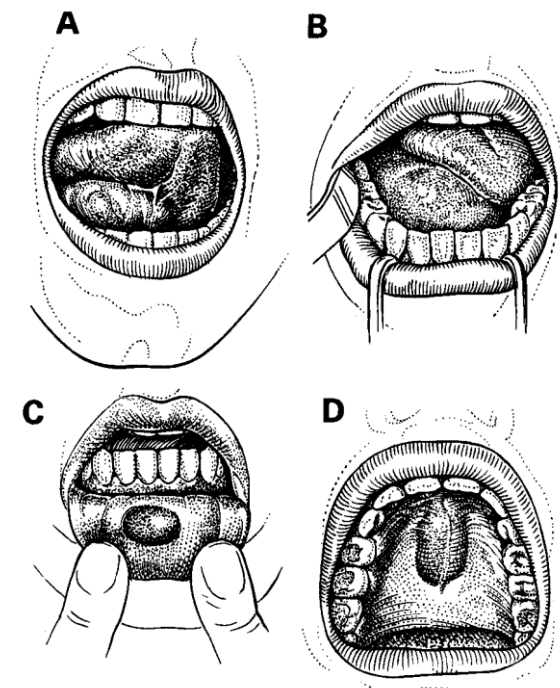


Fig. 31-17 CYSTS IN THE MOUTH.

A, ranula. B, sublingual dermoid cyst. C, mucocoele of the lip. D, secondarily infected nasopalatine cyst.

Adapted from drawings by Frank Netter, with the kind permission of CIBA-GEIGY Ltd, Basle, Switzerland.

If there is a midline swelling in the middle of the mouth, it may be a rare NASOPALATINE CYST (31-17D), which may have become secondarily infected. More likely, it is a pleomorphic adenoma (mixed salivary tumour) in an ectopic site.

(e) Tongue-tie (Ankyloglossia)

In neonates the lingual fraenum seems short and attached to the tip of the tongue; appearances change in the next 1-2yrs and the tongue is actually perfectly mobile protruding easily over the lower incisor teeth.

Poor speech is almost invariably due to *hearing deficiency* or *brain damage*. True tongue-tie is very rare and causes the tongue to indent deeply in the midline on protrusion, and requires a Z-plasty correction: this is a procedure that requires proper GA, mouth packing, good lighting and good equipment!

(f) The mouth in facial palsy

If a patient cannot close the mouth because the facial nerve is paralyzed, because of leprosy, a stroke, or parotid disease or surgery, the gums may dry and he may dribble food and drink and become socially outcast. His teeth will also be more susceptible to caries.

One solution is a *plantaris* or *fascia lata* tendon transfer to support the lip, by slinging it from the zygoma or temporalis fascia on both sides. Although this is a static sling, it will keep the mouth closed, improve its appearance, and stop the dribbling. If there is no lagophthalmos (lid-lag: 28.17), try to arrange a temporal muscle transfer to reactivate the mouth.