

# 34 Surgery of the skin & soft tissues

## 34.1 Hypertrophic scars and keloids

A surgical scar, especially if it is on the face, should be nearly invisible if made along Borges's lines (34-1). These are relaxed skin tension lines and differ from the Langer cleavage lines, especially on the forehead, mid-cheek, scalp and lateral to the eyes, and over joints. Sometimes a scar becomes very visible indeed as the result of hypertrophy and keloid formation. Both these processes can follow surgery, tattooing, infection or almost any breach of the skin surface. Both cause large scars, and are identical histologically, but they behave differently. Keloids are difficult to treat. If you excise one through normal skin and graft the gap, it is likely to recur round the edges of the graft, or in any gaps or splits within the graft. Both a hypertrophic and a keloid response are more likely if a wound is infected, contaminated by foreign material (even monofilament sutures), or under tension.

### TYPES OF SCARS AND LANGER'S LINES

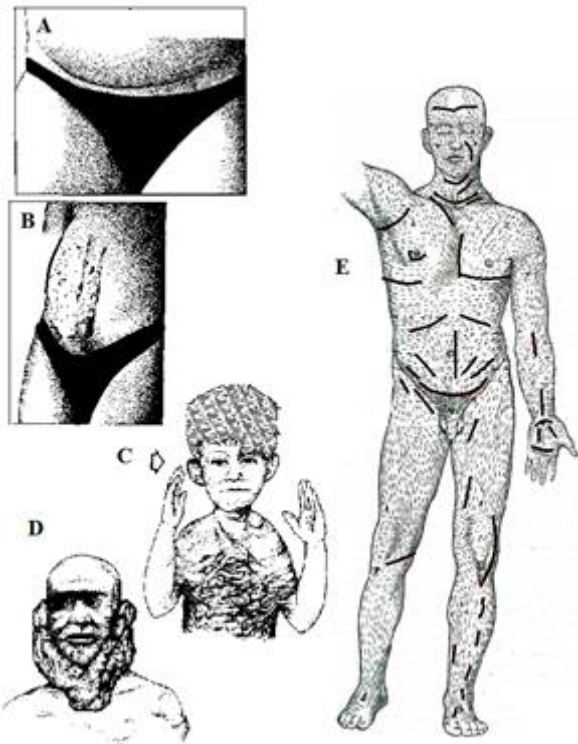


Fig. 34-1 TYPES OF SCARS.

Both patients had laparotomies c.8 months previously: A, the Pfannenstiel incision in the skin crease has healed almost invisibly. B, the vertical scar has formed a keloid. C, hypertrophic scarring on the chest after burns. D, keloid neck scar. E, incisions along Borges's lines are not under tension and form less keloid: they differ from Langer's lines on the face and joints.

After Bowesman C, *Surgery and Clinical Pathology in the Tropics*, Livingstone, 1960 with kind permission.

(a) **Differential diagnosis** may be difficult early on.

**Suggesting a hypertrophic scar (34-1C):** abnormal uniform growth starting within weeks of injury, growth restricted to the confines of the original scar, darker than surrounding skin, spontaneous regression in 6 months to 3yrs to become broad, soft, thin, and level with the surrounding skin, anywhere in the body, very common in burns scars, itching commonly which may be severe.

Give reassurance that it will eventually regress naturally. *Never operate during the active phase.* If you decide to operate, do so during the mature phase,  $\geq 3$ yrs after the original wound. Then, excise the scar, and apply the preventive measures above. Considerable improvement is possible.

**Suggesting a keloid (34-1D):** onset delayed for months/yrs, invasion of the surrounding skin, growth stops in due course but there is no regression, localized commonly on the earlobes, chin, neck, presternal area, and the midline, not uncommon in young black patients, uncommon in burn scars, very uncommon below the groin and where vascularization is poor.

If diagnosis is difficult, remember that a keloid becomes increasingly raised, and extends beyond the confines of the original scar.

### (b) Prevention of keloids and hypertrophic scars

Minimize tension in the scar by planning incisions in skin creases where possible. If you have to cut across a crease, use a Z-plasty (34-4).

Avoid scars in areas that are normally under tension:

- (1) in the neck especially,
- (2) in the coronal plane in the upper arm, especially its lateral side,
- (3) in the upper back.

*CAUTION! Midline sternal and abdominal scars and longitudinal incisions in the arm are particularly likely to develop keloids: they cross skin creases.*

Maintain careful asepsis, minimize trauma when you operate, and control bleeding carefully at the end of the operation. *Don't pull sutures too tight, and avoid mattress sutures. Avoid incisions in the midline and in visible sites.*

### POST-OPERATIVELY

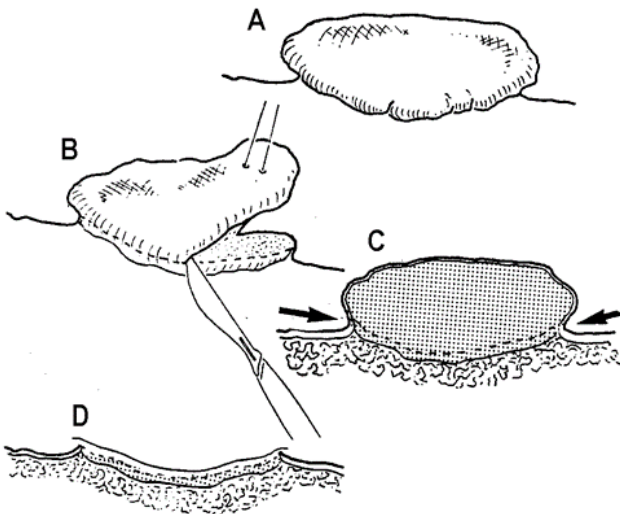
**If a patient is particularly likely to develop a hypertrophic scar or a keloid,** as shown by his previous history, apply pressure to the scar for 9-12 months after an operation. Ideally, a tight elastic garment (like sportswear) should be made to fit. This may not be practical, but you may be able to cut a piece of foam rubber to fit a smaller scar, and hold it in place with an elastic bandage. Tell the patient not to remove it except to wash. Unfortunately, both an elastic garment and an elastic bandage are difficult to tolerate for long, especially in a hot climate.

(c) **Treatment** is more successful if you start it early.

(1) For developing keloid, within 1-2 months of the injury, apply pressure and inject a 2ml suspension of hydrocortisone at each site spread out subcutaneously. Or, better, use triamcinolone 1ml at 3wk intervals x4.

(2) For an established keloid, *steroids have no effect. Resist the request to operate.* The worse the keloid, the more likely it is to recur if you excise it. Operate only on those keloids that are infected or cause functional deficit (*e.g.* over a joint). If you operate, excise the abnormal tissue *within* the keloid, leaving a margin of keloid tissue all round (34-2). Avoid sutures: use steristrips. If necessary, graft the bare area. You may be able to shave skin off the keloid and use this as a graft. All this is difficult, as is closing the wound tidily. Complete the incision and then inject steroid suspension into the scar. Post-operatively, administer 4 more steroid or triamcinolone injections at 3wkly intervals. Apply a pressure bandage or an elastic garment for 9 months: this is essential! You can use specially made compression ear-rings, but make sure they are worn rigorously, because otherwise your patient will end up with a bigger and uglier keloid than before!

#### A 'SHAVING' METHOD FOR KELOIDS



**Fig. 34-2 A 'SHAVING' METHOD FOR KELOIDS.**  
A, keloid mass. B, the way to shave it off. C, the plane through which to remove it. D, the graft in place ready for dressing.  
After Bowesman C. *Surgery and Clinical Pathology in the Tropics*, Livingstone, 1960 Fig. 194 with kind permission.

#### CAUTION!

- (1) Use a sharp knife.
- (2) *Don't pull on the keloid as you excise it*, or you may enter the subcutaneous tissue. Instead, if necessary, depress the surrounding tissues.
- (3) *Don't use diathermy.*
- (4) *Don't place sutures.*

## 34.2 Skin contractures

Whilst all contractures are functionally disabling, the approach to their treatment depends on whether it is the skin and underlying tissue or the muscles and joints that are primarily involved. Obviously skin contractures can lead to joint stiffness eventually, and joint stiffness to muscle atrophy and tightening of the skin; before these end-stage developments occur, you can still do much to alleviate the problems. However, try to determine whether the main problem is in the skin or the muscle and joint (32.1). Infected wounds and burns, especially across skin creases, will cause skin contractures, whilst ischaemia, poliomyelitis, leprosy, neuropathies, cerebral palsy, severe soft tissue and bony injuries, soft tissue and bone infections and arthritis of all kinds will lead to muscle and joint contractures.

Such may require repeated complex interventions which may daunt you. Consider gradual stretching of such contractures by using a distracting external fixator at a rate of 2mm/day (32.1). This is usually only possible after releasing a skin contracture, but may well avoid complex tenotomies.

Remember patients need close follow-up and prolonged splinting to prevent recurrent contractures.

Another odd cause of hand contracture, associated with excess alcohol intake, is Dupuytren's which causes a flexion deformity especially of the pip joint of the middle and ring fingers, particularly in men of 40-50yrs. Treat it like other contractures.

#### (a) Broad burns contractures

*If you wait for the expertise of a plastic surgeon in a referral hospital, a burn contracture is likely to become an almost incurable deformity.* If you are persistent and careful, you will not find them as difficult to treat in a district hospital as you might expect. You have skin loss to cope with, so they are more difficult than polio contractures (32.7). The post-operative care is half the battle. Insist on taking graft dressings off *yourself*: do this gently, with much soaks of water!

Contractures of the larger joints are not too difficult, but those of the hand are tasks for an expert; yet you may have to try. *They are certainly not the contractures to start with.* Contractures on the palm are slightly less difficult than those on the back of the hand, where the mcp joints readily become hyper-extended, as part of a claw hand. The joints are close to the surface and are involved early.

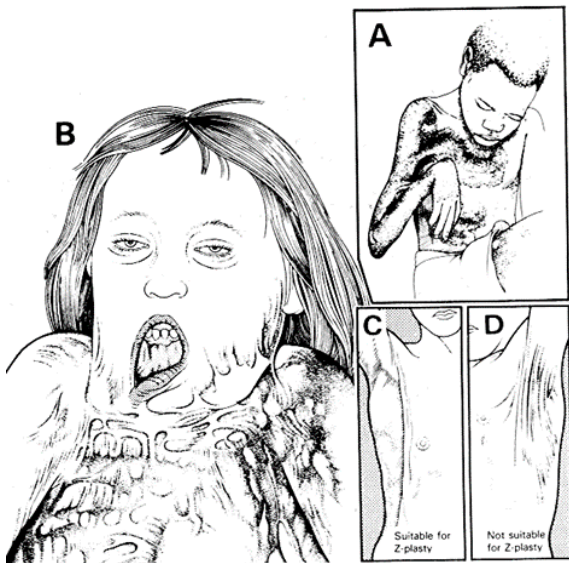
Fortunately, a child's joints don't become stiff nearly so easily as those of an adult. After you have grafted the flexor surfaces of a child's fingers, you can safely immobilize them in extension. Contractures may be linear or, more commonly, broad.

Excise linear contractures with a Z-plasty. Release broad contractures widely without excising all the scar tissue; then graft the bare area with a medium or thick split skin graft. Splint the limb in a position opposing the contracture, and start exercises as soon as the graft has taken (c.10-14 days).

Use sheets of thick split skin, meshed if necessary. The result is less good, though, than if you use unmeshed full-thickness graft. Make children your 1<sup>st</sup> priority: you will be much less successful with adults.

*Don't try to relieve burns contractures by using serial casts (32.1).*

### AXILLARY AND NECK CONTRACTURES



**Fig. 34-3 AXILLARY AND NECK CONTRACTURES.** A, contractures of the axilla, elbow and wrist. If the joints had been splinted in the positions of function, their contractures would have been prevented. B, contractures of the neck and axilla. C, a narrow contracture which is suitable for simple Z-plasty. D, a broad contracture which needs excision and skin grafting.

*Kindly contributed by Jack Cason, Ian MacGregor and Peter Bewes.*

#### (1) MANAGEMENT OF A BROAD CONTRACTURE (GRADE 2.3)

Wait until a burn has healed completely. This operation is not a task for the minor theatre. Administer iron and folate so that the Hb is >100g/L. Have blood cross-matched if you cannot use a tourniquet (3.4).

Infiltrate into and under the contracture a mixture of saline 80ml, 2% lignocaine 20ml, 1:1000 adrenaline 0.5ml, and preferably hyaluronidase 1500U. This solution will:

- (1) demonstrate the tissue planes more clearly,
- (2) allow you to separate the scar more easily,
- (3) control bleeding,
- (4) reduce the amount of GA needed.

Cut perpendicularly through the scar down to the subcutaneous tissue, in the middle of the contracture. Keep it under tension as you do so. If necessary, cut right down to the tendons.

Try to separate the scar from the deeper tissues by blunt dissection. Push your scissors into the tissues, then open them (4-9B). This will help you to avoid any superficial veins. It is wise not to try to excise the scar initially, either in the main part of the contracture, or at its upper or lower ends.

#### **CAUTION!**

- (1) Release the contracture first, and *then* decide how much more scar tissue you need to excise. You will always need more extensive incisions than you expect!
- (2) *Don't cut the deep fascia*, unless the scar tissue extends right through it.
- (3) Vessels in scar tissue do not contract, so bleed a lot. So, beware of congested veins, especially in the axilla and neck.
- (4) *Beware you don't expose nerves, tendons or joints that you cannot later cover!*

Carry the incision beyond the limits of the scar tissue, and beyond the axes of the joint on each side. If you don't do this, the contracture will recur. Or, make a double-Y (34-5D); this will reduce the length of the incision you need to make.

Start taking skin from the donor site. When the contracture is straightened out, you will need more skin than you expect. Cover the bare area with a sheet split skin graft, and suture it in place preferably with a tie-over dressing. Immobilize the area carefully, with splints or plaster of Paris in the position of full release of the contracture.

#### **CAUTION!**

Graft the exposed raw areas immediately, especially over joints. This will reduce the risk of the contracture recurring, and the risk of infection reaching the joint.

Remove the dressing *yourself* after 5 days. Keep the area in a night splint *for*  $\geq 3$  months. Maintain a regular review; you may need to make serial releases with several operations.

#### (2) RELEASE OF NECK CONTRACTURES

If the chin is contracted down on the sternum (34-3), *the anaesthetic problems are considerable: you cannot extend the neck to see the vocal cords*, unless you have a flexible bronchoscope over which you can thread an endotracheal tube. You may be able to use a laryngeal mask, but it is probably safer to infiltrate the scar with LA, administer ketamine, cut through the scar quickly, and then perform the intubation.

**METHOD.** Incise the scar transversely, if necessary almost from ear to ear. Carefully release the scar tissue by blunt dissection to reveal a huge gap in the front and sides of the neck. Try to apply a single sheet of split skin graft secured with a tie-over dressing. Immobilize the neck with the head well extended. To prevent recurrence, keep the neck in extension. Apply a soft collar as soon as the skin is soundly healed, and leave it there for at least 6 months.

A night splint is mandatory for several more months. If necessary, repeat the procedure, several times if required, to obtain a little more movement each time, particularly if the lips are involved.

### (3) RELEASE OF AXILLARY CONTRACTURES

Try to restore full abduction and elevation in a single operation. If there is a broad contracture, incise the scar as above, and abduct the arm. Apply a large medium-thickness split skin graft to the bare areas, and secure it with a tie-over dressing. Cover this with plenty of dry wool, and bandage this (preferably with crepe bandages) to include the whole arm as well as the axilla and chest.

**In a small child**, a large ball of cotton wool bandaged into the axilla may hold the arm in the right position.

**In an older child or an adult**, raise the head and back on a suitable support as for a hip spica, and apply a plaster shoulder spica to include the arm and hand, with the arm at 90° from the chest, the elbow flexed, and the wrist dorsiflexed. This is the most comfortable position.

#### CAUTION!

- (1) *Don't injure the axillary vessels or nerves.*
- (2) *Don't hyper-abduct the shoulder*, as you may injure the brachial plexus.

### (4) RELEASE OF ELBOW CONTRACTURES

A large scar may involve the whole flexor surface of the elbow. Make a cautious transverse incision across the fold of the elbow, starting laterally, and avoiding any congested veins. If the whole width of the elbow is involved, extend the incision into healthy tissue on each side. Find a fatty layer and then work gently medially. If you have found the right fatty plane, this should free up the scar tissue. When the incision is complete, divide any deeper strands of fibrous tissue. Fill the large diamond-shaped gap with a medium-thickness split skin graft. Secure it with a tie-over dressing. Immobilize the extended and supinated elbow in a cast which should also immobilize the wrist.

When the wound has healed, apply a cast of the elbow alone in extension for at least 6-12wks. *You are operating for a flexion contracture, so lack of flexion will not be a problem.*

### (5) RELEASE OF HAND CONTRACTURES

**If the contracture is mild**, a dynamic splint may cure it, or at least partially correct the deformity, so that operation will be easier.

**If the wrist is hyperextended**, divide the scar transversely, and apply a medium-thickness split skin graft: *beware of the median nerve and ulnar nerve and artery!*

**If the mcp joints are hyperextended as part of a claw hand**, this is a particularly difficult contracture, because the capsules of the joints may need opening up and freeing.

Make transverse incisions over their dorsal surfaces, flex them, graft the gap, and splint the hand in the position of function.

**If there are flexion contractures of the fingers**, incise them transversely maximally *taking care not to damage the digital nerves and arteries*, and fill the gap with a full thickness or a thick split skin graft sutured into place.

*For a child*, splint the fingers in extension for 3 months, or the contracture will recur. To help the cast stay in place, apply it with the wrist extended. Examine the cast daily at first, and later weekly, to make sure it has not slipped. *For an adult, don't immobilize the extended fingers for >10 days.* Use dynamic splints and night splints.

**If there is a very severe finger deformity**, you may need to amputate the finger, or arthrodesis it in the position of function.

### (6) RELEASE OF GROIN, KNEE, ANKLE, AND FOOT CONTRACTURES

Follow the general method, as described above, taking care to extend the incision well beyond the axis of the joint. Tendons may bow-string across the knee and prevent full extension: in this case you will need to make a tenotomy and tendon lengthening (32.8,10).

#### (b) Difficulties with burns contractures

**If you cannot get sufficient release of a contracture in a single stage**, release it as much as you can; splint it, leaving it open, and release it further after a few days, then graft it.

**If there is an ulcer within a scar**, think of squamous carcinoma: excise it with adequate margins and send it for histology (34.5).

### MOST SEVERE CONTRACTURES ARE THE RESULT OF POOR CARE

#### (c) Narrow burns contractures

A Z-plasty is a useful way of releasing a contracture, if it is narrow enough. It is not an easy method, but if your result is not perfect, you can always graft any bare areas that remain. Good results are easier to achieve than with wide contractures which need grafting.

Make a Z-plasty by excising the scar and then cutting 2 flaps in the form of isosceles triangles which share one common limb, and so form a Z. When you extend the limb, the triangular flaps will change their positions spontaneously. Initially, the 2 triangles together form a parallelogram, with its shorter diagonal in the line of the contracture, and its longer diagonal transversely across it (34-4C).

Releasing the contracture and transposing the 2 triangles changes the shape of the parallelogram, so that the new contracture diagonal is the same length as the transverse diagonal was before (34-4D).

The difference in length between the 2 diagonals determines the amount of lengthening in one direction and shortening in the other.

Transposing the triangular flaps increases any extra elasticity that there may be across a scar by at least  $\frac{1}{3}$ , and changes its direction of function.

Expert plastic surgeons find this useful for changing the direction of a facial scar, so that it lies along a Borges line (34-1): if you make one large 'Z', all the transverse shortening and all the tension is concentrated in one transverse diagonal (34-4E,F). But, if you make multiple 'Zs', the lengthening is additive, because all the contracture diagonals are in the same line, but the transverse shortening is spread out over several smaller 'Zs' (34-4G,H). In practice, you will not achieve quite as much lengthening with multiple 'Zs' as you would expect, but it is still a very useful method.

Unfortunately, as most burns usually cause scarring in all directions, there may be no lax tissue available, making a Z-plasty impossible. Where it is suitable, however, it is very effective indeed.

#### (d) Z-plasty (GRADE 1.4)

##### INDICATIONS

A narrow contracture of the axilla, elbows, fingers, knee or neck, especially one of the bowstring type, provided the surrounding tissues are reasonably lax and undamaged. If there is no transverse slack tissue to start with, a Z-plasty will not work on its own, but it still may be helpful combined with excision of scar and skin grafting.

##### A single 'Z' based on the whole length of the contracture.

This is useful if, at right angles to the contracture, the tissue is lax enough to allow some shortening in the transverse axis, and the bowstring is reasonably linear, not extending laterally: if this is the case, multiple 'Zs' would be wiser.

**Multiple 'Zs' (W-plasty).** This is necessary if the available lax tissue is not available at one point, but is spread out along the length of the scar.

##### SINGLE 'Z'

Use a pen to draw your proposed Z-plasty on the skin; the longer the transverse diagonal, the more length you will gain. Its length will however be limited by the amount of loose tissue available at the sides.

You have 2 ways of choosing the direction of the Zs. Select the best one by drawing equilateral triangles on either side of the central limb, in both of the possible ways. Choose the flaps which:

- (1) have the better blood supply,
- (2) avoid scarring across the base,
- (3) will give the best cosmetic result, and
- (4) are likely to rotate most easily.

##### CAUTION!

- (1) Angle the flaps as near to  $60^\circ$  as you can. Use a pre-cut  $60^\circ$  pattern. *The temptation is to make the angles too small: this reduces the length gained.*
- (2) Make the sides the same length as the central limb, except that if one flap is scarred, cut it a little longer than the other.
- (3) If you are worried about the possible viability of a flap, curve it a little (34-4B).
- (4) The tip of a 'Z' is the part most likely to necrose, so make sure you cut it deep enough. If necessary, include some of the underlying scar tissue.

##### Z-PLASTIES

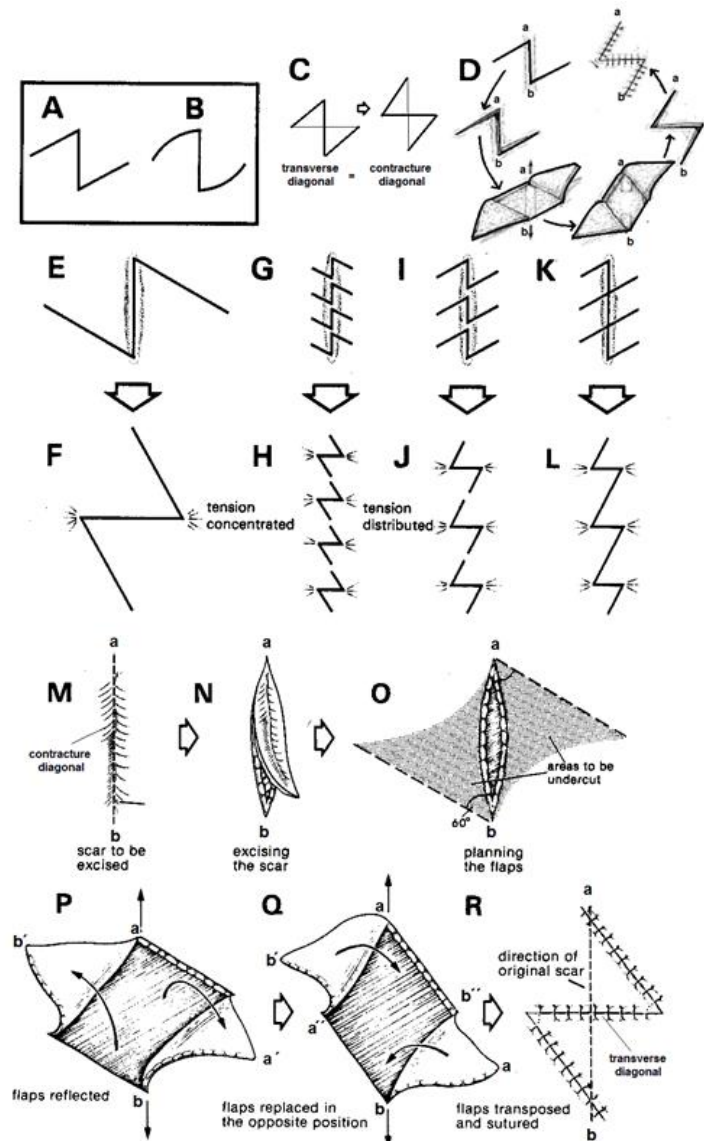
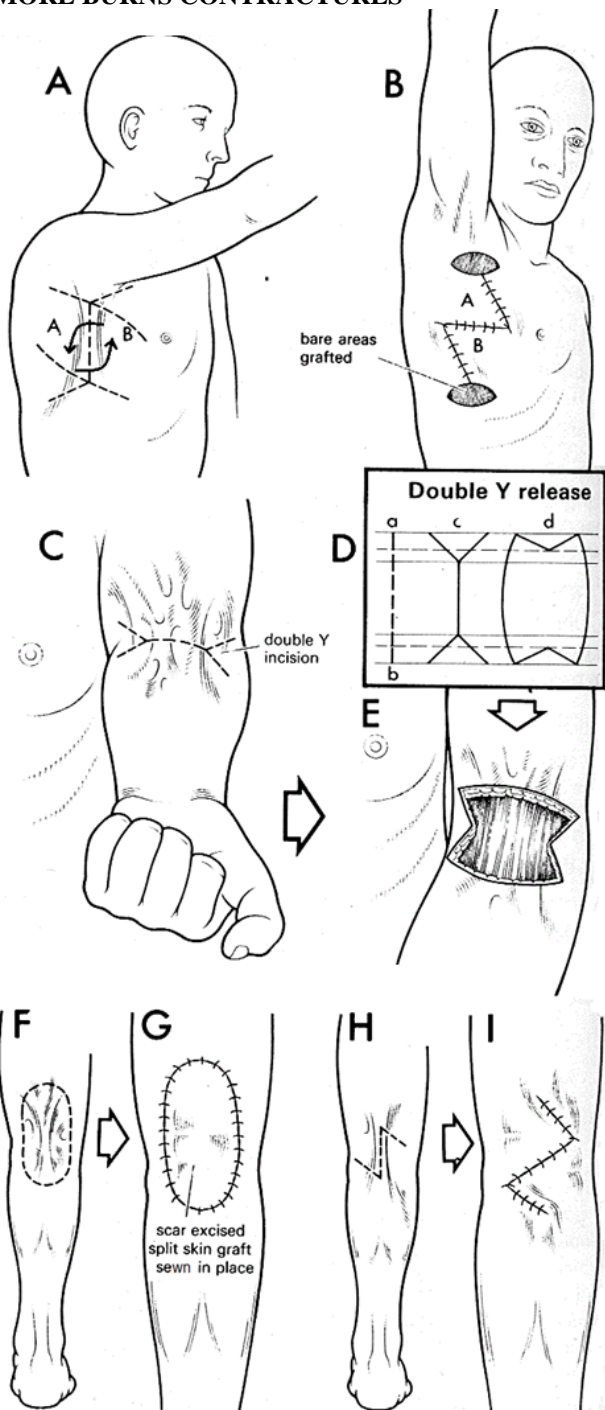


Fig. 34-4 Z-PLASTIES.

A, how flaps are usually cut. B, how to cut them if you are doubtful about their blood supply. C, initial layout of incisions, and how the flaps will transpose. D, final result: the contracture diagonal has lengthened and the transverse diagonal has shortened in equal measure. E,F, single 'Z' showing how the lateral tension is concentrated in a single line. G,H, multiple 'Zs' distributing the lateral tension. I,J, same but with fewer larger 'Zs'. K,L, 'Zs' joined up. M, scar. N, excise the scar. O, plan the flaps. P, raise the flaps. Q, transpose the flaps. R, the flaps in place: note the special suture at the apices.

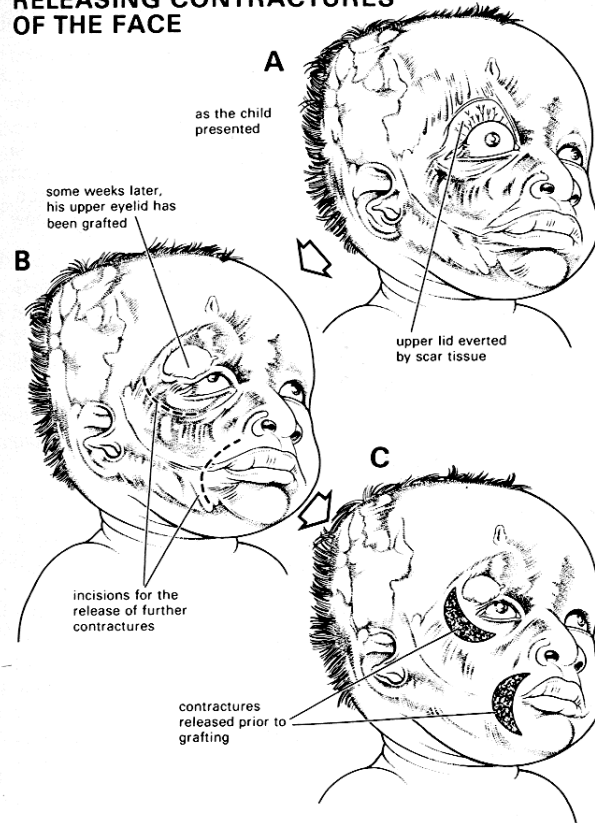
After MacGregor IA. *Fundamental Techniques of Plastic Surgery*, Churchill Livingstone 1980 with kind permission.

## MORE BURNS CONTRACTURES



**Fig. 34-5 MORE METHODS FOR BURNS CONTRACTURES.**  
 A,B, combining Z-plasties and skin grafting; make the Z-plasty with transverse incisions at each end of it. Open these to leave raw surfaces ready for grafting. C, contracture of the elbow showing a 'double Y' release incision. D, 'double Y' release. This will release the ends of the contracture maximally, without increasing its length: (a-b) the width of the scar, (c) 'double Y' to cover the full width of the elbow, (d) full release of the incision. E, 'double Y' incision ready for grafting. F,G, total excision of a scar with a split skin graft sewn in place. H,I, Z-plasty to treat a narrow popliteal contracture.  
 By the kind permission of Irving Feller & William C. Grabb, US National Institute of Burns Medicine.

## RELEASING CONTRACTURES OF THE FACE



**Fig. 34-6 RELEASING CONTRACTURES ON THE FACE.**  
 Make sure your grafts are big enough. These grafts are on the small side, particularly the first one. If you are experienced, you can avoid the 'trap-door' appearance of curved scars by making multiple Z-plasties.  
 Kindly contributed by Randolph Whitfield II.

### 34.3 Sebaceous (epidermoid) cysts

When the mouth of a sebaceous gland is blocked, a cyst results which is filled with creamy yellowish white sebum, into which you may be able to make a dent with your finger. Typically the cyst has a punctum at its centre. Sebaceous or epidermoid cysts are most common on the face, scalp and back, as hemispherical firm or elastic swellings, with no obvious edge, which are adherent to the skin.

Three complications may follow:

- (1) A sebaceous cyst can become infected; this makes it enlarge and become red and painful. Recurrent infection makes it adhere to the surrounding tissue, and become more difficult to remove. Often then you need to drain the abscess, and remove the cyst later when infection has resolved.
- (2) It can ulcerate, and discharge its contents. The lining membrane which is left can then resemble an epithelioma.
- (3) Its contents can escape, and become hard and form a sebaceous horn, which needs excision.

**(a) Excision of a sebaceous cyst (GRADE 1.2)**

Using LA, incise over the swelling, in the direction of the natural lines of the skin. This is particularly important in the face. *Don't use an elliptical incision*, which may later be difficult to close without tension. Deepen the incision very carefully until you reach the edge of the cyst. Push the points of fine curved scissors between the cyst and the tissue round it, and then open them, so as to define a plane for dissection. Repeat this all round the cyst until it is free, then try to remove it intact with a snip of the scissors.

Press firmly with dry gauze for 2mins to stop bleeding. If any bleeding vessels remain, tie them off. Close the skin, leaving a small Penrose drain (4-14B) in place unless the cavity is completely dry. Remove this at 24-48h.

**(b) Difficulties with sebaceous cysts**

**If the cyst is infected**, incise and drain it but *make no attempt to excise it till the infection has settled*.

**If the cyst ruptures**, try to remove all of its lining by operating gently with fine instruments; if you leave some behind, the cyst is likely to re-form.

**If the cyst does not have sebaceous material but hair**, it is a **DERMOID CYST**. You find these at the lines of skin fusion in the embryo, namely in the midline or, more commonly, at the lateral or medial ends of the eyebrow where the maxillary and ophthalmic divisions of the face meet. They may extend internally a considerable distance, so *don't underestimate this lesion*, as you may need to hollow it out of the frontal bone!

**If the 'cyst' turns out to be a fatty lump**, it is a lipoma: excise it anyway, by shelling it out.

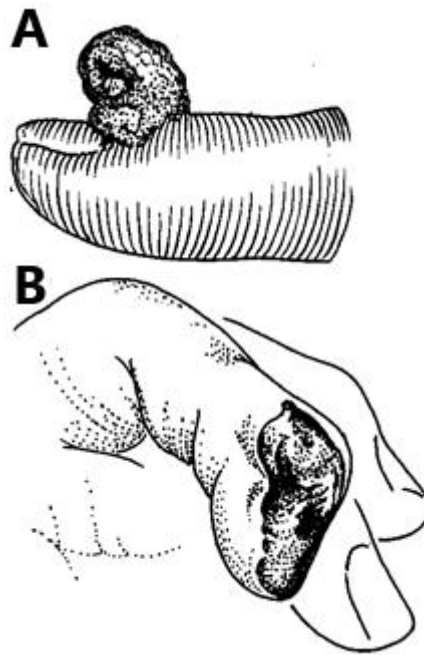
**34.4 Skin manifestations of HIV disease**

Unfortunately only few of the HIV-related skin conditions (5.6) are amenable to surgical treatment. These are pyogenic granuloma, condyloma (26.6) and Kaposi sarcoma (34.10). If the lesions of *molluscum contagiosum* (which typically look like little navels) are very extensive, you can provide some relief by removing these.

**(a) Pyogenic granuloma**

(Lobular capillary haemangioma)

Pyogenic granuloma is a misnomer; it can occur anywhere, but is commonest on the face, fingers, or toes, as a soft or moderately firm, dull red, 1cm lump, covered with atrophic epidermis or crusts, and which bleeds easily. This trivial lesion can be misdiagnosed and thought to be a sarcoma (34.15), when all that is needed is simple excision and curettage. Its cause is unknown but may be related to antiretroviral treatment. An antibiotic is only needed rarely if there are signs of spreading infection.

**'PYOGENIC GRANULOMA'**

**Fig. 34-7 PYOGENIC GRANULOMA (LOBULAR CAPILLARY HAEMANGIOMA).**

**Excise or curette these lesions. Don't mistake them for a sarcoma! If there is any doubt about the diagnosis, take a piece for histology.**

**(b) Condylomata (Warts)**

These can occur anywhere, but are particularly found in the perineal area from sexual contact; even in HIV+ve patients, wounds tend to heal well after excision, even if they are extensive or in the perineum (26.6), *but beware of scarring! Beware also of malignant change.*

**34.5 Nodules; basal and squamous carcinoma**

You should aim to excise any suspicious skin lump, especially if you think it looks malignant (with rolled everted edges) or might become so, particularly if you can do the operation without disfigurement under LA. *Don't wait till the signs of malignancy are obvious and far advanced!*

**(a) Skin nodules**

Most of these may ulcerate, and have many causes, some of which are specific to certain areas or people.

Remember many small ulcers are caused by insect or tick bites; these may result in various types of fever, *e.g. rickettsial typhus or trypanosomiasis.*

Some ulcers, *e.g. gouty tophi on elbows*, are metabolic in origin, and need medical treatment as well as excision for diagnostic or cosmetic purposes. Many are inflammatory or infective, however, and may have different treatments:

Name	Cause	Agent	Features	Treatment
<i>Bartonellosis</i> ( <i>verruca peruana</i> )	<i>B. bacilliformis</i>	sandfly in Andes mountains	raised purple nodules on limbs and face, fever,	chloramphenicol or ciprofloxacin
( <i>bacillary angiomatosis</i> )	<i>B. quintana</i> , <i>B. henselae</i>	lice; fleas on cats	haemolytic anaemia, red berries on skin	erythromycin or doxycycline
<i>Chromo(blasto)mycosis</i>	fungi spores (Medlar bodies: thick-walled brown sclerotic cells on scrapings + 10% H <sub>2</sub> O <sub>2</sub> )	thorns in Madagascar, Japan, Amazon and Central America	warty plaque on feet with lymphoedema	itraconazole
<i>Cysticercosis</i>	<i>Taenia soleum</i> (pork tapeworm)	ingestion of under-cooked pork	subcutaneous cysts + convulsions, visual loss	albendazole or praziquantel
<i>Dracunculiasis</i> (34.8) (Guinea worm)	<i>D. medinensis</i> (Sudan, Chad, Mali, Ethiopia)	contaminated drinking water	papule or cyst with long worm	immersion in water to discharge worm, or slow extraction
Kerion (inflammatory ringworm)	<i>Tinea</i> (various)	contact	pustular scalp mass	ketoconazole or griseofulvin
<i>Leishmaniasis</i> (34.7)	<i>L. braziliensis</i>	sandfly	itchy red papule, then firm, elastic scaly nodule with softened centre	ketoconazole and/or miltefosine; honey application for early lesions
Leprosy	<i>Myc. leprae</i>	long contact	facial, extensor arm nodules and sensory loss	rifampicin, dapsone and clofazimine
Mycetoma (Madura foot, 34.11)	<i>Actinomycetoma</i> (Sudan, Somalia, Mexico, India) + <i>Eumycetoma</i> spp. (dry areas)	thorn/stone	pustular mass + sinus discharging grains + swelling	trimethoprim  itraconazole
<i>Myiasis</i> (cutaneous)	larvae (maggots)	deposition from botfly, tumbu fly, blow fly, or <i>hypoderma</i>	itchy nodule with intradermal movements (larva migrans); also in wounds, body orifices	topical oil or jelly and extraction by forceps
<i>Onchocerciasis</i> (34.8)	<i>O. volvulus</i> (sub-Saharan Africa, Yemen, Central and South America)	blackfly, near fast-flowing streams; endosymbiosis with <i>Wolbachia</i>	itchy non-suppurating nodule on pressure points + hanging groin, and blindness	ivermectin and doxycycline
Sporotrichosis	<i>S. schenckii</i>	abrasion	necrotizing ulcerating nodules spread along lymphatics	potassium iodide, or itraconazole ( <i>not in pregnancy</i> )
Syphilis	<i>Treponema pallidum</i>	sexual contact	brown 2° nodule on palm, sole or face	benzathine benzylpenicillin or doxycycline or erythromycin
Tuberculosis (lupus vulgaris)  (Buruli ulcer, 34.9)	<i>Myc. tuberculosis</i>  <i>Myc. ulcerans</i> (West and Central Africa)	inhalation  water insects	painless nodule, then ulcerating and scarring  nodule quickly ulcerating causing tissue necrosis	ethambutol, isoniazid, rifampicin, and pyrazinamide  streptomycin and rifampicin
<i>Tungiasis</i>	<i>T. penetrans</i> (Brazil, Madagascar, Nigeria)	flea infestation especially from walking or lying on sand	fibrous painful nodule on foot, or exposed body surface	topical dimeticone, injected into lesions and tetanus prophylaxis

### (b) Basal carcinoma

Basal carcinomas are common in areas of white skin (including particularly albinos) exposed to the sun (34-8). Melanin in dark skin protects it from the effects of sunlight. The earliest stage is a raised nodule, but the usual presentation is of an old, or middle-aged, man complaining of a small ulcer on the face or scalp, commonly near the eye, which continues to break down and never really heals. It has a raised rolled edge, grows slowly, and eventually erodes into muscle, cartilage, or bone. Growth is slow and *metastases don't occur*. Prognosis is excellent if you treat lesions early, whether by surgery or radiotherapy.

DIFFERENTIAL DIAGNOSIS includes:

- (1) kerato-acanthoma (a solitary firm nodule with central ulceration, initially rapidly growing, then resolving),
- (2) skin tuberculosis,
- (3) fungal lesions.

#### EXCISION OF BASAL CARCINOMA (GRADE 1.2)

Excise the lesion with at least 1cm of normal tissue all round it. If you cannot do this, try hard to get help to make an adequate excision because otherwise it will recur and spread extensively. It will not spread to the regional lymph nodes, so there is no need to excise these. Send a specimen for histology. For very small lesions, radiotherapy offers no advantage over surgery, because the diagnosis has to be confirmed by biopsy anyway; for middle-sized or large lesions, it is of some cosmetic value.

### (c) Squamous carcinoma

Squamous carcinomas are also common in areas of white skin (including particularly albinos) exposed to the sun. They are rare in dark skins, except as a complication of chronic ulcers (34.9), burn scars, radiation, condylomata in HIV+ve patients, hidradenitis outside the axilla, xeroderma pigmentosum (autosomal recessive sensitivity to UV light) or arsenic exposure (*e.g.* in miners, glass workers or from contaminated groundwater).

Squamous carcinomas develop in adult life or, occasionally, earlier (especially in albinos). They are low-grade tumours which spread to the regional nodes late, and rarely metastasize through the blood. Ulcerating lesions are late stages; typically they have irregular, raised, round, everted edges and indurated bases, which soon become attached to deeper structures, and may erode the bone underneath, causing a pathological fracture.

In theory, prevention is simple: by covering exposed white skin, and treating chronic ulcers and burns to make sure they heal. Unfortunately, albinos from disadvantaged families often face serious discrimination.

**RADIOGRAPHS.** If the lesion is overlying bone, get a radiograph. A translucent area in the bone under the ulcer shows that bone is being infiltrated. Thickening of the bony cortex and trabeculae, however, indicate secondary chronic osteitis, caused by infection.

### SKIN CARCINOMAS

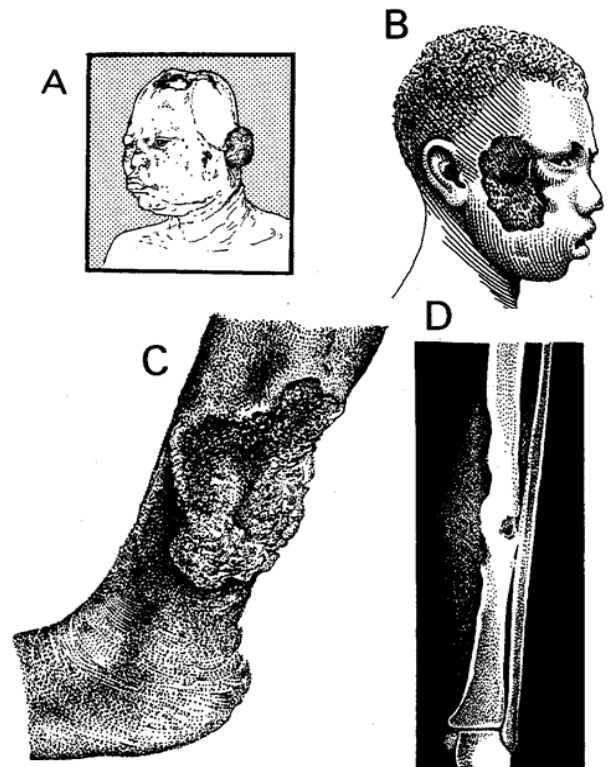


Fig. 34-8 CARCINOMAS OF THE SKIN, squamous and basal carcinoma.

A, this albino has already had several squamous carcinomas. One has eroded the skull; it was successfully excised, and the dura grafted, leaving a large depression. Another large one has now destroyed the ear. B, another albino with a large basal carcinoma (rodent ulcer) of the side of the face. C, a squamous carcinoma in the leg. Note its raised edges. D, radiograph of the same lesion, showing bone destruction and sclerosis.

B, after Bowsman C, *Surgery and Clinical Pathology in the Tropics*, Livingstone, 1960 with kind permission.

DIFFERENTIAL DIAGNOSIS includes:

- (1) A benign chronic ulcer (34.9) – the distinction can be difficult clinically and histologically.
- (2) A tuberculous ulcer.
- (3) Yaws (34.9).
- (4) Syphilis.
- (5) Pyogenic granuloma (34.4).
- (6) Fungal lesions.
- (7) Kaposi sarcoma (34.10).
- (8) Amelanotic melanoma (34.6).

#### EXCISION OF SQUAMOUS CARCINOMA (GRADE 1.2)

**CAUTION!** Always confirm the diagnosis histologically first, before starting treatment.

Try to excise a squamous carcinoma with any malignant infiltration around it. So remove at least a 0.5cm margin of macroscopically normal skin around the lesion, and at least a 0.5cm margin underneath it.

**If there is a large defect but a satisfactory base**, for example muscle, excise any deep fascia and apply a split skin graft. Tie-over sutures are useful to keep the dressing in place.

**If the base is not suitable for grafting** (if it is connective tissue, fat, tendon, or infected), wait 5-7 days till granulations are satisfactory, and then apply a split skin graft. (*You can store graft wrapped in paraffin gauze in a refrigerator for c.10 days.*)

**If bone is exposed**, chisel away the cortex until you reach a bleeding surface, wait 7-14 days for granulations to form, and then apply a graft. Occasionally, you can close the defect with either a rotation, a transposition or a myocutaneous flap. If the carcinoma is infiltrating bone so much that the bone would fracture if you remove enough of it to excise the lesion properly, amputate at the first joint proximal to the lesion instead.

#### **Lymph nodes involved by a squamous carcinoma**

**If the regional lymph nodes are not hard or matted together**, leave them. Do a careful follow-up. *Don't do a block dissection prophylactically*, because there is a 10% chance that lymphoedema (34.12) will develop afterwards, and it will not improve the prognosis.

**If the nodes are enlarged, and you think that this is caused by secondary infection**, use cloxacillin, and wait  $\geq 2$ wks. If they don't respond, biopsy one, and make a careful follow-up.

**If you think that the nodes are involved clinically but are not fixed to deeper structures, or there is an advanced ulcer-cancer** (most commonly in the groin), perform a block dissection (17.8), and wide excision of the primary, at the same time. The prognosis following wide excision of the primary and block dissection is good.

**If nodes in the groin are enlarged and fixed to the femoral vessels**, leave them. They will fungate, but there is little you can do about this unless you perform an extended excision with a vascular graft.

**If the inguinal nodes become enlarged when they were normal previously, or increase in size after the amputation stump has healed completely, but are still mobile**, perform a block dissection.

#### **DIFFICULTIES WITH SQUAMOUS CARCINOMAS**

**An albino** is particularly prone to multiple squamous carcinomas. Advise long skirts or trousers, long-sleeved high-necked shirts, wide hats, tinted glasses, and the avoidance of unnecessary exposure to the sun, especially between 11am and 3pm. The patient must report any new lumps or bumps immediately. Advise the use of the fruit of the sausage tree (*Kigelia africana*): soften the skin of the fruit with 10% urea or 2% salicylate, and use this as a protective cream. *Keep a careful follow-up of your albino patients*: they may be ostracized socially.

Use lotions with high protective factor (30+ or 50+): they are quite expensive, so instead you can use zinc oxide on the lips as this blocks the sunlight. You may be able to abort pre-cancerous lesions with topical 5% fluorouracil. Otherwise, treat squamous carcinoma in the same way as above.

**If the lesion is bleeding profusely**, apply hydrogen peroxide or 10% formalin soaked onto gauze, avoiding contact with normal skin.

### **34.6 Melanoma**

In a black patient, malignant melanomas arise only from non-pigmented parts of the skin: the soles of the feet (most commonly), the palms of the hands, the nail beds, and the mucosa. In a white patient, a melanoma can arise anywhere, usually in a pre-existing naevus, especially after long exposure to sunlight, commonly on a man's trunk or a woman's legs, or, rarely, from the choroid plexus of the eye. In all skin colours, malignant melanomas only occur after puberty; most are pigmented, but a few are amelanotic. They may occur at the junction of depigmented and pigmented skin in severe cases of vitiligo.

They spread:

- (1) by local infiltration, usually horizontally at first, or as satellite nodules, but later vertically into the deeper tissues,
- (2) to the regional lymph nodes; deposits may also grow in lymphatic channels on the way there,
- (3) through the bloodstream.

Treatment is by wide surgical excision; there is no effective radiotherapy or chemotherapy. Amputation may be necessary to obtain clearance.

#### **(a) Prevention**

- (1) Excise any elevated mole (pigmented lesion)  $>0.5$ cm in diameter which shows any sign of growth, colour change, bleeding, ulceration or itching.
- (2) *Don't expose white skins, including those of children and especially albinos, to sunlight.*

**(b) Differential diagnosis** includes a benign naevus, a pigmented seborrhoeic wart, a squamous papilloma or carcinoma (34.5), a capillary cavernous haemangioma (33.12), pyogenic granuloma (34.4) and Kaposi sarcoma (34.10).

*N.B.* Histologically, the diagnosis can be difficult.

**Suspect that a black patient has a melanoma** if there is:

- (1) Any growing dark lesion on the soles of the feet, on the palms of the hands, or in the nail beds, particularly on the big toe. The commonest site is at the junction of the deeply and lightly pigmented areas on the hands and feet.
- (2) A deeply pigmented lesion on the sole of the foot,  $>2$ cm in diameter, whether or not it is ulcerated.
- (3) An ulcerated lymph node in the groin, with dark areas showing through the skin, or in the base of the node.

## MELANOMAS

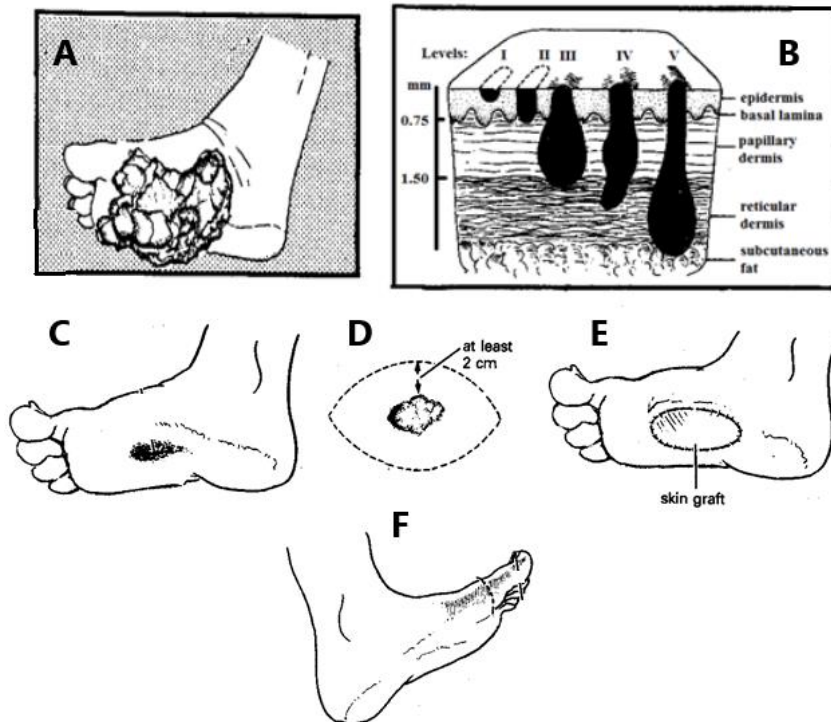


Fig. 34-9 MALIGNANT MELANOMAS.

A, if a melanoma presents as late as this, amputation has no immediate advantage over local excision and grafting but skin-grafting the sole may not be very satisfactory in the long term. B, Clark's levels of invasion: Level I does not penetrate the basement membrane. Level II extends into the papillary dermis. Level III extends to the reticular interface. Level IV invades the reticular dermis. Level V penetrates the subcutaneous fat. Compare this with Breslow's staging level. C, excise a melanoma with a margin of  $\geq 2$ cm of normal skin round it. D, if it presents sufficiently early, excise it and E, graft the wound. F, amputate a toe for a subungual melanoma.

B, after Grabb WC, Smith JW, *Plastic Surgery. A Concise Guide to Clinical Practice*. Little Brown, with kind permission. C-E, after Seigler HF in Rob C, Smith R. *Operative Surgery*. Butterworth 1981 p.221 with kind permission.

#### Suspect that a white patient has a melanoma if:

- (1) any previously existing pigmented mole enlarges, weeps, scabs, bleeds, itches, ulcerates, becomes darker, or produces a dark surrounding halo.
- (2) any pigmented lesion keeps growing progressively. Be especially suspicious if it is  $>1$ cm, with an irregular border, surface, or pigmentation.
- (3) there is a rapidly growing brownish fleshy ulcerated skin tumour, even if it is pale (it may be amelanotic).

#### (c) Staging malignant melanoma

Prognosis depends on the size of the tumour and depth of infiltration of the excised specimen macroscopically. Breslow's level is more accurate: I  $\leq 0.75$ mm, II 0.76-1.5mm, III 1.51-2.25mm, IV 2.26-3.0mm, V  $>3$ mm. Survival drops drastically from level III.

#### (d) Excision of malignant melanoma (GRADE 1.3)

If you suspect that a lesion is a melanoma, but have not previously biopsied it, excise it with a margin of at least 1cm of normal tissue all round for each mm of tumour thickness, with preferably more on the proximal end.

Remove all the underlying subcutaneous tissue and deep fascia. If the bed that remains is suitable, graft it immediately. Take a split skin graft from the opposite limb, *not the limb bearing the melanoma*.

*Prophylactic block dissection of the regional nodes probably does not help.* However, you can inject 5ml of blue dye around the primary lesion, and then explore the groin 20mins later, and remove a blue-tinted *sentinel node*. If this is visibly black on section or contains melanoma on histology, a block dissection is indicated. Otherwise follow up regularly, so that if the regional nodes enlarge, you can perform a block dissection.

**If there is local infiltration, and spread to the regional nodes,** make a wide local excision, and a block dissection of the regional nodes (usually inguinal, 17.8). If there is growth in the intervening lymphatics (for example in the neck), excise these in continuity. It is doubtful if this improves survival, but it does remove deposits which may ulcerate.

**If there is already widespread dissemination,** there is nothing you can do, except provide terminal care (37.1).

**If wide local excision is not possible without amputation,** as for example under the big toe or a nail, amputate well proximal to the lesion.

(e) **Histology.** If possible, send the whole specimen for examination. If this is impractical, cut and orientate it for the pathologist to make it possible to ascertain the depth of penetration, and the margins of normal tissue excised in the vertical and horizontal planes; fix the specimen on card and label the card "anterior/posterior", "medial/lateral", "superior/inferior".

### 34.7 Leishmaniasis

The female sandfly is the vector for transmitting the flagellate *protozoa Leishmania* from rodents, particularly gerbils, or domestic animals, especially dogs, to humans and between humans themselves. Different types of *Leishmania* give rise to specific diseases: normally cellular immune responses prevent a second infection, but with HIV disease widespread infestation often occurs. Deforestation has exposed many millions of non-immune people to *Leishmania*, which is now endemic in 88 countries.

There are 4 forms of *leishmaniasis*: cutaneous, mucocutaneous, visceral and post-kala azar dermal types.

They are caused by specific *Leishmania*: 90% of cases of the cutaneous form occur in Afghanistan, Brazil, Iran, Peru, Saudi Arabia and Syria; 90% of the mucocutaneous form occur in Bolivia, Brazil and Peru; 90% of the visceral form occur in Bangladesh, Brazil, India, Nepal and Sudan. Post-kala azar dermal *leishmaniasis* occurs after treatment for the visceral disease.

**(a) Cutaneous leishmaniasis** (Oriental sore)

After an incubation period of days to months from the time of the sandfly bite, an itchy red papule develops on exposed parts of the body, especially the face. This then produces a firm elastic scaly nodule with a shallow, well-defined, punched-out central ulcer having yellow-red granulations at its base. Spontaneous healing occurs after 3-12 months depending on the species of *Leishmania*. If there is HIV disease, the nodules spread extensively on the skin, and often cause visceral involvement.

**(b) Mucocutaneous leishmaniasis**  
(Espundia, Chiclero ulcer, uta)

Nodules tend to appear at the mucocutaneous junction of nose and lips; later after months or years, they may spread by lymph or bloodstream to the nasopharynx, palate, uvula, larynx and the airways. This results in destruction of these tissues, with resulting gross facial deformities needing plastic reconstruction (29.18).

**(c) Visceral leishmaniasis** (Kala azar)

Dissemination of *amastigotes* throughout the reticulo-endothelial system results in fever, weight loss and massive splenomegaly. There is often also lymph node enlargement and hepatomegaly, particularly in children where the skin becomes darker ('kala azar' means, in Hindi, the black sickness). Visceral *leishmaniasis* is particularly common in HIV+ve patients.

**(d) Tests.** Fix a smear or aspirate from a nodule or ulcer, from a lymph node, or from the spleen (after checking the clotting and bleeding times) in methanol, and stain it with Giemsa. You should see many *amastigotes* (Leishman-Donovan bodies) which are rounded 2-3µm bodies inside macrophages.

**(e) Treatment**

Although nodules heal, they take long and do so with scarring; if there are many, the disfigurement is significant. Single-dose IV liposomal amphotericin B 3mg/kg followed by oral miltefosine 2.5mg/kg for 7 days gives >95% cure rates. *Antimonials were standard treatment but may cause pancreatitis or cardiac angina.* Drug resistance and toxicity are very common with HIV+ve patients; relapse is frequent after 1 month to 3yrs. Repeated relapses may occur. Ketoconazole and the application of honey are useful for early cutaneous lesions.

### 34.8 Guinea worm infestation (dracunculiasis, dracontiasis) and onchocerciasis

**(a) Guinea worm infestation**

This occurs when an encysted subcutaneous filarial worm is released when the skin becomes wet or ulcerates; gravid females release larvae which are swallowed by the crustacean cyclops (water fleas 1-2mm in size). When man, cat or dog swallows fresh water from a well infested with these cyclops, the larvae are liberated by digestive juices, migrate through the intestinal wall to areas of loose connective tissue, and finally after c.1yr the females lodge as fertilized worms under the skin of the legs, or more rarely the arms. They are 60-90cm long.

It was endemic in Saudi Arabia, Iraq, Central Asia, Nigeria, and Sudan, but now remains mainly in South Sudan, Chad, Mali and Ethiopia, especially in areas of conflict. Eradication has been effective by treating drinking water with the effective organophosphate larvicide, *temephos* (1ppm), and filtering it with polyester cloth.

When the worm emerges from the skin, it causes intense itching and oedema. Scratching may encourage secondary infection. When the affected part is put in water to soothe the discomfort, the female worm contracts at the base of the ulcer and releases thousands of first-stage larvae, so contaminating the water further.

**If a guinea worm presents on the skin, don't try to dissect it out,** because severe sepsis usually follows. Instead, carefully wind it round a matchstick, and be prepared to take 3wks in doing so, leaving the stick with its coil of worm under a dressing, and pulling out a little more each day. If the worm is broken, milk out the larval fluid. Treat with a topical antiseptic and tetanus toxoid as an adjunct to mechanical removal. If you can extract the worm before it emerges, you will prevent contamination of water resources. Applying topical metronidazole or thiabendazole cream eases the irritation and reduces risk of infection.

**If a large rubbery cystic mass develops,** usually on the trunk, and typically on the back near the angle of the scapula, distinguish a guinea worm cyst (a low-grade encapsulated abscess) from a lipoma:

- (1) A guinea worm cyst often has a small scar on its surface.
- (2) On contraction of the muscles, you can see that a lipoma is usually superficial, and a guinea worm cyst deep.
- (3) Aspirate the mass with a wide needle. A guinea worm cyst usually contains sterile pus. If necessary, dissect out the mass, taking care not to injure surrounding structures. There is no easy plane of cleavage.

**If the cyst becomes infected,** it may be impossible to distinguish it from pyomyositis (7.1) or septic arthritis (7.17), especially of the knee: you will have to drain these in the usual way.

## ENCYSTED GUINEA WORMS

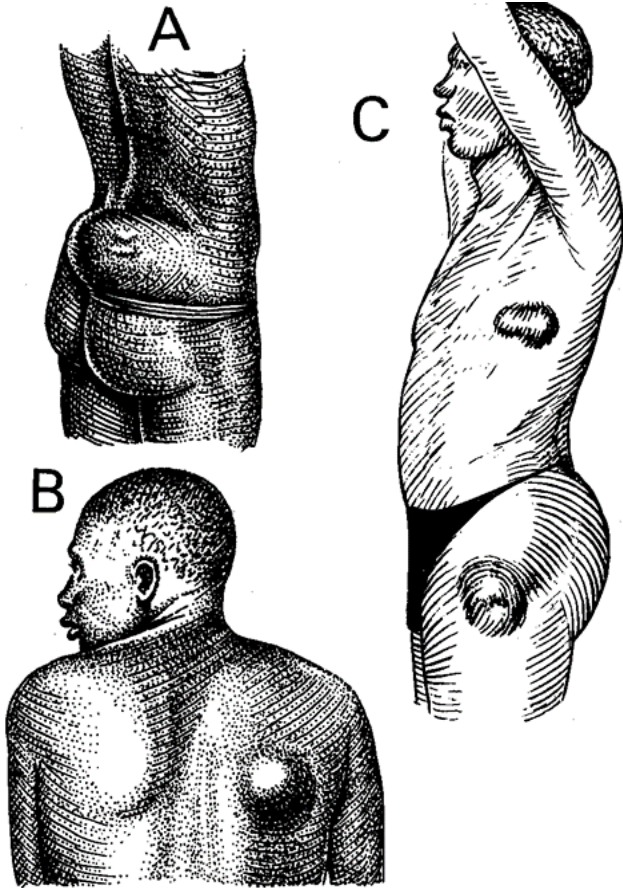


Fig. 34-10 ONCHOCERCAL NODULES AND ENCYSTED GUINEA WORMS.

Both are easy to remove surgically. A,B, encysted guinea worms are commonly found on the trunk, particularly over the inferior angle of the scapula and the crest of the ilium. C, onchocercal nodules are usually found over the iliac crests, trochanters, sacrum, knees, shoulders or head.

Partly after Bowesman C. *Surgery and Clinical Pathology in the Tropics*, Livingstone 1960 with kind permission.

(b) *Onchocerciasis* results from infestation by a filarial nematode, *Onchocerca volvulus*, which comes to live in subcutaneous nodules or free in the skin. The female worm is 35-70cm long and twists itself inside a capsule; the fibrous nodules so resulting may exist for up to 15yrs. The worm itself produces millions of *microfilariae* which invade skin and connective tissue where they are ingested by biting blackflies and develop into infective larvae. Bites in Africa tend to be low on the body from flies breeding by fast-flowing streams; in South America bites are on the head from flies breeding in small hillside streams.

It is endemic in 36 countries, especially in sub-Saharan Africa, but also common in Brazil, Venezuela and Yemen, affecting 18 million individuals, 99% of whom are in Africa.

Most *microfilariae* die within the skin and cause itchy popular dermatitis, which becomes lichenified, atrophied and depigmented; in the eye keratitis and chorio-retinitis (28.7) result. Regional lymphadenopathy is a common consequence. Co-infection with loiasis is common.

**Tests.** Take at least 2 skin snips and place these for 1-24h in the well of a microtitre plate full of saline; under low-power microscopy, you will then see *microfilariae* migrate out of the skin. If they don't appear, cover the plate with clingfilm and re-examine after 24h.

**Treatment.** Treat with ivermectin once every 6 months according to weight:

15-25kg	26-44kg	45-64kg	65-84kg
3mg	6mg	9mg	12mg

This treatment may need to continue for up to 10yrs to cover the lifespan of the worm, as the drug kills *microfilariae* but not the adult worm. Add doxycycline 100mg bd for 4wks to eradicate *Wolbachia*, which is usually present as well.

**If a patient from an endemic area has firm onchocercal nodules**, 2-3cm diameter on bony prominences, especially over the iliac crests, trochanters, sacrum, knees, shoulders, or head, remove them under local anaesthesia, and examine for an encysted worm.

**If an inguinal adenolymphocele develops** (hanging groin, 18-5), you might need to excise it if it becomes very uncomfortable.

**If an inguinal hernia develops**, repair this bearing in mind the tissues will be weak (18.4).

## 34.9 Tropical ulcer

These are full-thickness necrotizing bacterial infections of the skin, arising through a puncture wound or dirty laceration. Spreading cellulitis (6.22) with spirochaetes *Treponema vincentii* and fusiform organisms (both are penicillin-sensitive) causes dermal gangrene and skin breakdown, which is enhanced by further infection, trauma or solar exposure. Their characteristic distribution (34-11D) is probably explained by their origin from infected cuts from the sharp grasses of bush paths.

An acutely painful ulcer begins with a raised, thickened, and slightly undermined edge. This ulcer grows rapidly for several weeks. A bloody discharge covers the grey slough on its floor, the skin around it is dark and swollen, and muscle, bone, and tendon occasionally lie exposed in its base. After about a month, the pain, swelling, and discharge improve, and it either heals or becomes chronic, resembling any other longstanding indolent ulcer. Osteomyelitis is rare, but a reactive periostitis may in time raise an ulcer above the surrounding skin. Sometimes its edge is thickened and everted, and resembles a carcinoma.

It is very similar to pyoderma gangrenosum, found in adults on the shins but in children on the head and neck, associated with inflammatory conditions such as Crohn's disease, and which typically recurs in sites of trauma. This responds rapidly to prednisolone 1mg/kg od and then azathioprine 50mg od whilst tapering off the steroids.

## TROPICAL ULCERS

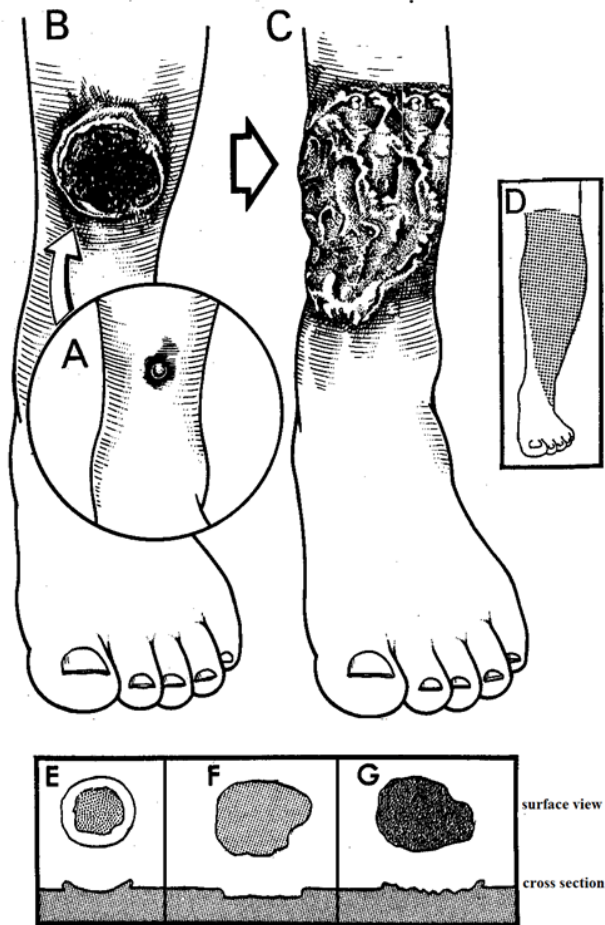


Fig. 34-11 TROPICAL ULCERS.

A, earliest stage of a tropical ulcer: a pustule containing *Treponema vincentii* and fusiform bacilli. (Commonly, however, the early stage is just a small cut.) B, pustule rupturing to form an acute ulcer. C, chronic ulcer showing the exposed tendons. D, characteristic site of tropical ulcers anteriorly on the lower leg, becoming more lateral lower down. E, acute tropical ulcer, with an everted oedematous edge, and a dirty slough covering much of its base. F, chronic ulcer, with an edge which is not raised, and a uniform avascular base. G, note difference with a squamous carcinoma, with its everted edge, and irregular base.

#### (a) Differential diagnosis

The site of a tropical ulcer is its most important diagnostic feature. Distinguish chronic non-specific ulcers from those with specific cause, e.g. *mycobacteria*, spirochaetes, protozoa, fungi, carcinoma or repeated trauma.

**Suggesting tuberculosis:** a ragged, shallow ulcer, with bluish overhanging edges. Its base is less vascular and more fibrous.

**Suggesting a Buruli ulcer:** an otherwise fit child, or young adult, suffering from a huge ulcer with deeply undermined edges, anywhere on the body, not necessarily on the feet and lower legs.

**Suggesting leprosy (32.2):** a trophic ulcer from pressure necrosis, usually on the anaesthetic sole of the foot.

**Suggesting anthrax:** a red papule with a ring of vesicles forming a black eschar associated with significant oedema, from contact with infected animals especially carcasses, often with extreme toxicity. Other causes may be cowpox or monkeypox!

**Suggesting diphtheria (desert sore):** a ragged ulcer with an overhanging edge and a grey-brown base, persisting if there is also HIV disease. There may be cardiac effects and a neuropathy.

**Suggesting yaws:** a child with heaped hyperkeratotic ulcers on moist surfaces, especially soles and hands.

**Suggesting syphilis:** an ulcer appearing 6wks to 6 months after a chancre.

**Suggesting leishmaniasis (34.7):** a reddish, sharply defined, indurated ulcer around a sandfly bite.

**Suggesting mycetoma (34.11):** a painless swelling on the foot with sinuses discharging grains.

**Suggesting herpes (5.6):** ulceration along one or more dermatomes in an HIV+ve patient.

**Suggesting carcinoma (34.5):** a heaped-up, irregular, longstanding ulcer with rolled everted edges.

**Suggesting varicose ulcer (35.1):** a brownish eczematous sloughy ulcer above the medial malleolus associated with varicose veins, deep vein thrombosis, and obesity.

**Suggesting sickle cell disease:** a chronic ulcer over the lateral malleoli in a sickle cell patient.

**CAUTION!** The macroscopic differentiation of a chronic tropical ulcer from a specific or malignant ulcer (34.5) can be difficult when there is no extension into the surrounding tissues. Be sure to take a biopsy before you perform any radical surgery.

#### MOST GRAFTING SHOULD BE DONE AT THE ACUTE OR SUBACUTE STAGE

#### (b) Treatment for acute tropical ulcers

Debride the ulcer and get it clean with daily soaks, and honey, ghee, banana, pawpaw or zinc-medicated dressings (2.10). When it is clean, usually within 7 days, and if it is >5cm diameter, perform a split skin graft. *Don't use topical antibiotics.*

Smaller ulcers will heal without grafting. If the granulations are abundant, scrape the base of the ulcer with a scalpel. There is no need to anaesthetize it; there are no nerves in granulation tissue, so this does not hurt, provided you avoid the epithelium. Scraping does not improve the 'take', but it does reduce fibrosis under the graft later and so makes it more stable. Control bleeding with hot packs.

If possible, apply the graft as a single sheet, which has been meshed to allow the escape of exudate and blood, or, less satisfactorily, apply it as patches or pinch grafts. Immobilize the affected part, and expose the graft on the 5<sup>th</sup> day, or earlier if it is smelly.

Then soak off the dressing slowly to avoid removing the graft at the same time. It may need covering for another week. The donor site should have healed in 10 days.

### (c) Treatment for chronic tropical ulcers

**If an ulcer is deep fibrotic and on the lower leg,** measure the

ulcer carefully over a period of follow-up (with photographs if possible); apply platelet-rich fibrin (from centrifuging venous blood) as a thin layer weekly with fine forceps, elevate the limb and enforce rest in bed, though encouraging movement in the other limbs! *Take especial care of pressure points, the patient's skin elsewhere, and the condition of the feet, including the toenails.*

**If there is spreading secondary infection,** use cloxacillin and apply a thick absorbent dressing 2cm thick with a firm but not over-tight bandage, carefully applied to avoid wrinkles and folds. *If the dressing is soaked, it needs to be changed as the discharge will cause further skin erosion.* A vacuum dressing will help remove excess fluid and slough: this can be economically locally made using low-pressure (125mm Hg) suction machines.

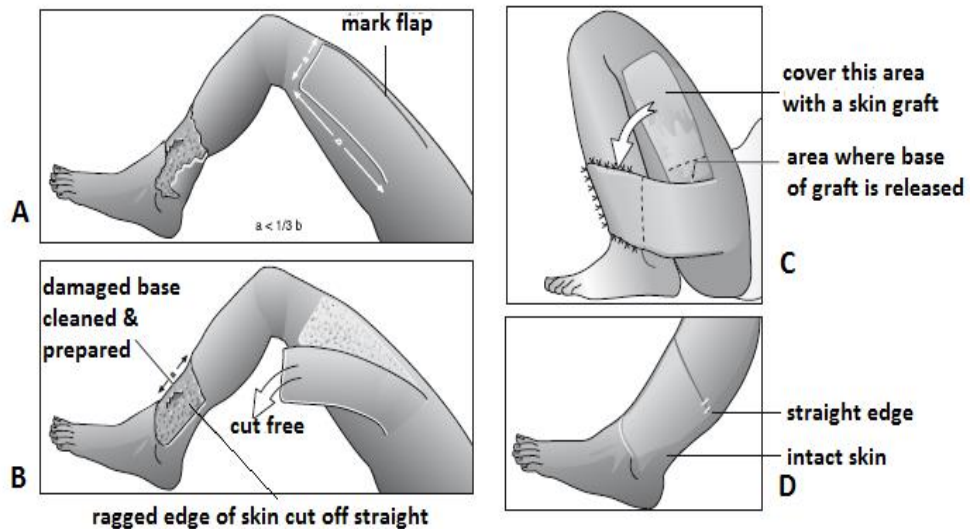
*Split skin grafts don't take on longstanding fibrotic ulcers.* These cause longstanding morbidity, and may become malignant. If the base of the ulcer is suitable, and is not too deeply fibrosed or over bone or tendon, excise and graft it as a single procedure.

Alternatively, apply a tourniquet (3.4), and excise the ulcer. Cut away all avascular scar tissue, until you reach a raw, bleeding surface; if necessary, use an osteotome to remove any dead bone. Apply hypochlorite, or a dry dressing, to the ulcer bed, cover it with gauze, cotton wool, and a bandage, and release the tourniquet. After 5-10 days, when the base of the ulcer is covered with suitable granulation tissue, prepare a myocutaneous flap (34-12).

### IPSILATERAL THIGH-TO-LEG FLAP (GRADE 3.2)

Check that the peripheral arterial supply in the distal leg is good. Plan the operation meticulously, measuring the size of the flap and making sure it will cover the ulcer when the knee is flexed. Use a piece of cloth as a template, and cut it the right size, and then mark the skin with indelible ink (34-12A). Infiltrate the flap area with dilute lignocaine/adrenaline solution. Debride the ulcer thoroughly to produce fresh clean granulation tissue.

### THIGH-TO-LEG TENSOR FASCIA LATA FLAP



**Fig. 34-12 IPSILATERAL THIGH-TO-LEG TENSOR FASCIA LATA FLAP.**

**A, chronic distal leg ulcer with flap marked out on the thigh, where  $a < \frac{1}{3}b$ . B, during transfer. C, flap sutured prior to immobilization. D, end result after division of flap.**

*After Badran HA. Plastic Surgery in Kamel R, Lumley J. (eds) Textbook of Tropical Surgery, Westminster 2004 p.722 Fig 163.1.*

Raise the flap using the blood supply to the ilio-tibial tract which comes from the lateral femoral circumflex artery. Take the skin attached to the *tensor fascia lata* muscle from the level of the pubic tubercle anteriorly along a line just lateral to the anterior superior iliac spine, and posteriorly along a line down from the greater trochanter. The ilio-tibial tract lifts off the *vastus lateralis* and you can then swing the flap in the direction you want.

With the knee firmly flexed, attach the flap over the ulcer (34-12C) with 3/0 interrupted nylon sutures. Put a split skin graft on the lateral thigh defect. Dress the wounds, and immobilize the knee in plaster.

After 5 days expose the grafted area, and redress the wound, putting on a tight crepe bandage so that the patient cannot extend the knee. After 3wks, divide the flap, allowing enough tissue to be sutured to the recipient site, and suture the proximal portion to its donor site.

**CAUTION!** *Don't perform this operation if there is peripheral ischaemia, or if the patient has significant arthritis: the knee may become permanently stiff after 3wks of immobilization. Make sure the ulcer site is free of infection before you attempt such a flap.*

You can use a flap from the opposite leg but immobilizing both legs for a cross-leg flap is difficult.

**(d) Buruli ulcer** occurs in areas near rivers and stagnant water, especially where there has been environmental change, *e.g.* due to mining. It is found in West and Central Africa, India, China, Indonesia, Australia (where koalas and possums carry the disease), Mexico, Peru and Bolivia; aquatic insects may transmit the causative organism, *Mycobacterium ulcerans*, which causes necrosis of skin and deep fascia through the action of cytotoxins.

Commonly a child <15yrs presents with a painless, small, well-demarcated, indurated swelling, attached to the skin, but not to deeper tissues. It is almost always single and on the limbs, and is often near a joint, although the site is variable. There is little pain or tenderness, little or no fever, and the regional lymph nodes are not enlarged. The lesion grows, the skin over it desquamates creating a plaque, becomes pigmented, and then breaks down to form a chronic expanding ulcer with a necrotic base and edges which may be undermined 5-15cm. Secondary infection occurs, and a foul slough forms. Satellite ulcers may appear, but metastatic spread is rare. Some ulcers remain unchanged for weeks; others cover much of a limb, or the trunk, in a few weeks. Untreated, they result in scarring and severe contractures.

DIAGNOSIS is suggested by the appearance of the swelling and the ulcer, the absence of lymph node enlargement, and the failure to respond to tropical ulcer therapy.

SPECIAL TESTS. Look for AAFB in the ulcer base; send material for culture. *M. ulcerans* grows on media used for *M. tuberculosis*, but only at 33°C. Mycolactone produced can be detected by PCR.

TREATMENT. Early on, use rifampicin and streptomycin or, better, clarithromycin for 4-8wks; healing continues after completing the course of treatment. If the lesion is ulcerated, control secondary pyogenic infection with antibiotics, and irrigate with warm water. Excise all diseased tissue, and when granulations are healthy (c.3-4wks), re-examine the wound for residual TB, and if clear, cover the wound with a skin graft.

(e) **Desert sore** (diphtheritic ulcer) occurs in dry desert climates, starting as a painful vesicle leaving a raw and tender ulcer with a grey-brown base. Later this becomes punched out with an undermined edge. The organism, *Corynebacterium diphtheriae*, produces an exotoxin which can give rise to myocarditis and peripheral neuropathy. Use benzylpenicillin and immunize contacts with diphtheria toxoid.

(f) **Yaws** (framboesia) occurs amongst poor children living in unsanitary and overcrowded conditions in warm, humid tropical climates. It is caused by *Treponema pertinue*, which is transmitted by direct contact through clothing and insects. A painless swelling which occasionally ulcerates, the 'mother yaw', starts at the site of the contact with concurrent regional lymphadenopathy. This heals spontaneously after 3-6 months when the infection spreads to moist areas of the skin, e.g. soles, palms and the back of the knees. These usually ulcerate, become infected, and may destroy joints and bone. Use a single oral dose of azithromycin 30mg/kg.

(g) **Herpetic ulcers** occur characteristically in HIV+ve patients following the acute episode of the herpes zoster reaction. One or more dermatomes may be involved. Acyclovir 800mg x5 od for 1wk is useful early in the eruption. Post-herpetic neuralgia may be severe.

(h) **Hidradenitis suppurativa** (Verneuil's disease) or **pyoderma fistulans sinifica** (fox-den disease) may have a genetic predisposition. These result in localized skin sepsis arising from apocrine glands (so don't develop in children), especially in the axillae, groins, perineum, back of the neck and under the breasts. The result is quite marked skin thickening, fistulae and multiple skin bridges, but the disease does not extend below the fascia. *Be careful to distinguish this from necrotizing fasciitis* (6.23). You will achieve a lasting cure only by excising the whole affected area and leaving the wound to granulate.

### 34.10 Kaposi sarcoma

Kaposi sarcoma (KS) starts as a proliferation of lymphatic endothelial cells which transform into a sarcoma; the stimulus is infection with the herpes virus type 8, transmitted by saliva, promoted by immunosuppression. The HIV tat protein also promotes KS.

(a) **Presentation** is in 4 main types (in decreasing order of frequency):

(1) By far the most common, HIV-related KS in men and women, with symmetric lymphadenopathy, oral purplish patches or plaques, pulmonary infiltration and skin nodules (though these are often absent). The nodules don't occur in areas subject to sustained pressure (e.g. the soles of the feet or under dental prostheses). Ultimately lesions lead to woody hard oedema and ulceration.

(2) Endemic (HIV-ve) African KS usually of younger men, with indolent nodules on the limbs preceded by hot oedema, ultimately resulting in widespread infiltrating and visceral involvement.

(3) Iatrogenic KS as a result of immunosuppressive drugs for cancer or connective tissue disease, where if the drugs are withdrawn, KS regresses, often completely.

(4) Classical KS of elderly men usually of Arabic, Jewish or Southern European descent, with indolent nodules on the limbs that may regress spontaneously.

#### (b) Diagnosis

Plaques and nodules are so typical that skin biopsy is rarely necessary in the presence of HIV disease.

*N.B. Biopsy of oedematous skin may produce a non-healing wound.*

Lymph node excision biopsy may be useful (17.1). All patients suspected of KS must have an HIV test.

#### (c) Treatment

Chemotherapy (doxorubicin, vincristine, or bleomycin) gives a dramatic response, but there is early relapse in HIV+ve patients unless they also have ARV therapy (5.8). Radiotherapy is useful for isolated limb lesions, but supplement it with chemotherapy. Early KS may not warrant treatment, which may cause serious side-effects; in HIV+ve patients, co-existent pulmonary disease is common: you usually have to treat this first.

## KAPOSI SARCOMA

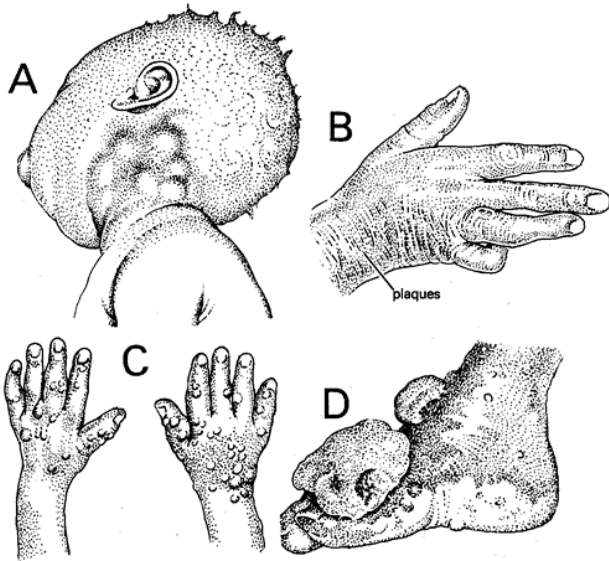


Fig. 34-13 KAPOSI SARCOMA (KS).  
A, lymphadenopathy in children. B, infiltrating type. C, nodules (more often seen on the leg). D, large cauliflower-like lesions.

**Amputation** (35.3) can relieve much distress if a heavily affected limb is ulcerated, septic and useless; *don't do this, though, if oedema extends up to the groin. Beware of bleeding* (especially if there is thrombocytopenia): use a tourniquet.

## 34.11 Mycetoma (Madura foot)

Mycetoma is a chronic progressive granulomatous inflammation caused by implantation of filamentous fungus-like bacteria (*streptomyces*, *actinomyces*, *nocardia* etc), or the true fungi (*eumycetes*, particularly *madurella* and *leptosphaeria*, *exophiala*, *pyrenochaeta*, *scedosporium*), through cracks in the skin caused by sharp objects, especially thorns, splinters or stones. Typically it occurs on the foot, but may affect the hand, particularly in those working in the fields in arid zones with short rainy seasons especially in latitudes between 15°S and 30°N.

It begins slowly to form a circumscribed, rubbery or cystic, *painless* lobulated mass. If it is on the sole, pressure flattens it into a disc. Sinuses appear, and occasionally discharge granules. As one sinus heals, more appear, and become secondarily infected, but this secondary infection does not extend deeply. By the time that 5yrs have elapsed, the whole foot is swollen, and covered with open sinuses and scars. Progression of the disease is faster with *actinomyces* than *eumyces*.

Differentiate this from botryomycosis (6.4), which also produces 'sulphur granules' but which arises from staphylococcal infection.

## MYCETOMA

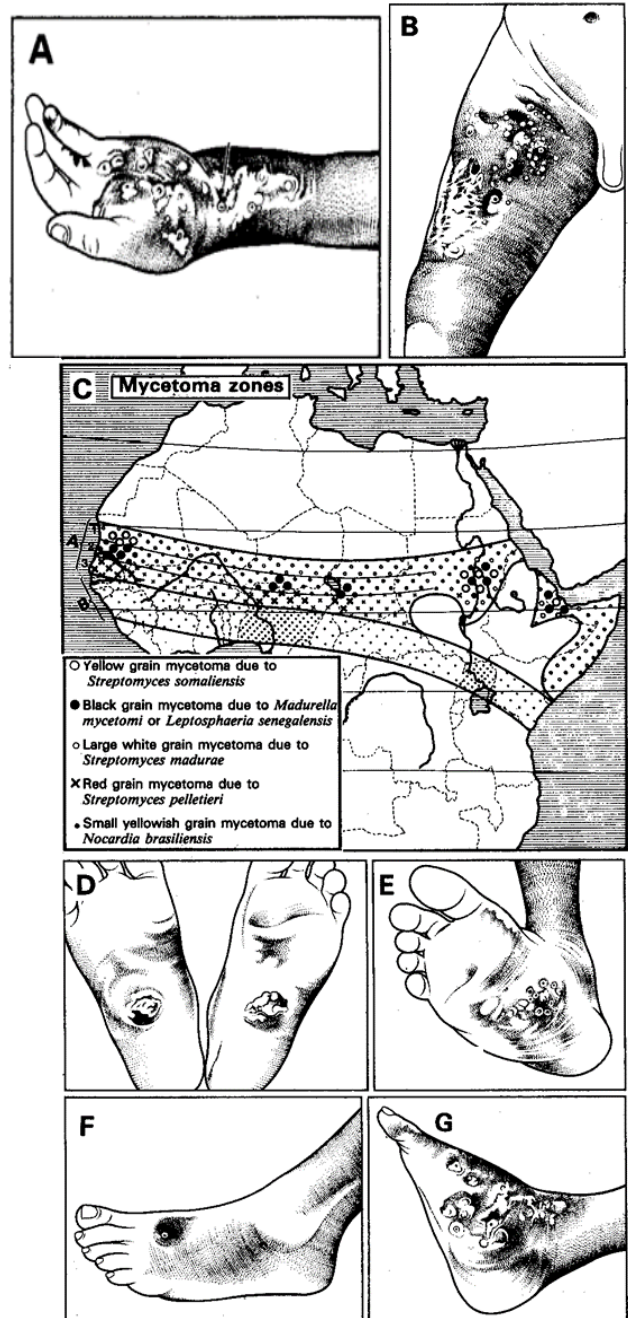


Fig. 34-14 MYCETOMA.  
A, mycetoma of the hand, spreading through the carpal tunnel into the forearm (unusual). B, advanced mycetoma of the thigh 20yrs after infection had begun in the foot. C, endemic and sporadic mycetoma zones in Africa. D, early black grain mycetomas of the soles of both feet, showing flattened disc-shaped swellings. This is the typical early lesion but simultaneous involvement of both feet is rare. E, more advanced lesion. F, mycetoma of the dorsum of the foot. This may be part of a dumb-bell lesion extending from the sole between the metatarsals. G, diffuse mycetoma of 10yrs' duration; still painless and the sufferer was still working.

After Crockett DJ. Mycetoma. *Tropical Doctor* 1973;3(1):28-33 with kind permission.

The primary site of infection is usually in the subcutaneous fat; it may spread beyond the plantar or palmar fascia, which form a natural barrier. It may then spread in the deep fat between the tendons, along the lumbrical canals, and even through the carpal tunnel, up into the forearm.

The bone may be invaded relatively early, still without causing pain, and is rapidly destroyed. *Mycetomas never regress spontaneously*.

Regional lymph nodes are usually not enlarged, but may be affected by secondary sepsis and occasionally by lymphatic spread of mycetoma.

**(a) Diagnosis.** Try to find the granules, because without them, all a pathologist can say is that there is a granulomatous infection with multiple micro-abscesses. The colour and size of the grains can give a clue to the cause: *Actinomyces pelletieri* produces small red grains, *Streptomyces somaliensis* medium-sized yellow, *Actinomyces madurae* large white, *Nocardia brasiliensis* small yellow, *Madurella mycetomi* and other *eumyces* large brown-black. If you cannot see the grains with the naked eye, get an aspiration specimen for cytology. You should see filaments with x40 magnification.

**(b) Radiographs.** Once the periosteum is breached, the tarsal and metatarsal bones are rapidly destroyed. New bone in the walls of abscesses forms buttresses projecting outwards at angles to the shaft of a long bone. The centre of an infected bone has a honeycomb appearance, and a good film shows tiny cystic areas of bone destruction, each the site of a micro-abscess. Differentiate this from an osteosarcoma or tuberculosis.

**(c) Ultrasound.** This shows typical thick-walled cavities with no acoustic enhancement, with the grains giving numerous bright hyperreflective echoes, especially with *eumyces*. These are less distinct with *actinomyces*.

**(d) Differential diagnosis**

Actinomycosis produces yellow granules but occurs very rarely on the foot.

Cutaneous B-cell lymphoma may look identical, and equally chronic.

**(e) Treatment**

For *actinomyces*, use trimethoprim. Rifampicin can replace streptomycin and sulfadoxine-pyrimethamine (Fansidar), and ciprofloxacin can replace cotrimoxazole in resistant cases.

For *eumyces*, try ketoconazole 400mg od, for 1yr, but the chance of cure is much lower.

For *nocardia*, use cotrimoxazole with amikacin for 2wks. Otherwise, try griseofulvin 500mg od.

Curette and drain any low-grade abscesses that form.

**If a lesion is localized, and is confined to the soft tissues,** excise it and repair the defect with a split skin graft. *Take great care not to rupture the capsule of eumyces* as you will otherwise transfer the fungus to adjacent areas, and recurrence will be inevitable.

Excise a margin of healthy tissue with *actinomyces* as its border is ill-defined. *Always* use a tourniquet to produce a bloodless field. Flood the operative field at the end of the operation with iodine to minimize risks of contamination.

**If bone is involved, or will be,** Syme's amputation (35.7) is appropriate provided you can clear the disease adequately.

**If there is a lesion of the hindfoot with severe bone and joint destruction,** perform a below-knee amputation (35.6).

**If there is a lesion of the hindfoot with minor bone involvement, and without severe destruction of its joints,** you will probably have to amputate, but wait until the foot becomes a real nuisance. Make sure there is no response to medical treatment.

Always combine surgery with long-term medical treatment for at least 6 months.

**CAUTION!**

(1) Mycetoma is painless, so *don't amputate a limb until the patient is quite convinced that the limb is of no use.*

(2) Follow the patient up carefully, and make sure he reports any involvement of the inguinal nodes. When he does, this is an indication for urgent amputation and block dissection of the nodes (17.8).

## 34.12 Elephantiasis

If there is gross generalized swelling of the leg, arm, or scrotum, or if a woman has a similar swelling of her breast or vulva, the condition is known colloquially as elephantiasis. Usually, this is due to longstanding lymphatic obstruction. Occasionally, it is due to venous obstruction, but this is seldom gross enough to need surgery. Distinguishing between lymphatic and venous obstruction can be difficult. Oedema due to lymphatic obstruction becomes firm quite rapidly, but early cases may show pitting. Oedema due to venous obstruction becomes solid late, and eventually reaches a stage where it fails to pit.

In most areas, the causes of lymphatic obstruction (lymphoedema), in decreasing order of frequency, are:

- (1) Tuberculosis
- (2) Repeated lymphangitis due to lymphatic obstruction, usually from *streptococci*, filariasis or podoconiosis (34.13)
- (3) Malignant glands in the groin, or less often the axilla
- (4) Kaposi sarcoma
- (5) Block dissection of the glands, usually for carcinoma
- (6) Congenital lymphatic hypoplasia (Milroy's disease).

Other causes include:

- (7) Chronic fungal infections
- (8) *Onchocerciasis* (34.8)
- (9) Lymphogranuloma venereum.

Filariasis due to infection in tropical and subtropical regions with *Wuchereria bancrofti* and less often to *Brugia malayi* or *B. timori* is restricted by the prevalence of the insect vectors but its geographical range spans a population of c.1 billion people in 80 countries, mainly in remote rural or poor peri-urban areas. *B. malayi* and *B. timori* give rise to lymphoedema below the knees; *W. bancrofti* to the whole leg, arm, breast, scrotum, or vulva.

Elephantiasis due to advanced podoconiosis (whether it has reached the 'mossy foot' stage or not) responds fairly well to surgery. Elephantiasis due to filariasis is difficult to treat surgically (34.14).

**(a) Differential diagnosis**

**Suggesting venous oedema:** rapid onset, pitting of the skin with ulceration, varicose veins, medical causes (*e.g.* heart failure, hypoproteinaemia, nephritis, cirrhosis).

**Suggesting filariasis** (34.14): scrotal involvement, oedema which starts at the most dependent part for each site and moves upwards: below the malleoli for the leg, the fundus for the scrotum, the foreskin for the penis, and the dorsum of the hand for the arm. Microfilariae found in blood films.

**Suggesting podoconiosis** (34.13): a barefooted patient from a podoconiosis area; worse on one leg than the other; below-knee swellings most marked distally. Symptoms are the first evidence of disease (in filariasis they are the last), and include burning of the lower legs at night, with persistent itching of the 1<sup>st</sup> and 2<sup>nd</sup> toe clefts, and plantar oedema of the forefoot. No microfilariae in the blood, and a chronic warty thickening of the lower legs ('mossy foot').

**Suggesting chronic non-specific lymphangitis:** some source for it, such as a tropical ulcer (if the swelling is in the lower leg). Acute recurrent attacks of lymphangitis. Enlargement of the nodes draining the swollen area only: these may be large and firm, or small and fibrotic. Lines of hyperpigmentation on the skin indicating previous lymphangitis. A lymph node biopsy showing fibrosis and non-specific inflammatory changes.

**Suggesting tuberculosis** (17.4): chronic enlargement of many superficial nodes (inguinal, axillary, and cervical); a history of prolonged illness in the past, with fever and enlarged nodes, some of which discharged for long periods; multiple sinuses, or the scars that follow their healing, especially over the lower end of the vertical chain. Involvement of an entire leg from toes to groin, or an entire arm or a woman's breast. A +ve lymph node biopsy confirms the diagnosis; if tuberculosis is no longer active, only non-specific fibrosis may be seen.

**Suggesting lymphogranuloma:** also produces sinuses, but these are usually confined to the superior group of nodes, over the medial part of the inguinal ligament.

**Suggesting malignant disease:** firm mass in the groin or axilla; typical purplish raised lesions of Kaposi sarcoma.

*N.B. The site involved indicates the probable cause:*

Breast and arm, or vulva	tuberculosis, filariasis
Scrotum or vulva	filariasis
Lower leg	filariasis, podoconiosis

**(b) Treatment**

If you are in doubt, try the appropriate specific treatment for tuberculosis or filariasis. Lymphoedema due to tuberculosis nearly always settles with anti-TB therapy, unless it is diagnosed very late. Antibiotics are unlikely to influence chronic non-specific inflammation. Check the HIV status.

### 34.13 Podoconiosis

Podoconiosis ('dust in the feet': non-filarial endemic elephantiasis) is found in fertile highland volcanic regions in Uganda, Tanzania, Cameroon and Sao Tome, and Central and South America and Indonesia due to alkaline red clay soils whose silicates penetrate the skin and are taken into the lymphatics. It only involves the legs, presenting as bilateral asymmetrical swelling of the feet and lower legs. This causes the lymphatics to fibrose and obstruct, and the femoral nodes to enlarge.

This in turn makes the legs and feet swell, and progress through stages which are described as 'water bag', 'rubbery', and 'wooden' (34-15). Finally, the leg becomes hyperkeratotic, 'mossy', and nodular. Lymph may ooze through the skin, which may be secondarily infected by fungi or bacteria. The disease may progress steadily, or there may be a succession of acute episodes which resolve incompletely. Villagers in endemic areas are often able to recognize the early stages.

'Mossy foot' can also describe other diseases causing multiple excrescences on the feet, notably *chromoblastomycosis* (34.5).

Elevation, elastic stockings, and long leather boots help in the earlier stages, but once the 'wooden' stage has developed, the only treatment is surgical. If you see a patient early, persuade him to wear boots or shoes which will minimize further progression. The main preventive measure is wearing fully protective shoes rather than sandals or open shoes from childhood.

Podoconiosis is disfiguring, and may result in chronic disability, so treatment is important. Unfortunately, on presentation, the lymphatics are often incurably blocked, so that medical treatment is ineffective.

Surgically, you can:

- (1) Compress the leg of a 'soft' case by intermittent compression.
- (2) Excise individual nodules over the toes.

**(a) Early diagnosis.** After a long day's work in the fields, or a long walk, one of the feet becomes swollen, and feels tense. The lymph nodes are enlarged and firm.

## PODOCONIOSIS

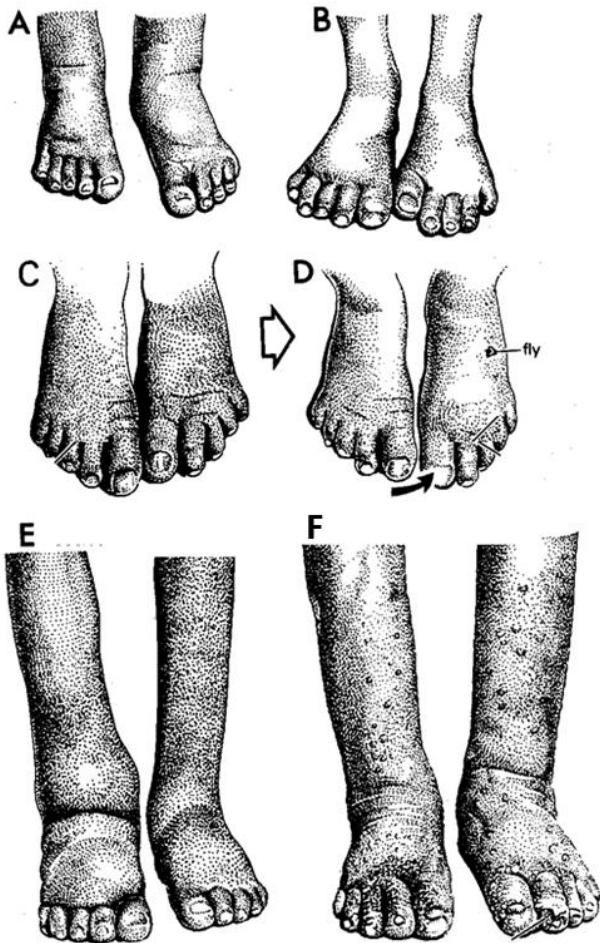


Fig. 34-15 DIAGNOSING PODOCONIOSIS.

A, 'block toes'. Early oedema of the left forefoot affecting the plantar aspect of the metatarsal pad, as well as the toes, which appear rigid, as if they were wooden and nailed on to the forefoot. They may be lifted off the floor by plantar oedema, and lack the usual curve of normal toes. B, 'knocking' big toes on walking, due to splaying of the forefeet as the result of deep oedema at the level of the metatarsal heads. C, D, increased skin markings, which become more evident if the toes are compressed. Flies, attracted by exuded lymph to an otherwise clean foot, are characteristic. E, wet 'waterbag' foot, which is readily reduced by compression or elevation; its skin is soft, and you can pinch it off the bone. F, dry 'wooden' type, which cannot be reduced by compression or elevation; it is hyperkeratotic, and often nodulated. After Price EW, *Pre-elephantiasic stage of endemic nonfilarial elephantiasis of lower legs: 'podoconiosis'*. *Tropical Doctor* 1984; 14(3):115-9 with kind permission.

Try to recognize the following early stages:

(1) 'Burning leg' is a burning sensation in the lower leg, from in front of the medial malleolus to behind the medial condyle of the knee, sometimes extending upwards into the thigh. The femoral nodes may be tender. Pain is usually worst at night, and is relieved by uncovering the leg. Each episode usually affects the same leg, and the second leg does not usually become involved until the first one shows clear signs of disease. Although the burning area of the leg may be tender, few patients seek help at this stage. (2) 'Itchy foot' is a persistent localized pruritis, usually on the dorsum at the base of the first or second toe clefts, or below the middle malleolus. Thickening of the skin (pachydermia), from constant scratching, is a common presentation.

When the toes start swelling, the itchy area precedes the upper level of the swelling, and indicates progression of the disease.

(3) 'Block toes' (34-15A) lack their normal curves, and look wooden and rigid, as if they were nailed on the forefoot. 'Splayed forefoot' is a widening of the forefoot, and separation of the toes, which gives the foot a spatula-like appearance, on one or both sides (34-15B). It is due to deep oedema between the metatarsal heads. The skin is unusually resistant to being lifted by your fingers.

## TREATING PODOCONIOSIS

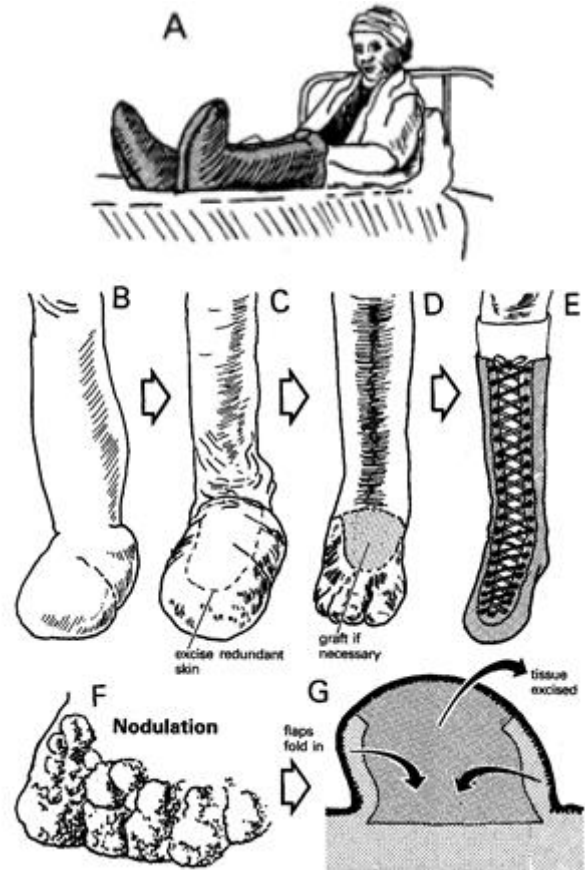


Fig. 34-16 TREATING PODOCONIOSIS.

A, intermittent compression in use (the foot is raised during treatment). B, 'waterbag' foot before decompression. C, same foot after initial reduction of swelling of the lower leg. D, removal of excess skin nodules over the toes. E, leg protected in a boot. F, nodulation. G, how to excise a nodule.

After Price EW, *Pre-elephantiasic stage of endemic nonfilarial elephantiasis of lower legs: 'podoconiosis'*. *Tropical Doctor* 1984; 14(3):115-9 with kind permission.

Plantar oedema is asymmetrical (unlike cardiac or renal oedema). Press with your thumb on the sole over the head of the first metatarsal. You may see mild lymphatic oozing, tiny blebs of lymph, or an unusual number of flies attracted to it.

The forefoot shows an excessive deposit of keratin on the dorsum at the base of the first or second toe cleft. The clefts themselves usually remain normal, even in advanced disease with increased skin markings at the base of the first toe cleft and running longitudinally rather than laterally (as is normal). Compressing the toe (34-15D) shows the marks more clearly.

**(b) Early treatment**

- (1) Raise the foot of the bed to the height which relieves the discomfort; a hammock is suitable.
- (2) Apply ankle-length elastic socks before rising in the morning; or apply wide (10cm) one-way stretch elastic bandages; crepe bandages are inadequate.
- (3) Protect the skin of the feet from the soil, preferably in shoes. Treat any other conditions present.
- (4) Use pH-neutral soap.
- (5) Start to reduce the size of the swellings with intermittent compression (34-16A-C).
- (6) Advise the wearing of stockings and boots (34-16E).

**(c) Excision of foot nodules.** Excise these for aesthetic reasons, or to make wearing shoes easier (34-16D). They have no sensory nerves, so you can remove them without anaesthesia.

*CAUTION! Don't try to remove the femoral nodes.*

*Don't try to remove redundant tissue unless rigorous barriers are in place to prevent contact with the soil.* Recurrent swelling is more painful and debilitating than the original disease.

*N.B.* The difference in treatment between podoconiosis and filariasis is that the first is caused by contents of the soil, which are hard to avoid without moving home and work. The second is caused by a vector, mosquitoes, which can, at least in theory, be avoided.

Although the long-term consequence is blockage of the lymphatics, surgery has therefore more to offer in filariasis than in podoconiosis.

### 34.14 Filariasis

Filariasis is a parasitic infection which causes considerable morbidity to c.120 million people in 80 countries of the tropics and subtropics. *Wuchereria bancrofti* is the cause in >90% of cases, but *Brugia malayi* or *B. timori* occur in Asia. Larvae ingested by *Culex*, *Anopheles*, *Aedes* or *Mansonia* mosquitoes are deposited on the skin of humans, and microfilariae then migrate to the lymphatics *via* the insect bite.

**(a) Symptoms** start within a few weeks to months of infection, as fever, lymphangitis, tender lymphadenopathy, erythema, and oedema. The inguinal, epitrochlear, and axillary nodes are commonly involved. Attacks may be repeated every few months. There may also be secondary bacterial infection.

In males, the spermatic cord, epididymis and testes are often involved, resulting in painful recurrent attacks of epididymo-orchitis (27.3), which may be followed by suppuration in the scrotum.

Synovitis, arthritis and asthmatic-type attacks also occur.

**(b) Chronic effects** are the result of lymphatic obstruction, commonly in the retroperitoneum. This can produce:

- (1) Lymphoedema, which may progress to gross hypertrophy of the subcutaneous tissues (elephantiasis: 34.12) affecting the whole leg and scrotum (*W. bancrofti*) or below the knee (*B. malayi* or *timori*), or the arm, breast, or abdominal wall (less common). No known treatment will reverse these changes, although doxycycline may arrest the progression by treating co-existent *Wolbachia*.
- (2) Hydrocoele (27.24), which is very common in areas of filariasis, usually with chronic epididymo-orchitis.
- (3) Vulval lymphoedema, which is very uncomfortable and embarrassing, and may become enormous. This causes obvious sexual dysfunction, extreme mental anguish, and may result in urinary retention, and severe difficulty in walking. Surgery is complicated and needs an expert.
- (4) Varicocoele (27.37).
- (5) Lymphocoele of the spermatic cord, which may be diffuse, resembling a varicocoele (34-17E), or encysted (34-17F). Beware: *it may exist with an irreducible inguinal hernia* (34-17G)!
- (6) Lymphatic varix (hygroma). This is a soft cystic lymph-filled swelling in the axilla, neck, or groin.
- (7) Chyluria (27.37), due to rupture of dilated lymphatics into the urinary tract.
- (8) Chylous ascites, due to rupture of dilated lymphatics into the peritoneal cavity.

**(c) Special tests**

- (1) The microfilariae of *W. bancrofti* and *B. malayi* are usually present in Giemsa-stained thick blood films taken between 10pm and 2am.
- (2) Puncture an enlarged node, or lymphatic varix, with a needle, and look for microfilariae in the small volume of fluid you aspirate.
- (3) Fluid aspirated from an infested hydrocoele is amber-coloured and has vacuolated mesothelial cells, fibrin, old blood clots, cholesterol crystals and 'calcium dust': these findings associated with epididymitis are highly suggestive of filariasis in an endemic area. You can test this fluid for filaria by ELISA or PCR tests, if they are available. Microscopic examination of the fluid rarely reveals the filaria.

**(d) Ultrasound** of dilated lymphatics can show viable adult worms 'dancing'. The hydrocoele fluid shows a mottled echogenicity. Measure skin thickness by ultrasound at the malleoli to monitor progression of the disease.

**(e) Treatment**

Use doxycycline 100mg bd for 6wks, which also treats symbiotic *Wolbachia*. Add a single-dose albendazole 400mg, and then a single dose of ivermectin (at dose according to weight, 34.8) after 4wks.

(Although both albendazole and ivermectin have limited effects on adult worms, doxycycline, by eliminating *Wolbachia*, will remove the microfilariae.)

*N.B. Diethylcarbamazine is no longer recommended especially in areas endemic for onchocerciasis or loiasis, because of the potentially fatal reactions. Likewise the provocation test (for sampling blood) is not advised.*

### SOME FILARIAL LESIONS

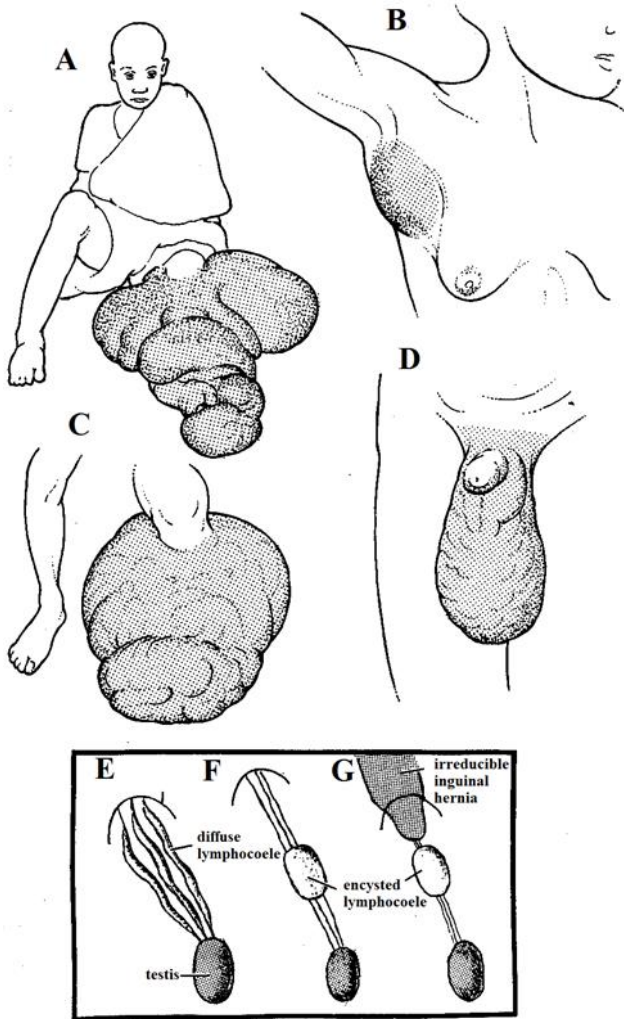


Fig. 34-17 SOME FILARIAL LESIONS.

A, extensive filarial involvement of the leg. After the operation she could walk without support. B, East African woman with an axillary swelling; needle puncture showed that this was a lymphatic varix. C, this filarial mass required amputation; after the operation the patient weighed only half as much as he did before. D, elephantiasis of the scrotum with involvement of the groin nodes, but without involvement of the penis. E, lymphocoele of the cord. F, encysted lymphocoele. G, strangulated hernia with an encysted lymphocoele. After Mahadevan R, *Surgical aspects of filariasis*. *Tropical Doctor* 1978;8(1):28-35 with kind permission.

Reduce lymphoedema by prolonged firm bandaging; then prevent further swelling by supporting the tissues permanently. Intermittent positive pressure methods, as with podoconiosis (34.13), reduce the oedema very effectively. A patient previously unable to walk may thus be able to do so.

Alternatively, insist on bed rest and bandage the leg with crepe bandages from the foot upwards, using sponge rubber to protect the tissues from too tight bandaging. Remove the bandages every day, and replace them a little tighter. When you have reduced the swelling, fit a graduated compression stocking, which will be useful despite the discomfort in hot, moist climates.

If the disease is advanced, mobilize the oedema fluid by initial elastic compression, and then consider surgery; this is not easy. The operation is a 2-stage process; excise half the circumference of the swollen tissues at a time. This ensures that skin flaps of adequate thickness retain a blood supply.

The deep fascia must be included in the excision to allow drainage through the deep muscle compartments of the leg. Afterwards continue with the use of elastic compression stockings.

*N.B.* The Charles operation, where only the oedematous subcutaneous tissue is removed, and the fascia covered with skin graft, results in inevitable worsening of lymphoedema distally, and is not recommended.

### 34.15 Sarcomas

These include rhabdomyosarcomas, fibrosarcomas, liposarcomas, synovial sarcomas, dermatofibrosarcomas, histiocytomas, neurofibrosarcomas, epithelioid sarcomas and angiosarcomas. They all arise from mesenchyme, are commonest from the 2<sup>nd</sup> to the 4<sup>th</sup> decades, and vary considerably in malignancy. They spread by local infiltration, and lymphatic spread is usually late but may be present in up to 10%. In less differentiated tumours, blood dissemination may occur early, especially to the lung.

Treatment is mainly surgical. The results of *radical* local excision are at least as good as very radical surgery involving amputation. Sarcomas are relatively radioresistant. Chemotherapy is an expensive supplement to surgery, and is not nearly so effective as with lymphoma or neuroblastoma.

Distinguish these tumours from cutaneous metastases especially from breast, lung, prostate, pancreas, thyroid or kidney cancers.

Make sure that if you take a biopsy, you can include your incision in subsequent surgery to remove the tumour, so as to remove the biopsy track. Many of these sarcomas need wide excision; this may however only be possible by amputation. *You must never 'shell out' a sarcoma*: there is no proper capsule, and recurrence will be inevitable. If you are going to operate, make sure you can excise the tumour with a margin of normal tissue.

*N.B.* Don't try to excise such a tumour unless you know the full extent of its spread.

#### (a) Rhabdomyosarcoma

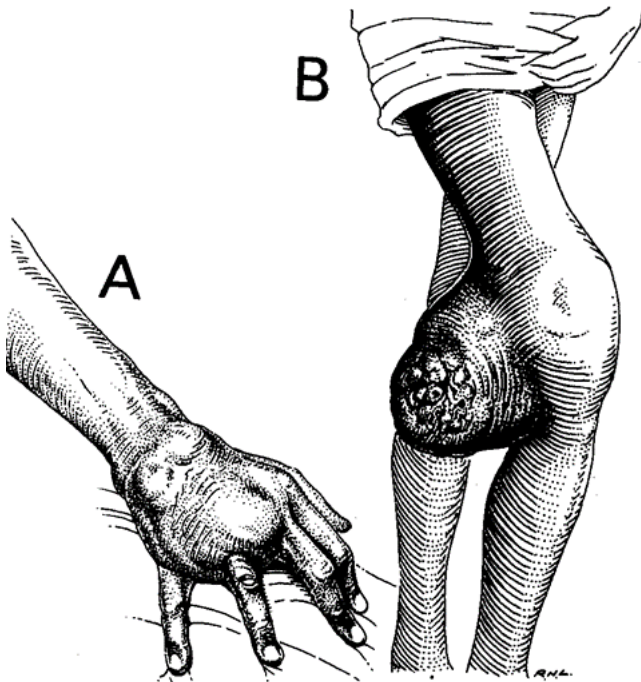
This is the commonest soft tissue sarcoma in those <15yrs. It occurs more often in males than in females, usually at 5-25yrs, in the trunk and limbs, head and neck. (It also occurs in the orbit, bladder, and testis.)

Rhabdomyosarcomas probably arise from embryonic mesenchymal tissue and are fairly malignant: they spread locally quite rapidly.

### (b) Fibrosarcoma

This usually arises from the muscle sheath or periosteum of the thigh, lower leg, or back. The patient, who is usually 30-50yrs, presents with a firm to hard mass which is usually painless in its early stages. Fibrosarcomas are moderately malignant, and spread by local infiltration.

## A CHONDROMA AND A SARCOMA



**Fig. 34-18 A CHONDROMA AND A SARCOMA.**  
A, chondroma of the 4<sup>th</sup> metacarpal. B, advanced sarcoma of the lower end of the right femur.  
*After Bowsman C, Surgery and Clinical Pathology in the Tropics, Livingstone, 1960 with kind permission.*

### (c) Liposarcoma

Typically, this occurs in the soft tissues of the thigh, retroperitoneum, or mesentery, in patients of 30yrs or older. There are basically 4 histological types: well differentiated (hard to distinguish from a lipoma), mixed (commonest), round cell (most malignant), and pleomorphic. Low-grade varieties (mixed and well differentiated) tend to recur locally; round cell ones (rare) metastasize early.

A lipoma (34.3) is probably in fact malignant if:

- (1) it forms a steadily growing mass in the thigh or abdomen, or recurs after excision,
- (2) it has reddish necrotic areas on its cut surface, with cysts instead of plain fatty tissue,
- (3) it is difficult to shell out of the surrounding tissues.

In the thigh, distinguish a liposarcoma from pyomyositis by aspiration of pus in the latter.

### (d) Synovial sarcoma

This presents as a solid swelling like a ganglion; because of its position next to tendons, excision is usually inadequate and recurrence common. Make sure you use a tourniquet when removing these tumours and use a meticulous technique.

### (e) Dermatofibrosarcoma 'protuberans'

This starts as an intradermal plaque and extends slowly over many years into surrounding tissues, especially in patients of 30-50yrs. Classically it has an hourglass shape, with one nodule pressing inwards and one outwards, hence 'protuberans'. Excision results in recurrence in over 50% of cases, so make sure there is a wide (3-5cm) margin of normal tissue, especially in surgery for the second time.

### (f) Malignant fibrous histiocytoma

This usually occurs on the extremities arising in subcutaneous tissue or in the fascia, where the prognosis is worse with c.30% having metastatic disease. It probably arises from fibroblasts. Wide excision with 3cm margins including adjacent fascia and muscle is necessary.

### (g) Neurofibrosarcoma (Malignant schwannoma)

This develops from neural sheath tissue often in longstanding neurofibromas in Von Recklinghausen's disease (neurofibromatosis type 1), where the chance of malignant transformation is 15%.

## 34.16 Pressure sores (Decubitus ulcers)

It takes <1h to produce ischaemic changes in the skin from a pressure point; this is usually owing to a bony prominence bearing the patient's weight, but it might also be an area of skin compressed by a tight plaster. The 1<sup>st</sup> grade is redness (difficult to see on pigmented skin); then there is bluish discoloration from bruising and later pallor from ischaemia. The 2<sup>nd</sup> grade is skin blistering, abrasion, and ulceration. The 3<sup>rd</sup> grade is deep ulceration with undermining of adjacent tissue. The 4<sup>th</sup> grade is necrosis, which is often deeper than you might imagine, with osteitis and subsequently pyoarthrosis.

Pressure sores occur in:

- (1) the paralyzed,
- (2) the severely debilitated patient,
- (3) those with neuropathy.

Damage to the skin from pressure is made worse by contamination with pus, urine or faeces; with septic sores or incontinence, huge sores can develop within 48h (54.11).

Obviously it is best to prevent this disaster happening: in hospital this should be possible with dedicated nursing, turning a patient regularly every 2h *day and night*.

However, patients may come to you from elsewhere with pressure sores, expecting a miracle.

You will not succeed with surgery for pressure sores if you cannot provide the dedicated nursing these patients need; avoid pressure on the suture lines!

*N.B. You will not get a pressure sore to heal on an HIV+ve patient without antiretroviral therapy (5.8).*

#### (a) Special tests

Screen for HIV and diabetes. Check the Hb level. Take skin snips if you suspect leprosy. Take pus swabs. If you suspect osteomyelitis, X-ray the underlying bones.

#### (b) Treatment

(1) **Psychological care and routine nursing** of the paraplegic is essential; if this is not available, *don't embark on difficult surgery*. Make sure pressure is kept off the sore, and the patient is turned every 2h. Hammocks, sheepskin and inflatable mattresses are all helpful but do not substitute for nursing care.

(2) **Correct the nutritional deficit**; these patients need high-protein, high-calorie diets even just for healing.

(3) **Clean and dress the sores**, initially twice daily, and treat HIV disease and diabetes. Transfuse blood if the Hb is  $<70\text{g/L}$ . *Don't use antibiotics unless there is spreading cellulitis.*

(4) **Debride** the pressure sore: a small ulcer often hides a large area of necrosis. You have to be radical with the removal of ischaemic tissue, otherwise sepsis will continue and necrosis will extend. The aim of getting successful skin cover is to remove the pressure point, so *don't be afraid to remove bony prominences*, especially if they too are ischaemic or septic.

*N.B.* An initial debridement on a paraplegic needs no anaesthetic (because of the sensory loss), but beware blood loss, which will not be compensated by peripheral vasoconstriction. *Sudden hypotension may be catastrophic!* Use sedation or a light anaesthetic for subsequent debridements and flaps, if you need to move the patient intra-operatively.

For a sacral sore, **divert urine and faeces** by catheterization and a temporary sigmoid colostomy (11.5). Though this adds considerably to the burdens of the patient, it significantly eases nursing care, and avoids contamination of the sore. *It is very disappointing to see a successful graft or flap destroyed by sepsis!*

(5) **Obtain skin cover** when the wound is clean, nutrition and anaemia corrected, HIV treated and diabetes controlled. Good, lasting skin cover is rarely possible by simple skin grafting, although this may be a useful preliminary to a flap procedure. The type of flap depends largely on the site of the pressure sore.

It is best to use a piece of cloth as a template for the flap; mark out the size and shape of the flap on the skin and cut it always a little larger to allow for errors of calculation. For pressure sores, it is usually not possible to fashion an advancement flap (where you loosen the base of a flap to give it greater stretch). You will need to use a transposition (34-20) or rotation flap (34-21). Triangulate the defect to be excised, making 2 equal sides longer than the base (34-19).

Such a flap takes the skin and underlying subcutaneous tissue, but *not* muscle. However, the blood supply of a myocutaneous flap, such as the *tensor fascia lata* (34-12), *gracilis*, *latissimus dorsi* and *pectoralis major* flaps, is much more reliable and makes them worth learning from an expert.

*N.B. Be careful when you prepare the flap that you don't damage its arterial supply.*

#### PLANNING A LOCAL FLAP

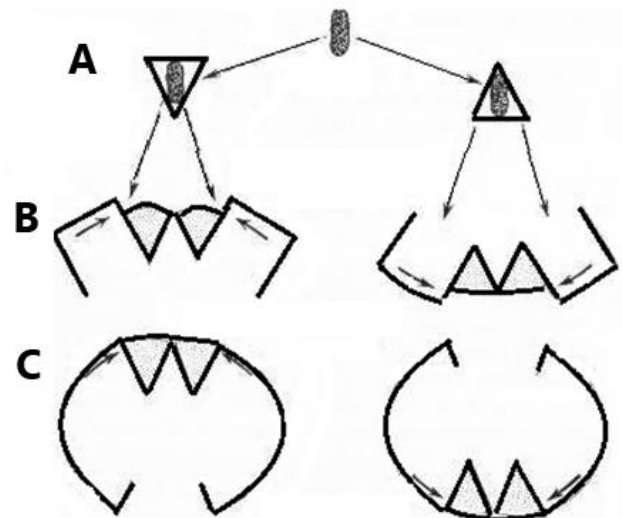


Fig. 34-19 STEPS IN PLANNING A LOCAL FLAP.

A, Step I, triangulate the defect, and select the direction of its base. B, Step II, select whether a transposition or C, rotation flap is best, and select on which side of the defect the flap should be constructed. After MacGregor IA. *Fundamental Techniques of Plastic Surgery*, Churchill Livingstone 1980 p.139 Fig 4.28.

Make sure, when you make a transposition flap, that you make it approximately square (*its length must never be greater than its base*) and that there is adequate length of the flap (longer than the triangular defect) so that it pivots around a point on its base furthest from the defect (34-20).

#### DESIGN OF A TRANSPOSITION FLAP

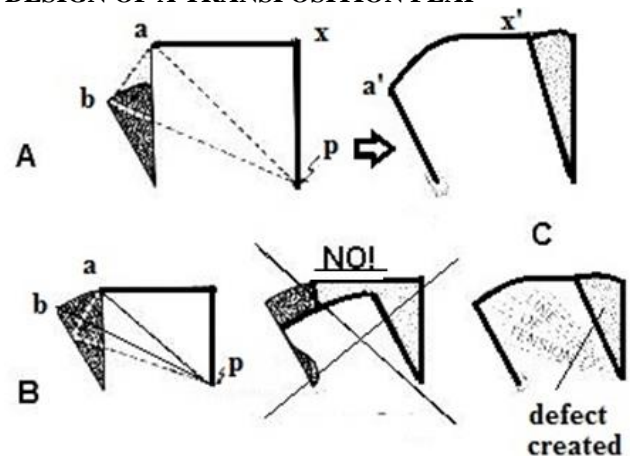


Fig. 34-20 DESIGN OF A TRANSPOSITION FLAP.

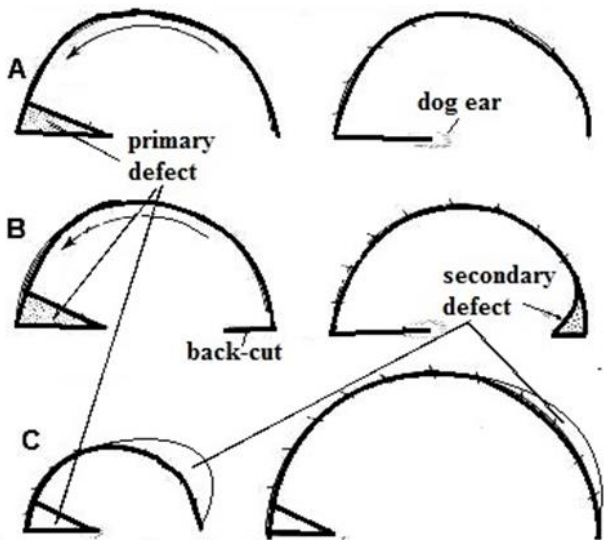
A, a correct design where  $pa=pb$ ; a moves to a' and x to x' (p is the pivot point). B, an incorrect design where  $pa < pb$  and transfer will only be achieved with tension. C, lines of tension; close the defect created primarily or with a skin graft.

After MacGregor, IA. *Fundamental Techniques of Plastic Surgery*, Churchill Livingstone, 1980. p.140 Fig 4.29.

When you make a rotation flap, the bigger the flap size, the less tension there will be; make a 'back-cut' (34-21) along the diameter of its circle as this will allow some lateral movement as well. Close the defects created primarily, or secondarily with a skin graft if there is not enough laxity to close without tension.

For both types of flap, use subcutaneous suction drains post-operatively.

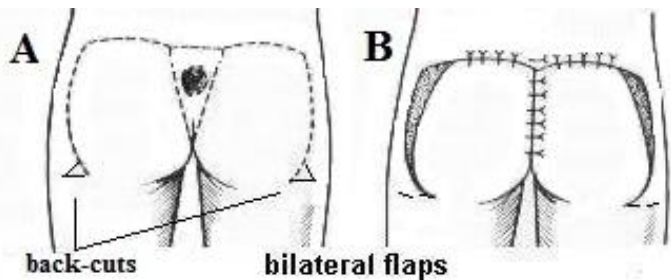
**DESIGN OF A ROTATION FLAP**



**Fig. 34-21 DESIGN OF A ROTATION FLAP.**  
 A, without back-cut making a dog ear. B, with back-cut making a secondary defect needing closure. C, difference on tension with flap size: the area of the secondary defect is the same with both flaps.  
 After MacGregor, IA. *Fundamental Techniques of Plastic Surgery*, Churchill Livingstone 1980 p.137 Fig 4.27.

**If there is a sacral sore,** use an **INFERIORLY-BASED BUTTOCK ROTATION FLAP (GRADE 2.5)**. If the patient is paraplegic, use a unilateral rotation flap or bilateral flaps which will give you more cover (34-22).

**SACRAL PRESSURE SORE REPAIR**



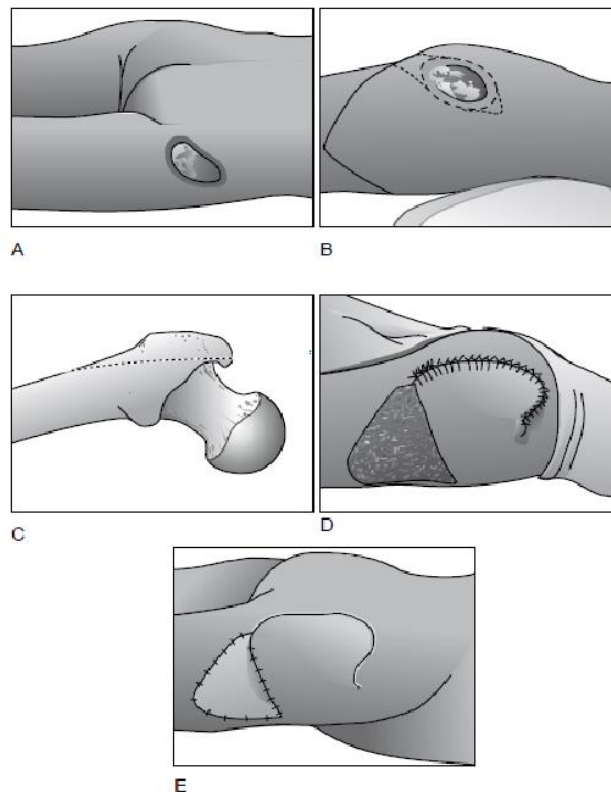
**Fig. 34-22 SACRAL PRESSURE SORE REPAIR.**  
 A, marking the flaps, with back-cuts. B, secondary defects, which you can usually close primarily.  
 After MacGregor, IA. *Fundamental Techniques of Plastic Surgery*, Churchill Livingstone 1980 p.230,232 Figs 7.2,4.

**If there is a trochanteric sore,** use a **LATERALLY-BASED POSTERIOR THIGH TRANSPOSITION FLAP (GRADE 2.5)**.

You can make the blood supply of the flap more reliable if you incorporate the ilio-tibial tract (the *tensor fascia lata* muscle) into the flap, thus making it a myocutaneous flap.

(Its length can then be up to 3x its base.) Remember to cut off a wedge of protruding femoral trochanter (34-23C).

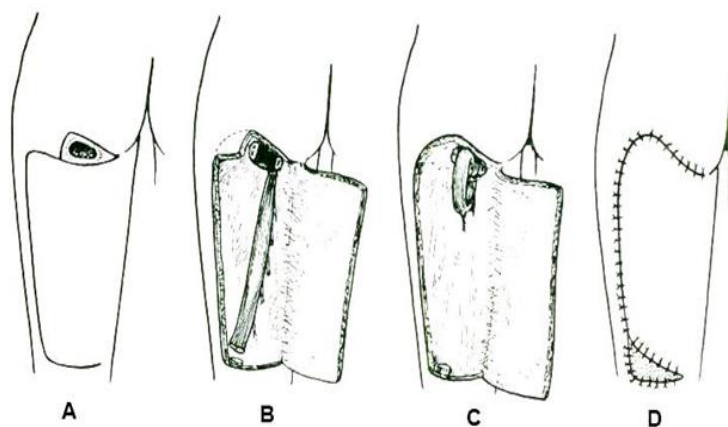
**TROCHANTERIC PRESSURE SORE REPAIR**



**Fig. 34-23 TROCHANTERIC PRESSURE SORE REPAIR.**  
 A, outline the sore. B, mark out the transposition flap on the lateral upper thigh. C, excise a lateral wedge of trochanter. D, transfer the flap by rotating it clockwise. E, skin graft the remaining defect.  
 After MacGregor, IA. *Fundamental Techniques of Plastic Surgery*, Churchill Livingstone 1980 p.231 Fig 7.3.

**If there is an ischial sore,** use a **MEDIALY-BASED POSTERIOR THIGH TRANSPOSITION FLAP (GRADE 2.5)**.

**ISCHIAL PRESSURE SORE REPAIR**

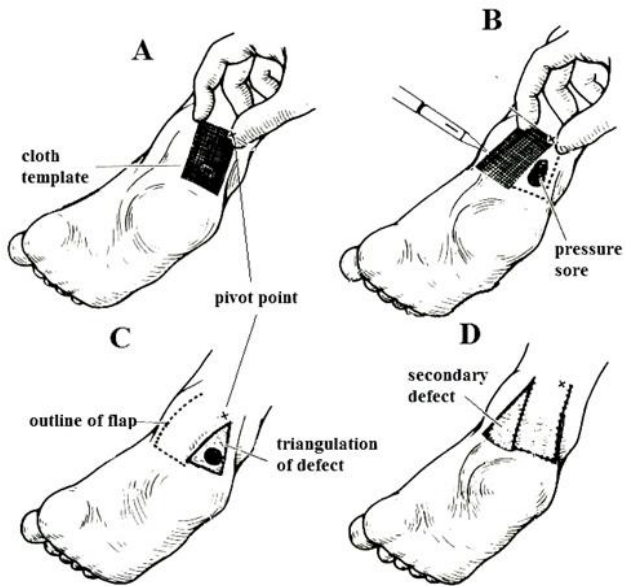


**Fig. 34-24 ISCHIAL PRESSURE SORE REPAIR.**  
 A, mark the transposition flap. B, expose the hamstring muscle with the flap prepared. C, divide the hamstring muscle and roll its distal end into the cavity left by excising the ischial tuberosity. D, close the wound, and graft the small defect inferiorly.  
 After MacGregor, IA. *Fundamental Techniques of Plastic Surgery*, Churchill Livingstone, Edinburgh 1980. p.233 Fig 7.5.

Flex the hip when you plan the flap: *ensure suture lines don't rest on pressure points*. Make a very broad-based flap, and excise the ischial tuberosity; this leaves a dead space which, in a paraplegic, you can fill by dividing the lower end of the hamstring muscle, dividing the lower half of its perforating vasculature, and rolling it upwards into the defect (34-24C). Then transpose the flap superiorly to cover the defect.

*N.B.* If you use a *tensor fascia lata* flap, the blood supply is more assured, but make the flap longer.

### HEEL PRESSURE SORE REPAIR



**Fig. 34-25 HEEL PRESSURE SORE REPAIR.**

A, make a cloth template of the flap. B, outline the flap, noting its pivot point, and triangulate the defect. C, cut the flap. D, transpose the flap and graft the residual defect.

**If there is a foot sore**, examine the insensitive foot carefully (32.11). For an uncomplicated heel sore, use a SUPERIORLY-BASED POSTERO-MEDIAL TRANSPOSITION FLAP (GRADE 2.5).

Mark the flap out carefully, triangulate the defect, and transpose the flap. Graft the residual defect.

*N.B.* Don't take skin from the ball of the heel: it is specialized for walking!

**If the Achilles tendon is involved in the sore**, remove its necrotic parts; sacrifice it in a paraplegic.

**If the foot is hopelessly infected**, perform an amputation (35.3).