

# 36 Thoracic surgery

## 36.1 Spontaneous (non-traumatic) pneumothorax

Most thoracic surgery is outside the scope of this manual; check elsewhere for drainage of pus in the pleura (9.1), pericardium (9.2) and lung (9.3). Consult Volume 2 for traumatic pneumo- and haemo-thorax.

Pneumothorax describes air collecting in the pleural space. This air will compress the lungs, and if there is a communication with the air passages, the pneumothorax may continue to expand alarmingly. The mediastinum may then shift and block venous filling of the heart, producing profound shock (a tension pneumothorax).

Pneumothorax can occur spontaneously, typically in tall young adults, or secondary to lung disease, classically with TB, asthma, pneumocystis pneumonia in HIV+ve patients, anorexics or those with cystic fibrosis. Frequently a ruptured bulla on the lung surface is the cause, and this is more frequent in smokers, especially cannabis smokers.

### (a) Clinical features

There may be chest pain and breathlessness: *the severity of symptoms doesn't give an indication of the size of the pneumothorax*. You will note an absence of breath sounds on the affected side, and a thorax resonant or hyper-resonant to percussion. However, signs may be subtle. Agitation may be the sole sign of hypoxia. Check the pulse and blood pressure: hypotension may develop quickly. Check for the position of the trachea manually in the supra-sternal notch: if it is shifted to the opposite side, a tension pneumothorax may be developing, *though it remains central if there are bilateral tension pneumothoraces*.

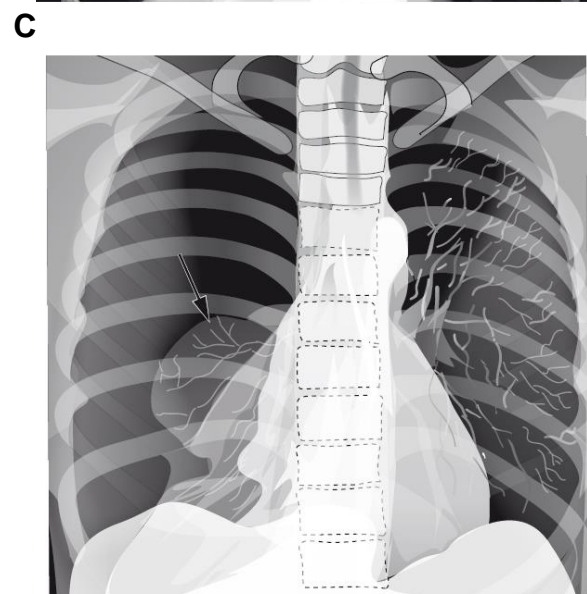
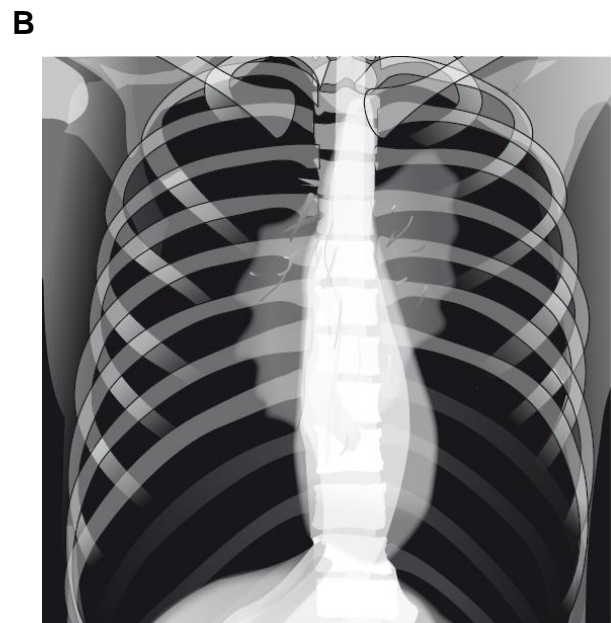
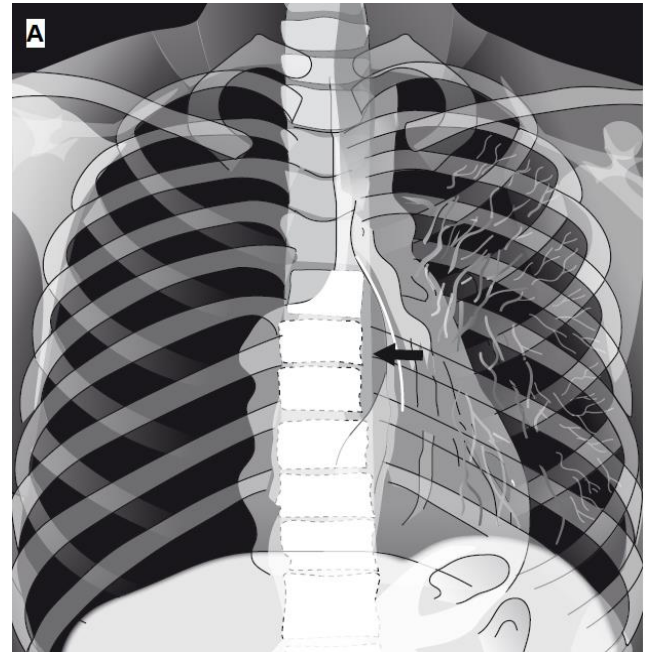
### (b) Radiographs

An *erect* PA chest radiograph, best taken in expiration, shows the typical uniform black appearance of air in the pleural cavity with *the absence of lung markings*. Look for a thin line medially marking the edge of the lung. *Don't confuse this with the medial edge of the scapula!*

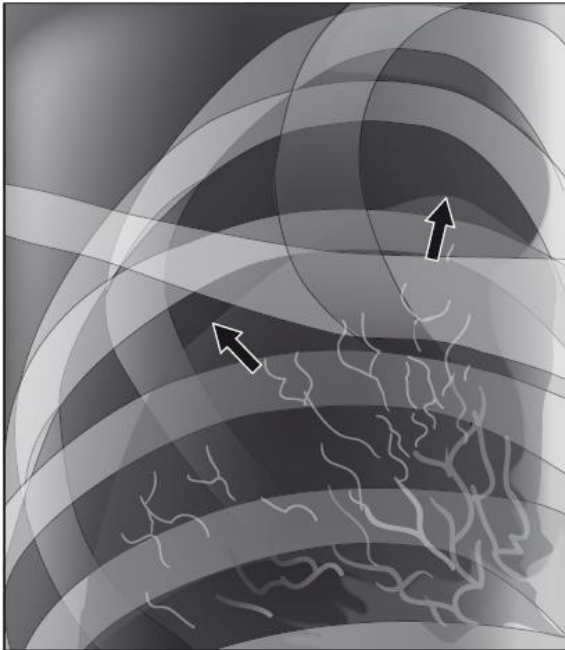
In adults, a visible rim  $>3\text{cm}$  from the chest wall represents a pneumothorax  $>50\%$ . You occasionally need a lateral chest radiograph to show the pneumothorax. A *supine* radiograph may not show a pneumothorax clearly.

### (c) Ultrasound

Place the probe either longitudinally or transversely below the clavicles in the midline, and watch for the sliding movement of the lung against the pleura, seen as a bright line below the dark rib, as a constant 'wiggle'. You can also see, dropping from this line, so-called 'comet tails' which are artefacts. These don't appear in a pneumothorax and there is no 'wiggle'.



D



**Fig. 36-1. RADIOGRAPHS SHOWING A RIGHT-SIDED PNEUMOTHORAX.**

**A**, tension pneumothorax, with tracheal and mediastinal shift (shown by the arrow). *You should not see this image, because you should already have put in a needle to decompress the pneumothorax!* **B**, bilateral tension pneumothorax (no lung vessel markings visible, trachea central and a heart that has 'disappeared'). *Likewise, you should not see this image, but have dealt with it by needle decompression beforehand!* **C**, large pneumothorax, showing the totally collapsed lung border (shown by the arrow). **D**, medium-sized pneumothorax (supero-lateral section) showing the lung border >3cm from the edge of the chest wall, signifying partial lung collapse with a pneumothorax of >50%.

#### (d) Treatment

*N.B. Don't delay! A tension pneumothorax may develop very quickly! This is a critical emergency!* So much air has filled the pleural space that the mediastinum is pushed to the opposite hemithorax, thus reducing venous return to the heart. Immediately insert a large cannula or needle in the 2<sup>nd</sup> intercostal space, in the mid-clavicular line, and as soon as you can, insert a formal chest drain in the 4<sup>th</sup> intercostal space in the midaxillary line.

**If there are bilateral pneumothoraces**, insert a needle as for a tension pneumothorax on both sides, and as quickly as possible, insert a chest drain first on the worse side, and then on the other. Or, insert drains simultaneously if someone can assist you.

**If the pneumothorax is small** (the rim <2cm from the chest wall) and there is no breathlessness, observe the patient for 24h and repeat the chest radiograph. If the rim has enlarged, aspirate as below.

*N.B. You should advise a patient to avoid non-pressurized air travel till the pneumothorax is completely resolved, and to avoid smoking and deep-sea diving permanently.*

**If it is spontaneous, associated with no fluid, and it is the first occasion it has happened**, insert a wide-bore cannula in the 2<sup>nd</sup> intercostal space in the mid-clavicular line and aspirate through this, or attach it *via* a piece of giving set to an underwater seal drain. Usually 30mins is sufficient, but if you drain <2.5L air, repeat the exercise. An alternative to using an underwater seal drain with its bottle which might spill, fall over and break, is attaching a sterile glove with 2 fingers cut off to the tube attached to the cannula. This way, air will exit but not enter.

**If the pneumothorax is large**, insert a cannula or needle first before inserting a formal drain to avoid a sudden rapid evacuation of the pneumothorax, which can cause problems (see below).

**If the pneumothorax is associated with air in the mediastinum or pericardium**, there may be an oesophageal perforation (30.7).

**If it is a repeat pneumothorax, or a hydro- or haemothorax, or due to trauma**, insert a formal chest drain.

*N.B. Don't apply suction* (except if you suspect a broncho-pleural fistula: see below!)

*N.B. Don't clamp a chest tube* unless there is sudden chest pain from rapid re-expansion of a collapsed lung causing pulmonary oedema. *In rare cases this may be fatal!*

Once there is no more air bubbling out of the chest, or >50ml draining per day, remove the drain. Get an assistant to hold the skin opening closed, ask the patient to breathe in, hold his breath, and rapidly pull out the drain.

*N.B. Don't remove the drain slowly so that air can return to the pleural cavity by way of one drain hole outside the chest and one inside!*

Repeat the radiograph if you have doubts about a persisting or recurrent pneumothorax.

**If the pneumothorax is iatrogenic** (e.g. caused through insertion of a central venous line), treat this initially with puncture and aspiration alone. Keep the patient under observation and repeat a chest radiograph after 24h.

**If the pneumothorax persists**, probably due to a broncho-pleural fistula, apply suction up to a pressure of 20cm water (=15mm Hg) to see if this makes the lung stick to the chest wall. If this fails, prepare a sterile slurry of 2-5g talc in 50ml saline and add 20ml 1% lidocaine, and inject this via the chest drain into the pleural space using a wide-bore syringe. This causes an adhesive inflammation, and is often very painful, so use copious analgesics. Continue the suction. Repeat the chest radiograph after 24h, and if there is only minimal fluid and residual air, remove the drain. If this fails, wait a week, and if the pneumothorax persists, do the same thing with 1% silver nitrate solution instead of talc.

*Avoid positive pressure ventilation in anyone with a pneumothorax: it may enlarge catastrophically!*