

# 6 The surgery of sepsis

## 6.1 'Where there is pus, let it out'

Draining pus is the commonest surgical operation in low- and middle-income countries all over the world. It is also one of the most useful and usually one of the simplest. Quite a small district hospital can expect to drain 200 large abscesses each year, some containing up to 3 litres pus. Although pus can collect almost anywhere, particularly important sites are the breast (6.13), muscles (7.1), bones (7.2), joints (7.16), hand (8.1), pleura (9.1), peritoneum (10.1), and eye (28.3). The most serious consequence of pyogenic infection is septic shock.

Why sepsis of all kinds is so common is not altogether clear, but malnutrition, anaemia, HIV, diabetes and poor hygiene may all play a part. Over 50% of patients with surgical sepsis are malnourished (with protein and calorie deficiency): the malnutrition is either primary or arises because of the sepsis. It may not be immediately visible in fat patients! This malnutrition increases the risk of further infection, pressure sores (34.16), pneumonia and multi-organ failure.

Abscesses are more common in children and young adults, and a patient may have a dozen or more at the same time. *Staphylococci* are almost always responsible, except in the perineal and perianal region, which is commonly infected by coliforms and anaerobes. Some abscesses are tuberculous (5.7), or from actinomycosis. In the presence of HIV disease, Gram-ve organisms may be responsible at any site.

Initially, when there is cellulitis (bacteria multiplying in the tissues), antibiotics will be effective. Infection should then abate within 24h, or develop an abscess, which needs draining. Before pus has collected, drainage is not possible. Antibiotics and drainage thus both have their proper time and place, and *you must not confuse them*.

The tighter the space for an abscess, the more urgent the need for drainage. If a patient has pus in the bones, joints, tendon sheaths, or the pulp space of the fingers, draining it early is particularly urgent. Elsewhere, you have more time, but then pus may not present itself so obviously! If pus gathers in loose tissues near the surface of the body, you can usually detect fluctuation.

But you will not detect fluctuation, or only detect it very late, if pus is under tension in some tight compartment, or if it is inside a large fatty region such as:

- (1) the pulp spaces of the fingers or toes (8.5),
- (2) the fascial spaces of the hand (8.12) or foot (8.17),
- (3) the ischio-rectal fossae (6.17),
- (4) the lobules of a woman's breast (6.13),
- (5) the neck or iliac regions (6.16),
- (6) the parotid gland (6.10).

Incise abscesses in any of these places without waiting for fluctuation, or for pus to point.

For fluctuation to be a useful sign, a minimum quantity of pus must be present, and it must be near the surface. *Don't wait till a huge bag of pus has formed and much tissue has been destroyed. Use a needle to aspirate: you will be surprised how often you find pus!* Even if you don't find pus, an incision will allow infection to drain more readily (by the path of least resistance).

### Some sites of sepsis

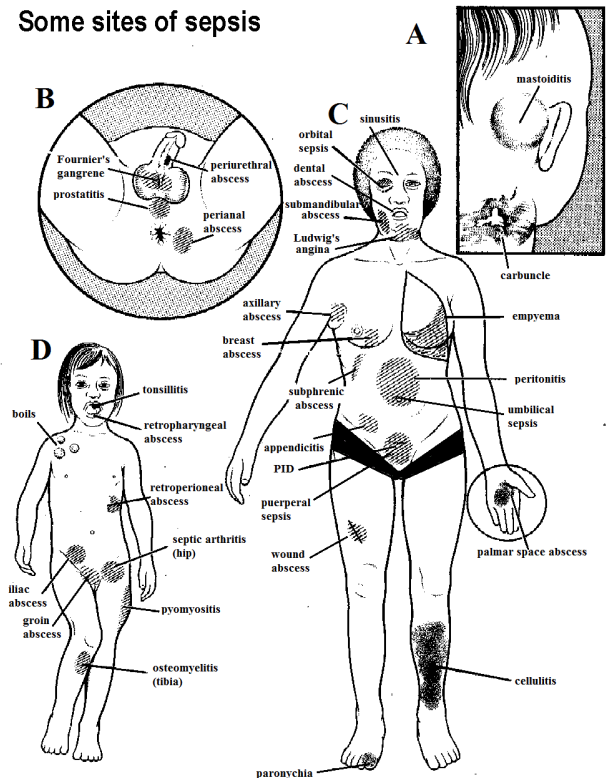


Fig. 6-1 SOME SITES OF SEPSIS. Pus can gather almost anywhere, but here are some of the commoner places: A, behind a child's ear. B, in the male perineum. C, in an adult female. D, in a child.

### WHERE THERE IS PUS, LET IT OUT

## 6.2 Abscesses

The typical symptom of an abscess is severe throbbing pain. The infected part is tender (*dolor*) and swollen (*tumor*), and the skin over it stretched, shiny, and red (*rubor*), although this may not be evident on pigmented skin. Touching an abscess is acutely painful. If it is large or there are several abscesses, fever, weakness, toxæmia, and anaemia may be present. The usual signs of inflammation and suppuration suggest the diagnosis, but *don't necessarily expect to find fluctuation in the sites where pus is in a tight compartment*. Severe pain is a useful sign that an abscess is ripe for incision, but pain may be mild when the tissues are loose. If diagnosis is difficult, try aspirating it with a syringe and a wide bore (1.5mm) needle, but remember that pus may be present *even if you fail to aspirate any*. Always aspirate a lump if there is the slightest hint of diagnosing an abscess: tubercular abscesses are often *not* warm, hence the term 'cold abscess', but they are not actually cold! *Never try to treat an abscess by one aspiration alone*. An ultrasound scan may be useful in detecting a localized fluid collection.

Even if an abscess has ruptured spontaneously, adequate drainage by incision is necessary. *There is no need to curette the walls of an abscess*, except in the hand where you want inflammation to resolve particularly rapidly and completely. Suspect a wound abscess if a suture line becomes indurated and tender; it may not be fluctuant (11.13).

So incise an abscess adequately and let the pus flow out; break down any septa in a large cavity and open up any smaller cavities (loculi) off the main one.

Abscesses are often placed at the end of an operating list of otherwise 'clean' cases, and are often left to very junior staff. They are often not treated as genuine emergencies, even though the great risk of septicaemia is ever present. *Don't therefore underestimate the seriousness of abscesses!*

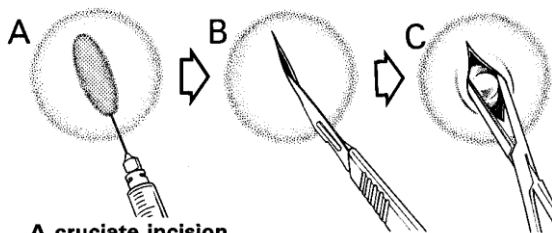
Nevertheless, *be careful*:

- (1) The diagnosis can be difficult, *e.g.* an iliac abscess (6.16).
- (2) Drainage has its risks, especially severe bleeding when there is a large abscess or many of them, so watch blood loss carefully.
- (3) A superficial abscess over the tibia, femur, or humerus may turn out to be pyomyositis (7.1) or, more seriously, osteomyelitis (7.2).
- (4) A 'chronic abscess' may turn out to be a solid tumour. Some cancers may present as infections (24.4; 34.15).
- (5) *Don't forget the possibility of TB!*

ULTRASOUND will readily demonstrate a collection of fluid: use this if you can when the diagnosis is unclear.

## INCISION AND DRAINAGE

### A linear incision



### A cruciate incision

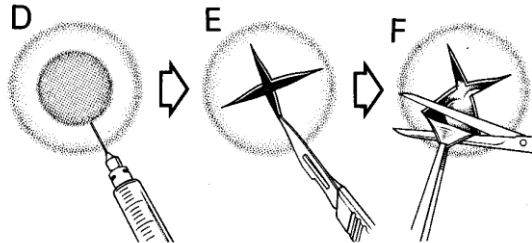


Fig. 6-2 INCISION AND DRAINAGE (I&D).

A-C, linear incision being made and its edges spread. D-F, cross-shaped incision, cutting off the edges of the skin, and so removing the roof of the abscess. After Hill G.J. *Outpatient Surgery*, WB Saunders 1973 Fig. 5.12, with kind permission.

EXAMINATION. Assess the general condition carefully, especially if there are many abscesses, or large ones. Look for anaemia.

## SPECIAL TESTS

(1) **If the infection is severe**, take blood cultures. You may be able to isolate the causative organism (this is important in osteomyelitis).

(2) Test the blood or urine for sugar; this may be the first presentation of diabetes: always do this if there is more than one septic infection.

(3) **If there is a particularly large or unusual abscess** (especially in the hand in the absence of trauma or penetrating foreign body, thyroid, muscle, abdominal wall, retroperitoneal space, penis and scrotum, or in the breast of a non-lactating woman), or recurrent ones, test for HIV.

ANTIBIOTICS *are not usually needed*. Use them *only* if:

- (1) there is a severe constitutional disturbance with high fever and toxæmia;
- (2) there are signs that the infection is spreading: increasing erythema, cellulitis, lymphangitis, severe lymphadenitis, or fever;
- (3) the abscess is in the groin (a 'bubo') related to *chlamydia* (lymphogranuloma venereum): use doxycycline;
- (4) the abscess is deep-seated, *e.g.* in the brain or liver (15.10).

## DRAINAGE OF AN ABSCESS (GRADE 1.2)

INDICATIONS. A collection of pus anywhere accessible.

**If you suspect that there is a foreign body in an abscess**, this is an added reason for exploring it. Try to remove the offending object and drain the cavity at the same time.

**If you are not sure if pus is present or not**, aspirate the lesion with a wide bore needle to see if you can withdraw pus. If pus is present, drain it.

**If you fail to aspirate pus with a needle**, *this does not mean that there is no pus present!*

*Signs that an infection is spreading are not a contraindication to drainage*; if you suspect pus is present, drain it.

## ANAESTHESIA

(1) You don't need muscular relaxation, so ketamine is very suitable.

(2) If an abscess is already pointing, but the superficial skin is not paper-thin, you can infiltrate the skin at the site of the incision with LA (6-2A). Alternatively you can infiltrate all around the circumference of the abscess, if this is not too big.

(3) Use morphine or pethidine beforehand if the abscess is big or in a sensitive spot, especially for inpatients.

(4) Ethyl chloride local spray is the least satisfactory, but you can use it for very superficial abscesses where the skin is so thin that LA infiltration is virtually impossible. It makes the tissues hard and difficult to incise.

(5) For babies <6-9 months, a quick incision is safer (and kinder) than multiple needle pricks to establish LA or GA.

(6) IV diazepam with pethidine has the hazards of a proper GA and requires all the usual precautions, and *has no advantage over ketamine*.

## INCISION

Drain the abscess at the site of maximum tenderness and try to follow Langer's lines (34-1E).

**If an abscess is superficial**, use a pointed (#11) blade (6-2).

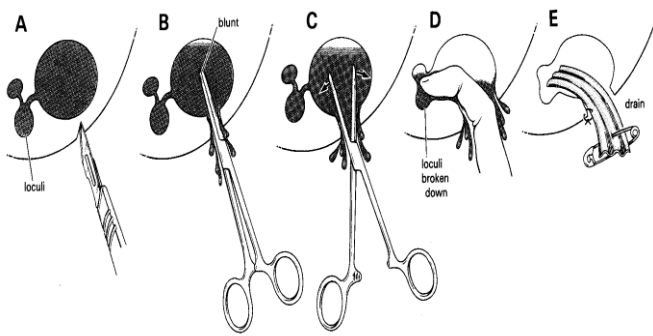
### CAUTION!

(1) **If the abscess is deep**, try to incise parallel to any nerves or vessels, not across them.

(2) *A common mistake is not to make the incision large enough*, so extend the incision the whole diameter of the abscess!

HILTON'S METHOD is indicated if there is anything near the abscess which you might possibly injure. Incise the tissues down to the deep fascia; then push blunt scissors or a haemostat into the softest or most prominent part of the swelling. Open them out inside the abscess. If necessary, enlarge the wound by blunt dissection inside the tissues.

### EXPLORING AN ABSCESS



**Fig. 6-3 EXPLORING AN ABSCESS BY HILTON'S METHOD.**  
**A**, incise the abscess at its lowest point, if this is practicable. **B**, push blunt scissors or a haemostat into it. **C**, open the haemostat. **D**, explore the abscess with your finger. **E**, insert a drain.

**DRAIN THE PUS** by putting your finger into the abscess, and breaking down all the loculi, so that there remains only one cavity. Use your little finger if the abscess is small.

**If there is much pus**, suck it out or clean out the cavity with a swab. Make sure you remove all the pus: rinse the cavity thoroughly with water: you may need to squeeze for some time till all the pus comes out: this is painful for the patient so use adequate analgesia. *Provide free drainage*. Make sure that any more pus which collects can drain from the bottom of the cavity.

**If the abscess you are draining has a tendency to heal over and leave a cavity**, derroof it (6-2F). This is especially necessary with perianal (6.17) and Bartholin's abscesses. Cut away some skin, particularly any dead skin. Allow drainage with a soft rubber drain with a suture to hold it in place.

**If pus has to drain downwards**, as in the breast, try to incise the lowest part of the abscess. This is better than making a counter incision at its lowest point, and it also avoids making 2 incisions.

**If the drained abscess site bleeds**, pack the cavity (3.1). If necessary, infuse IV 0.9% saline. You rarely need to transfuse blood unless there are multiple abscesses or severe pre-existing anaemia.

**GENERAL MEASURES.** **If the abscess is in some critical place**, such as the lateral pharyngeal space (6.9), or the mid-palmar space (8.9), admit the patient. Make sure the fluid intake is adequate, and *don't forget to supply an analgesic*: abscesses are painful!

**POST-OPERATIVE CARE.** Rest the affected part, and where possible raise it. For example, put the hand in a St John's sling, or, for an inpatient, raise the hand in a roller towel.

### ALWAYS INCISE AT THE POINT OF MAXIMUM TENDERNESS

**If the foot is infected** (8.17), raise the foot of the bed. Make sure your nurses wash the abscess cavity and *don't merely put a dressing on the surface*: the wound will then close over the cavity and the abscess will recur. Make sure free drainage remains possible.

### DIFFICULTIES WITH ABSCESSSES

**If there is severe prostration without a fever**, suspect that resistance to infection is low and treat with particular care. Check the HIV status.

**If there are many abscesses**, with pyaemia, multiple sites of pyomyositis, or septicaemia, bleeding may be profuse when you drain the abscesses. For anaemia, transfuse pre-operatively and, if necessary, again during the operation. Draining multiple abscesses is a major procedure, particularly if a child is severely anaemic or malnourished, so be careful before you incise too many abscesses at one sitting: *children have been known to bleed to death!*

**If there is a huge abscess in a very ill patient**, he will not tolerate an extensive procedure. It may occasionally be necessary to take him to the theatre several days in succession for repeated drainage, slowly increasing the exposure.

**If an abscess fails to heal**, *don't forget the possibility of diabetes, TB (5.7) or HIV (5.6)*, or a combination of these, syphilis, an underlying tumour, or occasionally actinomycosis (which produces yellow so-called 'sulphur' granules). In Southeast Asia, think of melioidosis (6.10). Check that no foreign body, *e.g.* part of a drain or suture, has been left *in situ*.

*N.B.* The best instrument to find and pull out a suture knot in a chronically infected wound is a crochet hook!

**If you suspect a TB or syphilitic lymph node abscess**, perform an ULTRASOUND and look for perinodal fluid, necrosis of the lymph node and calcification. Drainage is not necessary and will only risk causing a non-healing sinus *if you don't treat the underlying cause*.

### 6.3 Pustules (Boils)

Pustules, as well as carbuncles (6.4), are contagious skin infections which are usually caused by penicillin-resistant *staphylococci*. There may be a crop of them, and in a closed community they may become epidemic.

Clean the skin round the boil with water, and cover it with a dry dressing. Let it burst spontaneously. If it is pointing, a small incision will let it discharge and will reduce the pain. You can use a sterile needle to do this.

**CAUTION!** *Never squeeze a pustule; especially on the face, never let the patient squeeze it.*

**If there are many pustules**, advise washing thoroughly with soap and water, and to shower bd. The bath, shower and toilets must be clean. Advise a daily change of underwear, and washing it by boiling. Exposure to the sun is one of the best cures. *Avoid using 'roll-on' deodorants.*

### 6.4 Carbuncles

A carbuncle is typically the result of neglected skin infection in a dirty, malnourished, and underprivileged patient, particularly a diabetic or one with HIV. A staphylococcal infection starts in one of the hair follicles, usually at the back of the neck or on the back of a finger (8.1), and then spreads. In doing so, the infection lifts the skin above it on a sea of necrotic fat and pus. At presentation, pus will probably be discharging. *Antibiotics don't cure a carbuncle*, although they may stop it spreading. You will probably have to let the slough separate slowly, and then remove it.

Be sure to test the blood or urine for sugar. Consider HIV testing.

**If a collection of pus forms**, cut down on it and drain it.

**If the skin around the carbuncle is hairy**, shave it with as little trauma as you can. Wash it with water, apply dry gauze, and change this frequently. A large slough will form in the middle of the carbuncle. You may be able to lift the slough off painlessly without an anaesthetic.

**If the slough is slow to separate**, excise it, and apply a dressing of petroleum jelly gauze.

**If the bare area is large**, apply a split skin graft, as soon as it is clean and granulating.

**If a black central pustule with surrounding vesicles forms**, consider ANTHRAX and treat with penicillin IV.

**If multiple pustules enlarge and spread exuding 'sulphur granules'**, this is botryomycosis (*not a fungal infection, though it looks like mycetoma*): treat this with debridement and longer-term broad spectrum antibiotics.

### 6.5 Extradural abscess

Pus may gather between the skull and dura as the result of:

- (1) The spread of infection from sepsis nearby.
- (2) Exposure of the bone as the result of an injury.
- (3) Metastatic spread from elsewhere in the body.

**If the abscess is large**, there will be fever with signs of raised intracranial pressure (impaired consciousness and pupillary changes) and localizing motor signs, usually on the other side of the body, but not always so. Locally, there may be a diffuse inflammatory oedematous swelling of the scalp over the lesion (Pott's puffy tumour). If the abscess is not so large, the only symptoms may be confusion. Making burr holes should be one of your basic skills, so draining the pus should not be too difficult.

If you have limited imaging facilities, your problem will be to diagnose an extradural abscess in the first place and to know where it is: the abscess is underneath the swelling.

**SPECIAL TESTS:** The skull radiograph will only show changes if an extradural abscess is chronic, or if there is osteomyelitis of the bone. If you can perform a carotid arteriogram (38.1), this will localize the abscess beautifully.

#### DRAINAGE (GRADE 3.3)

Drain the extradural abscess through a burr hole. Make this on the edge of the area of swelling on the skull (where present), and nibble away the skull around it until the abscess is well drained.

**If the abscess is secondary to osteitis, and there is a sequestrum**, removing it will drain the abscess adequately. Likewise, if it is secondary to a neglected compound depressed skull fracture, elevation of the bone fragments will locate and drain the abscess.

### 6.6 Infections of the orbit

Acute suppurative infection is common near the eye, especially in children. It can occur in front of or behind the orbital septum. This is a sheet of fibrous tissue which stretches from the edges of the orbit into the eyelids, and divides the periorbital region from the orbit. Infections of both these regions usually start acutely with erythema and oedema of the eyelids; distinguish between them as described below. The danger with any infection in this region is that infection may occasionally kill the patient by spreading to the cavernous sinus or the meninges.

**(a) Periorbital cellulitis** occurs in front of the orbital septum, is more common than orbital cellulitis and occurs in younger children. It can be primary, or secondary to: (1) local trauma, (2) skin sepsis, (3) a recent upper respiratory infection often with *H. influenzae* (associated with bacteraemia).

**(b) Orbital cellulitis** occurs behind the orbital septum, and is less common but more serious. It is usually due to spread from the paranasal, commonly the frontal or ethmoid, sinuses.

**(c) Subperiosteal abscesses** may form when bacteria spread from the adjacent sinuses.

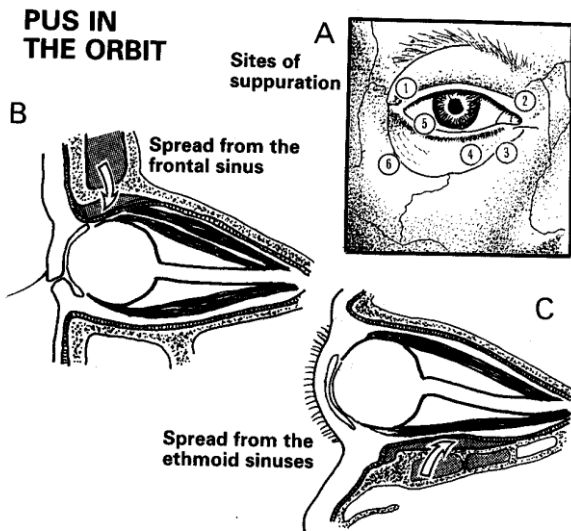


Fig. 6-4 PUS IN THE ORBIT.

A, some important infections around the eye. B, pus spreading under the periosteum from the frontal sinus. C, pus spreading under the periosteum from the ethmoid sinus.

(1) lachrymal gland (dacryoadenitis). (2) frontal sinus and anterior ethmoidal air cells (sinusitis). (3) tear sac (dacryocystitis). (4) tarsal cysts. (5) sty (hordeolum). (6) periostitis of the margin of the orbits and suppurating tarsal cysts can occur anywhere on the lids, and periostitis anywhere in the orbit.

After Dudley HAF (ed) Hamilton Bailey's Emergency Surgery, Wright 10th ed 1977 Figs 187-9, with kind permission.

(d) **Cavernous sinus thrombosis** can be:

- (1) Occasionally, aseptic as a result of trauma, tumours, or marasmus.
- (2) More commonly, septic as a result of the spread of infection from the nose (a nasal furuncle is the commonest source), face, mouth, teeth, sphenoid or ethmoid sinuses, the middle ear, or the internal jugular vein.

A cord of thrombus spreads from the site of the infection to the cavernous sinus, and sometimes to the cerebral veins and meninges to cause:

- (1) A rise in pressure in the veins draining the eye, resulting in severe oedema and proptosis.
- (2) Paralysis of the III<sup>rd</sup>, IV<sup>th</sup>, VI<sup>th</sup> (commonly) and the first 2 branches of the V<sup>th</sup> cranial nerves.
- (3) Meningeal irritation.
- (4) Depressed conscious level. If treatment starts late, visual impairment, ocular palsies, and hemiplegia may result.

RANGIT (60yrs) was admitted with a history of septic teeth for many years. Recently he had had fever, headache, rigors, and gradual swelling of the mandible. He was ill, dehydrated, shocked, jaundiced, and confused. Pus discharged from his mouth, the submental glands were enlarged, the neck was stiff, and Kernig's test was positive. Both globes were proptosed, particularly the left, which was fixed; the forehead and cheek were oedematous, and the CSF turbid. Despite vigorous antibiotic treatment he died. Postmortem examination revealed left dental and mandibular abscesses; the left orbit and cavernous sinus were full of pus.

LESSONS (1) This is a very dangerous condition. (2) Proptosis in the presence of facial sepsis is a sign of danger. (3) The organisms responsible are often penicillin-resistant.

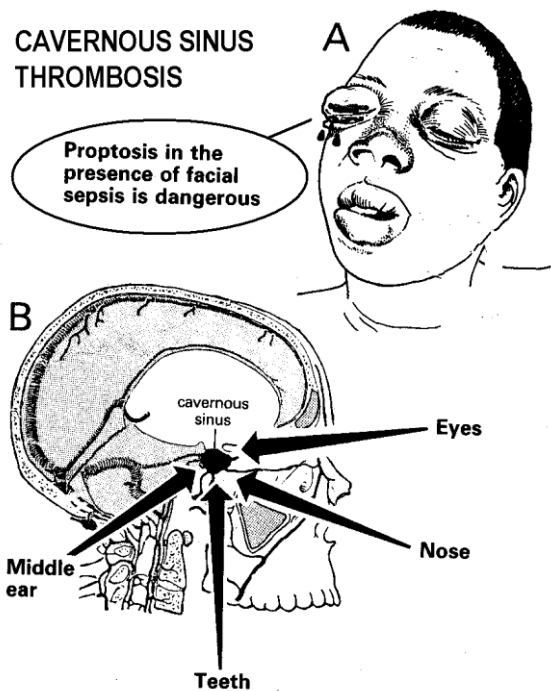


Fig. 6-5 CAVERNOUS SINUS THROMBOSIS.

A, orbital oedema and proptosis may be associated with paralysis of the III<sup>rd</sup>, IV<sup>th</sup>, VI<sup>th</sup> (commonly), and the first 2 branches of the V<sup>th</sup> cranial nerves, and also with meningeal irritation. B, infection may spread to the cavernous sinus from the eyes, nose, teeth, middle ear, or the paranasal sinuses.

*Don't be frightened of operating in the orbit.* Because of the danger of cavernous sinus thrombosis, you must drain pus early. A negative exploration will not cause harm, and you are very unlikely to damage the globe.

#### EXAMINATION

Gently separate the eyelids. Examine for induration and tenderness of the lids, chemosis (subconjunctival oedema), proptosis (his globe is pushed forwards), limitation of ocular movement, and loss of visual acuity.

**RADIOGRAPHS.** Infection may have spread from the paranasal sinuses, so consider X-raying them (if this is possible), to see if you can find a loss of translucency on the affected side (29-8). The films may be difficult to interpret, especially in children in whom the sinuses are small.

**TREATMENT.** If you suspect orbital cellulitis, take blood cultures and start IV penicillin with cloxacillin or chloramphenicol. Or, use a cephalosporin immediately!

#### CAUTION!

- (1) Oedema and erythema of the lids are common to both orbital and periorbital cellulitis.
- (2) If the treatment of orbital cellulitis is delayed or incorrect, cavernous sinus thrombosis may follow.

### DIFFICULTIES WITH ORBITAL SEPSIS

If the globe is displaced by an inflammatory swelling, and its movement impaired, perhaps accompanied by loss of visual acuity, suspect a subperiosteal abscess of the orbit. For example, an abscess above the eye will displace it downwards. Try aspirating the pus from the roof of the abscess with a needle. The eye may go back into place. Then incise and evacuate the abscess through a conjunctival fornix: the inferior fornix if swelling is maximal inferiorly, and the superior fornix if it is maximal superiorly. Pus will probably be coming from a paranasal sinus and you may find the track through which pus has spread. Insert a drain.

If there is an inflammatory swelling in the upper, outer part of the orbit, involving the outer 3<sup>rd</sup> of the upper lid, suspect that the lachrymal gland is infected (DACRYOADENITIS). Incise the abscess through the upper fornix of the conjunctiva, or through the eyelid.

If there is an inflammatory swelling below the medial aspect of the lower lid, suspect an abscess in the lachrymal gland (DACRYOCYSTITIS). Press it; pus may exude through the punctum. If it suppurates, incise it through the skin of the lower lid. When the infection has subsided, arrange for a dacryocystorhinostomy which will usually re-establish the flow of tears.

If the conjunctiva becomes increasingly congested with bloody tears, the globes protrude, the ocular movements become more and more impaired, accommodation paralyzed, the pupil fixed and dilated, and the cornea anaesthetic, this is a CAVERNOUS SINUS THROMBOSIS. It will probably involve both eyes. Early vigorous treatment may avoid death. Use high-dose IV penicillin with chloramphenicol or a cephalosporin, together with diuretics (furosemide or mannitol) to reduce cerebral oedema. Don't forget to deal with the cause of the sepsis!

### 6.7 Peritonsillar abscess (Quinsy)

Abscesses round the tonsils are quite common, and follow tonsillitis. The patient, who is usually a child, has a tense swelling above and behind one of the tonsils, displacing it downwards and forwards. Non-operative treatment is almost always successful and is much safer than draining, which is a heroic procedure and is seldom necessary, because much of the swelling is inflammatory oedema.

#### NON-OPERATIVE TREATMENT

Treat as an inpatient with IV penicillin, ampicillin, or chloramphenicol, as well as IV fluids and morphine or pethidine. Expect a response within 24h: the abscess will probably burst spontaneously, or the inflammation will subside sufficiently to make drainage much easier.

### PUS IN THE THROAT

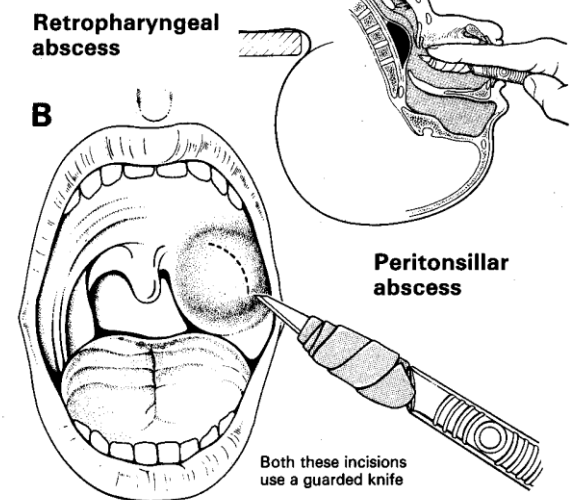


Fig. 6-6 TWO ABSCESSES IN THE THROAT.

A, the danger with a retropharyngeal abscess is that an unconscious child may inhale pus and get bronchopneumonia. Avoid this by incising it while the head is hanging over the end of a table. B, peritonsillar abscess occasionally follows tonsillitis, and may need draining. Do both these incisions with a guarded knife that cannot cut too deeply.

#### INCISION (GRADE 1.4)

In the unlikely event that non-operative treatment fails, sit the patient upright in a chair with the head supported, and a gag in the mouth. Get a very good headlight.

#### CAUTION!

- (1) Don't allow inhalation of pus.
- (2) Have suction instantly available.

Spray the pharynx with LA solution, such as 4% lidocaine. If opening the mouth wide enough is impossible, you may have to use GA and intubation with the head on the side as low as possible. Place a swab over the tongue. Pack the pharynx. This can be very hazardous anaesthesia. Have a tracheostomy set (29.15) and suction ready.

Use a guarded scalpel to incise the abscess over its most prominent part (6-6B). Divide only the mucosa; then use sinus forceps to find pus by Hilton's method (6.2).

If severe bleeding follows and you cannot control it, try firm compression through the mouth with a tightly rolled swab. You will then be faced with a very difficult intubation, keeping pressure on the tonsillar fossa in order to insert tight 'figure of 8' sutures around the bleeding points.

### 6.8 Retropharyngeal abscess

Occasionally, an abscess forms in the lymph nodes behind a child's pharynx which bulges forwards. Sometimes an abscess is the result of infection round an impacted fish bone. If the swelling is large enough, asphyxiation may result. If it bursts, aspiration pneumonia may result. The major differential diagnosis is a chronic tuberculous abscess, which may have spread from the cervical spine.

## TREATMENT

**If the patient is dehydrated**, correct the deficit with IV fluids.

### INCISION (GRADE 1.5)

#### ACUTE ABSCESS IN A CHILD

The great danger of a GA is that the patient will inhale pus. Ketamine is relatively safe because the cough reflex is less suppressed. Use it IV, and keep the head down.

Have a tracheostomy set (29.15) and suction ready. Put the child supine with the head over the end of the table, so that the pharynx is as nearly upside down as possible.

If the abscess is pointing, you may be able to open it with sinus forceps alone. If you can get a really good view, you may be able to aspirate it with a needle. If this is impractical, open the abscess with a guarded knife (6-6A). Put your index finger into the mouth, and slide the knife along it. Drain it by Hilton's method (6.2), as for a peritonsillar abscess.

*CAUTION! Don't allow inhalation of pus: aspirate immediately you incise.*

**If severe bleeding follows, and you cannot control it**, apply local pressure for 15mins. If that fails (rare), be prepared to tie the external carotid artery (29-7).

#### ACUTE ABSCESS IN AN ADULT

Anaesthetize the mucosa over the abscess with 4% lidocaine, preferably as an aerosol, and incise it with the head down and on one side, as in a child.

**TUBERCULOUS RETROPHARYNGEAL ABSCESS** is usually subacute and follows infection of the body of a vertebra. Only consider drainage if obstruction to the airway is a real danger. Drain the abscess through an external incision in front of the sternomastoid down to the prevertebral fascia. Displace the thyroid gland and trachea anteriorly, as in a cervical oesophagostomy (30-5).

## 6.9 Dental abscess

The classic presentation is with a painful, throbbing, swollen, red face (a 'fat face'), perhaps with fever, trismus and lymphadenitis; this is probably an acute dental or oral infection, most probably an alveolar abscess.

There may be:

**(a) An alveolar (peri-apical) abscess:** an infection which spreads to bone from a dead tooth after suppuration of the pulp of the tooth. There is severe pain and the tooth is tender to percussion, and may be slightly extruded from its socket. There is pyrexia and facial swelling develops (and trismus if the molars are involved). If drainage is delayed, the pus in the abscess discharges spontaneously through a sinus (31-9) in the gum or face, which may become chronic.

**(b) A periodontal abscess** at the side of a tooth, caused by spread from an infected gum. This may cause dramatic destruction of alveolar bone resulting in a loose tooth; *it is not usually tender to percussion.*

**(c) A pericoronal abscess** caused by infection of the gum over the crown of an unerupted and impacted tooth, usually a lower 3<sup>rd</sup> molar (an infected 'wisdom tooth'). Often, an abscess does not form, and the gum round the tooth is merely inflamed. *Extraction of the tooth does not promote drainage and may spread the infection.*

Pus from all 3 of these spaces, especially the first, can track in towards the cheek, the tongue, or the palate, or downwards into the neck. Pus can discharge inside or outside the mouth. It can collect:

- (1) On any of the surfaces of the gum ('gumboils').
- (2) In the buccal sulcus of either jaw on the oral or deeper side of the attachment of the buccinator muscle (common).
- (3) On the surface of the face superficial to the buccinator attachment.
- (4) On the palate (less common).
- (5) In the submasseteric space between the masseter and the ascending ramus of the mandible.
- (6) In the pterygomandibular space between the medial pterygoid and the ascending ramus of the mandible.
- (7) In the sublingual space above or below the mylohyoid muscle.
- (8) In the submandibular space superficial to the mylohyoid.
- (9) In the submental space in the midline under the jaw.
- (10) Anywhere down the side of the neck.

*Don't be daunted by the complexity of this anatomy.* Some of these spaces communicate with one another and more than one space may be involved.

Infection can spread in some particularly dangerous directions:

- (1) From the upper jaw (or upper lip or nose) to cause cavernous sinus thrombosis, perhaps fatal (6.6).
- (2) From the lateral pharyngeal space up towards the base of the skull, down to the glottis or into the mediastinum. Infection of this space is one of the most dangerous conditions in dentistry. There is difficulty swallowing and speaking.
- (3) From the lower jaw, via the sublingual and submandibular spaces, to the tissues of the neck, where it may cause oedema of the glottis, respiratory obstruction and death. This is Ludwig's angina (6.11).

### HISTORY AND EXAMINATION

A patient of any age >5yrs who has a swollen face, looking ill and distressed. He has usually had toothache in the past, and now he tells you that he has had pain for 1wk. He has fever, trismus, and a unilateral, tender, shiny, warm, indurated swelling. Looking at him will tell you which side of the face and which jaw is involved. Feel for warmth with the back of your index finger and test for fluctuation.

A tooth with large holes in it probably has an apical abscess under it. It may be firm, but is usually loose.

**If there are either obvious periodontal disease or several loose teeth**, suspect a periodontal abscess.

## INFECTION FROM THE TEETH

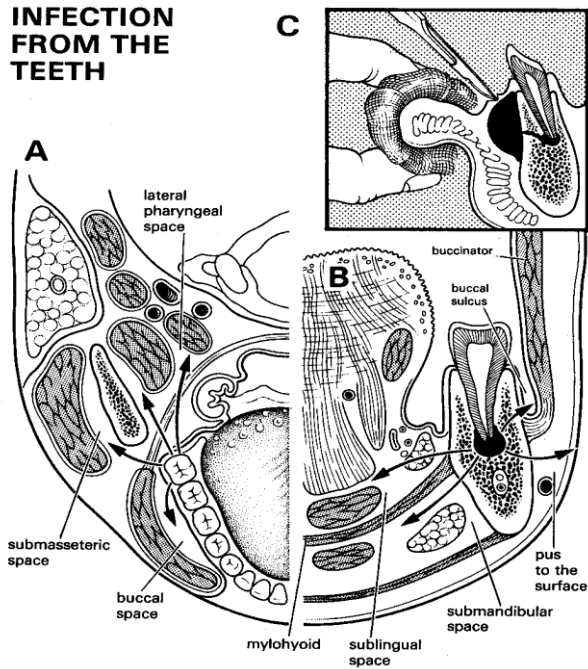


Fig. 6-7 THE DIRECTIONS IN WHICH PUS CAN SPREAD.

A,B, views of the same structures at 90° to one another. The attachments of the mylohyoid and buccinator muscles determine whether pus, originating in the lower jaw, points inside or outside the mouth. A, pus from the lower third molar spreading into the buccal space, the submasseteric space, and the lateral pharyngeal space. B, attachments of the mylohyoid and buccinator muscles. The attachments of these muscles determine whether pus spreads into the sublingual space, the submandibular space, the buccal sulcus, or on to the surface of the face. C, incision of an abscess in the buccal sulcus. Partly after Dudley HAF (ed) Hamilton Bailey's *Emergency Surgery*, Wright 10th ed 1977 Fig. 151 with kind permission.

### BEWARE OF CAVERNOUS SINUS THROMBOSIS AND LUDWIG'S ANGINA

If you are in doubt as to which of the teeth is the site of infection, tap them with some metal object or press them with your gloved index finger. A tooth which is much more painful than the others is probably the source of an alveolar infection. It may also be slightly raised in its socket. A tooth with a periodontal abscess is usually not tender to percussion, but often loose.

*N.B. It is quite difficult sometimes to localize the affected tooth; be gentle and patient to be certain which tooth is the offending one. It is a tragedy to remove the wrong tooth!*

**RADIOGRAPHS.** If possible, X-ray the offending tooth. You may see:

- (1) A radiolucent area at its apex when an apical abscess has been present for 2-3wks.
- (2) Caries between two adjacent teeth which may not be visible from the mouth.
- (3) The impacted tooth which is responsible for a pericoronal abscess.
- (4) Some other source for the infection, such as an infected cyst, or a fracture.

**DIFFERENTIAL DIAGNOSIS** includes acute inflammation of the salivary glands (6.10), mumps, Burkitt's lymphoma (17.6), lymph node swellings and

glandular fever, as well as snake bite, and trigeminal neuralgia.

**TREATMENT.** Make sure fluid intake is adequate because drinking may be difficult.

**CAUTION!** Don't apply poultices or any kind of local heat to the face: that may spread the infection. If an abscess is pointing inside the mouth, hot saline mouth washes may ease the pain.

Antibiotics are often unnecessary, because many dental infections can be treated by local drainage only. Use IV penicillin if there is surrounding cellulitis or actinomycosis (31.6). When you have drained an abscess, culture the pus and change the antibiotic if necessary.

**CAUTION!** Explain that a course of antibiotics is not sufficient treatment for the abscess, and that review is essential, even if the swelling improves.

### ANAESTHESIA

- (1) 2% or 4% lidocaine spray or a swab soaked in lidocaine solution.
- (2) Inject LA solution into the outer wall of the abscess over the proposed site of the incision.
- (3) Ethyl chloride local spray is suitable for an abscess which presents on the face or in the labial or buccal sulci. Isolate the infected area with gauze packs, and then spray on ethyl chloride until crusting occurs. Then open the abscess with a #11 blade.

**CAUTION!** Avoid GA, unless it is expert (especially if there is danger of respiratory obstruction), with intubation throat packing.

A dentist may be able to save the tooth by draining the abscess through it, and later filling its root. If you cannot refer to a dentist, remove the tooth. Many abscessed teeth are loose, and you can then easily pick them out of their sockets.

Removing the tooth to allow pus to drain through the socket may be sufficient. *Don't incise a non-fluctuant swelling.* If it is not yet fluctuant and ripe for incision, use hot saline mouth washes, as hot as can be borne without the risk of being scalded, several times a day. Treat with cloxacillin and metronidazole and wait till the cellulitis settles.

### CAUTION!

- (1) Don't pull out the tooth (31.3) before starting treatment for periodontal cellulitis.
- (2) If there is a tense inflammatory swelling of the upper part of the neck, suspect Ludwig's angina and treat urgently (6.11).

**PUS POINTING INSIDE THE MOUTH** can point in several places:

**If an abscess is pointing on the alveolus**, open it into the mouth.

**If it is pointing in the labial sulcus (6-7C)**, make a 1.5cm incision through the mucous membrane parallel to the alveolar ridge. Push a fine haemostat into it and open the jaws.

**If it is pointing in the palate**, make an antero-posterior incision, parallel to the nerves and vessels, remove an ellipse of tissue and let the pus flow out.

**If it is pointing in the floor of the mouth**, push flat forceps through the midline muscles.

**If there is pus in the pterygomandibular, lateral pharyngeal, or submasseteric spaces**, drain it through a vertical incision inside the mouth parallel to the ascending ramus of the mandible, taking care to avoid the parotid duct. This runs in the cheek under the middle 1/3 of a line between the tragus of the ear and the commissure of the lips, and opens in line with the first molar tooth. Push forceps to the lingual or buccal side of the ramus, wherever the pus seems to be pointing. If it is under the masseter, insert a drain deep to this muscle down to the mandible from outside the face. Insert the drain through an incision just below the inferior border of the mandible.

#### PUS POINTING OUTSIDE THE MOUTH

Drain it through one of the incisions below, as soon as you have started antibiotics for any cellulitis present. Removing the tooth to let the pus drain is not enough, even if it does drip from the root canal. If the abscess is fluctuant, it needs draining too.

**If you are not sure whether it is ready for drainage or not**, insert a wide bore needle under LA. If you aspirate pus, incise it by Hilton's method (6.2) where it points at the softest and most tender spot. To minimize scarring, make an incision below the inferior border of the mandible, where possible. Make an incision on the face in line with the creases in the skin. These may not always be over the most fluctuant part of the abscess.

#### INCISION FOR DENTAL ABSCESS (GRADE 1.3)

**CAUTION!** When you plan your incision, consult 6-8 and remember important features of the anatomy:

- (1) The extension of the lower pole of the parotid gland into the side of the neck.
- (2) The mandibular branches of the facial nerve. These run horizontally and cross the lower border of the mandible, just anterior to the masseter, deep to the platysma muscle in the anterior mandibular region and deep to the fascia posteriorly.
- (3) The facial artery and vein. These enter the face from between the submandibular salivary gland and the lower border of the mandible; they cross the ramus of the mandible 3cm from the angle of the jaw and then run obliquely across the lower third of the face superficially on the buccinator muscle. You may have to compromise between choosing the best site for dependent drainage and an inconspicuous scar in the crease lines of the face. Here are some likely sites:

**If there is a submental abscess**, drain it through a small midline transverse incision under the chin.

**If the abscess is under the body of the mandible**, drain it through a horizontal incision 1-2cm below the lower border of the mandible, taking care to avoid the mandibular branch of the facial nerve and the facial vessels. Push sinus forceps towards the lingual side of the mandible to drain the pus there.

**If the abscess points external to the buccinator**, drain it through a small incision over the swelling.

**DRAINS.** Suture a drain into the wound for 2-5days, or leave it open with its edges separated by gauze.

For a **PERIODONTAL ABSCESS**, refer to a dentist for a conservative operation, or pull out the tooth (31.3). For a **PERICORONAL INFECTION** (infected 'wisdom tooth'), see 31.4.

**POST-OPERATIVELY**, after you have incised any intraoral abscess, treat the patient with warm mouth washes to help the incision stay open as long as is necessary.

#### DIFFICULTIES

**If the mouth cannot open to let you get at the abscess** (trismus), irrigate the mouth with warm water for 15-20mins and try again.

## 6.10 Parotid abscess

Although a parotid abscess can occur without any obvious cause, it occurs most often in debilitated or HIV+ve patients, or after major surgery when mouth care has been neglected. The parotid is painful and is usually much swollen; the skin over it is tight and shiny. You may see pus coming from the parotid duct (inside the cheek level with the first molar tooth). Pus forms in several lobules of the gland between its septa, and does not form a single abscess. This, and the division of the facial nerve into its five branches within the parotid gland, make drainage difficult; it is however essential. *Don't wait for fluctuation.*

In Southeast Asia, melioidosis (due to *Burkholderia pseudomallei*) may be the cause, especially in children. This needs IV ceftazidime and can be difficult to eradicate.

#### INCISION (GRADE 1.4)

Start incising anterior to the pinna. Keeping close to it, proceed towards the mastoid and then continue in the angle between the pinna and the neck until you reach a skin crease, then cut along this for up to 10cm. Raise a flap of skin and subcutaneous tissue, so as to expose the parotid gland. Make multiple incisions into this in line with the branches of the facial nerve. Explore each incision by Hilton's method and clean out each abscess cavity with gauze. Close the wound with continuous or interrupted sutures of 3/0 monofilament, leaving a dependent Penrose drain emerging from the inferior part of the incision.

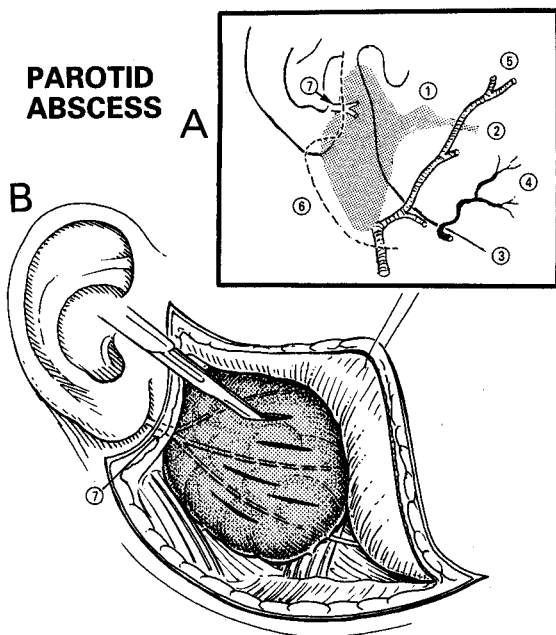


Fig. 6-8 DRAINING A PAROTID ABSCESS.

A, anatomy of the parotid gland. The facial nerve (7) enters the substance of the parotid so that, if you only incise the skin and subcutaneous tissue superficial to the gland when you reflect the flap, you will not injure it. Note that it extends well down into the neck. Incise where the pinna meets the skin of the face and neck and continue on in a skin crease. B, turn back the flap and incise radially to avoid the branches of the facial nerve (7).

(1) parotid gland. (2) parotid duct. (3) border of the mandible. (4) facial artery crossing the mandible about 3cm anterior to its angle. (5) facial vein. (6) incision. (7) VII<sup>th</sup> cranial (facial) nerve.

DIFFERENTIAL DIAGNOSIS is mumps or parotid cysts (17.5). There is no pus at the orifice of the parotid duct, mumps is usually bilateral, and the skin over the swelling is less shiny. *Mumps parotitis does not require surgical drainage*, it resolves spontaneously. Simply aspirate HIV-related parotid cysts.

## 6.11 Pus in the neck: Ludwig's angina

You may see these acute suppurative infections in the neck:

(1) **Suppuration in a lymph node**, especially a deep cervical one, is common in children, and is much like suppuration in any other lymph node.

(2) **Suppuration arising from an infected tooth (Ludwig's angina)** occurs in children and adults: it is a severe bilateral brawny cellulitis of the sublingual and submandibular regions, and may extend as far as the clavicles. It usually starts as a dental abscess in the mandible, which results in fever and severe toxicity. If the infection is neglected, it may obstruct the respiration by causing oedema of the glottis, and by pushing the tongue up against the roof of the mouth. Anaerobes and spirochaetes may be responsible. Death from septicaemia is likely. Urgent intensive antibiotic treatment is mandatory, together with drainage to decompress the tissues at the floor of the mouth, even if no pus is aspirated.

If you see chronic suppuration in the neck, think of:

- (1) Tuberculous lymphadenitis (17.4),
- (2) Actinomycosis (31.6).

If breathing is not significantly obstructed, you may be wiser to wait for 24h for the antibiotics to act and the oedema to subside a little, before you drain the lesion.

If breathing is significantly obstructed, you may be forced to do a tracheostomy (29.15). This is difficult, because the tissues of the neck are firm and oedematous.

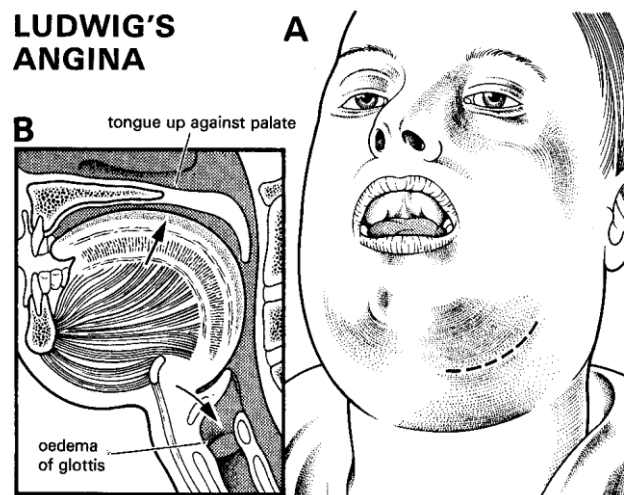


Fig. 6-9 LUDWIG'S ANGINA.

A, note the massive swelling of the chin. B, swollen tissues have compressed the tongue against the palate. The infection may spread to cause oedema of the glottis.

Partly after Dudley HAF (ed) *Hamilton Bailey's Emergency Surgery*, Wright 10th ed 1977 Figs.153,154 with kind permission.

## ANAESTHESIA

(1) Use LA, but it will be painful and distressing, so add a little ketamine, unless the airway is almost totally obstructed.

(2) *Don't administer an inhalation anaesthetic.* The voluntary muscles are needed to maintain the airway, and you will be unable to pass a tracheal tube without great difficulty.

## TREATMENT

This is an acute emergency: use high doses of penicillin, metronidazole and chloramphenicol IV.

## INCISION FOR LUDWIG'S ANGINA (GRADE 1.4)

Make a generous incision below the angle of the mandible, over the point of maximum tenderness, taking care to avoid the facial artery and in the line of a skin crease if possible. The abscess will be surrounded by inflammatory oedema. Cut through the skin and deep fascia, and explore it by Hilton's method (6.2). You may need to do some careful blunt dissection to release a little pus at the centre of the abscess. *Don't be alarmed if you don't actually find pus:* it will drain spontaneously. Leave the wound open. If there is much bleeding, wash the wound with hydrogen peroxide. Later, remove the offending tooth (if this is the cause, 31.3), and when infection has settled secondarily suture the incision wound.

## 6.12 Thyroid abscess

(Acute bacterial thyroiditis)

Abscesses of the thyroid are not uncommon in the developing world, especially in the HIV patient. Presentation is with a wide, very painful, oedematous swelling of the neck which is maximal over the thyroid. The pus is too deep for you to be able to detect fluctuation. Inflammatory oedema may be so marked as to cause Ludwig's angina (6.11).

**DIAGNOSIS.** Confirm the presence of pus by needle aspiration, if necessary under ultrasound guidance.

**ANAESTHESIA.** Use IV ketamine or a GA with intubation. LA is not satisfactory, unless the pus is pointing, but if your anaesthetist is not expert, you may have to use it. An alternative option in this case is repeated aspiration (preferably under ultrasound guidance). *The anaesthetist must be experienced to administer a GA.*

**INCISION (GRADE 1.5).** Use a scalpel to make a transverse incision  $\geq 5$ cm over the area of maximal swelling. Insert a haemostat and drain the pus by Hilton's method (6.2). Insert a drain and treat with an antibiotic (chloramphenicol or a cephalosporin) for 5 days.

*N.B. There may be perforation of the trachea, so be prepared to aspirate the airway vigorously!*

## 6.13 Breast abscess

The importance of a breast abscess is less for a mother than for the child, who may cease to be breastfed as a result of it, and develop marasmus. So your main objective must be to see that when you have treated the abscess, mother continues to breastfeed.

**Acute septic breast infections** usually occur during the 2<sup>nd</sup> week of the puerperium, in a breast which is either engorged or has a cracked nipple. Antibiotics alone are only effective if you use them early, during the phase of acute cellulitis. As soon as there is a definite lump or the presence of pus found by aspiration, incise the breast.

Avoid these common mistakes:

(1) *Don't delay incision, and don't continue with antibiotics alone after an abscess has formed.* The mass may fail to resolve, and become so hard (an 'antibioma') that you cannot distinguish it from carcinoma.

(2) *Don't wait for fluctuation, or for the abscess to point.* If you do, she will suffer much unnecessary breast destruction.

(3) Provided that the mother does not present so late that breastfeeding is impossible, *don't take the baby away from the breast unless pus is actually draining from the nipple.* A suckling baby is much the best tool to keep the breast from being engorged.

(4) *Don't suppress lactation with diethylstilbestrol;* its effects are temporary anyway.

(5) *Don't forget to insert a drain.*

**Subacute or chronic recurrent abscesses** are unrelated to lactation, and are less painful. Frequently they are a presenting sign of HIV disease, or the result of nipple-piercing. They are usually close to the areola, are often associated with inversion of the nipple, and they commonly involve both breasts, either simultaneously or one after the other. A mammary fistula may be present. Actinomycosis (31.6) or filariasis may be the cause. If the lesion is localized, excise it (6-10).

*Beware of the highly malignant condition MASTITIS CARCINOMATOSA, which occurs in pregnancy and mimics breast infection (24.4). The breast is inflamed and hard.*

**ANAESTHESIA.** Use GA or ketamine. You should use LA, which is not very satisfactory, only for very superficial small abscesses. Be sure to add premedication with pethidine.

### ABSCESSSES IN LACTATING BREASTS

#### INDICATIONS FOR INCISION

(1) An area of tense induration. You will feel this most easily when the breast is empty.

(2) Pain which is severe enough to prevent sleep.

Use the tip of your finger to feel for the point of maximum tenderness. Run your finger firmly across the oedematous swelling: you may feel that its centre is slightly softer than its edges. If you are in doubt, aspirate it with a needle (6.1).

**INCISION (GRADE 1.4).** If an abscess points at the areola, or near it, make a circumferential skin incision at its margin. Elsewhere in the breast, a circumferential incision is preferable to a radial one, which leaves an uglier scar. In order to get a finger to break down loculi, the incision will have to be at least 2cm wide.

*CAUTION! Don't wait for fluctuation.*

**If you are still in doubt,** try to get an ultrasound scan.

Cut through the skin and subcutaneous tissue. Push a long haemostat into the abscess, and open its jaws. Pus will ooze out. Feel every part of the breast against the haemostat, and try to enter all its loculi. Remove the haemostat, and use your gloved finger to break down any septa between the loculi. If it is in the subcutaneous tissue, feel for a deeper extension.

Insert a soft drain, suture it in place, and apply a dry dressing. Wash the cavity bd. You may pack a cavity initially if there is significant bleeding, but remove it after 24h.

**If there is a large abscess in a lower quadrant,** make a single incision in the lower part of the breast. *There is no need to make a main incision, and another counter incision inferiorly to provide free drainage.*

**If you cannot find any pus,** the lesion may be an anaplastic carcinoma or the highly aggressive inflammatory carcinoma of the young lactating woman; so send a biopsy for examination.

## BREAST ABSCESS & FISTULA

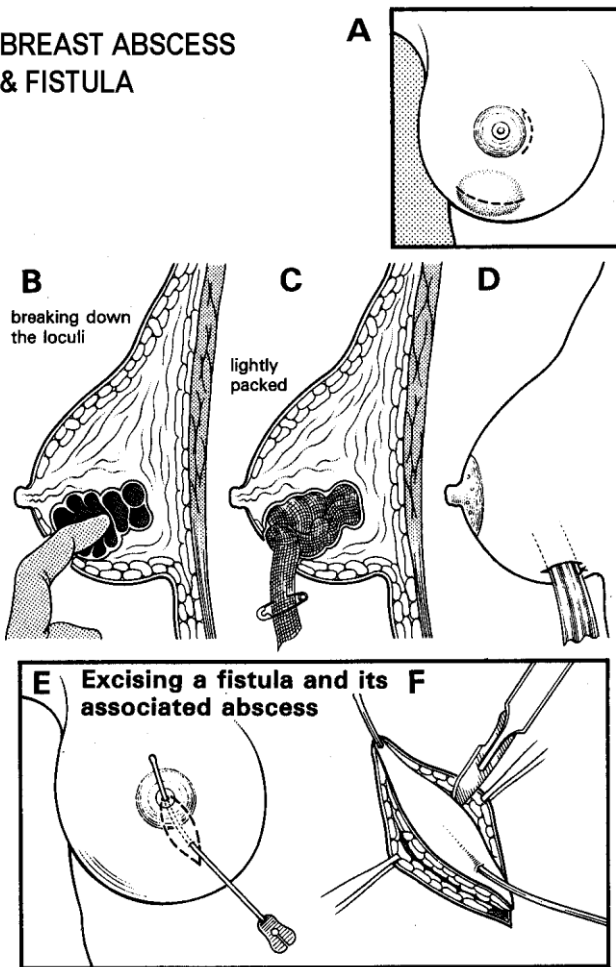


Fig. 6-10 BREAST ABSCESS AND FISTULA.

A, if an abscess points at the areola, or near it, make a circumferential skin incision at its margin. Elsewhere in the breast, a circumferential incision is preferable to a radial one, which leaves an uglier scar. B, insert your finger and break down all loculi. C, loosely pack the cavity. D, insert a dependent drain if the cavity extends below the incision. E,F, excise both ends of a mammary duct fistula, including 2cm of skin distal to the distal opening.

After Hughes LE in Rob C and Smith R, *Atlas of General Surgery*, Butterworth, 2<sup>nd</sup> ed 1981 p.121 Fig.25,26 with kind permission.

If milk flows from the wound, advise that it will stop, provided breastfeeding is re-established.

### CAUTION!

- (1) If there is no fever, or throbbing pain, consider the possibility of a carcinoma.
- (2) Do a careful follow-up. Another abscess may form.

**BREASTFEEDING must not stop!** Let the baby continue to suck from the normal breast and, as soon as possible, from the infected breast. But *don't let him suck from an infected breast if:*

- (1) Its nipple is cracked.
- (2) Pus comes from it.

If so, express the milk, by hand or with a breast pump. Discard it if it is obviously mixed with pus, otherwise pasteurize it. As soon as the baby can fix onto the nipple, encourage him to suck from it.

If presentation is late, when breastfeeding has become impossible, incise and drain the breast, and use an antibiotic to hasten the resolution of inflammatory oedema. Start expressing the breast as soon as possible, and *follow up until breastfeeding has been re-established.*

### SUBACUTE AND CHRONIC ABSCESSSES

Be sure to take a biopsy for tuberculosis and cancer, and examine pus for acid, alcohol-fast bacilli.

If there is a small opening discharging pus, at or near the areolar margin, or recurrent abscesses continue to reappear at the same site, near the areola, this is a MAMMARY FISTULA (or sinus). Examine the patient during a quiescent phase. See if you can pass a probe from the site of the abscess, through to the nipple. If you can, a fistula is present and you may be able to excise the whole lesion (6-10E,F). Make the incision round the fistulous track, and continue it 2cm distal to the fistula. There is no need to remove more than ½cm of skin on either side of the track. Deepen the incision to expose the underlying tissue, and excise the fistula. Be sure to excise the central part of the duct, because if you leave it behind, the lesion is sure to recur.

If there is necrotizing fasciitis of the breast, there is widespread tissue destruction. This is a sign of advanced HIV disease. The options are extensive debridement or mastectomy (24.5): blood loss may be extensive, so be prepared to transfuse!

### RE-ESTABLISH BREASTFEEDING QUICKLY IN AN INFECTED BREAST

## 6.14 Axillary abscess

Suppuration in the axilla can take several forms:

- (1) Pus can form superficially in the apocrine glands.
- (2) It can form more deeply in the lymph nodes under the *pectoralis major*. Open a deep abscess promptly, because pus can track along the nerve trunks into the neck.
- (3) It can arise in the scent glands (hidradenitis suppurativa) as a result of the use of deodorant 'roll-ons' which block the excretory ducts.

### TREATMENT

Abduct the arm.

If the abscess is superficial, incise over it.

### DRAINAGE (GRADE 1.4)

If the abscess is deep, make a 3-5cm incision just behind the fold of the *pectoralis major*, so as to avoid the axillary vessels. Push a haemostat upwards into the swelling, open its handles parallel to important structures, and open the abscess. Insert a drain, and suture it in place.

If the whole axilla is a bag of pus, incise low in the axilla.

If there is a large subacute or chronic abscess, consider the possibility of tuberculosis, especially if the surrounding tissues are indurated, sinuses are present, and the breast is swollen from lymphoedema, perhaps with the sign of *peau d'orange*.

If there are multiple recurrent small abscesses in the skin, the cause may be:

- (1) tuberculosis, so take a biopsy. Otherwise start a therapeutic trial with chemotherapy for tuberculosis;
- (2) fungi or actinomycosis (31.6);
- (3) hidradenitis suppurativa (34.9): avoid incision and drainage, and treat with cloxacillin and metronidazole or rifampicin. Regular swabbing with surgical spirit after showering helps to open up the excretory ducts.

*N.B. Chronic hidradenitis results in sinuses, keloid formation and contracture, and may need wide excision leaving a 2cm adjacent and deep margin of soft unaffected tissue.*

## 6.15 Retroperitoneal abscess

Retroperitoneal abscess is a common feature of HIV disease; it may become very large in size because it often remains undetected for a long time. It does not necessarily arise from the cortex of the kidney as does the perinephric abscess. The latter is mainly staphylococcal, but the former may have a wide variety of organisms, including *salmonella* and anaerobes.

The patient, who may be any age, presents with fever and a tender swollen area in the loin or subhepatic area.

If the abscess is small and related to the upper pole of the kidney, there may be no localizing signs.

ULTRASOUND (38.2h) is the best way of diagnosing and defining a retroperitoneal collection, and can distinguish this from a subphrenic collection. You can also gain information on the kidney in this way, and use ultrasound to localize where to insert a needle for diagnosis and a therapeutic drain.

RADIOGRAPHS. A plain radiograph may show obliteration of the *psaos* shadow, and scoliosis with a concavity towards the abscess. Look also for disease of the spine, especially narrowing of intervertebral discs and erosion of the bodies of the vertebrae nearby, especially anteriorly (osteomyelitis, an important differential diagnosis). *An IVU is not usually necessary*; it may show a normally functioning kidney which may be displaced, especially medially or posteriorly, or a hydro- or pyo-nephrosis, but ultrasound is the imaging of choice.

### DIFFERENTIAL DIAGNOSIS

- (1) Pyomyositis of the abdominal wall or paraspinal muscles.
- (2) Pyonephrosis.
- (3) Subphrenic abscess.
- (4) Osteomyelitis of the spine, with spread to the paraspinal tissues.

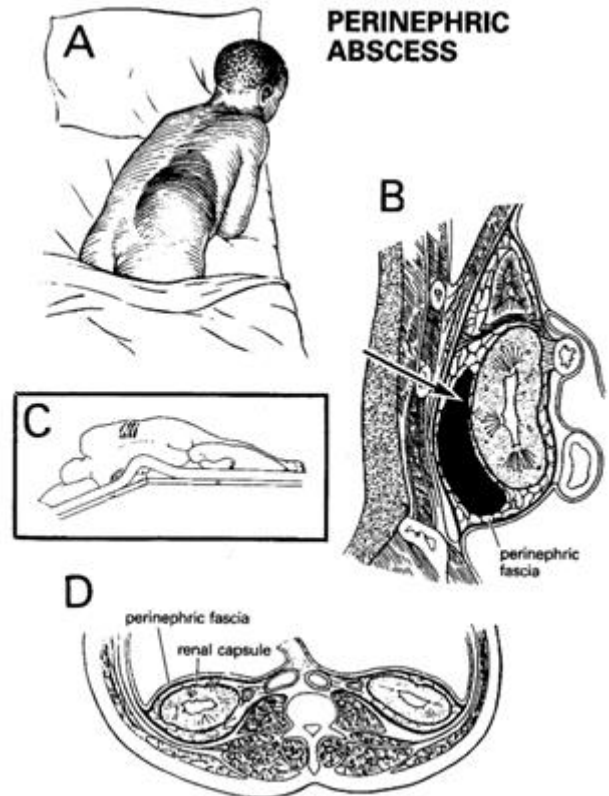


Fig. 6-11 PERINEPHRIC ABSCESS.

A, unusually large perinephric abscess. B, approach a perinephric abscess through the bed of the 12<sup>th</sup> rib. C, patient in the left lateral position. D, true renal capsule is closely applied to the surface of the kidney. Outside this, the perinephric fat is surrounded by the perinephric (Gerota's) fascia. After Flanigan RC in *Rob's Operative Surgery*. 1981 Figs.1b,3,12a with kind permission.

(5) Retroperitoneal sarcoma: this is rare, but if you incise into the tumour, you will lose the chance to excise it properly.

TREATMENT. The pus must be drained. You may not know for certain if it is perinephric, subphrenic (especially in the posterior or subhepatic spaces, 10-5B), or has spread from osteitis of the spine. Treat with chloramphenicol or a cephalosporin. If you can, insert a tube drain under LA with ultrasound guidance.

POSITION. Lateral, as for a nephrostomy (27.14).

### INCISION FOR RETROPERITONEAL ABSCESS (GRADE 3.2)

The retroperitoneal abscess of HIV may become so superficial that dissection is not necessary. Otherwise, make a 15cm lumbotomy incision slightly below the 12<sup>th</sup> rib just lateral to the *sacrospinalis* muscle (about the midpoint of the rib) extending down obliquely towards the posterior iliac spine. You can extend this laterally just above the line of the posterior iliac spine if necessary. *Take care to avoid the iliohypogastric nerve* at the lower end of the incision. Retract *latissimus dorsi*, *external* and *internal oblique* and *transversus abdominis* muscle origins, and cut through the deep fascia onto retroperitoneal fat behind the kidney.

If the pus is in the muscles (pyomyositis), you will discover this before you reach the rib (unless it is in the *psaos* or *quadratus lumborum*). If it is spreading from the spine or is subphrenic, you will also find it.

*N.B.* The lumbotomy incision is easier than the 12<sup>th</sup> rib bed incision, but gives poorer access to the kidney itself; it is, however, perfectly satisfactory for drainage of an abscess.

Drain the pus by Hilton's method (6.2). Insert a wide bore tube or corrugated drain and close the wound in layers.

## 6.16 Iliac abscess

When you see a child or young adult with a painful flexed hip, and c.7-day history of fever, anorexia, pain, and swelling in the inguinal area, think of iliac adenitis. The infection may have reached the iliac nodes from the leg, the perineal area (including the genitalia), or the buttocks. The abscess lies near the *psaos* muscle; this goes into spasm and sharply flexes the hip, so that extension beyond 90° and walking is impossible. There is a tense, tender, hard mass in the iliac fossa, which is lower, and closer to the anterior iliac spine, than an appendix mass. Fluctuation is rare, and only occasionally will you find the site of the primary infection.

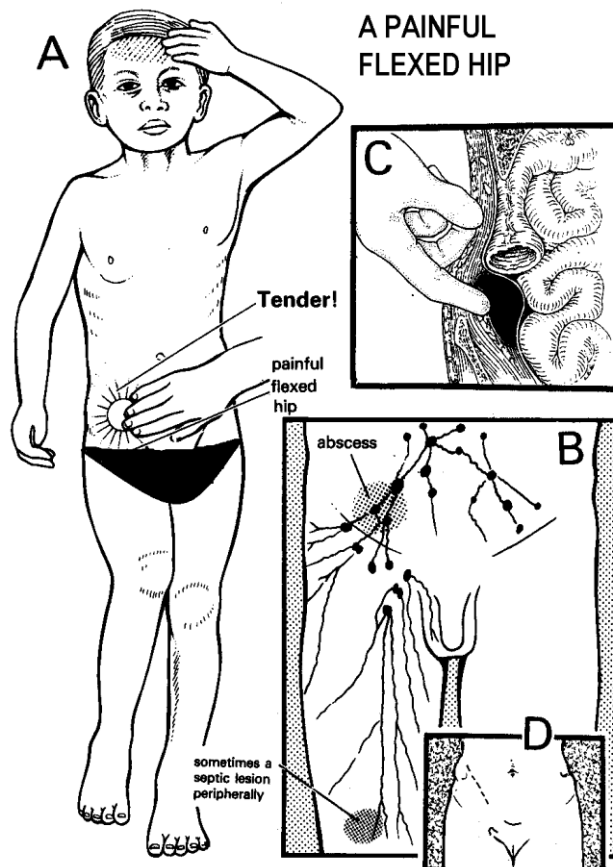
It is useful to distinguish 'periadenitis' without suppuration (common), which resolves on antibiotics and does not need drainage, from an iliac abscess (less common), which needs drainage and which can follow periadenitis, or pyomyositis of the *iliopsoas*, or be an extension from osteomyelitis of the spine. An appendix abscess is quite different, and is inside the peritoneum, whereas all these other conditions are retro-peritoneal. Consider brucellosis if you don't find any pus.

Iliac abscess is also known as iliac adenitis, deep inguinal adenitis, extraperitoneal iliac abscess, or suppurating deep iliac nodes. It has several important differential diagnoses, and is often misdiagnosed.

**DIFFERENTIAL DIAGNOSIS** is that of the 'sick child with the painful flexed hip'. It is more difficult if the right hip is flexed, because the diagnosis on this side includes appendicitis.

**Suggesting inguinal (groin) abscess:** a septic lesion in the skin or groin lymph nodes which may be minimal or extensive, and may complicate TB or malignancy. You should look for the origin of the sepsis on the foot, leg, perineum, or abdominal wall. If there is pus, drain it following recommendations as for an axillary abscess (6.14).

**Suggesting pyomyositis of the *iliopsoas*:** the same signs as iliac adenitis. The differential diagnosis may be impossible, and is not important because the treatment is the same.



**Fig. 6-12 A PAINFUL FLEXED HIP** in an ill patient has a variety of differential diagnoses. A, typically the hip is more flexed than is shown here. B, iliac abscess forms in the iliac nodes. C, exploring extraperitoneally for iliac suppuration. D, incision for an iliac abscess. C,D, after Dudley HAF (ed), *Hamilton Bailey's Emergency Surgery*, Wright 10th ed 1977 p.287 Fig 26.1 with kind permission.

**Suggesting an appendix abscess:** a different anatomical site: intraperitoneally in the right iliac fossa, with nausea and vomiting, less spasm, and only mild flexion of the hip (14.1).

**Suggesting septic arthritis of the hip:** severe joint spasm, acute pain on percussing the greater trochanter, no palpable mass, no movement of the hip owing to severe pain, and a radiograph showing a widened joint space. This is equivalent to osteomyelitis because the epiphyseal plate is inside the capsule of the hip joint (7.18).

**Suggesting tuberculosis of the hip:** a chronic history and radiograph signs of tuberculosis (5.7). Other possibilities include Perthes' disease (32.14), a slipped epiphysis, and a fracture.

**Suggesting a tuberculous *psaos* abscess arising from the spine:** a chronic history, radiographic changes in the spine. A *psaos* abscess does not usually need drainage, unless it is very large and causing pain. It will resolve slowly on therapy for tuberculosis; incising it can lead to secondary infection.

**Suggesting acute and usually staphylococcal osteomyelitis of the spine** (uncommon): more pain, spasm of the *sacrospinalis*, radiographic signs in the spine. Drain the lesion as for osteomyelitis (7.2).

If the diagnosis is difficult, and you suspect an abscess, you can: (1) Make an examination under GA, with the abdominal muscles relaxed. Feel the exact site of the mass and its consistency and boundaries, and feel for fluctuation. (2) Aspirate the mass with a large-bore needle, medial to the anterior superior iliac spine.

**NON-OPERATIVE TREATMENT.** *Deep inguinal (iliac) adenitis with peradenitis and without pus formation does not require drainage.* The hip is flexed as when an abscess is present. You can feel deep tender glands above the inguinal ligament. Treat with penicillin or chloramphenicol. If infection is slow to resolve, use skin traction ( $\frac{1}{7}$ <sup>th</sup> of the body weight) to avoid contracture and raise the foot of the bed.

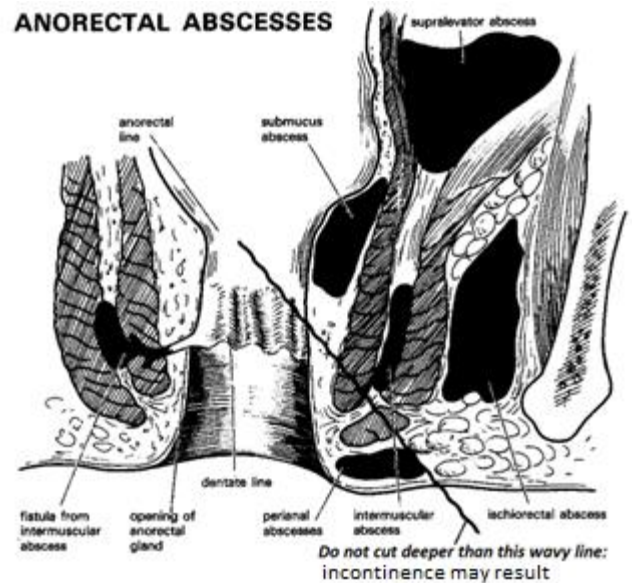
**DRAINAGE (GRADE 2.4).** If you have aspirated pus with a needle, you can safely open up the deeper layers. The abscess will have pushed the peritoneal lining of the right iliac fossa medially and superiorly. Make an incision 5-10cm or more over the swelling about 2cm above the inguinal ligament, starting just medial to the antero-superior iliac spine (6-12D). Take a long haemostat and push this through the muscle over the abscess until you find pus. Then, using your fingers, enlarge the opening. Take a specimen, drain the lesion, and continue antibiotics. If the leg remains in spasm, apply traction as above.

**CAUTION!** Draining an iliac abscess is potentially dangerous: you may injure the caecum or the iliac vessels. So follow the method above and aspirate first. Ultrasound guidance (38.2) will help.

## 6.17 Anorectal abscess

An anorectal abscess usually originates in an anal gland, and may communicate through a tiny opening with the anal canal, at the pectinate line. A connection between the skin and the anus (a fistula) is the reason why about half of these abscesses recur, or discharge persistently. Abscesses (with no opening to the skin), sinuses (with an opening to the skin, but not to the anus), and fistulae (with openings to both) are thus part of the same disease process (26.3). Most abscesses settle by discharging spontaneously, or being drained, but a serious life-threatening infection can sometimes spread in the soft tissues, or deeply into the pelvis.

Presentation is usually acute because the pain is intense: severe throbbing pain keeps the patient awake at night. On examination, you find a tense tender swelling near the anus. Sometimes, there may be little to see and no fluctuation to feel, except mild tenderness at the anal margin, or the whole perineum may feel tense and tender. If the pain suddenly resolves, the abscess has probably spontaneously ruptured. But there may now be a persistently discharging sinus or fistula opening on to the skin near the anus.



**Fig. 6-13 AN ANORECTAL ABSCESS forms in the anal glands. The pus can track in any of the directions shown. When an abscess bursts into the anal canal and on to the skin a fistula may form.**  
After Macleod JH. *A Method of Proctology*, Harper & Row 1979 Fig.7.9 with permission.

As anal glands are mostly posterior, most abscesses and most fistulae are posterior. These glands extend into the sphincters, so that pus can track in various directions:

- (1) downwards to cause a perianal abscess;
- (2) laterally, through the sphincters, to cause an ischioanal abscess. The ischioanal spaces connect with one another behind the anus, so that infection on one side can spread to the other side (horseshoe abscess);
- (3) rarely, medially under the mucosa of the anal canal to form a submucous abscess, or
- (4) upwards between the sphincter muscles to form a high intermuscular abscess, or further above the *levator ani* muscles to form a supralelevator abscess.

Here are the classical types of anorectal abscess, but you may see combinations, and the diagnosis can be difficult. Only the 1<sup>st</sup> two are common.

**(a) A perianal abscess** presents as a red tender swelling close to the anus. On rectal examination, there is little or no tenderness, induration, or bulging in the anal canal. There may be a fistulous track, going straight through or above the subcutaneous external sphincter, and usually through the lowest part of the internal sphincter.

**(b) An ischioanal abscess** lies deeper than a perianal one, is larger and further from the anus; it forms a deep tender brawny swelling and is not fluctuant until late. The patient is likely to be toxic, febrile, and debilitated. On rectal examination you may feel a tender induration bulging into the anal canal on the same side. The infection may spread posteriorly and then to the other side as a horseshoe abscess, so that there now are signs on both sides. The presentation may then be with urinary retention.

(c) A **submucous or high intermuscular abscess** (rare) presents with pain in the rectum and no external swelling, unless it is complicated by an ischiorectal or perianal abscess. On rectal examination you may be able to feel a soft, diffuse, tender swelling extending upwards from the pectinate line. You will often need to administer a GA to do a rectal examination: confirm and treat the condition by draining the abscess.

(d) A **pelvirectal abscess** (rare) presents with fever, but no local anal or rectal signs. Later, it may extend downwards into the ischiorectal fossa. With your finger in the anus, you may be able to feel fluctuation above and lateral to the anorectal ring.

*Don't delay treatment in the hope that an anorectal abscess will cure itself: always incise it.* If the abscess is large, warn that it is going to take weeks to heal. De-roof it and let it granulate. *Don't try to curette it, and close it by primary suture.* A large incision will not necessarily give a better result; recurrence depends on whether or not there is a tiny communication between the abscess and the anal canal.

#### PERIANAL ABSCESS

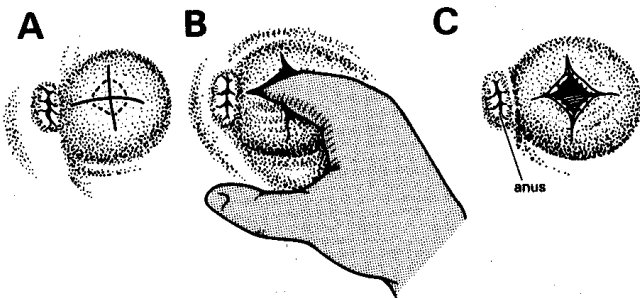


Fig. 6-14 DRAINAGE OF A PERIANAL ABSCESS. A, cruciate incision. B, insert your finger and break down loculi. C, wound with its edges trimmed, being left to granulate.

#### CAUTION!

- (1) **If there is an acute abscess**, *don't probe around looking for fistulae*: wait until the lesion has become chronic. *If you probe unwisely, you may create an iatrogenic extrasphincteric fistula* which will be very difficult to treat.
- (2) **In the chronic phase**, look carefully for the tracks in the skin and rectum that show its presence. Unless you demonstrate the presence and course of the fistula, you cannot hope to cure it.
- (3) **If an abscess lies anteriorly**, consider the possibility of a periurethral abscess in a man, or a Bartholin's abscess in a woman.
- (4) **If there are multiple abscesses**, these are likely to be the result of inadequately draining fistulae.

**INDICATIONS FOR INCISION.** Operate immediately you can feel a tender swelling. *Don't wait for fluctuation.* If pain has deprived sleep, open the abscess.

ZBIG (50yrs) complained of painful defecation and passing pus and blood rectally. He was found to have a perianal swelling, given a course of antibiotics, and sent home for readmission later for examination under anaesthesia. He returned after 3 days with severe pain, swollen crepitant buttocks, and a black gangrenous scrotum. The urine was tested and was found to contain sugar. He was referred, but died en route.

**LESSONS** (1) Bacteria in anorectal abscesses come from the gut and anaerobic infections can be dangerous. (2) Never treat an anorectal or perineal abscess with antibiotics without also draining it. (3) Spreading anaerobic infections originating in the gut need metronidazole and in this case at least chloramphenicol, and early debridement of all the dead tissue. (4) Always test the urine for sugar and check for HIV. Serious infections are particularly common in diabetics. Recognize Fournier's gangrene early!

**ANTIBIOTICS** will not treat an abscess and are useful only if there are signs of spreading infection. If so, treat with chloramphenicol and metronidazole, and look if there are signs of necrotizing fasciitis (6.23) which needs wide debridement. Occasionally use prophylactic antibiotics if the patient has a hip prosthesis *in situ* or has had rheumatic fever. Rarely, if there is severe neutropenia due to bone marrow failure, you should use antibiotics rather than performing an incision, as in this case *there will be no pus!*

#### ANAESTHESIA

For a large abscess, use GA or ketamine: *make sure you put the legs up in the lithotomy position before you give the ketamine, otherwise the legs may be too stiff to elevate!*

*N.B. LA is unsatisfactory, except for a small abscess.*

#### EXAMINATION UNDER ANAESTHESIA

Use the lithotomy position. Put a finger into the anus and feel its entire wall between two fingers (26-2F). Feel if there is an indurated upward extension of the abscess under the mucosa 3cm or more above the internal sphincter. Feel the extent of the abscess, and for the point of maximum fluctuation. Insert a bivalve speculum and look for pus coming out of an internal opening near the dentate line. Press on the abscess: you may see a bead of pus escape from the internal opening. You may feel the opening as a localized tender depression in the anal canal in the place suggested by Goodsall's rule (26-6I).

#### DRAINAGE (GRADE 1.4)

Support the mass with your finger in the rectum. Make a cruciate incision the length of the diameter of the abscess over its most prominent or fluctuant part. This will be externally for a perianal or ischiorectal abscess, and inside the rectum above the anorectal line for a rare submucous or pelvirectal abscess. Make the incision large enough to admit one or two fingers, so that you can explore the abscess fully with your finger and break down all loculi (6.2). *Don't break down any natural barriers to the spread of infection.* If possible, send a specimen of the pus for culture. Now look again, but *don't probe*, to see if there is a fistulous opening.

**If you do find a fistula**, which you will only find in about 10% of cases, determine where it is in relation to the pectinate line. Make sure there is no foreign body in the rectum.

**If the abscess is acute**, you will not find a track. *Don't probe around*, you may make a false track!

**If the abscess is chronic with a well-defined wall,** and the patient is well anaesthetized, probe carefully to look for a fistula.

**If there is no fistula,** cut off the corners of the flaps to prevent the edges of the wound coming together and adhering. A linear incision is *hardly ever* adequate. Wrap your finger in gauze and clean the walls of the abscess cavity.

**If there is a fistulous opening,** pass a seton (26.3). *Don't lay open the fistula even if it is a low type,* unless you are certain of the patient's HIV-negative status.

POST-OPERATIVELY, insert a soft drain, suture it in place, and make sure the patient showers bd. Insert a pad inside the underwear. Recommend laxatives if there is a tendency to constipation.

#### DIFFICULTIES WITH AN ANORECTAL ABSCESS

**If there is an abscess on both buttocks,** use circumferential incisions 3-5cm apart on both sides and loop a drain between them to keep the space open (6-15). There is sure to be a track across the midline behind the anus. *But be sure not to cut in the midline either anteriorly or posteriorly* because healing will be very slow and you may damage the sphincter.

**If there is pus draining from the anus,** the abscess has either drained internally, or there is an infected HIV-related anal ulcer (26.2), or other underlying disease (e.g. tumour, amoebiasis, schistosomiasis, gonorrhoea, tuberculosis, inflammatory bowel disease or trauma).

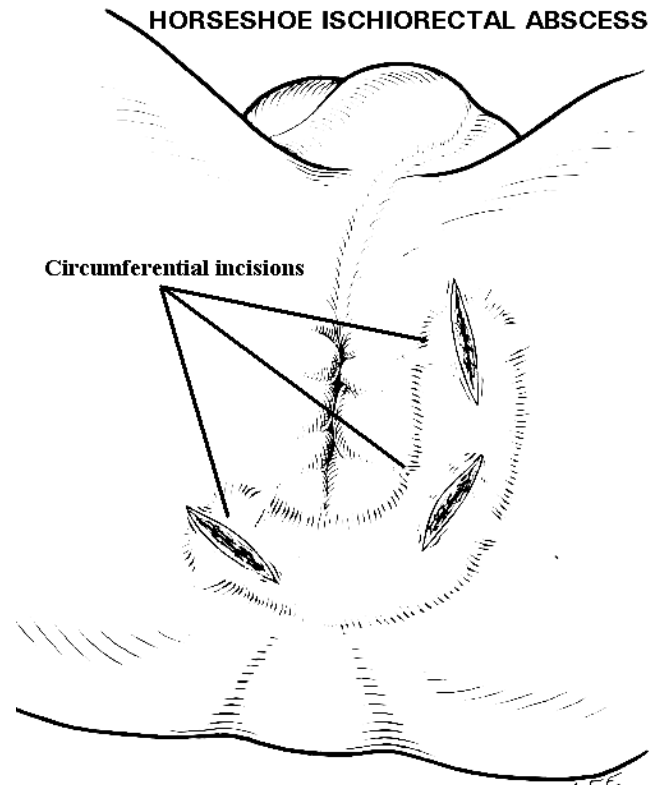
**If there is an internal opening** which communicates with the ischiorectal fossa above the anorectal ring (rare), *don't cut externally,* or incontinence will result! Drain the abscess internally. You may then possibly avoid the complications of a fistula.

**If the abscess extends submucosally** (rare: 6-13), make an opening internally. *Don't lay it open* as it will probably bleed copiously, and if there is untreated HIV disease, it may never heal.

**If there is a supralelevator abscess** (very rare), explore the abdomen and drain the abscess, preferably extraperitoneally.

**If there are signs of spreading infection,** such as gross inflammatory swelling, areas of necrosis, or crepitation, this is necrotizing fasciitis. Start urgent IV metronidazole plus chloramphenicol or a cephalosporin and perform a wide debridement.

**If there is a recurrent abscess** (common), there is almost certainly an underlying fistula. The opening may be very small, and you may have overlooked it when you drained the first abscess. Check the HIV status and glucose. Drain the abscess and attend to the fistula when the infection has settled.



**Fig. 6-15 DRAINAGE OF A HORSESHOE ISCHIORECTAL ABSCESS.**

**Incisions circumferential to the anal canal 3-5cm on both sides without crossing the midline: a loop drain between them keeps the space open.** Adapted from Dudley HAF (ed) *Hamilton Bailey's Emergency Surgery*, Wright 10th ed. 1977 p.384 Fig 39.5.

**If a fistula develops later,** pass a seton (26.3).

**If there is gross faecal incontinence,** fashion a defunctioning colostomy to allow the sepsis to settle, and later re-examine the remaining fistula(e).

## 6.18 Periurethral abscess

A periurethral abscess presents as a tender inflamed area in the perineum, or under the penis. The abscess commonly arises in the bulbar urethra, probably in Cowper's para-urethral glands, and is usually caused by *gonococci* to begin with, but these are soon replaced by secondary invaders. The danger is that urine may leak from the abscess cavity, extravasate widely, and cause extensive cellulitis or a fistula (27.11). The urine is infected, so this kind of cellulitis is more dangerous than that following traumatic rupture of the urethra. There may or may not be retention of urine due to an inflamed stricture, which will prevent you passing a catheter, so you may have to drain the bladder with a suprapubic cystotomy (27.8).

#### DIFFERENTIAL DIAGNOSES

- (1) A perianal abscess.
- (2) A scrotal abscess is in a different place and is not associated with urinary symptoms.
- (3) Localized penile extravasation of urine.

**ANTIBIOTICS.** Use ampicillin or chloramphenicol, until you have the results of culture of the urine and pus, if this is possible.

**DRAINAGE (GRADE 1.4).** Try passing a soft rubber urethral catheter (*even if there is no urinary retention*).

**If catheterization is successful,** drain the abscess by a midline perineal incision; be sure to open it widely, but *take care not to damage the urethra*.

**If catheterization fails,** as it probably will, and you cannot identify the urethra, perform a suprapubic cystostomy (27.8); then drain the abscess.

**If the stricture is short and the sepsis minimal,** gently pass a bougie until the stricture is reached. Open the abscess as before and feel for the bougie; display the urethra and perform an external urethrotomy by opening it longitudinally from the bougie distally across the stricture in order to pass the bougie into the bladder. *Don't cut into the roof of the urethra!* Replace the bougie by a urethral catheter. (*It will then be much easier to manage the stricture than if you leave it and try to dilate it later.*) **Don't extend your incision in the bulbar urethra** as massive haemorrhage may result, which will be very difficult to control. Insert a soft rubber drain and encourage showering bd. Manage the stricture by gently attempting to pass a bougie after 2-3wks.

#### DIFFICULTIES WITH A PERIURETHRAL ABSCESS

**If the urine extravasates,** treat with antibiotics and divert the urine (27.12).

**If the abscess recurs,** consider diabetes, HIV, tuberculosis or carcinoma of the urethra.

**If a fistula develops,** divert the urine (27.11).

## 6.19 Prostatic abscess

*Gonococci* or coliforms can infect the prostate. To begin with, they cause a prostatitis, and later a frank abscess. The patient presents with urgency, frequency, and dysuria, or with urinary retention. There is fever, rigors, and severe rectal or perineal pain, sometimes with tenesmus. The prostate is enlarged, usually more so on one side than the other, and is exquisitely tender. Untreated, the abscess may burst into:

- (1) the urethra,
- (2) the perirectal tissues, where it can present as an ischiorectal abscess,
- (3) the perineum,
- (4) the rectum, forming a rectourethral fistula.

#### DIFFERENTIAL DIAGNOSIS

Extreme prostatic tenderness should make the diagnosis clear. *Don't confuse a prostatic abscess with:*

(1) An ischiorectal abscess: the swelling is to one side of the midline.

(2) An abscess in a seminal vesicle: rectally, the site of maximum swelling and tenderness will be higher and more to one side.

**SPECIAL TESTS.** Test the urine for sugar, and culture it. Check the HIV status.

**ANTIBIOTICS.** Treat with ampicillin or chloramphenicol, until you know the results of culture.

#### MANAGEMENT

If the prostate is not fluctuant, see what antibiotics alone will do in 48h. Try to find an expert urologist, who can drain the abscess into the urethra with a resectoscope. Otherwise drain the abscess yourself, as follows. Fortunately, this is very rarely necessary.

#### DRAINAGE (GRADE 2.4)

The ideal, if antibiotics fail to cause a marked improvement in 48h, or the abscess is fluctuant, is endoscopic drainage by a urologist using a resectoscope. If this is not possible, use an exaggerated lithotomy position and administer a GA. Start by passing a rubber Jacques catheter. If this passes easily, leave it in place. If you cannot pass it, perform a suprapubic cystostomy.

To drain the abscess, pass a metal sound, and cut down on to this through a 5cm midline incision immediately in front of the anus.

Remove the sound and control bleeding. Put your finger through the incision into the prostatic urethra, and then through its posterior wall into the abscess cavity. If this contains several loculi, break down the septa between them.

Pack the wound loosely with a dry dressing and leave it open, or suture the skin edges loosely over it. Remove the catheter about the 7<sup>th</sup> day.

## 6.20 Abscess in the seminal vesicles

This is rare; the symptoms are the same as with an abscess of the prostate, but the warmth, the swelling and the tenderness, instead of being over the prostate, are higher and more to the side, over one, or occasionally both, of the seminal vesicles. There may also be pain suprapubically, in the back, or down the inner side of the thighs.

#### DRAINAGE (GRADE 2.4)

Use an exaggerated lithotomy position, and make an oblique lateral perineal incision. Dissect bluntly until you feel the swollen vesicle. Push a haemostat into it, drain it, and close the wound lightly round a drain.

## 6.21 Penoscrotal abscess

### (a) Penile infection (balanitis)

Infection of opposing surfaces of the prepuce and glans may be the result of inadequate hygiene, incomplete retraction of the foreskin, underlying ulceration with chancroid, syphilis or carcinoma, or unusual sexual practice.

#### SPECIAL TESTS

Test for diabetes and HIV. Biopsy a suspicious ulcer.

#### TREATMENT

If proper cleaning with chlorhexidine (or similar) fails, either because of the severity of the infection or because there is phimosis or underlying ulceration, use an antibiotic such as cloxacillin, and arrange circumcision when the inflammation has settled.

**If there is phimosis and urinary retention**, perform a circumcision (27.29). A dorsal slit is not really adequate.

**If gangrenous patches develop**, this is phagedaena and the patient becomes septicaemic. Use IV chloramphenicol and cloxacillin, and under ketamine, debride necrotic tissues widely. This will involve removing the foreskin, and may mean removing skin from the penile shaft also. If sepsis is extensive, insert a urethral catheter in order to show you where the urethra is and avoid damaging it during debridement.

### (b) Scrotal abscess

**If pain and swelling develop with explosive rapidity in the scrotum and the base of the penis, with hypotension**, this is acute necrotizing infection known as

### (c) Fournier's gangrene (6.23).

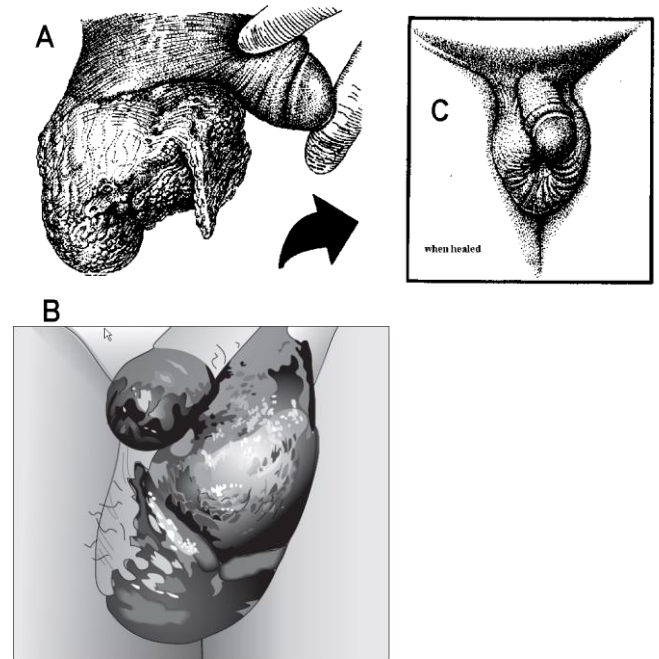
SPECIAL TESTS. Test for diabetes and HIV.

This occurs with HIV disease or in diabetics spontaneously but may follow surgery to the scrotum or penis, or extravasation of urine, especially if infected. It is caused by a synergistic combination of organisms, including anaerobes. (*Clostridium welchii* is sometimes responsible, and may form gas in the scrotum.) It spreads rapidly, because the necrosis affects all the fascial layers, *dartos* and *tunica vaginalis* together, and eats away much of the scrotum, penis or abdominal wall, and ends in Gram-ve septicaemia and death.

#### TREATMENT; DEBRIDEMENT (GRADE 2.2)

Treat with IV gentamicin, or a cephalosporin, and metronidazole. Resuscitate with IV Ringer's lactate or saline. Apply wet dressings and arrange debridement immediately. (Hydrogen peroxide is effective, but quite painful.) The sloughs will probably separate rapidly to expose the testes.

## FOURNIER'S GANGRENE



**Fig. 6-16 FOURNIER'S GANGRENE OF THE SCROTUM.**

**A, it is usually much worse than this. B, when it affects the penile shaft as well. C, healed without skin grafting, after radical debridement.** After Bowesman C. *Surgery and Clinical Pathology in the Tropics*, Livingstone 1960 with kind permission.

Excise all dead tissue as soon as possible, sacrificing some living tissue if necessary. The testes are spared, having their own blood supply, and it may be necessary to expose both testes and leave them dangling free. You may have to extend the debridement to the shaft of the penis and abdominal wall. *Unless you remove all dead tissue in severe cases, sepsis cannot be controlled and death is inevitable.* Examine the wound bd, and if you see further necrotic tissue, do another debridement.

When the infection has settled, attempt secondary suture of the remaining elastic scrotal skin over the testes, or if this is not possible, just allow the wound to granulate. If there is insufficient scrotal skin left, you may have to bury the testes in the medial part of the thighs.

### (d) Epididymo-orchitis and testicular abscess

If chronic infection of the epididymis persists, suppuration may result and spread to the testis itself. Alternatively septic micro-emboli travel directly to the testis resulting in septic necrosis. This occurs with HIV disease. The infection is inside the scrotum rather than in the scrotal wall; the scrotal skin is normal until the sepsis points through. There is deep pain, which may be felt in the abdomen.

#### TREATMENT

Antibiotics (usually doxycycline) may already have been given. Explore the scrotum through a transverse incision; if the testis and/or epididymis are severely infected, perform an orchidectomy (27.26) and close the wound round a drain.

## 6.22 Cellulitis

Infection in the fatty tissues under the skin is extremely common, but is dangerous because it can spread easily, and there is no demarcation as with pus in an abscess. Cellulitis can occur anywhere and is especially dangerous in the face and orbit (6.6) or neck (Ludwig's angina, 6.11) but usually arises in a limb, commonly the lower leg, which is swollen, warm and tender; later it becomes red or shiny, frankly oedematous and increasingly painful. Erysipelas is similar, affecting the subcuticular lymphatics, resulting in pustular eruptions on the skin. There is a high fever, which can develop quickly into bacteraemia with rigors.

The cause is usually a small abrasion, puncture wound (especially by a thorn, metal-piercing, or conventional surgery), blister, ulcer, burn, or infected bursa but in diabetics and HIV disease, it can arise spontaneously. Cellulitis used to be caused almost exclusively by *streptococcus*, but now at least 50% of cases are from *staphylococcus*, and in HIV patients, may harbour Gram-ve organisms. *De novo* cellulitis, in the absence of diabetes, is a frequent presentation of HIV, which should be tested for. *Actinomycosis* produces a chronic cellulitis discharging yellowish granules in suitably anoxic conditions. In Southeast Asia, check for melioidosis (6.10).

### SPECIAL TESTS

Test the blood or urine for sugar, and screen for HIV.

### DIFFERENTIAL DIAGNOSIS

You may have difficulty differentiating cellulitis from a **deep vein thrombosis** (DVT): this is usually less shiny, not warm, and not so tender but the diagnosis of DVT is notoriously hard: you really need a Doppler to be sure as Homan's sign is useless.

There may even be cellulitis together with a DVT, which occurs especially in those >40yrs, after pelvic or prolonged surgery, with patients using an oral contraceptive, and those having had prolonged air or bus travel.

In **necrotizing fasciitis** (6.23), the skin is not shiny but dull and purplish.

### TREATMENT

Start IV cloxacillin 1g stat, then 500mg qds preferably; if penicillin is ineffective, valuable time may be lost trying it out. However, the most important thing is to *elevate* the limb so that (for the leg) the *big toe is level with the nose* and (for the arm) the hand is strung up inside a sling on a drip stand, and insist on bed rest. Once the temperature has come down, give antibiotics orally, and when the swelling has reduced (the skin often becomes wrinkly as the oedema disappears) you need no longer continue elevating the limb.

### DIFFICULTIES WITH CELLULITIS

**If sepsis persists**, do blood cultures and change to a different antibiotic, check that the patient has not been walking around, and look for any abscess formation or necrosis. *Make sure any foreign body has been removed.*

**If swelling worsens with purplish discolouration and skin peeling**, there is developed fasciitis (6.23) and this needs urgent widespread debridement.

**If there is chest pain or dyspnoea**, think of DVT: if this is more likely, start anticoagulants.

**In children**, cellulitis is often secondary to acute osteomyelitis (7.3), which needs drilling.

**In the diabetic foot** (8.17), sepsis often spreads rapidly and even more so with HIV disease, resulting in osteomyelitis and gangrene; radical debridement with amputation of suspect toes is necessary. Frequently you will have to perform a below- or above-knee amputation to clear the sepsis.

## 6.23 Necrotizing fasciitis

Mixed infection in the superficial and deep fascial tissues with aerobes and anaerobes can cause extremely rapid dissolution of collagen in connective tissue, gross oedema and so interruption of blood supply to the overlying skin, and fat, which necrose. Advance of infection however may be sudden, alarming and relentless, and its extent is greater than at first seems apparent, particularly if there is *mucormycosis* (fungal infestation), which can occur in extensive natural disasters such as volcanic eruptions (34.13).

It can occur anywhere: in the abdomen it is known as Meleney's gangrene, maybe as a result of contamination from a colostomy, or a septic umbilicus (33.5), or in the scrotum as Fournier's gangrene (6.21), maybe as a result of extravasation of septic urine. It may arise after any type of perineal sepsis, including FGM. However, it is often spontaneous, especially in HIV disease and diabetics. The limbs, neck, chest wall and breast may all be affected; in the mouth it leads to gross facial destruction (cancrum oris, 31.5).

There is marked swelling and tenderness with areas of blistering, patchy central necrosis and crepitus; the patient is much sicker than with cellulitis, and pain extends beyond the confines of visible inflammation. The skin is not shiny, but dull and purplish. The necrotic fascia is greyish in colour and has lost its sheen but there is also a telltale milky exudate separating the sick fascia from the fat. Septicaemia soon overtakes, and he becomes very toxic, dehydrated and anaemic.

With certain infections, however, and typically *mycobacterium ulcerans*, the necrosis is slower to develop and limited to subcutaneous fat and results in a well-defined tropical ulcer (34.9), with an undermined edge due to skin survival through development of collateral circulation.

### SPECIAL TESTS

Test for diabetes and HIV. Cross-match blood if necrosis is extensive.

### DEBRIDEMENT (GRADE 2.3)

Start IV gentamicin or chloramphenicol and metronidazole. Resuscitate with IV saline rapidly to correct dehydration which is almost universal. Add fluconazole if you suspect *mucormycosis*.

*Do this in the septic theatre.* Excise all the affected fascia; this is inevitably more widespread than the overlying skin, and debridement *must* be radical. If you leave dead tissue behind, the patient will die. (*Necrosis involving the breast may mean doing a mastectomy!*) You may not know how far the necrosis has spread, but you must continue till no more grey fascia is found! You may lose a considerable amount of blood, so transfuse especially if he is anaemic to start with. Irrigate the wound with hydrogen peroxide.

You will be surprised how drastically the condition improves if you have done an adequate debridement (and how miserably it deteriorates if you haven't). Extend the debridement if you find more necrosis. Inspect the wound bed, and skin graft the defect when it is clean. You can speed up this process dramatically by using suction dressings (11.13).

MAZHOU (36yrs) was brought to a small mission hospital *in extremis*. He had uraemic frost, he was hardly conscious with shallow breathing, and had necrotizing fasciitis extending from the base of the scrotum to the costal margins. Whilst intravenous saline was poured in, under oxygen alone all the necrotic fascia was cut away: it hardly bled, and gave off ammonia fumes! Towards the end of the procedure he started moving and needed nitrous oxide to finish the operation. The next day he was conscious and hungry. He then explained that the scrotal swelling began after someone forcibly removed a urethral catheter that had been inserted when he'd been admitted with cerebral malaria. He was faithfully married with 3 children, and later tested HIV-ve. The urethral stricture was later successfully dilated, and the extensive abdominal wound grafted.

LESSONS (1) Extensive surgery is possible *in extremis* with no or hardly any anaesthesia. (2) Radical debridement gives results. (3) A small blunder gave rise to a huge problem. (4) Urethral catheterization is invasive and potentially hazardous. (5) Not everyone who is moribund is HIV+ve.

## 6.24 Gas gangrene

This is an anaerobic infection of injured muscle caused by various species of *clostridia*. Suspect that it may occur if:

- (1) There are extensively lacerated muscles, or a missile wound, especially if this involves the buttocks, thighs, or axillae, or the retroperitoneal muscles following an injury to the colon.
- (2) The blood supply to these parts of the body has been interfered with.
- (3) The wound is grossly or deeply contaminated with soil.
- (4) There is prolonged dead conceptus in the uterus.

Gas gangrene is probably developing *if there has been satisfactory progress and then sudden deterioration*. Over 2-3h the patient becomes anxious, frightened, or euphoric. The face becomes pale or livid, often with circumoral pallor. The injured limb feels uncomfortable and heavy. Although there may be recovery from shock and no bleeding, the pulse rises. It quickly becomes feeble as the blood pressure falls. There may be vomiting. The wound may have a sickly-sweet smell of apples.

*Don't let these features mislead you:*

- (1) *There may not always be the smell of death*, and even if there is, there may not be gas gangrene.
- (2) *Gas in the tissues is a late sign*, and even if it is present, it does not always mean gas gangrene.

One of the muscles may be involved, or more often a group of them, or a whole limb, or part of it. Infection spreads up and down a muscle, and has less tendency to spread from one muscle to another. As infection progresses along a muscle, it changes from brick red to purplish black (6-17). At first the wound is relatively dry; later, you can express from its edges a thin exudate with droplets of fat and gas bubbles, which becomes increasingly offensive. Stain this and look for Gram+ve rods.

*N.B.* Try to prevent gas gangrene:

- (1) Always perform a thorough wound toilet, especially in all extensive muscle wounds of the buttock, thigh, axilla or retroperitoneal tissues. Use plenty of clean water, and remove dead tissues and foreign material. *Never close these wounds primarily.*
- (2) Administer prophylactic antibiotics such as cloxacillin, gentamicin or chloramphenicol. Start immediately after the injury for a maximum of 24h. There is probably no absolute need for prophylactic antitoxin serum, which is probably hard to obtain, if you have performed a thorough wound debridement.

Once gas gangrene has developed, *don't delay exploring the wound because there is hypotension*. Radical excision and massive doses of penicillin are the only hope. You will be wise to excise too much muscle rather than too little.

### GAS GANGRENE: AREAS AT PARTICULAR RISK

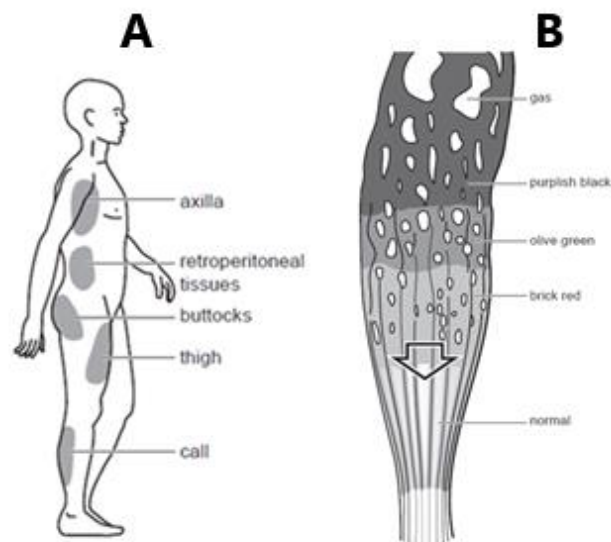


Fig. 6-17 MUSCLE CHANGES IN GAS GANGRENE.

A, areas which are at risk. B, as the infection advances down muscle, its colour changes from its normal purple, through brick red and olive green, to purplish black.

**ANY MUSCLE WOUND IS A POTENTIAL SITE FOR GAS GANGRENE**

**DIFFERENTIAL DIAGNOSIS.** Gas gangrene is *not the only cause of gas in the tissues*. Air sometimes escapes into the tissues from under the skin. In ischaemic gangrene (35.2), there is *no toxæmia*, unless the gangrenous tissue becomes secondarily infected. The diagnosis is usually clear. There are however 2 other conditions where the diagnosis is not so obvious. Both require drainage and penicillin or doxycycline but neither needs radical muscle excision.

**Suggesting necrotizing fasciitis (6.23):** Infection is limited to the subcutaneous tissues, but the patient is toxic and may be uraemic. Spread may be rapid and there may be much subcutaneous gas. Sometimes the whole abdominal wall is involved. When you remove the affected tissue, the muscle underneath appears healthy, and bleeds and contracts normally. Remove *all* the necrotic tissue, and drain the wound.

**Suggesting anaerobic streptococcal myositis:** Spreading redness and swelling originating in a stinking discharging wound with Gram+ve cocci and pus cells in its exudate. The muscles are boggy and pale at first, then bright red and later pale and friable. The characteristic toxæmia of gas gangrene does not develop. Make radical incisions through the deep fascia to relieve tension and provide drainage.

#### TREATMENT FOR GAS GANGRENE

**NURSING.** Isolate the patient from the other surgical patients. If possible, barrier nurse him.

**ANTIBIOTICS.** Treat with 10MU benzylpenicillin IV qds for 5 days. Or, use ciprofloxacin 400mg IV bd.

Culture the wound, do sensitivity tests, and if necessary change the antibiotics. Although *clostridia* are not sensitive to metronidazole, some other anaerobic bacteria are and may coexist in the wound, so use it.

*There is no need to use ANTITOXIN.*

**RESUSCITATION.** Infuse IV saline rapidly, and keep this running during the operation. You may need to transfuse blood if there is severe anaemia.

**EXPLORATION (GRADE 1.3).** *Do this in a septic theatre.* Open the wound, enlarge it if necessary, lengthwise in the limb, and cut the deep fascia throughout the whole length of the skin incision. Excise all infected muscle widely. Remove:

- (1) Any black crumbling muscle.
- (2) Any muscle which is swollen and pale and looks as if it has been boiled.
- (3) Any muscle which does not contract when you pinch it.
- (4) Muscle which does not bleed.
- (5) Muscle which contains bubbles of gas.

If necessary, remove whole muscles from their origin to insertion, part of a large muscle, or a whole group of muscles. Remove any suspect muscle: if you leave any dead muscle behind, he will die. Excise also any dead tissue. Irrigate the wound with hydrogen peroxide.

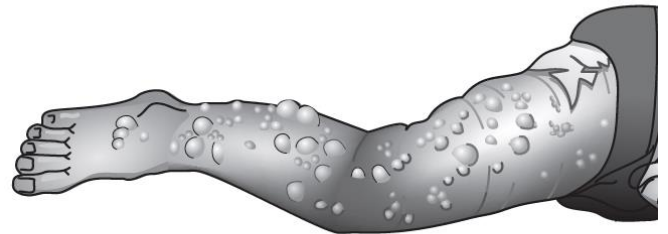
Close the wound later by secondary suture, with a skin graft or flap.

**AMPUTATION.** If the limb is disorganized by injury or infection, amputate it (35.3), especially if there are signs of severe toxæmia. Take a radiograph of it first to see how far the gas has reached. Amputate under a tourniquet. When you have amputated, the toxæmia should improve rapidly.

**CAUTION!** Close the stump by delayed primary suture, even if you think you are amputating through healthy tissue.

**POST-OPERATIVE CARE.** Septic shock and/or fat embolism may develop if it has not already done so. Expect, and treat as best you can, the dehydration, vomiting, delirium, jaundice, and anuria that may develop.

#### GAS GANGRENE



**Fig. 6-18 SEVERE GAS GANGRENE.**

**This followed an intramuscular injection, but it could equally well have followed a severely contaminated wound.**

*Adapted from a photograph, Fry.D. with kind permission of Tropical Doctor.*