

# 7 Pus in the muscles, bones & joints

## 7.1 Pyomyositis

Pyomyositis describes abscesses forming inside striated muscle. It is common between 5-35yrs, especially with HIV disease and in those debilitated by poverty, diabetes, steroid therapy or cirrhosis. One or more muscles become exquisitely painful, tender, and swollen, and the skin overlying smooth and shining. A single muscle may be involved, or a group of them, or several in different parts of the body. The larger muscles, such as those of the thighs, buttocks, shoulders, back, and abdominal wall, are more often involved than the smaller ones, though this ratio seems to be reversed in HIV disease. Infection makes them hard and indurated, so that movement is painful. Later, the signs of inflammation may subside as the infected muscle is replaced by pus and becomes fluctuant. Infection of the muscle limits the movement of joints nearby. Serious complication with fever and rigors is common as bacteraemia ensues. Lymph node involvement is not conspicuous. Septicaemia associated with pyomyositis may be fatal and is often not diagnosed. The patient is very ill and drowsy, with a high fever and multiple tender areas over the muscles. He may have a history of a trivial skin laceration, a blister, or a small sore. The condition rapidly progresses, so that he becomes desperately ill with a swinging fever, weakness, prostration, dehydration and hypotension. Pyaemia associated with pyomyositis results in a sequence of abscesses in one muscle after another.

*Staphylococci* are responsible in 90% of cases but Gram-ve organisms may be found especially with HIV disease. Also, an abscess in muscle may arise secondary to hydatid disease (15.12), cysticercosis, actinomycosis, or a haematoma from any injury. If *streptococcus* is the cause, the prognosis is usually worse.

SITA (38yrs) presented with fever and a vague, mild pain in her left hip, which was made slightly worse by movement. No malaria parasites were found and no definite diagnosis was made. She was treated with gentamicin and cloxacillin and her fever improved. Ten days later she returned with a huge abscess in her left inguinal region. This was incised and she recovered completely. LESSON Pyomyositis may cause large abscesses in the deeper muscles with few localizing signs.

DIFFERENTIAL DIAGNOSIS includes osteomyelitis (7.2) and septic arthritis (7.16). The exact site of the tenderness and swelling will usually lead you to the correct diagnosis. There are several other possibilities which depend on the site of the abscess:

**In the upper abdomen**, pyonephrosis or a perinephric abscess (6.8), a liver abscess (15.10), a subphrenic abscess (10.2), or an acute abdomen (12.1).

**In the lower abdomen**, an appendix abscess (14.1), an iliac or psoas abscess (6.16), a strangulated groin hernia (18.6, 18.8), pelvic abscess (10.3) or PID (23.1).

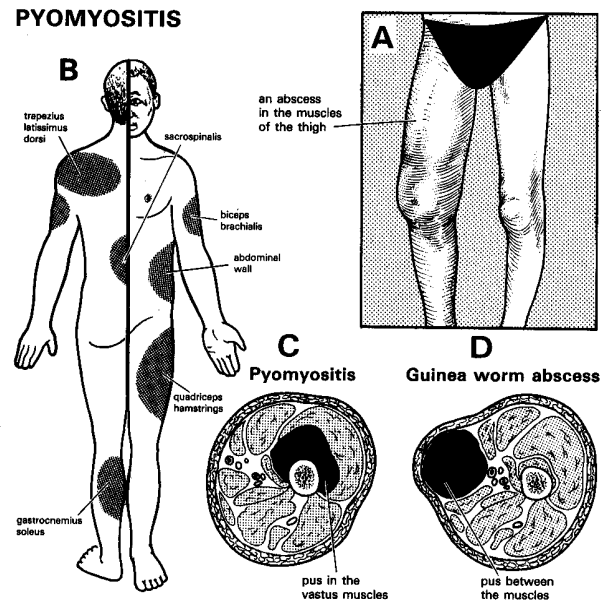


Fig. 7-1 PYOMYOSITIS.

A, shows an abscess in one of the muscles of the thigh. B, the common sites. C, D, the distinction between pus in the muscles (as in pyomyositis), and pus between them, as in an abscess round a dead Guinea worm (34.8).

After Adeloye A, *Davey's Companion to Surgery in Africa*, Churchill Livingstone Edinburgh 2<sup>nd</sup> ed 1987 p143-4 Figs. 12.1,4 with kind permission.

**In the thigh**, acute osteomyelitis (7.3), guinea worm infection (34.8), a haematoma, or a sarcoma (34.15).

**In the calf**, deep vein thrombosis, cellulitis (6.22) or a sickle cell crisis with bone infarction.

**DRAINAGE (GRADE 1.4)**. If you are not sure whether pus is present or not, aspirate it with a large bore needle. If you are not sure where to point your needle, use an ultrasound to guide you if possible. Make a small incision to begin with, if possible in the most dependent position, and open the abscess by Hilton's method (6-3). If it is large, extend the incision, so that you can insert your finger, break down any loculi and explore the whole cavity. *Don't use a curette*. You may find >1L pus: make sure your incision drains it adequately.

**If the bone feels rough and craggy at the bottom of the abscess cavity**, it may be involved; if so, this is osteomyelitis, *not* pyomyositis. Chronic osteomyelitis (7.5) may develop later.

**If there are signs of spreading infection** (cellulitis), treat with IV cloxacillin as well as draining the abscess(es) and taking a culture of the pus.

**If there is hypotension** with septicaemia, correct hydration with large volumes of saline or Ringer's lactate, and if there is severe anaemia, transfuse blood whilst you drain the abscesses. Use IV cloxacillin and chloramphenicol (2.7,8). Change these if different sensitivities are reported. *Don't forget to drain the abscesses nonetheless*. If there is already coma from septicaemia, *don't add to the problems by using an anaesthetic!*

**If there is a succession of abscesses** (pyaemia), drain them as they appear, culture the pus, and treat with an appropriate antibiotic as soon as you know the results of culture. Treat with cloxacillin or chloramphenicol meanwhile. Check the HIV status.

#### DIFFICULTIES WITH PYOMYOSITIS

**If blood pours from the abscess**, pack the cavity tightly with gauze for 24h. *Don't curette an abscess*. It may be an infected false aneurysm (35.9); make sure you have vascular clamps ready when you re-explore.

**If there are very many or very severe lesions**, you may have to make >10 incisions, with repeated staged visits to the theatre, to evacuate pus and remove dead muscle.

**If there is overlying black necrotic skin**, removing it may reveal a huge quantity of avascular greyish-pink, mushy suppurating muscle extending deeply underneath. Remove this, taking care: (1) *not to injure vital structures*, (2) *not to lose more blood than is inevitable*. Survival may depend on aggressive (but not too aggressive) surgery, intensive antibiotic treatment, and IV fluid replacement. If you have had to remove much muscle, there will inevitably be resulting weakness, deformity, and loss of function, but you will have saved the patient's life! If you are afraid of too much blood and muscle loss, do an amputation (35.3).

**If there are fever and rigors after drainage**, there is septicaemia, from either new abscesses or inadequate drainage.

**If abscesses are near joints and liable to develop contractures** (32.1), apply skin traction or a cast, as appropriate.

## 7.2 The pathology of osteomyelitis

Osteomyelitis is a particularly tragic preventable disease which often disables for life if it is treated late or inadequately. You can treat osteomyelitis satisfactorily only if you treat it early. Later treatment is difficult, expensive, and time-consuming. There are several kinds.

### (a) Haematogenous osteomyelitis

The acute stage of haematogenous osteomyelitis is a systemic disease which may be life-threatening. It is associated with sickle cell disease (common in Brazil, Africa and India), and is an indicator of poverty, manifested by poor hygiene and a poor nutritional state. Typically it is an affliction of children between 4-14yrs and is more common in boys, probably because boys are more prone to trauma and boys are socially allowed to be dirtier. There is often a history of minor trauma, such as being kicked on the football field, and the most commonly affected bones are the tibia and the femur where the commonest sites of infection are the distal metaphyses of the femur and the proximal metaphyses of the tibia, where the blood flow is sluggish.

However, other sites of infection are also common: the proximal femur, the proximal humerus, the distal radius or ulna, the distal tibia, or the calcaneus. But any bone can be involved, and sometimes several of them at the same time, especially in neonates where the maxilla is often involved (7.14), and the origin of the sepsis may be umbilical, pneumonic or from gastroenteritis.

Metaphyses are endowed with a rich network of subperiosteal vessels and it appears that the primary lesion is a subperiosteal hematoma. People who walk barefoot and whose skin is exposed to all manner of scratches and thorn pricks and insect bites, people who suffer from pimples, eye and ear infections and who pick their noses, are prone to episodes of bacteraemia. Boluses of bacteria are quickly eliminated from the circulation but devitalized blood is an excellent culture medium and hence if bacteria settle in the subperiosteal hematoma, infection will ensue and a subperiosteal abscess will develop. Pus accumulates under pressure, breaks out and strips the periosteum off the shaft and deprives part of the bone of its blood supply, so that it dies and forms a sequestrum. Alternatively, pus erupts into the muscle and spreads along fascial planes, and so resembles pyomyositis (7.1).

Although acute haematogenous osteomyelitis can be caused by a whole array of micro-organisms, *staphylococci* are by far the most common bacteria implicated, and *salmonellae* are probably the second commonest microbes. *E. coli*, *Haemophilus influenza* and *Salmonella* are often found with sickle cell disease or other haemoglobinopathies.

With HIV disease, haematogenous osteomyelitis occurs in adults as well as children, often with *enterobacteria* but also with all manner of bacteria. There is little periosteal reaction, but osteopenia leading to bone destruction.

Before the age of 6 months, an epiphysis offers no barrier to the spread of infection, so that pus in a metaphysis rapidly spreads to a joint. After this age, the cartilage of an epiphyseal plate limits the spread of infection, so that a joint is infected only if an infected metaphysis extends inside a joint capsule, as in the hip or shoulder.

### (b) Acute traumatic osteomyelitis

Here the organisms reach bone directly from an open fracture, particularly if the wound is contaminated in road vehicle trauma, war, or a gunshot incident. The bone in such wounds is *always* at risk especially if there is inadequate wound toilet, or immediate instead of delayed wound closure.

Similarly, infection can reach bone through internal fixation of fractures, and so you must seriously weigh the advantages of such procedures against their risks.

### (c) Subacute localized pyogenic osteomyelitis

Here the infection develops insidiously from the metaphysis of a long bone, which cavitates and produces a surrounding reactive bone sclerosis, known as a Brodie's abscess (7-2A). Ultimately the marrow cavity is obliterated.

#### (d) Late HIV-related foreign-body osteomyelitis

Infection occurs in HIV+ve patients around metallic bone implants years after they have been inserted. This results in septicaemia systemically, and bone destruction locally. The larger the implant, the greater the problem. *Staphylococci* are usually responsible, but you may find many other organisms.

#### THE PATHOLOGY OF OSTEOMYELITIS

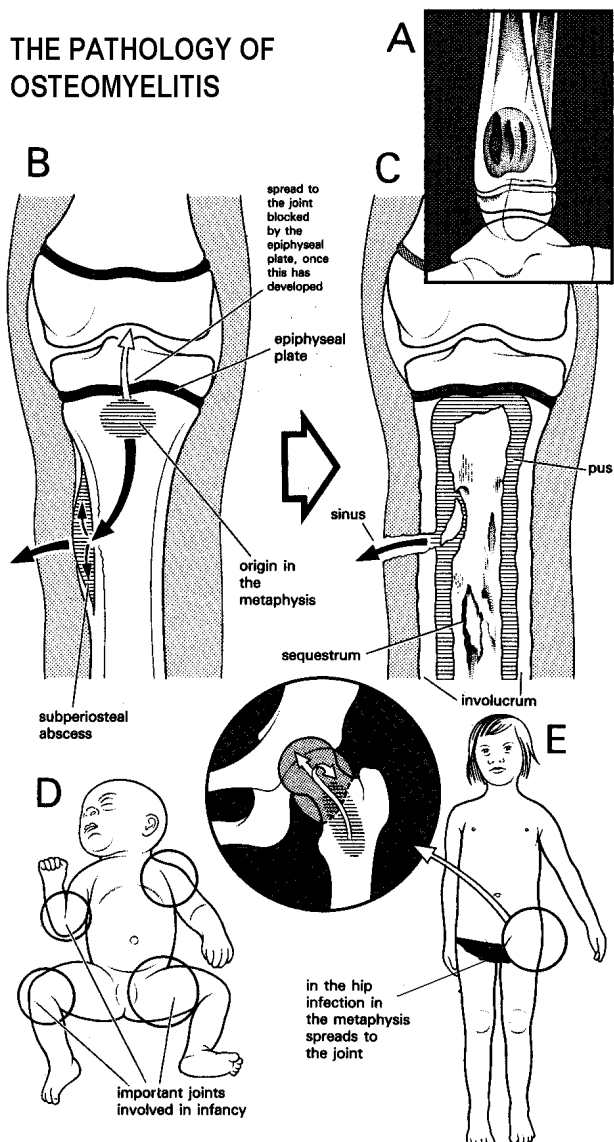


Fig. 7-2 PATHOLOGY OF OSTEOMYELITIS.

A, Brodie's abscess is an uncommon form of chronic osteomyelitis: the upper end of the tibia or the lower femur are the common sites. B, initial infection in osteomyelitis typically is in the metaphysis. After 6 months, the epiphyseal plates have developed sufficiently to prevent infection spreading to the joints, except in the hip. Before this age, infection spreads to the joints. C, chronic osteomyelitis with sequestra and a sinus. D, in a baby <6mths old, osteomyelitis is always associated with septic arthritis. E, osteomyelitis of the proximal femur is always associated with septic arthritis, regardless of the age of the patient, because the epiphyseal line is intracapsular.

#### (e) Chronic pyogenic osteomyelitis

The stripped periosteum of acute osteomyelitis responds by producing new bone. Where acute osteomyelitis is inadequately treated, the bone dies and is known as a sequestrum. It behaves then as a foreign body allowing infection to persist. The sequestrum becomes surrounded by new bone from the surviving periosteum and this new bone is known as the involucrum. The stability of the bone may depend on this involucrum. Persisting infection within the sequestrum may rupture through the involucrum, producing multiple sinuses.

#### (f) Other chronic bone infections

Certain other types of chronic bone infection however do occur, because of tuberculosis (32.3), actinomycosis, especially in the jaw (7.14), or mycetoma (34.11). In these there is a locally destructive process with little periosteal reaction, in contrast to the situation with syphilis and yaws.

### 7.3 Acute osteomyelitis

Acute haematogenous osteomyelitis is a surgical emergency. It is also the supreme example of the axiom, "Where there is pus, let it out." Your challenge is to let out the pus before it causes pressure necrosis of the bone, and to do so with the least possible delay. If you don't explore an infected bone early enough, or don't explore it at all, the patient may become severely disabled. Early operation is not difficult, but the sequestrectomy that may be necessary later will be very difficult.

Typically, a child from a poor family living under unhygienic conditions presents with fever and an *exquisitely painful tender bone near a joint* which he is unwilling to move. Or, the parent may bring him to you with fever, pain, and a limp. When you first see him, the tender area will probably not yet have started to swell. Soft tissue swelling is a late sign which shows that pus has already started to spread out of the bone.

Unfortunately, many children present late after they have already sought help elsewhere. Often, the history is atypical and may be misleading:

- (1) There may be no history of an acute illness; the first sign may be a boil-like lesion which discharges spontaneously or is incised, and which is followed by a chronically discharging sinus.
- (2) If an infant is very ill, he may have no fever and few general signs of infection.
- (3) There may be signs of a severe general infection, but few local signs.
- (4) There may be a history of a fall, suggesting a fracture. So think of osteomyelitis in any ill child who is not using one limb.

The only sure way to confirm or exclude osteomyelitis is to decompress the bone, urgently. Many doctors are only used to soft tissue surgery and don't like working on bone and look upon it as specialized orthopaedics. The main message of this chapter is that *you must decompress osteomyelitis early!*

Do your utmost to drain pus from an infected bone before it has stripped the periosteum off the shaft. After this has happened, the bone normally heals by forming a sequestrum and an involucrum, with all the disability that this causes. Early treatment needs early diagnosis, so everyone who provides primary medical care must be aware of osteomyelitis. Make sure that your staff in the clinics know about it, and immediately refer any child with fever and a painful limb. Because of the common practice of giving antibiotics and seeing if the patient improves, osteomyelitis is apt to be one of the worst-treated diseases in primary care. One reason why it is such an important disease in resource-poor settings is that patients are so often referred to hospital late, after they have been inadequately treated in peripheral units.

Any of the diseases in the list below can cause pain, fever, and inability to move a limb. Local redness and oedema are later signs. The important decision is not what the exact diagnosis is, but whether you should decompress bone or not. The site of the greatest tenderness (at the end of a metaphysis near a joint) is a useful point of differential diagnosis, and so is the young age of the patient. The tenderness is localized and is greatest on direct pressure and percussion.

MURARULAL (9yrs) was brought in by the mother with a one-day history of a limp. There was tenderness over the right fibula and he had a low-grade fever, but no other signs, and no radiographic changes. The diagnosis was uncertain, so the fibula was explored. It looked normal when it was exposed, but even so it was drilled. Pus came out under pressure. The wound was dressed and left open and he was given chloramphenicol. He rapidly improved and the wound healed spontaneously. A month later he had no limp and no discharge, but a radiograph showed periosteal elevation. A year later the radiograph was normal.

BUROO (8yrs) was admitted with a swelling over the upper end of her right tibia present for the last 4 days. A small abscess pointed. This was incised and drained. A week later a radiograph was taken and considered normal. After three months of antibiotic treatment, her wound was still discharging, and radiographs showed obvious chronic osteomyelitis.

LESSONS (1) If osteomyelitis is a possibility, drill the bone, especially the upper tibia. (2) Drill it even if it looks normal when you expose it. If Buroo's bone had been drilled early, she would have been spared many years of disability. (3) When you have found pus, leave the wound open.

## HIGH FEVER AND A TENDER BONE MEAN OSTEOMYELITIS

### DIAGNOSIS

The diagnosis is clinical, but you can easily confirm it by ultrasound scan: look for a subperiosteal fluid collection >7mm in size (38-13). The simplest and fastest method of confirming this subperiosteal abscess is aspiration, which, at the same time, will yield a specimen for you to send for culture.

*Ordinary radiographs may not show any abnormality, especially when the disease is early and treatable!* Blood tests, particularly the white blood cell count, are unhelpful, as are sedimentation rate and C-reactive protein, for they simply suggest the presence of inflammation.

**If a child has a high fever and is acutely tender over a bone**, this is osteomyelitis until you have proved otherwise. If the mother tells you that there was an injury up to 2wks before, this may indeed have been true in 50% of cases as increased blood supply to the area may have been the predisposing factor producing the infection. *Radiographs don't help in the early diagnosis of osteomyelitis*, but they will exclude a fracture.

**If the tenderness is in the soft tissues, rather than over a bone**, this is more likely to be cellulitis or pyomyositis than osteomyelitis.

**If the lower leg is swollen, oedematous, tender and warm, but the tenderness is not particularly localized over a bone**, should you explore it or not? Its exact site may help you to decide. If you are still in doubt, be safe and drill. You will probably operate on some cases of cellulitis unnecessarily, but if you don't operate, you will miss osteomyelitis.

**If the point of maximal tenderness is over a joint, not over the adjacent bone, and all its movements are exquisitely painful**, this is probably a primary septic arthritis. Aspirate the joint and, if necessary, drain it.

**If there is fever and an acutely painful hip which is extremely painful to move**, this is osteomyelitis of the neck of the femur with septic arthritis (they are in effect the same disease). Aspirate to confirm that pus is present (7.16). Drill the upper femur and its neck, and drain the hip (7.18).

**If the muscles are swollen and tender**, this is probably pyomyositis (7.1): feel the site of tenderness carefully.

**If sickle cell disease is common**, suspect bony infarction, which is common in this condition, may be causing the symptoms, especially in a child <2yrs, if:

- (1) several of the bones are involved
- (2) an unusual bone is involved, such as the skull, or the small bones of the hands or feet, particularly in an infant
- (3) there is respiratory distress.

So check for sickle cells in the blood, and for anaemia.

*N.B.* Osteomyelitis can complicate avascular necrosis; both diseases may be present. *There is no certain way of distinguishing a sickle cell crisis from osteomyelitis except by decompression.* If there is sickle cell disease, a wait of 24h is reasonable, because the pain of an infarct improves rapidly with IV morphine. Signs in an SS patient are usually obvious clinically, but are not in SC patients (quite common in West Africa). *Don't transfuse so that the Hb level exceeds 100g/L.*

**If lesions in the hands are causing diagnostic difficulties**, remember that:

- (1) Tuberculous dactylitis is much less painful than sickle cell dactylitis.
- (2) Syphilis will probably show abundant new bone formation elsewhere.

If the disease is some weeks old, but there are no signs of new bone formation on the radiograph, suspect that this is tuberculosis, with or without HIV disease. This is most likely to be a diagnostic problem in the spine. Tuberculosis usually forms no new bone, whereas chronic pyogenic osteomyelitis is more likely to. Patients with HIV disease make very little involucrum.

If there is much swelling, but not much fever, suspect that this may be a sarcoma, which can mimic subacute osteomyelitis and may cause fever. Radiographs should distinguish one from the other. Confirm it by biopsy.

If there is a subperiosteal swelling without fever, this may be due to scurvy or a bleeding disorder.

If there is fleeting pain in many joints, this is probably a rheumatic polyarthritis. Rheumatic fever and parvovirus infections are other acute and subacute causes.

If any other septic lesion, such as a carbuncle or middle ear disease, coexists, suspect this may be the source of the osteomyelitis.

If the diagnosis is still difficult, consider brucellosis, yaws, syphilis, and leprosy.

#### PRESENTATION

The presenting symptoms and signs are pain, inability (or refusal) to move the limb, fever and prostration. As long as the abscess is subperiosteal, there are hardly any local signs.

**EXAMINATION.** Elicit tenderness and hypersensitivity to vibration by holding a tuning fork against the bone, even distant from the affected area.

Look for a septic problem anywhere, but especially from a child's skin, chest or stool from which the infection may have spread. Culture any skin lesion, sputum and diarrhoea stool.

**BLOOD CULTURES.** If there is pyrexia, take a blood culture (if you can), and preferably 2 more at 2hrly intervals, before you start antibiotic treatment. If treatment has already started, cultures will probably be unhelpful.

**RADIOGRAPHS.** Don't expect any signs in an early case. You will only see bony changes >10 days in an older child, or >5 days in an infant. Examine the edge of the bone with care: the earliest sign is the faintest second line of new bone about 1mm away from the shaft. You will see this more easily if you look at the film obliquely. Nonetheless it is useful to have a radiograph as a baseline.

#### IF YOU SUSPECT OSTEOMYELITIS, DECOMPRESS THE BONE AND LET OUT THE PUS!

**NEEDLE ASPIRATION** using a 16G needle may be useful in localizing pus. Unfortunately, if pus is present under the periosteum the disease is already advanced. Good results are obtained by decompressing bone earlier than this. Aspiration is useful for diagnosing septic arthritis, but not for treatment.

## THE DIAGNOSIS OF OSTEOMYELITIS

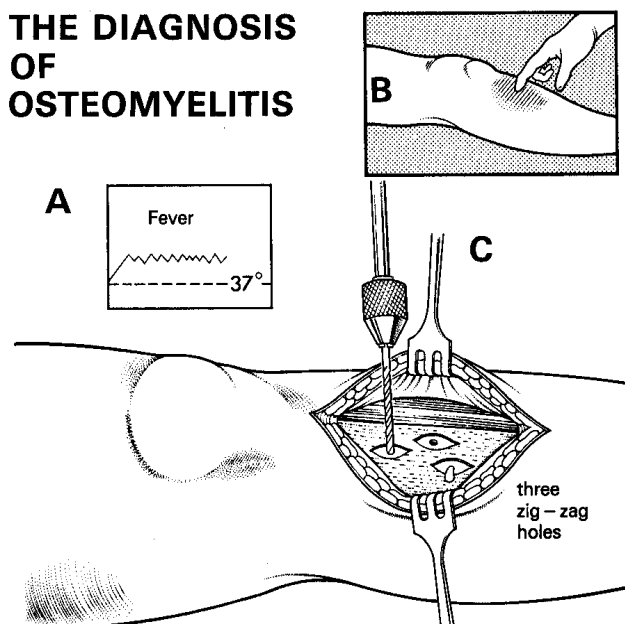


Fig. 7-3 DIAGNOSING OSTEOMYELITIS.

A,B, critical signs: fever and painful tender bone, especially close to an epiphysis. C, the only way to confirm or exclude osteomyelitis is to drill the bone. If a patient comes when pus is already discharging, it is too late for an easy cure.

#### CAUTION!

- (1) Explore the bone (7.4), whether or not you find pus.
- (2) Failure to aspirate pus does NOT exclude osteomyelitis!

**GENERAL CARE AND IMMOBILIZATION.** Correct dehydration. Ease pain with IV analgesics. Splint the limb in the position of function, or use skin traction for a leg.

**ANTIBIOTICS.** Start these immediately after you have taken a pus swab, and if possible a blood culture also. If you have been able to drain the lesion early and it is clinically quiescent, and there is no bone necrosis, continue for 2-3wks. Before you know the results of culture, or if culture is impossible, treat with IV chloramphenicol 10mg/kg qds, IV cloxacillin 10mg/kg qds, or azithromycin IV in sickle cell disease. Monitor the response by a drop in leucocytosis. Treatment has 3 objectives:

- (1) to treat and prevent pain,
- (2) to treat the septicemia and the associated inflammatory syndrome, and
- (3) to prevent the bone from dying.

You need to administer IV antibiotics and analgesia fast! Whilst the periosteum is relatively inelastic and cannot accommodate much inflammatory exudation, the bone is altogether incapable to adjust to the pressure rising in the Haversian system. Therefore, as the subperiosteal lesion expands, the periosteum will be stripped from the diaphysis, and as the pressure in the Haversian system eventually exceeds capillary pressure, the bone will become ischaemic and will die. Consequently, the 3<sup>rd</sup> objective of treatment is addressed by decompressing the subperiosteal abscess.

At a very early stage, antibiotics alone may abort the process, but in the regions where the condition is common, presentation is usually late, and decompression is necessary.

**If the bone looks normal**, drilling holes through the cortex of the diaphysis into the medullary cavity may in early cases decompress the Haversian system.

The unfortunate circumstance in poor-resource settings is that in the overwhelming majority of cases the bone, or parts of it, are dead at the time of presentation.

**If septicaemia persists**, grave complications will follow: pneumonia, endocarditis, pericarditis, and 'metastatic' abscesses. Fortunately most patients recover from septicaemia and if the bone has not died, the local inflammation will subside.

**If the bone has died**, as is usually the case, pain and local signs will continue to be present. After 10-14 days, a radiograph will show the extent of the dead bone: this will be relatively denser than the living bone, for the living bone will have begun to lose mineral density whereas the dead bone will not.

*N.B.* Damage to the growth plate in childhood may lead to stunted growth, and limb shortening or deformity.

## 7.4 Exploring a bone for pus

If you suspect that there is osteomyelitis, the critical procedure is to decompress the painful tender bone.

DECOMPRESSION FOR OSTEOMYELITIS (GRADE 1.4)

**TOURNIQUET.** A bloodless field will make the operation much easier (3.4). Elevate the limb first. *This is essential in sickle cell disease. Don't use an exsanguinating bandage, because this may spread the infection.*

**INCISION.** Expose the bone on either side of the point of greatest tenderness. Try to incise over a bony surface which is covered with muscle, rather than one which is covered only with skin. Make the incision long enough, and start it at the epiphysis. Incise the oedematous subcutaneous tissues.

**If you find pus in the muscles away from the bone,** *don't automatically think that there is pyomyositis.* Culture the pus. Make sure you wash the tissues with plenty of water, and create adequate drainage.

**If you don't find pus in the muscles,** continue your incision down to the periosteum. Incise it longitudinally, and if pus immediately floods up from under the periosteum, culture the pus and make sure there is adequate drainage.

**If you find no pus under the periosteum,** drill a minimum of 3 holes into the bone in a lazy zig-zag line, starting about 1cm from the epiphyseal line and at least 1cm apart.

Make a separate small incision in the periosteum for each drill hole. Drill at right angles to the bone, not obliquely, because drilling will be easier.

**If no pus or tissue fluid under pressure comes out,** there is probably no osteomyelitis, provided you really have drilled the tender area. If pus flows from the first hole, send a specimen for culture. Drill 1-2 more holes 1cm apart in a lazy zig-zag line down the shaft of the bone until only blood or tissue fluid flows out of the hole from healthy bone.

### CAUTION!

(1) *Don't elevate the periosteum,* because the bone under it will die.

(2) *Don't elevate too much muscle either,* because periosteum receives its blood supply from the muscles over it.

(3) *Don't incise the periosteum beyond the epiphyseal line,* or you may spread the infection to the epiphysis.

(4) *Don't remove any periosteum,* because the bone under the raw area will not regenerate.

(5) *Never drill a row of holes transversely across a bone,* because they weaken it.

(6) *N.B. A single drill hole may not drain an abscess sufficiently.*

(7) *Don't use suction drainage,* because this might suck excessive amounts of bone marrow straight out of the medullary cavity.

POST-OPERATIVELY, if there is any danger that the bone might break, apply a plaster gutter splint. In the lower femur or upper tibia, apply skin traction. If the limb is painful, elevate it.

**If at 2wks, the lesion is clinically quiescent,** and radiographs show no bone necrosis, stop antibiotics. Otherwise, continue for a maximum of 6wks. Follow up for 3 months; if the radiograph is normal, then you have succeeded. Unfortunately, even early decompression is not guaranteed to save the bone, though *you must try!*

**CAUTION!** If the bone is very osteoporotic, apply a cast before discharge to prevent a pathological fracture, especially if the leg is involved.

### DIFFICULTIES WITH ACUTE OSTEOMYELITIS

**If a child has radiographic changes on the first visit,** chronic osteomyelitis will follow. Proceed as above: pus in the tissues or under the periosteum will need draining.

**If the child is aged <6 months,** osteomyelitis arising in the metaphysis is inevitably complicated by septic arthritis. Drain the joint also. Bone necrosis is less likely, because the arteries are not end arteries.

### **DON'T REMOVE A LARGE SEQUESTRUM UNTIL THERE IS A STRONG INVOLUCRUM**

## 7.5 Chronic osteomyelitis

**If there is dead bone (sequestrum),** the condition is necessarily chronic. The sequestrum acts as a foreign body and maintains a chronic infection. However, here the general principle, that you must remove all dead tissue, needs delay in case the result destabilizes the limb.

If necrosis involves the entire width of the diaphysis as seen on a radiograph, in order to retain a limb that eventually can recover function, the sequestrum has to remain *in situ* so that it serves as a matrix for the newly forming bone (involucrum) that is made by the surviving periosteum. *Not only must the sequestrum be retained, it must be kept in position to avoid a pathological fracture.* You can achieve these objectives by applying a plaster cast or using an external fixator. You must leave holes in the plaster corresponding to any sinuses, so these may drain. *Contrary to common practice, antibiotics are not indicated at this stage.*

The timing of the removal of the sequestrum depends on the strength of the involucrum, but this itself may be weakened by removing the sequestrum!

*Don't remove a sequestrum until a patient has formed enough involucrum to make a new shaft for the entire bone.* Deciding when to operate is critical.

### UNTREATED OSTEOMYELITIS

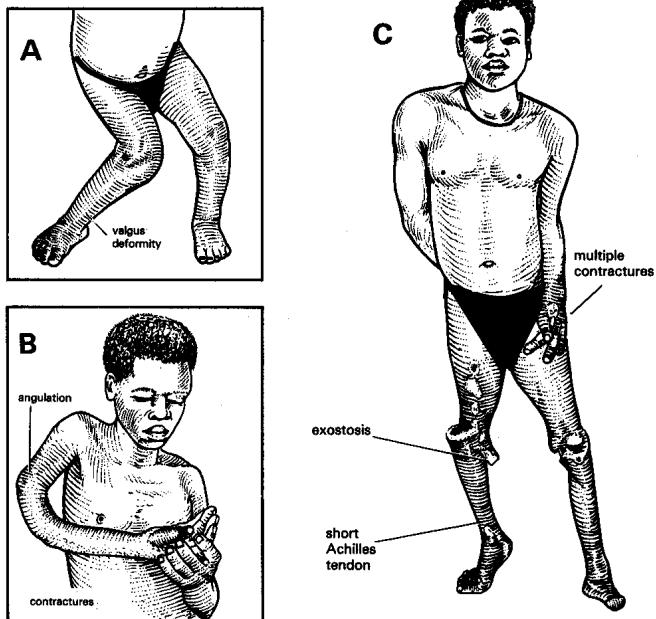


Fig. 7-4 UNTREATED OSTEOMYELITIS.

A, late osteomyelitis of the knee with a severe valgus deformity. B, destruction of the humerus causing angulation, combined with contractures of the elbow and wrist. C, osteomyelitis in several joints. This patient could run with simple boots after excising the exostosis, and lengthening both the Achilles tendons. So save a patient's limb if you possibly can: amputation (35.3) is usually avoidable unless there is HIV disease. Kindly contributed by Ronald Huckstep.

### INSTRUMENTS FOR BONES

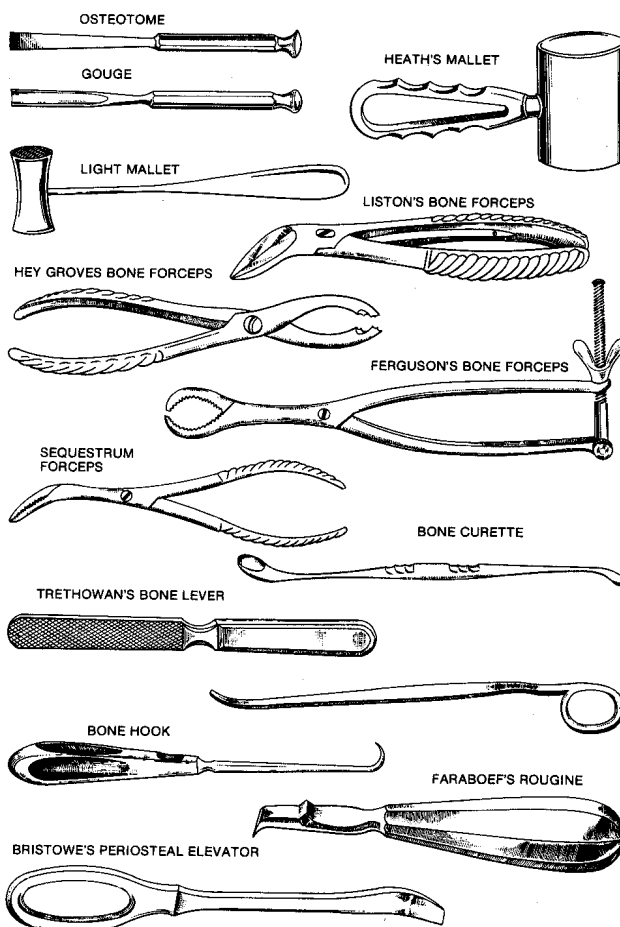


Fig. 7-5 INSTRUMENTS FOR CHRONIC OSTEOMYELITIS.

**OSTEOTOME**, Swedish model, solid forged stainless steel, (a) 6mm. (b) 10mm. Use these for cutting the bones of children. An adult's bones are too hard to be cut by an osteotome alone. Weaken them first with a line of drill holes.

**BONE NIBBLER**.

**GOUGES**, Swedish model, solid forged stainless steel, (a) 6mm, (b) 10mm. These curved bone chisels must be sharp. If necessary, get them sharpened on a grindstone. Use them for deepening a cavity in a bone.

**MALLET**, stainless steel, 350g. This is an adequate size of mallet, there is no need for a larger one.

**BONE FILE** or rasp.

**FORCEPS**, bone cutting, Liston, angled on flat, 200mm. These are general-purpose bone cutters. You can also use them instead of special rib cutters.

**FORCEPS**, bone-holding, Hey Groves, 210mm. This is for small bones, such as the radius.

**FORCEPS**, bone-holding, Lane's, 390mm. This is a heavier pair of forceps for larger bones such as the tibia.

**FORCEPS**, sequestrum, angled, 190mm. These are slender, angled forceps to remove sequestra.

**CURETTE**, or scoop, Volkman, double ended, size C. Use this to curette infected bone when you operate for osteomyelitis.

**LEVERS**, bone, Trethowan, 220mm. Put these round a bone to expose it.

**LEVERS**, bone heavy, 275mm.

**HOOK**, bone, 220mm.

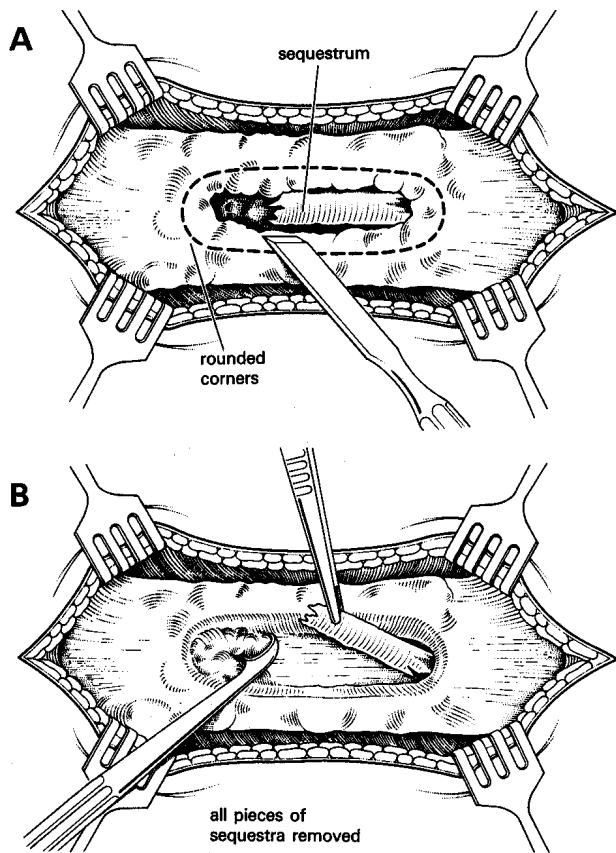
**ROUGINE**, Faraboeff, with curved end, chisel edge. Use this to scrape the periosteum from a bone.

**ELEVATOR**, periosteal, large.

Surgery for chronic osteomyelitis is difficult, bloody, and dangerous. If you have to operate, do so only to relieve persistent pain or remove persistent sinuses, not merely to improve the radiographs.

**If an area of bone is abnormally dense on the radiograph**, showing that it is dying or dead, it may be absorbed slowly if it is attached to existing healthy bone. But if it is lying free as a sequestrum, it will act as a foreign body and will not be absorbed, so you will have to remove it. Occasionally, you can remove a small sequestrum through a sinus, but you usually need to cut a window in the involucrum. Once you have removed a sequestrum, no new involucrum will form. This is an important exception to the general rule that a foreign body should be removed immediately, especially in the presence of infection.

## SEQUESTRECTOMY



**Fig. 7-6 SEQUESTRECTOMY.**  
A, sequestrum presenting through a cloaca (hole) in the bone. B, enlarge the cloaca and remove the sequestrum.  
Kindly contributed by John Stewart.

Antibiotics will not produce a cure, except perhaps if the infection (in Southeast Asia) is due to melioidosis (6.10). So, explore, curette, and if possible saucerize the cavity (*i.e.* obliterating the cavity by making the hole flat). This will relieve the pain dramatically. If possible, leave it open to the outside, and let it granulate from the bottom. If not, leave it open to the soft tissues.

When you have removed a sequestrum, there may be a defect in the soft tissues or skin; if the wound granulates, you can place a skin graft over it. Otherwise a complex flap may be necessary.

Encourage a strong involucrum to form by exercising the limb so that the newly growing bone of the involucrum is gently stressed, without being angulated or shortened. For example, in the femur use a trunk-to-groin (hip spica) or groin-to-knee cast, add crutches and allow cautious weight-bearing. Occasionally there is localized sclerotic osteitis without an involucrum (Brodie's abscess). *Always send tissue for histology to exclude TB or cancer.*

### SEQUESTRECTOMY (GRADE 2.5)

**INDICATIONS.** Consider removing any sequestrum which you cannot remove through a sinus. *Don't operate to remove a large sequestrum until:*

- (1) The involucrum extends across the defect that will follow.
- (2) The involucrum is made of rigid bone.
- (3) The limb is capable of being supported, either by the remaining healthy shaft, or by a sufficiently strong involucrum.

**CAUTION!** If you remove the sequestrum too early, the involucrum will stop making new bone, and will collapse, so that there is no hope of a sound limb.

**RADIOGRAPHS.** Examine AP and lateral films carefully to see where the sequestra are. If ordinary films don't show enough detail inside the bone, take more with greater penetration. *Don't operate just for radiographic appearances!*

### PREPARATION

**ANTIBIOTICS.** Culture the pus or liquid from a sinus, and start the appropriate antibiotic in high dose for 2-3 days before surgery.

**METHYLENE BLUE** may help to show up sequestra during an operation. Sterilize a 1% solution, and inject it into the sinus 24h beforehand. It will stain everything blue, except the sequestra, which will remain white.

**EQUIPMENT.** As for acute osteomyelitis (7.3), plus 6 and 10mm osteotomes and gouges; 10 and 15mm chisels; a 250g mallet, a Volkmann's scoop, a curved sequestrum forceps, and a bone nibbler. In the thigh you will need strong retractors, a strong assistant, and a good light. Use an ordinary electric drill (held in a sterile glove) with a rotation saw (which you can autoclave).

**TOURNIQUET.** Bleeding can be alarming, because infected tissues are very vascular, so always use a tourniquet (3.4), unless you are operating on the proximal femur or humerus, or there is sickle cell disease (7.4). The anatomy may be very distorted, and without a tourniquet, important structures will be very difficult to recognize. Tie any vessels you see as you operate. Have blood cross-matched, and infuse IV fluid.

**INCISION.** The choice of incision will depend on the anatomy of the sequestrum, the involucrum and the neurovascular structures of the limb. (Incise the tibia antero-medially, and the femur laterally.) Start by probing any sinuses to see where they extend. They often join up. Where possible, make one of the standard incisions described. These are given for the entire length of the bone. Use ketamine for GA.

You will usually only need part of an incision. Very often it will include the draining sinuses. If possible, make the incision over one of the larger gaps in the involucrum. The tissues will be tough, so use a sharp scalpel.

Open the indurated periosteum in the length of the incision, and elevate it on each side. You will have to make a hole by chisel or drill and rongeur in the involucrum so that you can extract the sequestrum. Either: enlarge an existing gap in the involucrum with a gouge. Or: drill holes so as to outline a window (7-6). Then open it with an osteotome.

**CAUTION!**

(1) Scar tissue may have disturbed the normal position of the nerves and arteries.

(2) *Don't break the bone.* If you have carefully outlined the window with drill holes, this will be less likely.

Use a hammer and gouges or chisels to cut bits of bone from the involucrum until you get to the marrow cavity. Look for sequestra inside it.

**Sequestra** move separately from the surrounding involucrum. If they have been covered by tissues, they are ivory white and have a brittle texture which is different from ordinary bone. If they have been exposed to the air, they may be black or grey.

Sometimes it is necessary to break the sequestrum and remove it piecemeal. To prevent the bone splitting, use a drill with a rotation saw instead of a hammer and gouge to chip away the involucrum around each sequestrum so that you can remove it. To minimize weakening, make a window 1x10cm in the cortex longitudinally. Round or taper the ends of the window; these will be stronger and allow it to fill with soft tissue more easily. Pull out sequestra with sequestrectomy forceps. If necessary, remove more involucrum to free a sequestrum. There will be pus, but usually not much: send it for culture.

When you have removed all the sequestra you can find, explore the abscess cavity up and down quite widely with a probe. If necessary, extend the skin incision and enlarge the hole in the involucrum until you have explored the whole cavity. You may need a 2<sup>nd</sup> osteotomy in the diaphysis. Scrape the granulation tissue in its walls with a bone curette (Volkman's spoon), until you reach bleeding healthy bone. If sinus tracts in the soft tissues are short, excise them. If they are long, curette them.

**If bone overhangs the edge of the cavity**, chisel it away. Lavage the cavity with warm water.

**CAUTION!** If the operation is to succeed, you must remove all sequestered bone. The radiographs will suggest how much there is, but expect to find more. Allow muscle to fall into the cavity (7-10); if this is inadequate, mobilize a flap of muscle, preserving its blood supply, to fill the cavity.

**CLOSURE.** Complete meticulous haemostasis is essential. A suction drain may be beneficial to avoid accumulation of blood. Fix a sponge drain to the wound with a stitch, because a simple drain will block or get lost in the wound, and act as a foreign body.

Apply a pressure dressing for the first 48h, but watch the circulation distally.

After some weeks there will be a floor of healthy granulation tissue, which will either epithelialize spontaneously, or can be grafted. As you change the dressings you will find that fewer are needed as it closes. A large wound takes a long time to close.

**CAUTION!** Remove all the dressings you put into a wound. If any fragments remain, they will act as foreign bodies, and cause infection to persist. If you use pieces of gauze to pack a wound, knot them together, so that you can pull them all out at the same time.

**POST-OPERATIVELY**, the wound will ooze. Do all you can to improve nutrition. You will need quantities of sterile dressings. Change them regularly. Remove any dead tissue as necessary. *You may need to perform further formal sequestrectomies under GA to do this.* After you have removed all the dead tissue, the disease process comes to an end and rehabilitation can begin. Encourage use of the limb, walking with crutches without weight-bearing if the lesion was in the leg, and the use of the arm as much as possible. In severe cases this active movement will encourage the periosteum to produce a really robust involucrum, which will not happen if the limb remains completely immobile.

**If the involucrum might fracture**, apply a cast and window it. Or, in the leg, apply skin traction. If a large area of bone has been destroyed, careful splinting is essential. Get radiographs at a convenient time post-operatively. This is only necessary to assess the strength of the leg for weight-bearing, or, if sinuses persist, to look for more sequestra.

#### DIFFICULTIES WITH CHRONIC OSTEOMYELITIS

**If there is severe bleeding into the dressings**, return to theatre, open the wound, tie off any bleeding vessels, repack it tightly, and apply a pressure bandage. Back in the ward raise the limb, and put a cradle over it, so that you can inspect it readily. *Don't leave a pressure dressing in place for >48h*, or it will promote infection.

**If pus continues to discharge from the wound**, it may be due to:

- (1) Inadequate excision of fibrous tissue and curettage of the granulations.
- (2) Leaving sequestra behind.
- (3) Leaving a swab or piece of dressing in the wound.
- (4) Not opening up the cavity in the bone widely enough.

**If the leg has malunited in a deformed position**, an osteotomy may be necessary.

**If there is a pathological fracture**, splint the limb in the correct position in a cast until it has healed soundly. While it is healing, pay special attention to the alignment of the knee and ankle. Keep the wound open, dress and toilet it regularly. Skin traction is suitable for the femur and upper tibia, especially <14yrs. Otherwise an external fixator is best.

**If osteomyelitis has followed internal fixation with a plate**, remove it. The only exception is an AO compression plate. If this is still maintaining compression, leave it, but if it is holding a gap open between the fractured ends, remove it.

**In an infant**, the bone will probably heal well, even after you have removed a large sequestrum. If an operation is needed, *don't hesitate to operate as soon as a satisfactory involucrum has formed.*

**If there is sickle cell disease**, new bone will form particularly slowly.

**Amputation** (35.3) is justified if:

- (1) The infection is so extensive that antibiotics and surgery have been unable to arrest the disease. This is usually the case with HIV-related osteomyelitis.
- (2) Life is in danger from infection.
- (3) So much bone has to be removed that the leg is useless.
- (4) There is constant pain.
- (5) There is no chance of referring the patient for cancellous bone implantation to reconstruct the leg.

## 7.6 Osteomyelitis of the humerus

Osteomyelitis usually occurs at the ends of the humerus, more often at the upper than the lower end. You can expose and drill the bone through quite limited incisions; the upper end anteriorly and the lower end either anteriorly or posteriorly. If absolutely necessary, you can expose the humerus from end to end by approaching it from the antero-lateral side.

The main danger is that you may injure the radial nerve, as it winds round the humerus posteriorly. If you are working near it, find it first so that you can avoid it.

Proximally, enter the arm between the *pectoralis major* and the *deltoid*. Distally, enter it between the *brachioradialis* and the *biceps*. As you do so, retract the radial nerve laterally, and the musculo-cutaneous nerve medially with the *biceps*.

### (a) Proximal end

Approach this in the deltopectoral groove. Find the cephalic vein, and try to displace it medially. If necessary, tie it proximally and distally. Reflect the deltoid laterally, and expose the humerus by using two pairs of bone levers. Both the heads of *biceps* and *coracobrachialis* lie medial to the insertion of the tendon of *pectoralis major*.

### (b) Distal end, posterior approach

Make a midline incision in the posterior surface of the upper arm, and end it 3cm above the epicondyles, so as to avoid the olecranon pouch. *Don't extend the incision up into the middle third of the arm*, or you will injure the radial nerve. Divide the tendon of the triceps and the muscle under it to expose the humerus.

### (c) Distal end, anterior approach

Open the arm between the *brachioradialis* laterally, and the *biceps* medially (7-7B). Separate these muscles by blunt dissection, find the radial nerve and leave it laterally. Incise the *brachialis* medial to the nerve and expose the humerus. Retract the muscles by placing two pairs of bone levers subperiosteally.

## EXPOSING THE ENDS OF THE HUMERUS

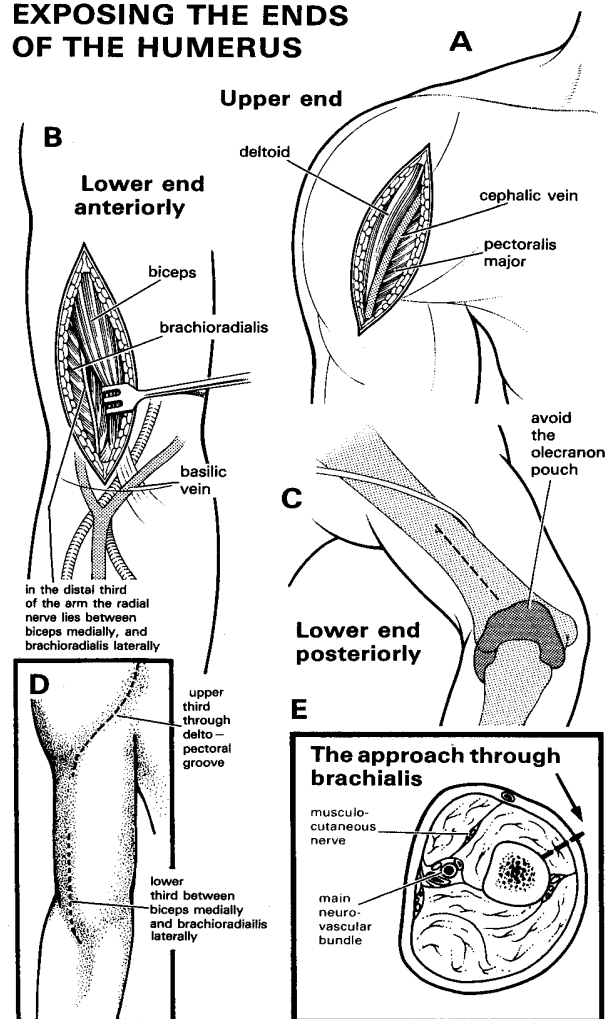


Fig. 7-7 OSTEOMYELITIS OF THE HUMERUS.

A, approach for the upper end. B, anterior approach to the lower end. C, posterior approach to the lower end. D, incisions to approach the ends of the bone. E, cross-section a little below the mid-point of the arm above the origin of *brachioradialis*, to show the approach to the middle of the shaft and the position of the radial nerve.

If necessary, you can split the *brachialis* to within 3cm of the epicondyles without entering the elbow joint. *Don't extend the incision beyond the flexor crease of the elbow*, because you may cut the radial artery.

### (d) The shaft

Put a sandbag under the shoulder on the same side. Drape the whole arm. Extend the approach to the upper humerus distally, or the lower anterior approach proximally. Distally, divide the deep fascia to expose division between *biceps* and *brachialis*. The musculo-cutaneous nerve lies between these muscles. Displace it medially with the *biceps*. Separate the *biceps* and *brachialis* and find the radial nerve. Above the origin of the *brachialis*, it lies between *biceps* and *triceps* and winds posteriorly round the humerus in the radial groove.

Post-operatively, put the arm in a sling and encourage active movements within the confines of the sling, or apply a backslab.

## 7.7 Osteomyelitis of the radius

You can expose the distal  $\frac{2}{3}$  of the shaft of the radius by approaching it from its anterolateral side. The difficult part is its proximal  $\frac{1}{3}$ , which is covered by the *supinator* muscle, through which the posterior interosseous nerve passes. So avoid operating here if you possibly can. Enter the forearm between the *brachioradialis* laterally (it has a characteristic flat broad tendon) and the *flexor carpi radialis* medially. The radial artery lies between these 2 groups of muscles. *Pronator teres* is inserted into the middle of the radius. You can approach the bone on either side of this muscle, and displace it medially or laterally. Distally, *pronator quadratus* covers the radius, so you will have to divide it.

### EXPOSING THE RADIUS AND ULNA

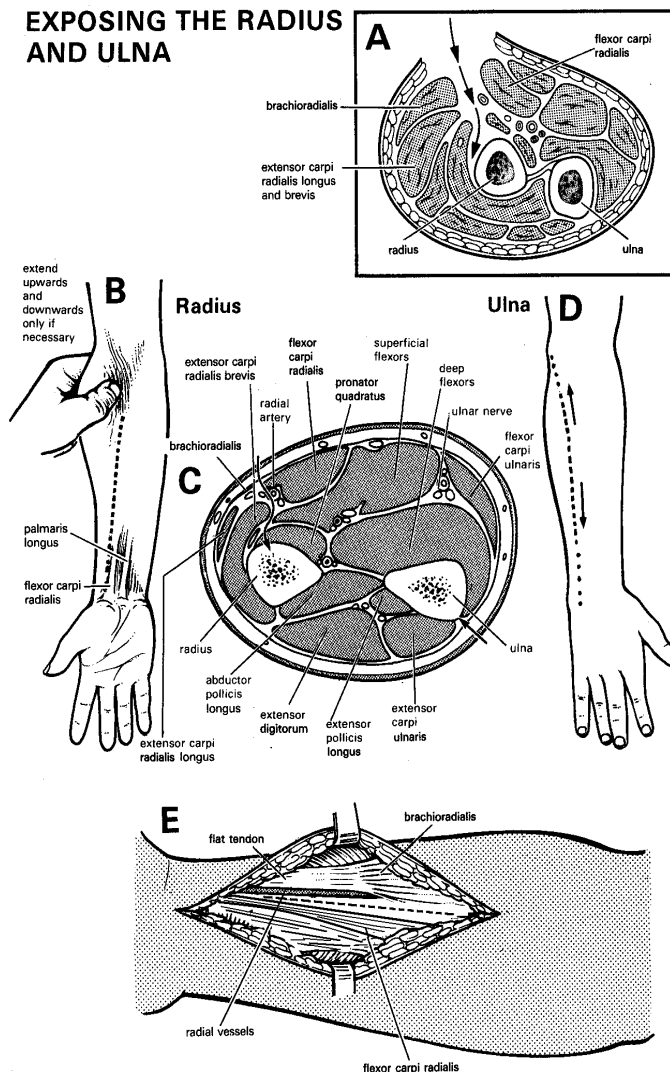


Fig. 7-8 EXPOSING THE RADIUS AND ULNA.

A, cross-section of the forearm at the level of the radial tuberosity. B, to expose the radius, enter the forearm between the *brachioradialis* and the two radial wrist extensors laterally, and the *flexor carpi radialis* medially. C, a transverse section through the middle of the arm. D, the ulna is subcutaneous, so you can approach it easily. E, *brachioradialis* has a long flat tendon, so you can recognize it easily. It and *flexor carpi radialis* flank the incision for the lower part of the radius. Partly after Watson-Jones R, *Fractures & Injuries*, E&S Livingstone 1960, with kind permission.

### (a) Distal end

Lay the patient supine with the arm on a side table and the forearm supinated. Define the line of the incision by identifying the tendons of the *palmaris longus* and the *flexor carpi radialis* at the wrist. Incise just lateral to this muscle (7-8B).

You will probably only need to incise over the distal  $\frac{1}{3}$  of the bone. If necessary, you can continue the incision proximally to include its middle  $\frac{1}{3}$ .

**CAUTION!** Don't extend the incision to the proximal  $\frac{1}{3}$ , or you may injure structures on the front of the elbow.

Cut the deep fascia in the line of the skin incision. Tie any vessels you meet. Retract laterally the 3 muscles that lie along the lateral border of the forearm: *brachioradialis*, *extensor carpi radialis longus* and *brevis*. When you retract them, the superficial radial nerve will be included with them. This is sensory only.

Find the radial artery and vein, which lie between the lateral group of muscles and *flexor carpi radialis*. Retract them laterally. You will now have exposed the anterolateral surface of the distal  $\frac{2}{3}$  of the radius.

Post-operatively, apply plaster only if a fracture threatens or has occurred. If so, apply a tubular forearm cast leaving the wrist and elbow free. The remaining bone will prevent angulation. Encourage use of the arm.

## 7.8 Osteomyelitis of the ulna

The ulna has a subcutaneous border throughout its whole length, so it is easy to expose.

Make an incision anywhere from the tip of the olecranon to the ulnar styloid. Use the most appropriate part of the incision (7-8D), not all of it. Cut straight down on to the shaft of the bone and elevate the periosteum. This will carry the muscular origins of the *flexor carpi ulnaris* anteriorly, and those of the *extensor carpi ulnaris* posteriorly.

Post-operatively, apply plaster only if a fracture threatens or has occurred. If so, apply a tubular forearm cast leaving the wrist and elbow free. The remaining bone will prevent angulation. Encourage use of the arm.

## 7.9 Osteomyelitis of the femur

If osteomyelitis is acute, you need only drill the upper or lower end of the femur, for which you will only need a limited incision. If osteomyelitis is chronic, it may have involved the entire shaft of the bone. By a lateral approach, you can expose it from its greater trochanter to its lateral condyle. Cut straight through the *vastus lateralis* down to the bone. The head and neck of the femur are more difficult to reach. If osteomyelitis has involved the neck, which is partly inside the capsule of the hip joint, it will have also involved the head and the hip joint. This will need draining. The anterior approach is easiest for drilling the femoral neck (7.18).

Osteomyelitis of the femur commonly involves the hip joint, and occasionally the knee, but seldom both. When a child's knee is involved, the distal femoral epiphysis may slip. If this happens, the shaft of the femur usually slips anteriorly in front of the distal epiphysis, unlike in injury in which it slips posteriorly. Prevent further slipping by applying skin traction up to the mid thigh. You may need to manipulate it under GA.

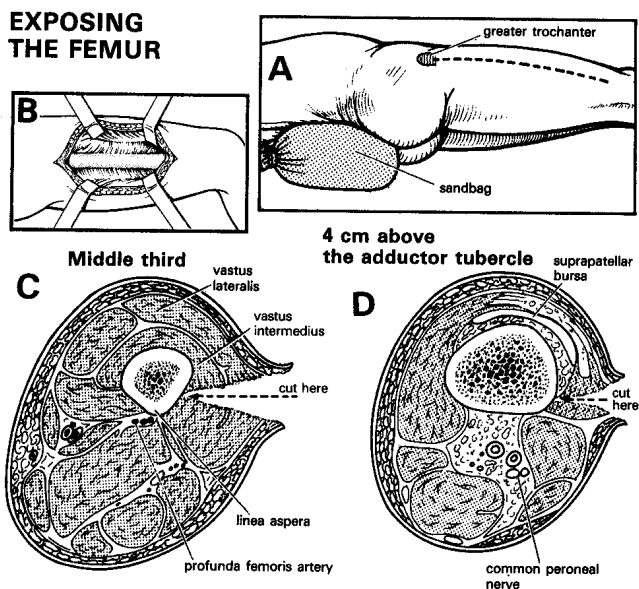


Fig. 7-9 EXPOSING THE FEMUR.

You can expose the femur by cutting straight down onto it along the lateral side of the thigh. A, prop up the buttock on a sandbag, and secure the patient on the operating table so he does not fall off! B, expose the middle 1/3 of the femur. C, cross-section of the middle of the thigh. D, cross-section about 4cm above the adductor tubercle.

Kindly contributed by John Stewart.

#### (a) Femoral shaft

Cross-match two units of blood; this can be a bloody operation, especially if you cut too far posteriorly. Use the supine position with a sandbag under the hip on the infected side. Use a tourniquet when you operate on the middle or distal thirds of the bone.

Cut along the relevant part of the incision (7-9A). This extends from just distal to the greater trochanter to just above the lateral femoral condyle. Cut through the skin, subcutaneous fat, and *fascia lata*. Then cut straight through the *vastus lateralis*, down to the lateral side of the shaft of the femur. There will be some bleeding, but much less than there would be if you cut posteriorly on to the *linea aspera*.

#### CAUTION!

- (1) Take care to stay on the lateral surface of the femur.
- (2) Avoid the *linea aspera*, and vessels near by.
- (3) Remember that blood loss in a small child is proportionately more serious.

If there is bleeding from the vessels of the *linea aspera*, catch them with a haemostat, and transfix them with a ligature on a curved needle. Pass the needle round under the haemostat and the vessels at least twice. Pull the ligatures tight as you release the haemostat. They are usually too deep into the wound to tie on the tip of a haemostat. If you cannot reach a bleeding vessel, pack the wound tightly, raise the foot of the table and wait for the bleeding to stop.

If you are operating towards the distal end of the femur:

- (1) Don't enter the knee joint or the suprapatellar bursa.
- (2) Stay strictly on the lateral side of the knee.
- (3) Don't go posteriorly: you may injure the lateral popliteal nerve.
- (4) Don't go medially because you may injure the main vessels.

Post-operatively, apply skin traction. This will be easier than applying a medial plaster splint, which is the alternative. Later, use a hip spica or a plaster cylinder from the groin to the knee, add crutches, and encourage weight-bearing.

## 7.10 Osteomyelitis of the tibia

The tibia is one of the most common sites for osteomyelitis, which is fortunate, because it is one of the easier bones to approach. If the infection is early, decompress it through a short incision. If chronic infection exists, *don't operate before a firm involucrum has formed*, or you will leave a gap in the bone which will need extensive reconstructive surgery to repair. A gap is particularly likely in the tibia, because so much of it is subcutaneous.

DRILLING. Make a linear incision 1cm lateral to the anterior border of the patient's tibia (7-10).

#### EXPOSING THE TIBIA

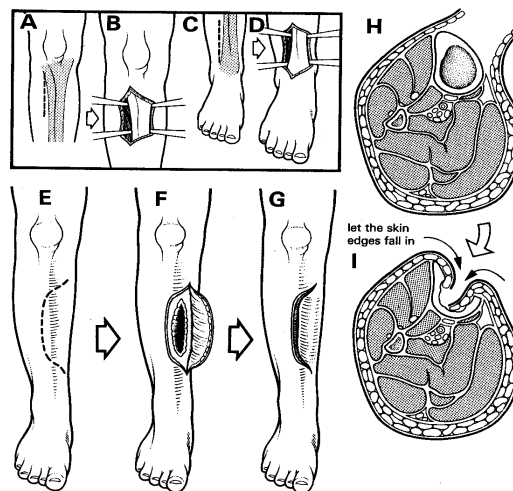


Fig.7-10 OSTEOMYELITIS OF THE TIBIA.

A-B, expose the upper end of a patient's tibia. Incise over muscle on the lateral side. C-D, expose the lower tibia; again incise over muscle on the lateral side. E-G, expose the shaft of the tibia. Incise mainly on the lateral side and reflect a flap medially. H-I, allow the edges of the flap to fall into the wound to close it post-operatively.

**SEQUESTRECTOMY.** Make the main part of the incision over the muscles rather than the bone. Make the longitudinal part of the incision 1cm lateral to its anterior border. Proximally, *don't extend it higher than the tibial tubercle*. If possible, avoid taking it across the tibia where this is infected, because the scar from the incision will stick to the bone and become painful later. If necessary, curve its upper and lower ends to cross the anterior border of the bone.

Reflect the skin with the periosteum. They will probably be so closely bound together that you will be unable to separate them. Hold the skin flap lightly with skin hooks. Incise the periosteum midway between the anterior and posteromedial borders of the bone.

**If the position of sinus tracks is medial,** you can make a medial flap in the same way, with most of the length of the incision over the muscle on the medial side of the tibia.

After you have removed the sequestrum:

(1) If the tissues are not too tight, close the wound lightly and insert a drain in its lower part.

(2) If the tissues are tight, let the skin edges fall into the wound and leave it unsutured (7-10H,I). Healing will take longer like this. Apply a posterior slab or a long leg cast with the ankle in neutral, and the knee in 20° of flexion. Mark a window in it while it is still soft, cut out the window with a knife, or with a plaster saw 2 days later when it is hard. Dress the wound through this window.

**If you have left a deep trough in the front of the tibia** which is slow to granulate and epithelialize, graft it.

**CAUTION!**

(1) *Don't go directly anteriorly through the subcutaneous surface of the tibia.*

(2) Make sure your assistant retracts the skin flaps gently, because they can easily necrose.

Apply a long leg cast with a walking heel, then encourage early weight-bearing with as normal a gait as possible.

**DIFFICULTIES WITH OSTEOMYELITIS OF THE TIBIA**

**If there is a very large skin defect in the tibia which is slow to heal,** consider making relieving incisions about 15cm long down the medial and lateral sides of the calf, and pushing the tissues forward to cover part of the gap. Hold them in place with sutures or strapping. Graft the gap made by the relieving incisions.

**If a large part of the tibia has been destroyed, and inadequate involucrum has formed,** try to get the fibula to hypertrophy. Apply a below-knee calliper. Later, an operation in which a length of the fibula is moved across to form a new tibia is needed. This is done in two steps, moving one end at a time. The transposed piece of the fibula can hypertrophy greatly.

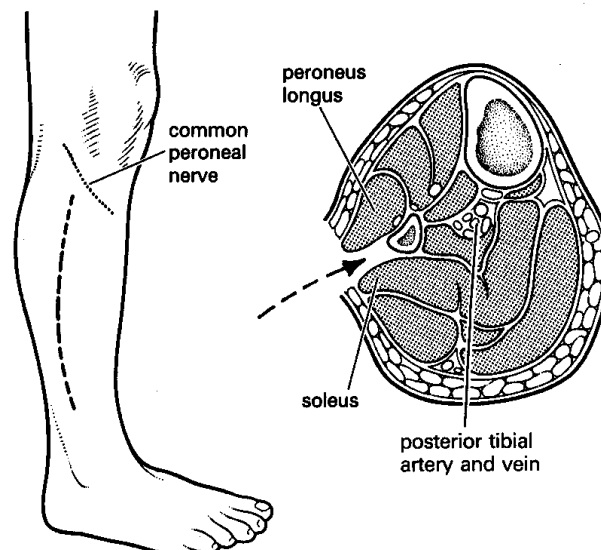
**If: (1) a sequestrum was removed before a firm involucrum had formed, or (2) the periosteum in the middle 1/3 of the shaft of the tibia is destroyed,** use a Sarmiento cast, to support the leg and prevent the foot going into inversion until such a time as you can get a fibula transplantation done.

**If a child's tibia is completely destroyed,** the fibula may hypertrophy, and push the foot into *varus*; this needs expert correction.

## 7.11 Osteomyelitis of the fibula

Osteomyelitis of the fibula is uncommon. If the tibia is not involved, you can remove a sequestrum from the fibula as soon as is convenient, without waiting for an involucrum to form, because the tibia will support the leg. You can expose any part of the fibula by approaching it between the peroneal muscles anteriorly and the *soleus* posteriorly. The posterior tibial nerve and vessels are well out of harm's way; but *be careful not to injure the peroneal artery and veins which are close to the postero-medial angle of the shaft of the fibula*. If the head of the fibula is involved (rare), *be very careful not to injure the common peroneal nerve*.

### EXPOSING THE FIBULA



**Fig. 7-11 OSTEOMYELITIS OF THE FIBULA.**

Approach the fibula between the peroneal muscles anteriorly, and the *soleus* posteriorly.

**INCISION.** Use the lateral position with the affected leg uppermost, and the knee slightly flexed. Use the appropriate part of an incision which starts 5cm below the head of the fibula, and curves gently posteriorly down towards the lateral malleolus. Reflect short skin flaps anteriorly and posteriorly. Avoid the head and neck of the fibula, because the common peroneal nerve winds round it. If you have to remove sequestra from the head, try to pull them down from below.

**If you are working on the middle 1/3 of the fibula,** incise the periosteum vertically, and separate muscle from bone subperiosteally.

**CAUTION!** The peroneal vessels are close to the medial side of the fibula, *so strip the muscles carefully*.

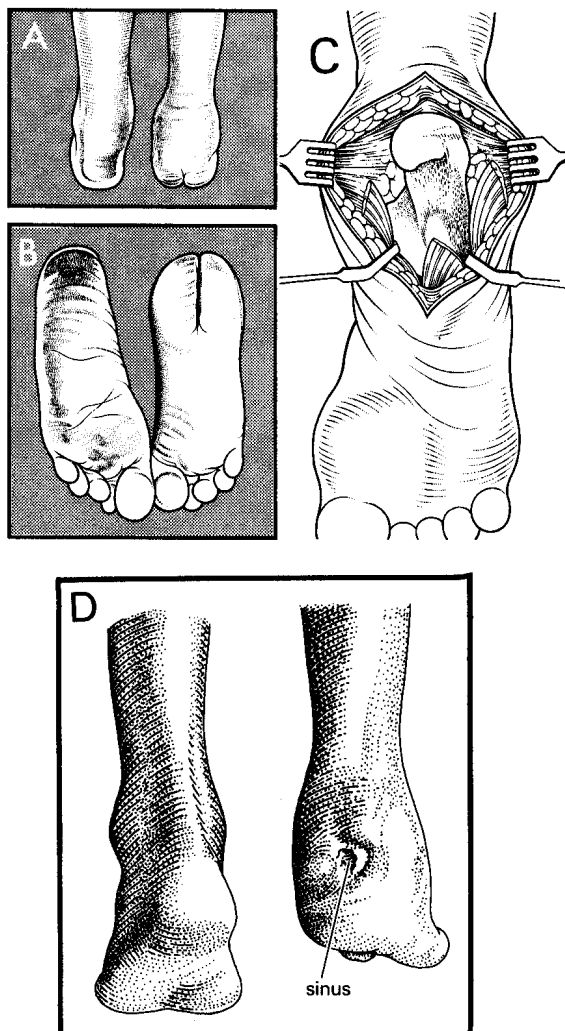
### EXCISION OF THE FIBULA (GRADE 2.5)

If necessary, and if the child is >10yrs, remove the entire shaft of the fibula, except for its lower 5cm. Use a Gigli saw, *not an osteotome, or bone-cutting forceps*, which will splinter it. *Be very careful to avoid the common peroneal nerve winding round its upper end.*

## 7.12 Osteomyelitis of the calcaneus and talus

The calcaneus is a completely cancellous bone which never forms an involucrum and seldom an isolated sequestrum. Pus soon perforates its periosteum without destroying much of its cortex. The most practical operation, and some would say the only one, is to remove the whole of the calcaneus to obtain an ugly but surprisingly useful foot.

### OSTEOMYELITIS OF THE CALCANEUS



**Fig. 7-12 OSTEOMYELITIS OF THE CALCANEUS.** Split the heel for the easiest approach to the calcaneus; this brings no disability. A-B, after the operation. C, expose the calcaneus. D, osteomyelitis of the right calcaneus with a sinus.

After Crenshaw AH, Campbell JW *Operative Orthopaedics*, CV Mosby, 5<sup>th</sup> ed 1971 Fig. 10-18 with kind permission.

**If infection is limited to the pin track**, opening up and scraping out the granulation tissue from around the pin track may occasionally be all that is needed.

You can approach the calcaneus from either side in order to drain a soft tissue abscess or to remove a window from the cortex during the acute stage of osteomyelitis.

#### (a) Calcaneus

Use the prone position with a support under the foot. Make a longitudinal incision exactly in the middle of the heel. Start it in the midline level with the base of the 5<sup>th</sup> metatarsal. Extend the incision proximally to split the distal end of the Achilles tendon for c.3cm.

Incise the plantar aponeurosis in a plane between the *flexor digitorum brevis* and *abductor digiti minimi*. Shell out the bone. You cannot remove it from inside its periosteum, so strip this away from the soft tissues of the heel and remove the bone completely, either as a single piece or in several smaller ones.

**CAUTION!** Start in the midline, stay close to bone and reflect everything you meet medially and laterally. In this way you will avoid important structures, especially the plantar nerves entering from the medial side of the foot.

**POST-OPERATIVELY**, allow the wound edges to collapse together, but don't suture them. Apply much gauze. Hold the ankle in a neutral position with a gutter plaster splint held with a crepe bandage. As the wound heals, start walking with crutches; later, progress to full weight-bearing. The edges of the scar will turn deeply inwards and split the heel into two cushions. If its surface is uneven, suggest wearing shoe pads.

#### (b) Talus

Presentation is with a painful ankle. Radiographs show an irregular dense talus. Sequestra are unusual. If you apply a below-knee cast and treat with an antibiotic for 3wks, the infection will probably settle without surgery, but degenerative arthritis may follow.

## 7.13 Osteitis of the cranium

Flat bones like those of the skull differ from long ones: (1) They have little marrow between their diploë, so that when they are infected the condition is an osteitis, rather than an osteomyelitis.

(2) Unlike long bones, flat bones seldom sequestrate, and *don't form an involucrum*.

(N.B. Osteitis of a rib is usually due to TB.)

When sequestra do form in the skull, it is usually because a burn has destroyed the blood supply to the outer diploë.

Osteitis of the skull presents with headache, combined with tenderness and swelling over the lesion which may be particularly marked.

It may be secondary to:

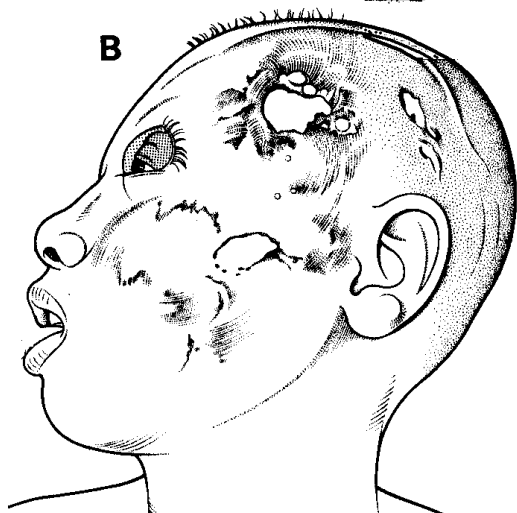
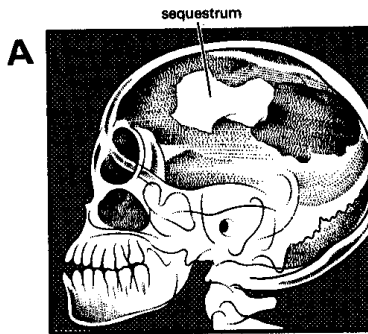
- (1) A deep burn.
- (2) An open skull fracture.
- (3) Frontal sinusitis (29.8).
- (4) An extradural abscess (6.5).
- (5) Septic thrombophlebitis of the scalp.
- (6) Pyaemia causing metastatic lesions in the skull.

When you plan the incision, consider the arteries of the scalp, and incise between them. For example, don't make a transverse incision in the temple which will divide the temporal artery. *Split skin grafts will not take on bare skull*, but they will take on granulations. So, if necessary, remove dead bone, apply saline dressings for a few days, and wait for granulations to form.

**CAUTION!** If a sequestrum is firmly anchored, use an osteotome and light taps from a heavy hammer; *don't open the dura or injure the brain.*

If osteitis follows **FRONTAL SINUSITIS** (29.8), define the extent of the frontal sinus with radiographs. Shave the anterior 3cm of the scalp. Make a long incision above the hairline from ear to ear, and reflect the skin of the forehead downwards as a flap, based on the supraorbital vessels.

## SEQUESTRUM OF THE SKULL



**Fig. 7-13 SEQUESTRUM IN THE SKULL.**

There is a dense white sequestrum in the skull, which has extended forwards. Burns of the scalp are however the commonest cause of necrosis of the skull. Another cause is septic thrombophlebitis of the scalp, which causes it to necrose and expose the bone underneath.

*Kindly contributed by Gerald Hankins.*

Remove the anterior wall of the frontal sinus; try to curette away all its lining, so that no more fluid will form. If possible, try to establish drainage through the nose. Insert drains through stab incisions above the outer end of each eyebrow. Lead them horizontally from the frontal region of the sinus through these incisions. Or, insert them below the inner eyebrows. Close the flap.

## 7.14 Osteomyelitis of the jaws

Osteomyelitis can affect either of the jaws, usually the lower one, and can be secondary to:

- (1) An infected tooth socket in an adult, especially the mandible (6.9, 31.3). Suspect it if there is pain, swelling, tenderness, trismus, and fever after he has had an infected tooth removed (sometimes months before), or an alveolar abscess drained.
- If the osteomyelitis becomes chronic, there may be sinuses over the lower face, or over the inferior border of the mandible (31-9). The offending teeth are usually loose, and you may see pus discharging around them.
- (2) An open fracture, especially comminuted, of the lower jaw.
- (3) Cancrum oris (31.5).
- (4) Sickle cell disease.
- (5) Actinomycosis (31.6).

### (a) Acute osteomyelitis

If osteomyelitis is due to an infected tooth, extract the tooth (31.3).

If it is due to an open fracture or haematogenous, it is probably subacute and can be satisfactorily treated by antibiotics.

### (b) Chronic osteomyelitis

**RADIOGRAPHS.** PA and oblique views may rarely show a sequestrum, or a patchy osteoporosis accompanied by new bone formation (dense thickened bone). No significant radiographic changes with multiple skin sinuses discharging 'sulphur granules' suggest actinomycosis (31.6).

**TREATMENT.** Treat with antibiotics (cloxacillin or chloramphenicol) for up to 2wks. Improve the oral hygiene. Remove any loose teeth. If a sequestrum is present, remove it. There is no need to wait for an involucrum to form unless the sequestrum is very large.

### SEQUESTRECTOMY

- (1) **Maxilla.** As the dead bone separates, it loosens. Wait for nutrition to improve. If the sequestrum is small and loose, remove it under sedation only. If it is larger, remove it under ketamine *in toto* or in pieces. If necessary, chip away a little living bone. Curette the residual defect. If the cavity bleeds, pack it for 5mins.

(2) **Mandible.** To avoid an unsightly scar, incise 1cm below the inferior border of the ramus of the mandible. Cut through healthy skin and subcutaneous tissue near the sequestrum. Avoid, or clamp and tie, the facial artery and vein, as they cross the ramus of the mandible 3cm (in an adult) anterior to its angle. Chisel away the outer bone covering the sequestrum and curette the cavity. Close the wound loosely, leaving a corrugated drain through one end, or through a separate stab wound.

*CAUTION! Don't operate on a malnourished child until the general condition is acceptable.*

## 7.15 Osteitis of the spine, pelvis and ribs

The spine can rarely be affected by suppurative osteitis: the patient is usually a very ill child with fever and severe back pain, usually in the lumbar region. There may be some inflammatory oedema over the spine, which is very tender, and may be arched backwards by muscle spasm, as if he had tetanus or meningitis.

Ultrasound or radiographs may show a paravertebral abscess, usually with normal bones. There may be paraplegia as the result of inflammatory oedema involving the cord. If there is to be any chance of survival, the pus must be drained by removing the transverse processes of some of the vertebrae and part of some of the ribs. If there are no spasms, recovery will probably occur in 3-6 months. But if there are extensor or, worse, flexor spasms, the paraplegia is likely to be permanent.

Osteitis may be chronic in an older child or adult. There is pain, but little or no fever, and no arching of the back.

Tuberculosis of the spine (32.4) is the commonest type of **spondylodiscitis** (infection of the disc space). This occurs more commonly in HIV disease. Ambulatory treatment with standard anti-tubercular therapy is effective if patients can walk: there is no advantage of an initial period of bed rest, application of a spinal POP jacket, or adding streptomycin to the regime. A costo-transversectomy (32.5) for the drainage of a cold abscess is only indicated when neurological signs ensue.

In sickle cell disease, *salmonella* is frequently the cause, and *staphylococcus* less so. The only early radiographic sign may be disc-space narrowing; treatment with IV antibiotics is necessary for 6wks, associated with spinal immobilization. Drainage is required if there is no response to antibiotics, neurological signs ensue, or there is an epidural abscess.

### THE SPINE

**If there is marked osteoporosis but minimal or no osteosclerosis,** suspect tuberculosis (32.4).

**If the bodies of the vertebrae are abnormal, but not the intervertebral discs,** suspect malignancy.

**If the disc and the adjoining bone are diseased, especially if this is maximal anteriorly,** suspect infection. The diseased bone softens, and the vertebral bodies become wedge-shaped.

**In a child,** consider Burkitt's lymphoma (17.6).

### THE PELVIS

Osteitis of the pubis may occasionally follow symphysiotomy (21.7).

If it involves the innominate bone, try antibiotics for up to 6wks. Sequestra are unusual.

### THE RIBS

Osteitis of the ribs is rare, and almost always due to tuberculosis, usually only confirmed on rib resection.

## 7.16 Septic arthritis

An infected joint is another condition in which failure to drain pus early is a real disaster: severe chronic and probably painful disability results. If you don't drain the infected joint early, it will be destroyed and may ultimately ankylose. In a child, the epiphyses near it may displace or dislocate. As soon as you have made the diagnosis, drainage is urgent: *this is not an operation to leave until the next day!* If you allow pus to accumulate under pressure in the hip, it may impair the blood supply to the head of the femur within 8h, so that it necroses. Pus can also damage a joint, even if the blood supply is not impaired.

Bacteria can reach a joint:

(1) Before the age of 6 months, from osteomyelitis in the metaphyses of any long bone. After this age, the epiphyseal plates prevent such spread.

(2) At any age, in the hip, because the proximal metaphysis of the femur is partly within the capsule of the hip joint. This makes septic arthritis of the hip and osteomyelitis of the neck of the femur virtually the same disease. The hip may also be infected in a child as a result of femoral artery or vein puncture.

(3) Through the blood from a distant septic focus, or IV injection of drugs. This is haematogenous septic arthritis, which involves the knee, hip, shoulder, and ankle in this order of frequency. It is more frequent in HIV disease.

(4) From sexually acquired infections: gonococcal arthritis affects usually knees and ankles.


(5) Through a penetrating wound of a joint, especially of the fingers or knee, particularly after an animal bite, or previous surgery especially if a prosthesis has been inserted.

The first sign of septic arthritis is immobility. One of the joints, commonly the hip or knee, becomes so painful that moving it even a little in any direction causes great pain. Sometimes, several joints are involved at the same time. There is usually pyrexia. The combination of fever and a painful immobile limb is caused by either osteomyelitis or septic arthritis, until you have proved otherwise. Later, if the infected joint is near the surface, you will be able to feel that it is warm and swollen with fluid. Unfortunately, the shoulder and the hip are so deep that you cannot easily detect fluid, so that the only local sign is acutely painful limitation of movement.

*Septic arthritis does not always run a typical course, and so is not often easy to diagnose.* Here are some of the difficulties:

- (1) In the very old or very young, there may be few general signs of infection, and the effusion may not even appear to be inflammatory.
- (2) In the spine, the sacroiliac joints, and the hips, pain may be the only presenting symptom.
- (3) The pus may be too thick to aspirate.
- (4) Only 50% of patients have a fever or a leucocytosis, especially if HIV+ve.
- (5) You can easily confuse tuberculous with subacute suppurative arthritis. To distinguish them, rely on the radiograph and your findings on aspiration (pus or caseous tissue). If you are still in doubt, treat for both diseases. Review the progress at 3 and 6wks, when suppurative arthritis should show much improvement, whereas it is still too early for tuberculosis to show much change.

### DISASTER WITH AN INFECTED HIP



**Fig. 7-14 DISASTER WITH AN INFECTED HIP.** Radiograph and classic position seated. Infection has displaced the epiphysis of the femur, and moved its shaft upwards. The infection in the thigh is producing gas.

The diagnosis is particularly difficult in babies:

AHMED (1yr) was brought by the mother saying he had fever and was drawing up the left hip in pain. This in itself was unusual, because, if a baby does this, he usually draws up both of them. He was found to have suppurative arthritis of the right hip, which was too painful to move. It was aspirated, antibiotics were started within 24h, and he recovered. LESSON The diagnosis was made early and treatment started immediately.

Septic arthritis is more common in the disadvantaged and malnourished and also in infancy and old age. It is common in HIV disease, as well as diabetes mellitus, chronic renal failure and in joints previously damaged by trauma or inflammatory disease.

*Staphylococcus aureus* is the dominant organism, but if the patient has HIV or sickle cell disease, you may find *E. coli* or *salmonella* in the joint. *Haemophilus influenzae* is the most frequent organism in newborns, but is seldom seen in older patients. Other organisms include *streptococci*, *brucella* and *gonococci*. Congenital syphilis presents as swelling of both knees without much fever, in childhood. Actinomycosis and mycetoma (34.11) may also invade joints from outside.

Several things can happen to a severely damaged joint:

- (1) It can dislocate.
- (2) An epiphysis can slip, either immediately, or several weeks later (7-14).
- (3) It can become fixed in a painless stable bony ankylosis in the position of function.
- (4) It can develop a painful unstable fibrous ankylosis, which can be a serious disability.

HASINA (17yrs) was admitted with pain in her left hip and inability to walk for 3 days. She was given physiotherapy, nursed on a fracture bed for 3wks, and discharged on crutches. Some weeks later she was readmitted, pyrexial, and with a swelling of her right thigh extending from her knee to her iliac crest. 3L yellow-green pus were aspirated (7-14).

MARIAMU (12yrs) was admitted with osteomyelitis of her tibia. This was settling nicely when she developed pain in her left hip and became pyrexial. The radiographs of her hip were normal, septic arthritis was diagnosed, and she was given large doses of the latest broad-spectrum antibiotic. Her pain improved slowly but her fever continued. Later, radiographs showed destruction of the head of her femur. Traction was applied. Sinuses developed, and she was never able to walk again. Two years later her pain was so severe that she had to have her hip disarticulated. All this happened in a 'good' hospital.

LESSONS (1) The early diagnosis of septic arthritis of Hasina's hip was not made, although the history and signs were obvious. (2) Rest in bed on traction would have prevented her epiphysis slipping. At best she will have a painful hip, either for life, or until her hip has ankylosed spontaneously, or been fused surgically. (3) Explore a hip on the suspicion of septic arthritis.

### ASPIRATE ALL SPONTANEOUS JOINT EFFUSIONS AND DRAIN ALL INFECTED JOINTS

ASPIRATION. Use pethidine IV; thoroughly sterilize the skin site you plan to use for the aspiration. Carefully choose the site of puncture and push a large (1.2mm) needle down into the joint (7-15). The critical investigation is to *aspirate the joint as soon as you suspect infection*. Frank pus in the syringe, or even slightly cloudy synovial fluid, confirms the diagnosis. You may get a false -ve, but apart from contaminants in the culture, you will never get a false +ve result. *Aspiration alone is not enough; it only tells you that pus is present: you must thoroughly irrigate the joint till the effluent is clear.* However, aim to aspirate as much of the pus as you can. Aspirating the more superficial joints is usually easy (7.17).

**If you fail to aspirate a joint that you think is infected,** you must incise and drain it, *i.e.* perform an arthrotomy. The results of not doing so are so serious that the dangers of attempting it are well worthwhile. Likewise, if the pus is too thick to aspirate properly, perform an arthrotomy to wash out the joint.

**SPECIAL TESTS.** Culture the synovial fluid (30% +ve result) and blood (14%). Screen for HIV.

**RADIOGRAPHS.** Signs are:

- (1) Widening of the joint space.
- (2) The signs of early osteitis (7.3). You may see the first signs of new bone formation as early as the 5<sup>th</sup> day in an infant, but it will not appear before the 10<sup>th</sup> day in an older child, and may take longer.

**ANTIBIOTICS.** Try to isolate the organism, otherwise cloxacillin or chloramphenicol are most suitable. Under 5yrs, salmonella is most common. In acute cases treat for 2-3wks; in chronic cases for up to 6wks. When infection is well established, antibiotics seldom help. Treated early, septic arthritis may recover fully. In Asia, if the infection is due to melioidosis, use ceftazidime IV.

**If, when you drain an infected joint and wash out the pus, its joint surfaces are smooth,** there is a good chance of having a normal or nearly normal joint. The prognosis is worse if cartilage has been lost, if the joint surfaces are rough, if the bone is soft, or if a radiograph shows severe joint destruction. There is still hope of a movable joint, especially in the young; a child's epiphysis may seem to be destroyed on a radiograph, and yet regenerate considerably.

#### EXPLORATION ARTHROTOMY (GRADE 2.1)

Open the infected joint. Use a tourniquet where possible, and if the hand is involved, watch out for the nerves. Irrigate the interior of the joint forcefully using a syringe and warm water. Do this until the fluid comes back clear. Feel the surfaces of the joint. Leave the wound open. The linear incision you have just made will become elliptical, and you will see the cartilage underneath. If the joint is superficial, it needs no drain. If it is deep, as in the hip and shoulder, insert a rubber drain.

**If the joint surfaces feel smooth,** the prognosis is good. After 10 days of rest, start gradual active movements.

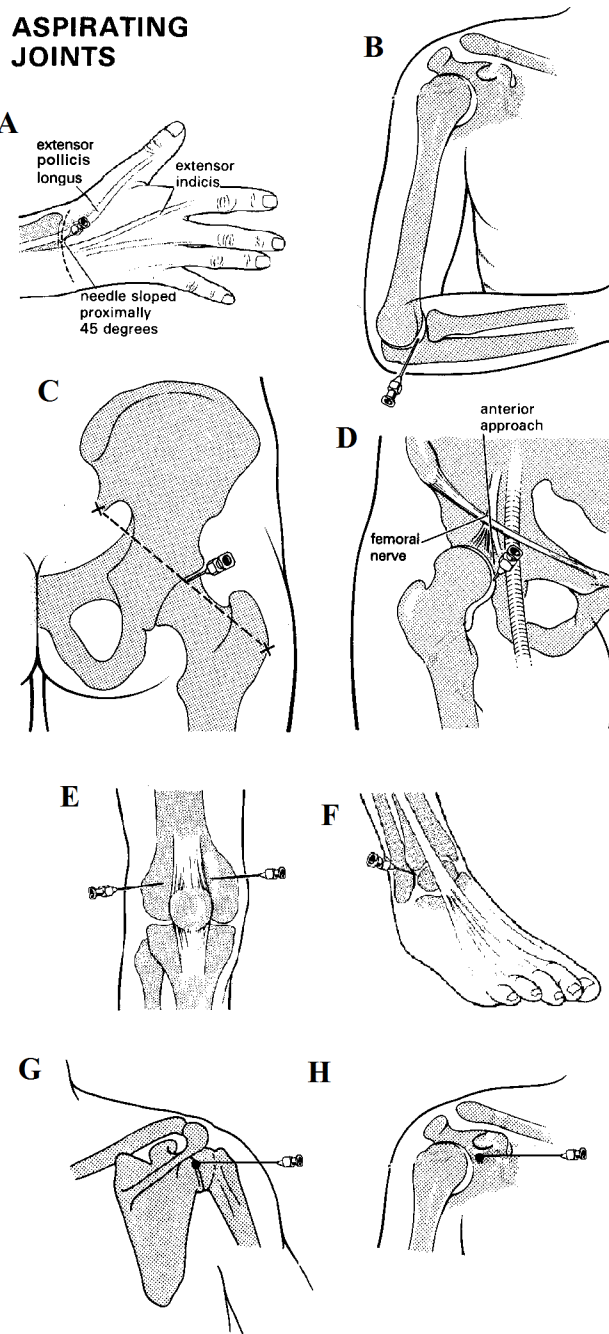
**If the joint surfaces feel rough but some cartilage still covers the bones,** there may still be useful function in the joint.

**If all its cartilage has been destroyed,** the prognosis is bad. The best hope is a stable ankylosis in the position of function (7-16). If the hip or knee is involved, apply temporary skin traction.

**If, later, there is a persistently painful joint with limited movement,** an arthrodesis is indicated. Fusing a joint is difficult in a child, and is rarely necessary; if it is done too early, there will be growth problems, so delay this as long as possible.

## 7.17 Methods and positions for septic joints (except the hip)

Joints need to be in particular positions for particular purposes, so be sure to get it right. These positions seldom coincide with one another, and the position of function is absolutely critical.



**Fig. 7-15 ASPIRATING A JOINT** may confirm the diagnosis, if pus is thin enough to come out of the needle. It is not effective treatment alone unless you wash the joint thoroughly.

A, wrist. B, elbow. C, posterior approach to the hip. D, anterior approach to the hip. E, knee. F, ankle. G, posterior, & H, anterior approaches to the shoulder (*right-sided joints shown*).

A-F, after Dudley, HAF (ed) *Hamilton Bailey's Emergency Surgery*. Wright 11<sup>th</sup> ed 1986, with kind permission. G kindly contributed by Jack Lange.

**The position of function** is the best position for a joint to be in if it is going to be fixed, or if its movement is going to be severely limited. It is also called the position for ankylosis.

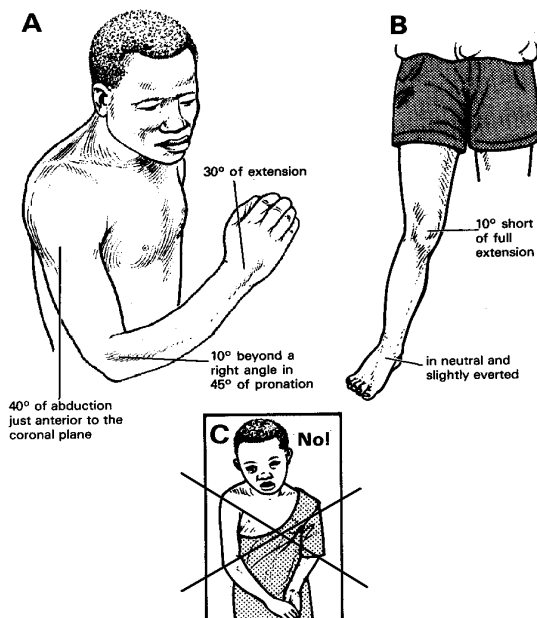
**The position of rest** is the most comfortable position for a joint to lie. Put it into this position if it has to be rested for any reason, but is in no danger of ankylosing.

**The neutral position** of a joint is that from which its movement is measured. It is for anatomical description only.

**The position of safety** is for the hand only. It is the position in which the collateral ligaments of the finger joints are stretched, and in which fingers which are temporarily not going to be moved are least likely to become stiff.

Any kind of ankylosis, stable or unstable, is a dreadful disability if the joint becomes fixed in the wrong position, so make sure that, if it is going to ankylose, it does so in the most useful position. The position of function varies from joint to joint, and may depend on what the patient wants to do with it. You never know for sure when a joint is going to ankylose, so put it into the position of function for every case of septic arthritis. For example, splint the knee just short of full extension; splint the right (or dominant) elbow flexed. Make quite sure this position is maintained before discharge! *Don't leave this task to a physiotherapist in the hope that it will be achieved later!*

## POSITIONS OF FUNCTION



**Fig. 7-16 POSITIONS OF FUNCTION.** If a joint is going to ankylose, the position in which it does so is critical. A, notice that the shoulder is abducted, the right elbow is flexed and in mid-pronation, the left elbow is extended (for toilet purposes) and B, the knee is just short of full extension, and the ankle is in neutral and slightly everted. C, this girl had an infected burn of her right elbow. The joint became infected. Tragically, it was allowed to ankylose in nearly full extension, so that she cannot eat with it or write! Kindly contributed by John Stewart.

## THE POSITION OF A JOINT IS ALL IMPORTANT!

### (a) The shoulder

#### ASPIRATION

**Posterior route:** sit the patient in a chair to face its back, ask him to touch the opposite shoulder with the arm that is to be aspirated, so as to adduct and internally rotate the shoulder. Feel for the head of the humerus. Keeping the needle horizontal, push it 30° medially into the joint space, from a point just under the postero-inferior border of the acromion (7-15G).

**Anterior route:** this is easier but more hazardous. Feel for the coracoid process just below the clavicle in the space between the *pectoralis major* and *deltoid* muscle. Push the needle into the joint slightly below and medial to the tip of the coracoid process. Slope it laterally 30° and push it backwards, until it enters the loose pouch under the lower part of the shoulder joint (7-15H).

#### EXPLORATION ARTHROTOMY (GRADE 2.4)

Approach the shoulder joint as if you were operating on the upper humerus for osteomyelitis (7-7), and separate the *deltoid* from the *pectoralis major* in the deltopectoral groove. Open the joint and irrigate with warm sterile water. Keep the wound open with a drain into the joint.

**POSITION OF REST.** Put the arm in a sling.

**POSITION OF FUNCTION.** Put the shoulder into a PoP spica in 45° of abduction, with the elbow just anterior to the coronal plane, in 70° of medial rotation so that the hand can reach the mouth.

### (b) The elbow

#### ASPIRATION

Bend the elbow to 90°. Feel for the head of the radius, the olecranon and the lateral epicondyle of the humerus. Using these points of a triangle, push the needle through its centre into the posterolateral aspect of the joint.

#### EXPLORATION ARTHROTOMY (GRADE 2.4)

Make a 3cm longitudinal incision posteriorly in the sulcus between the olecranon and the head of the radius. Go through the skin and fascia, insert a haemostat, and open the joint. Irrigate it with warm sterile water. Keep the joint open with a drain.

**CAUTION!** Stay close to the olecranon, and remember that the posterior interosseous nerve winds round the neck of the radius 3cm distal to its head.

**POSITION OF REST.** Keep the arm in a sling in 90° of flexion.

**POSITIONS OF FUNCTION** depend on whether one or both joints are going to ankylose.

**If the dominant elbow is going to ankylose,** consider the patient's needs. For example, Muslims and many other peoples write and eat with their right hands and use their left hands for toilet purposes. If so, the right elbow should be more flexed than the left.

The dominant elbow will probably be most useful if it is flexed 10° beyond a right angle, with the forearm pronated 45° so that feeding, scratching the nose, and writing are possible. Put it into this position by fitting a collar and cuff.

**If both the elbows are going to ankylose**, arrange their positions so that the dominant arm can reach the mouth. Let the non-dominant elbow fuse in 10° short of full extension, so the hand can reach the anus.

### (c) The wrist

#### ASPIRATION

Feel for the radial styloid; it will show you the line of the joint. Feel for the tendons of *extensor pollicis longus* on the radial side of the 'anatomical snuffbox'. Aspirate on its ulnar aspect, at the level of the wrist joint. Push the needle between *extensor pollicis longus* and the index tendon of *extensor digitorum* into the joint inclining it proximally 45° (7-15A).

#### EXPLORATION ARTHROTOMY (GRADE 2.4)

Flex and extend the wrist, as you feel for the exact line of the joint. Feel for the hollow between the tendons of *extensor pollicis longus* and the index tendon of *extensor digitorum*. Make a 3cm transverse incision, taking care not to cut the cutaneous branch of the radial nerve which runs in the web space of the thumb. Retract the skin edges and expose the joint through a longitudinal incision between the two tendons. Irrigate the joint with warm sterile water.

#### POSITIONS OF REST AND FUNCTION

Keep the wrist in 30° of extension with a volar plaster slab.

### (d) The hand

THE POSITION OF SAFETY is peculiar to the hand and is the position which will minimize stiffness after an injury. Keep the mcp joints nearly fully flexed, the pip and dip joints fully extended. Keep the thumb well forward of the palm in opposition to the fingers, with its pulp about 4cm from them. To maintain this position use aluminium finger splints, plaster slabs, or a boxing glove dressing, as appropriate.

### (e) The knee

#### ASPIRATION

Extend the knee. Push the needle into the suprapatellar pouch 2½cm above the upper border of the patella, from either the medial or the lateral side.

#### EXPLORATION ARTHROTOMY (GRADE 2.4)

With the knee extended, make a 5cm incision 2cm behind the medial edge of the patella and its tendon. Go through the *quadriceps* expansion, longitudinally, and put a curved haemostat into the suprapatellar pouch, under the surface of the patella. Put your finger into the joint and use it to remove the pus. Take a piece of joint capsule for biopsy. Irrigate the joint with warm sterile water. Leave the wound open, or sew up the upper part, and leave a corrugated drain in place.

Dress the wound and apply skin traction, or a plaster backslab. Without one or the other, a painful flexion contracture is likely. Leave the drain in for 4-7 days.

#### POSITION OF REST

Apply skin traction to the lower leg to prevent flexion. Or apply a plaster backslab held on with a crepe bandage.

**If there is already a flexion contracture following septic arthritis**, put the knee in extension traction until it has been corrected. Then apply a cylindrical cast and encourage weight-bearing. With luck, a painless bony ankylosis will develop. If this does not happen, a compression arthrodesis of the knee will be necessary.

#### POSITION OF FUNCTION

Make sure the knee ankyloses in 10° of flexion, so the foot can just clear the ground on walking. Do the same when both knees are ankylosed.

### (f) The ankle

#### ASPIRATION

Find the line of the joint by moving the ankle. Insert the needle into its anterior aspect just medial to the lateral malleolus. Push it backwards and slightly downwards, so that it enters the space in the angle between the tibia and the talus.

#### EXPLORATION ARTHROTOMY (GRADE 2.4)

Start the incision on the anterolateral aspect of the ankle, 5cm above the joint, and continue it downwards 1cm in front of the lateral malleolus to the base of the 4<sup>th</sup> metatarsal, lateral to the extensor tendons of the toes. Divide the superior and inferior extensor retinaculum as far as is necessary, so as to expose the capsule of the ankle joint. Then divide this and open the joint. (This incision will expose both the ankle and the tarsal joints.)

#### POSITION OF REST

Keep the ankle in neutral, without any flexion, extension, inversion, or eversion. Apply a plaster gutter splint.

#### POSITION OF FUNCTION

Keep the ankle neutral and slightly everted. Inversion will produce painful callus under the head of the 5<sup>th</sup> metatarsal on walking.

### **ANKYLOSIS IN THE WRONG POSITION IS A REAL DISASTER!**

## 7.18 Septic arthritis of the hip

An acutely tender hip in varying degrees of flexion, together with fever, suggests infection. An important sign is spasm of the hip muscles. Test for this by rolling the thigh (7-17). If this is acutely painful, suspect that the hip is infected. **If there is septic arthritis or osteomyelitis**, tapping the greater trochanter lightly with your clenched fist will be painful.

If there is deep inguinal adenitis (6.16) or pyomyositis (7.1), it will not. In septic arthritis or osteomyelitis, the epiphysis of the femur may become indistinct, or even absent on a radiograph, but it often reappears. *This is not an indication for its removal!*

#### TWO USEFUL HIP SIGNS

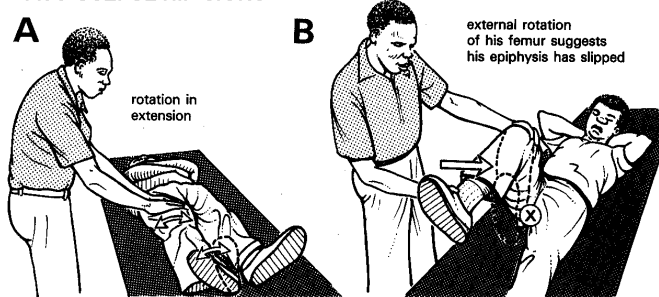


Fig. 7-17 SIGNS IN SEPTIC ARTHRITIS OF THE HIP.

A, lie the patient flat, place your hand on the thighs and try to roll the leg to and fro. A normal hip rolls easily; if it is infected, this will be acutely painful. B, if you flex a normal hip, it will flex without rotation. If it rotates externally into position 'X' as you flex it, the upper femoral epiphysis may have slipped. This can happen spontaneously in teenagers; it also happens in late septic arthritis.

Kindly contributed by John Stewart.

There are 3 operations you may need to perform, but only the 1<sup>st</sup> is common. Be prepared to:

- (1) Drain pus in septic arthritis.
  - (2) Remove the head of the femur, when this has been destroyed as the result of infection.
  - (3) Perform Girdlestone's operation in chronic septic arthritis to remove the head and neck of the femur (7.19).
- Sepsis may also follow after an arthroplasty or hemiarthroplasty. Draining the pus in these cases is just as important; removing the prosthesis is difficult and may not be necessary: it is anyway something for an expert!

If you don't treat septic arthritis of the hip early, any of these things may happen:

- (1) A flexion contracture may develop, which will be a great disability if you let it become permanent. Prevent and treat this in 2 ways.
  - (a) Apply extension (skin) traction to the lower leg. This is very effective prevention, so do it routinely.
  - (b) If a contracture has started to develop, extend the leg by using the prone position if this is tolerated. Few patients, especially children, will do this for long if their bed faces a wall! So make sure the bed faces the centre of the ward.
- (2) The upper femoral epiphysis may slip off the shaft of the femur, and become a dead sequestrum in the hip joint (7-14). Later in the course of the disease there is a useful test to find out if it is slipping. Bend the knee to 90° and then flex the hip (7-17B). If the leg turns to external rotation as you do this, the head of the femur may have slipped. Confirm this by taking a 'frog-leg view' radiograph. If a sequestrum has formed, open the hip joint and remove it.
- (3) The hip joint may be destroyed. When this happens, there are 2 choices:
  - (a) Fuse the hip in the position of function by applying a spica for 3 months or more.

(b) Remove the remains of the partly destroyed head and neck of the femur by Girdlestone's operation (7.19). This will result in a much more comfortable joint with some movement.

(4) The infection may extend into the acetabulum and involve the bones of the pelvis. When this has happened, there is little you can do, except drain the pus. The osteitis usually settles.

#### THE ANTERIOR APPROACH TO THE HIP

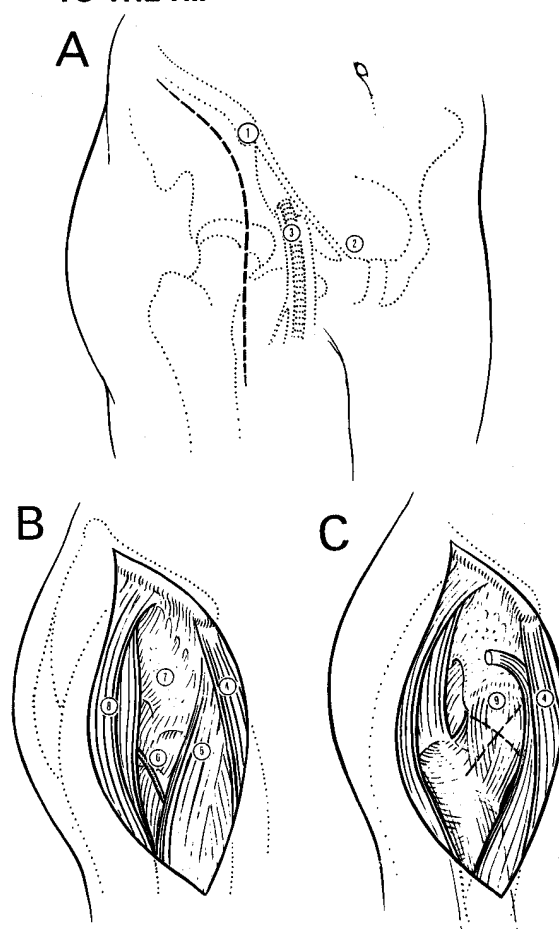


Fig. 7-18 ANTERIOR APPROACH TO THE HIP.

A, incision. B, retract the muscles. C, prepare to incise the capsule. (1) anterior superior iliac spine. (2) pubic tubercle. (3) femoral vein, artery and nerve from medial to lateral in this order. (4) sartorius. (5) rectus femoris. (6) ascending branch of the lateral circumflex vessels. (7) exposed surface of the ilium. (8) gluteus medius and tensor fascia lata. (9) incision in the capsule.

#### ASPIRATION

The hip lies immediately behind the mid-inguinal point. Use a thick lumbar puncture needle. If you can, do this under ultrasound guidance. If the anterior approach fails, try the posterior one.

**Anteriorly**, feel for the femoral artery 2.5cm below the inguinal ligament midway between the anterior iliac spine and the pubic tubercle. Insert the needle 1.5cm lateral to the artery (and thus lateral to the femoral nerve). If you cannot feel the femoral artery, insert the needle 2.5cm below and 2.5cm lateral to the mid-inguinal point.

Push the needle in, inclining it 15° medially and 15° superiorly. This will aim it at the joint directly behind the mid-inguinal point. Push it through the capsule into the joint. Aspirate. If you don't find pus, advance it into the cartilage. To prove that the needle is in the cartilage, rotate the thigh internally a little. This should move the adaptor of the needle medially. Withdraw it slightly to remove it from the cartilage, and aspirate. If necessary, alter its position and try again, if need be several times.

**Posteriorly**, use the prone position. Feel for the posterior inferior iliac spine and the centre of the greater trochanter. Insert your needle midway between these two points into the hip joint.

#### EXPLORATION ARTHROTOMY (GRADE 2.5)

Approach the hip anteriorly or posteriorly. If you can safely anaesthetize a prone patient, the posterior approach is easier because it allows better drainage, but the anterior approach is safer in children.

#### ANTERIOR APPROACH

**POSITION.** Use the supine position, but with a tilt to the opposite side by putting a sandbag under the affected hip.

**INCISION.** Cut from the mid-point of the iliac crest to the anterior-superior iliac spine. Extend the incision distally down the leg for 10-12cm. Divide the superficial and deep fascia. Use a periosteal elevator to separate the *gluteus medius* and *tensor fascia lata* from the iliac crest. Continue the dissection distally between the *tensor fascia lata* posterolaterally, and the *sartorius* and *rectus femoris* anteromedially. Divide the ascending branch of the lateral circumflex vessels between ligatures.

Insert 2 bone levers on each side round the upper shaft of the femur and retract the muscles. You will now see the thickened, oedematous, boggy capsule of the hip joint. Check that it is the joint by aspirating. Now open the joint with a cruciate incision. Take a biopsy. Ask a theatre assistant to grasp the patient's ankle and externally rotate the hip. You will see the head of the femur moving inside the acetabulum. If you want better access to the joint, insert levers round the neck of the femur. If you suspect osteomyelitis, drill at least 4 holes into the neck and upper shaft of the femur. Irrigate the joint with warm sterile water. Insert a suction drain from the joint to the surface, and leave it in for 5-7 days. *Don't suture the capsule.* Bring the muscles together lightly with a few '0' absorbable sutures. Close the fascia over the iliac crest. Close the skin with 2/0 monofilament.

**POST-OPERATIVELY**, apply 2-5kg of skin traction up to the mid thigh, with the leg in 1-15° of abduction and minimal flexion. Raise the foot of the bed.

## THE POSTERIOR APPROACH TO THE HIP

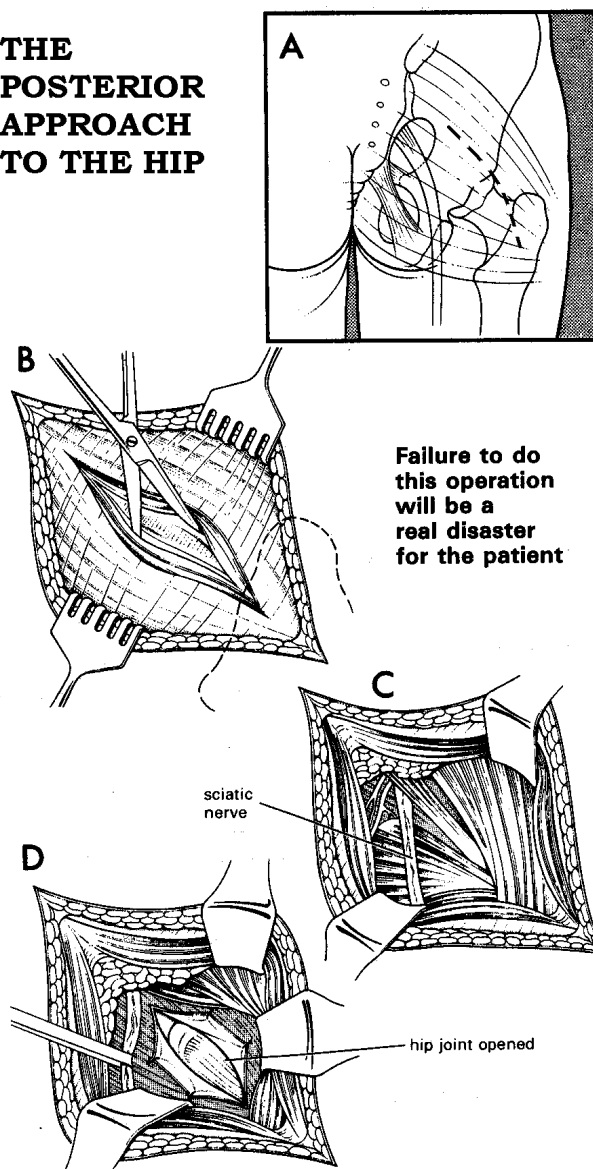


Fig. 7-19 POSTERIOR APPROACH TO THE HIP.

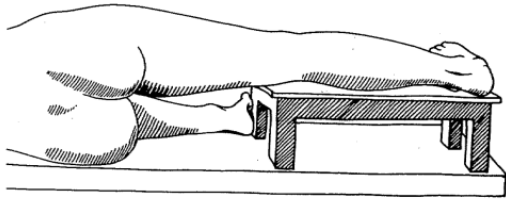
A, incise the *gluteus maximus*. B, separate its fibres. C, be careful not to injure the sciatic nerve. D, incise the hip joint.

#### POSTERIOR APPROACH

**POSITION.** Either use the prone position (needing GA and intubation) with a sandbag under the affected hip, or use the lateral position (needing GA alone or ketamine) with the affected hip uppermost (7-20).

**INCISION.** Find the tip of the great trochanter. Cut from its anterior margin obliquely up towards a point on the iliac crest 6cm in front of the posterior superior iliac spine, and down vertically for 5cm. Cut through the skin and superficial fascia. Separate the fibres of the *gluteus maximus* using your index finger and the end of a curved haemostat, until you meet the capsule of the hip joint. Open the incision with retractors.

## LATERAL POSITION FOR POSTERIOR APPROACH TO THE HIP



**Fig. 7-20 LATERAL POSITION FOR POSTERIOR APPROACH TO THE HIP.**

The affected limb rests horizontally upon a simple platform. The unaffected limb either lies beneath the platform, or, preferably, is flexed at the hip and knee in order to stabilize the pelvis. Place a pillow on the table to protect the leg from its hard edges!

After Crawford Adams J, *Standard Orthopaedic Operations*. Churchill Livingstone 1976 p.25, Fig 10.

**If you find pus in the muscles of the buttock, before you reach the hip**, this is pyomyositis. If you go further and open a normal hip through an abscess in the muscles, you will probably infect it, *so stop!*

Ask an assistant to take hold of the ankle and rotate the hip internally, so as to increase the space between the trochanter and the acetabulum. Make a small incision in the distended capsule of the hip joint and widen it with a haemostat. Irrigate the joint with warm sterile water.

### CAUTION!

(1) The sciatic nerve leaves the buttock halfway between the greater trochanter and the ischial tuberosity. There is no need to incise or dissect this far medially.

(2) The capsule of the hip joint is only 2cm wide between the posterior aspect of the greater trochanter and the posterior margin of the acetabulum.

**If the upper femoral epiphysis has slipped and is forming a sequestrum**, remove it. You will need to modify the incision by carrying it down to the greater trochanter. Remove the loose head of the femur with large bone forceps, and as much of its neck as is necrotic.

POST-OPERATIVELY, reduce the tendency of the hip to slide proximally by using traction for 6wks, while fibrous tissue forms to limit movement. The result will be an unstable hip, needing a crutch for support, but it should be pain-free and walking will be possible.

### POSITION OF REST FOR THE HIP

If you are sure that the painful hip is only temporary, rest it in moderate flexion and 15° of abduction. In this position the legs are comfortably spread apart. Hold the hip in this position with skin traction. To produce abduction, bring the cord holding the weight to the end of the bar at the foot of the bed. If necessary, make sure it stays there by moulding a plaster pulley on the bar. Or, have a detachable bar with notches at suitable places, which you can tie to the foot of the bed. Or, put both the legs into abduction.

### POSITION OF FUNCTION

Put the hip in a minimum amount of flexion, preferably none, 5° of abduction, and no rotation. *However, don't apply a spica with the hip in the position of function*, especially in a child. Otherwise, when you remove it, that spasm has rotated the pelvis anteriorly, and there is too much flexion. Instead, immobilize the hip in a spica in complete extension and 15° of abduction. When you remove the spica, you will find that it has gone into 15° of flexion, which is where you want it to be.

**RELIEF OF SPASM.** In a child, use diazepam, and apply up to 1/7<sup>th</sup> of the body weight of extension (skin) traction. This will relieve the spasm of the muscles, and will prevent development of a flexion contracture.

## 7.19 Girdlestone's operation (Hip excision arthroplasty)

Most procedures for infected hips are needed by children. An excision arthroplasty may help an adult whose hip has been partly destroyed by infection, avascular necrosis or a painful non-united femoral neck fracture. Walking will be less painful if what is left of the head and neck of the femur is excised, so as to allow the upper end of the femur to bear on scar tissue on the underside of the ilium. A false joint will develop, the leg will be short and a stick and a shoe-raise will be necessary but there will probably be very little pain.

Girdlestone's operation is a salvage procedure to relieve pain when an arthrodesis or, exceptionally, a prosthesis is impractical. It is inelegant and old-fashioned, and is not as good as an arthrodesis or a hip prosthesis, *but better than nothing*.

### INDICATIONS

Walking painfully as the result of:

- (1) Previous septic or tuberculous arthritis, which is now inactive.
- (2) Aseptic necrosis of the head of the femur.
- (3) A longstanding non-united fracture of the femoral neck.
- (4) An infected hip prosthesis.
- (5) A joint extensively damaged by a gunshot wound.

**PREPARATION.** Cross-match 2 units of blood. Use the lateral position with the affected hip uppermost (7-20).

### INCISION (GRADE 3.5)

Reach the hip joint by the posterior approach (7.18) extending the incision down the leg for 10cm. Retract the sciatic nerve well medially. Incise the capsule of the patient's hip joint widely to expose the head and neck of the femur and the remainder of the greater trochanter.

You will find that removing the head is easier if you excise part of the upper rim of the acetabulum. Dislocate the hip by lateral or medial rotation of the femur. Curette all necrotic and infected bone from inside. Cut the femoral neck right down to its base from greater to lesser trochanter, and smooth it by chiselling away all sharp edges (7-21).

## EXCISION ARTHROPLASTY OF HIP (GIRDLESTONE OPERATION)

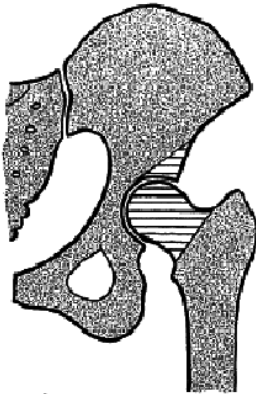


Fig. 7-21 EXCISION ARTHROPLASTY OF HIP (GIRDLESTONE OPERATION).

Remove this amount of bone (*shaded*).

After Crawford Adams J, *Standard Orthopaedic Operations*. Churchill Livingstone 1976 p.234, Fig 161.

To help reduce lateral rotation deformity, you can detach the *psaos* tendon from its insertion on the lesser trochanter and bring it round the front of the femoral shaft. Suture it to the tissues on the posterolateral side of the femur, so that it will act as a *medial* rather than lateral rotator of the thigh.

Fill the space created by removal of bone by a wad of *gluteus medius* muscle and sew back the edges of the incised *gluteus maximus*. If there is little active infection, insert a suction drain. If you find the bone seriously infected, leave the wound partly open with 1-2 rubber drains.

POST-OPERATIVELY, to prevent shortening, apply 3-10kg of skeletal traction using a pin through the tibia with the hip in 20-30° of flexion for 4-6wks. This will not be necessary if the hip is already fibrotic. In the elderly, if you are worried about a prolonged period in bed (because of pneumonia, bedsores etc), encourage walking with a stick after this time.

**CAUTION!** Try to prevent proximal displacement of the femur. This will prematurely seal off the area and defeat the purpose of the operation, which is to allow free drainage when there is active infection.

### DIFFICULTIES WITH EXCISION HIP ARTHROPLASTY

**If the head of the femur is not necrotic, or the hip is ankylosed, don't proceed with the operation!**

**If there is a prosthesis or cement *in situ*,** remove these with a hammer, chisel and osteotome: this may present formidable difficulty, but you must get all the infected cement out.