

# 8 Pus in the hands & feet

## 8.1 The infected hand

A badly infected hand can be a real disaster. Some infections arise spontaneously, others follow quite minor injuries, or even a seemingly trivial scratch. They are particularly common in diabetics, HIV disease and leprosy (32.18). The best prevention is an early and thorough toilet of all hand wounds, which is quite a minor procedure. The great danger of late or inadequate treatment is a stiff finger, which is a great disability and may ultimately need amputation (35.4).

Antibiotics may be effective in an early case, and may prevent a serious lesion spreading. *A careful wound toilet and early drainage is much more important.*

There are many spaces in the hand where pus can collect; each type of abscess has its own signs and incisions. *These spaces are not rigidly defined;* some run into one another, and more than one may be infected at the same time (8-1), so don't be dismayed by their apparent complexity. The common places for pus to collect are in the pulp spaces of the fingers (8.5), and in the web spaces (8.7). Even after pus has formed, recovery should be complete if treatment is correct, provided that tendon sheaths are not involved.

### PUS IN THE HAND IS COMMON AND SERIOUS!

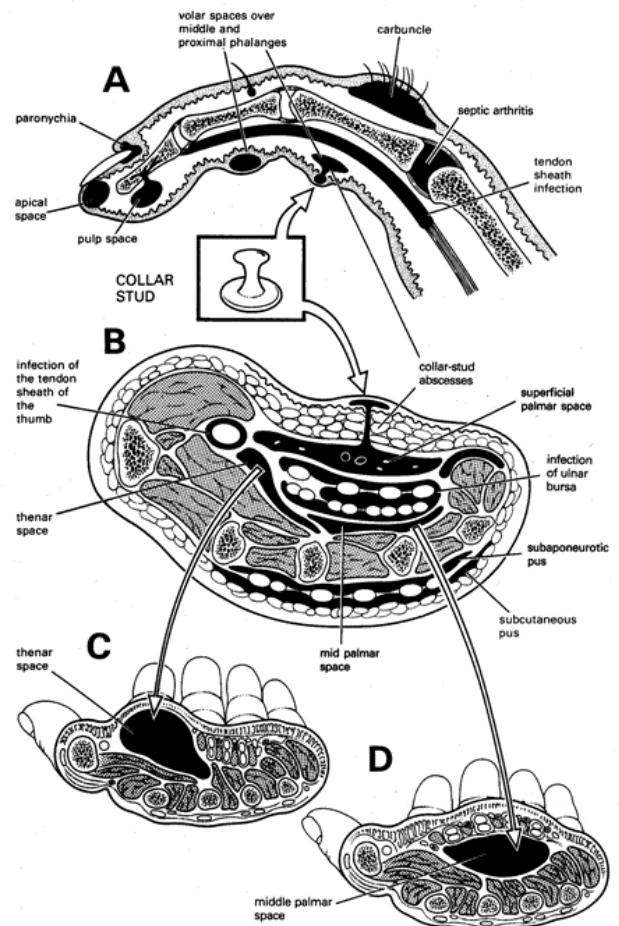
One difficulty is knowing when to incise an infected hand. Pus is so tightly trapped in the spaces of the hand that you cannot use fluctuation as a sign that it is present. A good rule to remember is that, if pain in the hand prevented sleep the previous night, or there is a suspicion of a foreign body, it needs incising.

When you operate:

- (1) *Don't cut the digital nerves:* remember that they run on the radial and ulnar aspects of the fingers just anterior to the tips of the finger creases (8-6D).
- (2) *Don't cut through a superficial abscess into the flexor sheaths underneath,* or you may infect them. These are in the greatest danger where they are nearest to the surface, under the flexor creases of the fingers. So *don't incise the palmar surface of a finger proximal to its distal flexion crease,* unless you are deliberately draining an infected tendon sheath.
- (3) When you drain pus, be sure to remove the granulation tissue that surrounds it, so that the wall of the abscess is clean.
- (4) Use a bloodless field whenever you can, so that you can see the anatomy clearly.

**DON'T WAIT FOR FLUCTUATION  
INCISE THE HAND USING A TOURNIQUET**

## PUS IN THE HAND



**Fig. 8-1 THE MANY PLACES WHERE PUS CAN COLLECT IN THE HAND.**

After Rintoul RF (ed) Farquharson's Textbook of Operative Surgery, Churchill Livingstone 7<sup>th</sup> ed 1986 Fig. 302; Milford, L, Hand Infections, in Edmondson AS, Crenshaw AH (ed), Campbell's Operative Orthopaedics, CV Mosby Fig. 3-357. Both with kind permission.

### WHERE IS THE PUS?

Feel carefully for the point of greatest tenderness by probing with a matchstick.

**If the whole hand is swollen,** the pus is probably in the mid-palmar space, or in a flexor tendon sheath, especially if movement of the little and ring fingers is impossible.

**If the greatest swelling is over the web of the thumb,** there is probably pus in the thenar space, especially if the index finger is held flexed, and its movement or the thumb's is impossible.

**If: (1) the whole finger is swollen and tender, (2) there is no obvious sign of the pus pointing, and (3) any movement of the finger is exquisitely painful,** there is probably a tendon sheath infection.

**If all the fingers, especially the 5<sup>th</sup>, are held semi-flexed and rigid,** suspect that the tendon sheaths in the ulnar bursa are infected.

**Check if the terminal phalanx is infected (8.5).**

**If there is lymphangitis, lymphadenitis, or fever,** the infection is spreading. If pus is present, incise the hand under antibiotic cover, and continue after the temperature and pulse have become normal.

*CAUTION!* Pus is much more likely to be present on the palmar surface than on the dorsum, so *don't be misled by swelling on the back of the hand.* The commonest cause of a swollen dorsum is a web space infection.

SPECIAL TESTS. Screen for diabetes and HIV.

**TREATMENT**

**RAISE THE HAND** for comfort and to promote healing. In less severe infections, raise the arm in a St. John's sling. In more severe cases, such as a tendon sheath infection, *make sure you rinse the tendon sheaths (8.12),* and admit the patient and raise the hand in a roller towel.

**ANTIBIOTICS** are necessary if the infection is spreading: treat with metronidazole and cloxacillin or chloramphenicol. *Don't forget to add an analgesic.*

**INDICATIONS FOR INCISION**

*Don't try to treat an infected hand by aspiration only.* Base your decision to incise on:

- (1) The presence of acute local tenderness: this shows that pus is present and where it is pointing.
- (2) The length of the history, particularly if symptoms are worse after 48h.
- (3) The severity of the swelling.
- (4) The nature of the pain, especially if throbbing pain prevents sleep.

**ANAESTHESIA** must be adequate. For any but the most minor infection, avoid LA close to the infection, because this will only spread it and increase the swelling.

**If the infection is in the distal 2/3 of the finger or thumb,** you should use a distal palmar block *without* adrenaline. For all other hand infections, use an axillary block, or an IV forearm block, or ketamine, or GA.

A **TOURNIQUET** is essential in all but the most superficial infections, because a bloodless field makes the operation easier (3.4). *Don't exsanguinate the arm with an Esmarch bandage,* because it may spread the infection.

**If the pus is in the distal segment,** wrap a rubber catheter twice round the base of the finger or thumb, and clamp it with a heavy haemostat.

**If the pus is anywhere else,** apply a pneumatic tourniquet (3.4).

**INCISING, DESLOUGHING AND DRAINING THE HAND (GRADE 1.3)**

Clean the skin with antiseptic. Incise where pus points, and take care you don't cut the digital nerves or spread superficial pus deeply (8-6). When you extend an incision, do so in a skin crease. If necessary, jump from one crease to another by making a Z-shaped incision. Remove skin that is

already dead. If necessary, extend an incision to explore the whole abscess cavity, and remove deeper dead tissues.

**If more than one space is infected,** adapt your incision(s) accordingly. For example, if the mid-palmar space, several web spaces and the tendon sheaths are infected, you may need to make several incisions (8-5). As soon as you are through the skin, insert a haemostat, open it, and explore the abscess cavity (Hilton's method). Culture the pus.

**If there are no vulnerable structures such as periosteum, nerves or tendon sheaths nearby,** scrape away the lining of the abscess with curette or a swab. If there are vulnerable structures nearby, be more cautious, and only use a swab.

Drain the abscess by putting a piece of rubber glove into it. Or, leave a piece of petroleum jelly gauze between the wound edges.

*CAUTION!*

(1) *Don't cut the nerves (8-6).*

The digital nerves run near the anterolateral margins of the fingers. So cut either near the middle of the palmar surfaces of the fingers, or on their lateral surfaces fairly posteriorly at the apex of the finger creases. The muscular branch of the median nerve comes off the main trunk just distal to the tuberosity of the scaphoid and curves round into the thenar muscles.

(2) *Don't pack the wound tightly.*

**CONTROL BLEEDING** after removing the tourniquet by raising the arm and pressing firmly on the wound for 5mins without interruption.

**POST-OPERATIVELY,** be sure to elevate the hand, until pain and swelling subside: this is an important way of reducing stiffness. Rapid resolution of inflammatory oedema is more important than early movement in reducing stiffness. Wrap the wound with plenty of gauze, and use the dressings to splint it in the position of safety. Inspect the wound daily and wash with water bd.

**If the infection was extensive,** check for residual infection or necrotic tissue which may need further debridement.

*CAUTION!* Start active movements as soon as pain has subsided.

**RAISE AN INFECTED HAND  
STIFF FINGERS RESULT IN POOR FUNCTION****8.2 Subcutaneous hand infection**

The skin and subcutaneous tissue can be infected anywhere in the hand. Pulp infections and paronychia are merely subcutaneous infections at the tip of a finger, the latter at the nail border. If there is pus under the keratinized layers of the epidermis, strip these off, and see if you can find the hole through which it has tracked from a deeper abscess underneath. An abscess near the surface may communicate with pus deep inside the hand through a narrow opening, forming a 'collar-stud abscess' (8-1). So, whenever you find a superficial abscess, look for the passage which might be joining it to a deeper abscess.

Carbuncles (6.4) may form in the hair follicles on the back of the fingers and hand. *Antibiotics will not cure this, so desloughing is necessary.*

### DON'T BE MISLED BY A COLLAR-STUD ABSCESS

#### INFECTION AROUND THE NAIL

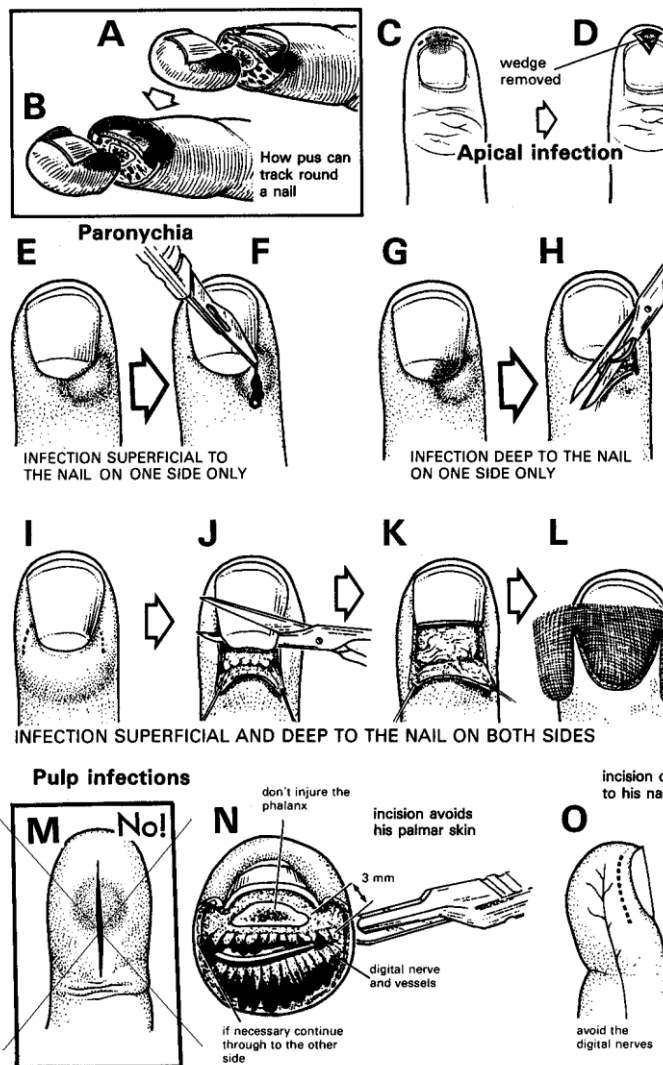


Fig. 8-2 INFECTION AROUND THE NAIL.

There can be pus apically (C-D), on the side of the nail, either superficial (E-F), or deep (G-H). It may track all round the nail (A-B) so that the proximal part of the nail needs excising (I-L). *Avoid incising the ball of the finger (M) unless pus is already pointing there.* N-O, if infection is already present in several of the compartments of the pulp, make a lateral incision. Keep your incision away from the palmar skin, and *not more than 3mm from the edge of the nail.*

*N.B. In N, don't cut the end of the finger off! This is a schematic cross-section only!*

*A,B, after Flatt AB, Functional Anatomy, Fig. 14.2 with kind permission.*

### 8.3 Apical finger space infection

The apical space lies between the distal part of the nail and the bone of the distal phalanx. It may be infected when a splinter digs under the nail. The finger is painful, but there is little swelling. Tenderness is greatest at or just under the free edge of the nail. Cut a small 'V' out of the edge of the nail over the point of greatest tenderness (8-2C,D).

Remove the full thickness of the skin as a small wedge, and drain the pus.

### 8.4 Paronychia

Paronychia is an infection beside or proximal to the nail. Pus may track round it (8-2A-B), either superficial to the nail (8-2E-F), or deep to it (8-2G-H). Early antibiotic treatment may abort the infection, but you usually have to drain pus.

**If the pus is superficial to the nail on one side only**, incise it by angling the knife away from the nail to avoid cutting the nail bed (8-2E-F). If there is only a little swelling, you may be able to drain the pus simply by lifting the skin over the nail with a blunt needle: this doesn't even need LA.

**If the pus lies under one corner of the nail**, reflect a little flap and remove that corner only (8-2G-H).

**If pus has tracked to the other side of the finger under the nail**, make a second incision there, retract the flap, excise the proximal  $\frac{1}{3}$  of the nail, pack the wound open and drain it (8-2I-L).

**If the infection fails to resolve, or the nail becomes indurated and red**, suspect a fungal infection, and examine scrapings microscopically. If you find fungi, remove the nail and apply wet dressings, or a topical antifungal agent, such as gentian violet.

### 8.5 Finger pulp space infection

This is the commonest hand infection; pus more often gathers in the finger tips than anywhere else in the hand. The pulp of a finger is divided into many small fatty compartments by strands of fibrous tissue which run from the skin to the periosteum of the terminal phalanx. A sheet of fibrous tissue runs from the distal flexor crease to the periosteum, and so separates the pulp space from the rest of the finger. There is little room for swelling, so that infection causes a throbbing pain early. Pus from the pulp can track through to the skin outside, or through the periosteum, causing osteomyelitis of the distal phalanx. Its epiphysis is supplied by a separate artery, so this usually survives the infection. Tenderness is maximal over the ball of the finger tip.

## PULP INFECTION

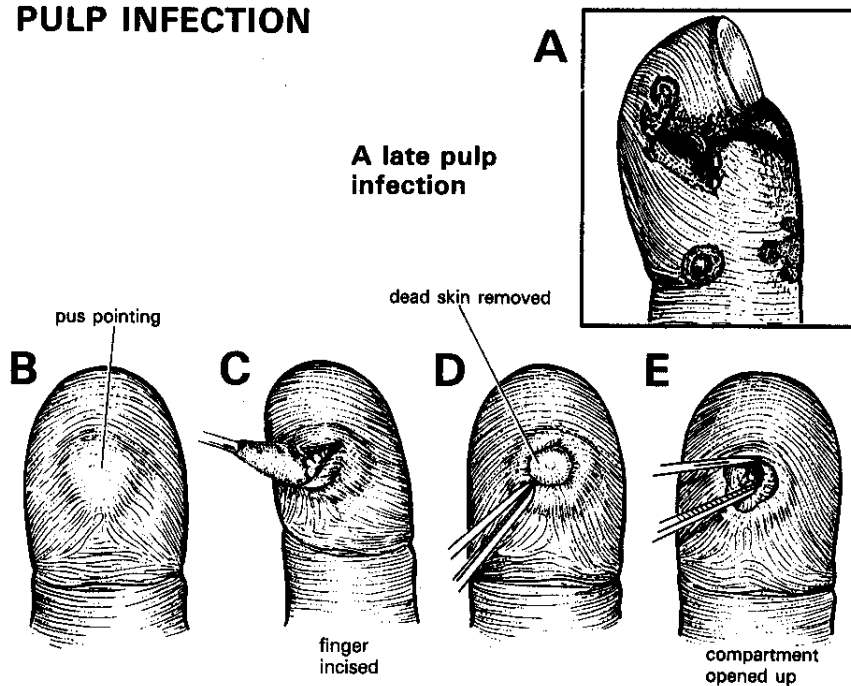


Fig. 8-3 PULP INFECTIONS. A, neglected pulp infection: much of the finger tip is already destroyed, and pus is starting to discharge spontaneously. B, if pus is already pointing, make a cross-shaped incision. C, swab away the pus. D, remove any dead skin. E, open up the infected pulp compartment. If it is not pointing and several spaces are infected, open up the finger tip from the side (8-2N).

**If the abscess is in the distal pulp, and is already pointing to its centre**, drain it by making a cross-shaped incision, or by removing a small circular or elliptical segment of skin over the abscess (8-3B-E). The incision will heal to leave a small punctate scar.

**If the abscess is deep, is not pointing, and appears to extend into several compartments**, make a J-shaped lateral longitudinal incision close to the bone,  $\leq 3$ mm in a palmar direction from the free edge of the nail. Keep your knife away from the palmar skin (8-2N-O), and avoid the tip of the finger. Remove pus and slough, and lightly pack the wound with gauze. *Don't suture the incision.* Change the dressing after 2 days.

**If the infection has been neglected, so that the whole terminal segment of the finger is swollen**, continue the incision over the end of the finger and round to the other side. Divide the vertical septa and let the wound gape open. Dress it as above.

### CAUTION!

- (1) *Don't incise the tips of the fingers, or the palmar surfaces of the distal phalanges*, unless pus is already pointing there, because pressure on the scar may be painful.
- (2) Any incision, other than those described, is likely to be a painful nuisance later, especially if you carry it towards the palmar surface.
- (3) *Don't damage the periosteum.*
- (4) Check for a collar-stud abscess (easy to see if you have used a tourniquet to provide a bloodless field).

## DIFFICULTIES WITH FINGER PULP SPACE INFECTION

**If the infected finger continues to discharge for >2wks**, suspect osteomyelitis (8.16) or the presence of a foreign body. Obtain a radiograph. When this shows a foreign body, or a sequestrum that has separated, remove it.

In a child, the distal phalanx will regenerate under its periosteum. In an adult, the result will be an ugly curved nail and a short terminal phalanx.

## 8.6 Infection on the volar surface of the middle or proximal phalanx

Pus sometimes collects on the volar surfaces of the fingers, superficial to the tendon sheaths (8-1A). The spaces where it forms are separated from one another by the fibrous septa which run dorsally from the flexor creases of the fingers. The proximal

space in each finger communicates with the web spaces in the palm. Pus may collect under the epidermis or under the deep fascia, and is less likely to remain localized than in a terminal phalanx.

The swollen, tender, indurated finger remains semi-flexed. Trying to straighten it is acutely painful. Explore the finger and rinse the infected space abundantly with sterile water, using a cannula. Drain pus from a volar space through a transverse incision over the point of greatest tenderness.

If the tendon sheath is infected, rinse it out thoroughly by making incisions c.2-3cm apart (8.12). *Take great care not to cut into the tendon underneath or to damage the digital vessels or nerves* (8-6G). Use a tourniquet to provide a bloodless field.

### EXPLORE A TENDON SHEATH BUT DO NOT OPEN A JOINT UNLESS IT IS INFECTED

## 8.7 Web space infection

Three spaces, filled with loose fat, lie between the bases of the fingers in the distal part of the palm. They lie just proximal to the deep transverse ligaments, near the mcp joints. Pus more often gathers here than anywhere else in the hand, except in the pulp spaces of the finger tips. It gathers mostly near the palmar surface, but it may track:

- (1) posteriorly towards the dorsum,
- (2) along a lumbrical canal into the mid-palmar space,
- (3) across the front of a finger into a neighbouring web space, or
- (4) distally into the finger.

Pain and swelling may be so great that presentation is before much pus has formed. The back of the hand is swollen (8-5D).

If infection is severe, the fingers on either side of the web separate: a very useful sign. The point of maximum tenderness is on the palmar surface of the web, and may extend a short way into the palm. Although you may suspect a web space infection, it is usually difficult to exclude an infected tendon sheath.

Make a V-shaped incision between the fingers (8-5).

If pus is pointing into the palm, pass a probe proximally from the incision you have just made in the web space up into the palm. Its tip should underlie the place where the pus is pointing. Make a 2<sup>nd</sup> incision there. Scrape the walls of the abscess cavity free from granulation tissue. If necessary, divide some strands of the palmar fascia.

## 8.8 Superficial palmar space infection

When pus collects in the superficial palmar spaces of the hand, it does so under the palmar fascia. Sometimes, it tracks superficially and forms a collar-stud abscess under the superficial layers of the epidermis (8-1B).

If you can see pus under the epidermis, remove it and look for a track leading deeper into the hand.

If you cannot see any pus, make a small transverse incision over the point of maximum tenderness, in the line of the nearest skin crease. Probe the abscess cavity. If you find an opening leading to a deeper collection of pus, enlarge it. Scrape infected granulations from the wall of the cavity.

### THE THENAR AND THE MIDDLE PALMAR SPACES

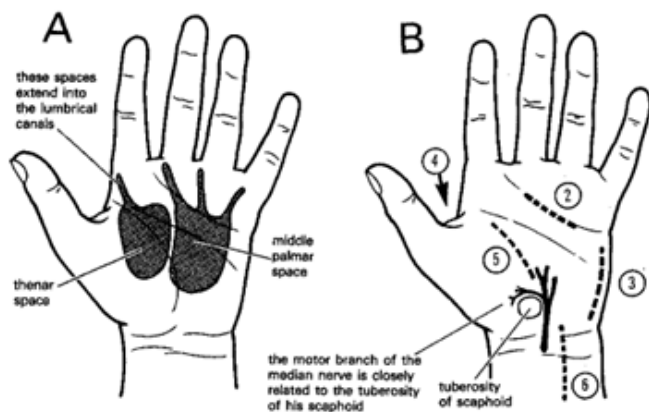


Fig. 8-4 THE THENAR (RADIAL) AND THE MID-PALMAR SPACES lie deep to the flexor tendons, between them and the fascia covering the metacarpals and *interossei*. They communicate with the lumbrical canals. Incise the mid-palmar space in the middle 1/3 of the distal (or proximal) palmar crease (incision 2), or along the ulnar border of the hand (incision 3). Incise the thenar space in the web between the thumb and the index finger (incision 4), or along the thenar crease in the palm (incision 5). Beware of the motor branch of the median nerve!

## 8.9 Mid-palmar space infection

This is the most important space in the hand, and is frequently infected in leprosy patients (32.18). It lies deep to the flexor tendons and lumbricals, and between them and the fascia covering the *interossei* and metacarpals. It is separated from the thenar space by a fibrous septum which extends from the middle metacarpal towards the palmar fascia. Infection reaches this space from a lumbrical canal, or from an infected tendon sheath.

The hand is so grossly swollen that it looks like a blown-up rubber glove. The normal hollow of the palm is obliterated, and the dorsum of the hand is swollen. Movement of the middle or ring fingers is impossible. The *interossei* are surrounded by pus and paralyzed, so that holding a piece of paper between the extended fingers is impossible.

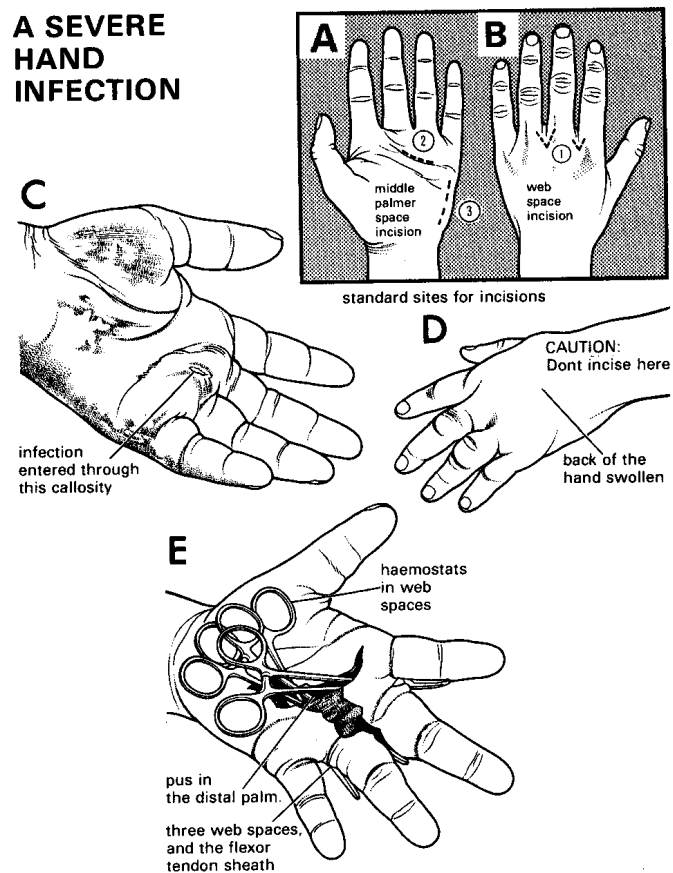


Fig. 8-5 SEVERE HAND INFECTION.

This started as a web infection which spread to the mid-palmar space. A, the standard site of incisions for a middle palmar space infection (incisions 2 and 3), and B, for web space infections (incision 1). In this patient these incisions had to be modified. C, callosity through which infection entered. D, although the back of the hand was swollen, swelling was due to secondary inflammatory oedema only. E, pus found in the distal palm, the 3 web spaces, and the flexor sheaths. Drain the spaces and excise necrotic tissue. After Milford, L. *Hand Infections*, in Edmondson AS, Crenshaw AH (ed), *Campbell's Operative Orthopaedics*, CV Mosby Fig. 3.355-6 with kind permission.

The mid-palmar space communicates through the carpal tunnel with a space deep to the flexor tendons in the forearm (the space of Parona). If there is pus there, you may be able to detect fluctuation between it and the pus in the palm.

*N.B. Always use a tourniquet.*

Make a transverse incision (incision 2) in the middle  $\frac{1}{3}$  of the distal or proximal palmar creases or wherever fluctuation is maximal. Enter the middle palmar space on either side of the flexor tendon of the ring finger. Or, enter it through an incision along the ulnar border of the hand, passing between the 5<sup>th</sup> metacarpal and the hypothenar muscles (incision 3). As soon as you are through the skin, use blunt dissection (Hilton's method) in the line of the tendons and nerves (8.13).

#### CAUTION!

(1) *Don't make your initial incision deeper than the palmar fascia.* Push a blunt instrument through it to free the pus underneath. You can then see clearly to open up the space more by a combination of sharp and gentle blunt dissection. (2) *Don't cut the digital nerves or vessels, the flexor tendons, or the lumbrical muscles.*

**If there is pus in the space of Parona,** drain it through a longitudinal incision (8-6A: incision 6) on one side of the *palmaris longus* tendon (absent in 5% of people), taking care *not to injure the median and ulnar nerves or the radial and ulnar vessels.* *Don't incise the dorsum of the hand* (8-5D).

## 8.10 Thenar space infection

The thenar space (8-1B,C) is sometimes infected because of a penetrating wound. It lies underneath the palmar fascia, and is bounded dorsally by the transverse head of the *adductor pollicis*. On its ulnar side a fibrous septum divides it from the mid-palmar space. The thenar eminence is grossly swollen, and the thumb is abducted.

Drain the thenar space over the point of greatest tenderness through a curved incision in the web between the thumb and index finger, parallel to the border of the first *dorsal interosseous* muscle, on the dorsal edge of the hand (8-6C: incision 4). Or, drain it through an incision along the thenar crease in the palm (8-6A: incision 5). Insert a haemostat deep into the abscess, and open it. You will usually find that it is walled off from the muscles of the thumb.

**CAUTION!** Remember the course of the sensory and motor branches of the median nerve which lie within the thenar muscles. These are in less danger from incision 4 (8-6C) than from incision 5 (8-6A).

### THE COMMONEST CAUSE OF SWELLING ON THE DORSUM IS INFECTION IN THE PALM

## SOME INCISIONS FOR HAND INFECTIONS

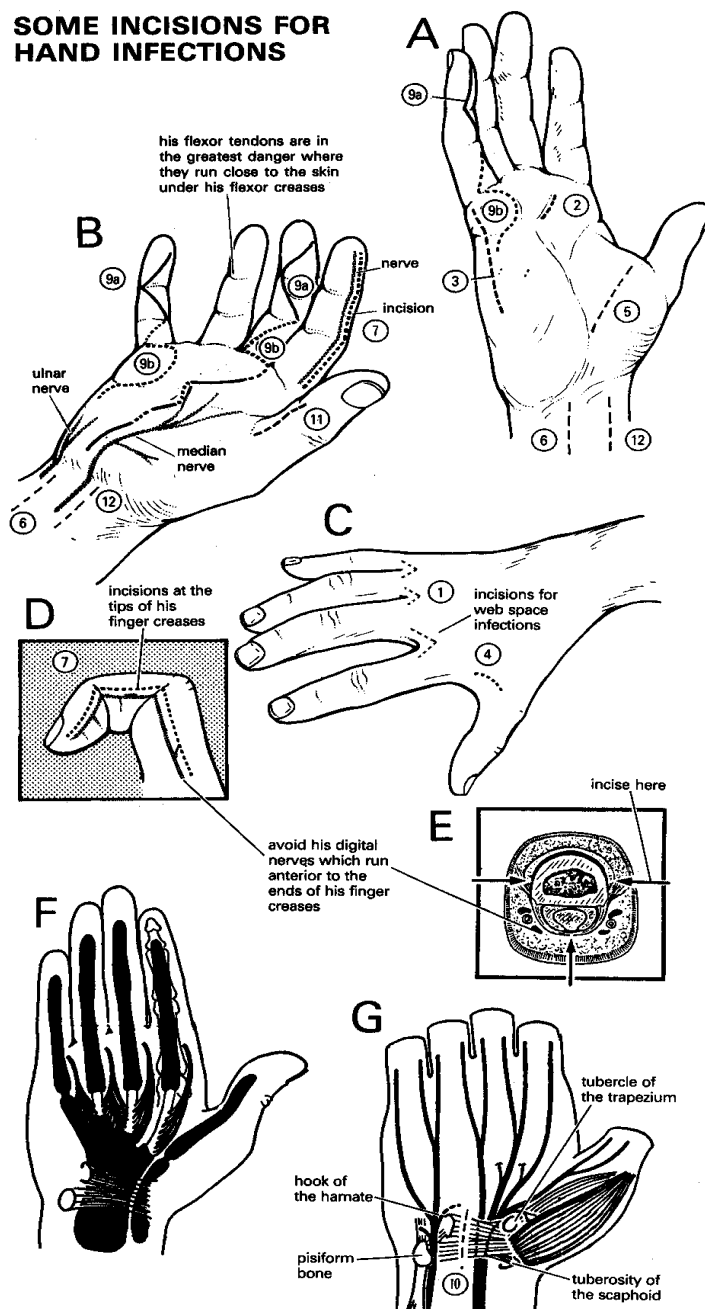


Fig. 8-6 INCISIONS FOR HAND INFECTIONS.

A-D, incisions for more serious hand infections: Incision 1 for web space infections. Alternative incisions 2,3 for a mid-palmar space infection. Alternative incisions 4,5 for a thenar space infection. Incision 6 for pus in the space of Parona (proximal to the flexor retinaculum and deep to the flexor tendons). Incision 7 for mild tendon sheath infection. Incision 9; 9a the 1<sup>st</sup> part, and 9b the 2<sup>nd</sup> part if necessary for more serious infections. Incisions 11 or 12 drain the radial bursa. E, cross-section of the finger. F, tendon sheaths, radial and ulnar bursae, lumbrical muscles, and flexor retinaculum. G, incision 10 for dividing the flexor retinaculum.

On the ulnar side of the retinaculum, the palpable landmarks are the pisiform and the hook of the hamate. On the radial side, you can feel the tubercle of the scaphoid and, more deeply, the tuberosity of the trapezium. The digital nerves are at the 'edges' of the palmar surfaces, so *don't incise there*. Either incise towards the middle of the palmar surfaces or laterally towards the dorsum as shown by the arrows. Incisions for the finger tips are shown in 8-2,3. Some infections don't have fixed incisions (the volar surfaces of the proximal and middle phalanges, the superficial palmar space, and the dorsum of the hand). E-F, after Basmajian, JV, *Grant's Method of Anatomy*, 9<sup>th</sup> ed 1975. Williams & Wilkins, with kind permission.

## 8.11 Dorsal hand and finger infection

Infection almost anywhere in the hand makes the dorsum swell, but pus seldom collects there. On the rare occasions when it does, it is usually subcutaneous, and only occasionally in the subaponeurotic space under the extensor tendons (8-1B).

**If localized tenderness persists for >48h, don't wait for fluctuation.** Drain it through a longitudinal incision over the point of greatest tenderness.

## 8.12 Flexor tendon sheath infection

The sheaths of the flexor tendons in the hand lie nearest to the skin as they pass under the flexor creases of the fingers. It is here, and particularly over the distal flexor crease, that they are most often punctured and infected. They can also be infected by spread from a pulp infection. The sheaths of the little finger and thumb (and occasionally those of the other fingers also) extend proximally into the palm, and so provide a path through which infection can spread.

**If an infected tendon sheath bursts,** it does so into the mid-palmar space, through one of the lumbrical canals.

*N.B.* (1) An infected tendon may later stick to its sheath and make a finger stiff.

*N.B.* (2) If pressure inside a sheath exceeds that in its vessels, which can occur if drainage is delayed, the tendon will become ischaemic and slough.

**If infection is localized or one area is maximally infected,** *staphylococci* are the usual cause. Only one segment of the finger is swollen, so that distinguishing a localized tendon sheath infection of this kind from an infection of one of the middle palmar and thenar spaces can be difficult (8.9).

**If infection is fulminating,** *streptococci* are usually responsible, and the whole finger is swollen, sausage-shaped and acutely tender, without becoming red. The swelling extends into the distal palm. The finger remains partly flexed, except perhaps for a little movement at its mcp joint.

*The danger when you open a tendon sheath is that you may cut the digital nerves.* So study where these run in the cross-section of the finger (8-6G). Either approach a tendon laterally, well towards the dorsum, or from the palm. The danger area is the 'palmo-lateral' region. The other nerve which is in danger is the motor branch of the median nerve as it curves round the distal end of the flexor retinaculum and the tubercle of the trapezium.

Adjust your incisions to the severity of the infection. You can approach an infected tendon sheath:

(a) along the side of a finger towards the dorsum (8-6B: incision 7).

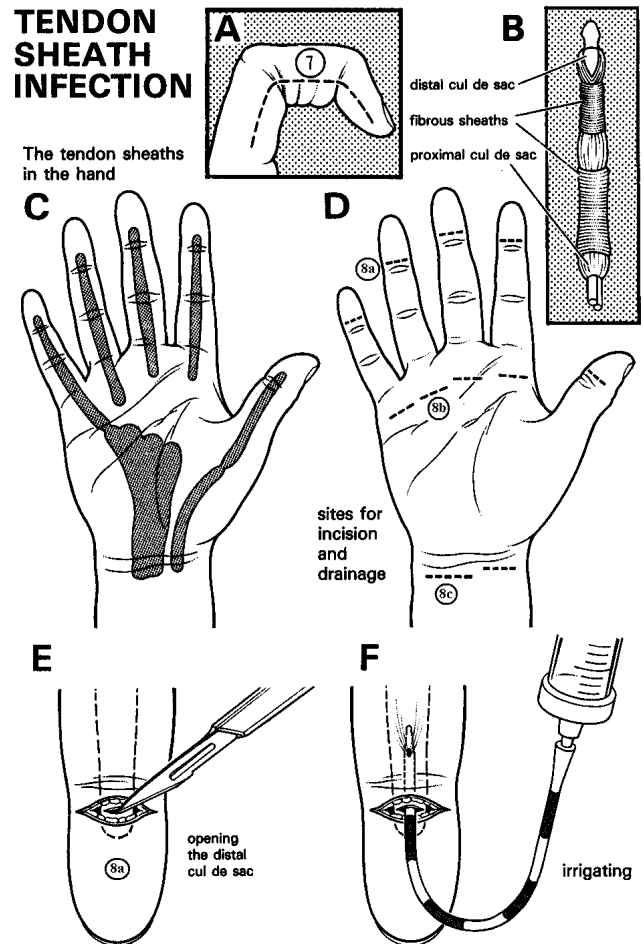
(b) through several transverse palmar incisions (8-7D: incision 8).

(c) by zig-zag cuts on the palm (8-6B: incision 9); these give the best exposure, but take longer to heal. Incisions 7 and 8 are for less severe infections.

Tendon sheath infections are common in leprosy (32.18), where loss of sensation allows neglect of an infection until it has destroyed the tendon sheaths themselves.

### EXPOSING THE TENDON SHEATHS

Start by opening the soft tissue over the involved segment through a small lateral incision (8-7A: incision 7). Examine the synovial sheath. If there is any sign of infection (redness or thickening), open the sheath itself and look carefully at the fluid. If there is much fluid, it is probably infected; if it is even a little cloudy, it is certainly infected.



**Fig. 8-7 INFECTIONS OF THE TENDON SHEATHS.**

A, lateral incision for opening an infected tendon sheath (incision 7). B, anatomy of a tendon sheath, to show the fibrous pulleys opposite the shafts of the phalanges. C, surface markings of the tendon sheaths. D, transverse incisions for draining tendon sheaths (incisions 8a,b). E, open the distal *cul-de-sac* (incision 8a). F, irrigate the tendon sheath. E, F, After Rintoul RF (ed) Farquharson's *Textbook of Operative Surgery* Churchill Livingstone 7<sup>th</sup> ed 1986 Fig. 317-8 with kind permission.

**If a sheath is infected,** make several incisions over the finger(s) and distal palm (8-7D,E: incisions 8a,8b). Hold the sheath open with hooks and retractors. Using a stiff catheter, syringe the sheath with sterile water (8-7F).

**If a sheath is infected in the palm (as is usual with the little finger and thumb),** make a further incision (8-7D: incision 8c) at the wrist, and repeat the irrigation, inserting the catheter through the palmar incision.

**If the tendon sheaths are grossly infected**, operate urgently. Open the sheath by a zig-zag incision on the volar surface of the finger (8-6B: incision 9a,9b). Do this in 2 stages. First cut along the solid lines and then, if necessary, join up these incisions by cutting along the dotted lines. Cut the flaps in the palm larger than those in the fingers, and make them follow the skin creases where possible. Cut through the skin and open the tissues with scissors. Leave bridges of the sheath over the joints to act as pulleys to prevent the tendons prolapsing.

*CAUTION! Don't take the incisions laterally where they may injure the neurovascular bundles.*

Wash out the pus with water. *Don't close the incision;* the flaps will heal by granulation to leave a linear scar.

**If a tendon has become a grey slough**, extend the incision, withdraw the dead part into the wound, and excise it. Preserve its sheath and pulley. Allow the wound to heal. If the hand settles well, it may be possible to insert a tendon graft later. This will be worthwhile only if the joints of the fingers are mobile. So, as soon as the swelling is starting to settle, start intensive physiotherapy, both by the patient himself and by a physiotherapist: *this is important!* If the finger remains stiff, try to persuade that it should be amputated (35.4) as a stiff finger can be a severe handicap.

**If a tendon and its sheath are extensively disorganized**, amputate the finger. *If you don't do so:*

- (1) infection may spread and cause further damage,
- (2) when the finger heals, it will be stiff, and cause considerable disability by impairing the grip of the other fingers (35.4).

*N.B. A stiff thumb is much better than no thumb, so don't amputate the thumb.*

**If the palm is seriously infected**, divide the flexor retinaculum to free the tendons. Approach this either:

- (a) through a longitudinal incision 1cm to the ulnar side of the scaphoid tubercle. Make a 5cm longitudinal incision over the retinaculum. Keep to the ulnar side of the median nerve and its ulnar branch (8-6G: incision 10), or
- (b) as shown for the ulnar bursa (8-6A: incision 3).

#### **AN UNNECESSARY INCISION IS BETTER THAN A LOST FINGER**

### **8.13 Ulnar bursa infection**

Infection of the ulnar bursa is the most serious hand infection, because it contains all the flexor tendons of the fingers. The whole hand is oedematous, the palm is moderately swollen, and there may be a fullness immediately above the flexor retinaculum. The flexed fingers resist extension, particularly the little finger, and least of all, the index. The radial and ulnar bursa sometimes communicate with one another. So if one of them has been infected, infection may follow in the other a day or two later.

Open the tendon sheath of the little finger with palmar flaps (8-6B: incisions 9a and if necessary 9b).

Incise the skin and deep fascia over the antero-medial side of the 5<sup>th</sup> metacarpal (8-6A: incision 3). Separate the *abductor* and *flexor digiti minimi* muscles from the bone. Retract them forwards and you will see the *opponens digiti minimi* muscle. Divide this close to its attachment to the flexor retinaculum.

Divide the flexor retinaculum deep to *opponens digiti minimi*: you will see the bulging ulnar bursa. Wash this out, as for a tendon sheath infection (8.12).

You can also drain the mid-palmar space through this incision (8.9).

### **8.14 Radial bursa infection**

The radial bursa is a continuation of the tendon sheath of the *flexor pollicis longus*, so that any infection inevitably involves both of them. The distal phalanx of the thumb is flexed and rigid. Extension of the thumb is impossible but extension of the other fingers is possible. The hand is tender over the sheath of *flexor pollicis longus*, and you may be able to feel a swelling above the flexor retinaculum. If treatment is delayed, infection may spread to the ulnar bursa, or the tendon of *flexor pollicis longus* may slough.

Incise the radial bursa (8-6B: incision 11) along the proximal phalanx of the thumb. Open it at its distal end; pass a probe proximally towards the wrist, and make a 2<sup>nd</sup> incision over its proximal end (8-6B: incision 12). Insert a fine catheter down the sheath and irrigate it with water.

*CAUTION! Don't incise along the radial border of the first metacarpal.* Dissecting among the muscles there may impair the ability to bring the thumb across the palm.

### **8.15 Septic arthritis of the finger**

The finger joints are easily infected from open wounds, or from nearby infections. A human bite into a joint is particularly dangerous. The infected joint is acutely tender, swollen and painful. An early sign is if twisting the joint is painful. Its ligaments, cartilage, and bone are soon involved, so that inevitably the result is a stiff joint. A stiff dip joint is little disability, but a stiff mcp or pip joint produces a severely disabled finger which is probably better amputated.

Treat with cloxacillin or chloramphenicol *and* metronidazole; but this is less important than drainage and an efficient surgical toilet.

Open the joint immediately, especially if there is a wound over it. If the edges of the wound are not obviously infected, excise their extreme margins. Examine the extensor tendon.

***DON'T AMPUTATE THE THUMB***  
(except in extreme circumstances)

If you have not divided the extensor tendon, enter the dorsolateral aspect of the joint and retract it to the opposite side. Look inside the joint. Remove any debris and loose bits of cartilage or bone. Syringe it out with water. Leave the skin wound open for delayed primary closure.

If you had to divide the extensor expansion, repair it when you have drained the pus. Immobilize the joint in the position of function (7.17), in case it stiffens, *not the position of safety*.

If the finger (but not the thumb) is stiff, consider amputation (35.4) in an adult, but *not in a child!*

## SEPTIC ARTHRITIS

Acute suppurative arthritis with a sinus

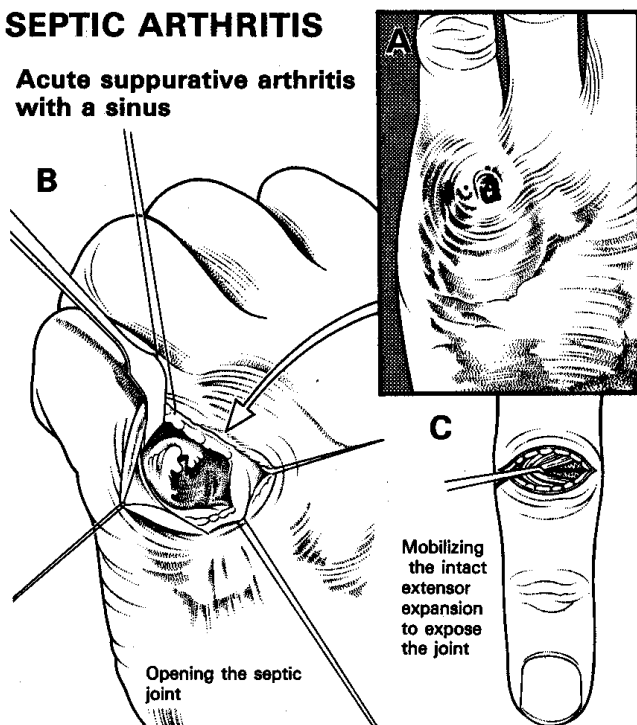


Fig. 8-8 SEPTIC ARTHRITIS.

A, acute suppurative arthritis presenting with a sinus. B, explore the lesion. C, mobilize an intact extensor tendon to expose a suppurating pip joint.

After Bailey DA, *The Infected Hand*, HK Lewis 1963 Figs 65-67, with kind permission.

## 8.16 Difficulties with hand infection

Hand infections, particularly if they are not well treated, can cause many problems.

If, a few hours after a minor scratch, the hand becomes hot and shiny, red lines spread up the arm, and there are rigors, tachycardia, and severe headaches, this is lymphangitis progressing to streptococcal bacteraemia and septicaemia. Treat with IV chloramphenicol or cloxacillin, and if an abscess or gangrene forms later, incise or deslough the hand.

If the hand has been infected as the result of a human or animal bite, perform an efficient wound toilet under a tourniquet, excise all tissue of doubtful viability, and leave the wound open. Treat with chloramphenicol or cloxacillin and metronidazole.

There is great danger of a serious infection, particularly with anaerobes. If you treat early, recovery is likely with a useful, mobile hand. If presentation is late (8-9), it will remain stiff, especially if a joint or a tendon sheath is involved. When the infection is controlled, amputate the stiff useless finger (35.4).

If swelling and tenderness spread above the wrist, pus has probably tracked proximally behind the flexor tendons up the arm into the space of Parona, as a result of a neglected palmar infection (8.9). Drain it (8-6A: incision 6).

If there are exposed joints or tendons after a hand infection, leave them open for c.1wk until the infection is controlled. Raise the hand in a roller towel, and start movements as soon as pain permits. When healthy granulations have appeared, try to get tissue cover by using an abdominal wall or groin flap.

If osteomyelitis develops, continue antibiotic treatment, immobilize the hand in the position of function. Get a radiograph 2wks later and remove sequestra through dorsal incisions as necessary. Osteomyelitis of the distal phalanx is common in untreated pulp infections (8.5), and can follow other hand infections. You may eventually have to amputate the infected finger.

## DISASTER WITH AN INFECTED FINGER

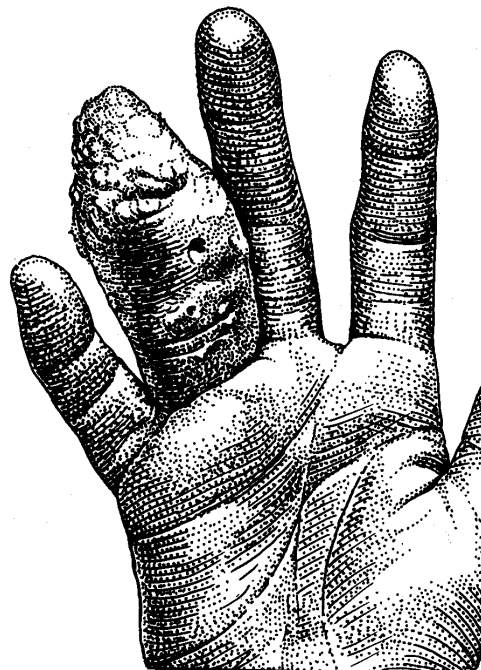

Fig. 8-9 DISASTER WITH A HUMAN FINGER BITE.

The wound entered the dip joint, which became infected. The finger might have been saved by an efficient wound toilet soon after the injury. Amputation is advisable in this case (35.4).

After Bowesman, C. *Surgery and Clinical Pathology in the Tropics* Livingstone. 1960, permission requested.

**If it involves a metacarpal** (uncommon), treat this as if it were any other long bone. Approach it through a dorsal incision, and reflect the extensor tendons. Approach the middle and lateral phalanges through mid-lateral incisions.

**If it involves a distal phalanx**, this will usually present at the finger tip. Cut it off with a bone nibbler.

**If discharge and pain persist**, this is from:

- (1) Inadequate drainage and desloughing.
- (2) Osteomyelitis.
- (3) Spread of a more superficial infection to a tendon sheath, or another fascial space.
- (4) Sloughing of a tendon.
- (5) A foreign body.

**If an adult's finger continues to be painful and discharge because of osteomyelitis or established septic arthritis of an mcp or pip joint**, consider amputation (35.4), because the proximal joints may become stiff too. A stiff dip joint is not much of a disability. Amputate at least through the joint proximal to the bone involved. *Don't merely remove part of the involved bone*, because the infection will spread. The thumb is an exception; spare as much bone as you can, and *don't amputate if you can avoid doing so*, because even a stiff stump of a thumb is better than no thumb at all.

**CAUTION!** A child is much more likely to regain some useful movement eventually, so *don't amputate* unless the finger remains stiff after infection has settled.

## 8.17 Pus in the foot

Foot infections are common, especially in communities where people don't wear shoes. Fine movements are not so important in the foot as they are in the hand, so that infection of the tendon sheaths of the foot is less of a disaster. *You must however drain septic arthritis and osteitis*, or persistent sinuses may follow.

Some foot infections are more complicated, e.g. osteomyelitis of the calcaneus and talus (7.12) and mycetoma (34.11). Diabetic and leprosy patients are particularly liable to foot infections (32.2), because of neuropathies.

### SUPERFICIAL INFECTIONS

Manage subcutaneous infections (8.2), apical toe space infections (8.3), paronychia (8.4), pulp infections (8.5) and web space infections (8.7) as in the hand. They are all fairly common.

For all but the most superficial infections, use a tourniquet (3.4), unless the circulation has been impaired by ischaemic disease.

DEEP INFECTION OF THE PLANTAR SURFACE OF THE FOOT is usually due to an injury, such as a thorn, which has penetrated deeply.

**If you suspect a foreign body**, incise the abscess, search for the foreign body and clean out the cavity thoroughly. Leave the wound open sufficiently for it to heal up from below.

**If infection is spreading on to the foot and up the leg**, explore and drain the lesion, and treat with an antibiotic suitable for the *staphylococci* in your area. As in the hand, rapidly spreading infections are likely to be due to haemolytic *streptococci*.

INFECTIONS OF THE DORSUM OF THE FOOT present early, and you can usually drain them through a small incision using LA.

INFECTIONS OF THE TENDON SHEATHS are uncommon except in leprosy, and when there is a foreign body involving the tendon sheath. Incise over the infected part, drain it, and leave the wound open. In a late case you may need to remove necrotic tendon.

SEPTIC ARTHRITIS can involve any joint.

**If a pip or dip joint is involved**, open it widely through a longitudinal incision on the dorsal surface to one side of the extensor tendon. Clean it out and leave it open to drain.

**If an mcp joint is involved**, approach it either from the dorsal surface (open it from just one side of the extensor tendon), or from the plantar surface. Open the wound widely and let it drain. Wounds in the plantar surface heal well.

**If other joints are involved**, approach them from the side where the bone is nearest to the surface. Clean the joint out well and leave it open.

OSTEITIS. Treat with cloxacillin or chloramphenicol and remove necrotic bone as necessary in chronic cases.

**If the phalanges are involved**, drain the infection and it will probably settle. Osteitis commonly follows infection in the soft tissues, especially infections of the pulp of the distal phalanx.

**If the metatarsals are involved** (rare), there may be:

- (1) Osteomyelitis following an injury. Approach the bone through a dorsal incision and reflect the extensor tendons. Drain the wound and remove necrotic tissue. Loss of 1 or 2 metatarsals is of little functional importance.
- (2) Acute haematogenous osteomyelitis. In a child <10yrs, an antibiotic alone may be adequate. In a child >10yrs, the bone will also need drilling.
- (3) Chronic haematogenous osteomyelitis. This presents with persistent pain and sinuses. Remove necrotic bone, without waiting for the formation of an involucrum.

**CAUTION!** **If the foot becomes infected without obvious reason**, search carefully for:

- (1) A foreign body.
- (2) Diabetes.
- (3) HIV disease.
- (4) Ischaemia.
- (5) Leprosy (32.2).

Severe infection in these cases is best treated by below-knee (35.7), through-knee or above-knee amputation (35.6) as piece-meal debridement usually fails to control the sepsis and just prolongs the agony.

POST-OPERATIVELY, *stop weight-bearing.*

**If there is a severe infection,** apply a plaster gutter splint to hold the foot in neutral position. This will reduce pain and ensure that the foot is in the best position if it does become stiff.