

# Use Of Ethyl Alcohol Myoneural Blocks In Cerebral Palsy

Benjamin Joseph, Hitesh Shah, ND Siddesh  
Paediatric Orthopaedic Service  
Kasturba Medical College, Manipal, India

## Introduction

In cerebral palsy uncontrolled spasticity can lead to contracture of the affected muscle. In turn, this may result in joint deformity or dislocation with compromise of function of the limb. One of the ways of reducing spasticity is to use a myoneural block which temporarily weakens the muscle. This provides a window of opportunity for more effective physiotherapy and helps delay the need for surgical intervention. The most widely used medication for myoneural blockade is Botulinum A toxin. However, this drug is prohibitively expensive and far beyond the reach of most children with cerebral palsy in developing countries. An alternative to Botulinum toxin is 40% alcohol (1) and we have been using this routinely to reduce the spasticity in children with cerebral palsy for over 20 years.

## Indications

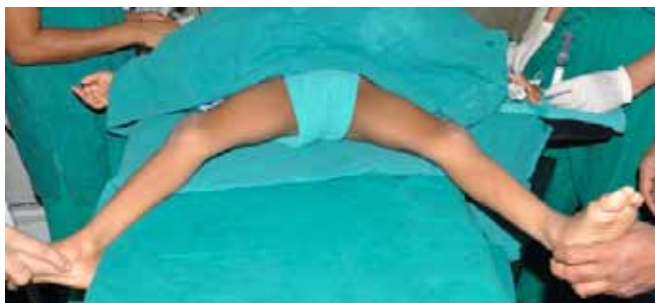The indication for a myoneural block with alcohol is exactly the same as that for Botulinum toxin; to reduce spasticity that is severe enough to produce a dynamic deformity that cannot be adequately treated by stretching, casting or bracing (2). Myoneural blockade is ineffective once a contracture has developed and hence is not indicated if a rigid deformity is present. We avoid the use of alcohol in the upper limb and restrict its use to treatment of lower limb spasticity. The muscles most frequently injected are the hip adductors, the hamstrings and the gastrocnemius.

## Technique

### Setup

The myoneural block with alcohol is done in the operating room with the child under anesthesia. The child is examined under anesthesia again to confirm that there is no contracture by demonstrating a full range of passive motion (Fig. 1).

Fig. 1. Passive abduction of the hips demonstrated while the child is anesthetized to ensure that there is no contracture of the adductor muscles before proceeding with the myoneural block.



## 2 Tips and Techniques

### Injection

Under sterile conditions 0.5 to 0.75ml (in older children) of 40% ethyl alcohol is injected into the muscle belly (Figs. 2 a, b, c.). The injection is guided by palpation of the muscle belly alone; we do not use nerve stimulation, ultrasonography or any other imaging to locate the site of injection.

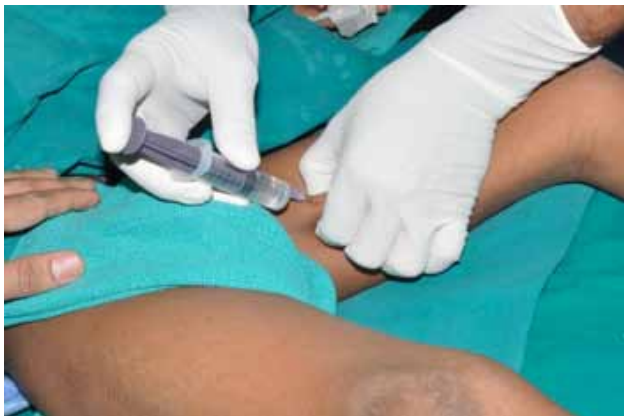

Fig. 2a. The adductor longus is palpated and alcohol is injected into the muscle belly.

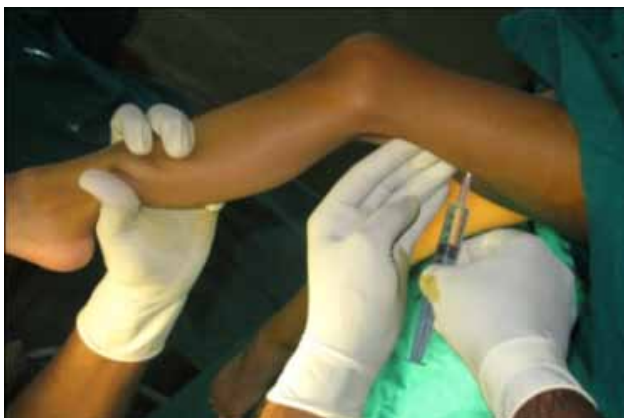

Fig. 2b. The biceps femoris is palpated and injected.

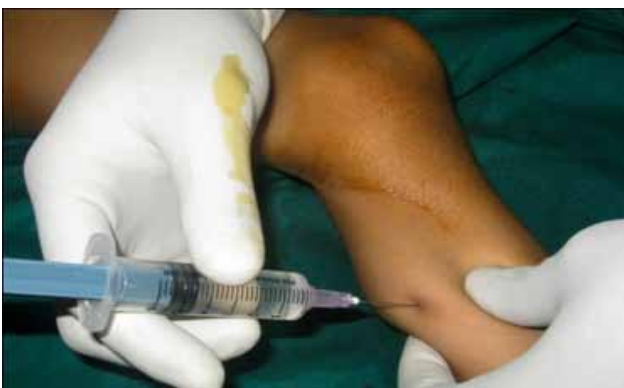

Fig. 2c. The bellies of the medial and lateral heads of the gastrocnemius are palpated and injected.

### 3 Tips and Techniques

#### Cast

A cast is applied with the injected muscle stretched (Fig. 3) and the child is sent home the next day. The cast is retained for 6 weeks; a short period of supervised physiotherapy and gait training in hospital is begun once the plaster is removed. Physiotherapy is continued at home thereafter. The effect of the injection (i.e. demonstrable reduction of spasticity) is noted as soon as the casts are removed and lasts for 6 to 9 months. The injection can be safely repeated after this period of time.

#### Adverse effects

Some children complain of pain at the site of the injection which usually responds to oral analgesic medication.

#### Method of preparation of 40% alcohol for injection

Absolute alcohol (100% pure ethyl alcohol) is diluted with distilled water, loaded into 10 ml vials and sealed under sterile conditions.

Cost of 10 ml of 40% alcohol: 30 cents (0.3 US \$).

**Example case:** This 7-year-old girl walked with scissoring on account of spasticity of the adductors and there is tendency for a mid-foot break with spasticity of the gastrocnemius muscle on both sides (Video before injection). When examined under anesthesia it was confirmed that these muscles were not contracted. 0.5ml of 40% alcohol was injected into the adductor longus and the medial and lateral heads of the gastrocnemius on either side; long leg casts were applied and retained for six weeks. The gait pattern after gait training for a week has improved; there is no scissoring and the feet are plantigrade (Video after injection).

[Click for Before Example \[Web Video\]](#)

[Click for After Example \[Web Video\]](#)

#### References

1. Carpenter EB, Seitz DG. Intramuscular alcohol as an aid in the management of spastic cerebral palsy. *Dev Med Child Neurol* 1980; 22: 497–501.
2. Cosgrove AP, Graham HK. Botulinum toxin A in the management of spasticity with cerebral palsy. *Br J Surg* 1992; 74:135–6.




Fig. 3. A broomstick cast is applied after blocks to the hip adductors.